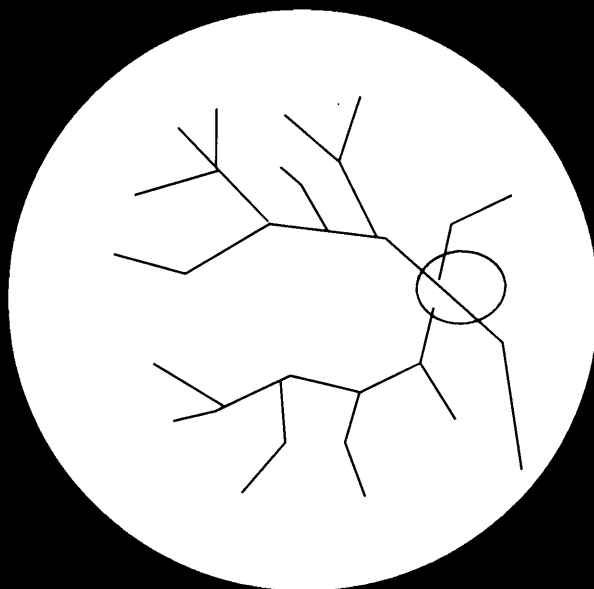


Retinal Diseases

2



R. Brancato

G. Coscas

B. Lumbroso

REPRINTS

Kugler & Ghedini

EVALUATION OF VISUAL OUTCOME AFTER LASER TREATMENT IN BRANCH RETINAL VEIN OCCLUSION COMPLICATED BY MACULAR EDEMA

S. PIERMAROCCHI, T. SEGATO and E. MIDENA

Centro per lo Studio ed il Trattamento della Retinopatia Diabetica e delle Vasculopatie Oculari, Institute of Ophthalmology, University of Padua, Italy

Introduction

Branch retinal vein occlusion (BRVO) is an important cause of visual loss among people over 50. After diabetic retinopathy, it appears to be the most frequent retinal vascular disorder. After the acute onset of the thrombosis, two symptomatic phases are commonly seen. In the acute phase visual symptoms are usually present when a temporal branch is involved; they can be due to macular hemorrhages, macular edema (MO) or macular ischemia. In the chronic phase retinal hemorrhages gradually reabsorb and collateral shunts develop; if present, retinal ischemia in the affected area becomes visible in this phase. In relation to the capillary non-perfusion, retinal neovascularization can be observed. These new vessels can easily produce vitreous hemorrhages. Furthermore, depending on the effectiveness of collateral vessels, different degrees of MO are present.

Many authors suggested a possible role of photocoagulation therapy in reducing progressive visual loss in the chronic phase of BRVO.¹⁻³ However, relatively few trials have been performed to date.⁴⁻⁶

Aim

The aim of this study is to evaluate the effectiveness of laser treatment in preserving visual function in a group of patients with BRVO complicated by MO.

Subjects and methods

Thirty-two subjects affected by BRVO complicated by MO, with or without neovascularization have been submitted to photocoagulation. Depending on the age of the thrombosis they were divided into two groups: group A included 17 patients with BRVO of relatively recent appearance; group B included 15 subjects with long-standing BRVO (Tables 1 and 2). Two main indications were considered for treatment: (1) MO with visual acuity (VA) less than 0.6; (2) MO associated with neovascularization. Both groups were compared with two control groups of subjects having BRVO with clinical features similar to those of the treated eyes, but not submitted to photocoagulation (Group Ac and Group Bc respectively). Informed consent was obtained. A blue-green 'Coherent' argon laser was used. 0.2 sec, 300 to 500 μm ,

Retinal Diseases-2

Proceedings of the Retina Workshop

held in Florence, Italy, May 2-3, 1986, pp. 97-101

© 1987 Kugler Publications—Amsterdam—Berkeley/Ghedini Editore—Milano

TABLE 1

	<i>Gr A</i>	
Time elapsed from the onset of BRVO up to the laser treatment		14 mo. (6–28 mo.)
Time elapsed from the laser treatment up to last control		14 mo. (5–37 mo.)
	<i>Gr Ac</i>	
Time elapsed from the onset of BRVO up to last control*		27.5 mo. (14–49 mo.)

* NB: Visual acuity at 14 months from the onset of BRVO is also available in this group.

TABLE 2

	<i>Gr B</i>	
Time elapsed from the onset of BRVO up to laser treatment		6.6 yr. (4.1–17.4 yr.)
Time elapsed from the laser treatment up to last control		1.7 yr. (0.3– 4.5 yr.)
	<i>Gr Bc</i>	
Time elapsed from the onset of BRVO		7.8 yr. (5–12 yr.)

scattered spots were applied to the affected retinal area where vascular abnormalities could be observed (non-perfused retinal areas and leaking capillary abnormalities). The eyes were re-evaluated three months after treatment with fluorescein angiography. Additional burns were applied if leaking areas and foveal edema persisted. A complete ophthalmological examination was periodically performed. Mean follow-up after treatment was 14 months (5 to 37 months) in Group A and 1.7 years in Group B (0.3 to 4.5 years). Only variations of two lines or more were considered significant. The chi-square test was used for statistical analysis.

Results

Group A vs Group Ac

Modifications of the visual acuity as regards improvement, worsening or no change of VA are described in Table 3. Similar results are obtained when subjects are distributed among three classes of VA (0.1 or less, 0.2 to 0.4, 0.5 or more) (Table 4).

Group B vs Group Bc

Modifications of visual function are summarized in Table 5. Distribution according to three classes of VA is shown on Table 6. In Group Bc no modification of VA was observed during the study.

TABLE 3
MODIFICATIONS OF VISUAL ACUITY AT THE END OF THE STUDY (GROUP A VS GROUP AC)

	<i>Improved</i>	<i>No change</i>	<i>Worsened</i>	
Group A	10(58.8%)	7(41.2%)	0	17(100%)
Group Ac	2(11.8%)	13(76.4%)	2(11.8%)	17(100%)

$p < 0.02$

TABLE 4
DISTRIBUTION OF SUBJECTS ACCORDING TO THREE CLASSES OF VISUAL ACUITY

		≤ 0.1	$0.2-0.4$	≥ 0.5	
Group A	VA at time of treatment	4(23.5%)	8(47%)	5(29.5%)	17(100%)
	VA after treatment	2(11.8%)	5(29.5%)	10(58.7%)	17(100%)
Group Ac	VA at 14 months	4(23.5%)	8(47%)	5(29.5%)	17(100%)
	VA at 27.5 months	4(23.5%)	8(47%)	5(29.5%)	17(100%)

N.S.

TABLE 5
MODIFICATIONS OF VISUAL ACUITY AT THE END OF THE STUDY (GROUP B VS GROUP BC)

	<i>Improved</i>	<i>No change</i>	<i>Worsened</i>	
Group B	4(27%)	10(67%)	1(6%)	15(100%)
Group Bc		20(100%)		20(100%)

$p < 0.02$

TABLE 6
DISTRIBUTION OF SUBJECTS ACCORDING TO THREE CLASSES OF VISUAL ACUITY

		≤ 0.1	$0.2-0.4$	≥ 0.5	
Group Bc	VA at time of treatment	6(40%)	5(33%)	4(27%)	15(100%)
	VA after treatment	7(47%)	2(13%)	6(40%)	15(100%)
Group Bc	VA during the study	7(35%)	9(45%)	4(20%)	20(100%)

N.S.

Discussion

The appearance of a BRVO on the temporal side usually corresponds to a significant decrease of VA.

During the recovery phase, a partial recanalization of the occluded vein and the formation of collateral shunts produce an improvement in blood circulation in the affected retina. This fact, along with the reabsorption of retinal hemorrhages, determines a spontaneous increase of VA. During the chronic phases late complications

TABLE 7

VISUAL ACUITY MODIFICATION IN RELATION TO THE INTEGRITY OF PERIFOVEAL RETINAL CAPILLARIES

	<i>Improved</i>	<i>No change</i>	
Little or no change of PRC	9(69.2%)	4(30.8%)	13(100%)
Heavy changes of PRC	1(25%)	3(75%)	4(100%)

N.S.

usually take place, *i.e.*, MO and retinal neovascularization. MO can lead to a slow and time-dependent deterioration of visual function. To evaluate the possible role of laser treatment, a controlled trial is consequently needed. In our study we have separated BRVO of relatively recent appearance (Group A and Group Ac) from long-standing BRVO (Group B and Group Bc). According to many authors^{4,7,8} laser treatment was considered at least six months after the acute onset of the thrombosis.

If extensive treatment was required, photocoagulation was distributed in two sessions, to avoid excessive retinal reaction. In the first session laser burns were applied to the posterior part of the affected area. According to our experience this can protect the macular zone from reactive edema when extensive treatment is subsequently given to the remaining retina. In our study a significant improvement has been observed in the treated groups compared with control groups. The integrity of perifoveal retinal capillaries seems to be of particular importance. Those patients with breakdown of perifoveal capillaries showed little or no improvement of visual function (Table 7). Even though some positive results have been registered, less evident visual changes have been observed in Group B. Considering the duration of the retinal changes, the mean follow-up is relatively short. This fact does not allow us to draw final conclusions on the effectiveness of laser treatment in obtaining visual improvement by resolving MO in this stage of the disease. In our opinion, better responses to photocoagulation can be expected in early retinal changes than in older steady thrombosis. However, there is no evidence in our study to confirm this hypothesis. Apart from a transient increase of MO in some eyes, no other significant complication has been described. In our study no case of visual loss was due to vitreous hemorrhage. Evolution of new vessels was not one of the objects of the study.

Conclusions

From this study we can conclude that laser treatment is effective in maintaining good VA when MO is of relatively recent appearance. Further investigations are required to evaluate the role of photocoagulation in long-standing BRVO.

ACKNOWLEDGEMENT

Study supported by funds of the Italian Ministry of Public Instruction.

REFERENCES

1. Demeler U: Management of retinal venous occlusion. *Ophthalmologica (Basel)*, 180:61–67, 1980
2. Gutman F: Macular edema in BRVO: Prognosis and management. *Trans Am Acad Ophthalmol Otorhinol* 83:488, 1977
3. Gutman F, Zegarra H: The natural course of temporal retinal branch vein occlusion. *Trans Am Acad Ophthalmol Otorhinol* 78:178, 1974
4. Wetzig P: The treatment of acute BRVO by photocoagulation. *Am J Ophthalmol* 87:65–73, 1979
5. The branch vein occlusion study group: argon laser photocoagulation for macular edema in BRVO. *Am J Ophthalmol* 98:271–282, 1984
6. Gutman F, Zegarra H et al.: Photocoagulation in BRVO. *Ann Ophthalmol* 13:1359–1363, 1981
7. Campbell C, Wise G: Photocoagulation therapy of BRVO. *Am J Ophthalmol* 75:28–31, 1973
8. Laatikainen L: Photocoagulation in retinal vein occlusion. *Acta Ophthalmol* 55:478–488, 1977