

Sonovaginography is a new technique for assessing rectovaginal endometriosis

Salvatore Dessole, M.D.,^a Mario Farina, M.D.,^a Giovanni Rubattu, M.D.,^a
Erich Cosmi, M.D.,^a Guido Ambrosini, M.D.,^b and Giovanni Battista Nardelli, M.D.^b

University of Sassari, Sassari, and University of Padua, Padua, Italy

Objective: To evaluate the efficacy of a new technique, the sonovaginography, for the assessment of rectovaginal endometriosis.

Design: Prospective study.

Setting: University hospital.

Patient(s): Forty-six women were scheduled for laparotomic or laparoscopic surgery because of rectovaginal endometriosis suspected on the basis of patient history and/or clinical examination.

Intervention(s): Before surgery, all the women underwent transvaginal ultrasonography and then sonovaginography. The latter is based on transvaginal ultrasonography combined with the introduction of saline solution to the vagina that creates an acoustic window between the transvaginal probe and the surrounding structures of the vagina. Ultrasound findings were compared with the results of surgical exploration and histological examination.

Main Outcome Measure(s): We assessed the accuracy of transvaginal ultrasonography and of sonovaginography for the detection and the location and extension assessment of rectovaginal endometriotic lesions, as well as compared patient compliance between the procedures.

Result(s): Sonovaginography diagnosed rectovaginal endometriosis more accurately than did transvaginal ultrasonography, with a sensitivity and specificity of 90.6% and 85.7%, respectively, whereas the transvaginal ultrasonography has shown a sensitivity and specificity of 43.7% and 50%, respectively. Patient discomfort did not differ significantly between the procedures.

Conclusion(s): Sonovaginography is a reliable and simple method for the assessment of rectovaginal endometriosis and provides information on location, extension, and infiltration of the lesions, which are important factors in selecting the kind of surgery. (Fertil Steril® 2003;79:1023–7. ©2003 by American Society for Reproductive Medicine.)

Key Words: Rectovaginal endometriosis, transvaginal ultrasonography, sonovaginography (SVG)

Received May 22, 2002;
revised and accepted
December 8, 2002.

Reprint requests: Salvatore
Dessole, M.D., Department
of Pharmacology,
Gynecology and
Obstetrics, University of
Sassari, 100 Viale San
Pietro 12, Sassari, Italy
(FAX: 39-07-9228265; E-
mail: dessole@uniss.it).

^a Department of
Pharmacology, Gynecology
and Obstetrics, University
of Sassari.

^b Department of
Gynecology and
Obstetrics, University of
Padua.

0015-0282/03/\$30.00
doi:10.1016/S0015-0282(02)
04952-X

Rectovaginal septum endometriosis occurs infrequently (1) and represents the deepest and most severe form of endometriosis (2). Deep pelvic endometriosis is defined as an endometriotic lesion infiltrating the retroperitoneal space to a depth of ≥ 5 mm and is considered a specific entity that is extremely active and tends to develop with time (3–5).

Transvaginal ultrasonography can detect endometriotic foci, but its sensitivity is poor for the diagnosis and workup of posterior pelvic lesions (6, 7). Transabdominal ultrasonography, transvaginal ultrasonography, rectosigmoidoscopy, as well as computerized tomography and nuclear magnetic resonance, may not accurately assess the extension of endo-

metriosis into the rectovaginal septum (8). Furthermore, laparoscopy sometimes fails to estimate the extension of an endometriotic lesion in the rectovaginal septum (9). The transrectal ultrasonography has been shown to be an efficient method for assessing rectovaginal endometriosis, with a high sensitivity and specificity (10, 11).

On the basis of our experience with sonohysterography (12), we are introducing a new technique to assess rectovaginal endometriosis, the sonovaginography.

In this study we report the data for this new technique in the detection and the location and extension assessment of endometriotic lesions in the rectovaginal septum.

MATERIALS AND METHODS

From January 2000 to October 2001, 46 women were prospectively enrolled in the study. All were scheduled for laparotomic or laparoscopic surgery because rectovaginal endometriosis was suspected based on patient history and clinical examination. The mean age of the study group was 30.3 ± 4.2 years; the mean height and weight were 162.5 ± 6.5 cm and 57.6 ± 9.2 kg, respectively; the mean body mass index was 21.4 ± 3.9 kg/m².

None of the patients had undergone a surgical pelvic procedure before entering the study. Six patients received medical treatment for a period of 3 to 6 months: four were treated with GnRH analogues (Triptorelin, Decapeptyl; Ipsen Biotech, Paris, France) and two with Danazol (Danatrol; Sanofi-Synthelabo SPA, Milano, Italy). The treatment was interrupted in all of these patients ≤ 6 months before the patient was enrolled in the study.

Thirty-eight women were referred because of chronic pelvic pain, dysmenorrhea, or dyspareunia, and 8 women were enrolled because an endometriotic lesion was detected during a routine gynecologic examination. Among the study group, 20 women presented infertility problems, 7 presented with gastrointestinal disorders, and 6 presented with urinary disorders.

Informed consent was obtained from each patient, and the institutional review board and local hospital ethics committee approved the study.

In the ultrasound study, all patients were scheduled for transvaginal ultrasonography and for sonovaginography using a Siemens Sonoline 1 (Erlangen, Germany) with a transvaginal, 5- to 7.5-MHz probe.

In the transvaginal ultrasound examination, the operator obtained longitudinal and transversal scans of the uterus, and particular attention was given to the rectovaginal septum for the detection of endometriotic lesions.

The sonovaginography examination consisted of transvaginal ultrasonography combined with the introduction of saline solution to the vagina. Each patient was asked to partially empty her bladder, thus leaving a small amount of urine within to enhance visualization of the anterior vaginal wall and of the vesicovaginal septum during the procedure.

The patient sat in a gynecological position, and the reclining seat was slightly angled upward to avoid saline solution reflux from the vaginal channel during the procedure. A 24-mm Foley catheter then was introduced into the vagina, and its balloon was inflated using 5–6 mL of saline solution.

An operator and an assistant were required to perform each examination for the study. The operator inserted the transvaginal probe into the vagina, using the right hand to handle the probe. The operator closed the vaginal channel with the left hand, narrowing the minor labia with the dorsal

surface of the forefinger and the middle finger. This was necessary to prevent the reflux of saline solution from the vagina. The assistant injected 200–400 mL of saline solution through a Foley catheter and operated the ultrasound machine. Sometimes the entire procedure was videotaped.

The solution, once in the vaginal channel, created an acoustic window between the transvaginal probe and the surrounding structures of the vaginal channel. Moreover, the saline solution exerted a pressure in the vaginal channel that distended the vaginal walls, permitting enhanced visualization of the vaginal walls, vaginal fornix, uterosacral ligaments, pouch of Douglas, rectovaginal septum, and vesicovaginal septum.

The transvaginal probe was not in contact with the portio but was placed in a position different from that of the traditional transvaginal scan, thus allowing the operator to analyze the structures between the probe and the acoustic window created. The operator obtained ultrasound scans by moving the transvaginal probe back and forward, longitudinally and transversally, with up, down, and angled movements around the portio, which was used as a reference point (Fig. 1).

With this technique, endometriotic lesions were detected as hypoechoic, irregular structures at the level of the vaginal wall; they often infiltrated the surrounding structures and the uterosacral ligaments. Once an endometriotic lesion was detected, its location, size, extension, and infiltration were evaluated.

On the basis of the images collected, we classified the endometriotic lesions as follows (Fig. 2): esophitic, infiltrating, plaque, and mixed lesion.

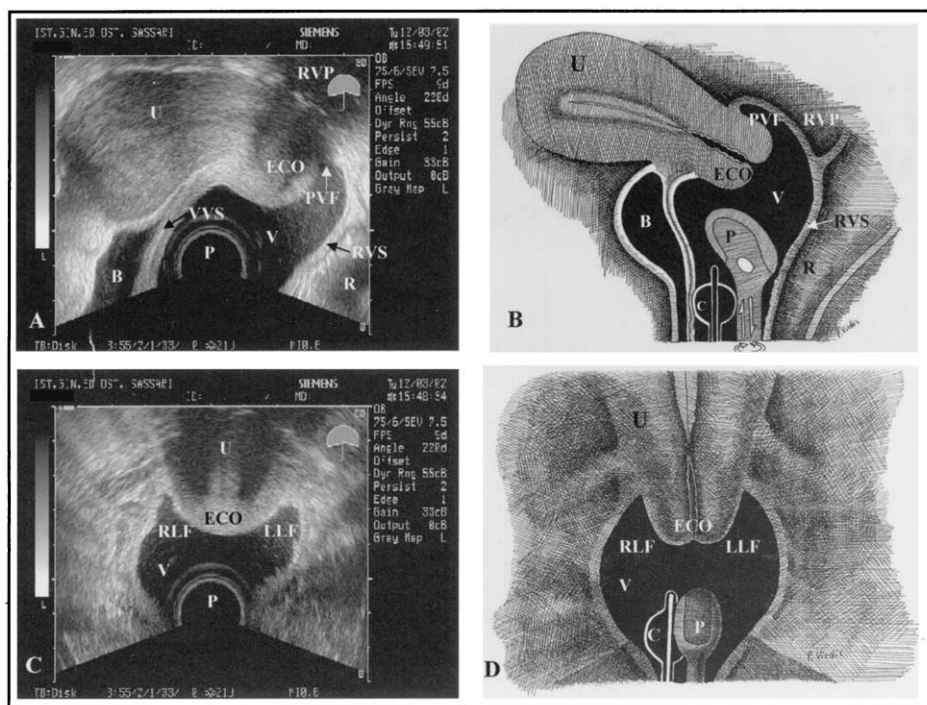
Esophitic lesions were defined as structures originating from the vaginal wall and protruding into the vaginal channel; infiltrating lesions were structures extending through the vaginal wall, reaching the vesicovaginal or rectovaginal septum and/or Douglas pouch. Plaque lesions were defined as structures confined to within the vaginal wall. Mixed lesions were those that presented more than one of the above lesions' characteristics.

The degree of discomfort that the patient experienced during the procedure was assessed using a 10-point rating scale, with 1 denoting no discomfort at all and 10 denoting severe discomfort (13). At the end of each exam, the operator recorded the discomfort score as stated by the patient.

After the ultrasound study, all patients underwent colposcopy, and a biopsy at the level of the posterior fornix was performed in 8 patients in whom an endometriotic lesion had been detected during the gynecological evaluation.

The entire study group underwent surgery. The kind of operation was chosen on the basis of clinical and transvaginal ultrasonographic findings: laparoscopy was performed when rectovaginal endometriosis was suspected; a lapa-

Anatomical view of lower pelvis structures including the rectovaginal septum. (A), Sonovaginographic longitudinal scan showing the following structures: bladder (B), vesicovaginal septum (VVS), uterus (U), cervix and external os (ECO), posterior vaginal fornix (PVF), rectovaginal pouch (RVP), rectovaginal septum (RVS), and rectum (R). V = vaginal channel distended by saline solution; P = ultrasound probe; C = catheter. (B), Schematic representation of a sonovaginographic longitudinal scan and the structures detected by this technique. (C), Sonovaginographic transversal scan in which the cervix and left and right lateral fornix are visualized. LLF = left lateral fornix; RLF = right lateral fornix. (D), Schematic representation of a sonovaginographic transversal scan and the structures detected by this technique.



Dessole. Sonovaginography. *Fertil Steril* 2003.

rotomic approach was chosen in all patients who had intestinal and/or urinary involvement suspected on a clinical and/or radiologic basis and in patients in whom a frozen pelvis was suspected. During surgery, location, extension, and infiltration of endometriotic lesions were evaluated; biopsy and histological examination were also carried out.

The ultrasound findings of the study were compared with the results of surgical exploration and histological examination. Sensitivity, specificity, and positive and negative predictive values (PPV and NPV) of transvaginal ultrasonography and of sonovaginography were calculated in the diagnosis of rectovaginal endometriosis and the capability to assess the location and extension of the lesions.

Independence among the two methods was assessed using the χ^2 test. Statistical significance was set at $P < .05$.

RESULTS

Among 46 patients, 20 underwent laparoscopic surgery and 26, laparotomic surgery. Intraoperative assessment

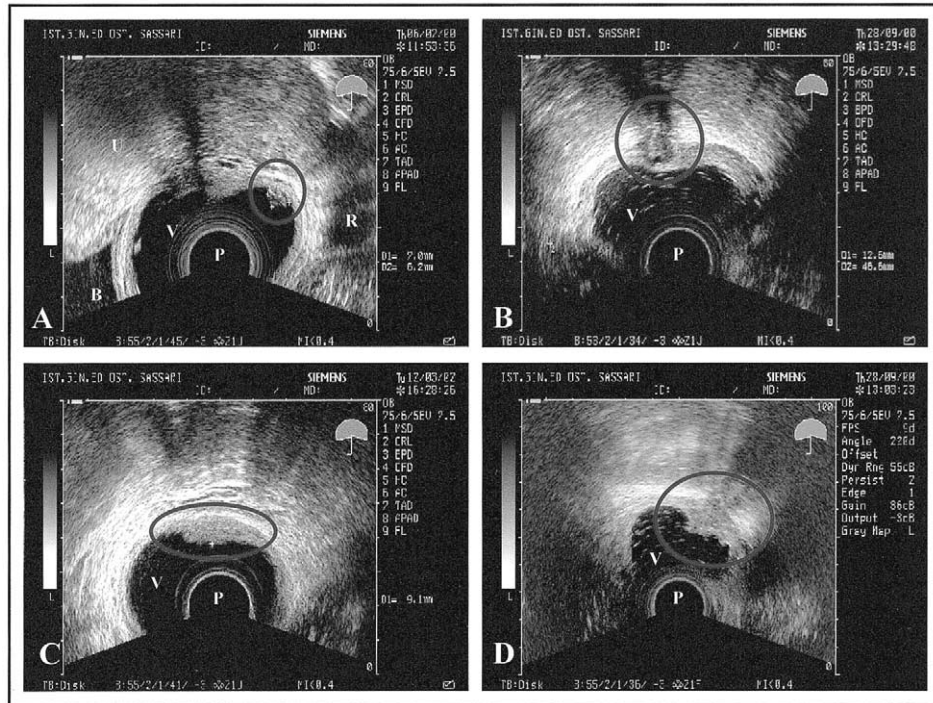
showed no endometriotic lesions in 6 patients, pelvic endometriosis (superficial peritoneal and/or ovarian sites) in 8 patients, and rectovaginal endometriosis, confirmed by pathologic findings, in 32 (69.5%) patients. In the latter group, vaginal wall infiltration was confirmed in 22 patients and rectal wall infiltration in 3 patients, and one or both the uterosacral ligaments were involved in 7 patients.

Transvaginal ultrasonography detected rectovaginal endometriosis in 14 (43.7%) of 32 cases, vaginal wall infiltration was diagnosed in 10 (45.4%) of 22 cases, rectal wall extension was diagnosed in 1 (33.3%) of 3 cases, and uterosacral ligament involvement was diagnosed in 2 (28.5%) of 7 cases.

Sonovaginography detected rectovaginal endometriosis in 29 (90.6%) of 32 patients; these lesions then were confirmed by intraoperative exploration and histopathological diagnosis. In 12 (85.7%) of 14 cases, rectovaginal endometriosis was excluded. Vaginal wall infiltration was diagnosed in all 22 cases; rectal wall infiltration was diagnosed in 2 (66.6%)

FIGURE 2

Classification of endometriotic lesions. (A), Esophitic endometriotic lesion detected at the level of the posterior vaginal wall (longitudinal scan). B = bladder; U = uterus; R = rectum; V = vaginal channel distended by saline solution; P = ultrasound probe. (B), Infiltrating endometriotic lesion visualized at the level of the vaginal wall and the posterior fornix. The thickness of the left vaginal wall is greater than that of the right as a result of the lesion (transversal scan). (C), Endometriotic plaque lesion visualized at the level of the posterior vaginal wall (transversal scan). (D), Mixed endometriotic lesion at the level of the posterior fornix with the characteristics of an esophitic lesion, infiltrating the uterosacral ligament (transversal scan).



Dessole. Sonovaginography. *Fertil Steril* 2003.

of 3 cases; and uterosacral ligaments were involved in 5 (71%) of 7 cases. In one patient, an endometriotic lesion has been detected at the level of the anterior vaginal fornix.

The sensitivity, specificity, PPV, and NPV of transvaginal ultrasonography were 43.7% (14/32), 50% (7/14), 66.6% (14/21), and 28.0% (7/25), respectively. The sensitivity, specificity, PPV, and NPV of sonovaginography were 90.6% (29/32), 85.7% (12/14), 93.5% (29/31), and 80.0% (12/15), respectively. Sonovaginography diagnosed rectovaginal endometriosis more accurately than did transvaginal ultrasonography ($P < .001$). Patient discomfort did not differ significantly between transvaginal ultrasonography and sonovaginography (ratings: 5.4 ± 1.4 vs. 5.6 ± 1.6 , respectively).

DISCUSSION

Several studies have reported the effectiveness of transrectal ultrasonography in the diagnosis of deep pelvic endometriosis, and in particular of rectovaginal endometriosis, with a sensitivity of 97%–100% (10, 11).

In this study, starting from the basis of our experience in the use of sonohysterography (12), we decided to introduce sonovaginography, in which a saline solution is introduced to the vaginal channel. In this way, the acoustic window is formed between the transvaginal probe and the surrounding structures of the vaginal channel, that is, the vaginal fornix, the vaginal walls, rectovaginal septum, the uterosacral ligaments, and vesicovaginal septum.

The low sensitivity (43.7%) and specificity (50%) of transvaginal ultrasonography suggest that this technique is not a reliable method in the assessment of rectovaginal endometriosis.

The results of the sonovaginography, compared with surgical and pathologic findings, enabled the detection of rectovaginal endometriosis with high sensitivity (90.6%); moreover, it showed satisfying sensitivity in evaluating the location and extension of the different types of endometriotic lesions in the vaginal wall (100%). Furthermore, patient compliance was similar in both techniques.

These results show that introduction of sonovaginography is a reliable method for the assessment of rectovaginal endometriosis: it is simple in its performance and provides information on location, extension, and infiltration of endometriotic lesions in the rectovaginal septum, which are important in selecting the kind of surgery.

This technique can also distinguish those lesions that are not placed in the true rectovaginal septum but in the vaginal portion of the rectovaginal pouch (14) (Fig. 1B). Moreover, a slight distension of the bladder creates a further acoustic window, which allows more accurate visualization of the anterior vaginal wall and of vesicovaginal septum.

This study may be criticized because of the small number of patients included, but rectovaginal endometriosis is a relatively rare condition, and these preliminary results strongly encourage the use of this technique in the assessment of rectovaginal endometriosis, with good sensitivity and specificity. Further studies are necessary to confirm these data in a larger sample size to address this new, simple, and quick technique in the assessment of rectovaginal endometriosis.

Acknowledgments: The authors thank Paolo Viridis, M.D., and Giampiero Capobianco, M.D. (Department of Pharmacology, Gynecology and Obstetrics, University of Sassari) for their help in preparing this article.

References

1. Chen TF, Collier DJ, Everett WG, Dixon AK. Endometriosis of rectovaginal septum treated by anterior resection. *Ann Chir Gynaecol* 1989; 78:324–6.
2. Koninckx PR, Martin DC. Deep endometriosis: a consequence of infiltration or retraction or possibly adenomyosis externa? *Fertil Steril* 1992;58:924–8.
3. Koninckx PR, Meuleman C, Demeyere S, Lesaffre E, Cornillie FJ. Suggestive evidence that pelvic endometriosis is a progressive disease, whereas deeply infiltrating endometriosis is associated with pelvic pain. *Fertil Steril* 1991;55:759–65.
4. Cornillie FJ, Oosterlynck D, Lauweryns JM, Koninckx PR. Deeply infiltrating endometriosis: histology and clinical significance. *Fertil Steril* 1990;53:978–83.
5. Koninckx PR, Martin DC. Surgical treatment of deeply infiltrating endometriosis. In: Shaw RW, ed. *Endometriosis. Current understanding and management*. Oxford, United Kingdom: Blackwell, 1995:264–81.
6. Hill LM. Infertility and reproductive assistance. In: Nyberg DA, Hill LM, Velez MB, Menderson EB, eds. *Transvaginal ultrasound*. St. Louis, MO: Mosby, 1992:43.
7. Chapron C, Dubuisson JB. Deep pelvic endometriosis: diagnostic approach. *Ann NY Acad Sci* 2001;943:276–80.
8. Koninckx PR, Martin D. Treatment of deeply infiltrating endometriosis. *Curr Opin Obstet Gynecol* 1994;6:231–41.
9. Friedman H, Vogelzang RL, Mendelson EB, Neiman HL, Cohen M. Endometriosis detection by US with laparoscopic correlation. *Radiology* 1985;157:217–20.
10. Chapron C, Dumontier I, Dousset B, Fritel X, Tardif D, Roseau G, et al. Results and role of rectal endoscopic ultrasonography for patients with deep pelvic endometriosis. *Hum Reprod* 1998;13:2266–70.
11. Fedele L, Bianchi S, Portuese A, Borrito F, Dorta M. Transrectal ultrasonography in the assessment of rectovaginal endometriosis. *Obstet Gynecol* 1998;91:444–8.
12. Dessole S, Farina M, Capobianco G, Nardelli GB, Ambrosini G, Meloni GB. Determining the best catheter for sonohysterography. *Fertil Steril* 2001;76:605–9.
13. Huskisson EC. Visual analogue scales. In: Melzack R, ed. *Pain measurement and assessment*. New York: Raven, 1983:33–7.
14. Kuhn RJP, Hollyock VE. Observations on the anatomy of the rectovaginal pouch and septum. *Obstet Gynecol* 1982;59:445–7.