

# Suramin Enhances Ethanol-Induced Injury to Gastric Mucosa in Rats

C. BLANDIZZI, MD, G. GHERARDI, MD, C. MARVEGGIO, PhD, G. LAZZERI, PhD, G. NATALE, MD, D. CARIGNANI, PharmD, R. COLUCCI, PharmD, and M. DEL TACCA, MD

---

Suramin is currently used in clinical practice as antineoplastic agent because of its complex interaction with the biological activity of various growth factors involved in tumor progression. The influence exerted by suramin on gastric injury induced in rats by intraluminal injection of absolute ethanol was investigated in the present study. The morphometric analysis of gastric histological sections revealed that suramin, 18 mg/kg, administered intraperitoneally for 14 days every other day, caused a marked enhancement of ethanol-induced mucosal damage. This effect was more pronounced 1-8 hr following ethanol administration, and it was still significant after 48 hr. In suramin-treated animals the evaluation of Alcian blue recovery from gastric-bound mucus showed that the levels of adherent mucus were significantly lower than those detected in untreated rats. In addition, pretreatment with suramin did not modify basal acid secretion, but caused potentiation of acid output stimulated by pylorus ligation or electrical vagal stimulation. Overall, the present results indicate that suramin exerts a negative influence on both gastric protective and repairing mechanisms. Due to the peculiar pharmacodynamic profile of suramin, it is suggested that interference with endogenous growth factors, endowed with physiological protective activity on gastric mucosa, might account for the damage-enhancing action of this drug.

---

**KEY WORDS:** suramin; ethanol; gastric damage; gastroprotection; mucus secretion; acid secretion.

---

Suramin is a symmetrical polysulfonated naphthylamine derivative of urea endowed with several pharmacological actions (1, 2). For over 60 years suramin has been extensively used to treat trypanosomiasis and onchocerciasis (3). Most recently, suramin has been characterized as a reversible antagonist at P<sub>2</sub> receptor sites, which mediate the contractile or relaxing actions exerted by adenosine triphosphate on smooth muscles (2, 4).

Suramin has also been evaluated as an antineoplastic agent (5), and at the present time it is currently employed in the treatment of hormone-refractory

prostate cancer (6). Although it appears likely that different pharmacological properties may account for the antitumoral effect of suramin, it is now widely accepted that this drug can affect the proliferation of neoplastic cells mainly by interfering with the biological activity of various growth factors (1, 2). Indeed, *in vitro* experiments have shown that suramin interacts directly with basic fibroblast growth factor (bFGF), epidermal growth factor (EGF), and transforming growth factor- $\alpha$  (TGF- $\alpha$ ), thus preventing their binding to specific membrane receptors (7, 8).

Growth factors are involved in a wide variety of biological processes, including embryogenesis, tissue cell growth, tissue repair, and tumor cell proliferation (9). Evidence has been provided that some growth factors as well as their specific cell receptors are naturally occurring throughout the gastrointestinal tract (10). It has been shown also that, among growth

---

Manuscript received March 11, 1996; revised manuscript received January 17, 1997; accepted January 28, 1997.

From the Institute of Pharmacology, School of Medicine and Dentistry, University of Pisa, Pisa, Italy; and Department of Pathology, Civil Hospital of Sondrio, Sondrio, Italy.

Address for reprint requests: Prof. Mario Del Tacca, Institute of Pharmacology, School of Medicine and Dentistry, University of Pisa, Via Roma, 55, I-56126 Pisa, Italy.

factors, EGF, TGF- $\alpha$ , and bFGF play an important role in the protection of gastroduodenal mucosa against different ulcerogenic and necrotizing agents (11, 12) as well as in the acceleration of mucosal repair and ulcer healing (12, 13). Several mechanisms appear to account for these protective actions. Indeed, EGF stimulates cell growth and differentiation in the stomach (10, 12), inhibits the stimulated acid secretion in a variety of mammalian species, including humans (10, 14), and increases the gastric mucosal blood flow (15). Systemic administration of TGF- $\alpha$  to rats prevents gastric necrotic lesions induced by ethanol and the protective effect is associated with a significant increase in insoluble mucin adherent to the epithelial surface (16). In addition, the healing effects exerted by both EGF and bFGF on chronic ulcers paralleled the increment of angiogenesis in the ulcer bed (13, 17).

On the basis of these findings, it appears conceivable that suramin might interfere with both the protective and healing activities of endogenous growth factors at the gastric level. To test this hypothesis, the present study investigates the influence of suramin on gastric mucosal damage induced by intraluminal injection of absolute ethanol. In order to obtain an accurate quantitative analysis of necrotic mucosal damage, the estimation of lesion index was carried out on the basis of histologic morphometric criteria. The effects of suramin on gastric bound mucus levels and acid secretion were also examined.

## MATERIALS AND METHODS

**Animals and Drug Treatment.** Albino male Wistar rats, 200–220 g body weight, were used throughout the study. They were fed standard laboratory chow and tap water *ad libitum* and were not used for at least one week after their delivery to the laboratory. The animals were housed, six in a cage, in temperature-controlled rooms on a 12-hr light cycle at 22–24°C and 50–60% humidity. Their care and handling were in accordance with the provisions of European Economic Community (EEC) Council Directive 86-609, recognized and adopted by the Italian government.

Rats were treated with suramin, 18 mg/kg, or its vehicle (0.5 ml 154 mM NaCl) intraperitoneally every other day for 14 days. The dose of suramin was selected on the basis of the treatment schedules currently adopted in the clinical practice. Animals underwent the experimental procedures on the fifteenth day, and 24 hr before the beginning of experiments, they were maintained in single cages that had wire net bottoms to prevent coprophagy and were deprived of food. Free access to water was allowed until 1 hr before the experiments started.

**Induction of Gastric Mucosal Damage.** Animals underwent the induction of gastric injury 12 hr after the last injection of suramin or its vehicle. The mucosal damage was

evoked with 1 ml/200 g body weight of absolute ethanol administered by intragastric gavage using a polyethylene orogastric catheter. One, 2, 4, 8, 12, 24, and 48 hr after the injection of the necrotizing agent, the rats were killed by cervical dislocation, and their stomachs were rapidly removed and processed for the quantitative evaluation of either necrotic mucosal damage or bound mucus levels. Absolute ethanol was chosen as the damaging agent on the basis of previous studies dealing with the influence exerted by growth factors on ethanol-induced gastric injury (16, 18, 19).

### Morphometric Evaluation of Gastric Mucosal Damage.

The morphometric evaluation of gastric mucosal damage was carried out following the procedure previously reported (20). The stomach was opened along the greater curvature, gently washed with saline (154 mM NaCl), pinned upon a cork plate with the mucosal surface turned upwards, and fixed in 10% formalin buffered with phosphate for 24 hr at 4°C. Each stomach was then dissected in parallel strips perpendicular to the lesser curvature and at a distance of 2 mm. The strips from each stomach were sequentially superimposed on a glass slide and oriented with the side of each strip distal to the pylorus upwards. A solution of melted 3% agar was gently poured on the strips and quickly cooled at 4°C to promote its solidification. The agar block was removed from the glass slide, dehydrated, and embedded in paraffin wax (Vogel Histo-Comp, Giessen, Germany). Then 3-mm-thick paraffin sections were cut using a microtome (HM 330 Microm, Heidelberg, Germany) and stained with hematoxylin and eosin (H&E).

Sections were observed by light microscopy (magnifications approximately 40 $\times$ ) and the length of both total and damaged mucosa was evaluated by means of a micrometric scale. The lesion index was estimated as the length fraction of damaged mucosa over the total length of mucosa (total damage), and expressed as percentage values. Moreover, taking into account the depth of the mucosal damage, three types of lesions were also discriminated, according to the criteria reported by Lacy and Ito (21). Type I lesions consisted of lysis of mucosal cells on the luminal free surface, with gastric pit cells being undamaged. Type II lesions consisted of damage to cells lying on both surface mucosa and gastric pits, with gastric gland cells being undamaged. Type III lesions consisted of damage to gastric glands associated with detachment of whole layers of necrotic superficial mucosa.

**Evaluation of Adherent Gastric Mucus.** The stomach was opened along the lesser curvature, washed with saline, and weighed. The measurement of mucus levels bound to the epithelial surface was performed as previously reported (20). The glandular portion of the stomach was excised and immersed for 2 hr in 0.1% Alcian blue in a 0.16 M sucrose solution buffered with 0.05 M sodium acetate (pH adjusted to 5.8 with HCl 1 N). The unbound dye was then removed by two subsequent washings of 15 and 45 min in 0.25 M sucrose solution and the mucus-bound dye was eluted by immersing the stomach in a 0.5 M MgCl<sub>2</sub> solution for 2 hr. Thus, the solution obtained was shaken with diethyl ether and the optical density of the aqueous phase was read at 605 nm with a Uvikon 930 spectrophotometer (Kontron Instruments, Milan, Italy). The amount of Alcian blue, extracted

per gram of wet glandular stomach, was then calculated from standard curves.

**Evaluation of Gastric Acid Secretion.** The evaluation of gastric acid secretion was carried out 12 hr after the last injection of suramin or its vehicle. In a first group of experiments, assessment of acid secretory activity was performed on conscious rats with pylorus ligation, according to the procedure previously reported (22). Three hours after pylorus ligation, the rats were sacrificed by cervical dislocation and the whole stomach was excised. The gastric contents were collected and centrifuged at 3000 rpm for 10 min in order to assess the net volume of luminal fluid (ml/3 hr). The acidity was determined by automatic potentiometric titration to pH 7.0 with 0.01 NaOH, using an Autotitrator pH meter (PHM 82, Radiometer, Copenhagen) and evaluated as both  $H^+$  concentration (microequivalents  $H^+$  per milliliter) and total  $H^+$  output (microequivalents  $H^+$  per 3 hours).

In a second set of experiments the measurement of acid secretion was performed on anesthetized animals under either basal conditions or in the presence of electrical vagal stimulation. For this purpose, continuous perfusion of the rat stomach *in situ* was carried out as previously reported (23). The animals were anesthetized with urethane (1 g/kg intraperitoneally), the stomach lumen was perfused continuously with 154 mM NaCl solution at 37°C at a rate of 1 ml/min, and 15-min effluent fractions were collected. Basal acid secretion was allowed to stabilize for 30 min, and basal acid output was then monitored at 15-min intervals for 3 hr.

In a group of anesthetized rats, both vagus nerves were carefully separated from the carotid arteries and cut at the cervical level. The distal end of the left vagus nerve was placed on a bipolar platinum electrode. Thirty minutes after surgical preparation, the acid secretion was elicited by continuous electrical stimulation of the left vagus nerve and was monitored at 15-min intervals for 3 hr. The stimulus parameters were square-wave pulses of 0.5 msec, delivered at 5 Hz with supramaximal intensity (10 V) by means of a Grass S5 stimulator (Grass Instruments, Quincy, Massachusetts). The acidity in the gastric perfusate was measured as described above, and expressed as total  $H^+$  output (microequivalents  $H^+$  per 3 hours).

**Statistics.** Results are given as mean  $\pm$  SEM. The significance of differences between means was evaluated by Student's *t* test for unpaired data.  $P < 0.05$  was considered significant; *N* indicates the number of experiments.

**Drugs.** The following drugs were used: suramin, kindly provided by Bayer AG, Leverkusen, Germany; and urethane ethyl carbamate, from Sigma Chemicals, St. Louis, Missouri. Other reagents were of analytical grade.

## RESULTS

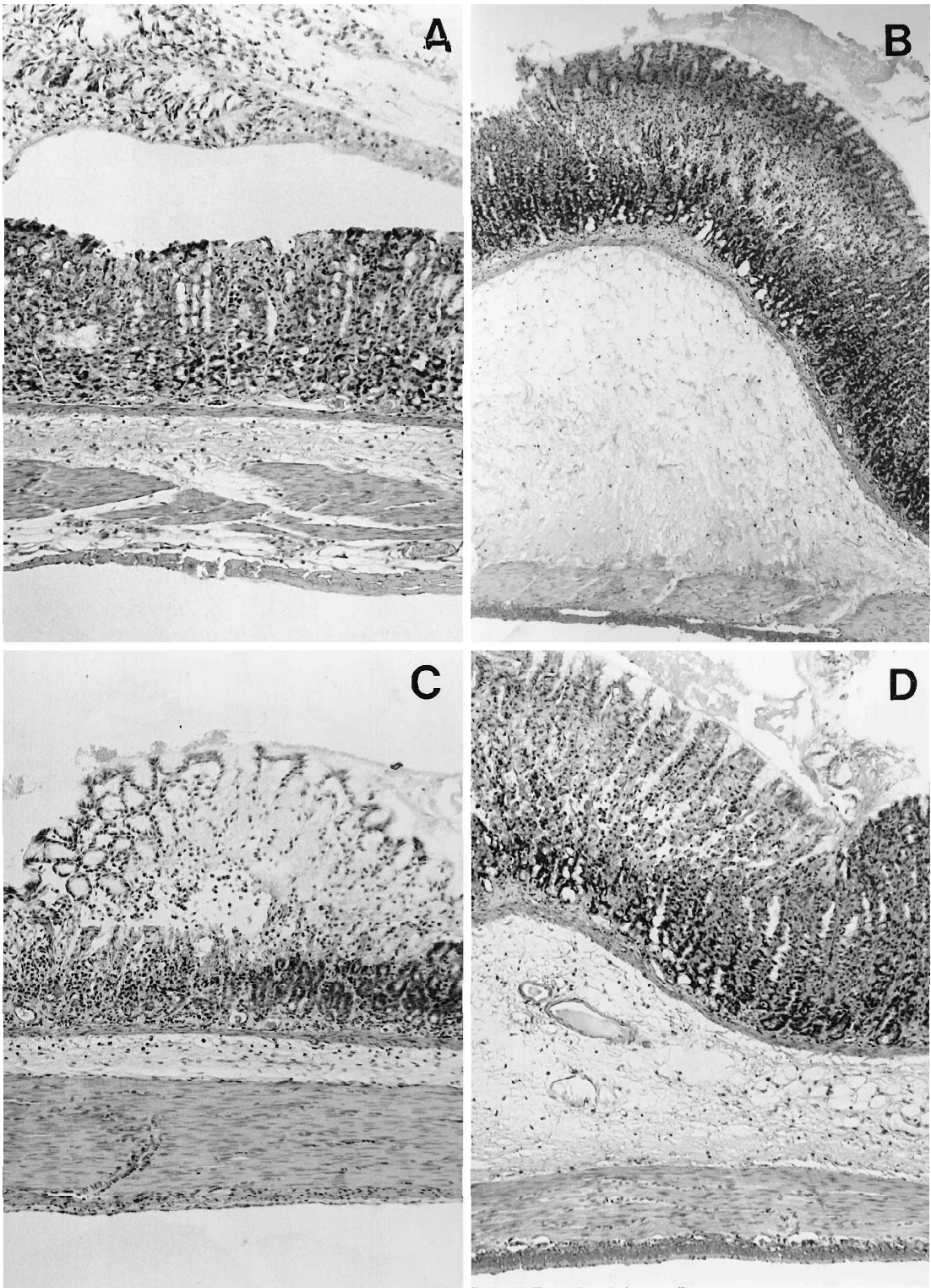
**Morphometric Evaluation of Gastric Mucosal Damage.** Under basal conditions, the histological examination of stomachs dissected from control animals, receiving saline solution intraperitoneally ( $N = 6$ ), revealed the presence of small mucosal lesions consisting exclusively of lysis of the surface epithelium (type I lesions) and accounting for  $0.52 \pm 0.03\%$  of

the total mucosal extension. Similar findings were obtained in rats treated with suramin over a period of 14 days, with  $0.48 \pm 0.05\%$  ( $N = 6$ ) of the gastric mucosa being affected by small lesions on the surface epithelium ( $P = 0.508$  vs controls).

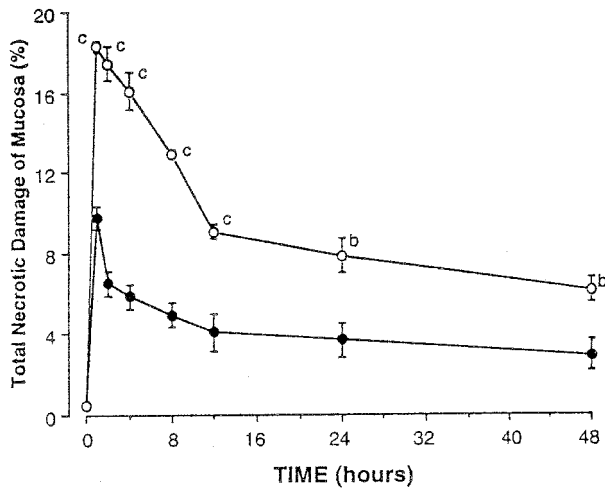
The injection of absolute ethanol into the gastric lumen induced gross lesions in the glandular part of the stomach both in untreated and suramin-treated animals (not shown). In control rats the mucosal damage was histologically characterized by necrosis of epithelial cells, which appeared vacuolated, with pyknotic nuclei, and had a lightly stained cytoplasm. Cellular lysis caused epithelial exfoliation, mainly as single elements or small portions of foveolar epithelium admixed with exudated fibrin. The interface with intact mucosa was irregular and poorly defined (Figure 1A and C).

The morphometric analysis of stomachs revealed that, following the administration of the necrotizing agent to control animals, the total mucosal damage reached the highest level 1 hr after the induction of gastric injury ( $9.75 \pm 0.59$ ,  $N = 6$ ), and then declined gradually (Figure 2). Forty-eight hours after intragastric ethanol injection, the necrotic damage still accounted for  $2.93 \pm 0.74\%$  ( $N = 6$ ) of the total mucosal extension, this value being significantly higher than that found under basal conditions ( $P < 0.01$ ). Moreover, taking into account the depth of mucosal damage induced by ethanol in control animals, types I and II lesions were slightly more represented than type III lesions at nearly all experimental times studied (Figure 3). In the present study the extent of ethanol-induced microscopic damage (ranging from 2.93 to 9.75% at various times examined) was quite lower than that obtained by Lacy and Ito (21) under similar experimental conditions. However, this discrepancy must be regarded as apparent in nature, since only a few mucosal specimens cut from each stomach were taken into account in the study of Lacy and Ito (21), whereas a complete examination of the whole gastric mucosa was carried out in our experiments.

The treatment with suramin over a period of 14 days caused a significant enhancement of ethanol-induced necrotic damage of gastric mucosa. In this case, the mucosal damage was mainly characterized by a peculiar desquamation of entire portions of necrotic epithelium that detached from intact mucosa as true pseudomembranes. Indeed, necrotic cells retained their mutual cohesion, with preservation of basic architecture of the mucosal layer, and desquamation occurred along a definite cleavage interface



**Fig 1.** Type II (A, B) and type III (C, D) lesions 1 hr after the intragastric administration of absolute ethanol in conscious rats pretreated with intraperitoneal suramin-vehicle (A, C) or suramin 18 mg/kg (B, D) every other day for 14 days. Stomachs from suramin-treated rats show that the necrotic tissue breaks off from the cleavage plane, forming a pseudomembrane. The submucosal layer appears edematous. Sections of fundic mucosa are stained with H&E. Magnifications:  $\times 80$  (A),  $\times 60$  (B),  $\times 70$  (C),  $\times 70$  (D). (Reduced to 89% for reproduction.)



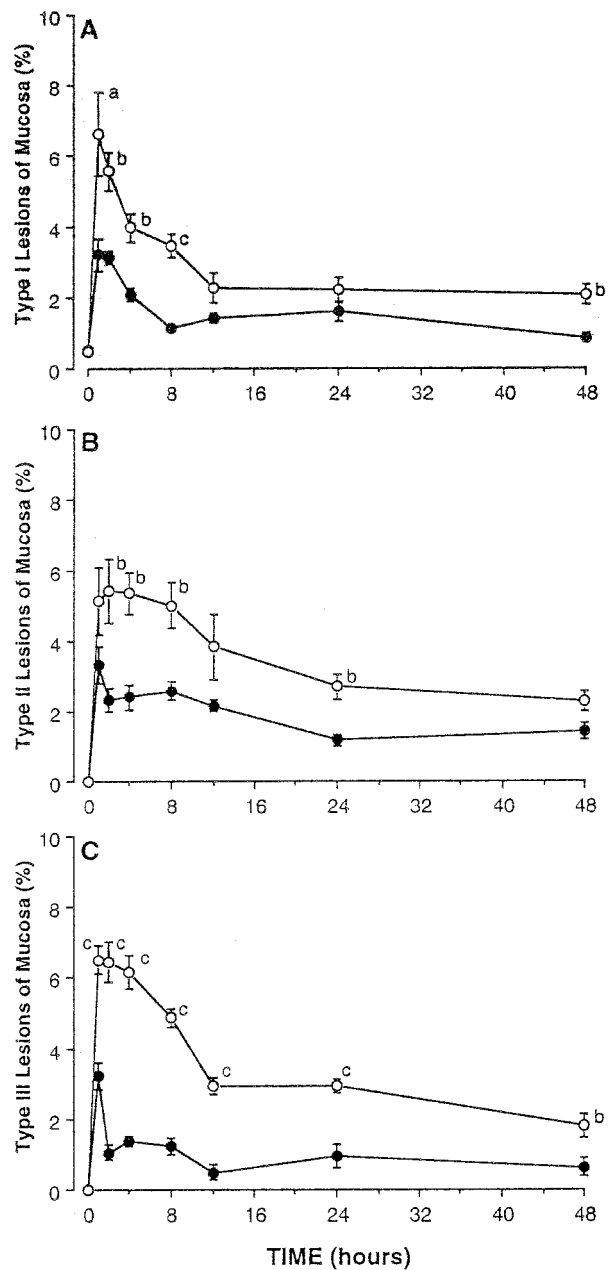
**Fig 2.** Morphometric evaluation of total mucosal damage induced by intragastric injection of absolute ethanol in conscious rats pretreated with intraperitoneal suramin-vehicle (●) or suramin 18 mg/kg (○) every other day for 14 days. Data are expressed as percent damage of the total mucosal length. At time zero values were obtained in the absence of intragastric ethanol. Each point represents the mean value obtained from six experiments  $\pm$  SEM (vertical lines). Significant difference from control values: <sup>b</sup> $P < 0.01$ ; <sup>c</sup> $P < 0.001$ .

that appeared somewhat smooth and with a concave profile. Only in deeper portions of the pseudomembrane did cells have pyknotic nuclei and a round outer profile, due to a loss of intercellular cohesion. Edema of the underlying submucosa, with capillary dilation, represented a constant and prominent finding (Figure 1B and D).

According to the morphometric analysis, the enhancing effect of suramin was more pronounced 1–8 hr after ethanol injection and then declined towards the control values (Figure 2). However, 48 hr after ethanol administration, the total mucosal damage in suramin-treated animals accounted for  $6.15 \pm 0.60\%$  ( $N = 6$ ), this value still being significantly higher than that obtained by morphometric analysis of control stomachs ( $P < 0.01$ ). In addition, when analyzing the depth of ethanol-induced gastric damage, it was observed that the potentiating action of suramin consisted mainly of type III lesions (Figure 3).

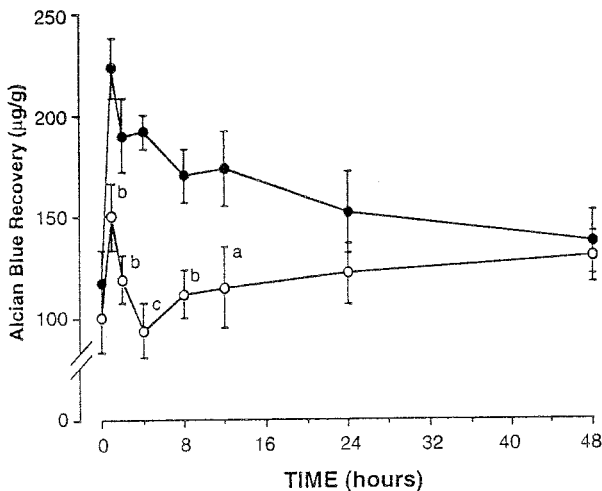
**Evaluation of Adherent Gastric Mucus.** In the absence of intragastric ethanol injection (basal), Alcian blue recovery from gastric-bound mucus of untreated animals ( $116.6 \pm 16.6 \mu\text{g/g}$ ;  $N = 6$ ) was found to be not significantly different from that measured in the stomachs of suramin-treated rats ( $99.9 \pm 16.2 \mu\text{g/g}$ ;  $N = 6$ ;  $P = 0.246$ ) (Figure 4).

Following the intraluminal instillation of absolute ethanol, a marked increase in Alcian blue recovery



**Fig 3.** Morphometric evaluation of type I (A), type II (B), and type III (C) lesions induced by intragastric injection of absolute ethanol in conscious rats pretreated with intraperitoneal suramin-vehicle (●) or suramin 18 mg/kg (○) every other day for 14 days. Data are expressed as percent damage of the total mucosal length. At time zero values were obtained in the absence of intragastric ethanol. Each point represents the mean value obtained from six experiments  $\pm$  SEM (vertical lines). Significant difference from control values: <sup>a</sup> $P < 0.05$ ; <sup>b</sup> $P < 0.01$ ; <sup>c</sup> $P < 0.001$ .

from adherent gastric mucus was obtained in control animals (Figure 4). Under these conditions, the bound mucus reached the highest level at 1 hr after ethanol administration and then declined gradually



**Fig 4.** Evaluation of Alcian blue recovery from gastric glandular mucosa following the intragastric injection of absolute ethanol in conscious rats pretreated with intraperitoneal suramin-vehicle (●) or suramin 18 mg/kg (○) every other day for 14 days. At time zero values were obtained in the absence of intragastric ethanol. Each point represents the mean value obtained from six experiments  $\pm$  SEM (vertical lines). Significant difference from control values: <sup>a</sup> $P < 0.05$ ; <sup>b</sup> $P < 0.01$ ; <sup>c</sup> $P < 0.001$ .

towards the basal value. In stomachs dissected 48 hr after the induction of mucosal necrosis, Alcian blue recovery was  $136.8 \pm 15.6 \mu\text{g/g}$  ( $N = 6$ ); this value is not significantly different from that detected under basal conditions ( $P = 0.198$ ). In animals pretreated with suramin, the measurement of Alcian blue recovery from gastric adherent mucus after the injection of ethanol showed that the levels of bound mucus remained significantly lower than values detected in control stomachs up to 12 hr after ethanol treatment.

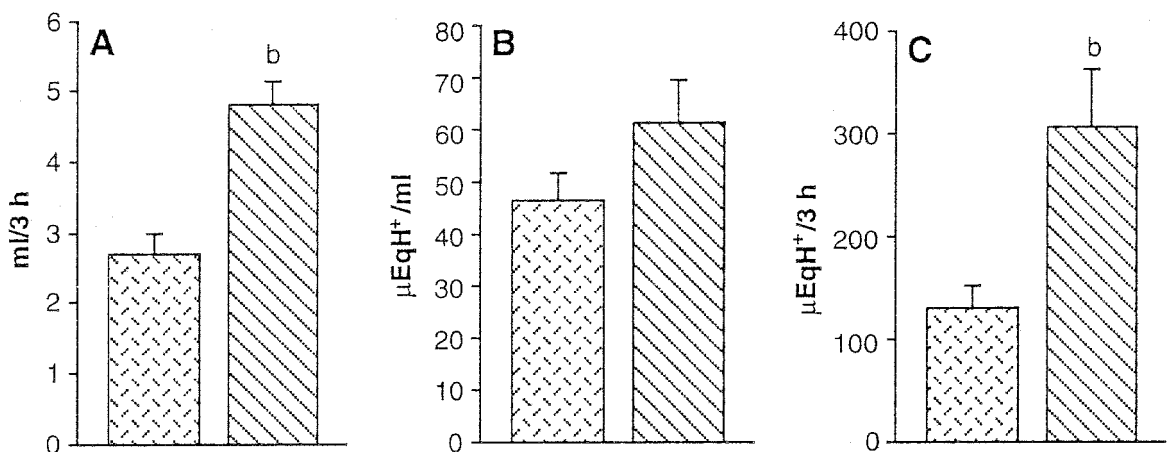
In particular, the increase in bound mucus induced by ethanol was markedly lower than that found in control animals, and it rapidly declined towards the basal level within 4 hr after ethanol (Figure 4).

**Evaluation of Gastric Acid Secretion.** The short-term treatment of rats with suramin caused a significant enhancement of gastric acid output induced by pylorus ligation in conscious rats. In particular, it was observed that suramin exerted its excitatory effect mainly on gastric secretory volume, whereas the hydrogen ion concentration in the gastric juice was not significantly affected (Figure 5).

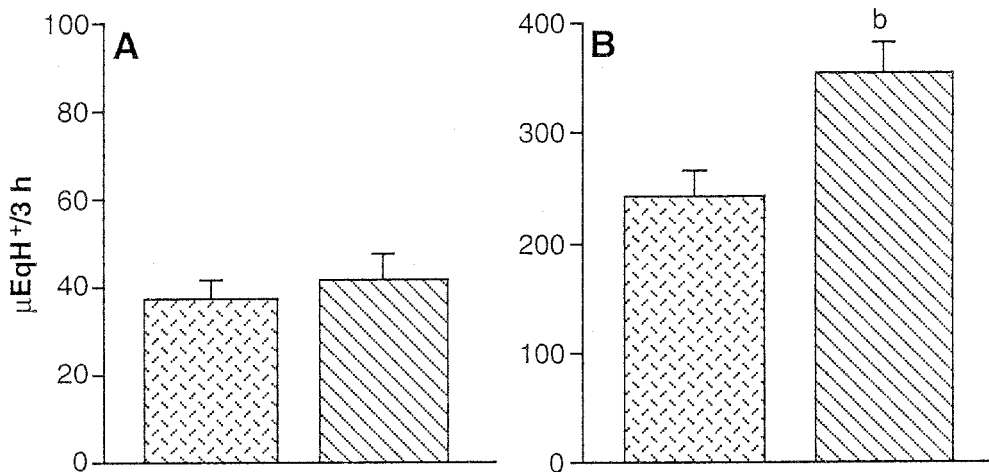
When acid secretion was measured in the gastric perfusate of urethane-anesthetized animals, it was observed that the suramin treatment did not significantly modify basal acid output (Figure 6). Following the electrical stimulation of the left vagus nerve, the acid output rapidly increased and reached a steady state within 30–45 min (not shown). Under these experimental conditions, the vagally induced hypersecretory response was significantly higher in suramin-treated than in control rats (Figure 6).

## DISCUSSION

Suramin is currently used in clinical practice as an antitumor agent because of its ability to interfere with the biological activity of various growth factors (1, 5). The main digestive side effects observed following administration of suramin in patients consisted of nausea and vomiting (2). However, the possibility that this drug might exert specific toxic effects on gastric mucosa, under either physiological conditions or in



**Fig 5.** Evaluation of gastric acid secretion from conscious pylorus-ligated rats pretreated with intraperitoneal suramin-vehicle (▨) or suramin 18 mg/kg (▩) every other day for 14 days: (A) total volume, (B) acid concentration, and (C) total acid output. Columns indicate the mean values obtained from eight experiments  $\pm$  SEM (vertical lines). Significant difference from control values: <sup>b</sup> $P < 0.01$ .



**Fig 6.** Evaluation of gastric acid secretion from urethane-anesthetized rats undergoing continuous perfusion of the gastric lumen, and pretreated with intraperitoneal suramin-vehicle (▨) or suramin 18 mg/kg (▩) every other day for 14 days: (A) basal acid output in animals with intact vagus nerves; (B) total acid output in animals undergoing bilateral cervical vagotomy followed by electrical stimulation (0.5 msec, 5 Hz, 10 V) of the left vagus nerve. Columns indicate the mean values obtained from eight experiments  $\pm$  SEM (vertical lines). Significant difference from control values: <sup>b</sup> $P < 0.01$ .

the presence of chemically induced damage, had not been investigated.

In the present study, suramin enhanced gastric mucosal injury elicited by intraluminal injection of absolute ethanol, a treatment associated with marked necrotizing effects on gastric mucosa (24). Since it has been shown that restitution of the gastric mucosa starts within few minutes of the challenge with ethanol (25), the time-course profile of suramin action suggests that the mechanisms supporting the healing of damaged mucosa were impaired in animals pretreated with this drug over a period of 14 days. However, the possibility that suramin might interfere with physiological factors providing protection to the gastric mucosa against acute chemical injury should also be taken into account. In this regard, severe necrotic lesions (type III) detected in suramin-treated animals 1–4 hr after ethanol administration were greater than would be expected on the basis of a simple failure of the mechanisms that repair ulcerated mucosa. Therefore, it remains to be demonstrated whether suramin treatment leads to an impairment of mucosal defense mechanisms, thus allowing necrotizing agents to exert a more aggressive action against the gastric wall.

Suramin exerts different pharmacological actions; these include inhibition of growth factor-receptor binding as well as inhibition of several enzymatic activities, all involved in critical biological events related to cellular growth and transmembrane signaling (1, 2, 9). Some of these effects might account for the

increased severity by suramin of ethanol-induced necrotic injury of gastric mucosa.

Among growth factors, EGF or TGF- $\alpha$  play a crucial role in both gastric mucosal protection and ulcer healing (26, 27). The removal of submandibular salivary glands, which results in a remarkable fall in the gastric content of EGF (11), increases the susceptibility of gastric mucosa to the formation of acute lesions induced by ethanol in rats (18). In addition, increased protection and repair of acute gastric injury, elicited by necrotizing agents including ethanol, can be observed after administration of exogenous EGF or TGF- $\alpha$  (15, 16, 26). On this basis, since suramin inhibits the binding of EGF and TGF- $\alpha$  to their specific receptors (7, 8, 28), this drug might induce in the stomach a condition of reduced availability of EGF, TGF- $\alpha$ , and possibly of other growth factors, like that observed in sialoadenectomized rats. In support of this view, the present treatment with suramin as well as sialoadenectomy (11) could not induce spontaneous gastric lesions, while enhancing the damaging action of necrotizing agents. Preliminary experiments indicated that suramin causes a significant reduction of immunohistochemically detectable EGF in rat salivary submandibular glands, thus suggesting that the ulcer-promoting action of this drug might depend, at least in part, on a decrease in endogenous production of EGF (29). However, the putative effects exerted by suramin on gastric EGF and/or TGF- $\alpha$  levels as well as its influence on gastric EGF receptor binding have not been elucidated.

Therefore, the possibility that the potentiating action of suramin on ethanol-induced mucosal injury might also result from its interference with the activity of other growth factors can not be ruled out. Accordingly, in a previous report suramin significantly counteracted the rapid epithelial restitution induced by endogenous bFGF after exposure of frog gastric mucosa to damaging concentrations of NaCl *in vitro* (30).

The present effects of suramin on gastric mucus and acid secretion appear to further confirm the hypothesis that this drug can enhance ethanol-induced mucosal injury mainly by affecting the gastroprotective factors and the restitution process. Gastric mucus play an important role in the pathophysiology of mucosal damage elicited by ethanol as well as in the subsequent restoration (31). Following the application of ethanol to the gastric mucosa, a release of gel mucus occurs, which, along with the entrapped fibrin, plasma, and cellular debris, generates a mucoid cap over the sites of damage, providing a microenvironment favorable to reepithelization (25, 31). Histological studies indicate that the thickness of such gelatinous material is much higher than that displayed by the mucus layer covering normal mucosa (32), and this characteristic might account for the increase in Alcian blue recovery detected here in control animals after intragastric instillation of absolute ethanol. The present observation that suramin significantly decreased Alcian blue recovery from the adherent mucous gel following the challenge with ethanol suggests that inhibition of mucus output might take part in the potentiating action exerted by suramin on ethanol-induced necrotic damage. Stimulation of gastric mucus production by EGF has been postulated by other authors (33), and the protective action exerted by TGF- $\alpha$  against ethanol-induced gastric injury in rats paralleled a significant increase in gastric bound mucus (16). These findings further suggest that suramin may enhance ethanol-induced mucosal injury by interfering with the biological actions of TGF- $\alpha$  or EGF at gastric level. However, additional investigations are required in order to better elucidate the putative role played by growth factors in the action of suramin on mucus output.

Under basal conditions, suramin did not affect gastric acid output in anesthetized rats, suggesting that acid secretion is not significantly involved in the damage-enhancing effect of this drug. Accordingly, acid secretion did not play a significant role in the damaging action exerted by ethanol on gastric mucosa (34). In the present study, suramin enhanced stimu-

lated acid secretion, and this effect, under particular pathophysiological conditions, might contribute to its delaying action on ulcer repair. However, the present suramin-induced hypersecretory effects, obtained from different models of vagal activation, are preliminary, and the underlying mechanisms deserve further investigation. In particular, since suramin increased mainly the gastric secretory volume, without modifying the hydrogen ion concentration, the possibility that this drug might affect electrolyte components of gastric secretion, such as bicarbonates, should be considered. It is also worth noting that in urethane-anesthetized rats acid secretion was induced only by unilateral stimulation of the left vagus nerve, and therefore different results might be expected when testing suramin in the presence of bilateral vagal stimulation, a condition associated with more extensive involvement of the gastric secretory mechanisms.

In conclusion, the present study provides morphological evidence that suramin enhances ethanol-induced gastric mucosal injury and delays the subsequent repairing process. Due to the particular pharmacological properties of suramin, it is suggested that an interference with endogenous growth factors as well as a reduction of gastric mucus production account for damage-enhancing action of this drug.

## ACKNOWLEDGMENTS

The experiments were performed with the technical assistance and collaboration of Mr. Bruno Stacchini.

## REFERENCES

1. Stein CA: Suramin: A novel antineoplastic agent with multiple potential mechanisms of action. *Cancer Res* 53:2239–2248, 1993
2. Voogd TE, Vansterkenburg ELM, Wilting J, Janssen LHM: Recent research on the biological activity of suramin. *Pharmacol Rev* 45:177–203, 1993
3. Hawking F: Suramin: With special reference on onchocerciasis. *Adv Pharmacol Chemother* 106:216–221, 1978
4. Dunn PM, Blakeley AGH: Suramin: A reversible P<sub>2</sub>-purinoceptor antagonist in the mouse vas deferens. *Br J Pharmacol* 93:243–245, 1988
5. La Rocca RV, Stein CA, Meyers CE: Suramin: Prototype of a new generation of antitumor compounds. *Cancer Cells* 2:106–115, 1990
6. Myers CE, Cooper M, Stein C, La Rocca R, McClellan MW, Weiss G, Choyke P, Dawson N, Steinberg S, Uhrich MM, Cassidy J, Kohler DR, Trepel J, Linehan WM: Suramin: A novel growth factor antagonist with activity in hormone-refractory metastatic prostate cancer. *J Clin Oncol* 10:881–889, 1992
7. Coffey R, Leof E, Shipley G, Moses H: Suramin inhibition of growth factor receptor binding and mitogenicity in AKR-2B cells. *J Cell Physiol* 132:143–148, 1987

8. Gansler T, Vaghmar N, Olson J, Graham S: Suramin inhibits growth factor binding and proliferation by urothelial carcinoma cell cultures. *J Urol* 148:910–914, 1992
9. Goustin AE, Leof EB, Shipley GD, Moses HL: Growth factors and cancer. *Cancer Res* 46:1015–1029, 1986
10. Podolsky DK: Peptide growth factors in the gastrointestinal tract. In *Physiology of the Gastrointestinal Tract*, 3rd ed. LR Johnson (ed). New York, Raven, 1994, pp 129–167
11. Olsen SP, Poulsen SS, Kirkegaard P, Nexø E: Role of submandibular saliva and epidermal growth factor in gastric cytoprotection. *Gastroenterology* 87:103–108, 1984
12. Barnard JA, Beauchamp RD, Russel WE, Dubois RN, Coffey RJ: Epidermal growth factor-related peptides and their relevance to gastrointestinal pathophysiology. *Gastroenterology* 108:564–580, 1995
13. Folkman J, Szabo S, Stovroff M, McNeil P, Li W, Shing Y: Duodenal ulcer. Discovery of a new mechanism and development of angiogenic therapy that accelerates healing. *Ann Surg* 214:414–427, 1991
14. Koffman CG, Elder JB, Ganguli PC, Gregory H, Geary CG: Effect of urogastrone on gastric secretion and serum gastrin concentration in patients with duodenal ulceration. *Gut* 23:951–956, 1982
15. Hui WM, Chen BW, Kung AWC, Cho CH, Luk CT, Lam SK: Effect of epidermal growth factor on gastric blood flow in rats: Possible role in mucosal protection. *Gastroenterology* 104:1605–1610, 1993
16. Romano M, Polk WH, Awad JA, Arteaga CL, Nannay LB, Wargovich MJ, Kraus ER, Boland CR, Coffey RJ: Transforming growth factor  $\alpha$  protection against drug-induced injury to the rat gastric mucosa *in vivo*. *J Clin Invest* 90:2409–2421, 1992
17. Hase S, Nakazawa S, Tsukamoto Y, Segawa K: Effects of prednisolone and human epidermal growth factor on angiogenesis in granulation tissue of gastric ulcer induced by acetic acid. *Digestion* 42:135–142, 1989
18. Tepperman BL, Soper BD, Morris GP: Effect of sialoadenectomy on adaptive cytoprotection in the rat. *Gastroenterology* 97:123–129, 1989
19. Brzozowski T, Majka J, Garlicki J, Drozdowicz D, Konturek SJ: Role of polyamines and prostaglandins in gastroprotective action of epidermal growth factor against ethanol injury. *J Clin Gastroenterol* 13(suppl 1):S98–S102, 1991
20. Blandizzi C, Gherardi G, Natale G, Marveggio C, Del Tacca M: Protective action of omeprazole against gastric mucosal injury induced by hemorrhagic shock in rats. *Dig Dis Sci* 39:2109–2117, 1994
21. Lacy ER, Ito S: Microscopic analysis of ethanol damage to rat gastric mucosa after treatment with a prostaglandin. *Gastroenterology* 83:619–625, 1982
22. Blandizzi C, Gherardi G, Marveggio C, Natale G, Carignani D, Del Tacca M: Mechanisms of protection by omeprazole against experimental gastric mucosal damage in rats. *Digestion* 56:220–229, 1995
23. Blandizzi C, Natale G, Colucci R, Carignani D, Lazzeri G, Del Tacca M: Characterization of  $\alpha_2$ -adrenoceptor subtypes involved in the modulation of gastric acid secretion. *Eur J Pharmacol* 278:179–182, 1995
24. Cho CH, Ogle CW: The pharmacological differences and similarities between stress- and ethanol-induced gastric mucosal damage. *Life Sci* 51:1833–1842, 1992
25. Ito S, Lacy ER: Morphology of rat gastric mucosal damage, defense, and restitution in the presence of luminal ethanol. *Gastroenterology* 88:250–260, 1985
26. Konturek JW, Brzozowski T, Konturek SJ: Epidermal growth factor in protection, repair, and healing of gastroduodenal mucosa. *J Clin Gastroenterol* 13(suppl 1):S88–S97, 1991
27. Alison MR, Chinery R, Poulson R, Ashwood P, Longcroft JM, Wright NA: Experimental ulceration leads to sequential expression of spasmolytic polypeptide, intestinal trefoil factor, epidermal growth factor and transforming growth factor alpha mRNAs in rat stomach. *J Pathol* 175:405–414, 1995
28. Hoffman R, Cameron L: Characterization of a scintillation proximity assay to detect modulators of transforming growth factor alpha (TGF $\alpha$ ) binding. *Anal Biochem* 15:70–75, 1992
29. Bernardini N, Blandizzi C, Bianchi F, Natale G, Del Tacca M: Effects of suramin on gastric ulceration and EGF content of submandibular glands. *Gastroenterology* 108:A58, 1995
30. Paimela H, Goddard PJ, Carter K, Khakee R, McNeil PL, Ito S, Silen W: Restitution of frog gastric mucosa *in vitro*: Effect of basic fibroblast growth factor. *Gastroenterology* 104:1337–1345, 1993
31. Wallace JL, Whittle BJR: Role of mucus in the repair of gastric epithelial damage in the rat. Inhibition of epithelial recovery by mucolytic agents. *Gastroenterology* 91:603–611, 1986
32. Allen A, Hutton DA, Leonard AJ, Pearson JP, Sellers LA: The role of mucus in the protection of the gastroduodenal mucosa. *Scand J Gastroenterol* 21(suppl 125):71–77, 1986
33. Okita K, Karita M, Nakanishi N, Takemoto T: Role of epidermal growth factor in protection and repair of gastric mucosal injury. *J Clin Gastroenterol* 13(suppl 1):S103–S108, 1991
34. Oates PJ, Hakkinen JP: Studies on the mechanism of ethanol-induced gastric damage in rats. *Gastroenterology* 94:10–21, 1988