

An unusual finding of massive pulmonary embolism in a patient during treatment with high-dose ibuprofen

Franca Bilora¹ · Angelo Adamo¹ · Fabio Pomerri² · Paolo Prandoni¹

Received: 24 August 2015 / Accepted: 22 September 2015 / Published online: 26 October 2015
© Springer International Publishing Switzerland 2015

Abstract Non-steroidal anti-inflammatory drugs have been associated with an increased risk of venous thromboembolism. We report for the first time, the case of a patient who developed massive pulmonary embolism after a long period of treatment with high doses of ibuprofen. A 65-year-old woman was admitted with severe dyspnea while on treatment with high doses of ibuprofen for diffuse spine pain due to arthrosis. A spiral computed tomography showed a massive pulmonary embolism. No other explanation for the thromboembolic disorder was found. She was successfully treated with therapeutic doses of low-molecular-weight heparin followed by rivaroxaban. Ibuprofen was discontinued and replaced by tramadol. High-dose ibuprofen is likely to have accounted for the life-threatening thromboembolic disorder.

Keywords Non-steroidal anti-inflammatory · Venous thromboembolism · Pulmonary embolism · Ibuprofen · Adverse effects

Introduction

Non-steroidal anti-inflammatory drugs (NSAIDs) are the most commonly used drugs for pain management. In the United States an estimated 5 % of all visits to a doctor

are related to prescriptions of NSAIDs [1]. A recent work analyzed the cardiovascular safety of NSAIDs by integrating all available direct and indirect evidence in network meta-analyses [2]. Ibuprofen was found to increase the risk of stroke with an estimated ratio as high as 3.36 (95 % CI 1.00–11.60), while the estimated ratio for cardiovascular death was found to be 2.39 [2]. According to the results of another recent review and meta-analysis, NSAIDs may increase by approximately 80 % the risk of venous thromboembolic (VTE) disorders [3]. Here, we report a case of massive pulmonary embolism in a 65-year-old woman who had been treated for 10 years with high doses of ibuprofen for diffuse spine pain.

Case report

A 65-year-old white woman was admitted to Padua Hospital with severe dyspnea associated with mild leg edema. The clinical history revealed painful cervical and lumbar hernias treated for 10 years with ibuprofen 600 mg three times daily. Eight years earlier she had a transient ischemic attack.

Clinical examination showed tachypnea, tachycardia and blood hypotension. Blood analysis showed an elevated D-dimer value (1231 µg/l, normal range 0–225), a slight anemia (hemoglobin 104 g/l), decreased iron concentration (7.4 µmol/l normal 9–30.4) and elevated levels of C-reactive protein (10.2 mg/l).

Markers of inherited or acquired thrombophilia were negative, as were markers of occult cancer. Spiral computed tomography showed bilateral pulmonary embolism with the involvement of lobar and segmentary ramifications of both pulmonary arteries (Fig. 1).

✉ Franca Bilora
franca.bilora@sanita.padova.it

¹ Internal Medicine, Coagulation Section, Cardiovascular Science Department, Padua University, Via Giustiniani, 2, 35128 Padua, Italy

² Internal Medicine Department (DIMED), Radiology Institute, Padua University, Padua, Italy

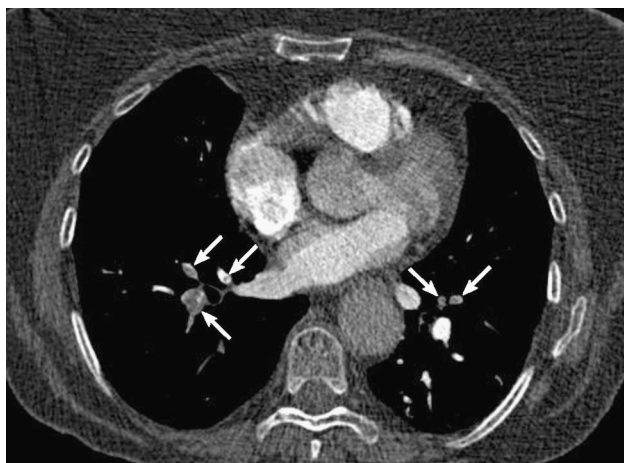


Fig. 1 Bilateral massive pulmonary embolism (*arrows*)

During hospitalization she underwent gastroscopy and colonoscopy, which showed hemorrhagic gastritis and a few aspecific ulcers of the sigma, respectively. An echography of abdomen and pelvis was normal, as was ultrasonography of the deep vein system of the legs. A spine magnetic resonance evidenced cervical and lumbar discal hernias.

The patient was treated with therapeutic doses of LMWH for 1 week, followed by full-dose rivaroxaban (15 mg twice daily for 2 weeks and then 20 mg once daily). Ibuprofen was discontinued and replaced by tramadol, in association with pantoprazole.

Discussion/comment

Although the association between the use of NSAIDs and the risk for thromboembolic disorders has long been identified [1, 2], little is known on the association between ibuprofen and VTE. Interesting enough, ibuprofen is often suggested as the NSAID of choice for patients on vitamin

K antagonists due to its low potential for hemorrhagic complications.

Our case report strongly supports the association between ibuprofen and VTE complications. Indeed, the patients had no personal or familial history of VTE, and examinations performed after admission excluded both thrombophilia and underlying malignancy. Conversely, she had been treated with unusually high doses of ibuprofen for many years.

Although the mechanism behind this association is unclear, a thromboxane–prostacyclin imbalance due to the COX-2 inhibition has been advocated [4].

Physicians should be aware of this association, and NSAIDs should be prescribed with caution, especially in patients at risk for thromboembolic disorders.

Compliance with ethical standards

Conflict of interest None.

Human and animal rights The study was approved by the institutional ethics committee. This article does not contain any studies with human participants or animals performed by any of the authors.

Informed consent Informed consent was obtained from the patient.

References

1. Kaufman DW, Kelly JP, Rosenberg L et al (2002) Recent patterns of medication used in the ambulatory adult population of the United States: the Slone survey. *JAMA* 28:7337–7344
2. Trelle S, Reichenbach S, Wandel S et al (2011) Cardiovascular safety of non-steroidal anti-inflammatory drugs: network meta-analysis. *BMJ* 342:c7086
3. Ungprasert P, Srivali N, Wijarnpreecha K et al (2015) Non-steroidal anti inflammatory drugs and risk of venous thromboembolism: a systematic review and meta-analysis. *Rheumatology* 54(4):736–742
4. Brooks Peter M, Day Richard O (1991) Non steroidal antiinflammatory drugs-differences and similarities. *New Engl J Med* 324:1716–1725