

Relevance of Retinal Thickness Changes in the OCT Inner and Outer Rings to Predict Progression to Clinical Macular Edema: An Attempt of Composite Grading of Macular Edema

Stela Vujosevic^a Monica Varano^b Catherine Egan^c Sobha Sivaprasad^d Geeta Menon^e
Ali Erginay^f Frank D. Verbraak^g Henrik Lund-Andersen^h Jose P. Martinezⁱ Ignasi Jürgens^j
Erica Smets^k Caroline Coriat^l Peter Wiedemann^m Victor Ágoasⁿ Giuseppe Querques^o
Frank G. Holz^p Sandrina Nunes^q Dalila Alves^q Catarina Neves^q Torcato Santos^q Luisa Ribeiro^q
Francesco Bandello^r Amparo Navea Tejerina^s José Cunha-Vaz^q for the EVICR.net

^aCentre for Clinical Trials, Department of Ophthalmology, University of Padova, Padova, and ^bG.B. Bietti Eye Foundation, IRCCS, Rome, Italy; ^cClinical Trials Unit, Moorfields Eye Hospital, NHS Foundation Trust, and ^dLaser and Retinal Research Unit, King's Health Partners, London, and ^eOphthalmology Clinical Trials Unit, Frimley Park Hospital Foundation Trust, Frimley, UK; ^fDepartment of Ophthalmology, Lariboisière Hospital, Paris, France; ^gDepartment of Ophthalmology, Academic Medical Center, Amsterdam, The Netherlands; ^hDepartment of Ophthalmology, Glostrup Hospital, Copenhagen University, Glostrup, Denmark; ⁱRotterdam Eye Hospital, Rotterdam, The Netherlands; ^jInstitut Català de Retina (ICR), Barcelona, Spain; ^kDepartment of Ophthalmology, Antwerp University Hospital, Antwerp, Belgium; ^lCentre d'Investigation Clinique, Centre National d'Ophthalmologie des Quinze-Vingts, Paris, France; ^mUniversity Eye Hospital Leipzig, Leipzig, Germany; ⁿInstituto de Oftalmologia Dr. Gama Pinto, Lisboa, Portugal; ^oCentre Hospitalier Intercommunal de Créteil, University Paris-Est Créteil, Créteil, France; ^pDepartment of Ophthalmology, University of Bonn, Bonn, Germany; ^qAIBILI, Association for Innovation and Biomedical Research on Light and Image, Coimbra, Portugal; ^rDepartment of Ophthalmology, University Vita Salute, Scientific Institute of San Raffaele, Milan, Italy; ^sFundación para la Investigación Biomédica y Sanitaria, FISABIO-Oftalmología Biomédica, Valencia, Spain

Key Words

Diabetic retinopathy · Diabetes · Optical coherence tomography · Macular edema

Abstract

Purpose: To characterize the relevance of macular thickness changes in the inner and outer rings in the progression of macular edema in eyes/patients with diabetes type 2. **Methods:** A total of 374 type 2 diabetic patients with mild nonproliferative diabetic retinopathy (ETDRS levels 20–35) were included in a 12-month prospective observational study to identify retinopathy progression. Retinal thickness analyses

were performed in 194 eyes/patients using Cirrus SD-OCT and 166 eyes/patients using Spectralis SD-OCT. The DRCR.net classification of subclinical and clinical macular edema was used. A composite grading of macular edema is proposed in this study. **Results:** A total of 317 eyes/patients completed the study. SD-OCT identified clinical macular edema in 24 eyes/patients (6.7%) and subclinical macular edema in 104 eyes/patients (28.9%) at baseline. Increased thickness of the central subfield is the best predictor for the development of clinical macular edema, with 85.7% sensitiv-

See EVICR.net Study Group at http://www.evicr.net/downloads/file270_gb.pdf.

ity and 71.9% specificity (OR: 2.57, 95% CI: 0.82–7.99). However, the involvement of the inner and outer rings is a cumulative predictor of progression to clinical macular edema (OR: 8.69, 95% CI: 2.85–26.52). **Conclusions:** A composite OCT grading of macular edema taking into account the retinal thickness changes in the inner and outer macular rings offers a simple way to characterize macular edema, with added clinical value.

© 2015 S. Karger AG, Basel

Introduction

The assessment and treatment of macular edema remains a major challenge in the prevention of visual impairment due to diabetes mellitus [1].

Because of varying definitions and classifications attached to the words focal and diffuse diabetic macular edema (DME), the Diabetic Retinopathy Clinical Research Network (DRCR.net) has recommended that future classification systems of DME should be based on objective measurements obtained from OCT (optical coherence tomography) and include concepts such as the extent and location of macular thickening, whether the center of the macula is involved and the presence or absence of vitreous traction. Ideally, a classification system for DME would be relatively easy to apply in practice and research and would be reproducible and clinically meaningful (e.g. differentiate the natural course, treatment response or both).

Recognizing these issues and the need for a simple way to use the classification of DME, this paper proposes a classification of DME based on OCT – an objective, reliable noninvasive method. The classification proposed is applied to the data obtained in a 1-year observational study of eyes/patients with mild nonproliferative diabetic retinopathy (NPDR).

Methods

Patients

This analysis was performed in the context of a prospective, multicenter observational study designed to follow eyes/patients with mild NPDR (20 and 35 of the Early Treatment Diabetic Retinopathy Study, ETDRS, classification) for a period of 1 year. The study was an investigator-driven observational study sponsored by the European Vision Institute Clinical Research Network (EVICR.net) [2]. Results of this study and procedures have been previously described [3–5].

A total of 374 patients were recruited between September 2010 and June 2012 in 19 European clinical sites and followed over a 1-year period. Men and women with diagnosed adult-onset type 2

diabetes, aged 35–82 years, with mild NPDR (20 and 35 of ETDRS classification), best-corrected visual acuity ≥ 75 letters ($\geq 20/32$) with no signs of vitreous traction (NVT) and refraction with spherical equivalent less than ± 5 dpt were included in the study [3]. Only 1 eye of each patient was included in the study. All patients gave written consent. The tenets of the Declaration of Helsinki were followed and approval was obtained from each institutional review board (ClinicalTrials.gov Identifier: NCT01145599).

Optical Coherence Tomography

SD-OCT was performed using Cirrus (Carl Zeiss Meditec Inc., Dublin, Calif., USA; n = 194), Spectralis (Heidelberg Engineering, Heidelberg, Germany; n = 166), Copernicus (OPTOPOL Technology, Zawiercie, Poland; n = 4) or 3D OCT-1000 (Topcon Corporation, Tokyo, Japan; n = 10). Only the 194 eyes/patients that were examined with Cirrus SD-OCT and the 166 eyes/patients that were examined with Spectralis SD-OCT are reported because of the availability of normative data and the number of patients examined. The data from these instruments were analyzed independently.

Retinal thickness (RT) measurements in the central subfield (central area with 1 mm in diameter) and the 4 areas of the inner and outer rings (within 1–3 and 3–6 mm, respectively) were collected.

To identify eyes/patients with increased RT in the central subfield (clinical and subclinical macular edema) and in the inner and outer rings, the reference values established by DRCR.net were used.

For clinical macular edema (ClinicalTrials.gov Identifier: NCT01909791) [6]:

- RT ≥ 290 μm in women and ≥ 305 μm in men for Cirrus SD-OCT
- RT ≥ 305 μm in women and ≥ 320 μm in men for Spectralis SD-OCT

For subclinical macular edema [7–9]:

- RT > 260 and < 290 μm in women and > 275 and < 305 μm in men for Cirrus SD-OCT
- RT > 275 and < 305 μm in women and > 290 and < 320 μm in men for Spectralis SD-OCT

For the inner and outer rings (ClinicalTrials.gov Identifier: NCT01331005):

- Normal RT, if there was no more than 1 area above the normal range (normal mean + 2 SD) and no area 15 μm above the normal range
- Increased RT, if there was at least 2 areas above the normal range and/or 1 area 15 μm above the normal range

The normal mean + 2 SD values for the inner and outer rings, for Cirrus SD-OCT and Spectralis SD-OCT, are presented in table 1.

Sample Size

This study is a post hoc analysis of a prospective, 1-year, observational longitudinal study of 374 eyes/patients with diabetes type 2 mild NPDR (ETDRS levels 20 and 35). The sample size was determined to characterize retinal disease progression in type 2 diabetic patients with early NPDR [3].

Data Analysis

Categorical variables are summarized with frequencies and percentages and numerical variables with means and SD. The χ^2 test was used for categorical variables.

Table 1. Threshold values for the inner and outer rings (normal mean + 2 SD) for Cirrus and Spectralis SD-OCT

	Inner ring, μm		Outer ring, μm	
	Cirrus ¹	Spectralis ²	Cirrus	Spectralis
Nasal	348	366	313	331
Superior	345	363	294	312
Temporal	333	351	279	297
Inferior	342	360	286	304

¹ Information from Cirrus SD-OCT User Manual. ² A scaling factor was used [3].

Table 2. Location scores

Score	Location with increased RT
0	No increases in the central subfield, inner ring or outer ring
1	Increases in outer ring: 2 quadrants \geq normal mean + 2 SD or 1 quadrant \geq normal mean + 2 SD + 15 μm
2	Increases in outer ring: 3 or 4 quadrants \geq normal mean + 2 SD
3	Increases in inner ring: 2 quadrants \geq normal mean + 2 SD or 1 quadrant \geq normal mean + 2 SD + 15 μm
4	Increases in inner ring: 3 or 4 quadrants \geq normal mean + 2 SD
5	Criteria for score 3 + score 2 or criteria for score 4 + score 1
6	Criteria for score 4 + score 2
7	Increase in central subfield: subclinical macular edema (DRCR.net)
8	Criteria for score 7 + score 1
9	Criteria for score 7 + score 2
10	Criteria for score 7 + score 3
11	Criteria for score 7 + score 4
12	Criteria for score 7 + score 5
13	Criteria for score 7 + score 6

Logistic regression analysis was performed to assess the association of progression to clinical macular edema with the developed score and to assess the involvement of the inner and outer rings as a cumulative predictor of progression to clinical macular edema, by estimating the odds ratios (OR). Logistic regression analysis was also performed to assess the association of progression to clinical macular edema with the macular edema volume and maximum RT adjusted for instrument, by estimating the OR.

A receiver-operating characteristic (ROC) analysis was made for the developed score to identify threshold values for progression to clinical macular edema. Similarly, a ROC analysis was made for the maximum RT to identify threshold values for progression to clinical macular edema for each instrument. All statistical analyses were performed with STATA version 12.1 (StataCorp LP, College Station, Tex., USA), and p values ≤ 0.05 were considered statistically significant results.

Development of a Grading Score

Taking the DRCR.net classification of subclinical and clinical macular edema into account, grading scores were tested to evalu-

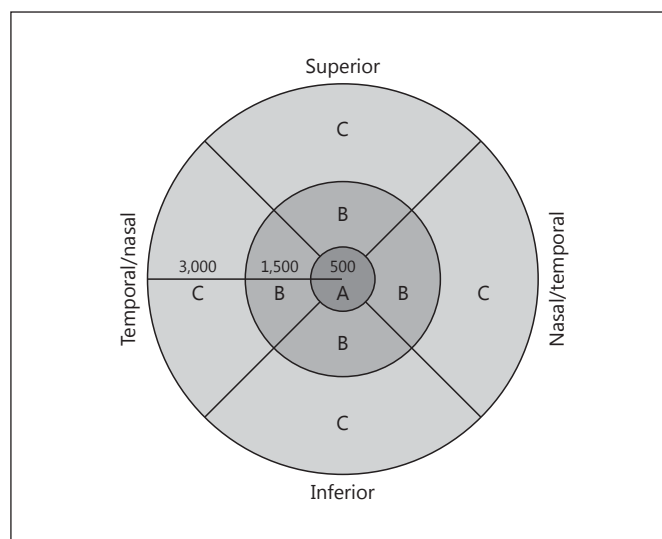


Fig. 1. Central subfield A and quadrants of the inner ring B and outer ring C as represented in OCT displays. Values are considered for the classification if they show an RT value in A corresponding to subclinical macular edema as defined by DRCR.net and RT values in B and C that are above threshold (average normal + 2 SD) in 2 quadrants or only 1 quadrant with an RT value 15 μm above threshold (average normal + 2 SD).

ate the relevance of RT changes in the 9 macular areas in the progression of macular edema.

The score takes into consideration the areas of increased RT (central subfield and inner and outer rings), as well as the number of affected areas (fig. 1). The developed grading score is presented in table 2.

Results

From the 194 eyes/patients (88 left eyes and 106 right eyes) examined with Cirrus SD-OCT at the baseline visit, 62 eyes/patients were classified as subclinical macular edema and 12 eyes/patients were classified as clinical macular edema. Twenty-five eyes/patients did not complete the 1-year follow-up. Therefore, a total of 169 eyes/patients (77 left eyes and 92 right eyes) were included in this analysis (fig. 2). From the 166 eyes/patients (78 left eyes and 88 right eyes) examined with Spectralis SD-OCT at the baseline visit, 42 eyes/patients were classified as subclinical macular edema and 12 eyes/patients were classified as clinical macular edema. Eighteen patients did not complete the 1-year follow-up. Therefore, a total of 148 eyes/patients (65 left eyes and 83 right eyes) were included in this analysis (fig. 2).

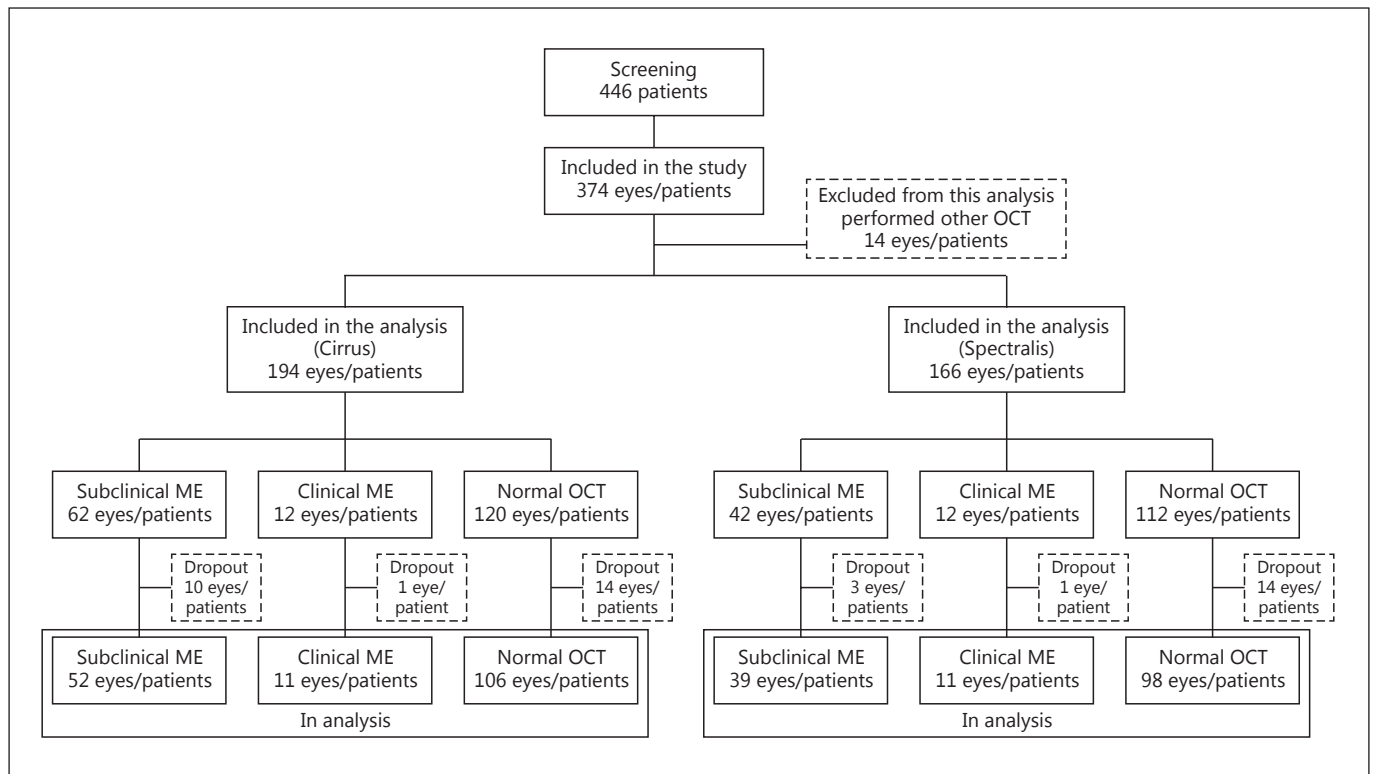


Fig. 2. Consort flowchart. ME = Macular edema.

Table 3. Baseline scores of eyes/patients with normal OCT and subclinical macular edema that completed the study (Cirrus, n = 158; Spectralis, n = 137)

Score at baseline	Cirrus		Spectralis	
	n	%	n	%
0	95	60.1	80	58.4
1	6	3.8	11	8.0
2	2	1.3	4	2.9
3	0	0.0	1	0.7
4	1	0.6	0	0.0
5	1	0.6	1	0.7
6	1	0.6	1	0.7
7	33	20.9	22	16.1
8	6	3.8	9	6.6
9	1	0.6	0	0.0
10	4	2.6	2	1.5
11	2	1.3	1	0.7
12	5	3.2	2	1.5
13	1	0.6	3	2.2
Total	158	100	137	100

The baseline characteristics of the patients enrolled in the study can be found in a previous publication of our group [3]. No statistically significant differences were found at baseline between the eyes/patients included in the study and the 43 eyes/patients that dropped out of the study.

Retinal Thickness

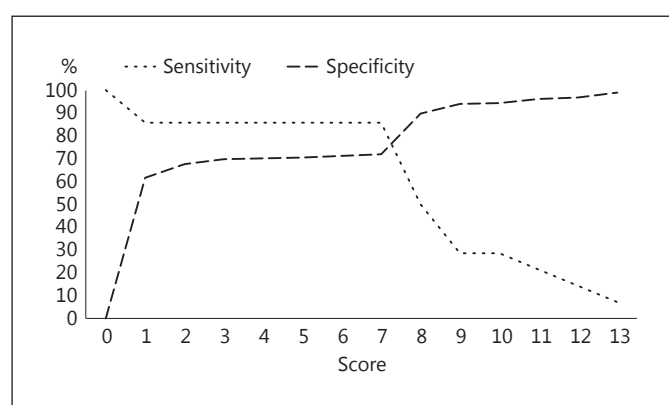
In the central subfield 24 eyes/patients (6.7%, corresponding to 6.2%, 95% CI: 2.8–9.6, with the Cirrus and 7.2%, 95% CI: 3.3–11.2, with the Spectralis) had an OCT diagnosis of clinical macular edema at baseline, according to the DRCR.net standards [6]. Subclinical macular edema was identified in 104 eyes/patients (28.9%, corresponding to 32.0%, 95% CI: 25.4–38.5, with the Cirrus and 25.3%, 95% CI: 18.7–31.9, with the Spectralis). Eyes/patients classified as subclinical and clinical macular edema at baseline occurred in eyes/patients with ETDRS levels of 20 and 35, respectively, in 8.3 and 25.9%.

The eyes/patients that showed increases in RT were in general the same during the entire follow-up period; 82.9% of the eyes with increased RT in the central subfield

Table 4. Baseline scores of eyes/patients that progressed and did not progress to clinical macular edema

	Score at baseline								
	<7	≥7	p value	<8	≥8	p value	<10	≥10	p value
No change to clinical macular edema, n (%)	202 (71.9)	79 (28.1)	<0.001*	252 (89.7)	29 (10.3)	<0.001*	265 (94.3)	16 (5.7)	0.001*
Change to clinical macular edema, n (%)	2 (14.3)	12 (85.7)		7 (50)	7 (50)		<0.001*	10 (71.4)	
Total	204 (69.2)	91 (30.8)		259 (87.8)	36 (12.2)		275 (93.2)	20 (6.8)	

*p ≤ 0.05 statistically significant.

**Fig. 3.** Score sensitivity and specificity.

at baseline had increased RT at month 12. An increase in RT occurred also in the inner ring (73.2%) and in the outer ring (72.8%).

The data were analyzed using the grading score presented in table 2. For these analyses the eyes/patients with clinical macular edema at baseline were excluded. The score, at baseline, of eyes/patients with normal OCT and subclinical macular edema at baseline that completed the study are presented in table 3. For the 14 eyes/patients that progressed to clinical macular edema in the 12-month period, 2 (14.3%) eyes/patients had a score of 0; 5 (35.7%) eyes/patients had a score of 7; 3 (21.4%) eyes/patients had a score of 8, and 4 (28.6%) eyes/patients had scores of 10 or higher.

An ROC analysis was made for the composite grading to identify threshold values for progression to clinical macular edema. The score presents a good discriminating value (AUC = 0.81). The score threshold value that best

predicted the progression to clinical macular edema was 7 (eyes/patients with increased central subfield), with 85.7% sensitivity and 71.9% specificity (fig. 3). To confirm the association of progression to clinical macular edema with the proposed score, the OR were estimated. The evaluation revealed that the score presented a significant association with progression to clinical macular edema (OR: 1.33, 95% CI: 1.16–1.52, p < 0.001).

When considering scores higher than 7, eyes/patients with increased central subfield and increased outer and/or inner rings, there was a statistically significant difference in the progression to clinical macular edema between eyes/patients with scores <8 and those with scores ≥8. Similar results were found considering score 10, eyes/patients with increased central subfield and at least increased RT in the inner ring (table 4).

To assess the involvement of the inner and outer rings as a cumulative predictor of progression to clinical macular edema, the OR were estimated considering as predictors central subfield increase only (score 7) and increased central subfield plus increased outer and/or inner rings (score >7). The evaluation revealed that a score >7 presented a higher association with progression to clinical macular edema (OR: 8.69, 95% CI: 2.85–26.52, p < 0.001) than a score of 7 (OR: 2.57, 95% CI: 0.82–7.99, p = 0.104).

In summary, during the 1-year follow-up period of the study, progression to clinical macular edema occurred in 14 eyes/patients, 14.3% of the eyes with scores <7, 35.7% of the eyes with a score of 7 (increased thickening only in central subfield) and 50% of the eyes with scores ≥8, showing the relevance of changes in the inner and outer rings.

Comparing the 2 subsets of data, score <7 and score ≥7, the score change was statistically significantly different. There was also a clear significant difference between

Table 5. Score change of eyes/patients with normal OCT and sub-clinical macular edema in the 12-month period

Score at baseline	Eyes/patients, n (%)		p value
	increase	no increase	
<7	28 (13.7)	176 (86.3)	0.027*
≥7	22 (24.2)	69 (75.8)	
<8	38 (14.7)	221 (85.3)	0.005*
≥8	12 (33.3)	24 (66.7)	
<10	45 (16.4)	230 (83.6)	0.320
≥10	5 (25)	15 (75)	
Total	50 (16.9)	245 (83.1)	

* $p \leq 0.05$ statistically significant.

the 2 subsets, score <8 and score ≥8, i.e. considering also the increase in the outer and/or inner rings. No difference was found between the 2 subsets of data, score <10 and score ≥10, i.e. considering also the increase in the outer and inner rings (table 5).

Macular Edema Composite Grading

The proposed composite grading should also include the highest absolute mean RT value of each of the 9 areas involved (central subfield, inner ring and outer ring) and an indication of the presence or absence of vitreous traction. In this study, eyes with vitreous traction were excluded. Because the value of volume of the increased areas is not immediately available to physicians in OCT machines, we looked at the data using the highest mean RT value registered in the central subfield or other areas, independently of its location. A multivariate analysis for the association of progression to clinical macular edema with the developed grading score and highest mean RT value controlled for age, gender and HbA_{1C} revealed that both grading score and RT values presented independent significant associations with progression to clinical macular edema, with score appearing to be the better predictor (OR: 1.20, 95% CI: 1.01–1.43, $p = 0.036$ and OR: 1.04, 95% CI: 1.00–1.09, $p = 0.044$, respectively).

An ROC analysis was also made for the highest mean RT value registered to identify threshold values for the progression to clinical macular edema for Cirrus SD-OCT and Spectralis SD-OCT. The highest mean RT value per area increased showed a good discriminating value (AUC = 0.82 for Cirrus SD-OCT and 0.81 for Spectralis SD-OCT). The best predictive value was 342 μm (with 83.3% sensitivity and 82.9% specificity) for Cirrus SD-

OCT and 348 μm (with 87.5% sensitivity and 69.0% specificity) for Spectralis SD-OCT.

We propose a composite grading for macular edema based on figure 2 and table 2. The mean RT values for the different areas of the OCT grid are considered abnormal if they correspond to the RT values defined by the DRCR.net as subclinical macular edema for the central subfield and if they are ≥2 SD beyond the normative database for the device used in the inner and outer rings of the OCT macula grid. The grading includes four characteristics: (1) the location of the edema (whether the central subfield is involved and which, if any, inner and outer rings are involved); (2) the amount of edema, represented by the highest absolute mean RT value registered in any of the subfields (central subfield or any quadrant of the inner and outer OCT rings); (3) the presence or absence of signs of vitreous traction, and (4) the identification of the OCT instrument with which the data were acquired. For example, an eye with increased RT in the central subfield and in two quadrants of inner ring, showing the highest mean RT value of 450 μm in one of the inner ring quadrants and NVT using Cirrus SD-OCT, would be identified as 10/450 μm/NVT/Cirrus SD-OCT. Another eye with increased RT only in the outer ring, involving three quadrants, showing the highest RT value of 480 μm in any one of the quadrants involved and NVT with the examination performed in the Spectralis SD-OCT, would be graded as 2/480 μm/NVT/Spectralis SD-OCT.

Discussion

This study is a post hoc analysis of a prospective, 1-year, observational longitudinal study of 374 eyes/patients with diabetes type 2 mild NPDR (ETDRS levels 20 and 35) and good visual acuity, examined at baseline and at 3, 6 and 12 months, in 19 clinical sites across Europe. The analysis focused on the identification of the relevance of RT changes in the inner and outer rings of the OCT macular area to characterize progression to clinical macular edema.

The study showed that increased RT in the central subfield is the best predictor for the development of clinical macular edema. However, the involvement of the inner and outer rings is also shown here to be a cumulative predictor of progression to clinical macular edema.

A composite grading of macular edema based on OCT measurements registered in the central subfield and the inner and outer macular rings was developed and tested

using the results of this study. The proposed composite grading takes into account the location of the edema, its extent and volume – parameters that were identified previously by an expert panel established to develop a classification of DME (led by Neil Bressler and including two of the authors of this document). More recently, a relatively simple approach was also suggested by Dolz-Marco et al. [10].

In the classification proposed here, the location of the edema is fundamental and is well identified by the involvement of the central subfield and/or other quadrants of the inner or outer rings. Volume is well represented by the highest mean RT value registered in any one of the subfields with edema. The presence or absence of signs of vitreous traction must be also indicated. Finally, the instrument with which the data were acquired should also be clearly identified.

A classification system for macular edema (once it is suspected from clinical examination or imaging of the retina) should be as simple and clear as possible, relatively easy to apply in clinical care and research, objective and reproducible. OCT provides an objective and reproducible method to identify and quantify macular edema, providing the necessary information for an objective classification.

The data presented here show that scores of 7 and higher, associated with higher RT values, are at higher risk for the development of clinical macular edema, needing medical intervention and indicating the need for closer follow-up.

The application of the proposed classification has been tested and validated in the present study. The potential drawbacks are directly associated with the OCT technique and instrumentation used and include fixation errors, instrument differences and the recognition that OCT machines are not available universally. This classification system is proposed as a basis for future refinement following its use in the ophthalmic community and research world.

Acknowledgment

This study was an investigator-driven observational nonfunded study sponsored by EVICR.net. The authors would like to thank the EVICR.net Study Group.

Disclosure Statement

None of the authors has any conflicts of interest to disclose.

References

- 1 Browning DJ, Altaweel MM, Bressler NM, Bressler SB, Scott IU: Diabetic macular edema: what is focal and what is diffuse? *Am J Ophthalmol* 2008;146:649–655, 655.e1–6.
- 2 EVICR.net. European Network of Clinical Research in Ophthalmology. Information update – January 2015. *Ophthalmic Res* 2015;53:188–193.
- 3 Ribeiro L, Bandello F, Tejerina AN, Vujosevic S, Varano M, Egan C, et al: Characterization of retinal disease progression in a one-year longitudinal study of eyes with mild non-proliferative retinopathy in diabetes type 2. *Invest Ophthalmol Vis Sci* 2015;56:5698–5705.
- 4 Bandello F, Tejerina AN, Vujosevic S, Varano M, Egan C, Sivaprasad S, et al: Retinal layer location of increased retinal thickness in eyes with subclinical and clinical macular edema in diabetes type 2. *Ophthalmic Res* 2015;54:112–117.
- 5 Tejerina AN, Vujosevic S, Varano M, Egan C, Sivaprasad S, Menon G, et al: One-year progression of diabetic subclinical macular edema in eyes with mild NPDR. Location of the increase in retinal thickness. *Ophthalmic Res* 2015;54:118–123.
- 6 Chalam KV, Bressler SB, Edwards AR, Berger BB, Bressler NM, Glassman AR, et al: Retinal thickness in people with diabetes and minimal or no diabetic retinopathy: Heidelberg Spectralis optical coherence tomography. *Invest Ophthalmol Vis Sci* 2012;53:8154–8161.
- 7 Bressler NM, Miller KM, Beck RW, Bressler SB, Glassman AR, Kitchens JW, et al: Observational study of subclinical diabetic macular edema. *Eye (Lond)* 2012;26:833–840.
- 8 Browning DJ, Fraser CM: The predictive value of patient and eye characteristics on the course of subclinical diabetic macular edema. *Am J Ophthalmol* 2008;145:149–154.
- 9 Pires I, Santos AR, Nunes S, Lobo C, Cunha-Vaz J: Subclinical macular edema as a predictor of progression to clinically significant macular edema in type 2 diabetes. *Ophthalmologica* 2013;230:201–206.
- 10 Dolz-Marco R, Abreu-González R, Alonso-Plasencia M, Gallego-Pinazo R: Treatment decisions in diabetic macular edema based on optical coherence tomography retinal thickness map: LET classification. *Graefes Arch Clin Exp Ophthalmol* 2014;252:1687–1688.