

1 SHORT COMMUNICATION

2

3 ***Dermocystidium* sp. (Mesomycetozoea: Dermocystidiaceae) primary ocular infection in a koi**
4 **carp (*Cyprinus carpio* var. *koi*)**

5

6 Rubina Sirri ¹, Andrea Gustinelli ¹, Silva Rubini ², Francesco Quaglio ³, Maria Letizia Fioravanti ¹

7

8 ¹*Alma Mater Studiorum University of Bologna, Department of Veterinary Medical Sciences,*
9 *Ozzano Dell'Emilia, Bologna, Italy;* ²*Istituto Zooprofilattico Sperimentale della Lombardia e*
10 *dell'Emilia Romagna, Cassana, Ferrara, Italy;* ³*University of Padua, Department of Comparative*
11 *Biomedicine and Food Science, Padua, Italy*

12

13

14 **Running head:** *Dermocystidium* sp. ocular infection in a koi

15

16

17

18

19

20 **Corresponding author:** Rubina Sirri. E-mail: rubina.sirri2@unibo.it

21

22

23

24

25 **Keywords:** *Dermocystidium* sp., Mesomycetozoea, koi carp, eye

26 *Dermocystidium* spp. (Mesomycetozoea: Dermocystidiaceae) comprises several species able to
27 infect a wide range of marine and freshwater fish (Gozlan et al., 2014; Rowley et al., 2013). The
28 taxonomic position of *Dermocystidium* is still under debate, even though Dyková and Lom (1992)
29 observed hyphae associated to *Dermocystidium koi* infection, suggesting its fungal nature.
30 Currently, the genus is classified in the superclass Mesomycetozoea which includes protists
31 “fungus-like” in the supergroup Opisthokonta (Gozlan et al., 2014).

32 The lesions caused by *Dermocystidium* spp. in fish are chronic and characterized by visible cysts or
33 nodules on skin and fins (Feist et al., 2004; Wildgoose, 1995; Zhang & Wang, 2005), but severe
34 gills and systemic infections causing mortality have been described in several species (Höglund et
35 al., 1997; Olson & Holt, 1995; Athanassopoulou, 1998; Landsberg & Paperna, 1992; Kirkbright et
36 al., 2016; Fujimoto et al., 2018).

37 The present study described a primary ocular infection by *Dermocystidium* sp. in a koi carp
38 (*Cyprinus carpio* var. *koi*). The koi carp was found dead by the owner of a private pond and sent
39 refrigerated to the laboratory. The fish presented an evident subconjunctival whitish exophytic
40 tissue, surrounded by reddish edges, that protruded over both ocular bulbs (Fig. 1a). The fish was
41 necropsied and tissues fixed in 10% buffered formalin. The ocular globes were then dissected under
42 stereomicroscope and smears of the exophytic tissue placed on slides, clarified with lactophenol or
43 stained with China ink, and examined under light microscope. For histopathology, tissues were
44 routinely processed, sections were cut at 4 μm and stained with Haematoxylin and Eosin (H&E),
45 Periodic Acid Schiff (PAS) and Gomori.

46 At the stereomicroscope, the peribulbar tissue and anterior chamber presented numerous filiform 3-
47 mm-length white hyphal-like cysts (Fig. 1b). At the light microscope, the cysts were filled with
48 round variably sized (5.53-12.90 μm in diameter; mean=9.71; sd=1.99; n=80) mature spores
49 referable to *Dermocystidium* sp. admixed with developmental stages (>5 μm). The spores showed a
50 large refractile body or central vacuole and a peripheral cytoplasm with a nucleus and three or more
51 vacuoles (Fig. 1c).

52 At histology, the peribulbar soft tissues until muscle and the choroid space of the posterior chamber,
53 adjacent to the retina, were infiltrated by numerous elongated cysts (Fig. 2f-h). The cysts had a
54 thick eosinophilic wall and contained numerous spores (Fig. 2h,i). Around the cysts, a
55 granulomatous inflammatory reaction was visible (Fig. 2h). The iris and the ciliary body were also
56 replete by numerous free mature spores. An intense mixed inflammatory infiltrate with
57 multinucleated giant cells, vascular congestion and abundant granulation tissue were observed (Fig.
58 2g). Haemorrhagic and necrotic areas were observed. Some basophilic granular aggregates referable
59 to bacteria were also found. Neither developmental stages of *Dermocystidium* sp. nor inflammatory
60 reaction were seen in internal organs. PAS and Gomori stains helped to visualize the developmental
61 stages (Fig. 1d,e) and exclude the presence of spores in other organs.

62 In literature, only three descriptions of ocular infection by *Dermocystidium* sp. are reported in fish
63 (Elkan, 1962; Molnar et al., 2008; Fujimoto et al., 2018). The present case is the first report of a
64 primary ocular infection in a koi carp. The spore size and morphology are consistent with literature
65 reports of *Dermocystidium koi* (Gjurcevic et al., 2008; Hoshina & Sahara, 1950). The life cycle of
66 *Dermocystidium* spp. is partly unknown. The parasite produces motile zoospores which encyst in
67 the host tissues, form sporonts by division of the plasmodia until subsequent maturation of spores
68 (Lotman et al., 2000; Mahboub & Shaheen, 2020). In experimental trials, it has been demonstrated
69 that fish can acquire the infection through intra-gastric and immersion routes. The pathogen cycle
70 begins from the ingestion of spores through feeding on infected fish or contaminated feed or via
71 penetration of spores into the gills (Mahboub & Shaheen, 2020).

72 Considering the economic value of koi carps and the possible direct transmission of the infection in
73 optimal temperatures condition, *Dermocystidium* spp. infection should be considered as an
74 important disease also in ornamental species.

75

76 **Conflicts of interests**

77 The authors declare to have no conflict of interests.

78

79 **Data availability**

80 The data that support the findings of this study are available from the corresponding author upon
81 request.

82

83 **References**

- 84 Athanassopoulou, F. (1998). Susceptibility of carp, roach and goldfish to a *Dermocystidium*-like
85 organism. *Journal of Fish Biology*, 53(5), 1137–1139. [https://doi.org/10.1111/j.1095-
86 8649.1998.tb00470.x](https://doi.org/10.1111/j.1095-8649.1998.tb00470.x)
- 87 Dyková, I., & Lom, J. (1992). New evidence of fungal nature of *Dermocystidium koi* Hoshina and
88 Sahara, 1950. *Journal of Applied Ichthyology*, 8(1–4), 180–185.
89 <https://doi.org/10.1111/j.1439-0426.1992.tb00681.x>
- 90 Elkan, E. (1962). *Dermocystidium gasterostei* n. sp., a parasite of *Gasterosteus aculeatus* L. and
91 *Gasterosteus pungitius* L. *Nature*, 196, 958–960. <https://doi.org/10.1038/196958a0>
- 92 Feist, S. W., Longshaw, M., Hurrell, R. H., & Mander, B. (2004). Observations of *Dermocystidium*
93 sp. infections in bullheads, *Cottus gobio* L., from a river in southern England. *Journal of Fish*
94 *Diseases*, 27(4), 225–231. <https://doi.org/10.1111/j.1365-2761.2004.00535.x>
- 95 Fujimoto, R. Y., Couto, M. V. S., Sousa, N. C., Diniz, D. G., Diniz, J. A. P., Madi, R. R., Martins
96 M. L., Eiras, J. C. (2018). *Dermocystidium* sp. infection in farmed hybrid fish *Colossoma*
97 *macropomum* × *Piaractus brachypomus* in Brazil. *Journal of Fish Diseases*, 41(3), 565–568.
98 <https://doi.org/10.1111/jfd.12761>
- 99 Gjurcevic, E., Bambir, S., Kozaric, Z., Kuzir, S., Gavrilovic, A., & Pašalic, I. (2008).
100 *Dermocystidium* infection in common carp broodstock (*Cyprinus carpio* L.) from Croatia. In
101 *Bulletin of the European Association of Fish Pathologists*, 28(6), 222–229.
- 102 Gozlan, R. E., Marshall, W. L., Lilje, O., Jessop, C. N., Gleason, F. H., & Andreou, D. (2014).
103 Current ecological understanding of fungal-like pathogens of fish: What lies beneath?

- 104 *Frontiers in Microbiology*, 5(62), 1–16. <https://doi.org/10.3389/fmicb.2014.00062>
- 105 Höglund, J., Alfjorden, A., & Nikkilä, T. (1997). Infection of juvenile salmon *Salmo salar* with a
106 *Dermocystidium*-like organism in Sweden. *Diseases of Aquatic Organisms*, 30(3), 171–176.
107 <https://doi.org/10.3354/dao030171>
- 108 Hoshina, T., & Sahara, Y. (1950). A new Species of the Genus *Dermocystidium*, *D. koi* sp. nov.,
109 Parasitic in *Cyprinus carpio* L. *Nippon Suisan Gakkaishi*, 15(12), 825–829.
110 <https://doi.org/10.2331/suisan.15.825>
- 111 Kirkbright, D., Huber, P., Lillie, B. N., & Lumsden, J. S. (2016). *Dermocystidium*-like organism
112 linked with a mortality event in yellow perch *Perca flavescens* (Mitchill) in Ontario, Canada.
113 *Journal of Fish Diseases*, 39(5), 597–601. <https://doi.org/10.1111/jfd.12379>
- 114 Landsberg, J., & Paperna, I. (1992). Systemic granuloma in goldfish caused by a *Dermocystidium*-
115 like aetiological agent. *Diseases of Aquatic Organisms*, 13, 75–78.
116 <https://doi.org/10.3354/dao013075>
- 117 Lotman, K., Pekkarinen, M., & Kasesalu, J. (2000). Morphological observations on the life cycle of
118 *Dermocystidium cyprini* Cervinka and Lom, 1974, parasitic in carps (*Cyprinus carpio*). *Acta*
119 *Protozoologica*, 39(2), 125–134.
- 120 Mahboub, H. H., & Shaheen, A. (2020). Prevalence, diagnosis and experimental challenge of
121 *Dermocystidium* sp. infection in Nile tilapia (*Oreochromis niloticus*) in Egypt. *Aquaculture*,
122 516, 7345562. <https://doi.org/10.1016/j.aquaculture.2019.734556>
- 123 Molnar, K., Muller, T., Lefler, K. K., & Csorbai, B. (2008). *Dermocystidium* infection in the eye of
124 crucian carp. *Magyar Allatorvosok Lapja*, 130(1), 53–56.
- 125 Olson, Robert E., & Holt, R. A. (1995). The gill pathogen *Dermocystidium salmonis* in Oregon
126 salmonids. *Journal of Aquatic Animal Health*, 7(2), 111–117. [https://doi.org/10.1577/1548-](https://doi.org/10.1577/1548-8667(1995)007<0111:TGPDSI>2.3.CO;2)
127 [8667\(1995\)007<0111:TGPDSI>2.3.CO;2](https://doi.org/10.1577/1548-8667(1995)007<0111:TGPDSI>2.3.CO;2)
- 128 Rowley, J. J. L., Gleason, F. H., Andreou, D., Marshall, W. L., Lilje, O., & Gozlan, R. (2013).
129 Impacts of mesomycetozoean parasites on amphibian and freshwater fish populations. *Fungal*

- 130 *Biology Reviews*, 27(3–4), 100–111. <https://doi.org/10.1016/j.fbr.2013.09.002>
- 131 Wildgoose, W. H. (1995). *Dermocystidium koi* found in skin lesions in koi carp (*Cyprinus carpio*).
- 132 *The Veterinary Record*, 137(13), 317–318. <https://doi.org/10.1136/vr.137.13.317>
- 133 Zhang, Q., & Wang, Z. (2005). *Dermocystidium* sp. infection in cultured juvenile southern catfish
- 134 *Silurus meridionalis* in China. *Diseases of Aquatic Organisms*, 65(3), 245–250.
- 135 <https://doi.org/10.3354/dao065245>

136

137 **Figure legends**

138 **Figure 1.** (a) Koi carp showing an ocular exophytic whitish tissue. (b) Numerous filiform hyphal-
139 like cysts visible at the stereomicroscope (bar=100 μm). (c) The cysts are filled with round mature
140 spores morphologically referable to *Dermocystidium* sp. (bar=10 μm). The spores show a large
141 refractile body (RB) and a peripheral cytoplasm with a nucleus and vacuoles (inset, arrow). (d)
142 Gomori stain shows cytological details of the spores (bar=10 μm). (e) PAS stain evidences the
143 developmental stages of the parasite. Four zoospores are visible inside a spore (arrowhead) (bar=10
144 μm).

145

146 **Figure 2.** (f) The choroid space near the retina is infiltrated by numerous cysts (asterisk) (H&E,
147 bar=500 μm). (g) The iris and the ciliary body are replete by numerous free mature spores
148 (arrowhead). A severe inflammatory reaction and granulation tissue are evident. Note the
149 multinucleated giant cells (inset) (H&E, bar=50 μm). (h) Around the cysts, a granulomatous
150 inflammatory reaction characterized by a wall of epithelioid cells is visible (inset) (H&E, bar=100
151 μm). (i) The cysts show a thick eosinophilic wall and contain spores at different developmental
152 stages (H&E, bar=50 μm).

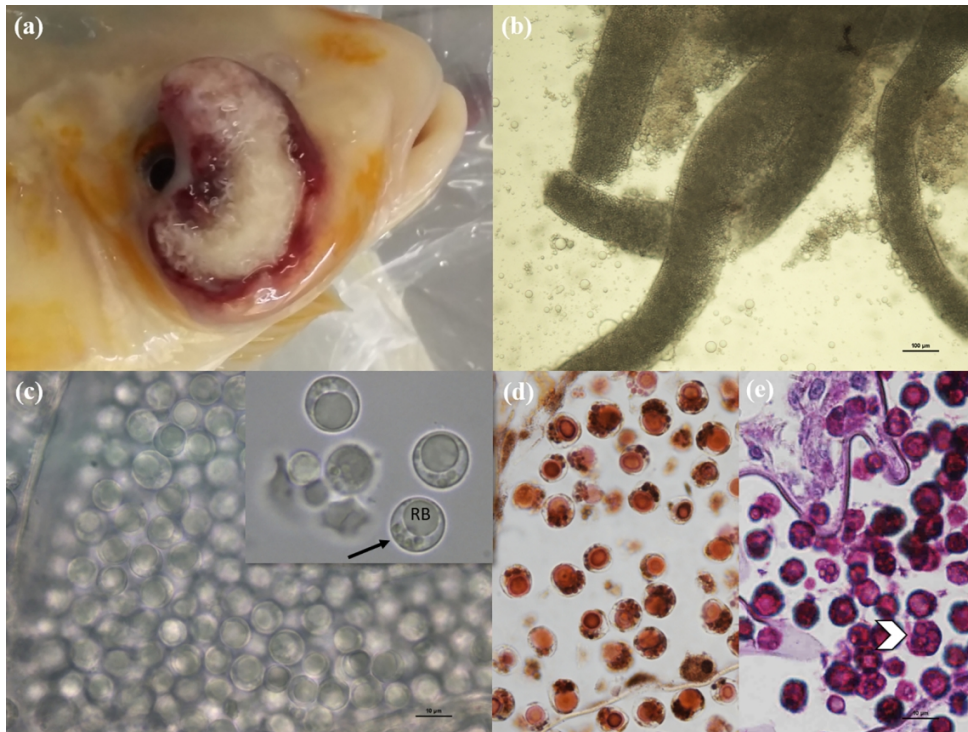


Figure 1. (a) Koi carp showing an ocular exophytic whitish tissue. (b) Numerous filiform hyphal-like cysts visible at the stereomicroscope (bar=100 µm). (c) The cysts are filled with round mature spores morphologically referable to *Dermocystidium* sp. (bar=10 µm). The spores show a large refractile body (RB) and a peripheral cytoplasm with a nucleus and vacuoles (inset, arrow). (d) Gomori stain shows cytological details of the spores (bar=10 µm). (e) PAS stain evidences the developmental stages of the parasite. Four zoospores are visible inside a spore (arrowhead) (bar=10 µm).

144x108mm (300 x 300 DPI)

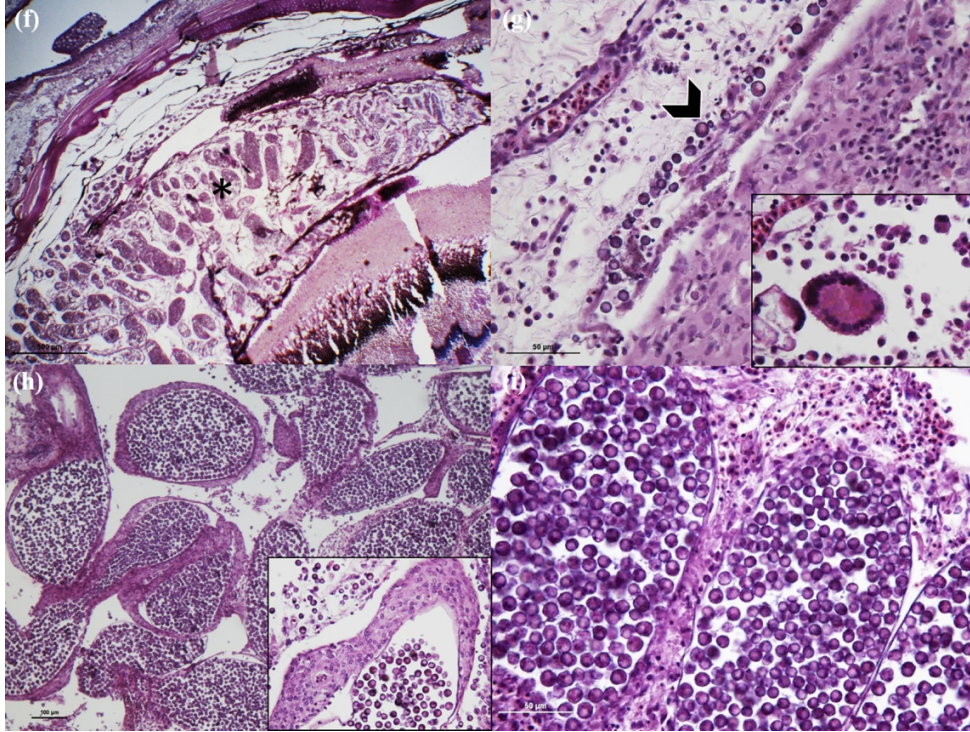


Figure 2. (f) The choroid space near the retina is infiltrated by numerous cysts (asterisk) (H&E, bar=500 μm). (g) The iris and the ciliary body are replete by numerous free mature spores (arrowhead). A severe inflammatory reaction and granulation tissue are evident. Note the multinucleated giant cells (inset) (H&E, bar=50 μm). (h) Around the cysts, a granulomatous inflammatory reaction characterized by a wall of epithelioid cells is visible (inset) (H&E, bar=100 μm). (i) The cysts show a thick eosinophilic wall and contain spores at different developmental stages (H&E, bar=50 μm).

144x108mm (300 x 300 DPI)