

Fecal microbiota transplantation for norovirus infection: a clinical and microbiological success

Brigida Barberio^{*}, Davide Massimi^{*}, Luciana Bonfante, Sonia Facchin, Lorenzo Calò, Marco Trevenzoli, Edoardo Vincenzo Savarino^{*} and Anna Maria Cattelan

Keywords: fecal microbiota transplantation, gut microbiota, norovirus, virus infection

Received: 15 May 2020; revised manuscript accepted: 26 May 2020.

We report a case of a 68-year-old woman, admitted to the Infectious Diseases Unit of Padua Hospital in April 2019 due to severe chronic diarrhea (up to 15 bowel movements with watery stools per day for 2 months), without associated general or gastrointestinal symptoms such as nausea, vomiting or fever. In her medical history, she reported a chronic pyelonephritis secondary to a congenital ureteral malformation, which required kidney transplantation in December 2008. Moreover, she presented with dyslipidemia and hypertensive cardiomyopathy due to a prior non-ST segment elevation myocardial infarction.

To note, before hospital admission the patient underwent optimization of immunosuppressive therapy with increasing the doses of tacrolimus, mycophenolate, and methylprednisolone because a biopsy showed chronic rejection (type 1A according to Banff 97 Classification), with a serum positivity for Anti-HLA Antibodies. Stools tested negative for pathogenic bacteria and parasites, but positive for norovirus (NoV) infection. C-reactive protein (CRP) levels >160 mg/dl and abnormal fecal calprotectin >2100 µg/g were observed. Although positive for NoV infection, she received antibiotic treatment with Cefixime for suspected bacterial superinfection for 10 days with poor clinical benefit and without stool negativization. A month later, during the outpatient visit, she continued to complain of diarrhea. Rifaximin and probiotics were prescribed without any success, and then antibiotic therapy with azithromycin was administered every other day until June 2019. But diarrhea and stool positivity for NoV persisted.

In July 2019, the clinical staff proposed fecal microbiota transplantation (FMT) as a possible remedy. The procedure was performed by colonoscopy, which was well tolerated and did not demonstrate mucosal abnormalities. During the FMT procedure, 250 ml of fresh fecal material was infused in the cecum of the patient. The donor's bacterial microbiota was analyzed and determined to be safe according to current FMT guidelines.¹ As described later, the patient's microbiota composition was profiled for research purposes both before and after the procedure. After FMT, complete symptom resolution was observed. Stool tests for NoV infection were repeated after 5 days and at four different time-points over 5 months and they all tested negative. No adverse events of clinical interest were observed. Fecal samples collected before FMT and 8 and 30 days after the procedure were examined. The fecal microbiota profiling was performed by sequencing partial 16S rRNA genes by Illumina Miseq (BMR Genomics, Padua, Italy). A dramatic decrease in *c_Epsilonproteobacteria* (*g_Campylobacter*: 14.6% versus 0.0%, before and after FMT, respectively) despite an increase in *c_Alphaproteobacteria* (*o_RF32*) and a rebalancing in *ph_Bacteroidetes* (1.4% versus 45.4% before and after FMT, respectively, with an increase of the *g_Bacteroides* and *g_Alistipes*) and *ph_Firmicutes* (84.3% versus 32.4% before and after FMT, respectively, with a decrease of *g_Anaerotruncus*, *g_Coproccoccus* and *g_Streptococcus* and an increase of *g_Ruminococcus*) were recorded. After 30 days, the relative abundance of *ph_Bacteroidetes* and *ph_Firmicutes* was retained and we observed an increase of *ph_Verrucomicrobia*

Ther Adv Gastroenterol

2020, Vol. 13: 1–4

DOI: 10.1177/
1756284820934589

© The Author(s), 2020.
Article reuse guidelines:
sagepub.com/journals-
permissions

Correspondence to:
Edoardo Vincenzo Savarino
Division of
Gastroenterology,
Department of
Surgery, Oncology
and Gastroenterology,
University of Padua, Via
Giustiniani 2, Padua,
35128, Italy
edoardo.savarino@unipd.it

Brigida Barberio
Davide Massimi
Sonia Facchin
Division of
Gastroenterology,
Department of
Surgery, Oncology
and Gastroenterology,
University of Padua,
Padua, Italy

Luciana Bonfante
Lorenzo Calò
Department of Internal
Medicine, Division of
Nephrology, University of
Padua, Italy

Marco Trevenzoli
Anna Maria Cattelan
Department of Internal
Medicine, Division of
Infectious Diseases,
University of Padua, Italy

*These authors
contributed equally to this
work.

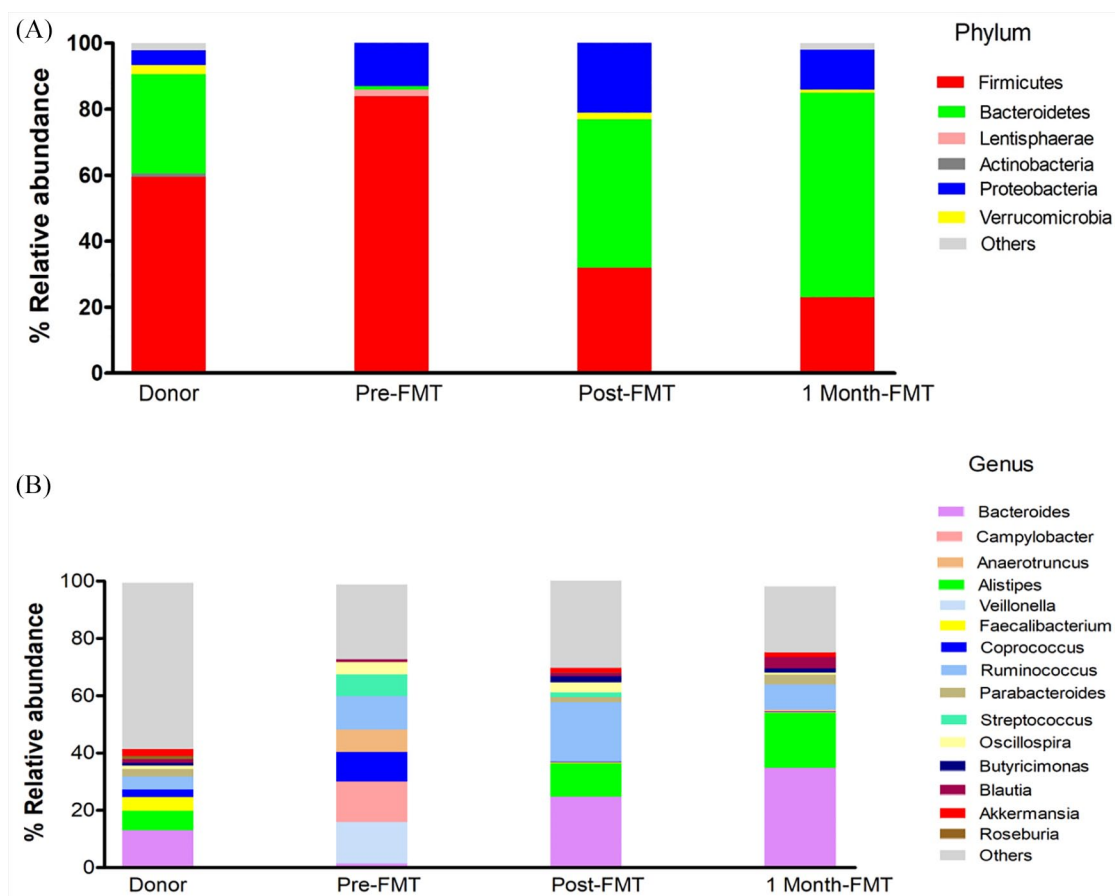


Figure 1. Bacteria relative abundance of donor fecal samples and of recipient at Phylum (A) and at Genus (B) level. FMT, fecal microbiota transplantation.

(g_ *Akkermansia s_muciniphila*) conversely the ph_ Proteobacteria (o_RF32) was clearly decreased (Figure 1A and B).

Discussion

FMT has proven to be a highly effective treatment for recurrent *Clostridioides difficile* infection, and, recently, its clinical utility in the management of intestinal multi-drug resistant (MDR) bacterial decolonization has gained considerable momentum.² At the state of art, eight case reports have been published showing that FMT is able to provide intestinal decolonization of extended spectrum β -lactamase (ESBL)-producing and carbapenemase-producing Enterobacteriaceae, vancomycin-resistant *Enterococcus*, or methicillin-resistant *Staphylococcus aureus* (MRSA).³ Moreover, interesting data support the use and safety of this procedure in immunodeficient patients.⁴

NoV infection is commonly reported in transplant recipients, in whom it tends to become chronic.⁵ Indeed, NoV showed intestinal cellular tropism and potential for persistent viral shedding after symptom resolution. Whereas relatively little is known about the *in vivo* replication of NoV, some insights have recently been gained into its cell tropism. A histopathological study of NoV-infected intestinal biopsies from immunocompromised patients revealed that NoV proteins can be detected in T cells, dendritic cells, and intestinal epithelial cells (IECs) throughout the length of the intestine. Early in the study of NoV–microbiota interactions, it was proposed that infection, which stimulates diarrheal disease, could alter the host intestinal microbiota. Viral diarrhea, in turn, decreases the diversity of the gut microbiome as a whole. In particular, Bacteroidetes, *Bifidobacterium spp.*, and *Lactobacillus spp.*, typically considered as healthy gut microbes, are decreased in children with

human norovirus (HNoV) diarrhea compared with healthy controls. Some NoV-infected adults have been reported to present with a similar decrease of Bacteroidetes and loss of bacterial richness and diversity, but this finding is true in only a minority of patients.^{6,7} Other studies have failed to detect microbiota changes in infected individuals.⁸ Therefore, it is reasonable to suspect that a variety of other factors including age, antibiotic usage, autoimmune status, host or viral genetics, and starting microbial composition may govern whether the host microbiota is susceptible to alteration by NoV infection. On the other hand, recent data suggest the intriguing possibility that specific bacteria may control NoV susceptibility. Abundance of two bacterial taxa, Ruminococcaceae and *Faecalibacterium* spp., were associated negatively with anti-NoV antibody titers in healthy controls. Subjects with a high abundance of these taxa may thus be protected naturally against NoV infection, as they lack a serological history of infection. However, the role of commensal bacteria in affecting NoV strains in gastrointestinal infection and strain-specific mechanisms is still to be determined. Indeed, the gut microbiota could play a role in both limiting and sustaining NoV infections.⁶⁻⁸

Beyond conservative therapies, there are no approved drugs for NoV treatment, although various strategies, including immunosuppression reduction, intravenous immunoglobulins, and nitazoxanide tablets (trade name Alinia produced in the United States but available in Italy for only off-label use), have been studied. Moreover, evidence supporting the use of FMT in the management of this kind of gastrointestinal viral infection is lacking. Indeed, the use of FMT in the treatment of NoV infection, is supported only by pre-clinical *in vitro* and *in vivo* studies on murine models.⁹ Moreover, although mechanisms underlying the alteration of NoV infection *in vitro* determined by specific microbial products have been investigated, their role in *in vivo* infections has not been fully assessed. In fact, modification of the taxonomic composition or specific bacterial pathways of the murine gut microbiota might allow a clearer assessment. The identification of microbial components that might consistently control NoV infection may have relevant therapeutic implications, and could, in part, explain the success we obtained with FMT in our case. Indeed, some preclinical evidence suggests that microbiota

modifying agents such as antibiotics and, in our case, FMT could play a therapeutic role in neutralizing the NoV infection. An alternative explanation of such success may be that the FMT treatment gave a reset enabling the microbiota to return to homeostasis, as it has been hypothesized to occur for recurrent *C. difficile* infections.

Our clinical case is the first to report clinical and biochemical success of FMT in NoV infection in an immunosuppressed patient, also during the follow up of 6 months. Thus, it seems to further support the efficacy of FMT in the management of gastrointestinal viral infections. No safety concerns have been raised, since the procedure was well tolerated despite the spectrum of clinically relevant comorbidities. In contrast to our result, it is important to note that a previous case series reported the lack of efficacy of FMT in one patient with chronic NoV infection, and, paradoxically, there are some cases in literature observing NoV infection following FMT, although the donors remained asymptomatic.^{10,11}

FMT is an innovative effective and safe procedure, not only to treat *C. difficile* infection but also to eradicate gastrointestinal infections sustained by virus and drug-resistant commensal bacteria that become pathogenic. Further studies are strongly needed to build even more solid evidence and to further implement the use of this procedure in clinical practice for indications different from *C. difficile* eradication.

Author contributions

BB, DM, SF, EVS, AMC: design of the study, data collection, writing of the manuscript, approving final version

LB, LC, MT: data collection and analysis, approving final version

Conflict of interest statement

The authors declare that there is no conflict of interest.

Ethics statement


Ethics approval was obtained from the local EC of Azienda Ospedaliera di Padova as amendment of the protocol n. 34358, 24/06/2015 approved by the Ethical Committee for Clinical Practice and written informed consent for the publication of this case report was obtained from the patient.

Funding

The authors received no financial support for the research, authorship, and/or publication of this article.

ORCID iDs

Brigida Barberio  <https://orcid.org/0000-0002-3164-8243>

Edoardo Vincenzo Savarino  <https://orcid.org/0000-0002-3187-2894>

References

1. Cammarota G, Ianiro G, Tilg H, *et al.*; European FMT Working Group. European consensus conference on faecal microbiota transplantation in clinical practice. *Gut* 2017; 66: 569–580.
2. Gargiullo L, Del Chierico F, D'Argenio P, *et al.* Gut microbiota modulation for multidrug-resistant organism decolonization: present and future perspectives. *Front Microbiol* 2019; 10: 1704.
3. Manges AR, Steiner TS and Wright AJ. Fecal microbiota transplantation for the intestinal decolonization of extensively antimicrobial-resistant opportunistic pathogens: a review. *Infect Dis (Lond)* 2016; 48: 587–592.
4. Neemann K, Eichele DD, Smith PW, *et al.* Fecal microbiota transplantation for fulminant clostridium difficile infection in an allogeneic stem cell transplant patient. *Transpl Infect Dis* 2012; 14: E161–E165.
5. Schorn R, Höhne M, Meerbach A, *et al.* Chronic norovirus infection after kidney transplantation: molecular evidence for immune-driven viral evolution. *Clin Infect Dis* 2010; 51: 307–314.
6. Walker FC and Baldrige MT. Interactions between noroviruses, the host, and the microbiota. *Curr Opin Virol* 2019; 37: 1–9.
7. Nelson AM, Walk ST, Taube S, *et al.* Disruption of the human gut microbiota following norovirus infection. *PLoS One* 2012; 7: e48224.
8. Chen SY, Tsai CN, Lee YS, *et al.* Intestinal microbiome in children with severe and complicated acute viral gastroenteritis. *Sci Rep* 2017; 7: 46130.
9. Sullender ME and Baldrige MT. Norovirus interactions with the commensal microbiota. *PLoS Pathog* 2018; 14: e1007183.
10. Lahtinen P, Mattila E, Anttila VJ, *et al.* Faecal microbiota transplantation in patients with *Clostridium difficile* and significant comorbidities as well as in patients with new indications: a case series. *World J Gastroenterol* 2017; 23: 7174–7184.
11. Schwartz M, Gluck M and Koon S. Norovirus gastroenteritis after fecal microbiota transplantation for treatment of clostridium difficile infection despite asymptomatic donors and lack of sick contacts. *Am J Gastroenterol* 2013; 108: 1367.