

Trauma and reconstruction

## The bladder-flap ureteral augmentation: An original solution in case of complex distal stricture

Alessandro Antonelli<sup>a</sup>, Nicolò Trabacchin<sup>a,\*</sup>, Carmelo Monaco<sup>a</sup>, Alessandro Tafuri<sup>a</sup>,  
Maria Angela Cerruto<sup>a</sup>, Fabrizio Dal Moro<sup>b</sup>

<sup>a</sup> Urology Clinic, Department of Surgery and Oncology, University of Verona, AOUI Verona, Piazzale Stefani n° 1, 37126, Verona, Italy

<sup>b</sup> Urology Clinic, Department of Surgical Oncological and Gastroenterological Sciences, University of Padua, Via Nicolò Giustiniani n° 2, 35126, Padua, Italy

### ARTICLE INFO

#### Keywords:

Bladder-flap  
Ureteral augmentation  
Innovative surgical technique  
Ureteral stricture management

### ABSTRACT

An original surgical solution for complex stenosis of the distal ureter is presented. A young, single-kidney male patient developed a stricture of the pelvic ureter after ureteroscopy and laser lithotripsy. Surgical repair was planned after the failure of conservative management. The ureter was sectioned prevesically and spatulated; a bladder flap with the same dimensions of the ureteral plate was taken from the anterior wall, and used to augment the ureter; finally an omental flap was wrapped around the reconstructed tract. Further radiological and ureteroscopic controls showed a largely patent reconstructed ureter, and follow up proved a regularly maintained kidney function.

### Introduction

Ureteral stenoses are a rare but major issue in urology, due to the iatrogenic cause in most of the cases and the potentially severe sequelae. Due to the large prevalence of urinary lithiasis and the advent of endourology as standard curative approach, the cases of ureteral stricture are increasing. A recent report indeed found an incidence of 1.8% cases/year on a sample of 995 procedures.<sup>1</sup>

Clinical presentation of ureteral stenosis covers a wide spectrum of scenarios depending on the site and extension. The pathogenesis is multifactorial because is related both on stone decubitus and surgical trauma.<sup>2</sup>

Surgery with open, laparoscopic or robotic approach, is generally reserved to the more complex strictures or those relapsed after endourological management.<sup>3</sup> The success depends on the achievement of tension-free, well vascularized and water-tight anastomoses. In pelvic ureter stenosis a ureteral resection and ureterocystoneostomy represents the first option, eventually combined with a bladder-psoas hitching, a vesical flap (Casati-Boari technique), or kidney mobilization. These solutions allow to treat the majority of pelvic stenosis, although in cases of longer strictures overpassing the iliac brim, the replacement of the ureter with bowel segments, interposition of the appendix, renal auto-transplantation, or autologous venous grafts can be required.<sup>4</sup>

Herein we present an original solution adopted to manage an extended benign stenosis of the pelvic ureter, by ureteral augmentation with a vesical flap.

### Case presentation

We report the clinical case of a 45-year-old patient with a single left kidney, following right nephrectomy in childhood for renal atrophy.

In May 2019 the patient underwent semi-rigid ureteroscopy (Ø 7 Ch) and laser lithotripsy (Calculase Storz holmium laser - 230 µm-6.4 Watt) of a 8-mm stone located in the pelvic ureter at the cross with iliac vessels; a double-J ureteral stent was allocated at the end of the procedure; post-operative course was uneventful and the stent was removed after 60 days. Thirty days later, the patient was admitted to the emergency department for acute flank pain, oligoanuria and lower limbs edema. Examinations revealed an acute renal failure - serum creatinine 1791 µmol/L - with metabolic acidosis and severe electrolytic imbalance, so that urgent dialysis was done. Unenhanced CT scan showed a left hydronephrosis until to the iliac cross with no residual stones, so that an ureteral stent was repositioned. Three months later the stent was removed, but in few days hydronephrosis relapse: at that time, any further attempt of retrograde and antegrade canalization failed, and a left percutaneous nephrostomy was placed. Descending

\* Corresponding author.

E-mail addresses: [alessandro.antonelli@aovr.veneto.it](mailto:alessandro.antonelli@aovr.veneto.it) (A. Antonelli), [nicolo.trabacchin@gmail.com](mailto:nicolo.trabacchin@gmail.com) (N. Trabacchin), [carmelo.monaco@aovr.veneto.it](mailto:carmelo.monaco@aovr.veneto.it) (C. Monaco), [aletaf@hotmail.it](mailto:aletaf@hotmail.it) (A. Tafuri), [mariaangela.cerruto@aovr.veneto.it](mailto:mariaangela.cerruto@aovr.veneto.it) (M.A. Cerruto), [fabrizio.dalmoro@unipd.it](mailto:fabrizio.dalmoro@unipd.it) (F.D. Moro).

<https://doi.org/10.1016/j.eucr.2021.101636>

Received 9 February 2021; Received in revised form 5 March 2021; Accepted 7 March 2021

Available online 10 March 2021

2214-4420/© 2021 The Authors.

Published by Elsevier Inc.

This is an open access article under the CC BY-NC-ND license

(<http://creativecommons.org/licenses/by-nc-nd/4.0/>).

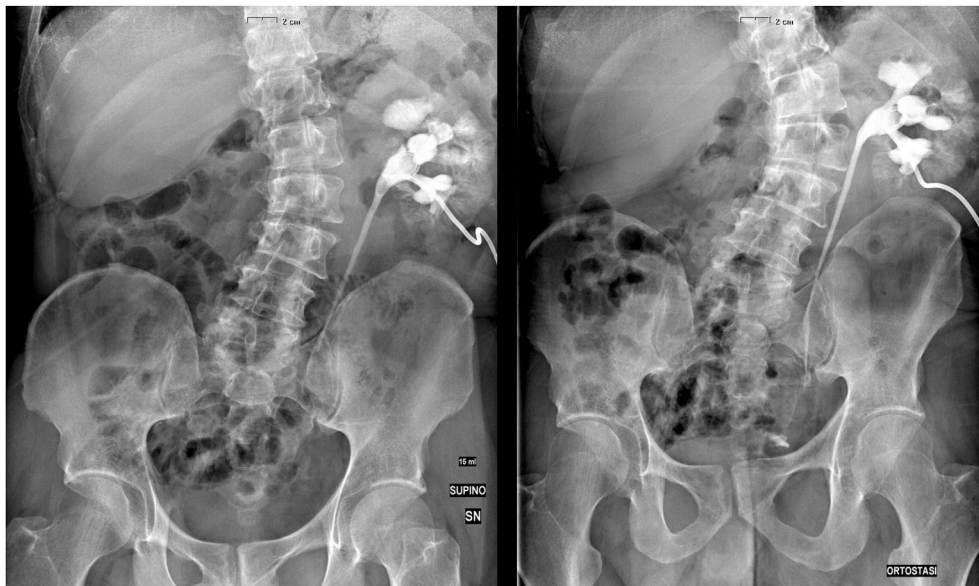

Fig. 1. Pre-operative descending nephrostography with minimal flow of contrast below the lower lumbar ureter and pyelocanalicular reflux caused by a higher-pressure injection.

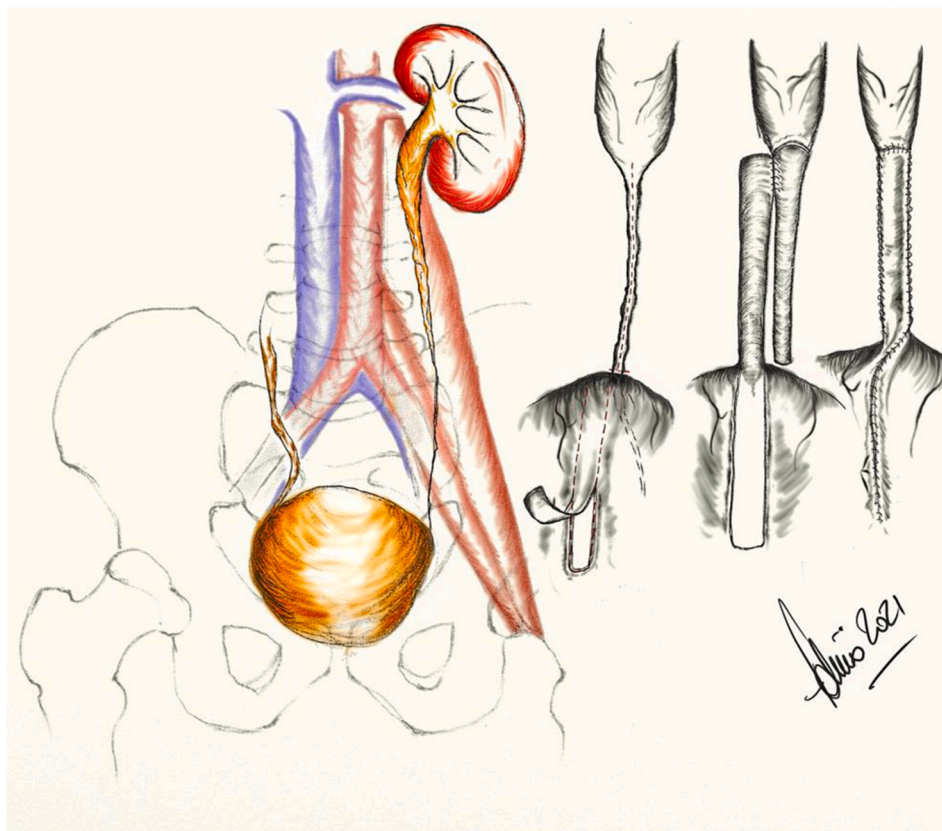
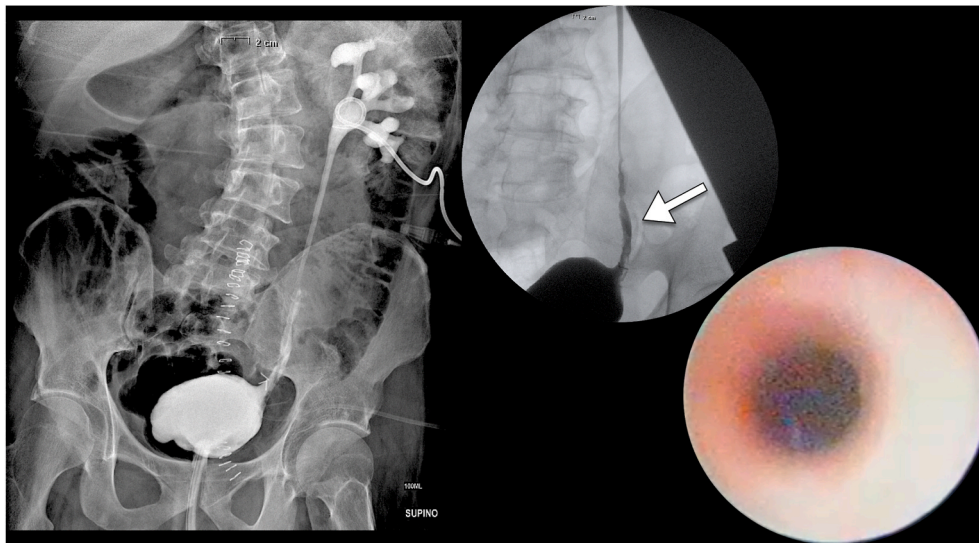


Fig. 2. Surgical steps to obtain a bladder-flap for ureteral augmentation by a side-to-side anastomosis.

nephrostography showed that, under pressure, there was only a minimal flow of contrast below the lower lumbar ureter, along a narrowed pelvic ureter (Fig. 1).

Accordingly, a surgical approach was planned with the aim to perform an ureterocystoneostomy with a Casati-Boari bladder flap, through a sub-umbilical midline laparotomy. The ureter was resected as distally as possible and longitudinally opened along its stenotic tract,

reaching a patent lumen only 3–4 cm above the cross with the common iliac artery; retrograde ureteroscopy confirmed the lack of residual stones and the adequate caliber of the remnant ureter. The umbilical arteries were sectioned and the bladder mobilized to configure a bladder flap, as planned. However, the bladder capacity and elasticity appeared suboptimal so that we decided to take bladder flap smaller than expected. Thus, instead of creating a narrow tubule made with such a



**Fig. 3.** Post-operative descending nephrostography with flow of contrast up to the bladder with a low injection pressure. Ureteroscopy that showed a wide and regular lumen of the augmented ureter with no signs of ischemia.

smaller flap, we decided to use it to augment the spatulated ureter by a side-to-side anastomosis. The ureterocystostomy was then completed, protected by polyfenestrated ureteral catheter, and the cystostomy sutured (Fig. 2). Finally an omental flap was wrapped around the augmented ureter. Post-operative course was uneventful, and the patient discharged in 10 days, after the removal of urethral and ureteral catheters. The descending nephrostography at 30 days from surgery showed a prompt flow through the augmented ureter, and nephrostomy was removed (Fig. 3). After 3 months the patient underwent urodynamics because of lower urinary symptoms, finding detrusor overactivity and bladder outlet obstruction: in order to protect the kidney from possible reflux and infection, transurethral resection of the prostate (TURP) was performed, with a complete relief of symptoms. Concomitantly to the TURP, an ureteroscopy was done and showed a wide and regular lumen of the augmented and native ureter, with no signs of ischemia (Fig. 3).

At 12 months of follow up the patient is asymptomatic, with regular renal function and ultrasound shows no dilation of the urinary tract.

## Discussion

The presented case deals with an extensive pelvic stenosis following the endourological treatment of lithiasis, for which conservative management was unsuccessful. A “standard” surgical approach was planned, with the aim to perform a Casati-Boari ureteroneocystostomy, but this solution proved to be unfeasible and we opt for a ureteral augmentation. Such a solution restored ureteral canalization and preserved renal function at long term. Moreover, we avoided to recur at ureteral replacement with an ileal segment or autotransplantation, with inherent concerns in surgical morbidity and potential metabolic sequelae. As widely accepted in case of complex strictures of the lumbar ureter, we followed the strategy to augment the stenotic tract, but using the bladder wall instead of other autologous tissues, as the buccal mucosa.<sup>5</sup> The premise for the success of this solution was that the stenotic ureter after spatulation provided a plate with adequate width. In such case a minimal bladder flap, long as the stricture and wide as the ureteral plate proved to be sufficient. The apposition of an omental wrap offered a further vascular supply to the reconstruction. Post-operative endoscopy

indeed confirmed a well vascularized and trophic mucosa in the augmented and native ureter. However, it should be acknowledged that achieving of a well vascularized flap represents the major issue of this technique and additional evidence is needed to confirm the safety of the presented solution.

The major drawback is the lack of antireflux mechanism, that implies to relief bladder outlet obstruction with high detrusorial pressures when present.

## Conclusion

The bladder-flap ureteral augmentation is a viable, technically easy and effective option to manage some selected cases of complex pelvic strictures not amenable of “standard” solutions.

## Funding

None of the authors received any financial support for this research.

## Declaration of competing interest

The authors declare no conflict of interest.

## References

1. Ulvik Øyvind, Harneshaug Jill-Randi, Gjengstø Peder. Ureteral strictures following ureteroscopic stone treatment. *J Endourol.* 2020 Oct 21. <https://doi.org/10.1089/end.2020.0421>.
2. Dong Hao, Peng Yonghan, Li Ling, Gao Xiaofeng. Prevention strategies for ureteral stricture following ureteroscopic lithotripsy. *Asian J Urol.* 2018 Apr;5(2):94–100. <https://doi.org/10.1016/j.ajur.2017.09.002>.
3. Schiavina R, Zaramella S, Chessa F, et al. Laparoscopic and robotic ureteral stenosis repair: a multi-institutional experience with a long-term follow-up. *J Robot Surg.* 2016 Dec;10(4):323–330. <https://doi.org/10.1007/s11701-016-0601-0>.
4. Tyritzis SI, Wiklund NP. Ureteral strictures revisited trying to see the light at the end of the tunnel: a comprehensive review. *J Endourol.* 2015;29:124e36. <https://doi.org/10.1089/end.2014.0522>.
5. Lee Ziho, Keehn Aryeh Y, Sterling Matthew E, Metro Michael J, Eun Daniel D. A review of buccal mucosa graft ureteroplasty. *Curr Urol Rep.* 2018 Mar 1;19(4):23. <https://doi.org/10.1007/s11934-018-0772-5>.