




Multidrug resistant *Enterococcus faecium* isolate from cholangitis/cholecystitis in a dog

Alessio Sposato¹  | Marco Cordisco¹  | Giuseppe de Ruvo² | Silvia Ferro³  |
 Rossana Alessandra Raineri² | Adriana Trotta¹ | Domenico Buonavoglia¹ |
 Marialaura Corrente¹

¹Department of Veterinary Medicine, University of Bari "Aldo Moro", Bari, Italy

²Cliniche Veterinarie Pinerolesi Srl, Turin, TO, Italy

³Department of Comparative Biomedicine and Food Science BCA, Legnaro, Padua, Italy

Correspondence

Alessio Sposato, Department of Veterinary Medicine, University of Bari, Valenzano, Bari, Italy.

Email: alessio.sposato@izspb.it

Abstract

Mucocele and cholecystitis were diagnosed in a 10 year-old Shetland-sheepdog presenting aspecific clinical signs. Blood examinations and ultrasonography investigation were performed before to surgical approach, which allowed to collect biopsies and samples for bacteriological analyses. In addition, the patient was subjected to cholecystectomy. A multidrug resistant *Enterococcus faecium* was isolated from the gallbladder specimens. On the basis of antimicrobial susceptibility test, nitrofurantoin was used. The correct bacteriological diagnosis is necessary to set up effective therapy, influencing the patient's prognosis and improving the recovery time.

KEYWORDS

Enterococcus faecium, gallbladder, liver pathology, MDR bacteria, mucocele

1 | INTRODUCTION

Cholangitis/cholecystitis are characterized by inflammation confined to the portal region of the liver with either infiltration into the bile duct epithelium or within the ductal lumen, involving the epithelium and lumen of the gallbladder (van den Ingh et al., 2006). In addition, mucocele of the gallbladder is characterized by the accumulation of mucin-laden bile in the gallbladder (Center, 2009; Crews et al., 2009) and cholestasis, resulting in excessive distension of the gallbladder walls (Kovatch et al., 1965).

Gookin and co-authors have reported gallbladder mucocele (GBM) in dogs affected by hyperadrenocorticism, hypothyroidism and hyperlipidemia. The authors speculate that these diseases heighten the risk of an already susceptible dog (Gookin et al., 2018). These conditions can cause gallbladder paresis resulting in biliary stasis and cholecystitis (Besso et al., 2000). Moreover, metabolic disturbances cause immune dysregulation and may contribute to the development of aseptic cholecystitis in dogs with gallbladder mucocele (Mori et al., 2009).

Some cases of cholangitis/cholecystitis and mucocele caused by bacteria have been described in dogs (Neel et al., 2006; O'Neill et al., 2006; Tamborini et al., 2016).

Usually, subjects suffering from cholangitis/cholecystitis do not have specific clinical signs or alteration in the haematological parameters, and the causes are not routinely investigated. Ultrasound examination is essential to evaluate changes in the typical aspects of the liver structures and to do diagnosis of liver pathology.

In this study, a case of mucocele and cholangitis/cholecystitis in a dog, associated with *Enterococcus faecium*, is reported.

2 | MATERIALS AND METHODS

2.1 | Case report

A 10-year-old, intact male Shetland-sheepdog was referred to the veterinary clinic "Cliniche Veterinarie Pinerolesi s.r.l.", presenting

This is an open access article under the terms of the [Creative Commons Attribution-NonCommercial-NoDerivs](https://creativecommons.org/licenses/by-nc-nd/4.0/) License, which permits use and distribution in any medium, provided the original work is properly cited, the use is non-commercial and no modifications or adaptations are made.

© 2022 The Authors. *Veterinary Medicine and Science* published by John Wiley & Sons Ltd.

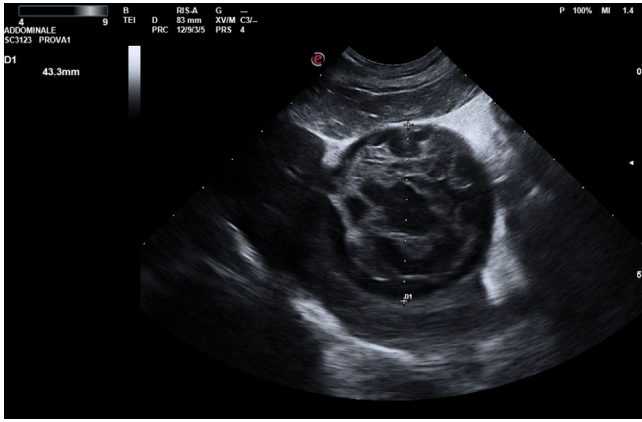


FIGURE 1 Ultrasound examination obtained by MyLabAlpha (Esaote S.p.A., Genova, Italy) using MicroConvex Probe SC3123 VET 4–9 mhz at 9 mhz, showing the gallbladder over-distended with hyperechoic material with an irregular structure referable to bile

anorexia, vomiting, diarrhoea and fever (40.6°). In addition, the dog was affected by severe depression, lateral decubitus with difficult in maintaining the normal station, tachycardia and abdominal pain. The animal was hospitalized and waiting for the results of blood analyses and ultrasound examination, fluid therapy was set up, associated with empiric antibiotic treatment (enrofloxacin, 5 mg/kg body weight [BW]) and pain relief therapy (buprenorphine hydrochloride, 0.02 mg/kg BW).

2.2 | Haematological and biochemical analyses

Several blood samples for haematological and biochemical analyses were taken in order to investigate the blood parameters alteration on day 1, 3, 6, 15, 18, 20, 24, 27 and 77.

The biochemical analysis suggested a hepatocellular injury (all the hepatic enzymes such as AST, ALT, ALP and GGT were altered), a decreased hepatic function (moderate hypoproteinaemia and hypoalbuminemia), with a severe form of cholestasis (hyperbilirubinemia and markedly increased of alkaline phosphatase (ALP) as shown in Table 1.

Haematological data initially showed no increase of white blood cells and a normal profile, except for a low platelets count (from day 1 up to 6). The animal presented right shift with presence of neutrophils with toxic granulations (Table 2). No haemoparasites were found in the blood smear.

2.3 | Ultrasound examination and cholecystectomy

A complete abdominal ultrasound examination was performed, and the gallbladder was seen overstretched, with the presence of mucus, along the walls and accumulation of bile in the centre of the cavity. The gallbladder appeared enlarged and over-distended, filled with compact green material and was subjected to histological exam. The instrumental examination also showed an ultra-distension of the common bile duct (Figure 1).

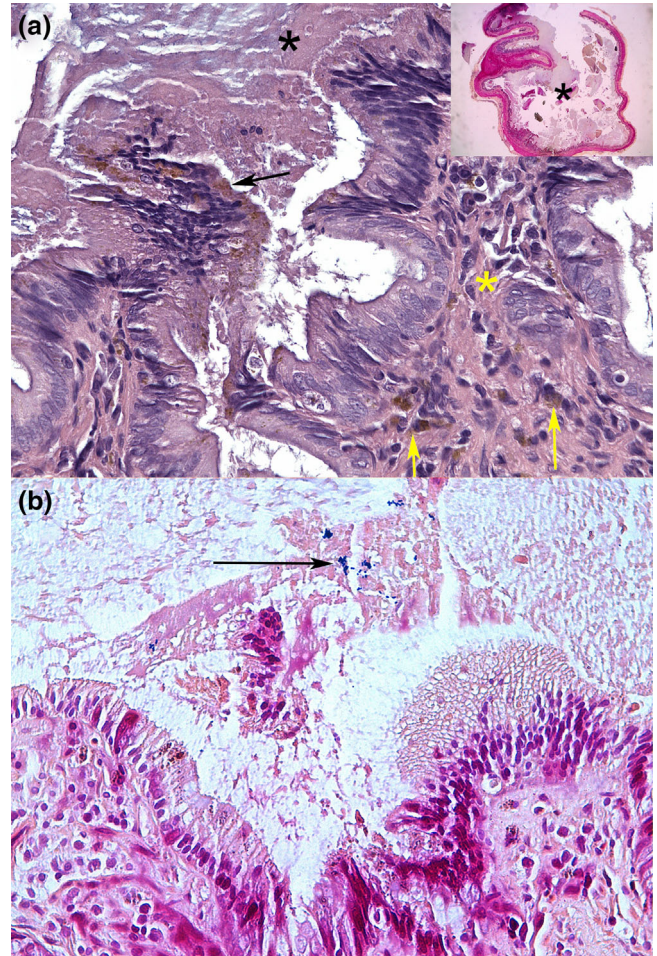


FIGURE 2 (a) Gallbladder, dog. The mucosa shows a mild lymphoplasmacytic infiltrate in the propria-sottomucosa (yellow asterisk), admixed with pigment macrophages (yellow arrows). A moderate amount of pigment is present also in the cytoplasm of some epithelial cells (black arrows) and abundant secretum fills the lumen (black asterisk). Hematoxylin and eosin (H&E) stain, x40 magnification. Inset: low magnification of full-thickness wall delimiting the lumen (asterisk). Gram stain, x2 magnification. (b) Gallbladder, dog. In the lumen there are some Gram-positive cocci (arrow). Gram stain, x40 magnification

Based on the results of diagnostic imaging, a gallbladder mucocele was diagnosed, caused by outlet obstruction of the gallbladder wall in the neck areas of the gallbladder or in the cystic duct. A cholecystectomy was performed in order to collect biopsies for histopathological examinations and bacteriological investigation.

At the histological examination (haematoxylin–eosin) the supporting stroma of the gallbladder wall presented inflammatory infiltration, mainly represented by lymphocytes and plasma cells containing greenish-yellow pigment, attributable to the biliary pigment (Figure 2a). In addition, Gram staining revealed the presence of Gram + in the gallbladder lumen (Figure 2b).

Few days after the surgery, although blood examinations of the previous days, showed no significant alteration, clinical conditions of the

TABLE 1 Biochemistry data of the Shetland-sheepdog

Parameters	Reference range	Values								
		Day 1	Day 3	Day 6	Day 15	Day 18	Day 20	Day 24	Day 27	Day 77
Creatine kinase UI/l	20–150	87	186	91	–	–	–	86	–	69
AST (GOT) U/l	12–54	176	117	42	83	40	45	23	47	24
ALT (GPT) U/l	15–64	216	239	14	41	12	23	16	9	47
ALP UI/l	20–120	305	468	587	213	213	458	234	244	20
GGT UI/l	2–8	9	9	11	–	–	–	7	–	3
Cholinesterases UI/l	3600–7600	3399	4175	4897	–	–	–	2582	–	3630
Lipase mg/dl	5–120	68.7	–	–	–	–	–	–	–	–
Total bilirubin (mg/dl)	0.08–0.3	0.97	0.67	0.56	0.25	0.57	0.43	0.23	0.18	0.15
Glucose (mg/dl)	75–115	107	109	95	88	106	108	97	95	95
Cholesterol (mg/dl)	110–330	189	202	192	–	–	–	184	–	212
Triglycerides (mg/dl)	23–110	304	92	88	–	–	–	42	–	46
Urea (mg/dl)	11–43	26	30	24	21	17	44	17	15	39
Creatinine (mg/dl)	0.7–1.30	0.72	0.72	0.74	0.52	0.41	0.50	0.78	0.45	0.54
Total protein (g/dl)	5.5–7.6	5.21	5.5	5.48	4.90	5.8	7.10	5.90	5.97	6.00
Albumin (g/dl)	2.4–3.8	2.24	2.36	2.67	2.39	2.61	3.16	2.74	2.42	2.82
Globulin (g/dl)	2.5–4.3	2.97	3.14	2.81	2.51	3.19	3.94	3.16	3.55	3.18
Albumin / Globulin (g/dl)	0.68–1.30	0.75	0.75	0.95	0.95	0.82	0.80	0.87	0.68	0.89
Calcium (mg/dl)	8.0–11.6	7.77	8.29	8.88	7.92	8.44	9.78	9.23	8.02	9.79
Phosphorus (mg/dl)	2.5–5.5	2.29	3.29	4	4.78	4.15	5.57	5.44	4.93	3.04
Calcium / Phosphorus (mg/dl)	<60	21	31	39	–	–	–	54	–	30
Sodium (Na) (mmol/l)	140–154	136	142	145	141	145	146	143	141	141
Potassium (K) (mmol/l)	3.8–5.6	3.49	3.88	4.52	4.06	4.15	4.85	5.17	4.66	4.71
Na / K	>27	39	37	32	35	35	30	28	30	30
Chloride (mmol/l)	102–117	108	109	104	112	110	109	108	108	107
Magnesium (mg/dl)	1.00–3.00	1.54	0.86	1.12	–	–	–	1.75	–	3.01
Iron (µg/dl)	100–220	57	67	93	47	63	158	105	35	138

Bold was used for the values that were different from the normal range of the individual analyzed parameters.

Abbreviation: GGT, gamma-glutamyl transferase; ALP, alkaline phosphatase; ALT, alanine aminotransferase; AST, aspartate aminotransferase.

dog worsened. Therefore, the blood examinations were repeated and the leukogram showed the high presence of White Blood Cells (WBC), segmented neutrophils and monocytes (at day 15th: WBC = 38.2 k/µl, segmented neutrophils = 34380 n/µl and monocytes = 1910 n/µl) providing suspicion of a possible bacterial infection, responsible of cholangitis/cholecystitis and the subsequent evolution into mucocele.

2.4 | Bacteriological analysis

Samples collected from the gallbladder lumen were taken by veterinary personnel of the clinic using Amies Transport swabs and were cultured onto Columbia blood agar (CBA), McConkey agar (MCK), Mannitol salt agar (MSA), (Liofilchem, Teramo, Italy) and incubated at 37°C, for 48 h with aerobic, anaerobic and microaerophilic conditions.

White haemolytic smooth colonies, with a diameter of 2–3 mm, grown on CBA plates, following 24 h of incubation in aerobic conditions, were observed. No other bacteria were observed after 48 h of incubation in other media.

Gram-positive cocci, catalase negative, were found and were biochemically identified as *Enterococcus* spp. using the API Strep System (bioMérieux, Marcy-l'Étoile, France).

Considering the main route for the etiopathogenesis of a bacterial cholecystitis (Sung et al., 1992), a rectal swab was also collected from the dog and the same culture procedure was performed. From this sample we isolated other colonies, which were biochemically identified as *Enterococcus* spp. using API Strep System (bioMérieux, Marcy-l'Étoile, France). The sample was taken by a veterinarian using Amies Transport swab.

Subculture in a selective medium for Enterococci (Slanetz and Bartley agar medium; Oxoid Ltd, Hampshire, United Kingdom), was used to obtain pure cultures for biomolecular identification.

TABLE 2 Hematological data of the Shetland-sheepdog

Parameters	Reference range	Values								
		Day 1	Day 3	Day 6	Day 15	Day 18	Day 20	Day 24	Day 27	Day 77
WBC (k/ μ l)	6.0–14.4	8.1	10.8	11.2	38.2	56.2	37.6	19.9	39.7	9.53
RBC ($10^6/\mu$ l)	5.5–8.1	5.76	6.14	6.33	5.80	5.05	5.20	5.71	4.75	6.18
Hgb (g/dl)	13.1–18.7	12.0	13.4	13.2	12.4	10.4	10.9	13.4	10.8	14.4
HCT (%)	38.6–54.5	38.7	41.3	42.7	39.0	33.7	34.7	38.9	32.1	42.6
MCV (fl)	61–72.6	67.2	67.2	67.5	67.2	66.8	66.8	68.2	67.4	68.9
MCH (pg)	20.8–25.3	20.8	21.8	20.8	21.4	20.6	21.0	23.4	22.6	23.3
MCHC(g/dl)	30–37	31.0	32.4	30.9	31.9	30.8	31.4	34.3	33.5	33.8
RDW (%)	11.9–15	13.2	13.8	14.2	13.1	14.2	13.1	14.8	14.3	12.7
PLT ($10^3/\mu$ l)	150–460	57	11	8	211	34	421	464	271	385
MPV (fl)	8–11.5	–	–	–	–	–	18.20	14.20	–	9.14
PCT (%)	0.12–0.4	–	–	–	–	–	0.765	0.660	–	0.352
PDW (%)	6–68	–	–	–	–	–	22.0	19.6	–	18.3
% Myelocytes (%)	0–0	0	–	–	–	–	–	–	–	–
% Metamyelocytes (%)	0–0	0	–	–	–	–	1	–	–	–
% Band Neutrophils (%)	0–3	0	0	0	0	1	2	2	1	0
% Segmented Neutrophils (%)	43–77	88	90	71	90	87	86	75	88	55
% Lymphocytes (%)	12–40	6	6	13	4	4	5	8	3	31
% Monocytes (%)	3–10	4	4	16	5	8	6	10	7	13
% Eosinophils (%)	0–7	2	0	0	1	0	0	4	1	1
% Basophils (%)	0–1	0	0	0	0	0	0	1	0	0
Myelocytes (n/ μ l)	0–0	–	–	–	–	–	–	–	–	–
Metamyelocytes (n/ μ l)	0–0	–	–	–	–	–	–	–	–	–
Band Neutrophils (n/ μ l)	0–300	0	0	0	0	562	752	398	397	0
Segmented Neutrophils (n/ μ l)	3000–8900	7128	9720	7952	34,380	48,894	32,336	14,925	34,936	5241
Lymphocytes (n/ μ l)	1300–4100	486	648	1456	1528	2248	1880	1592	1191	2954
Monocytes (n/ μ l)	200–1000	324	432	1792	1910	4496	2256	1990	2779	1238
Eosinophils (n/ μ l)	150–1100	162	0	0	382	0	0	796	397	95
Basophils (n/ μ l)	0–100	0	0	0	0	0	0	199	0	0
Toxic Neutrophils	0	2+	1+	2+	1+	3+	2+	1+	3+	0
Haemoparasites		Neg.	–	–	–	–	–	–	–	–

Bold was used for the values that were different from the normal range of the individual analyzed parameters.

Abbreviation: Hgb, hemoglobin; HTC, hematocrit; MCH, mean corpuscular hemoglobin; MCHC, mean corpuscular hemoglobin concentration; MVC, mean corpuscular volume; MPV, mean platelet volume; PCT, plateletcrit or platelet hematocrit; PDW, platelet distribution width; PLT, platelet; RBC, red blood cell count; RDW, red blood cell distribution width; WBC, white blood cell count.

2.5 | Biomolecular analysis

DNA was isolated from colonies grown on a selective medium, with the QIAamp DNA extraction kit (Qiagen, Hilden, Germany) following the manufacturer instruction and PCR was performed. Partial sequences of 1.381 bp of the 16S rDNA gene from the 2 isolates (1 from the gallbladder specimen and 1 from the rectal swab) were obtained by amplification with primers 27F and 1492R (Gürtler & Stanisich, 1996). The primers were: 27F 5'-AGAGTTTGATCCTGGCTCAG-3' (tm 57.3°C) and 1492R 5'-GGTACCTTGTTACGACTT-3' (tm 52.4°C). Cycling con-

ditions were as follows: 94°C, 2 min; 35 cycles of (94°C, 15 s; 55°C, 15 s; 68°C, 30 s). Reaction conditions (50 μ l) were as follows: 20 ng template DNA; 20 μ l Invitrogen Platinum II Hot-Start PCR Master Mix (2 \times), that contains Platinum II *Taq* Hot-Start Polymerase premixed in an optimized Platinum II PCR buffer with dNTPs, 80 pmol of each primer. PCR amplified products (1.381 bp) were purified by using enzymes QIAquick PCR Purification Kit (Qiagen, Hilden, Germany), and sequence analysis was performed using the Geneious 9.1 Software and compared with reference sequences available on the BLAST (Basic Local Alignment Search Tool) database (<https://blast.ncbi.nlm.nih.gov/Blast.cgi>).

Both isolates were confirmed to belong to *Enterococcus* spp. The isolate from the gallbladder was identified as *E. faecium*, while the isolate from the rectal swab belonged to *Enterococcus faecalis* species.

2.6 | Antimicrobial susceptibility test

Antimicrobial susceptibility testing (AST) was performed on both isolates by disk diffusion method (Bauer et al., 1966) on Muller Hinton agar (Liofilchem, Teramo, Italy). The following antibiotics were tested (antibiotic abbreviation and concentration in brackets): amoxicillin-clavulanic acid (AMC, 30 µg), ampicillin (AMP, 10 µg), azithromycin (AZM, 15 µg), ceftiofur (CVN, 30 µg), cefoxitin (FOX, 30 µg), cephalothin (KF, 30 µg), cephalexin (CL, 30 µg), chloramphenicol (C, 30 µg), ciprofloxacin (CIP, 5 µg), clarithromycin (CLR, 15 µg), clindamycin (CD, 2 µg), doxycycline (DXT, 30 µg), enrofloxacin (ENR, 5 µg), erythromycin (E, 15 µg), gentamicin (CN, 30 µg), kanamycin (K, 30 µg), levofloxacin (LEV, 5 µg), metronidazole (MTZ, 5 µg), moxifloxacin (MXF, 5 µg), nitrofurantoin (F, 300 µg), norfloxacin (NOR, 10 µg), ofloxacin (OFX, 5 µg), oxytetracycline (OT, 30 µg), penicillin (P, 10 IU), pradofloxacin (PRA, 5 µg), spiramycin (SP, 100 µg), streptomycin (S, 10 µg), tobramycin (TOB, 10 µg), tylosin (TY, 30 µg) and vancomycin (VA, 30 µg) (Liofilchem, Teramo, Italy).

The results were interpreted according to the Clinical and Laboratory Standards Institute criteria (CLSI, 2018). The two strains (*E. faecium* and *E. faecalis*) exhibited the same resistotype, that is, resistance to: AMC, AMP, AZM, CVN, FOX, KF, CL, CIP, CLR, CD, DXT, ENR, E, CN, K, LEV, MTZ, MXF, NOR, OFX, OT, P, PRA, SPS, TOB, TY and susceptibility to: C, F and VA.

3 | TREATMENT AND FOLLOW UP

On the basis of the results of AST, nitrofurantoin (5 mg/kg body weight -BW-, PO every 8 h) was prescribed, starting from day 25.

The exeresis of the altered gallbladder with fluid therapy, an anti-inflammatory (meloxicam, 0,2 mg/kg body weight for the first day and then 0,1 mg/kg BW, PO, SID) and the antibiotic therapy allowed the dog to recover in a short time (64 days).

In the following days, the animal regained completely its appetite, weight, started to stand up and recovering its normal conditions.

Regarding the biochemical and haematological analyses, all parameters turned up to normal value at day 77 as shown in Tables 1 and 2.

4 | DISCUSSION

Some breeds such as Shetland sheepdogs, Cocker Spaniels, Pomeranians and Chihuahuas appear to be predisposed to develop of GBM pathologies, however, a genetic link has not yet been established (Gookin et al., 2015, 2018).

In addition, reported perioperative mortality rates in dogs undergoing cholecystectomy are as high as 40% (Besso et al., 2000). The ambi-

guity about the optimal time for cholecystectomy in dogs with GBM may, in part, contribute to the high perioperative mortality rate, in fact a late timing of surgery can cause damage for the possible gallbladder rupture and the development of peritonitis (Jaffey et al., 2018).

A further study evaluated how a cholecystitis is a common comorbidity (28%) in cases of mucocele (Rogers et al., 2020). Apparently, the presence of bacteria as a cause of cholecystitis in dogs with GBM subjected to cholecystectomy does not affect survival rate. However, in that study the association between cholecystitis and an infectious agent could not be ruled out because most dogs received empirical antimicrobials treatment before cholecystectomy, impacting on the results of bacteriological culture.

The increase in triglycerides is a sign of hepatic distress or cholestasis, and the low ironemia is typical in the inflammatory process. A high GGT value is common in cases of liver or biliary damage (as intra or extrahepatic cholestasis), attributable to a case of jaundice.

In the study, the biochemical data returned to a normal value after the surgical treatment, while the haematological parameters showed a different trend.

In particular, a severe leukocytosis was shown, starting from day 15. The inflammatory profile could be related to post-operative reactivity. This could explain the lowering of the leukogram values around day 24, linked to the reduction of the acute inflammatory component after surgery. The existence of an infection in the biliary system was confirmed by the haematological findings of day 27 (that is, increase in the leukogram profile). We can assume that surgery alone perhaps would have solved the physical and mechanical problem but would not have solved the infection.

In dogs, a gallbladder thickening is often associated with cholangiohepatitis, acute or chronic hepatitis or cholecystitis, which can cause narrowing of the lumen and subsequent obstacle to the bile flow (Center, 2009) and it can be identified in case of sepsis or neoplasia.

The presence of compact greenish-yellow material in the lumen of the gallbladder with the thickening of the gallbladder were also clear signs of infectious cholecystitis, which was confirmed by the bacterial culture.

Sung and co-authors suggest two main routes of infection in bacterial cholangitis/cholecystitis in dogs: bacteria can reach the biliary tract by ascending infection from the duodenum or via the hepatic portal vein (Sung et al., 1992).

Two different species of *Enterococcus* were identified, one from the gallbladder and one from the intestine. Due to the sequencing results, this could probably mean that no ascending route has been occurred, but this cannot be completely excluded because, unfortunately, the faecal swabs were collected at a later time.

However, it is interesting to note that both isolates were multidrug resistant and had the same resistotype.

This case report was mainly based on the phenotypic evaluation of antimicrobial resistance (AMR). Enterococci are commensal bacteria, present in gut of mammals and birds (Byappanahalli et al., 2012) and the phenomenon of exchange of mobile genetic elements among bacteria belonging to this genus is very common (Trościarczyk et al., 2021). The selective pressure related to the increase in the use of

antibiotics in human and veterinary medicine brings out new resistances and it has been observed for several classes of antibiotics such as fluoroquinolones, macrolides and tetracyclines. For instance, a simultaneous transfer of resistance genes such as erythromycin and tetracycline resistance localized on the same transposon has been demonstrated in *E. faecalis* strains (Hidano et al., 2015; Nowakiewicz et al., 2017). In this case the therapy with nitrofurantoin appeared to be successful. Nitrofurantoin has been successfully used the treatment of vancomycin resistant enterococci infections in humans. In fact, co-resistance of nitrofurantoin with other antibiotics, transferable with mobile elements, has not been reported (Meena et al., 2017).

Several studies confirmed the presence of the same genotypes of *Enterococcus* spp. isolated from various animals and also in humans, suggesting interspecies transmission of strains (Larsen et al., 2010), and indicating that pets could easily act as a potential reservoir of bacteria causing problems regarding public health. Biomolecular studies are needed to better understand the mechanisms of resistance of the isolates from the dog and analyze the genetic profile.

The results presented in this case report should be viewed and interpreted with caution, but still considering that there is no evidence of how episodes of bacterial cholecystitis can affect the survival rate after a cholecystectomy for mucocele (Rogers et al., 2020). Early diagnosis of the bacterial biliary infection and the study of the antibiotic profile are necessary to practice an effective therapy which could allow to increase the chances of survival.

All samples were taken following a procedure by the Ethics Committee for Animal Experimentation of the DVM number 17.17.

CONFLICT OF INTEREST

The authors declare no potential conflict of interest.

DATA AVAILABILITY STATEMENT

The data that support the findings of this study are available from the corresponding author upon reasonable request.

PEER REVIEW

The peer review history for this article is available at <https://publons.com/publon/10.1002/vms3.826>.

ORCID

Alessio Sposato  <https://orcid.org/0000-0002-2063-8744>

Marco Cordisco  <https://orcid.org/0000-0002-8131-5594>

Silvia Ferro  <https://orcid.org/0000-0002-3643-7568>

REFERENCES

- Bauer, A. W., Kirby, W. M. M., Sherris, J. C., & Turck, M. (1966). Antibiotic susceptibility testing by a standardized single disk method. *American Journal of Clinical Pathology*, 45(4_ts), 493–496. https://doi.org/10.1093/ajcp/45.4_ts.493
- Besso, J., Wrigley, R., Gliatto, J., & Webster, C. (2000). Ultrasonographic appearance and clinical findings in 14 dogs with gallbladder mucocele. *Veterinary Radiology Ultrasound*, 41(3), 261–271. <https://doi.org/10.1111/j.1740-8261.2000.tb01489.x>
- Byappanahalli, M. N., Nevers, M. B., Korajkic, A., Staley, Z. R., & Harwood, V. J. (2012). Enterococci in the environment. *Microbiology and Molecular Biology Reviews*, 76(4), <https://doi.org/10.1128/MMBR.00023-12>
- Center, S. A. (2009). Diseases of the Gallbladder and Biliary Tree. *Veterinary Clinics of North America: Small Animal Practice*, 39(3), 543–548. <https://doi.org/10.1016/j.cvsm.2009.01.004>
- CLSI. (2018). *VET01 Performance standards for antimicrobial disk and dilution susceptibility tests for bacteria isolated from animals*. (5th Edition). https://clsi.org/media/2325/vet01ed5_sample.pdf
- Crews, L. J., Feeney, D. A., Jessen, C. R., Rose, N. D., & Matisse, I. (2009). Clinical, ultrasonographic, and laboratory findings associated with gallbladder disease and rupture in dogs: 45 cases (1997–2007). *Journal of the American Veterinary Medical Association*, 234(3), 359–366. <https://doi.org/10.2460/javma.234.3.359>
- Gookin, J. L., Correa, M. T., Peters, A., Malueg, A., Mathews, K. G., Cullen, J., & Seiler, G. (2015). Association of gallbladder mucocele histologic diagnosis with selected drug use in dogs: A matched case-control study. *Journal of Veterinary Internal Medicine*, 29(6), 1464–1472. <https://doi.org/10.1111/jvim.13649>
- Gookin, J. L., Mathews, K. G., Cullen, J., & Seiler, G. (2018). Qualitative metabolomics profiling of serum and bile from dogs with gallbladder mucocele formation. *PLOS One*, 13(1), <https://doi.org/10.1371/journal.pone.0191076>
- Gürtler, V., & Stanisich, V. A. (1996). New approaches to typing and identification of bacteria using the 16S-23S rDNA spacer region. *Microbiology*, 142(1), <https://doi.org/10.1099/13500872-142-1-3>
- Hidano, A., Yamamoto, T., Hayama, Y., Muroga, N., Kobayashi, S., Nishida, T., & Tsutsui, T. (2015). Unraveling antimicrobial resistance genes and phenotype patterns among *Enterococcus faecalis* isolated from retail chicken products in Japan. *PLOS One*, 10(3), <https://doi.org/10.1371/journal.pone.0121189>
- Jaffey, J. A., Graham, A., VanEerde, E., Hostnik, E., Alvarez, W., Arango, J., Jacobs, C., & DeClue, A. E. (2018). Gallbladder mucocele: Variables associated with outcome and the utility of ultrasonography to identify gallbladder rupture in 219 Dogs (2007-2016). *Journal of Veterinary Internal Medicine*, 32(1), 195–200. <https://doi.org/10.1111/jvim.14898>
- Kovatch, R. M., Hildebrandt, P. K., & Marcus, L. C. (1965). Cystic mucinous hypertrophy of the mucosa of the gall bladder in the dog. *Pathologia Veterinaria*, 2(6), 574–584. <https://doi.org/10.1177/030098586500200605>
- Larsen, J., Schønheyder, H. C., Lester, C. H., Olsen, S. S., Porsbo, L. J., Garcia-Migura, L., Jensen, L. B., Bisgaard, M., & Hammerum, A. M. (2010). Porcine-origin gentamicin-resistant *Enterococcus faecalis* in Humans, Denmark. *Emerging Infectious Diseases*, 16(4), 682–684. <https://doi.org/10.3201/eid1604.090500>
- Meena, S., Mohapatra, S., Sood, S., Dhawan, B., Das, B. K., & Kapil, A. (2017). Revisiting nitrofurantoin for vancomycin resistant enterococci. *Journal of Clinical and Diagnostic Research*, 11(6), DC19–DC22. <https://doi.org/10.7860/JCDR/2017/25140.10140>
- Mori, A., Lee, P., Izawa, T., Oda, H., Mizutani, H., Koyama, H., Arai, T., & Sako, T. (2009). Assessing the immune state of dogs suffering from pituitary gland dependent hyperadrenocorticism by determining changes in peripheral lymphocyte subsets. *Veterinary Research Communications*, 33, 757–769. <https://doi.org/10.1007/s11259-009-9224-5>
- Neel, J. A., Tarigo, J., & Grindem, C. B. (2006). Gallbladder aspirate from a dog. *Veterinary Clinical Pathology*, 35(4), 464–470. <https://doi.org/10.1111/j.1939-165X.2006.tb00167.x>
- Nowakiewicz, A., Ziółkowska, G., Trościarczyk, A., Zięba, P., & Gnat, S. (2017). Determination of resistance and virulence genes in *Enterococcus faecalis* and *E. faecium* strains isolated from poultry and their genotypic characterization by ADSSRS-fingerprinting. *Poultry Science*, 96(4), 986–996. <https://doi.org/10.3382/ps/pew365>
- O'Neill, E. J., Day, M. J., Hall, E. J., Holden, D. J., Murphy, K. F., Barr, F. J., & Pearson, G. R. (2006). Bacterial cholangitis/cholangiohepatitis with or without concurrent cholecystitis in four dogs. *Journal of Small*

- Animal Practice*, 47(6), 325–335. <https://doi.org/10.1111/j.1748-5827.2006.00012.x>
- Rogers, E., Jaffey, J. A., Graham, A., Hostnik, E. T., Jacobs, C., Fox-Alvarez, W., Van Eerde, E., Arango, J., Williams, F., & DeClue, A. E. (2020). Prevalence and impact of cholecystitis on outcome in dogs with gallbladder mucocele. *Journal of Veterinary Emergency and Critical Care*, 30(1), 97–101. <https://doi.org/10.1111/vec.12910>
- Sung, J. Y., Costerton, J. W., & Shaffer, E. A. (1992). Defense system in the biliary tract against bacterial infection. *Digestive Diseases and Sciences*, 37(5), 689–696. <https://doi.org/10.1007/BF01296423>
- Tamborini, A., Jahns, H., McAllister, H., Kent, A., Harris, B., Procoli, F., Allenspach, K., Hall, E. J., Day, M. J., Watson, P. J., & O'Neill, E. J. (2016). Bacterial cholangitis, cholecystitis, or both in dogs. *Journal of Veterinary Internal Medicine*, 30(4), 1046–1055. <https://doi.org/10.1111/jvim.13974>
- Trościańczyk, A., Nowakiewicz, A., Gnat, S., Łagowski, D., & Osińska, M. (2021). Are dogs and cats a reservoir of resistant and virulent *Enterococcus faecalis* strains and a potential threat to public health? *Journal of Applied Microbiology*, 131(4), 2061–2071. <https://doi.org/10.1111/jam.15074>
- van den Ingh, T. S. G. A. M., Cullen, J. M., & Twedt, D. C. (2006). Morphological classification of biliary disorders of the canine and feline liver. In J. Rothuizen, S. E. Bunch, & J. A. Charles (Eds.), *WSAVA standards for clinical and histological diagnosis of canine and feline liver disease*. (pp. 94–98). Saunders Elsevier.

How to cite this article: Sposato, A., Cordisco, M., de Ruvo, G., Ferro, S., Raineri, R. A., Trotta, A., Buonavoglia, D., & Corrente, M. (2022). Multidrug resistant *Enterococcus faecium* isolate from cholangitis/cholecystitis in a dog. *Veterinary Medicine and Science*, 8, 1366–1372. <https://doi.org/10.1002/vms3.826>