



Review article

Behavioral and dysexecutive variant of Alzheimer's disease: Insights from structural and molecular imaging studies

Fardin Nabizadeh ^{a,b}, Kasra Pirahesh ^c, Mohammad Hadi Aarabi ^d,
Alexandra Wennberg ^{e,**,1}, Lorenzo Pini ^{d,1,*}

^a School of Medicine, Iran University of Medical Sciences, Tehran, Iran

^b Neuroscience Research Group (NRG), Universal Scientific Education and Research Network (USERN), Tehran, Iran

^c School of Medicine, Tehran University of Medical Science, Tehran, Iran

^d Padova Neuroscience Center, University of Padova, Italy

^e Department of Clinical Neuroscience, Karolinska Institutet, Stockholm, Sweden



ARTICLE INFO

Keywords:

Frontal variant Alzheimer's disease
Behavioral and dysexecutive AD phenotypes
Structural imaging
Molecular imaging

ABSTRACT

Frontal variant Alzheimer's disease (AD) manifests with either behavioral or dysexecutive syndromes. Recent efforts to gain a deeper understanding of this phenotype have led to a reconceptualization of frontal AD. Behavioral (bAD) and dysexecutive (dAD) phenotypes could be considered subtypes, as suggested by both clinical and neuroimaging studies. In this review, we focused on imaging studies to highlight specific brain patterns in these two uncommon clinical AD phenotypes. Although studies did not compare directly these two variants, a common epicenter located in the frontal cortex could be inferred. On the contrary, ¹⁸F-FDG-PET findings suggested differing metabolic patterns, with bAD showing specific involvement of frontal regions and dAD exhibiting widespread alterations. Structural MRI findings confirmed this pattern, suggesting that degeneration might involve neural circuits associated with behavioral control in bAD and attentional networks in dAD. Furthermore, molecular imaging has identified different neocortical tau distribution in bAD and dAD patients compared to typical AD patients, although the distribution is remarkably heterogeneous. In contrast, A β deposition patterns are less differentiated between these atypical variants and typical AD. Although preliminary, these findings underscore the complexity of AD frontal phenotypes and suggest that they represent distinct entities. Further research is essential to refine our understanding of the pathophysiological mechanisms in frontal AD.

1. Introduction

Alzheimer's disease (AD) is the most common cause of dementia worldwide, affecting approximately 50 million people, and this number is projected to triple by 2050 [1], making AD a major global health emergency. From a clinical perspective, it is becoming increasingly apparent that AD is more clinically heterogeneous than once thought. Although most cases follow a typical trajectory with

* Corresponding author.

** Corresponding author.

E-mail addresses: alexandra.wennberg@ki.se (A. Wennberg), lorenzo.pini@unipd.it (L. Pini).

¹ Pini L and Wennberg A share co-last authorship

an early decline in memory functions, about 5 % of cases present with atypical features, a proportion that increases to one-third in patients with an early-onset AD (patients with symptom onset before 65 years of age) [2]. At the molecular level, AD pathophysiology is characterized by the progressive accumulation of misfolded amyloid-beta ($A\beta$) and tau proteins, which lead to plaques and neurofibrillary tangles, respectively, and eventual neurodegeneration [3].

In recent years, atypical AD has garnered more attention, and research into these variants has provided insight into the disease. These manifestations include a language phenotype known as logopenic variant primary progressive aphasia (lvPPA), which involves early deficits in language function, and a visual variant called posterior cortical atrophy (PCA), characterized by early visuospatial impairment [4]. Recently, a rarer distinct atypical phenotype of AD, presenting with either dysexecutive or behavioral syndromes, has been described. This phenotype is characterized by accumulation of neurofibrillary tangles, mainly in the frontal cortex, hence commonly referred to as frontal variant-AD [5]. Frontal variant-AD has considerable overlap with the behavioral variant of fronto-temporal dementia (bvFTD), which is the second most common cause of early-onset dementia [6], suggesting a differential diagnostic challenge [4,6,7]. Notably, the potential diagnostic overlap between bvFTD and frontal variant-AD may represent a significant confounding factor for disease management and monitoring.

Recent efforts have aimed to provide a better understanding of frontal variant-AD, referred to as b/dAD (from the (b)ehavioral and (d)yxecutive manifestations). These findings allow for better characterization of this sub-cohort of patients. It has become clear that some individuals initially diagnosed with b/dAD showed no remarkable behavioral changes, suggestive of a more complex puzzle, in which (b) and (d) can represent separate entities [8,9]. These new findings have led to a reconceptualization of frontal variant-AD, where the behavioral (bAD) and dysexecutive (dAD) AD (bAD) phenotypes are considered distinct clinical sub-phenotypes. The former is characterized by early onset predominant changes in behavior, social cognition, and personality, such as apathy, disinhibition, and social withdrawal. Patients with bAD may also exhibit symptoms such as agitation, aggression, and impulsivity [8]. Meanwhile, dAD is characterized by executive dysfunction, such as problems with planning, organization, and decision-making. Patients with dAD may also experience memory impairment and language difficulties, but these symptoms are typically less severe compared to other atypical AD phenotypes (e.g., lvPPA or PCA). Based on these findings, Ossenkoppele and colleagues proposed new research criteria for bAD, which are based on behavioral alterations and supported by neocortical tau aggregates [10]. Though no such guidelines yet exist for dAD.

Neuroimaging studies focusing on the structural and molecular changes in bAD and dAD may help to increase diagnostic confidence and unravel the pathophysiological mechanisms linked with these clinical phenotypes. Although only a handful of neuroimaging

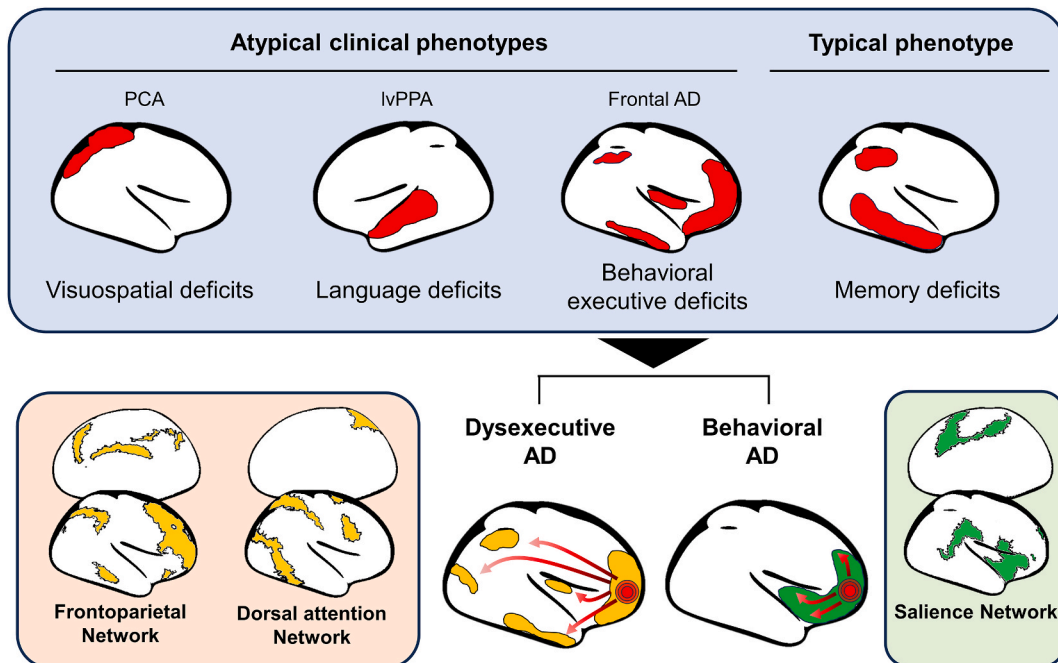


Fig. 1. Specific neurodegenerative epicenters are consistently observed in both typical and atypical Alzheimer's disease (AD) phenotypes. Left top panel: Atypical clinical AD phenotypes show specific pathological features. Posterior cortical atrophy (PCA) exhibits a degenerative pattern involving the parieto-occipital regions, logopenic variant primary progressive aphasia (lvPPA) is characterized by early vulnerability of the left temporal cortex, and frontal AD displays predominant frontal involvement, albeit with heterogeneity (PPA and PCA representations are based on 13). These patterns are different from typical AD phenotype (right top panel). Bottom panel: when investigating frontal AD in terms of behavioral and executive domains, although the epicenter of these clinical manifestations lies in similar frontal regions, dysexecutive AD shows a more widespread pattern. Different vulnerabilities within specific neural networks may underlie the clinical manifestations of frontal AD, such as the salience network for the behavioral variant and attentional networks for the dysexecutive phenotype.

studies have been conducted on this emerging topic, they can provide key information, laying the groundwork for future studies. With the recent establishment of research criteria for bAD [10], the objective of this review is to provide an updated overview of the principal structural, metabolic, and molecular findings in both bAD and dAD. The aim is to underscore both commonalities and differences between these two uncommon AD subtypes.

Table 1
Demographic characteristics and neuroimaging findings of recent studies investigating b/dAD phenotype.

Study	Sample size (F)	Age	Disease duration	MMSE	AD phenotype	AD confirmation	Sample size controls	Imaging modality
Behavioral Alzheimer's Disease (bAD)								
Dominguez Perez et al., 2022	16 [4]	68 [4]	3 (Na)	23 [3]	Criteria for bvFTD	CSF	67 bvFTD, 18 aAD, 26 HC	sMRI
Lehingue et al., 2021	20 [7]	72 [5]	5 [1]	25 [3]	Clinically prominent behavioral dysfunction	CSF	36 bvFTD, 22 AD	^{18}F -FDG-PET; sMRI
Ossenkoppele et al., 2015	55 [15]	65 [9]	Na	23 [5]	Ad hoc criteria for prominent bAD and dAD	CSF, PET, autopsy	58 typical AD, 59 bvFTD, 61 HC	sMRI
Perry et al., 2017	15 [5]	63 [14]	5.5 [3]	Na	Previous diagnosis of bvFTD	Autopsy	98 bvFTD	sMRI
Phillips et al., 2019	12 [5]	64 [5]	2.2 [2]	23 [5]	Criteria for bvFTD	CSF, autopsy	17 typical AD, 37 HC	sMRI
Singleton et al., 2020	29 [12]	64 [9]	Na	22 [6]	From Ossenkoppele et al., 2015	CSF, PET, autopsy	28 typical AD, 28 bvFTD, 34 HC	^{18}F -FDG-PET; sMRI
Singleton et al., 2021	7 [1]	69	Na	22 [3]	From Ossenkoppele et al., 2015	CSF, PET, autopsy	205 typical AD	Tau-PET
Dysexecutive Alzheimer's Disease (dAD)								
Corriveau-Lecavalier et al., 2022	17 [11]	54 [6]	2 (Na)	Na	From Townley et al., 2020	CSF or PET	None	^{18}F -FDG-PET
Ossenkoppele et al., 2015	29 [11]	69 [9]	Na	25 [3]	Ad hoc criteria for prominent bAD and dAD	CSF, PET, autopsy	58 typical AD, 59 bvFTD, 61 HC	sMRI
Corriveau-Lecavalier et al., 2023	52 [34]	56 [5]	8.6	Na	From Townley et al., 2020	CSF or PET	None	sMRI; ^{18}F -FDG-PET; Amyloid-PET; Tau-PET
Townley et al., 2020	55 [34]	57	3,3	Na	Ad hoc criteria for dAD	CSF, PET, autopsy	None (case series)	sMRI; ^{18}F -FDG-PET; Amyloid-PET; Tau-PET
Woodward et al., 2014	13 [5]	82	Na	24	Based on Frontal Assessment Battery	NR	40 typical AD	^{18}F -FDG-PET
Wong et al., 2016	23 [10]	64 [8]	3.4 (2.1)	Na	Executive impairment at cognitive examination	PET	12 Sparing executive function AD, 22 bvFTD, 38 HC	sMRI
Pooled sample of behavioral/dysexecutive Alzheimer's disease (b/dAD)								
Bergeron et al., 2020	8 [2]	60 [8]	Na	22 [6]	b/dAD	CSF or PET	8 bvFTD, 10 typical AD	^{18}F -FDG-PET
Bergeron et al., 2020	8 (Na)	62	Na	21	b/dAD	CSF or PET	12 FTD, 40 atypical AD	^{18}F -FDG-PET
Phillips et al., 2018	22 [11]	64 [8]	4 [2]	20 [8]	b/dAD	CSF, autopsy	22 typical AD, 115 HC	sMRI
Therriault et al., 2020	15 [9]	66 [9]	Na	20 [5]	b/dAD	PET	25 typical AD, 131 HC	Amyloid-PET; Tau-PET; sMRI
Sala et al., 2020	15 [5]	63 [6]	3 [2]	17 [5]	Frontal AD variant	CSF	22 typical AD, 16 Posterior variant AD, 14 PPA	^{18}F -FDG-PET
Wang et al., 2019	13 [9]	68 [3]	3.4 [1]	17 [6]	Frontal AD variant	PET	38 typical AD, 6 PCA, 8 lvPPA, 20 HC	Amyloid-PET; ^{18}F -FDG-PET

Age is reported as mean and standard deviation (in brackets). Abbreviations: AD, Alzheimer's disease; bAD, behavioral variant AD; b/d, behavioral/dysexecutive variant AD; bvFTD: behavioral variant frontotemporal dementia; dAD, dysexecutive variant AD; NR, Not Reported; CSF, cerebrospinal fluid; F: female; PET, Positron Emission Tomography; bvFTD, behavioral variant frontotemporal dementia; MRI, Magnetic resonance imaging. + marks a study in which a subset of patients (n = 15) was used for the imaging comparison.

2. Brain metabolism

Brain metabolism is typically assessed with ^{18}F -fluorodeoxyglucose positron emission tomography (^{18}F -FDG-PET), a common molecular imaging technique assessing glucose distribution across brain regions. ^{18}F -FDG-PET has been extensively employed in monitoring neurodegenerative diseases and proves useful in the early and differential diagnosis of major neurodegenerative disorders [11]. The typical ^{18}F -FDG-PET pattern in AD is characterized by reduced metabolism in the angular gyrus, posterior cingulate, and inferior temporal cortical regions (Fig. 1 and Table 1). This AD-signature can be quantified as the voxel-wise weighted average of the median glucose uptake of these regions normalized to the pons and vermis median [12]. In atypical AD, this pattern shows divergent trajectories, with involvement of visual and language regions in PCA and lvPPA, respectively [13].

Two studies from the same research group assessed glucose uptake among a pooled sample of b/dAD patients [14,15], reporting that they were able to discriminate between this cohort and typical AD patients based on metabolism within the orbitofrontal cortex, orbital gyrus, and temporal gyrus. These findings were in line with the study by Sala et al. reporting reduced frontal uptake (bilateral middle, superior frontal gyrus, and dorsolateral prefrontal cortex) in b/dAD patients compared to typical AD patients [16]. However, an independent study found significant hypometabolism in the dorsolateral prefrontal cortex [17]. Moreover, b/dAD showed overlap with typical AD regions, such as hypometabolism in the middle temporal gyrus, posterior cingulate, and angular gyrus [14,16]. Overall, the murkiness of these findings and the overlap with typical AD might indicate that considering bAD and dAD as separate entities from each other could better capture some specificity of frontal variant-AD.

A preliminary study showed a trend towards more severe frontal mesial reduction uptake in bAD patients compared to typical AD patients. This was similar to the findings showing similar trends comparing bAD and bvFTD patients [18]. However, this difference did not reach statistical significance, likely due to the relatively small sample size ($n = 20$ bAD patients), suggesting high inter-individual differences in the spatial metabolic pattern of bAD. Comparatively, Singleton and colleagues observed extended hypometabolism in the posterior cingulate, precuneus, and lateral temporoparietal regions among bAD patients, overlapping more with typical AD than with bvFTD, contrary to the main hypothesis of their study [19]. Nonetheless, the authors reported a subtle decline within the frontoinsular regions. These findings suggest two possibilities: first, there might be a divergence in the disease epicenter between typical AD and bvAD variants; second, neurodegeneration progresses more rapidly in frontoinsular regions in bvAD compared to tAD. In typical AD, the frontal regions typically remain unaffected until the disease reaches more advanced stages, a phenomenon distinct from what is observed in bvAD [19].

To our knowledge, metabolism alterations among patients with dAD were investigated in only four studies [9,20–22]. Corriveau-Lecavalier et al. showed higher hypometabolism in parietal and temporal areas, followed by frontal areas, and the posterior cingulate gyrus, anterior cingulate gyrus, occipital regions and subcortical areas (right caudate) among dAD patients [20]. A different study from the same research group clustered dAD patients into four subtypes based on the location of hypometabolism: left-dominant, right-dominant, bi-parietal-dominant, and heteromodal-diffuse [21]. Furthermore, Townley et al. reported widespread reduced glucose uptake in frontal, lateral parietal, dorsolateral prefrontal, precuneus, and posterior cingulate regions in the dAD group compared to typical AD patients [9]. These findings suggest, so far, a more widespread (and less consistent) hypometabolism pattern in dAD compared to bAD. However, Woodward and colleagues reported higher hypometabolism only in bilateral orbitofrontal regions and medial frontal regions in bAD compared to typical AD [22].

Overall, these studies confirm that the frontal cortex is a convergent zone exhibiting reduced metabolism in both dAD and bAD. Although results are not conclusive, evidence suggests that while in bAD hypometabolism is more focused in frontal regions, dAD showed widespread metabolism alterations beyond the frontal regions, involving parietal, temporal and occipital regions. This pattern is in line with their clinical phenotypes. Executive functions are linked with a more distributed set of multimodal cortical regions [23], consistent with the widespread hypometabolism in AD patients showing a dysexecutive manifestation. Further studies are necessary to confirm these metabolic patterns.

3. Structural MRI findings

Cortical atrophy is one of the most studied pathophysiological markers of AD [24]. Medial temporal lobe atrophy represents a common imaging substrate in typical AD, linked with early memory deficits [25]. However, different cortical atrophy patterns exist in AD subtypes. In a pivotal study, Frisoni and colleagues reported different cortical involvement in patients with late-onset AD (usually referred to as typical AD) and early-onset AD, with the former exhibiting atrophy mainly in the temporal lobe and the latter showing widespread neocortical atrophy [26]. A high proportion of early-onset AD patients presents with atypical clinical phenotypes, such as lvPPA, PCA and b/dAD. LvPPA and PCA show cortical atrophy in modality-specific brain regions (language and visuo-spatial regions, respectively) supporting the assumption that, despite a similar distribution of misfolded proteins (mainly $\text{A}\beta$), different neurodegenerative trajectories are observed [13]. As recently highlighted, b/dAD patients showed specific neurodegenerative patterns [27, 28]. This cohort of patients showed a fronto-temporal and insular atrophy pattern in the early stage of the disease, spreading to the parietal cortex in more advanced stages [27], suggesting a staging pattern different from typical AD. Further, Therriault et al., reported a similar atrophy pattern in an independent cohort of b/dAD patients, but observed no differences when this cohort was compared to typical AD [28]. Similar to ^{18}F -FDG-PET research, studies highlighting neurodegenerative pattern differences between bAD and dAD could resolve both commonalities and divergences in frontal variant-AD.

In bAD, several studies consistently reported brain atrophy in regions involved in behavioral controls, such as insula, orbitofrontal cortex, frontal gyrus, and anterior cingulate cortex [8,18,29,30]. Ossenkopppele et al. found that, besides a predominant temporo-parietal atrophy pattern, bAD patients showed additional involvement of the left orbitofrontal cortex, frontal poles, and

middle/superior frontal gyri compared to healthy individuals [8]. Further, fronto-insula and anterior cingulate atrophy was observed in these patients [29,30]. These regions are part of the salience network, a brain circuit involved in social cognition. Several psychiatric disorders such as autistic disorder and schizophrenia share alterations within this circuit, linked with the neuropsychiatric symptoms [31–33]. A similar involvement could represent the neural correlates of behavioral dysfunctions in bAD patients. This assumption should be investigated by functional connectivity imaging studies. bAD patients also exhibit neurodegeneration in the hippocampus, putamen, caudate nucleus, and thalamus compared to healthy individuals [19]. However, as aforementioned, bAD showed less atrophy in the left inferior frontal cortex compared to bvFTD patients [6]. This region is a key hub for language abilities, which are spared in the early stages of bAD, compared to PCA and lvPPA [6,34]. Conversely, Dominguez Perez et al. reported reduced cortical thickness in the left inferior frontal cortex in bAD, compared to bvFTD [35]. Also, these two studies found higher cortical thickness in the temporo-occipital area when contrasting bAD patients with typical AD and bvFTD [8,35]. However, other studies have not come to the same conclusions. Lehingue et al. did not report significant differences between bAD and bvFTD groups, so the cortical pattern in this AD phenotype remains an open question [18].

Regarding dAD, only three recent studies assessed gray matter volume [9,36]. Extensive prefrontal and medial temporal lobe atrophy in dAD patients has been reported, while AD patients with spared executive function showed significant atrophy in the middle frontal gyrus and the hippocampus [36]. However, these results were only partially replicated in a recent study which showed only minimal frontal atrophy in dAD [9]. Moreover, Ossenkoppele et al. reported non-significant cortical atrophy in the frontal cortex in dAD when compared to healthy individuals, with only a small cluster in the left middle temporal cortex surviving multiple comparison correction [8].

4. Amyloid and tau-PET

A β and tau accumulation is the key hallmark of typical AD pathology, with topographical patterns differing across atypical AD variants, including b/dAD, particularly for tau [37]. In typical AD, the deposition of A β plaques is observed in a diffuse pattern across the neocortex, with initial involvement of the posteromedial cortices and relatively limited effect on the medial temporal, primary sensorimotor, and visual cortices. In contrast to other imaging modalities, the distribution of A β remains similar between typical AD and atypical variants such as PCA and lvPPA [38]. As opposed to A β -PET, tau deposition is distinct when comparing typical and atypical AD variants [4]. Therriault et al. reported increased tau uptake in the anterior cingulate, medial prefrontal, and frontal insula cortices in b/dAD patients compared to typical AD patients, while regional A β deposition did not differ between the groups [28]. This result might point to a close relationship between frontal tau pathology and clinical presentation of b/dAD phenotype, as suggested by literature highlighting the role of the aforementioned frontal structure in emotional processing, decision making, and behavioral control [39,40]. Notably, these regions are not typically involved in the early stage of typical AD, in which tau is known to accumulate early in the entorhinal cortex and the medial temporal lobe [41,42].

Examining bAD and dAD patients separately, Singleton et al. reported prominent frontal and temporoparietal tau accumulation in bAD [43]. Similarly, dAD patients showed tau uptake in middle frontal and superior parietal lobes while A β followed typical AD-like accumulation patterns [9]. Taken together, these results suggest that typical AD, bAD, and dAD patients cannot be distinguished based on A β accumulation patterns, while tau pathology distribution patterns may be more specific across subtypes, and, although heterogeneous, are characterized by a main frontal involvement. In their study stratifying dAD patients into four different subtypes based on 18F-FDG-PET (left-dominant, right-dominant, bi-parietal-dominant, and heteromodal-diffuse), Corriveau-Lecavalier and colleagues found hypometabolic pattern echoed tau uptake and MRI-detected neurodegeneration for each specific subtype [21]. Again, the patterns of A β deposition were consistent across all subtypes, suggesting a specificity of tau in distinguish between AD phenotypes. However, further studies are needed to evaluate whether the tau distribution corresponds to the observed atrophy and metabolism patterns reported in both dAD and bAD patients.

5. Common epicenters, different trajectories

The preliminary findings in patients with bAD and dAD suggest a spectrum of structural changes compared to typical AD and bvFTD. These features range from those typically associated with AD to those resembling bvFTD. In general, bAD patients display neuroimaging patterns indicating frontal involvement, extending to brain regions associated with circuits governing social and behavioral control. In contrast, dAD is characterized by more extensive cortical involvement, suggesting widespread alterations that may contribute to dysexecutive impairments. Notably, both dAD and bAD exhibited a distinct pathological trajectory, differing from other atypical phenotypes such as PCA and lvPPA (Fig. 1). Although both dAD and bAD may share a common epicenter represented by the frontal cortex, distinct trajectories can underscore differences in cognitive and clinical phenotypes. The salience network, comprised of the anterior insula, anterior cingulate cortex, and prefrontal cortex, is implicated in various disorders linked to social cognition impairment, such as psychiatric disorders and frontotemporal dementia [44]. These findings might suggest an early involvement of this network in bAD, in contrast to the memory networks more typically affected in AD, such as the default mode network or the limbic network [45]. Attention networks, such as the frontoparietal and dorsal attention networks, are more closely associated with attentional and executive functions. The configuration of these networks may align more closely with the pathological observations in dAD (see Fig. 1). Additionally, genetic, and environmental factors play a role in shaping regional cortical alterations, contributing to distinct disease presentations. However, future functional MRI studies comparing networks in these sub-phenotypes are needed to draw more conclusions.

6. Conclusion

The current literature suggests a spectrum of neuroimaging features in patients with bAD and dAD, compared to typical AD and bvFTD, ranging from those typically associated with AD to those resembling bvFTD. In general, patterns of frontal involvement, extending to brain regions associated with circuits governing social and behavioral control were prominent in bAD patients compared to typical AD. In contrast, dAD has been characterized by more widespread neocortical involvement, suggesting more extensive brain circuit alterations that may contribute to executive impairments. Notably, a few studies included in this review were not independent, as they included the same pool of patients, underscoring the need for additional research in this field to provide more concrete conclusions. It will be important for future research to adopt a dysexecutive/behavioral dichotomy when investigating frontal AD, particularly due to the heterogeneity in the clinical classification of previous studies, where the categorization into dAD and bAD was notably heterogeneous. A larger amount of literature will also allow to perform quantitative assessments on the topic, helping to disentangle the imaging phenotypes of these AD clinical syndromes. Studies would also benefit from comparing bAD and dAD, as many of the findings were primarily derived from comparisons with healthy controls of bvFTD. Similarly, including connectivity (both functional and diffusion techniques) metrics could provide insights into the latent relationship between atrophy, metabolism, and misfolded protein accumulation in these uncommon phenotypes. Overall, incorporating a dichotomous approach in this work will be essential for unraveling the diverse pathological mechanisms underlying AD.

Declaration

Review and/or approval by an ethics committee were not needed for this study because it is a review. Informed consent was not required for this study because it is a review.

Data availability statement

No data was used for the research described in the article.

CRedit authorship contribution statement

Fardin Nabizadeh: Writing – original draft, Methodology. **Kasra Pirahesh:** Methodology, Data curation. **Mohammad Hadi Aarabi:** Data curation. **Alexandra Wennberg:** Writing – review & editing, Supervision. **Lorenzo Pini:** Writing – review & editing, Writing – original draft, Visualization, Supervision, Methodology, Conceptualization.

Declaration of competing interest

The authors declare that they have no known competing financial interests or personal relationships that could have appeared to influence the work reported in this paper.

References

- [1] P. Scheltens, B. De Strooper, M. Kivipelto, H. Holstege, G. Chételat, C.E. Teunissen, et al., Alzheimer's disease, *Lancet* 397 (10284) (2021) 1577–1590.
- [2] E.L. Koedam, V. Lauffer, A.E. van der Vlies, W.M. van der Flier, P. Scheltens, Y.A. Pijnenburg, Early-versus late-onset Alzheimer's disease: more than age alone, *J Alzheimers Dis* 19 (4) (2010) 1401–1408.
- [3] C.R. Jack Jr., D.A. Bennett, K. Blennow, M.C. Carrillo, B. Dunn, S.B. Haeberlein, et al., NIA-AA Research Framework: toward a biological definition of Alzheimer's disease, *Alzheimers Dement* 14 (4) (2018) 535–562.
- [4] J. Graff-Radford, K.X.X. Yong, L.G. Apostolova, F.H. Bouwman, M. Carrillo, B.C. Dickerson, et al., New insights into atypical Alzheimer's disease in the era of biomarkers, *Lancet Neurol.* 20 (3) (2021) 222–234.
- [5] M. Woodward, H. Brodaty, K. Boundy, D. Ames, G. Blanch, R. Balshaw, Does executive impairment define a frontal variant of Alzheimer's disease? *Int. Psychogeriatr.* 22 (8) (2010) 1280–1290.
- [6] R. Ossenkoppele, E.H. Singleton, C. Groot, A.A. Dijkstra, W.S. Eikelboom, W.W. Seeley, et al., Research criteria for the behavioral variant of alzheimer disease: a systematic review and meta-analysis, *JAMA Neurol.* 79 (1) (2022) 48–60.
- [7] M.S. Forman, J. Farmer, J.K. Johnson, C.M. Clark, S.E. Arnold, H.B. Coslett, et al., Frontotemporal dementia: clinicopathological correlations, *Ann. Neurol.* 59 (6) (2006) 952–962.
- [8] R. Ossenkoppele, Y.A. Pijnenburg, D.C. Perry, B.I. Cohn-Sheehy, N.M. Scheltens, J.W. Vogel, et al., The behavioural/dysexecutive variant of Alzheimer's disease: clinical, neuroimaging and pathological features, *Brain* 138 (Pt 9) (2015) 2732–2749.
- [9] R.A. Townley, J. Graff-Radford, W.G. Mantyh, H. Botha, A.J. Polsinelli, S.A. Przybelski, et al., Progressive dysexecutive syndrome due to Alzheimer's disease: a description of 55 cases and comparison to other phenotypes, *Brain Commun* 2 (1) (2020) fcaa068.
- [10] R. Ossenkoppele, E.H. Singleton, C. Groot, A.A. Dijkstra, W.S. Eikelboom, W.W. Seeley, et al., Research criteria for the behavioral variant of alzheimer disease: a systematic review and meta-analysis, *JAMA Neurol.* 79 (1) (2022) 48–60.
- [11] F. Nobili, J. Arbizu, F. Bouwman, A. Drzezga, F. Agosta, P. Nestor, et al., European Association of Nuclear Medicine and European Academy of Neurology recommendations for the use of brain (18) F-fluorodeoxyglucose positron emission tomography in neurodegenerative cognitive impairment and dementia: delphi consensus, *Eur. J. Neurol.* 25 (10) (2018) 1201–1217.
- [12] S.M. Landau, D. Harvey, C.M. Madison, R.A. Koeppe, E.M. Reiman, N.L. Foster, et al., Associations between cognitive, functional, and FDG-PET measures of decline in AD and MCI, *Neurobiol. Aging* 32 (7) (2011) 1207–1218.
- [13] L. Pini, A.M. Wennberg, A. Salvalaggio, A. Vallesi, M. Pievani, M. Corbetta, Breakdown of specific functional brain networks in clinical variants of Alzheimer's disease, *Ageing Res. Rev.* 72 (2021) 101482.
- [14] D. Bergeron, J.M. Bearegard, G. Jean, J.P. Soucy, L. Verret, S. Poulin, et al., Posterior cingulate cortex hypometabolism in non-amnesic variants of Alzheimer's disease, *J. Alzheim. Dis.* 77 (4) (2020) 1569–1577.

- [15] D. Bergeron, L. Sellami, S. Poulin, L. Verret, R.W. Bouchard, R. Laforce Jr., The behavioral/dysexecutive variant of Alzheimer's disease: a case series with clinical, neuropsychological, and FDG-PET characterization, *Dement. Geriatr. Cogn. Disord* 49 (5) (2020) 518–525.
- [16] A. Sala, C. Caprioglio, R. Santangelo, E.G. Vanoli, S. Iannaccone, G. Magnani, et al., Brain metabolic signatures across the Alzheimer's disease spectrum, *Eur. J. Nucl. Med. Mol. Imag.* 47 (2) (2020) 256–269.
- [17] Y. Wang, Z. Shi, N. Zhang, L. Cai, Y. Li, H. Yang, et al., Spatial patterns of hypometabolism and amyloid deposition in variants of Alzheimer's disease corresponding to brain networks: a prospective cohort study, *Mol. Imag. Biol.* 21 (1) (2019) 140–148.
- [18] E. Lehingue, J. Gueniat, S. Jourdaa, J.B. Hardouin, A. Pallardy, H. Courtemanche, et al., Improving the diagnosis of the frontal variant of Alzheimer's disease with the DAPHNE scale, *J. Alzheim. Dis.* 79 (4) (2021) 1735–1745.
- [19] E.H. Singleton, Y.A.L. Pijnenburg, C.H. Sudre, C. Groot, E. Kochova, F. Barkhof, et al., Investigating the clinico-anatomical dissociation in the behavioral variant of Alzheimer disease, *Alzheimer's Res. Ther.* 12 (1) (2020).
- [20] N. Corriveau-Lecavalier, E.C. Alden, N.H. Stricker, M.M. Machulda, D.T. Jones, Failed performance on the test of memory malingering and misdiagnosis in individuals with early-onset dysexecutive Alzheimer's disease, *Arch. Clin. Neuropsychol.* 37 (6) (2022) 1199–1207.
- [21] N. Corriveau-Lecavalier, L.R. Barnard, J. Lee, E. Dicks, H. Botha, J. Graff-Radford, et al., Deciphering the clinico-radiological heterogeneity of dysexecutive Alzheimer's disease, *Cerebr. Cortex* 33 (11) (2023) 7026–7043.
- [22] M.C. Woodward, C.C. Rowe, G. Jones, V.L. Villemagne, T.A. Varos, Differentiating the frontal presentation of Alzheimer's disease with FDG-PET, *J Alzheimers Dis* 44 (1) (2015) 233–242.
- [23] M. Corbetta, G. Patel, G.L. Shulman, The reorienting system of the human brain: from environment to theory of mind, *Neuron* 58 (3) (2008) 306–324.
- [24] L. Pini, M. Pievani, M. Bocchetta, D. Altomare, P. Bosco, E. Cavedo, et al., Brain atrophy in Alzheimer's Disease and aging, *Ageing Res. Rev.* 30 (2016) 25–48.
- [25] B. Dubois, H.H. Feldman, C. Jacova, H. Hampel, J.L. Molinuevo, K. Blennow, et al., Advancing research diagnostic criteria for Alzheimer's disease: the IWG-2 criteria, *Lancet Neurol.* 13 (6) (2014) 614–629.
- [26] G.B. Frisoni, M. Pievani, C. Testa, F. Sabattoli, L. Bresciani, M. Bonetti, et al., The topography of grey matter involvement in early and late onset Alzheimer's disease, *Brain* 130 (Pt 3) (2007) 720–730.
- [27] J.S. Phillips, F. Da Re, L. Dratch, S.X. Xie, D.J. Irwin, C.T. McMillan, et al., Neocortical origin and progression of gray matter atrophy in nonamnestic Alzheimer's disease, *Neurobiol. Aging* 63 (2018) 75–87.
- [28] J. Theriault, T.A. Pascoal, M. Savard, A.L. Benedet, M. Chamoun, C. Tissot, et al., Topographic distribution of amyloid- β , tau, and atrophy in patients with behavioral/dysexecutive alzheimer disease, *Neurology* 96 (1) (2021) e81–e92.
- [29] D.C. Perry, J.A. Brown, K.L. Possin, S. Datta, A. Trujillo, A. Radke, et al., Clinicopathological correlations in behavioural variant frontotemporal dementia, *Brain* 140 (12) (2017) 3329–3345.
- [30] J.S. Phillips, F. Da Re, D.J. Irwin, C.T. McMillan, S.N. Vaishnavi, S.X. Xie, et al., Longitudinal progression of grey matter atrophy in non-amnestic Alzheimer's disease, *Brain* 142 (6) (2019) 1701–1722.
- [31] E. Marshall, J.S. Nomi, B. Dirks, C. Romero, L. Kupis, C. Chang, et al., Coactivation pattern analysis reveals altered salience network dynamics in children with autism spectrum disorder, *Network Neuroscience* 4 (4) (2020) 1219–1234.
- [32] G. Quattrini, L. Pini, M. Pievani, L.R. Magni, M. Lanfredi, C. Ferrari, et al., Abnormalities in functional connectivity in borderline personality disorder: correlations with metacognition and emotion dysregulation, *Psychiatry Res. Neuroimaging.* 283 (2019) 118–124.
- [33] V. Menon, L. Palaniyappan, K. Supekar, Integrative brain network and salience models of psychopathology and cognitive dysfunction in schizophrenia, *Biol. Psychiatr.* (2022).
- [34] B. Ishkhanyan, V. Michel Lange, K. Boye, J. Mogensen, A. Karabanov, G. Hartwigsen, et al., Anterior and posterior left inferior frontal gyrus contribute to the implementation of grammatical determiners during language production, *Front. Psychol.* 11 (2020).
- [35] S. Dominguez Perez, J.S. Phillips, C. Norise, N.G. Kinney, P. Vaddi, A. Halpin, et al., Neuropsychological and neuroanatomical features of patients with behavioral/dysexecutive variant Alzheimer's disease (AD): a comparison to behavioral variant frontotemporal dementia and amnestic AD groups, *J. Alzheim. Dis.* 89 (2) (2022) 641–658.
- [36] S. Wong, M. Bertoux, G. Savage, J.R. Hodges, O. Piguet, M. Hornberger, Comparison of prefrontal atrophy and Episodic memory performance in dysexecutive Alzheimer's disease and behavioral-variant frontotemporal dementia, *J. Alzheim. Dis.* 51 (3) (2016) 889–903.
- [37] I. Sintini, J. Graff-Radford, D.T. Jones, H. Botha, P.R. Martin, M.M. Machulda, et al., Tau and amyloid relationships with resting-state functional connectivity in atypical alzheimer's disease, *Cerebr. Cortex* 31 (3) (2021) 1693–1706.
- [38] A.J. Polsinelli, L.G. Apostolova, Atypical Alzheimer disease variants, *Continuum* 28 (3) (2022) 676–701.
- [39] A. Etkin, T. Egner, R. Kalisch, Emotional processing in anterior cingulate and medial prefrontal cortex, *Trends Cognit. Sci.* 15 (2) (2011) 85–93.
- [40] L.Q. Uddin, Salience processing and insular cortical function and dysfunction, *Nat. Rev. Neurosci.* 16 (1) (2015) 55–61.
- [41] H. Braak, E. Braak, Neuropathological stageing of Alzheimer-related changes, *Acta Neuropathol.* 82 (4) (1991) 239–259.
- [42] J. Sepulcre, A.P. Schultz, M. Sabuncu, T. Gomez-Isla, J. Chhatwal, A. Becker, et al., In vivo tau, amyloid, and gray matter profiles in the aging brain, *J. Neurosci.* 36 (28) (2016) 7364–7374.
- [43] E. Singleton, O. Hansson, Y.A.L. Pijnenburg, R. La Joie, W.G. Mantyh, P. Tideman, et al., Heterogeneous distribution of tau pathology in the behavioural variant of Alzheimer's disease, *J. Neurol. Neurosurg. Psychiatr.* 92 (8) (2021) 872–880.
- [44] L. Pini, S.C. de Lange, F.B. Pizzini, I. Boscolo Galazzo, R. Manenti, M. Cotelli, et al., A low-dimensional cognitive-network space in Alzheimer's disease and frontotemporal dementia, *Alzheimer's Res. Ther.* 14 (1) (2022) 199.
- [45] L. Pini, C. Geroldi, S. Galluzzi, R. Baruzzi, M. Bertocchi, E. Chitò, et al., Age at onset reveals different functional connectivity abnormalities in prodromal Alzheimer's disease, *Brain Imaging and Behavior* 14 (6) (2020) 2594–2605.