

MINI-FOCUS ISSUE: TRANSCATHETER INTERVENTIONS

ADVANCED

CASE REPORT: TECHNICAL CORNER

# Transcatheter Therapies in Challenging Aortic Ailments



## TAVR in Extreme Horizontal Aortic Root With CoA Stenting

Alfredo Marchese, MD, PhD,<sup>a</sup> Antonio Tito, MD,<sup>a</sup> Fabrizio Resta, MD,<sup>a</sup> Giuseppe Tarantini, MD, PhD<sup>b</sup>

### ABSTRACT

Transcatheter aortic valve replacement (TAVR) for severe aortic stenosis in older adults may be challenging because of additional aortic comorbidities such as aortic coarctation (CoA). We report successful snared-assisted transfemoral TAVR in a patient with an extremely horizontal ventriculoaortic axis that was worsened by a previous endovascular repair of complex CoA. (**Level of Difficulty: Advanced.**) (J Am Coll Cardiol Case Rep 2021;3:905-9) © 2021 The Authors. Published by Elsevier on behalf of the American College of Cardiology Foundation. This is an open access article under the CC BY-NC-ND license (<http://creativecommons.org/licenses/by-nc-nd/4.0/>).

### HISTORY OF PRESENTATION

A 76-year-old woman was admitted for progressive dyspnea (New York Heart Association functional class II to III) and chest pain. Her blood pressure on admission was 220/115 mm Hg, and physical examination showed a harsh systolic ejection murmur. Severe renal failure (azotemia, evidenced by blood urea nitrogen, 222 mg/dl; creatinine, 3.90 mg/dl; estimated glomerular filtration rate, 21 ml/min) was detected.

### PAST MEDICAL HISTORY

She reported a significant 10-year history of severe refractory hypertension, chronic obstructive pulmonary disease, and severe isthmus coarctation of the aorta (CoA).

### DIFFERENTIAL DIAGNOSIS

Refractory hypertension, severe aortic valve disease, and aortic dissection were considered as different causes of her clinical presentation.

### LEARNING OBJECTIVES

- To select the best vascular access approach for patients undergoing TAVR when a patient has multiple aortic comorbidities.
- To overcome technical challenges arising during TAVR in patients with a unique aortic root combined with multiple anatomic shortcomings.

### INVESTIGATIONS

An in-hospital echocardiogram showed severe aortic stenosis (aortic valve area, 0.8 cm<sup>2</sup>; mean pressure gradient, 57 mm Hg; peak velocity, 4.6 m/s) with a normal left ventricular ejection fraction. Left-sided heart catheterization revealed clear coronary arteries and confirmed a post-ductal CoA with a peak-to-peak gradient of 110 mm Hg.

From the <sup>a</sup>Santa Maria Hospital, GVM Care & Research, Bari, Italy; and the <sup>b</sup>Department of Cardiac, Thoracic, and Vascular Sciences, University of Padua, Padua, Italy.

The authors attest they are in compliance with human studies committees and animal welfare regulations of the authors' institutions and Food and Drug Administration guidelines, including patient consent where appropriate. For more information, visit the [Author Center](#).

Manuscript received January 11, 2021; revised manuscript received March 15, 2021, accepted April 2, 2021.

**ABBREVIATIONS  
AND ACRONYMS**

- CoA** = coarctation of the aorta
- MSCT** = multislice computed tomography
- TAVR** = transcatheter aortic valve replacement
- TF** = transfemoral

Pivotal combined angiographic and multislice computed tomography (MSCT) imaging evaluation revealed calcified CoA, a remarkable degree of developing thoracic collateral vessels, and an extreme horizontal aortic root (Figures 1A and 1F to 1H). The aortic isthmus ratio, which was formerly used to reflect the degree of CoA, was 0.63 (1). Aortic valve measurements were as follows: the annulus area was 4.729 cm<sup>2</sup>, the perimeter-derived effective diameter was 77.5 mm, and the angle between the aortic annulus plan and the horizontal line was 73.27°/286.73° (Figures 1B and 1C).

The left subclavian artery was severely thinned and tortuous, with 2 acute angles immediately below its take-off. Its diameters ranged from 9.5 to 11.9 mm (Figures 1D and 1E). Right subclavian artery diameters ranged from 11.2 to 19.7 mm with a roughly calcified take-off (Figure 1D). The right and left common femoral artery diameters were 8 and 6.7 mm, respectively.

**MANAGEMENT**

Given the patient’s multiple comorbidities, staged endovascular repair of both disorders was clinically warranted by the heart team.

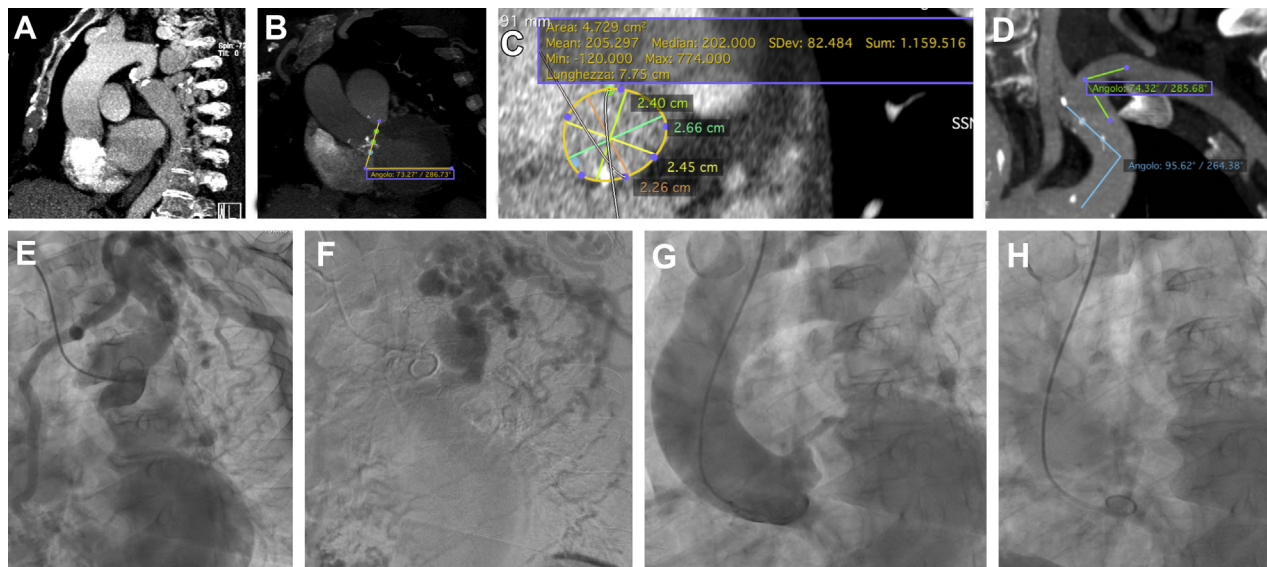
In view of the aforementioned anatomic shortcomings challenging alternate access, we opted for a staged CoA treatment followed by transfemoral (TF) transcatheter aortic valve replacement (TAVR).

Through the left common femoral artery, a 14-F smooth, tapered sheath was advanced on an Amplatz super-stiff 0.035-inch guidewire across the coarctation segment. Direct implantation of a double-balloon pre-mounted covered stent (CP NuMED, Heart Medical Europe BV, Best, the Netherlands), sized 22/45 mm according to MSCT-derived aortic diameters, was accomplished and obtained complete gradient resolution. However, the distal struts of the stent remained unflared despite a slightly oversized balloon post-dilatation up to 26 mm (maximum expandable diameter) (Figures 2A and 2B).

During the hospital stay, her renal function improved (creatinine, 1.59 mg/dl; azotemia, manifested by blood urea nitrogen, 77 mg/dl; estimated glomerular filtration rate, 52 ml/min), and a CoreValve Evolut R 29 bioprosthesis (Medtronic, Minneapolis, Minnesota) was delivered 1 week later.

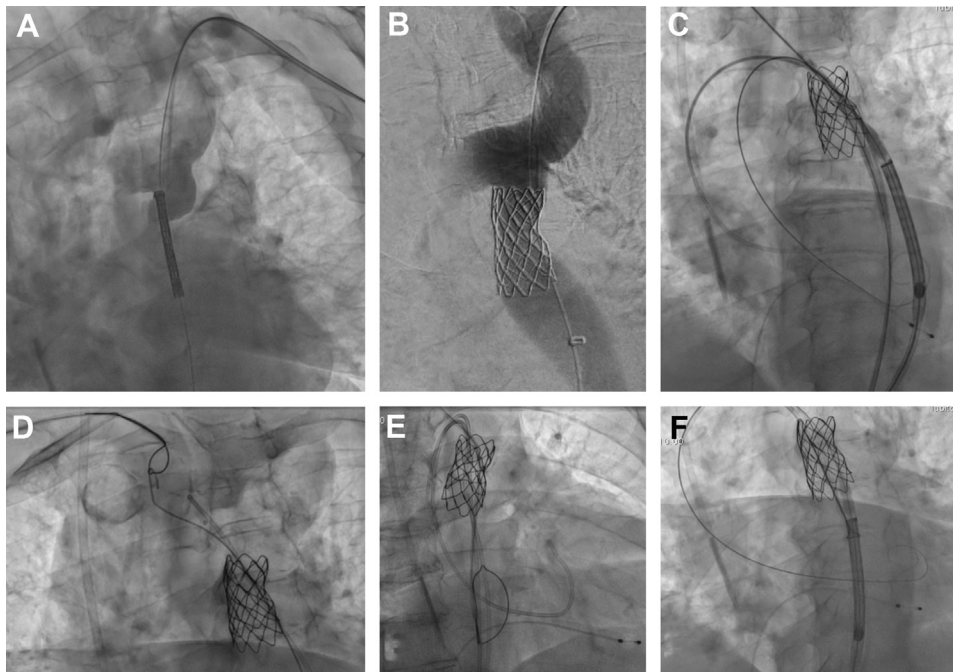
However, once the pre-mounted valve arrived on the covered-stent, it always became trapped on the distal unflared stent struts. Multiple attempts to push and rotate the device clockwise and counterclockwise failed. The use of facilitating rails, in the “buddy-

**FIGURE 1** Multislice Computed Tomography and Fluoroscopic Images



(A to D) Multislice computed tomography images. (A) Aortic coarctation. (B) Horizontal valve plane. (C) Aortic annulus measurements. (D) Left subclavian artery angles. (E to H) Fluoroscopic images. (E) Left subclavian artery severe tortuosity. (F) Huge thoracic collateral vessel development. (G and H) Ascending aorta and pigtail catheter horizontal valve-level position.

**FIGURE 2** Fluoroscopic Images



**(A and B)** Aortic coarctation stenting. **(C)** “Buddy-wire” and “balloon-sliding” techniques failure. **(D)** Snare guidewire retrieval. **(E)** Snare left open below the stent. **(F)** Nosecone hooked by the snare.

wire” and “balloon-sliding” techniques, was also unsuccessful (Figure 2C, Video 1). More aggressive post-dilatations, which may be helpful in resolving the crossing impairment, were avoided to prevent peri-procedural aortic complications.

The procedure was restarted with the snare-assisted technique. The snare was inserted by right radial access and advanced into the ascending aorta. There, it caught hold of a workhorse 0.035-inch guidewire that was previously passed through the stent, and both were retrieved in the descending aorta (Figure 2D, Video 2). All the standard steps of TAVR were repeated, passing through the opened snare (Figure 2E, Video 3). Once the device arrived on the stent, the snare was hooked at the level of the nosecone (Figure 2F). By pulling on the snare catheter while the delivery system was pushed forward, the snare lifted up the nosecone, which successfully crossed the stent and easily progressed into the arch (Figure 3A, Videos 4 and 5). When the device reached the aortic valve plane, the snare was retrieved in the midpart of the delivery system. Then, by lifting the snare using the “chaperone technique” (2), perfect horizontal alignment of the Evolut R was obtained (Figure 3B, Video 6). At this moment, the snare was

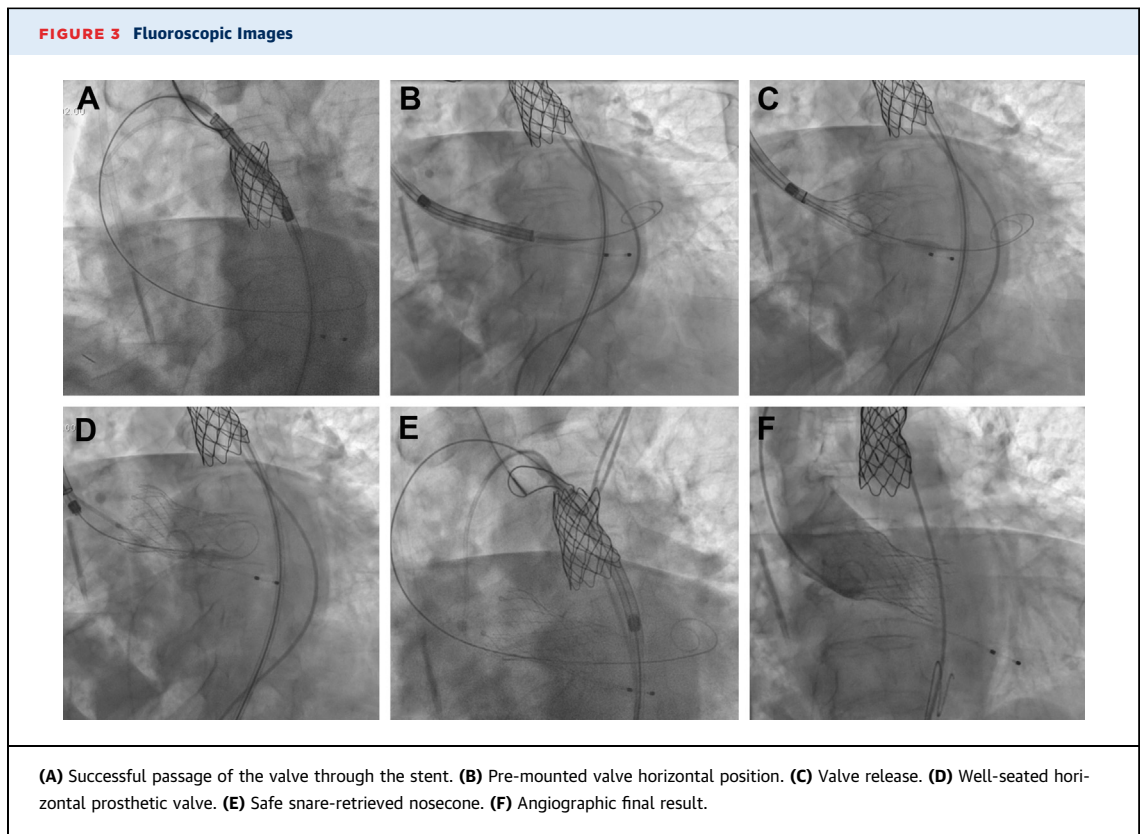
completely released and pulled back, pacing was started, and the valve was implanted (Figures 3C and 3D). After implantation of the valve, the delivery system was retrieved without snare support because neither friction nor the risk of a “whip effect” was perceived (Video 7). Once the nosecone was withdrawn up to the stent, it was re-snared to control its trackability, and to prevent damage to the stent, the stiff wire was withdrawn up to its flexible tip, and both freely retrieved (Figure 3E, Videos 8 and 9).

An optimal final result was obtained without any residual leakages (Figures 3F and 4, Video 10).

## DISCUSSION

The combination of symptomatic severe aortic stenosis and complex CoA is a rare clinical entity that poses several dilemmas in diagnosis and treatment because of the type and sequence of interventions as well as the anatomic shortcomings. Usually, concomitant single-step percutaneous treatment of both disorders is avoided because the risk of possible complications is too high.

Thus, a staged procedure was scheduled, and the heart team chose the option of TAVR by alternate



vascular access as a first step. However, unique adjunctive issues arose.

In some observational and randomized studies the transsubclavian access was found to be as effective as TF TAVR without the increased risks of vascular and nonvascular complications (3). Therefore, the left subclavian artery approach, especially in the presence of a horizontal ventriculoaortic axis, should be considered the most useful alternate access.

However, concerns exist regarding the abnormal histological features of the arterial wall adjacent to and distant to CoA that should be considered a general arteriopathy involving further vascular areas that are particularly prone to major complications. Thus, considering the thinned vessel wall, the severe tortuosity, and the extensive developing thoracic collateral vessels encountered in our patient, this access was discarded because it was deemed to incur a high risk of dissection, rupture, and major bleeding.

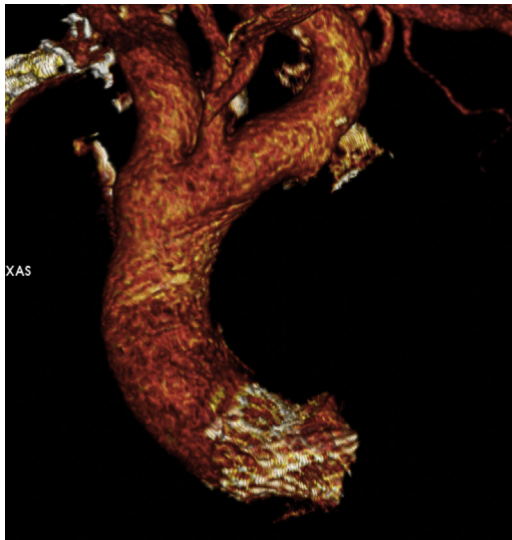
With regard to the right subclavian artery access, it involves additional technical issues. Specifically, if the angulation between the plane of the annulus and a horizontal reference line exceeds 30° to 60°, there can be difficulties positioning the transcatheter prosthesis correctly, and a higher rate of

peri-procedural valve complications (“pop-out” and paravalvular leak) is reported. Thus, this access was abandoned because of a contraindicated angle >70° (4). Other approaches (transcarotid, transapical) were associated with a prohibitive risk of major bleeding.

Therefore, CoA stenting was performed at first, and a safer TF approach for TAVR was scheduled 1 week later. Notably, a 4- to 6-week MSCT CoA stenting evaluation is recommended. However, it was discouraged because a further TAVR timing delay and the additional contrast dye administration were deemed risky, and even after the MSCT unflaring was confirmed, the TF remained the safest access.

Considering the cautious manipulations required to reduce the covered stent damage risk, the Edwards SAPIEN III prosthesis (Edwards Lifesciences, Irvine, California) would have been the preferred device because of the flexibility of its tip compared with the stiffer Evolut R prosthesis. However, the prominent procedural key factor of the extreme horizontal ventriculoaortic axis favored the recapture and reposition capability of the latter prosthesis. Regrettably, because the distal struts remained mildly unflared, the rigid nosecone of the device became stuck at that level even with the use of facilitating techniques.

**FIGURE 4** Multislice Computed Tomography Final Result



Subsequently, we started over with a fully snare-assisted TAVR technique. It consisted of retrograde right radial snare capture and control of the nosecone below the thoracic aortic stent. In fact, it allowed smoother, coaxial, and best-oriented tracking of the nosecone of the device through the stent.

Furthermore, the snare allowed the operator to track the device gently into the aortic arch and the ascending aorta, thus eliminating arch tortuosity and CoA stent friction. Finally, it proved useful to push the valve up before release, to allow an optimal

horizontal alignment across the eccentrically calcified native valve (2).

#### **FOLLOW-UP**

At 3-month follow-up, the patient was asymptomatic, with persistent normal renal function. An echocardiogram showed a well-seated valve with a mean gradient of 7 mm Hg and no valve leakage; the coarctation gradient was 8 mm Hg.

#### **CONCLUSIONS**

Multiple issues arise when adjunctive aortic disorders, such as complex CoA, occur in patients undergoing TAVR. These issues are mainly related to the procedural steps, the access route, and technical difficulties. In a patient with a horizontal aorta and previous CoA stenting, unique challenges may hamper the deliverability of the pre-mounted valve. In this case, further technical skills were required to rescue the procedure, and the snare technique proved safe and effective.

#### **FUNDING SUPPORT AND AUTHOR DISCLOSURES**

This work was supported by the Società Italiana di Cardiologia Interventistica-Gruppo Italiano di Studi Emodinamici (SICI-GISE). The authors have reported that they have no relationships relevant to the contents of this paper to disclose.

**ADDRESS FOR CORRESPONDENCE:** Dr. Alfredo Marchese, Interventional Cardiology, Ospedale Santa Maria, Via Antonio De Ferrariis 22, 70124 Bari (BA), Italy. E-mail: [alfma@libero.it](mailto:alfma@libero.it). Twitter: [@alfredomarches3](https://twitter.com/alfredomarches3).

#### **REFERENCES**

1. Alkashkari W, Albugami S, Hijazi ZM. Management of coarctation of the aorta in adult patients: state of the art. *Korean Circ J* 2019;49:298-313.
2. Medda M, Casilli F, Tespilli M, Bande M. The "chaperone technique." *J Am Coll Cardiol Intv* 2020;13:e15-8.
3. Beurtheret S, Karam N, Resseguier N, et al. Femoral versus nonfemoral peripheral access for transcatheter aortic valve replacement. *J Am Coll Cardiol* 2019;74:2728-39.
4. Testa L, Brambilla N, Laudisa ML, et al. Right subclavian approach as a feasible alternative for transcatheter aortic valve implantation with the CoreValve revalving system. *EuroIntervention* 2012;8:685-90.

**KEY WORDS** aortic ailments, aortic stenosis, complex aortic coarctation, snare-assisted TAVR

**APPENDIX** For supplemental videos, please see the online version of this paper.