

Lesson of the month 1: Case reports of arrhythmogenic cardiomyopathies in military personnel

Authors: Wajeeha Khan,^A Azeem S Sheikh,^B Emmanuel Ato Williams^C and Riccardo Proietti^D

ABSTRACT

In military recruits, sudden cardiac death rates have been reported as varying from 2 to 13 per 100,000 per year which are mostly related to exercise. However, the development of structural heart changes that may be associated with ventricular arrhythmias have not been reported among this cohort, despite them undergoing endurance training similar to athletes. Here, we report two cases where military personnel were found to have life-threatening cardiac arrhythmias associated with structural heart disease, highlighting the importance of early recognition and treatment of these arrhythmias.

KEYWORDS: Military, ventricular tachyarrhythmias, endurance, sudden cardiac death

Introduction

In military recruits, sudden cardiac death rates have been reported as varying from 2 to 13 per 100,000 per year, the majority of which are related to exercise. However, ventricular arrhythmias with associated structural heart changes are rare among this cohort. Here, we report two cases where military personnel were found to have life-threatening cardiac arrhythmias associated with structural heart disease, highlighting the importance of early recognition and treatment of these arrhythmias.

Case 1

A 37-year-old male soldier presented to an emergency department after experiencing palpitations while exercising in the gym. He had no significant medical history of note and denied family history of cardiomyopathy or sudden cardiac death. On arrival, he was experiencing palpitations but was haemodynamically stable. His electrocardiogram (ECG) demonstrated a regular broad complex ventricular tachycardia (VT) with left bundle branch block morphology. The patient's heart rhythm was reverted to sinus rhythm by intravenous amiodarone. Subsequent ECG showed sinus rhythm with 1st degree AV block and T-wave inversion in lead V1 and V2 (Fig 1a). Furthermore, the patient's echocardiogram

demonstrated a mildly dilated left ventricle and mildly impaired left ventricular systolic function (ejection fraction 40–45%). In addition, the right ventricle was dilated and mildly hypokinetic. The coronary angiography, electrophysiology (EP) study and a VT stimulation test were assessed to be normal. The cardiac magnetic resonance imaging (MRI) evaluation demonstrated a biventricular dilatation with right and left ventricular systolic function impairment (Fig 1b and 1c). Therefore, an ajmaline provocation test was performed which illustrated a spontaneous type 1 Brugada pattern on ECG at baseline (Fig 1d). However, incremental administration of ajmaline did not result in any significant changes in ST elevation and the test was terminated due to increased ectopic activity. The underlying diagnosis remained unclear but in view of the history of symptomatic broad-complex tachycardia, an implantable cardioverter defibrillator (ICD) was implanted. On his subsequent follow-ups, he had three separate episodes of fast VT terminated by ICD shocks over the course of following 3 years.

Case 2

A 53-year-old male ex-army officer was brought to an emergency department after having a cardiac arrest while playing football. The patient received cardiopulmonary resuscitation (CPR) and two automated external defibrillator (AED) shocks on the football pitch. On arrival, he was haemodynamically stable but with a reduced Glasgow Coma Scale score (13/15). The rhythm traces recorded by the AED demonstrated polymorphic VT, which was initially shocked to pulseless electrical activity (PEA) and then to ventricular fibrillation (VF) requiring further cardioversion. The patient was intubated and kept in the intensive care unit, made an excellent clinical and neurological recovery and was successfully extubated the following day. Later, it transpired that he had a history of exertional presyncope which was investigated 10 years earlier with ambulatory monitoring and showed a broad-complex tachycardia. However, his coronary angiography, EP study and echo were reported as normal at that time. He remained asymptomatic and continued as an endurance athlete.

On investigation, the patient's ECG demonstrated Epsilon wave in lead V1 among other changes as illustrated in Fig 2a. Echocardiography revealed a dilated left ventricle with moderate to severe impaired systolic function. The right ventricle was dilated with regional hypokinesis at both apex and the base. Furthermore, monitoring on the ward revealed frequent ectopics (more than 5,000 in a 24-hour period). The cardiac MRI demonstrated mildly elevated end-diastolic and end-systolic volumes of the right ventricle with a regional wall motion abnormality (Fig 2b and 2c).

Authors: ^Acore medical trainee, Morrision Hospital, Swansea, UK; ^Binterventional fellow, Morrision Hospital, Swansea, UK; ^Cspecialist registrar in cardiology, Morrision Hospital, Swansea, UK; ^DEP fellow, Morrision Hospital, Swansea, UK

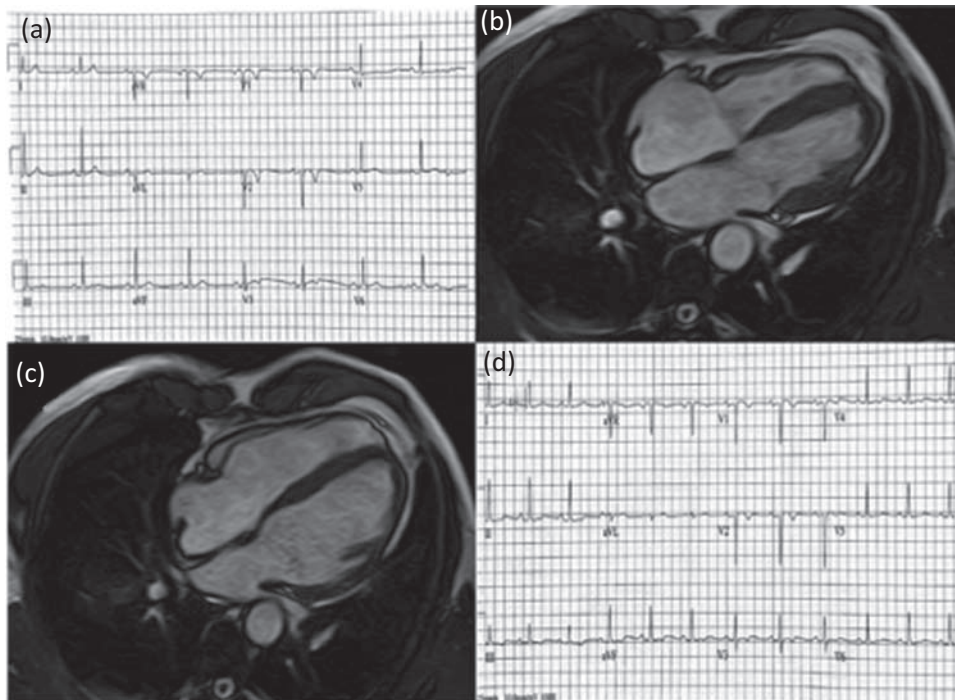


Fig 1. ECGs and cardiac MRI of case 1. Suggestive features of cardiomyopathy on ECG and MRI, and unmasking of the Brugada pattern with the Ajmaline provocation test. **(a)** A 12-lead ECG demonstrating sinus rhythm with 1st degree AV block and T-wave inversion in lead V1 and V2. **(b,c)** Cardiac MRI, SSFP 4-chamber view demonstrating biventricular dilatation, diastolic **(b)** and systolic **(c)** frames. **(d)** 12-lead ECG 1 hour after ajmaline provocation test showing spontaneous type 1 Brugada pattern. ECG = electrocardiogram; MRI = magnetic resonance imaging; SSFP = steady-state free precession

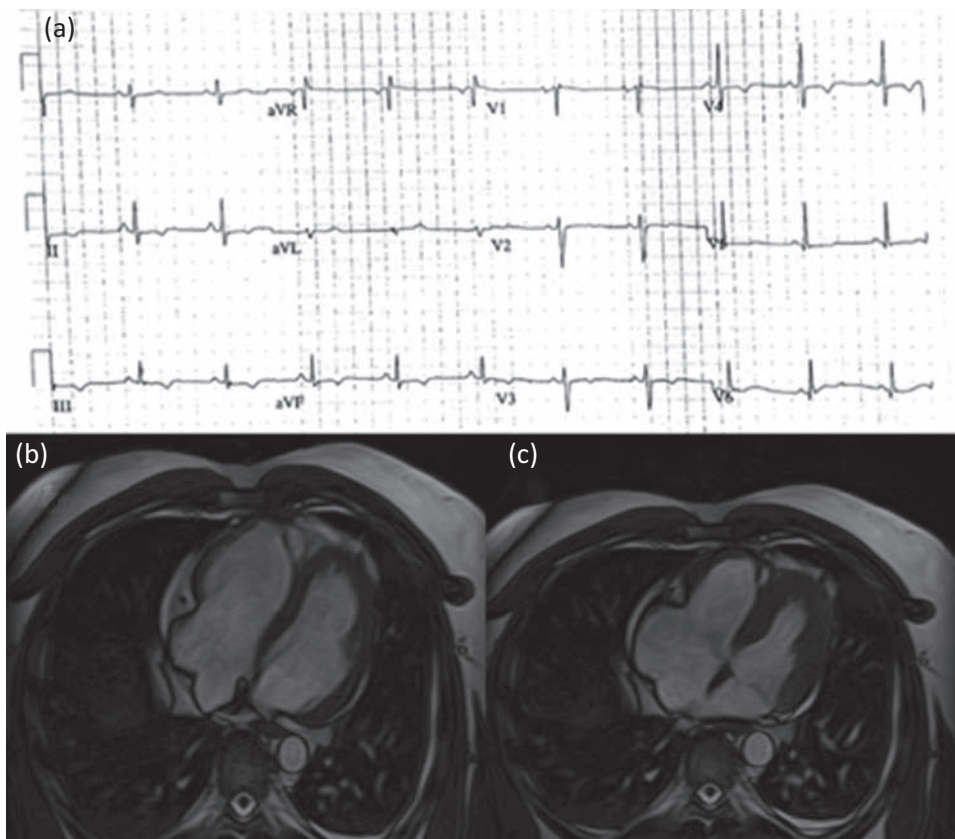


Fig 2. ECGs and cardiac MRI of case 2. Suggestive features of ARVD on ECG with evidence of cardiomyopathy on MRI. **(a)** A 12-lead ECG demonstrating Epsilon wave in lead V1 among other changes. **(b,c)** Cardiac MRI, SSFP transaxial stack, diastolic **(b)** and systolic **(c)** frames demonstrating RV dilatation. ARVD = arrhythmogenic right ventricular dysplasia; ECG = electrocardiogram; MRI = magnetic resonance imaging; RV = right ventricular; SSFP = steady-state free precession

The late gadolinium enhancement did not show any area of fibrosis. After some deliberation, it was felt that the patient fulfilled one major and two minor task force criteria for the diagnosis of arrhythmogenic right ventricular cardiomyopathy (ARVC), and so was offered an ICD which was successfully implanted. The patient was noted to have two self-limiting non-sustained VT (NSVT) and several episodes of supraventricular and ventricular ectopics on follow-up. These rhythm changes were noticed after a change in his exercise regime and diet, but resolved following adjustments in his diet and intensity of exercise regime.

Discussion

The cases reported here describe the development of structural heart changes in two soldiers that were associated with the occurrence of ventricular arrhythmias. Although it was not possible to make a definite diagnosis of ARVC or ion channel cardiomyopathy in either case, the presence of mostly right ventricle well-defined structural abnormalities on cardiac MRI points toward the presence of an arrhythmogenic cardiomyopathy. Notably, in both patients the ICD fired off to treat further ventricular arrhythmias at long-term follow-up.

Long-term intense physical training can lead to changes in diameters of heart cavities, wall thickness and functional parameters which can vary according to individuals age, nature of training and genetic factors.¹ These cumulative changes are termed as 'athletes heart'. Despite military recruits undergoing intense training similar to athletes there remains a paucity of literature reporting arrhythmias in soldiers.

Premature ventricular ectopic (VE) beats are usually an insignificant finding, present in up to 4% of the healthy adult population. In the British military, the criteria for investigation are strict: a single VE on a 12-lead ECG can be dismissed, but two or more requires Holter monitoring and referral to a cardiologist,² as the individual is at greater risk of an 'R on T phenomenon'. Frequent and more complex VEs such as bigeminy and trigeminy are more likely to be indicators of underlying cardiac disease.³

Classically, VT is associated with structural abnormalities of the heart, but it can occur in structurally normal hearts in up to 10% of patients.⁴ The most common cause of sudden cardiac death in the young is by a malignant ventricular tachyarrhythmia, originating from underlying inherited cardiac diseases such as cardiomyopathies and anomalous coronary arteries.⁵ Ventricular tachyarrhythmias can, however, be the result of many underlying pathologies and, in those older than 30 years, ischaemic heart disease and its sequelae are the most common trigger.⁶

More recently, Stanton *et al* reported on previously undescribed cardiac remodelling in young soldiers following military training and used the term 'soldier's heart' to describe these changes.⁷ The authors reported progressive changes in cardiac chambers, left ventricular mass and right ventricular function secondary to high-intensity exercises. Dello Russo *et al* evaluated 13 athletes with normal structure and function on cardiac imaging and history of ventricular arrhythmias with right ventricular biopsy and electroanatomical mapping and reported underlying myocardial inflammation and fibrosis.⁸ We believe that our two reported cases had symptoms secondary to intense military and personal training regimes and represent a spectrum of symptoms at two different

stages ie early and late stage of their underlying pathology. Both patients were considered high risk for future cardiac events and hence had an ICD inserted.

Since such patients usually present early with minor cardiac symptoms, a history of military background and intense training should trigger careful evaluation with further investigations. Imaging studies such as MRI to assess the heart morphology should be performed. Genetic testing is also warranted in case of strong family history and where indicated further evaluation with EP study should be performed. Follow-up of these patients is crucial to reduce the chances of any sudden cardiac events as evident from our second patient who was lost to follow-up and eventually sustained a cardiac event. The patient also continued endurance training following initial investigations and possibly would have benefited from early modification in training regime.

These case reports highlight the importance of early and thorough investigation of subjects with military background, who are involved in intense endurance training and are presenting with cardiac symptoms. The option of modification in exercise regimes should be explored early and patients should be followed up to ensure continuity of care and to minimize the chances of any adverse cardiac events. ■

Consent

Consent was obtained from both patients for the publication of their clinical details and images.

References

- 1 D'Andrea A, La Gerche A, Golia E *et al*. Right heart structural and functional remodeling in athletes. *Echocardiography* 2015;32(Suppl 1):S11–22.
- 2 Ministry of Defence. *Assessment of medical fitness, AP1269A* 3rd edn: MOD 1998:263–9 (Amendment date 20 October 2014). https://docksci.com/atrial-and-ventricular-tachyarrhythmias-in-military-personnel_5a30789bd64ab201b5038770.html
- 3 Findlow D, Doyle E. Congenital heart disease in adults. *B J Anaesth* 1997;78:416–30.
- 4 Issa A, Miller J, Zipes D. *Clinical arrhythmology and electro-physiology: A Companion to Braunwald's Heart Disease*. Saunders Elsevier, 2009:321–3, 440–2.
- 5 Corrado D, Basso C, Rizzoli G, Schiavon M, Thiene G. Does sports activity enhance the risk of sudden death in adolescents and young adults? *J Am Coll Cardiol* 2003;42:1959–63.
- 6 Amital H, Glikson M, Burstein M. Clinical characteristics of unexpected death among young enlisted military personnel: results of a three-decade retrospective surveillance. *Chest* 2004;126:528–33.
- 7 Stanton K, Wylie L, Coy A, Kienzle V, Celermajer D. Soldier's heart: Substantial left and right heart remodelling occurs during military training. *Heart Lung Circ* 2016;25(Suppl 2):S82.
- 8 Russo DA, Pieroni M, Santangeli P *et al*. Concealed cardiomyopathies in competitive athletes with ventricular arrhythmias and an apparently normal heart: role of cardiac electroanatomical mapping and biopsy. *Heart Rhythm* 2011;8:1915–22.

Address for correspondence: Dr Riccardo Proietti, Department of Cardiac, Thoracic, and Vascular Sciences, via Giustiniani 2, 35121 Padua, Italy.

Email: riccardoproietti6@gmail.com