

# Clinical Course and Outcome of Autoimmune Hepatitis/Primary Sclerosing Cholangitis Overlap Syndrome

Annarosa Floreani, M.D.,<sup>1</sup> Erik Rosa Rizzotto, M.D.,<sup>1</sup> Francesco Ferrara, M.D.,<sup>1</sup> Isabella Carderi, M.D.,<sup>1</sup> Diego Caroli, M.D.,<sup>1</sup> Luigi Blasone, M.D.,<sup>1</sup> and Vincenzo Baldo, M.D.<sup>2</sup>

<sup>1</sup>Department of Surgical and Gastroenterological Sciences, University of Padova, Padova, Italy; and <sup>2</sup>Department of Hygiene and Public Health, Institute of Hygiene, University of Padova, Padova, Italy

Autoimmune hepatitis/primary sclerosing cholangitis (AIH/PSC) overlap syndrome is a relatively uncommon variant of PSC.

**AIM:** To evaluate the natural history of AIH/PSC overlap syndrome compared to a group of “classical” PSC.

**METHODS:** Forty-one consecutive PSC patients, with a regular follow-up of at least 2 years, were prospectively included in the study. Among these, 7 fulfilled the criteria for AIH/PSC overlap syndrome.

**RESULTS:** The AIH/PSC overlap group significantly differed from the “classical” PSC group in the following parameters: mean age at presentation ( $21.4 \pm 5.0$  vs  $32.3 \pm 10$  years,  $p < 0.01$ ), AST  $191.0 \pm 14.8$  vs  $48.9 \pm 34.5$  U/L,  $p < 0.005$ ), ALT ( $357.0 \pm 26.5$  vs  $83.7 \pm 60.7$  U/L,  $p < 0.005$ ) and serum IgG ( $25.6 \pm 4.7$  vs  $12.9 \pm 6.0$  mg/dl,  $p < 0.0001$ ). The mean follow-up was similar in the 2 groups ( $93.3 \pm 65.9$  vs  $98.1 \pm 65.9$  months respectively). Treatment included immunosuppression + ursodeoxycholic acid (UDCA) in the AIH/PSC overlap patients, and UDCA in the “classical” PSC group. Deaths were recorded only in the classical PSC group. The median survival in the latter group was 207 months (95% C.I. 87.6–326.4). The major events during the follow-up included: OLTx (1/7 vs 6/34), and neoplasms (only in the group of “classical” PSC). The new Mayo score prognostic index only increased significantly during follow-up in the “classical” PSC group ( $r^2$  0.8117,  $p < 0.01$ )

**CONCLUSION:** Patients with AIH/PSC overlap syndrome seem to benefit from immunosuppression + UDCA therapy, survival is apparently better than in “classical” PSC condition.

(Am J Gastroenterol 2005;100:1516–1522)

## INTRODUCTION

Overlap syndromes are defined as conditions with the diagnostic features of more than one disease (1). In recent years, however, the term has been used to define the features of an autoimmune liver condition that is not entirely consistent with any of the established criteria for the diagnosis of autoimmune hepatitis (AIH), primary biliary cirrhosis (PBC), or primary sclerosing cholangitis (PSC) (1). While AIH/PBC overlap syndrome is frequent among adults, AIH/PSC overlap is more common in children (2). The clinical characteristics of this latter group are not well defined, however, in adults at least. Gregorio *et al.* identified a 49% prevalence of AIH/PSC overlap syndrome among AIH paediatric patients (3), whereas in adult series it seems to be quite rare.

In an attempt to identify this condition better, the new AIH scoring system (4) has been applied in a number of retrospective studies (5–9). On the basis of this method, 1.8–3.4%

of PSC patients satisfied internationally agreed criteria for the diagnosis of “definite” AIH. However, the utility of AIH scoring system regarding the diagnosis of AIH/PSC overlap syndrome is under discussion, due to its inadequacy to diagnose AIH in an individual patient. Moreover, clinical description of very few cases of this condition is reported in the literature, and reports on its natural history are still lacking.

The aim of the present study was therefore to evaluate the clinical course and outcome of AIH/PSC overlap syndrome by comparison with a group of “classical” cases of PSC.

## MATERIALS AND METHODS

### Patients

The study considered all patients consecutively diagnosed with PSC between 1985 and 2001, with a regular follow-up of at least 2 yr. In all, 41 patients (25 males, 16 females) were included. The diagnosis of PSC in all patients was based on the cholangiographic criteria obtained by endoscopic

retrograde cholangiography (ERCP). No patient had a previous history of choledocholithiasis nor bile duct exploration.

The revised scoring system for the diagnosis of AIH was calculated according to the report of the International Autoimmune Hepatitis group (4). The diagnosis of AIH/PSC overlap syndrome was established when the following criteria were met: (i) a total aggregate score for AIH > 15 (defining the AIH as “definite”); (ii) antinuclear antibodies (ANA) or anti-smooth muscle antibodies (ASMA) present in a titre of at least 1:40; and (iii) liver histology with piecemeal necrosis, lymphocyte rosetting, moderate or severe periportal, or periseptal lobular inflammation.

Association of inflammatory bowel disease (IBD) was assayed in each case by colonoscopy with multiple biopsies and/or (in the case of clinical symptoms of malabsorption), by barium enema. The diagnosis of ulcerative colitis was confirmed by conventional endoscopic, histological, and clinical criteria, according to the Truelowe-Edwards classification (10). Crohn’s colitis was accepted if chronic inflammatory colonic disease was associated with extensive small bowel involvement and showed typical histological and endoscopic appearances, or with segmental inflammation and a histologically normal rectum. In conjunction with a consistent clinical presentation of granulomas, focal inflammation, fissures, preserved epithelium, mucin production, or lymphoid aggregates were considered as the most discriminating features of Crohn’s disease. The diagnosis of Crohn’s disease was confirmed, as regards ileal localization, on the basis of radiological criteria (barium small bowel enema), and endoscopic/histological criteria (11).

Patients were treated with ursodeoxycholic acid (UDCA) 15–20 mg/kg per day. Patients with AIH/overlap syndrome were treated with prednisolone (initial dosage of 0.5 mg/kg per day) associated with steroid-sparing azathioprine (initial dosage of 2 mg/kg per day) with a tailored maintenance dosage of 10–15 mg/day of prednisolone and 50–75 mg/day of azathioprine plus UDCA (15–20 mg/kg per day).

The new Mayo risk score, based on a combination of five variables (bilirubin, age, prothrombin time, and severity of edema) was calculated for each patient (12).

### *Evaluation of Liver Histology*

Of the 41 subjects, 38 underwent liver biopsy. In three subjects (in the group of “classical” PSC) liver biopsy was not performed, because the patients refused this procedure.

Biopsy samples were examined by a dedicated pathologist in a blinded fashion using codes. The available stains included hematoxylin, stains for connective tissue, iron, and copper-associated protein. Histologic findings were classified according to Ludwig (13). The following histologic features were recorded: bile duct damage, periductal fibrosis, portal inflammation, interface hepatitis (piecemeal necrosis), ductular proliferation, lobular necrosis, and canalicular cholestasis.

### *Follow-Up*

The patients were followed-up regularly with clinical and biochemical examination every 4–6 months. Biochemical parameters included AST, ALT, ALP, immunoglobulins, bilirubin, red cell and white cell count, prothrombin time, CEA, and  $\alpha$ -fetoprotein. Liver ultrasound was performed every 6 months. ERCP was performed if liver function tests findings deteriorated.

Cholangio-nuclear magnetic resonance (cholangio-NMR) was performed after 1998 every 2 yr, and cholangio-NMR plus choangio-CT was performed in all patients every 2 yr from 2001.

Patients with diagnosis of IBD underwent colonoscopy with multiple biopsies every 2 yr.

The mean follow-up was  $93.3 \pm 65.9$  months in the group with AIH/PSC overlap syndrome and  $98.1 \pm 65.9$  months in the group with classical PSC.

### *Laboratory Methods*

Autoantibodies (AMA, ASMA, and ANA) were tested by indirect immunofluorescence method using normal human gastric mucosa and normal rat kidney and liver. Sera were tested at an initial dilution of 1:5 and were considered to be positive when they produced a reaction at a dilution of  $\geq 1:40$ . Anti-neutrophil cytoplasmic antibodies (ANCA) were determined by indirect immunofluorescence. The patient’s serum (diluted 1:20, 1:40) was applied to neutrophils previously fixed in ethanol and incubated with F(ab)<sub>2</sub> fragment of rabbit anti-human immunoglobulin (Ig)G gamma chain labeled with fluorescein isothiocyanate (Alifax Diagnostici, Padua, Italy). Immunofluorescent staining in the perinuclear zone (p-ANCA) or cytoplasmic compartment (c-ANCA) in the 1:20 sample was taken as positive.

Testing for anti-HCV was done in duplicate by second or third-generation ELISA (Ortho Diagnostic System, Raritan NJ) and confirmed by HCV-RNA detection using a commercially available qualitative polymerase chain reaction assay (Amplicor, Monitor assay; Roche Diagnostic System, Branchburg, NJ).

The other biochemical variables were assayed by standard methods.

### *Statistical Analysis*

Quantitative data are expressed as mean and standard deviation (SD). The *t*-test (with Fisher’s exact test when appropriated) was used for qualitative data,  $\chi^2$  for qualitative data, and Wilcoxon test for matched pairs. Survival was analyzed according to the Kaplan–Meier method and was assessed with the log-rank test. Statistical analysis was performed using SPSS software (SPSS, Chicago, IL).

## **RESULTS**

Seven patients fulfilled the criteria for AIH/PSC overlap syndrome, while a diagnosis of classical PSC was recorded in the

**Table 1.** Clinical Features of Patients at Presentation (Data are Expressed as Mean  $\pm$  SD)

	AIH/PSC	Classical PSC	<i>p</i>
Subject number	7	34	–
Age (mean $\pm$ SD)	21.4 $\pm$ 5.0	32.3 $\pm$ 10.2	<0.01
Male:female ratio	3:4	22:12	n.s.
Association with IBD	2 (28.5%)	21 (61.7%)	<0.05
HCV +	0 (0%)	4 (11.7%)	n.s.
Mayo score	2.71 $\pm$ 0.66	2.61 $\pm$ 0.66	n.s.
Total bilirubin (mmol/l)	22.3 $\pm$ 12.9	15.2 $\pm$ 8.2	n.s.
AST (IU/l)	191.0 $\pm$ 14.8	48.9 $\pm$ 34.5	<0.005
ALT (IU/l)	357.0 $\pm$ 26.5	83.7 $\pm$ 60.7	<0.005
ALP (IU/l)	223.6 $\pm$ 175.2	318.2 $\pm$ 229.4	n.s.
GGT (IU/l)	155.1 $\pm$ 242.7	229.1 $\pm$ 193.2	n.s.
Albumin (g/l)	43.1 $\pm$ 2.5	42.1 $\pm$ 5.6	n.s.
PT (%)	80.2 $\pm$ 7.3	91.3 $\pm$ 15.8	n.s.
IgG (g/l)	25.6 $\pm$ 4.7	12.9 $\pm$ 6.0	<0.0001
IgA (g/l)	3.8 $\pm$ 1.5	2.8 $\pm$ 1.8	n.s.
IgM (g/l)	2.3 $\pm$ 1.1	1.6 $\pm$ 1.1	n.s.
NOSAbs	7/7 (100%)	6/34 (17.6%)	<0.0001
p-ANCA	4/7 (57.1%)	17/34 (50%)	n.s.

NOSAbs = non-organ-specific autoantibodies.

remaining 34 patients. Patients with AIH/PSC overlap syndrome were initially diagnosed as having AIH and became resistant to immunosuppression. The AIH scoring system gave rise to a definite diagnosis of AIH in 7/7 cases. All of them underwent ERCP (that showed bile duct changes typical of PSC) at a median time of 17 months (range 6–30 months) after the initial diagnosis of AIH.

The patients' clinical features are summarized in Table 1. Patients with AIH/PSC overlap syndrome were significantly younger at presentation (21.4  $\pm$  5 vs 32.3  $\pm$  10.2 yr,  $p < 0.01$ ), and exhibited significantly higher serum levels of transaminases and IgG than the classical PSC group. Association with IBD was more common in the group with "classical" PSC than AIH/PSC overlap syndrome group ( $p < 0.05$ ). Moreover, all patients with AIH/PSC overlap syndrome were positive for non organ-specific autoantibodies, whereas this was true of only 6 (17.6%) in the group with classical PSC ( $p < 0.0001$ ). Four patients with classical PSC were chronically infected with hepatitis C (all of them were HCV-RNA positive at quantitative polymerase chain reaction).

The clinical details of the AIH/PSC overlap syndrome patients are summarized in Table 2. The diagnosis of AIH preceded the diagnosis of PSC in all cases by a median 2 yr (range 1–6 yr). In one case, the histological picture revealed advanced disease (cirrhosis). In three cases, the biliary tree involvement was intrahepatic, while it was extrahepatic in one, and both intra- and extrahepatic in the remaining three cases. An association with IBD was recorded in two cases (both cases with ulcerative colitis). A rheumatologic autoimmune condition was recorded in three cases (two had juvenile rheumatoid arthritis and one had seronegative spondylitis). One subject had peripheral vasculitis and one had autoimmune azoospermia.

All patients are still alive, but one patient (P.L.) received a liver transplant for increasingly severe portal hypertension; she had several episodes of gastrointestinal bleeding, and acquired de novo hepatitis B virus infection, and is taking Lamivudine treatment.

### Treatment

Patients with AIH/PSC overlap syndrome who received immunosuppression + UDCA showed a significant reduction in serum AST over a 5-yr course of treatment ( $r^2 = 0.7591$ ,  $p < 0.05$ ); a reduction in serum ALT was also observed, though it was not statistically significant. The cholestasis parameters (GGT and ALP) did not change significantly (Fig. 1).

No significant change was noted in these biochemical parameters over a 5-yr course of treatment (with UDCA) in the group with classical PSC (Fig. 2).

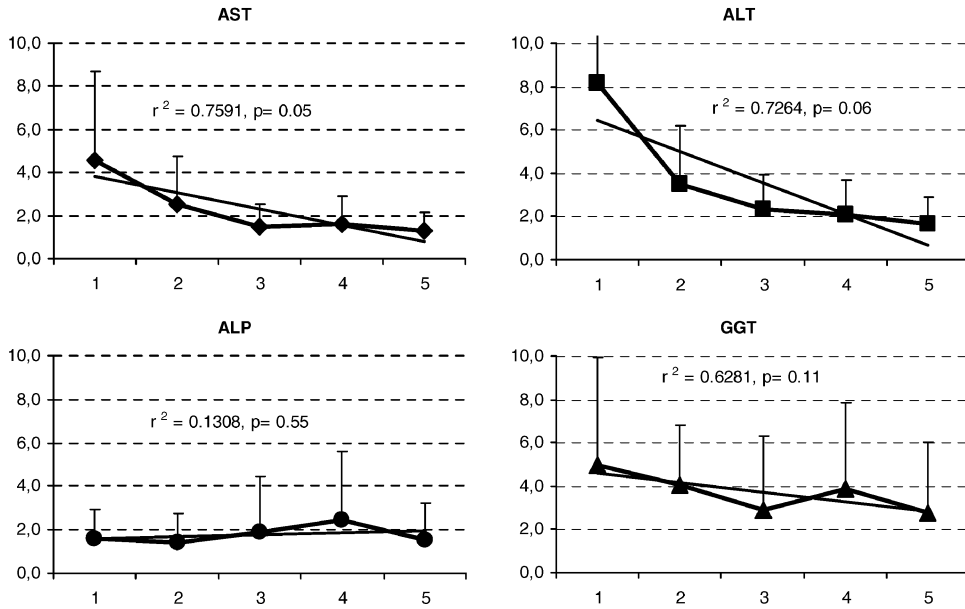
### Follow-Up

The Mayo score prognostic index only showed a significant progressive increase during the follow-up in the "classical" PSC group ( $r^2 = 0.8117$ ,  $p < 0.01$ ), whereas in the group with AIH/PSC syndrome it remained almost stable (Fig. 3).

During follow-up, an overall seven patients received OLTx (one in the group with AIH/PSC overlap syndrome and six in the group with classical PSC). Cholangiocarcinoma (CC) only developed only in the group with classical PSC (in five cases, 14.7%), but five other patients in said group (14.7%) developed extrahepatic malignancies: three colo-rectal cancers, one MALT lymphoma, and one lung

**Table 2.** Clinical Characteristics of AIH/PSC Overlap Syndrome

Pts	Sex	Age	AIH Diagnosis	Ludwig Stage Histologic Stage	PSC/AIH Diagnosis	Localization of PSC	Associated Conditions	Outcome
B.F.	F	26	1995	III	2001	Intrahepatic	Seronegative spondylitis	Alive
B.L.	M	19	1999	II	2000	Intrahepatic	UC	Alive
B.M.	M	32	2001	I	2002	Extrahepatic	Autoimmune azoospermia	Alive
N.A.	M	27	1990	III	1996	Intra and extrahepatic	UC	Alive
P.L.	F	15	1990	II	1995	Intrahepatic	Juvenile RA	OLTx (2000) and Lamivudine-resistant de novo HBV infection
R.M.	F	15	1995	III	1997	Intra and extrahepatic	Peripheral Vasculitis	Alive
S.E.	F	16	1999	IV	2000	Intra and extrahepatic	Juvenile RA	Alive



**Figure 1.** Changes in biochemical parameters over a 5-yr course of immunosuppression + UDCA in the AIH/PSC overlap syndrome patients.

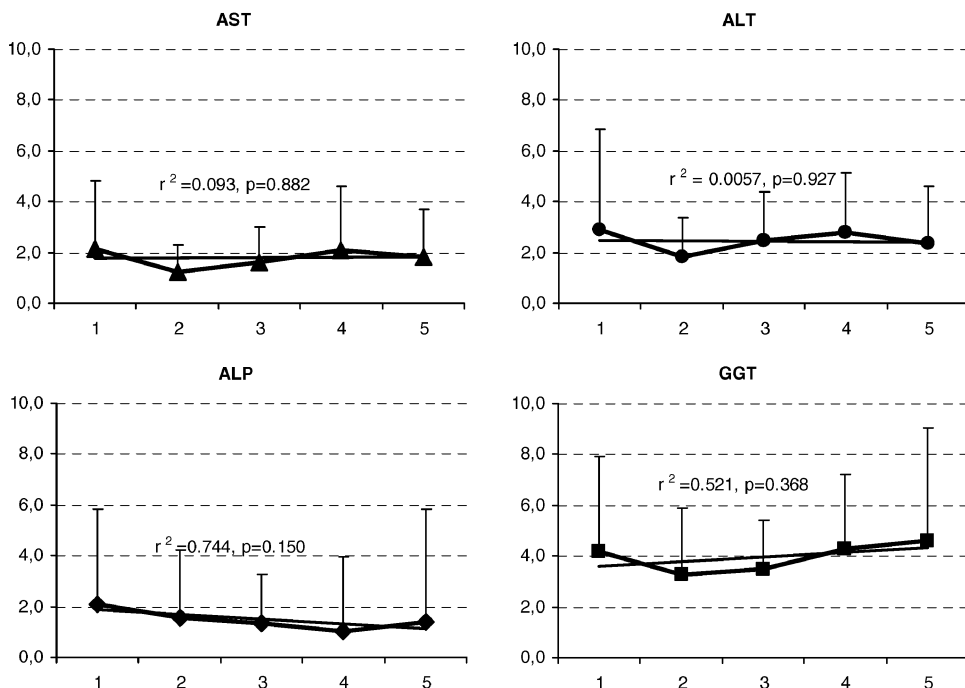
cancer. One patient developed a double cancer (CC and uterine carcinoma).

In all patients associated IBD remained in remission under maintenance therapy with Mesalazine.

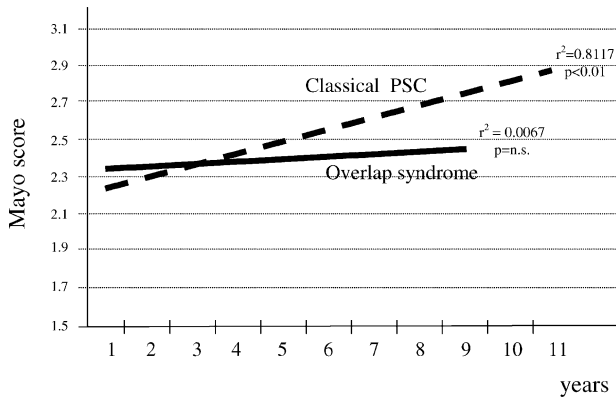
All deaths were recorded in the group with classical PSC (nine cases: eight for neoplasms and one for a cardiac event, namely toursade de pointes). Survival curves showed a median survival of 207 months in the group with classical PSC (95% CI: 87.6–326.4). The cumulative probability of survival at 256 months was 42.7%. (Fig. 4).

**DISCUSSION**

Our study suggests that PSC is a heterogeneous disease and its natural history is influenced by several factors, such as autoimmunity and certain associated conditions. Among PSC patients, a subgroup showing the characteristics of AIH/PSC overlap syndrome certainly has peculiar features. Considering the limited number of cases reported in the literature (Table 3), ours represents a relatively large series. The largest series (9 patients) has been reported by van Buuren *et al.*, (8)



**Figure 2.** Changes in biochemical parameters over a 5-yr course of UDCA in the group with classical PSC patients.

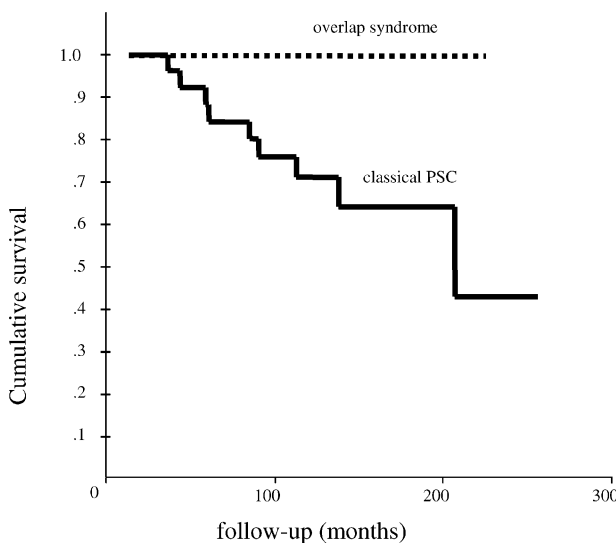


**Figure 3.** Trend of new Mayo score prognostic index during the follow-up.

in a retrospective study. Our study is the only one to have considered patients with AIH/PSC overlap syndrome prospectively by comparison with patients with classical PSC. Our results indicate that patients with AIH/PSC overlap syndrome are younger at presentation and have significantly higher serum levels of transaminases and IgG than patients with classical PSC; they seem to benefit from immunosuppression + UDCA therapy, and they appear to have a better survival than patients with classical PSC.

There are several points to be stressed. First of all, the diagnosis of AIH/PSC overlap syndrome is difficult to establish. Using the AIH scoring system modified in 1999 on 211 patients with PSC, Kaye *et al.*, (7) found three subjects (1.4%) with a definite AIH and 13 with probable AIH. In all our patients the clinical features at presentation were of AIH, while PSC was diagnosed subsequently, when immunosuppression failed to achieve clinical remission.

Boberg *et al.*, (6) observed four patients with clinical characteristics of typical AIH, who responded to immunosuppres-



**Figure 4.** Kaplan–Meier survival curves.

sion with prednisolone and azathioprine, and during follow-up they developed a biochemical profile with cholestasis and the typical cholangiographic signs of PSC. This pattern of initial response to immunosuppression was also observed by Abdo (24), McNair (22), Gohlke (19), and van Buuren (8). In the Dutch study (8), however, other patients diagnosed with PSC developed AIH/PSC overlap syndrome after 3 yr.

The second point to note is the response to immunosuppressive therapy in combination with UDCA. The majority of published studies (Table 3) describe AIH/PSC overlap syndrome patients treated with corticosteroids or combination (corticosteroids/azathioprine). One patient has been treated with cyclosporine (17). Two other patients were successfully given immunosuppression + UDCA successfully (19, 23). Among those treated with immunosuppression, a good biochemical response was reached in at least 50% of cases (6, 8, 15, 18, 20). In our group of patients with AIH/PSC overlap syndrome, a 5-yr treatment with immunosuppression + UDCA was significantly effective in amelioration AST; a drop in serum ALT, GGT, and ALP was also obtained, albeit without reaching a statistical significance. The most impressive results were obtained, however, considering the Mayo score. In fact, the Mayo score prognostic index did not change significantly during the follow-up (in our patients with AIH/PSC overlap syndrome), whereas it showed a significant progressive increase in the classical PSC group. On the other hand, the group with classical PSC showed no significant change in biochemical parameters. Kaplan–Meier survival curves showed a median survival time of 207 months in this latter group.

The major events affecting survival were the neoplastic complications, namely cholangiocarcinoma and other neoplasms. In fact, PSC should be regarded as a condition at high risk of neoplasia, not only for the liver and colon, but of all organs. This is consistent with Berquist *et al.* (26) finding a high incidence of hepatic and extrahepatic neoplasms in PSC. This high risk contributes to the difficult timing of liver transplant in these patients. Several time-fixed Cox regression prognostic models for survival in PSC have been published, but estimation of prognosis for the individual PSC patient still remains a challenge (27). Moreover, at present it is still difficult to recommend a useful strategy for preventing the neoplastic risk. Serum tumor markers can be monitored, but false negative and false positive results are a problem. There is a need to develop more sensitive serum markers together with improving imaging techniques to reveal the typical pattern of cholangiocarcinoma.

In our patients, with and without AIH/PSC overlap syndrome, we observed no reactivation or severe outcome of associated IBD. In all patients, the disease remained in remission with Mesalazine maintenance therapy. However, due to the high incidence of colonic cancer, an accurate surveillance program based on colonoscopy with multiple biopsies every 2 yr is recommended.

In conclusion, AIH/PSC overlap syndrome is a variant of PSC that mainly affects young people. It should be suspected

**Table 3.** Case Series of AIH/PSC Overlap Syndrome

Authors	Year	References	N.	IBD	Treatment	Response
Minuk	1988	14	2	UC	St	Poor
Rabinovitz	1992	15	1	UC	St/Az	Good
Perdigoto	1992	16	5	UC	St/Az	Failure in 4; OLTx in 2
Lawrence	1994	17	1	UC	Cyclosporine	Good
Wurbs	1995	18	1	No	St/Az	Good
Gohlke	1996	19	3	UC (#1)	St/Az + UDCA	Remission in 1
Boberg	1996	6	2	UC	St	OLTx in 1; death in 1
Protzer	1996	20	4	UC (#1)	St/Az	Good
Luketic	1997	21	5	UC (#2)	St/Az	OLTx in 4
McNair	1998	22	5	UC (#2)	St/Az	
Hatzis	2000	23	1	No	St/Az + UDCA	Good biochemical response
Van Buuren	2000	8	9	UC (#5) CD (#1) UD (#2)	St/Az	Good biochemical response in 5; 3 OLTx
Abdo	2002	24	6	UC (#3)	St/Az in 6 UDCA in 5 (after immunosuppression)	OLTx in 2; good in 3; poor in 1
Takiguchi	2002	25	1	No	St/Az + UDCA	Poor

St = steroids; Az = azathioprine; UC = ulcerative colitis; CD = Crohn's disease; UD = undetermined colitis; OLTx = liver transplant

in the case of little or no response to immunosuppression in a patient with AIH. However, since late sequelae have been described in patients with AIH, a careful monitoring of the biochemical markers of cholestasis is recommended. A cholangiographic study should also be recommended in patients presenting histological features of AIH and associated ductular damage. AIH/PSC overlap syndrome seems to benefit from immunosuppression + UDCA therapy and appears to offer a better chance of survival than classical PSC. Further prospective studies on the natural history of this variant are warranted to establish common guidelines in the management of this condition.

**Reprint requests and correspondence:** Annarosa Floreani, Department of Surgical and Gastroenterological Sciences, Via Giustiniani, 2, 35128 Padova, Italy.

Received November 23, 2004; accepted February 18, 2005.

## REFERENCES

- Woodward J, Neuberger J. Autoimmune overlap syndromes. *Hepatology* 2001;33:994–1002.
- Durazzo M, Premoli A, Fagoonee S, et al. Overlap syndromes of autoimmune hepatitis. What is known so far. *Dig Dis Sci* 2003;48:423–30.
- Gregorio GV, Portmann B, Karani J, et al. Autoimmune hepatitis/sclerosing cholangitis overlap syndrome in childhood: A 16 year prospective study. *Hepatology* 2001;33:544–53.
- Alvarez F, Berg PA, Bianchi FB, et al. International autoimmune hepatitis group report: Review of criteria for diagnosis of autoimmune hepatitis. *J Hepatol* 1999;31:929–38.
- Czaja AJ, Carpenter HA. Validation of scoring system for diagnosis of autoimmune hepatitis. *Dig Dis Sci* 1996;41:305–14.
- Boberg KM, Fausa O, Haaland T, et al. Features of autoimmune hepatitis in primary sclerosing cholangitis: An evaluation of 114 primary sclerosing cholangitis patients according to a scoring system for the diagnosis of autoimmune hepatitis. *Hepatology* 1996;23:1369–76.
- Kaya M, Angulo P, Lindor KD. Overlap of autoimmune hepatitis and primary sclerosing cholangitis: An evaluation of a modified scoring system. *J Hepatol* 2000;33:537–42.
- Van Buuren HR, van Hoogstraten HJF, Terkivatan T, et al. High prevalence of autoimmune hepatitis among patients with primary sclerosing cholangitis. *J Hepatol* 2000;33:543–8.
- Muratori L, Cassani P, Pappas G, et al. The hepatic/cholestatic “overlap” syndrome. An Italian experience. *Autoimmunity* 2002;35:565–8.
- Truelowe SC, Witts LJ. Cortisone in ulcerative colitis. Final report in a therapeutic trial. *BMJ* 1955;5:1041–8.
- Lennard-Jones JE. Classification of inflammatory bowel disease. *Scand J Gastroenterol Suppl* 1989;170:2–6.
- Kim WR, Therneau TM, Wiesner RH, et al. A revised natural history model for primary sclerosing cholangitis obviates the need for liver histology. *Mayo Clin Proc* 2000;75:688–94.
- Ludwig J. Surgical pathology of the syndrome of primary sclerosing cholangitis. *Am J Surg Pathol* 1989;13(suppl 1):43–9.
- Minuk GY, Sutherland LR, Pappas SC, et al. Autoimmune chronic active hepatitis (lupoid hepatitis) and primary sclerosing cholangitis in two young adult females. *Can J Gastroenterol* 1988;2:22–7.
- Rabinovitz M, Demetris AJ, Bou-Abboud CF, et al. Simultaneous occurrence of primary sclerosing cholangitis and autoimmune chronic active hepatitis in a patient with ulcerative colitis. *Dig Dis Sci* 1992;37:1606–11.
- Perdigoto R, Carpenter HA, Czaja AJ. Frequency and significance of chronic ulcerative colitis in severe corticosteroid-treated autoimmune hepatitis. *J Hepatol* 1992;14:325–31.
- Lawrence SP, Sherman KE, Lawson JM, et al. A 39 year old man with chronic hepatitis. *Semin Liver Dis* 1994;14:97–105.
- Wurbs D, Klein R, Terracciano LM, et al. A 28-year-old woman with a combined hepatic/cholestatic syndrome. *Hepatology* 1995;22:1598–605.
- Gohlke F, Lohse AW, Dienes HP, et al. Evidence for an overlap syndrome of autoimmune hepatitis and primary sclerosing cholangitis. *J Hepatol* 1996;24:699–705.
- Protzer U, Dienes HP, Bianchi L, et al. Post-infantile giant cell hepatitis in patient with primary sclerosing cholangitis and autoimmune hepatitis. *Liver* 1996;16:274–82.

21. Luketic VA, Gomez DA, Sanyal AJ, et al. An atypical presentation for primary sclerosing cholangitis. *Dig Dis Sci* 1997;42:2009–16.
22. McNair AN, Moloney M, Portman BC, et al. Autoimmune hepatitis overlapping with primary sclerosing cholangitis in five cases. *Am J Gastroenterol* 1998;93:777–84.
23. Hatzis GS, Vassiliou VA, Delladetsima JK. Overlap syndrome of primary sclerosing cholangitis and autoimmune hepatitis. *Eur J Gastroenterol Hepatol* 2000;13:203–6.
24. Abdo AA, Bain VG, Kichian K, et al. Evolution of autoimmune hepatitis to primary sclerosing cholangitis: A sequential syndrome. *Hepatology* 2002;36:1393–9.
25. Takiguchi J, Ohira H, Shishido S, et al. Autoimmune hepatitis overlapping with primary sclerosing cholangitis. *Int Med* 2002;41:696–700.
26. Bergquist A, Ekblom A, Olsson R, et al. Hepatic and extrahepatic malignancies in primary sclerosing cholangitis. *J Hepatol* 2002;36:321–7.
27. Boberg KM. Primary sclerosing cholangitis and cholangiocarcinoma. In: Bacon BR, Goodman ZD, Brunt EM, eds. *Liver disease in the 21st century: Clinico-pathologic correlates*. American Association for the study of Liver Diseases postgraduate course. 2003;172–7.