Reversed Gracilis Pedicle Flap for Coverage of a Total Knee Prosthesis*

By C. Tiengo, MD, V. Macchi, MD, E. Vigato, MD, A. Porzionato, MD, C. Stecco, MD, B. Azzena, MD, A. Morra, MD, and R. De Caro, MD

Investigation performed at the Section of Anatomy, Department of Human Anatomy and Physiology, School of Medicine, University of Padova, Padova, Italy

Background: Poor wound-healing and skin necrosis are potentially devastating complications after total knee arthroplasty. Primary soft-tissue coverage with a medial or lateral gastrocnemius transposition flap is typically the first choice for reconstruction. The aim of this study was to evaluate the use of a distally based secondary-pedicle flap of the gracilis muscle for reconstruction of a soft-tissue defect.

Methods: The characteristics of the distally based (secondary) pedicles of the gracilis muscle were studied with use of dissection (ten cadavers) and computed tomographic angiograms (fifty patients). On the basis of the anatomical features, an extended reversed gracilis flap based on the secondary pedicles was used in three patients with severe soft-tissue complications of total knee arthroplasty.

Results: The mean number of secondary pedicles was 1.8 (range, one to four). The pedicles originated from the superficial femoral or popliteal artery. The most proximal pedicle was often the largest (mean caliber, 2.0 mm), and its point of entry into the gracilis muscle was an average (and standard deviation) of 21 ± 3.6 cm (range, 16 to 28 cm) from the ischiopubic branch. A significant positive association ($p = 0.001$; $r^2 = 0.49$) was found between the caliber of the proximal secondary pedicle and the number of other secondary pedicles. In all three patients, the adequate caliber of the secondary pedicles (as shown on preoperative computed tomographic angiograms) and good muscle vascularization confirmed the utility of the gracilis as a distally based pedicle flap.

Conclusions: For the treatment of large soft-tissue defects of the patella or the proximal part of the knee, or for soft-tissue reconstruction over an exposed total knee prosthesis, the reversed gracilis pedicle flap may be an alternative to, or may be integrated with, a lateral or medial gastrocnemius flap.

Poor wound-healing and skin necrosis are potentially devastating complications after total knee arthroplasty[1,2]. Necrosis of the soft tissues about the knee can rapidly lead to deep infection at the site of the arthroplasty; the need to replace the prosthesis; or, in extreme cases, amputation[3]. Wound dehiscence, necrosis at the edge of longitudinal skin incisions, or total exposure of the prosthesis are very often due to poor vascularization of the skin secondary to the presence of multiple scars on the lateral and medial surfaces of the knee from prior operations[3-5]. While some authors have recommended free tissue transfers or pedicled fasciocutaneous flaps, such as an anterolateral thigh flap[6,7], for the treatment of periprosthetic infections of the knee[8], local muscle flaps are considered the most useful for reconstruction in cases of an exposed prosthesis. Primary soft-tissue coverage with a medial or lateral gastrocnemius transposition flap has become the primary reconstructive method of choice[5,9,10]. The proximally based gracilis and semimembranosus muscles have been used for supplemental coverage after detachment of their tendon distally[11].

The gracilis muscle has been used both as a free flap and as a proximally based pedicled flap, secondary to the adequacy of its proximal vascular pedicle and minimal associated morbidity[12,13]. A distally based gracilis muscle flap nourished by distal vascular pedicles has been proposed to cover areas of proximal tendon exposure in the knee[14].

*Presented at the Meeting of the Italian Society of Microsurgery, Milan, October 2007, and at the Winter Meeting of the British Association of Clinical Anatomists at King's College, London, December 2007.

Disclosure: The authors did not receive any outside funding or grants in support of their research for or preparation of this work. Neither they nor a member of their immediate families received payments or other benefits or a commitment or agreement to provide such benefits from a commercial entity.

In cases where a lateral or medial gastrocnemius flap is not available, or to treat large defects of the soft tissues in combination with the use of a gastrocnemius flap, we proposed the use of an extended reversed gracilis flap based on secondary pedicles (the GReSP flap) for the reconstruction of large defects of the knee. The purpose of this report is to describe anatomical features of the gracilis muscle on the basis of radiographic studies and dissections of cadaver thighs. We also present the preliminary clinical results in three patients in whom severe soft-tissue complications of total knee arthroplasty were treated with the GReSP flap.

Materials and Methods

Anatomical Study

Ten thighs of ten fresh cadavers (five male and five female) were studied. The external iliac artery was selectively injected with 200 mL of acrylic resin (Batson's #17 anatomical corrosion compound; Polysciences, Warrington, Pennsylvania), 1 cm above the inguinal ligament. The adductor region of the thigh was exposed through three skin incisions[15]. The skin was then reflected, and the superficial and deep fascia were removed, thus exposing the gracilis muscle and isolating its vascular pedicles. After polymerization of the resin (thirty minutes), the gracilis muscle and its vascular pedicles were sampled (Fig. 1).

Radiographic Study

Computed tomographic angiograms of fifty patients (forty male and ten female) were randomly selected from the archive of a diagnostic center. The patients had undergone computed tomography examination because of vascular abnormalities involving the abdominal aorta. Computed tomography images were obtained with a sixteen-slice multidetector computed tomography scanner (LightSpeed 16; GE Healthcare Milwaukee, Wisconsin) (2.5-mm slice thickness, 27.5-mm/rotation speed, 120 kV, and 300 mA). Analysis and post-processing of computed tomography scans was carried out on an Aquarius Workstation (version 3.6.2.3; TeraRecon, San Mateo, California).

Computed tomographic angiograms of both lower limbs were analyzed, with the investigator focusing on the anatomical features of the gracilis muscle (the length of the muscle and its muscle belly—i.e., the length without the tendons) and its secondary vascular pedicles.

We recorded the number, origin, course, caliber, and distance from the pubis to the entry point into the muscle of these vascular pedicles. Only secondary pedicles identified on computed tomographic angiograms and clearly directed toward the gracilis muscle were examined (Fig. 2). Results are expressed as mean values (and standard deviation) and ranges.

A linear regression test was used to look for a correlation between the caliber of the proximal secondary pedicle and the number of secondary pedicles and between the caliber of the proximal secondary pedicle and the length of the part of the gracilis muscle distal to the entry point of this pedicle (measured as the difference between the length of the whole muscle and the distance from the pubis to the entry point of the proximal secondary pedicle). $P < 0.05$ was considered significant.

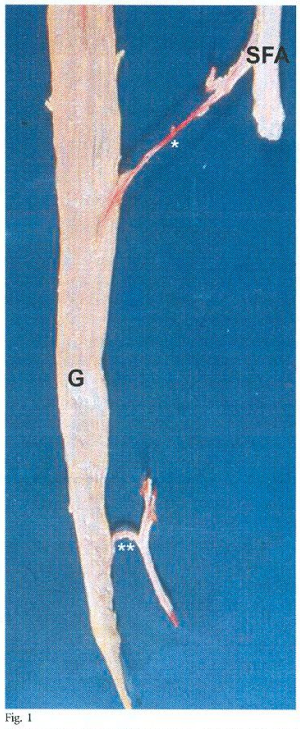

Fig. 1
Cadaver specimen of the gracilis muscle (G) after injection with acrylic resin. Note the secondary vascular pedicle (asterisk) originating from the superficial femoral artery (SFA) and another secondary pedicle (double asterisk) directed toward the distal part of the muscle.

Clinical Study

On the basis of the anatomical features, an extended reversed gracilis flap based on its secondary pedicles was used for three patients with severe soft-tissue complications of total knee arthroplasty. A preliminary computed tomographic angiogram was obtained to assess the adequacy of the secondary pedicle—i.e., the caliber of the proximal secondary pedicle had to be >2 mm and its distance from the ischiopubic attachment (pivot point) had to be adequate for the arc of rotation of the flap. All of the patients provided informed consent for the

TABLE I Demographic Data and Clinical Histories of the Patients, with Characteristics of the Secondary Pedicles of the Gracilis Muscles Derived from Computed Tomographic Angiograms

Case	Sex, Age *(yr)*	Indication for First Total Knee Arthroplasty	Complication	Removal of Total Knee Prosthesis	Antibiotic Therapy
1	M, 41	Trauma	Infection	Yes	Spacer
2	F, 72	Arthrosis	Infection	Yes	Spacer and intravenous
3	F, 45	Trauma	Infection	Yes	Spacer

surgical procedure. The demographic data and clinical histories of the patients are presented in Table I.

GReSP-Flap Surgical Technique

The patient was positioned supine, with the thigh abducted. The position of the gracilis muscle was identified by palpation, and the location of the main and secondary vascular pedicles, identified on the preoperative computed tomographic angiogram, were marked. A 10 to 15-cm sagittal skin incision was made at the anterior margin of the muscle, from the pubis to the location of the proximal secondary vascular pedicle, exposing the superficial aspect of the muscle. Particular attention was paid to the saphenous vein and nerve, which were protected (Fig. 3). Correspondence between the position of the vascular pedicles in the surgical field and that seen on the preoperative computed tomographic angiogram was verified. The muscular dissection was carried up to the entry point of the proximal secondary pedicle. The proximal tendon of the gracilis muscle was then transected to provide the maximal length for the muscle flap. The flap was then checked for perfusion, and the main vascular pedicle was clamped in order to verify that the blood supply to the proximal part of the

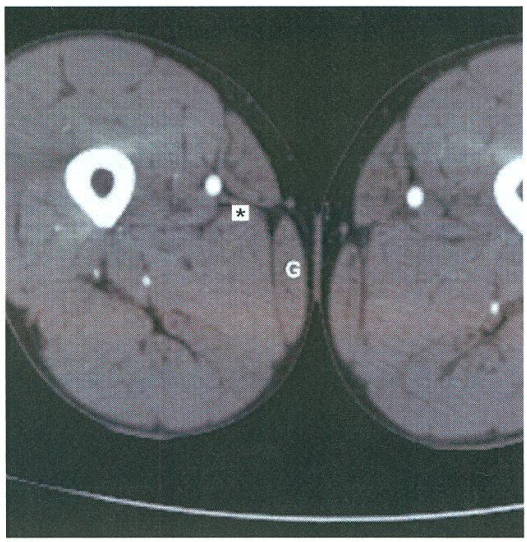

Fig. 2
Transverse section taken from a computed tomographic angiogram of a right lower limb. The gracilis muscle (G) is easily recognized, as is a secondary vascular pedicle (asterisk).

TABLE I (*continued*)

	Findings on Computed Tomographic Angiogram			Range of Motion *(deg)*	
Delay Until Reimplantation *(mo)*	No. of Secondary Pedicles	Caliber of Proximal Secondary Pedicle *(mm)*	Distance from Ischiopubic Attachment *(cm)*	Fixed Flexion Deformity	Arc of Flexion
6	2	2.2	22.5 and 25	10	70
5	2	2.1	25.5 and 29.7	10	75
4	2	2	24.5 and 30	10	65

muscle was sufficient when nourished only by the secondary pedicles. Then, the main neurovascular pedicles were ligated and transected. The muscle flap was reversed 180° and tunneled under the residual skin of the anterior aspect of the distal part of the thigh, in order to reach the exposed prosthesis. The proximal secondary pedicle was dissected as needed up to its origin from the superficial femoral artery, in order to achieve better mobility of the flap. The perfusion of the muscle was then evaluated intraoperatively with Doppler ultrasound, and the flap was sutured in place and covered with a split-thickness skin graft.

Source of Funding
There was no external source of funding for this study.

Results

The gracilis muscle was identified in all patients—i.e., both in the cadaver dissections and on the computed tomographic angiograms. The muscle had a mean length of 41 ± 2.1 cm (range, 37 to 45 cm) in the series as a whole, 42 ± 1.8 cm in males, and 39 ± 1.6 cm in females. The muscle belly had a fusiform shape, sagittally oriented in the medial aspect of the thigh. It had a mean length of 30 ± 2.1 cm (range, 27 to 34 cm) in the series, 31 ± 1.8 cm in males, and 28 ± 1.5 cm in females; a mean anteroposterior dimension of 44 ± 1 mm (43 ± 18 mm in males and 45 ± 15 mm in females), and a mean mediolateral dimension of 11 ± 2 mm (10 ± 18 mm in males and 13 ± 15 mm in females).

The anatomical dissections showed that the main pedicle contained one artery, two venae comitantes, and a branch of the obturator nerve, whereas the secondary pedicles had only one artery and venae comitantes, without a nerve (Fig. 1).

On the computed tomographic angiograms, each patient was seen to have at least one vascular pedicle distal to the main one. These secondary pedicles varied in number, with males having one to four (mean, 1.8) and females having one or two (mean, 1.5). These pedicles originated from the superficial femoral artery or the popliteal artery and reached the muscle by passing between the sartorius and the adductor longus muscle. The most proximal secondary vascular pedicle was often the largest, with a mean caliber of 2.0 mm (2.11 in males and 1.75 in females) (Fig. 2). A significant positive association ($p = 0.001$; $r^2 = 0.49$; slope [and standard error of the mean] = 1.1 ± 0.3 other pedicles/mm of proximal secondary pedicle caliber) was found between the caliber of this proximal secondary pedicle and the number of other secondary pedicles. An association also was documented between the caliber of this proximal secondary pedicle and the length of the part of the gracilis muscle distal to the entry point of this pedicle ($p = 0.05$; $r^2 = 0.23$; slope [and standard error of the mean] = 59 ± 28 mm of gracilis muscle/mm of proximal secondary pedicle caliber).

The distance between the entry point of the pedicle into the gracilis muscle and the pubis was a mean of 21 ± 3.6 cm (range, 16 to 28 cm) in the series as a whole, 22 ± 3.9 cm in males, and 18 ± 2.4 cm in females. When this point was considered in relation to the muscle length, it was found to be at the midpoint (as determined by dividing the entry point by the muscular length) and to be located between one-third and two-thirds of the muscle length in 95% of the cases.

Other distal secondary pedicles, when present, were smaller, arose from the superficial femoral artery or popliteal artery, and reached the distal part of the muscle belly, or its distal tendon, at a mean distance of 26 ± 2.7 cm (27 ± 0.9 cm in males and 26 ± 1.4 cm in females) from the pubis.

Clinical Study (Table I)

Case 1 (Fig. 4)

Seven days after delayed reimplantation of a knee prosthesis and contemporary reconstruction of the capsule and patellar tendon with use of an artificial polyethylene terephthalate tendon implant, the patient developed a large necrotic area of skin over the anterior surface of the knee. Surgical debridement completely exposed the prosthetic tendon and prosthetic implants.

After extensive debridement of the prosthesis, a medial gastrocnemius muscle flap nourished by the ipsilateral sural vascular pedicle was transposed to cover the distal portion of the defect. Because of the insufficient coverage by the medial gastrocnemius flap, a GReSP flap was developed and tunneled under the anteromedial skin of the thigh to reconstruct the proximal half of the defect. A skin graft was applied to the muscle surface, and the knee was immobilized with a rigid orthosis.

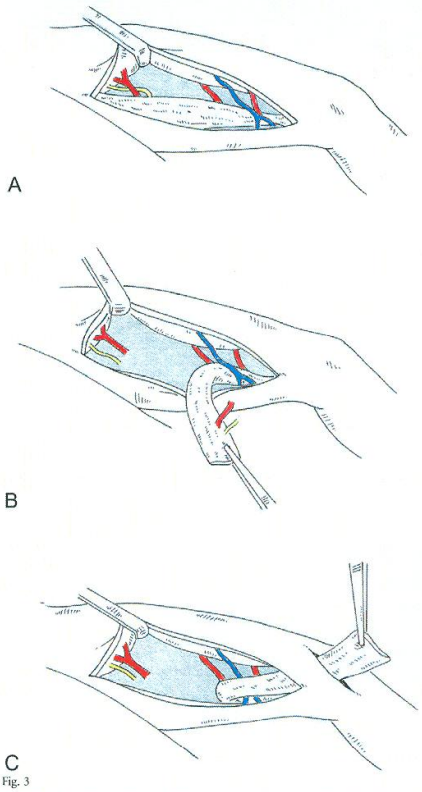

Fig. 3

The gracilis muscle belly is depicted during its mobilization as a reversed flap based on its secondary pedicles. *A:* Relationships of the skin incision, the gracilis muscle belly, and the motor branch of the obturator nerve (yellow), the saphenous vein (blue), and the vascular pedicles (red and blue). *B:* The muscular dissection is carried to the entry of the proximal secondary pedicle. The proximal tendon of the gracilis muscle is then transected to provide the maximal length for the muscle flap. After adequate blood flow is confirmed, the main vascular and nervous pedicles are ligated. *C:* The muscle flap is reversed 180° and tunneled under the residual skin of the anterior aspect of the distal part of the thigh, in order to reach the exposed prosthesis.

Systemic antibiotic therapy was administered for two weeks after the surgical procedure. The skin graft survived completely, with the flap being fully viable. Evaluation at twenty-two months revealed stability of the reconstruction without evidence of infection.

Case 2

Ten days after delayed reimplantation of a knee prosthesis, the paramedian skin incision developed a central dehiscence, with necrosis at the skin edges. Surgical debridement exposed a partially necrotic patellofemoral tendon and the prosthetic implant on the anterior aspect of the knee.

The gracilis muscle flap was mobilized and tunneled under the anteromedial skin of the thigh. The flap survived completely, and the patient was discharged after two weeks to begin physiotherapy. Systemic antibiotic therapy was administered for two weeks after the surgical procedure. At twenty-four months, complete soft-tissue healing had occurred.

Case 3

Six months after delayed reimplantation of a knee prosthesis, secondary stiffness of the knee joint prompted surgical revision to improve the range of motion. The patient developed a large area of necrotic skin over the anterior aspect of the knee. An irregular, oval 4 × 10-cm ulcer, oriented along the axis of the limb, was present on the anterolateral surface of the knee, exposing the patellar tendon and the total knee prosthesis. Following debridement, a GReSP flap was used to cover the defect, and the knee was immobilized with a rigid orthosis. Systemic antibiotic therapy was administered for two weeks after the surgical procedure. At twenty-four months, the soft tissues were healed without evidence of infection.

Discussion

Skin necrosis following total knee arthroplasty is a serious complication and one of the most difficult challenges for surgeons who perform knee joint reconstructions. Early reconstructive intervention is the best way to reduce the risk of deep infection, removal of the prosthetic implant, or amputation[16-18]. The presence of multiple scars over the knee surface and related poor skin vascularization often necessitate the use of a pedicled muscle flap from the leg[19,20] to cover such lesions, instead of using local fasciocutaneous flaps or tissue expanders[21]. The gracilis muscle has often been used as a free and proximally based pedicled flap[20,22-25]. We believe that the use of the gracilis muscle as a distally based flap nourished by secondary vascular pedicles can be an effective alternative, or addition, to a medial or lateral gastrocnemius flap.

We are not aware of any reports regarding the use of the gracilis muscle based solely on its distal pedicles for the treatment of extensive soft-tissue defects of the knee. Recently, Cavadas et al.[14] presented the preliminary clinical results of the use of a reversed gracilis muscle flap in two patients with small defects of the quadriceps tendon, but the gracilis muscle reached only the suprapatellar region.

Only a few studies have focused on the secondary vascular pedicles originating from the superficial femoral artery or the popliteal artery[26]. The number of these pedicles has been reported to range between one and five[27,28]. In our study, the number ranged from one to four, with a mean of 1.8. Taylor et al.[25] reported that the mean caliber of the proximal secondary

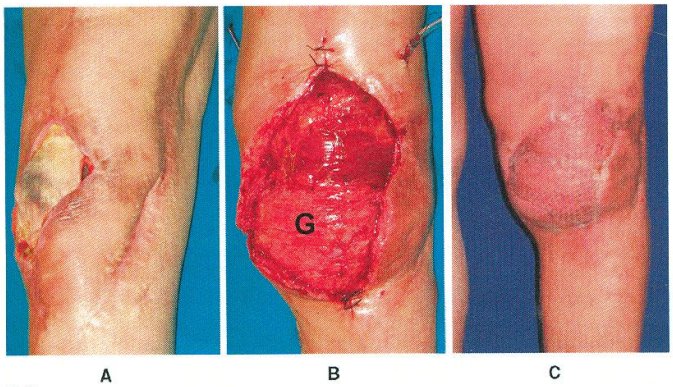

Fig. 4

Case 1. A forty-one-year-old man developed a large necrotic area of skin over the anterior surface of the knee seven days after delayed reimplantation of a knee prosthesis and a polyethylene terephthalate tendon implant. *A:* Surgical debridement completely exposed the prosthetic tendon and prosthetic implants. *B:* The distal portion of the defect was covered with a gastrocnemius pedicle flap and the gracilis (G) muscle flap was used to reconstruct the proximal half of the defect. *C:* Four months later, there was complete soft-tissue healing without evidence of infection.

vascular pedicle was 1.1 mm, whereas in our study it was 2.0 mm. This difference may be due to the fact that the study by Taylor et al. was based only on cadaver dissection, while our study included living patients who had undergone computed tomographic angiography.

The positive association between the caliber of the proximal secondary pedicle and the number of secondary pedicles confirms the importance of this pedicle in nourishing the gracilis muscle, especially its distal portion. A significant association between the caliber of this artery and the length of the muscle belly distal to the entry point of the pedicle was also found.

It should be noted that both Taylor et al.[25] and Cavadas et al.[14] demonstrated extensive intramuscular connections between the dominant and secondary pedicles through angiographic study of the gracilis muscle. In particular, Cavadas et al. showed that the proximal secondary pedicle usually divides into two branches, one ascending branch that anastomoses to descending branches of the dominant pedicle and a lesser descending branch that anastomoses to the distal secondary pedicle, with consequent retrograde flow. These observations suggest the importance of the secondary pedicles in nourishing not only the distal part of the muscle, but also the proximal part, which is classically considered to be perfused only by the main vascular pedicle. The mean 2-mm caliber of the secondary pedicles and the good vascularization of the muscle demonstrated intraoperatively after clamping of the principal pedicle in all three of our patients confirmed the feasibility of using the gracilis as a distally based pedicled flap.

In the study by Taylor et al.[25], the mean entry point of the proximal secondary vascular pedicle into the muscle was 21.8 cm from the ischiopubic branch. In our study, the pedicle was located at a mean of 21 ± 3.6 cm from the proximal insertion of the muscle, and a more distal secondary vascular pedicle, which was usually present, was found at a mean of 26 ± 2.7 cm. The distance of the proximal secondary pedicle from the ischiopubic branch represents the length of the muscle belly that is suitable for rotation and transposition as a muscular flap—i.e., it represents its pivot point. It is important to determine this distance preoperatively with computed tomographic angiography when a large, or very distal, defect must be covered, in order to ensure adequate length of the pedicle flap. To enhance rotation of the muscle, we suggest careful release of the secondary pedicle as far as the superficial femoral artery.

Multidetector computed tomographic angiography has emerged as a noninvasive operator-independent choice for evaluating the location and size of small vessels[29-33]. Our radiographic study shows that computed tomographic angiography is a useful, noninvasive preoperative tool, which can supply detailed information on each patient. These findings assist the surgeon in selecting patients for whom this kind of flap is suitable, providing a detailed description of the patient's vascular anatomy, and minimizing the time of operative dissection.

From these studies, we can conclude that the GReSP flap may be considered as an alternative, or an addition, to a gastrocnemius flap for soft-tissue reconstruction over an

exposed total knee prosthesis in patients with suitable vascular anatomy as evaluated with computed tomographic angiography. ■

NOTE: The authors are grateful to Gloria Sarasin and Anna Rambaldo for their skillful technical assistance. The authors also thank Euganea Medica for the radiographic study.

C. Tiengo, MD
V. Macchi, MD
E. Vigato, MD
A. Porzionato, MD
C. Stecco, MD
B. Azzena, MD
A. Morra, MD
R. De Caro, MD
Section of Anatomy,
Department of Human Anatomy and Physiology,
School of Medicine,
University of Padova,
Via A Gabelli 65, 35127 Padova, Italy.
E-mail address for C. Tiengo: tiengo@iname.com.
E-mail address for V. Macchi: veronica.macchi@unipd.it.
E-mail address for E. Vigato: enricovigato@yahoo.it.
E-mail address for A. Porzionato: andrea.porzionato@unipd.it.
E-mail address for C. Stecco: carla.stecco@unipd.it.
E-mail address for B. Azzena: bruno.azzena@sanita.padova.it.
E-mail address for A. Morra: aldo.morra@euganeamedica.it.
E-mail address for R. De Caro: rdecaro@unipd.it

References

1. Galat DD, McGovern SC, Larson DR, Harrington JR, Hanssen AD, Clarke HD. Surgical treatment of early wound complications following primary total knee arthroplasty. J Bone Joint Surg Am. 2009;91:48-54.

2. Vince K, Chivas D, Droll KP. Wound complications after total knee arthroplasty. J Arthroplasty. 2007;22(4 Suppl 1):39-44.

3. Ries MD, Bozic KJ. Medial gastrocnemius flap coverage for treatment of skin necrosis after total knee arthroplasty. Clin Orthop Relat Res. 2006;446:186-92.

4. Casanova D, Hulard O, Zalta R, Bardot J, Magalon G. Management of wounds of exposed or infected knee prostheses. Scand J Plast Reconstr Surg Hand Surg. 2001;35:71-7.

5. Nahabedian MY, Mont MA, Orlando JC, Delanois RE, Hungerford DS. Operative management and outcome of complex wounds following total knee arthroplasty. Plast Reconstr Surg. 1999;104:1688-97.

6. Gravvanis AI, Tsoutsos DA, Karakitsos D, Panayotou P, Iconomou T, Zografos G, Karabinis A, Papadopoulos O. Application of the pedicled anterolateral thigh flap to defects from the pelvis to the knee. Microsurgery. 2006;26:432-8.

7. Kuo YR, An PC, Kuo MH, Kueh NS, Yao SF, Jeng SF. Reconstruction of knee joint soft tissue and patellar tendon defects using a composite anterolateral thigh flap with vascularized fascia lata. J Plast Reconstr Aesthet Surg. 2008;61:195-9.

8. Manoso MW, Boland PJ, Healey JH, Cordeiro PG. Limb salvage of infected knee reconstructions for cancer with staged revision and free tissue transfer. Ann Plast Surg. 2006;56:532-5.

9. Jaureguito JW, Dubois CM, Smith SR, Gottlieb LJ, Finn HA. Medial gastrocnemius transposition flap for the treatment of disruption of the extensor mechanism after total knee arthroplasty. J Bone Joint Surg Am. 1997;79:866-73.

10. Menderes A, Demirdover C, Yilmaz M, Vayvada H, Barutcu A. Reconstruction of soft tissue defects following total knee arthroplasty. Knee. 2002;9:215-9.

11. Chim H, Tan BK, Tan MH, Tan KC, Song C. Optimizing the use of local muscle flaps for knee megaprosthesis coverage. Ann Plast Surg. 2007;59:398-403.

12. Whetzel TP, Lechtman AN. The gracilis myofasciocutaneous flap: vascular anatomy and clinical application. Plast Reconstr Surg. 1997;99:1642-55.

13. Hasen KV, Gallegos ML, Dumanian GA. Extended approach to the vascular pedicle of the gracilis muscle flap: anatomical and clinical study. Plast Reconstr Surg. 2003;111:2203-8.

14. Cavadas PC, Sanz-Giménez-Rico JR, Landín L, Martínez-Soriano F. Segmental gracilis free flap based on secondary pedicles: anatomical study and clinical series. Plast Reconstr Surg. 2004;114:684-91.

15. Jacobs JJ, editor. Shearer's manual of human dissection. 7th ed. New York: McGraw-Hill; 1989.

16. Vince KG, Abdeen A. Wound problems in total knee arthroplasty. Clin Orthop Relat Res. 2006;452:88-90.

17. Galat DD, McGovern SC, Hanssen AD, Larson DR, Harrington JR, Clarke HD. Early return to surgery for evacuation of a postoperative hematoma after primary total knee arthroplasty. J Bone Joint Surg Am. 2008;90:2331-6.

18. Jämsen E, Huhtala H, Puolakka T, Moilanen T. Risk factors for infection after knee arthroplasty. A register-based analysis of 43,149 cases. J Bone Joint Surg Am. 2009;91:38-47.

19. Misra A, Niranjan NS. Fasciocutaneous flaps based on fascial feeder and perforator vessels for defects in the patellar and peripatellar regions. Plast Reconstr Surg. 2005;115:1625-32.

20. Boopalan PR, Daniel AJ, Chittaranjan SB. Managing skin necrosis and prosthesis subluxation after total knee arthroplasty. J Arthroplasty. 2009;24:322.e23-7.

21. Manifold SG, Cushner FD, Craig-Scott S, Scott WN. Long-term results of total knee arthroplasty after the use of soft tissue expanders. Clin Orthop Relat Res. 2000;380:133-9.

22. Harii K, Ohmori K, Torii S. Free gracilis muscle transplantation, with microneurovascular anastomoses for the treatment of facial paralysis. A preliminary report. Plast Reconstr Surg. 1976;57:133-43.

23. Juricic M, Vaysse P, Guitard J, Moscovici J, Becue J, Juskiewenski S. Anatomic basis for use of a gracilis muscle flap. Surg Radiol Anat. 1993;15:163-8.

24. Sukkar SM, Daw JA, Chandler J, Dumanian GA. Gracilis muscle free flap transfer using a radial artery/venae comitantes composite vascular pedicle. Plast Reconstr Surg. 2001;108:156-61.

25. Taylor GI, Cichowitz A, Ang SG, Seneviratne S, Ashton M. Comparative anatomical study of the gracilis and coracobrachialis muscles: implications for facial reanimation. Plast Reconstr Surg. 2003;112:20-30.

26. Giordano PA, Abbes M, Pequignot JP. Gracilis blood supply: anatomical and clinical re-evaluation. Br J Plast Surg. 1990;43:266-72.

27. Morris SF, Yang D. Gracilis muscle: arterial and neural basis for its subdivision. Ann Plast Surg. 1999;42:630-3.

28. Coquerel-Beghin D, Milliez PY, Auquit-Auckbur I, Lemierre G, Duparc F. The gracilis musculocutaneous flap: vascular supply of the muscle and skin components. Surg Radiol Anat. 2006;28:588-95.

29. Alonso-Burgos A, García-Tutor E, Bastarrika G, Cano D, Martínez-Cuesta A, Pina LJ. Preoperative planning of deep inferior epigastric artery perforator flap reconstruction with multislice-CT angiography: imaging findings and initial experience. J Plast Reconstr Aesthet Surg. 2006;59:585-93.

30. Masia J, Clavero JA, Larrañaga JR, Alomar X, Pons G, Serret P. Multidetector-row computed tomography in the planning of abdominal perforator flaps. J Plast Reconstr Aesthet Surg. 2006;59:594-9.

31. Ribuffo D, Atzeni M, Corrias F, Guerra M, Saba L, Sias A, Balestrieri A, Mallarini G. Preoperative Angio-CT preliminary study of the TRAM flap after selective vascular delay. Ann Plast Surg. 2007;59:611-6.

32. Rozen WM, Palmer KP, Suami H, Pan WR, Ashton MW, Corlett RJ, Taylor GI. The DIEA branching pattern and its relationship to perforators: the importance of preoperative computed tomographic angiography for DIEA perforator flaps. Plast Reconstr Surg. 2008;121:367-73.

33. Rozen WM, Ashton MW, Grinsell D, Stella DL, Phillips TJ, Taylor GI. Establishing the case for CT angiography in the preoperative imaging of abdominal wall perforators. Microsurgery. 2008;28:306-13.