

LENGTHENING OF THE LOWER LIMBS IN ACHONDROPLASTIC PATIENTS

A COMPARATIVE STUDY OF FOUR TECHNIQUES

ROBERTO ALDEGHERI, GIAMPAOLO TRIVELLA, LODOVICO RENZI-BRIVIO, GIULIO TESSARI,
SAULO AGOSTINI, FRANCO LAVINI

From the University of Verona

We report our experience of lengthening by over 30% a total of 117 lower limbs in achondroplastic patients. We have compared four methods: transverse osteotomy, oblique osteotomy, callotasis of the shaft and chondrodiatasis of the epiphysis. Chondrodiatasis of the femur and callotasis of the tibia are the techniques which gave fewest complications.

Bilateral lengthening of the lower limbs of short-statured patients is a relatively new development in orthopaedic surgery. It is performed in a few orthopaedic centres for certain forms of disproportionate dwarfism. These include the Institute of Surgery, Kurgansk, USSR (Ilizarov, Deviatov and Trokhova 1972); the University Department of Orthopaedics at Ljubiana in Yugoslavia (Baebler and Srakar 1984), the Chairn Shaba Medical Centre, Tel Nashomen, Israel (Ganel et al. 1979), the Sophies Minde Orthopaedic Hospital, Oslo, Norway (Bjerkreim and Steen 1984), and at the G. Gaslini Institute, Genoa (Mastragostino, Bagliani and Maggiani 1980) and the Institute of Clinical Orthopaedics, University of Verona (De Bastiani et al. 1986, 1987) in Italy.

Pathological short stature is not very rare; it occurs in 5 per 1000 of the Italian population (Bonati et al. 1983). About 50% of patients of exceptionally short stature have a constitutional abnormality; 4.4% of these patients have osteochondrodysplasias, of which 70% are achondroplastic (Morabito 1980). Achondroplastic and hypochondroplastic patients are the most appropriate candidates for bilateral symmetrical leg-lengthening.

Achondroplasia is characterised by micromelic dwarfism, in which the muscular system is well-developed and intelligence and general health are usually

normal. In a previous publication (Aldegheri, Tessari and Lavini 1986) we have considered the physical, emotional, and social problems faced by these patients, and discussed the cosmetic, psychological and functional reasons which justify lengthening operations. In this paper we present our clinical results.

PATIENTS AND METHODS

We have reviewed 72 patients, 61 with achondroplasia and 11 with hypochondroplasia, treated between 1981 and 1985. Three patients treated during this period were excluded from the analysis; one continued treatment at another centre after the lengthening of the first limb, and two were operated on using combined techniques. Their exclusion does not affect the statistical significance of the series.

There were 33 males and 39 females, with an initial height between 112 cm and 142 cm. Lengthening of the femur and tibia of the same limb simultaneously (longitudinal lengthening) was performed in all cases because it was better tolerated than simultaneous operations on both femora or both tibiae (transverse lengthening). Major lengthening of one limb allows greater independent mobility during treatment, provides earlier evidence of progress and obliges the patient to continue with the lengthening of the other limb. In the event of any complication, the patient can continue to walk and bear weight on the unoperated limb.

The first operation was performed after a period of time as an inpatient in either the Institute of Clinical Orthopaedics, Verona, or the Italian Auxological Institute, Piancavallo (Morabito 1980). This allowed time for the investigation of the psychological and emotional state of the patient and his family, and for pre-operative physiotherapy. Detailed information was obtained from which to ensure satisfactory patient

R. Aldegheri, MD, First Assistant
G. Trivella, MD, Assistant
L. Renzi-Brivio, MD, Assistant
G. Tessari, MD, Assistant
S. Agostini, MD, Assistant
F. Lavini, MD, Assistant
Institute of Clinical Orthopaedics and Traumatology, University of Verona, Policlinico Borgo Roma, 37134 Verona, Italy.

Requests for reprints should be sent to Dr R. Aldegheri.

© 1988 British Editorial Society of Bone and Joint Surgery
0301-620X/88/1024 \$2.00
J Bone Joint Surg [Br] 1988;70-B:69-73.

selection and plan the most suitable programme of management.

After operation, once the patient could walk with crutches, he returned home to attend school and continue normal activities. If the family circumstances were unsuitable he was transferred to the Institute at Piancavallo where school and functional rehabilitation was available. Review after operation did not normally require admission, except when an external fixator was due to be removed; this was done after one or two weeks in hospital.

The second limb was lengthened at least six months after complete healing of the first, by which time that limb had regained good function (Fig. 1). At the time of this report 45 patients had completed lengthening of both lower limbs, and 27 had completed lengthening of the right leg only. We therefore report 117 limb lengthenings, or 234 bone lengthenings in femur or tibia.

Four different operative techniques were used:

1. Transverse osteotomy of the mid-shaft of the bone (Aldegheri, De Bastiani and Renzi-Brivio 1985), distraction by 1 mm per day and removal of the distraction system at consolidation in the femur and tibia of six limbs.
2. Oblique osteotomy of the shaft of the bone (Aldegheri et al. 1985), distraction by 1.5 cm per week and removal of the distraction system at consolidation in 10 limbs.
3. Callotasis of the shaft of the bone (De Bastiani et al. 1987) in 49 limbs.
4. Chondrodiatasis of the epiphyses (De Bastiani et al. 1986) in 52 limbs.

At all operations, either an Orthofix axial lengthener or a dynamic axial fixator (De Bastiani, Aldegheri and Renzi-Brivio 1979) was used because of the advantages described by De Bastiani et al. (1979, 1986). Results were assessed by the following parameters: the age of the patient; the number of centimetres of lengthening and the percentage of lengthening in relation to the initial length of the bone; the healing index (Aldegheri et al. 1985), that is, the number of treatment days required to obtain 1 cm of lengthening; and the number and percentage of complications.

RESULTS

The mean age of the 72 patients at the time of the first operation was 15 years (range 9 to 29 years).

Lengthening. The mean lengthening obtained in each limb was 15.1 cm (32.6%); 7.8 cm (29.6%) was obtained in the femora and 7.3 cm (35.5%) in the tibiae. The maximum percentage achieved in the femur was 52.5% and in the tibia 58%.

In all cases, the lengthening planned before operation was achieved precisely. This had been calculated on the basis of the ratios between the length of the trunk and the length of the lower limbs, and between the length

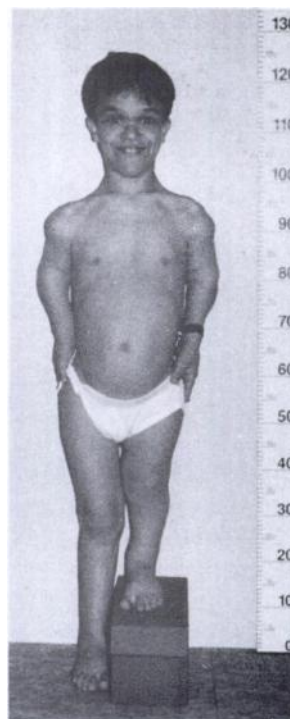


Fig. 1

An achondroplastic boy of 12 years after lengthening of one leg by 16 cm, before the operations on the other side.

of the femur and the length of the tibia. The lengthening we obtained restored these ratios to normal. For those who had completed treatment of both legs, the mean height was 117 cm before operation and 135 cm afterwards.

Healing index. The mean healing time for each limb was 10.3 months; the healing index was 40.76 days/cm for the femur and 42.05 days/cm for the tibia.

Complications. The total number of complications was 47 – that is, in 20% of the 234 segments; 15 occurred in 117 femora (12.8%) and 32 in 117 tibiae (27.4%).

Pseudarthrosis (2.6%) occurred four times after transverse osteotomy (one femur, three tibiae) and twice after oblique osteotomy (one femur, one tibia). In these cases there was no spontaneous formation of bone.

Dislocation of the hip occurred in one case (0.4%) with a dysplastic joint after an oblique osteotomy of the femur.

Fractures after too early removal of the fixator (5.6%), occurred in two cases after oblique osteotomy of the femur, in three after callotasis (two femora and one tibia) and in eight cases after chondrodiatasis (two femora and six tibiae).

Migration of the lateral malleolus at the ankle (9.4%) caused by early fusion of the fibular osteotomy occurred in three cases during callotasis and eight during chondrodiatasis. This may have been due to inadequate resection of a segment of fibula and subsequent relative instability of the distal tibiofibular syndesmosis. The higher incidence during chondrodiatasis is thought to be due to the fact that it was technically difficult to engage the fibula with the posterior epiphyseal screw and ensure

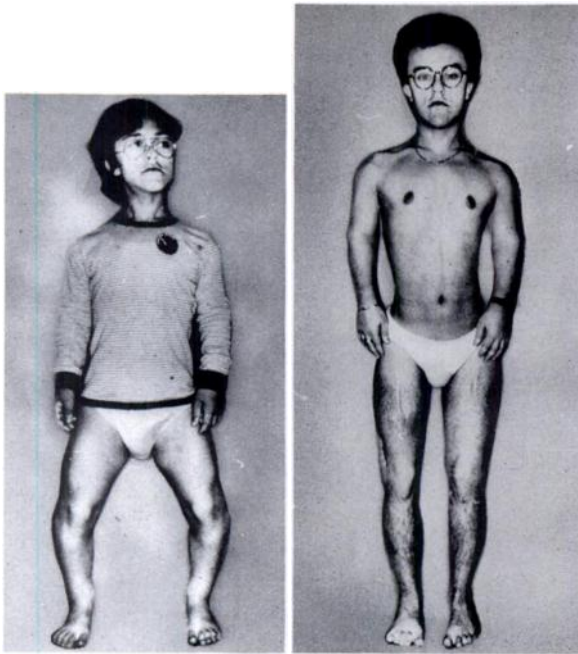


Fig. 2

Clinical appearance before and after bilateral leg-lengthening by 18 cm.

between the femur and the tibia in transverse osteotomy, oblique osteotomy and chondrodiatasis. In transverse osteotomy 16% of complications occurred in the femur and 50% in the tibia. In oblique osteotomy 40% of complications occurred in the femur and 10% in the tibia. In chondrodiatasis 5.8% of complications occurred in the femur and 42.3% in the tibia. Callotasis was the only technique in which the percentage of complications was similar in the femur (14.3%) and the tibia (12.2%).

Lengthening of the lower limbs gave a satisfactory result in all patients as regards appearance (Figs 2 and 3) and an improved psychological and emotional state, even when complications delayed the completion of treatment. Our aim was to restore a normal ratio between the length of the trunk and the length of the lower limbs; the mean lengthening (32.5%) achieved does restore this ratio. We considered that greater lengthening would result in an inverse disproportion between length of trunk and lower limbs and make it even more difficult, with short upper limbs, for the hands to reach the feet. Although lengthening of the upper limbs is possible, we do not favour it, since the defect is mainly one of appearance. This does not justify surgical treatment in the absence of functional difficulties.

DISCUSSION

Although the numbers of patients treated by each of the ways of lengthening and their ages at operation were not uniform, we believe that some useful conclusions can be drawn.

Transverse and oblique osteotomies involve more

extensive surgery than the other two methods of lengthening and are subject to more complications, particularly the serious one of non-union. We have now abandoned these techniques in favour of the better and more reliable results obtained by callotasis and chondrodiatasis.

We based selection between callotasis and chondrodiatasis on the age of the patient, the morphology of the bony segments and the presence of angular deformity. Callotasis is the preferred method in the tibia, in which the distal epiphysis is often thin and irregular. This makes the insertion of the fixator pins for chondrodiatasis difficult and engagement of the fibular epiphysis may give problems at the tibiofibular syndesmosis. The presence of varus deformity of the upper end of the tibia also favours callotasis.

In the femur, the choice is more difficult. Chondrodiatasis and callotasis showed similar healing indices over similar lengthenings, but chondrodiatasis had a smaller number of complications. This favours its use when the epiphyses are still open, though it should be noted that the growth-plate closes earlier in achondroplastic than in normal children. We believe that, where possible, lengthening should be completed before the onset of adolescence, at which time social and emotional factors play their greatest role. But we do not advocate operating before the age of nine or 10 years; a younger child cannot give full and active co-operation and the burden on the parents is correspondingly greater. These considerations limit the technique to the age of 11 or 12

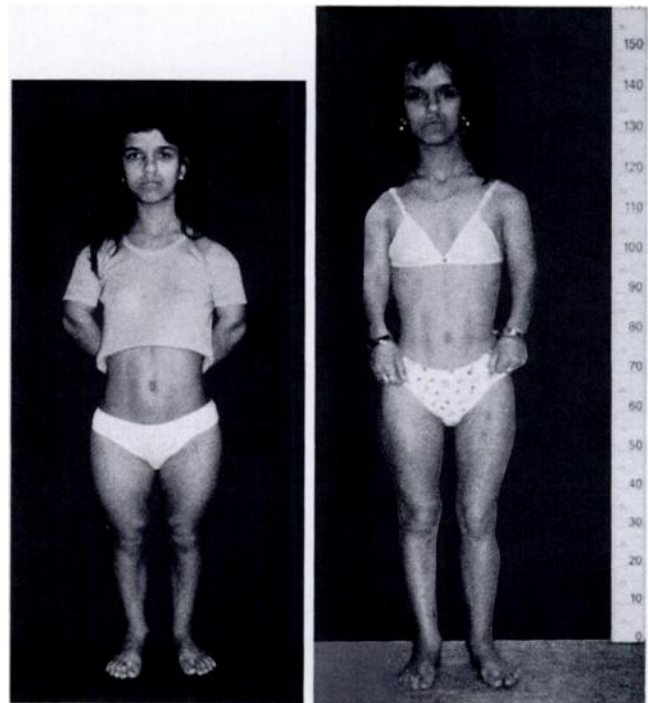


Fig. 3

Achondroplastic girl aged 16 years, before and after lengthening by 18 cm of both lower limbs. There is an improvement of proportion between trunk and limbs and an adequate increase in height.

Table I. Results and complications of lengthening operations on 117 femora

Technique	Number	Mean age (years)	Lengthening		Healing index (days/cm)	Complications	
			cm	per cent		Number	Type
Transverse osteotomy	6	18.6	7.0	24.5	51	1	Pseudarthrosis
Oblique osteotomy	10	19.2	8.4	33.6	39	4	Fracture (2) Pseudarthrosis Hip subluxation
Callotasis	49	16.7	7.8	26.0	37	7	Fracture (2) Fusion of osteotomy (3) Screw osteolysis (2)
Chondrodiatasis	52	11.8	7.7	33.0	44	3	Fracture (2) Unstable fixator

Table II. Results and complications of lengthening operations on 117 tibiae

Technique	Number	Age (years)	Lengthening		Healing index (days/cm)	Complications	
			cm	per cent		Number	Type
Transverse osteotomy	6	18.6	7.1	32.5	49	3	Pseudarthrosis
Oblique osteotomy	10	19.2	6.8	39.4	50	1	Pseudarthrosis
Callotasis	49	16.7	7.6	34.0	41	6	Fusion of fibula (3) Fracture Screw osteolysis Fusion of osteotomy
Chondrodiatasis	52	11.8	7.2	36.3	40	22	Fusion of fibula (8) Fracture (6) Axial deviation (4) Screw osteolysis (2) Unstable fixator (2)

that the distal segment of the fibula moved together with the distal epiphysis of the tibia. Early union of the fibula resulting in deformity of the ankle occurred in four cases after chondrodiatasis (3.4%).

Osteolysis around screws (2.3%) occurred in three cases of callotasis (two femora and one tibia) and in two of chondrodiatasis (two tibiae). Instability of the fixator (1.3%) was seen only during chondrodiatasis (one femur and two tibiae) as the other techniques make use of a rigid lengthener which precludes this possibility.

Occasionally, equinus deformity of the ankle, flexion deformity of the hip and transitory inflammation of screw-tracks were seen. These have not been included as complications, since they were rare and did not affect the final result. Tenotomy of the calcaneal tendon was needed for six patients in whom physiotherapy, weight-bearing and functional rehabilitation had not been adequate. Tenotomy of the iliopsoas and the adductors was needed twice during distraction treatment to correct flexion-adduction of the hip. This occurred in two achondroplastic patients with severe lumbar hyperlordosis. Inflammation of the skin and muscle around the femoral screws always resolved with rest and local antibiotics.

Comparison of the four methods of lengthening. The detailed results are related to the four methods of lengthening in Tables I and II.

After *transverse mid-shaft osteotomy*, mean lengthening was 28.5%, the healing index was 50, and the complication rate was 33.3%. After *oblique shaft osteotomy*, mean lengthening was 36.5%, the healing index was 44.5, and the complication rate was 25%. With *callotasis*, mean lengthening was 30%, the healing index was 39, and the complication rate was 13.3%. With *chondrodiatasis*, mean lengthening was 34.7%, the healing index was 42 and the complication rate was 24%. The greatest percentage of mean lengthening was obtained with oblique osteotomy of the tibial shaft (39.4%).

The lowest *healing index* was in callotasis of the femur (37) and the highest in transverse osteotomy of the femur (51). This index varied with the technique of operation and was different in the femur and the tibia; it was not affected by the age of the patient or the extent of percentage lengthening.

The lowest percentage of *complications* was obtained for chondrodiatasis of the femur (5.8%) and the highest for chondrodiatasis of the tibia (42.3%). There was a significant difference in the rate of complications

years, when either method can be used. For older children with fused epiphyses, callotasis of the femur and tibia is the recommended method.

The authors wish to thank their mentor, Professor G. De Bastiani, for his unfailing encouragement and perceptive teaching in this branch of surgery. They would also like to pay particular thanks to Professor W. J. W. Sharrard for his co-operation not only in relation to surgical protocol but also for revising the data and helping to prepare this paper.

REFERENCES

- Aldegheri R, De Bastiani G, Renzi-Brivio L.** Allungamento diafisario dell'arto inferiore (studio di 78 casi). *Chir Organi Mov* 1985;70:111-9. (Eng. Abstr.)
- Aldegheri R, Tessari G, Lavini F.** Aspetti psicologici e relazionali dell'acondroplasia sottoposto ad allungamento degli arti inferiori. *Acta Paediatr Latina* 1986;39:106-15.
- Baebler B, Srakar F.** Elongation of the shaft of the long bones at the University Orthopaedic Hospital in Ljubljana from 1963 to 1982. In: *Leg Length Inequality*, International Orthopaedic Symposium, Utrecht, 1984:6.
- Bjerkreim J, Steen H.** Bilateral lengthening of the lower limbs in short stature. In: *Leg Length Inequality*, International Orthopaedic Symposium, Utrecht, 1984:42a.
- Bonati B, Morabito F, Della Casa L, Nicoletti I.** La clinica dei nanismi e delle ipostaturalità. In: Bonati B, ed. *Difetti dell'accrescimento staturale*. Rome: Edizioni L. Pozzi, 1983:55-74.
- De Bastiani G, Aldegheri R, Renzi-Brivio L.** Fissatore esterno assiale. *Chir Organi Mov* 1979;65:287-93.
- De Bastiani G, Aldegheri R, Renzi-Brivio L, Trivella G.** Chondrodiatasis - controlled symmetrical distraction of the epiphyseal plate: limb lengthening in children. *J Bone Joint Surg [Br]* 1986;68-B:550-6.
- De Bastiani G, Aldegheri R, Renzi-Brivio L, Trivella G.** Limb lengthening by callus distraction (callotasis). *J Pediatr Orthop* 1987;7:129-34.
- Ganel A, Horoszowski H, Kamhin M, Farine I.** Leg lengthening in achondroplastic children. *Clin Orthop* 1979;144:194-7.
- Ilizarov GA, Deviatov AA, Trokhova VG.** Operativnoi udlinenie ukorochennoi nizhnef konechnosti. *Vesn Khir* 1972;107:100-3.
- Mastragostino S, Bagliani GP, Maggiani M.** Nanismi disarmonici ed allungamento chirurgico. In: *Atti del simposio sull'acondroplasia*, Stresa 1980. Milano: Centro Auxologico Italiano, 1980:65-80.
- Morabito F.** Introduzione al simposio. In: *Atti del simposio sull'acondroplasia*, Stresa 1980. Milano: Centro Auxologico Italiano, 1980:3-11.