

Queries for attr-48-01-11

This manuscript/text has been typeset from the submitted material. Please check this proof carefully to make sure there have been no font conversion errors or inadvertent formatting errors. Allen Press.

Pneumomediastinum and Pneumopericardium in an 11-Year-Old Rugby Player: A Case Report

Valentina Vanzo, MD; Samuela Bugin, MD; Deborah Snijders, MD; Laura Bottecchia, MD; Veronica Storer, MD; Angelo Barbato, MD

Department of Pediatrics, University of Padova, Italy

Objective: Pneumomediastinum and pneumopericardium are rare occurrences in young athletes, but they can result in potentially life-threatening consequences.

Background: While involved in a rugby match, an 11-year-old boy received a chest compression by 3 players during a tackle. He continued to play, but 2 hours later, he developed sharp retrosternal chest pain. A chest radiograph and an echocardiograph at the nearest emergency department showed pneumopericardium and pneumomediastinum.

Differential Diagnosis: Sternal and rib contusions, rib fractures, heartburn, acute asthma exacerbation, pneumomediastinum, pneumopericardium, pneumothorax, traumatic tracheal rupture, myocardial infarction, and costochondritis (Tietze syndrome).

Treatment: Acetaminophen for pain control.

Uniqueness: To our knowledge, this is the only case in the international literature of the simultaneous occurrence of pneumomediastinum and pneumopericardium in a child as a consequence of blunt chest trauma during a rugby match.

Conclusions: Pneumomediastinum and pneumopericardium may be consequences of rugby blunt chest trauma. Symptoms can appear 1 to 2 hours later, and the conditions may result in serious complications. Immediate admission to the emergency department is required.

Key Words: retrosternal chest pain, compression trauma, youth athletes

Pneumomediastinum (PM) and pneumopericardium (PP) are conditions in which air is present in the mediastinal and pericardial spaces, respectively. The mediastinum is the central compartment of the thoracic cavity and contains the heart and great vessels, trachea, esophagus, phrenic and cardiac nerves, thoracic duct, thymus, and lymph nodes. It extends from the sternum in the front to the vertebral column in back. The pericardium is a double-walled sac that contains the heart and the roots of the great vessels. The pathogenesis of PM and PP during a thoracic compression is probably an increase in intra-alveolar pressure; alveolar overdistention results in rupture of alveolar walls, allowing air to travel through the pulmonary interstitium along the perivascular sheaths to the lung hilum and mediastinum and the pericardial reflection.¹⁻³ Pericardial connective tissue is discontinuous at the lines of reflection of the parietal pericardium near the ostia of the pulmonary veins, creating a site of potential weakness where microscopic dissection of air into the pericardial sac is possible.^{1,2,4-6}

Pneumomediastinum can be spontaneous, occurring without an evident primary cause, or secondary to underlying and predisposing conditions, such as asthma, bronchiolitis obliterans, tobacco smoke, illegal drug ingestion, or blunt thoracic trauma. In the case of trauma, PM is more serious due to the likely association with other injuries and the higher risk of complications.^{7,8} In a series of 986 children admitted to the trauma center of an emergency department, PM accounted for 0.6% of thoracic injuries.⁹

Pneumopericardium is typically secondary to recent heart surgery or to blunt or penetrating trauma,¹⁰ but it can also

occur with infectious pericarditis from gas-producing organisms or from a fistula formation between the pericardium and an adjacent air-containing organ.¹¹

In children, PM and PP are rarely reported simultaneously¹²⁻¹⁵ and even less often as complications of trauma during sports.^{11,16} In the latter condition, PP is secondary to PM when great forces applied to the chest provoke the passage of air from the mediastinal space to the pericardial space.¹⁷ We report a case of chest pain secondary to PM and PP in a child as a result of blunt chest trauma during a tackle in a rugby match.

CASE REPORT

During a rugby tournament, an 11-year-old boy was involved in a tackle. Three opposing players (each weighing approximately 35 kg) tackled him from behind, causing him to fall to the ground while holding the ball and to receive chest compressions from the tacklers, one on top of the other. The tackle was interrupted a few seconds later by the on-field referee. The child continued the match without any clinical signs or symptoms. Two hours later, during a short intermission between matches, he complained of a sudden, sharp retrosternal chest pain. The child was unable to resume the match and was taken to the emergency department (ED). Upon admission, he complained of a sharp retrosternal chest pain (7 of 10 on the visual analog scale). He was assessed urgently at triage evaluation. He reported no history of asthma or previous thoracic injuries. On physical examination, the child presented normal vital signs: hemoglobin oxygen saturation was 99% on room air, heart rate was 74 beats/min,

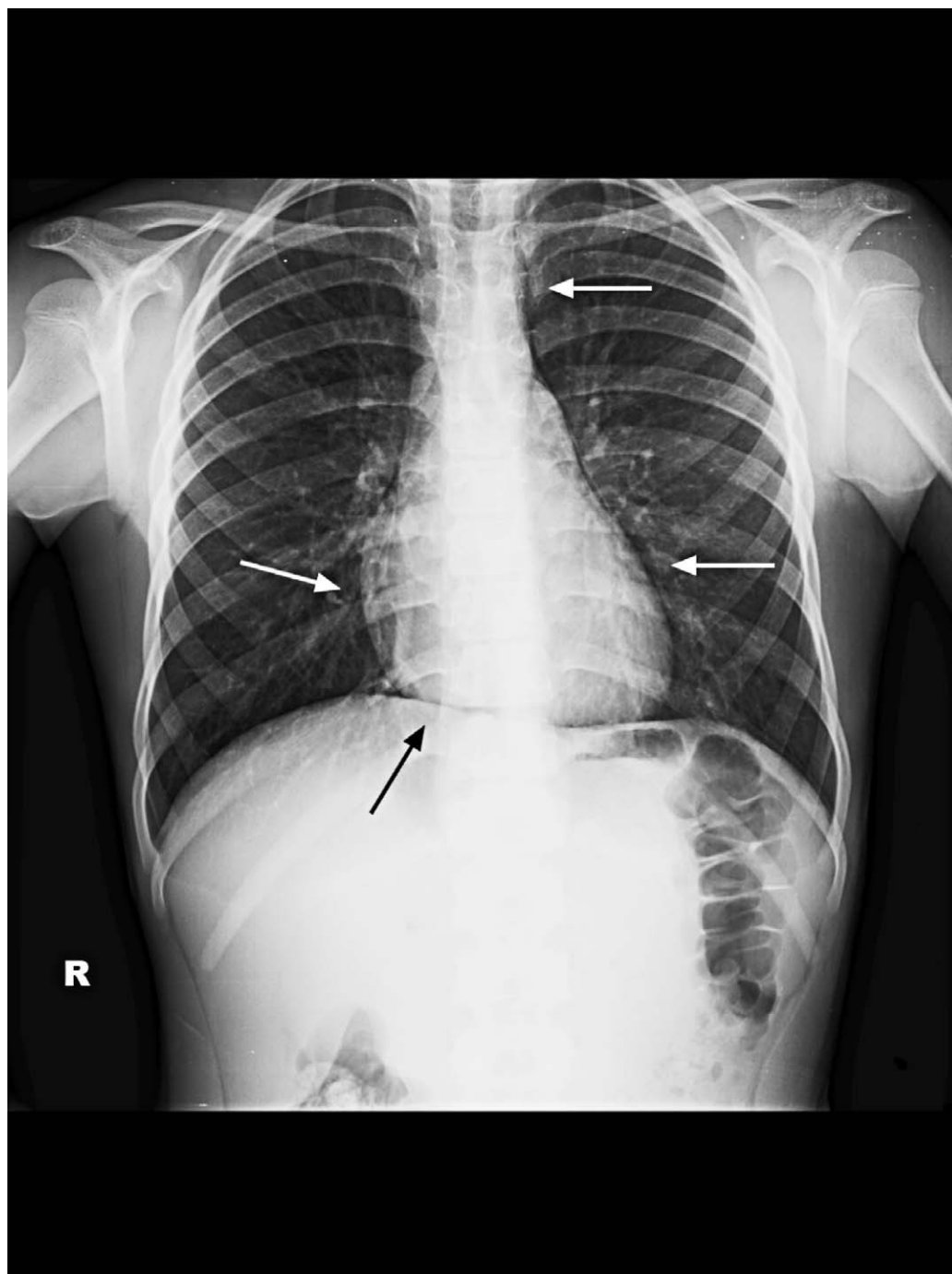


Figure 1. Anteroposterior chest radiograph shows gas outlining the inner surface of the mediastinal pleura (white arrows) and a thin band of gas between the heart and diaphragm (continuous diaphragm sign; black arrow).

respirations were 24/min, and body temperature was 36.8°C. Observational findings were unremarkable: no visible hematoma of the chest wall and no visible redness or swelling of the throat. No palpable tenderness or subcutaneous emphysema was noted in the face, neck, chest, or shoulders. No external signs of sternal and rib contusions or fractures or chest pain at external compression from front to back and from the sides toward the middle were present. Chest pain was aggravated by coughing and deep inspiration. No unusual breath sounds or wheezing were heard at chest auscultation. The pain

remained unchanged during the time in the ED and was significantly reduced after the administration of acetaminophen.

The differential diagnosis of sharp retrosternal chest pain includes sternal and rib contusions, rib fractures, heartburn, acute asthma exacerbation, PM, PP, pneumothorax, traumatic tracheal rupture, myocardial infarction, and costochondritis (Tietze syndrome). The child underwent a chest radiograph that showed free air lining the mediastinal and pericardial structures (Figure 1). The presence of PM and PP is an indication for immediate hospitalization. The child

underwent bronchoscopy to exclude tracheal and bronchial traumatic lesions; to exclude cardiac involvement, an electrocardiogram (normal), serum troponin I ($< 0.017 \mu\text{g/L}$), and creatine kinase (116 U/L; normal = 5 to 130 U/L) were obtained. White blood cell count and C-reactive protein values were within normal limits. Echocardiography demonstrated free air surrounding the cardiac outline, consistent with PP.

The patient was treated empirically with antibiotics (ceftazidime intravenously for 7 days) to prevent infection and acetaminophen for pain control. Rest in a comfortable position (sitting or semireclined) was recommended. The chest pain resolved within 12 hours after admission to the hospital. To monitor the evolution of PM and PP, echocardiography was repeated 3 days later and showed complete resolution of PP. The chest radiograph demonstrated complete resolution of PM after 7 days. The child was discharged from the hospital on day 8, with abstention from physical activities recommended for at least 3 months. At the follow-up 5 months later, the child was completely healthy and had resumed his previous training schedule.

DISCUSSION

Regardless of the sport, PM is rare.^{18–20} The combination of PM and PP is a very unusual consequence of injuries to children that occurred during sports. To our knowledge, only 2 cases have been reported in the international literature: a 15-year-old boy after a direct blow to the left side of his chest from another player's shoulder during a soccer game¹¹ and a 12-year-old asthmatic boy performing cycling and swimming in the same day.¹⁶ Our report is the first case of PM and PP in a healthy boy from a rugby tackle.

Tackling is considered the rugby phase most commonly associated with injuries, secondary to the great forces released when 1 player makes contact with an opponent²¹; 58% of all injuries in this sport occur during tackles.²² Despite this, only 2% of thoracic injuries requiring medical treatment happen during participation in sports²³; during rugby matches, injuries to the trunk are rare (4% to 11% of all professional rugby union injuries), and most of these tend to be less severe than injuries to other body areas.²¹

The most common signs and symptoms of PM or PP are sharp retrosternal chest pain (80% to 90% of cases), dyspnea (50% of cases), and a positive Hamman sign at chest auscultation (a crunching sound that is heard in time with the cardiac cycle).^{16,19,24} The signs and symptoms may be aggravated by coughing, deep inspiration, or swallowing or when the patient is lying down, as a consequence of the inappropriate presence of gas in the mediastinal and pericardial spaces.²⁵

A chest radiograph is the first diagnostic step to identify thoracic injuries and confirm the diagnosis of PM and PP.²⁶ An anterior-posterior radiograph would demonstrate a thin gas line around the different mediastinal structures: multiple thin and lucent streaks in PM and a broad band (halo sign), often with visible thickening of the pericardium, in PP. Furthermore, in PP, gas distribution usually changes with the patient's position, whereas in PM that does not happen.¹⁰ High-resolution computed tomography

scanning can be helpful for diagnosis but is recommended only when symptoms are persistent.²⁶

It is necessary to consider the differential diagnosis to evaluate the potential causes of sharp chest pain, including sternal and rib contusions, rib fractures, heartburn, acute asthma exacerbation, PM, PP, pneumothorax, traumatic tracheal rupture, myocardial infarction, and costochondritis (Tietze syndrome).^{26–28} Many of these conditions can be ruled out with the history or physical examination of the patient. It is important that athletic trainers be familiar with these conditions, their possible causes, and severity and with the need to send young athletes with sharp chest pain that appears suddenly during a rugby match to the ED quickly for adequate evaluation (Figure 2). A delay in presentation to the ED is often reported in similar cases, which may be due to the good general physical condition of the athletes or their desire to complete the match.^{23,29} After the trauma, chest pain can appear some time later and worsen: The timing of onset depends on the effect of the mechanical forces applied to the thorax and the amount of air accumulating in the mediastinal and pericardial spaces over time.³⁰ Initially, no signs or symptoms may be evident, but over time, as the air collection increases, important structures such as organs, vessels, and nerves are compressed and symptoms occur. Most cases are self-limiting, and recovery usually occurs in 2 weeks, but life-threatening events can result when PM or PP lead to compression of the heart and the major vessels in the mediastinum, similar to cardiac tamponade, as reported occasionally in pediatric patients. Surgical intervention to decompress a tension PM or PP is occasionally indicated in these posttraumatic conditions.³¹

A handful of small case series in the literature have suggested the benign course of this condition,²³ but there are still no clear guidelines regarding the diagnostic and therapeutic interventions needed for patients with PM and PP. Treatment includes analgesics, rest in a comfortable position (usually sitting or semireclined) and oxygen therapy if necessary²⁵; despite reports that supplying 100% oxygen promotes the rapid absorption of mediastinal emphysema (so-called nitrogen washout), the efficacy of such intervention is not conclusive.^{7,23,32} Antibiotics are administered to prevent the infectious complications that affect up to 80% of patients,⁸ and their use is necessary in case of fever, leukocytosis, and a high level of C-reactive protein.³⁰ It seems reasonable to allow these children to return to full activity once the PM and PP have resolved, signs and symptoms have disappeared, and echocardiography and chest radiograph are normal.³³

CONCLUSIONS

Pneumediastinum and PP are very rare consequences of rugby trauma. To prevent such injuries, coaches and players should emphasize proper techniques to avoid dangerous tackles.²² The apparently simple resolution of most cases of PM and PP should not mask the real risk of severe complications, such as mediastinitis and pericardial effusion with cardiac tamponade.

A child who complains of pain after chest trauma during a match needs adequate evaluation, and coaches must be alert to injuries presenting 1 to 2 hours later. In the case of suspected PM, alone or in combination with PP, the child

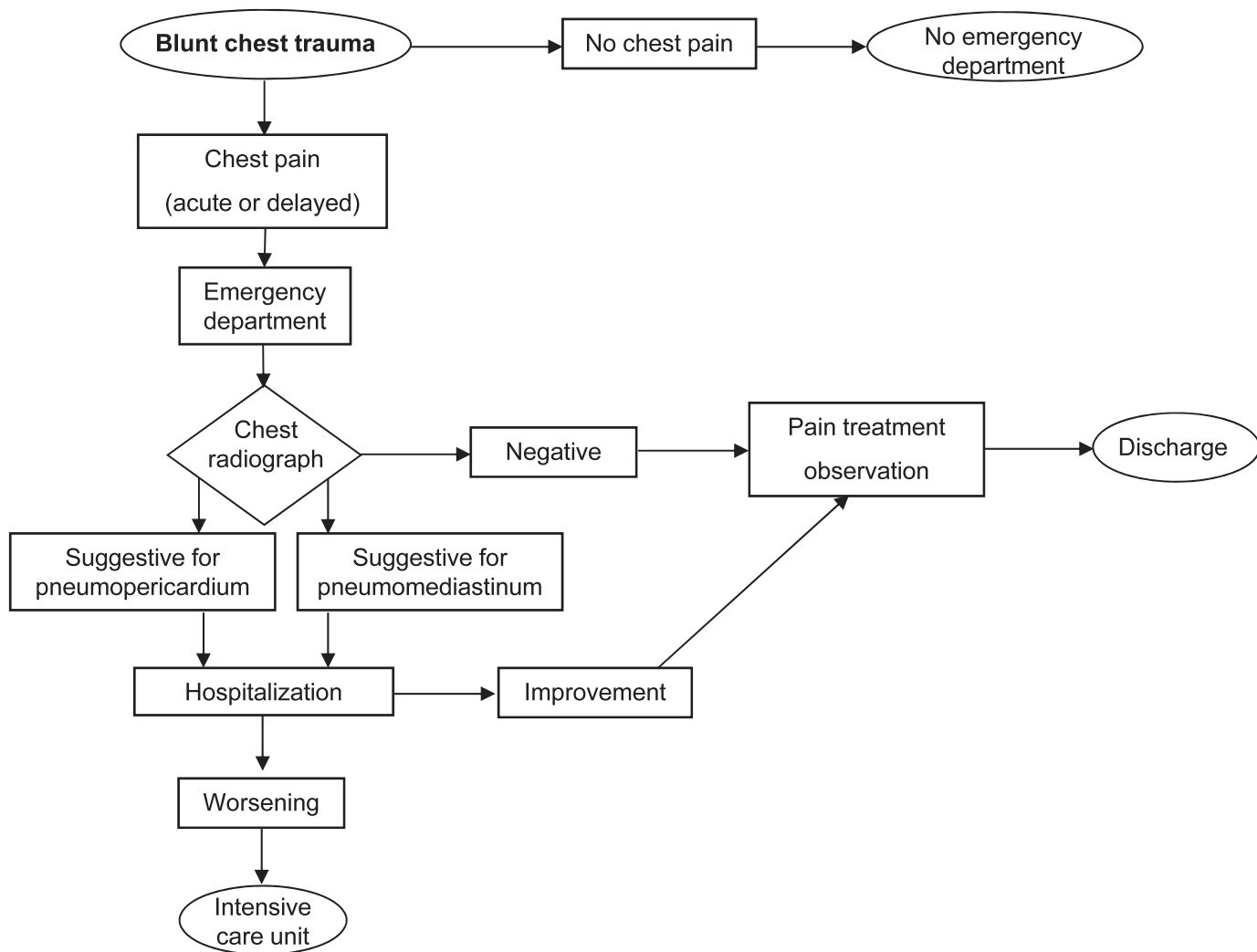


Figure 2. Diagnostic flow chart for the evaluation of chest pain after blunt thoracic trauma in children.

requires immediate admission to the nearest ED. A short hospitalization can limit the risk of complications. Management should be tailored, depending on the history, age, and clinical conditions of the young athlete.

REFERENCES

- Cummings RG, Wesly RL, Adams DH, Lowe JE. Pneumopericardium resulting in cardiac tamponade. *Ann Thorac Surg.* 1984;37(6):511–518.
- Capizzi PJ, Martin M, Bannon MP. Tension pneumopericardium following blunt injury. *J Trauma.* 1995;39(4):775–780.
- Leitman BS, Greengart A, Wasser HJ. Pneumomediastinum and pneumopericardium after cocaine abuse. *AJR Am J Roentgenol.* 1988;151(3):614.
- Katzir D, Klinovsky E, Kent V, Shucri A, Gilboa Y. Spontaneous pneumopericardium: case report and review of the literature. *Cardiology.* 1989;76(4):305–308.
- Toledo TM, Moore WL Jr, Nash DA, North RL. Spontaneous pneumopericardium in acute asthma: case report and review of the literature. *Chest.* 1972;62(1):118–120.
- Luby BJ, Georgiev M, Warren SG, Capito R. Postpartum pneumopericardium. *Obstet Gynecol.* 1983;62(suppl 3):46S–50S.
- Caceres M, Ali SZ, Braud R, Weiman D, Garrett HE. Spontaneous pneumomediastinum: a comparative study and review of the literature. *Ann Thorac Surg.* 2008;86(3):962–966.
- Takada K, Matsumoto S, Hiramatsu T, et al. Spontaneous pneumomediastinum: an algorithm for diagnosis and management. *Ther Adv Respir Dis.* 2009;3(6):301–307.
- Holmes JF, Sokolove PE, Brant WE, Kuppermann N. A clinical decision rule for identifying children with thoracic injuries after blunt torso trauma. *Ann Emerg Med.* 2002;39(5):492–499.
- Bejvan SM, Godwin JD. Pneumomediastinum: old signs and new signs. *AJR Am J Roentgenol.* 1996;166(5):1041–1048.
- Franklin WJ, Arora G, Ayres NA. Pneumopericardium and pneumomediastinum in an adolescent after blunt chest trauma. *Tex Heart Inst J.* 2003;30(4):338–339.
- Killinger JS, Ross SL, Pass RH. Pneumomediastinum and tension pneumopericardium after congenital diaphragmatic hernia repair: presentation and transcatheter drainage. *Pediatr Cardiol.* 2009;30(7):1048–1049.
- Markarian MK, MacIntyre DA, Cousins BJ, Fildes JJ, Malone A. Adolescent pneumopericardium and pneumomediastinum after motor vehicle crash and ejection. *Am J Emerg Med.* 2008;26(4):515.e1–e2.
- Küçükosmanoğlu O, Karakoç GB, Yılmaz M, Altintas D, Güneser Kendirli S. Pneumomediastinum and pneumopericardium: unusual

- and rare complications of asthma in a 4 years old girl. *Allergol Immunopathol (Madr)*. 2001;29(1):28–30.
15. Ameh V, Jenner R, Jilani N, Bradbury A. Spontaneous pneumopericardium, pneumomediastinum and subcutaneous emphysema: unusual complications of asthma in a 2-year-old boy. *Emerg Med J*. 2006;23(6):466–467.
 16. Eberle C, Jünger K, Debatin KM, Wabitsch M. Spontaneously occurring pneumomediastinum related to a pneumopericardium, a pneumothorax and a skin emphysema in a 12-year old boy. *Klin Padiatr*. 2010;222(1):40–44.
 17. Mansfield PB, Graham CB, Beckwith JB, Hall DG, Sauvage LR. Pneumopericardium and pneumomediastinum in infants and children. *J Pediatr Surg*. 1973;8(5):691–699.
 18. Morgan EJ, Henderson DA. Pneumomediastinum as a complication of athletic competition. *Thorax*. 1981;36(2):155–156.
 19. Haynes RJ, Evans RJ. Pneumomediastinum after rugby training. *Br J Sports Med*. 1993;27(1):37–38.
 20. Pierce MJ, Weesner CL, Anderson AR, Albohm MJ. Pneumomediastinum in a female track and field athlete: a case report. *J Athl Train*. 1998;33(2):168–170.
 21. Kaplan KM, Goodwillie A, Strauss EJ, Rosen JE. Rugby injuries: a review of concepts and current literature. *Bull NYU Hosp Jt Dis*. 2008;66(2):86–93.
 22. Quarrie KL, Hopkins WG. Tackle injuries in professional Rugby Union. *Am J Sports Med*. 2008;36(9):1705–1716.
 23. Mihos P, Potaris K, Gakidis I, Mazaris E, Sarras E, Kontos Z. Sports-related spontaneous pneumomediastinum. *Ann Thorac Surg*. 2004;78(3):983–986.
 24. Giuliani S, Franklin A, Pierce J, Ford H, Grikscheit TC. Massive subcutaneous emphysema, pneumomediastinum, and pneumopericardium in children. *J Pediatr Surg*. 2010;45(3):647–649.
 25. Munsell WP. Pneumomediastinum: report of 28 cases and review of the literature. *JAMA*. 1967;202(8):689–693.
 26. Zylak CM, Standen JR, Barnes GR, Zylak CJ. Pneumomediastinum revisited. *Radiographics*. 2000;20(4):1043–1057.
 27. Cava JR, Sayger PL. Chest pain in children and adolescents. *Pediatr Clin North Am*. 2004;51(6):1553–1568.
 28. Bernstein D. Evaluation of the cardiovascular system. In: Kliegman RM, Behrman RE, Jenson HB, Stanton BF. *Nelson's Textbook of Pediatrics*. 18th ed. Philadelphia, PA: Saunders Elsevier; 2004;1851–1855.
 29. Kizer KW, MacQuarrie MB. Pulmonary air leaks resulting from outdoor sports: a clinical series and literature review. *Am J Sports Med*. 1999;27(4):517–520.
 30. Al-Mufarrej F, Badar J, Gharagozloo F, Tempesta B, Strother E, Margolis M. Spontaneous pneumomediastinum: diagnostic and therapeutic interventions. *J Cardiothorac Surg*. 2008;3:59.
 31. Tutor JD, Montgomery VL, Eid NS. A case of influenza virus bronchiolitis complicated by pneumomediastinum and subcutaneous emphysema. *Pediatr Pulmonol*. 1995;19(6):393–395.
 32. Chalumeau M, Le Clainche L, Sayeg N, et al. Spontaneous pneumomediastinum in children. *Pediatr Pulmonol*. 2001;31(1):67–75.
 33. Funk DA, McGanity PL, Hagemeyer KF 3rd, Schenck RC Jr. Pneumothorax in high school football. *Tex Med*. 1998;94(5):72–74.

Address correspondence to Angelo Barbato, MD, Department of Pediatrics, University of Padova, via Giustiniani 3, 35128 Padova, Italy. Address e-mail to barbato@pediatria.unipd.it.