

## ORIGINAL ARTICLE

## Auditory neuropathies and electrocochleography

ROSAMARIA SANTARELLI<sup>1</sup>, IGNACIO DEL CASTILLO<sup>2,3</sup> & ARNOLD STARR<sup>4</sup><sup>1</sup>Department of Neuroscience, Service of Audiology and Phoniatrics, University of Padua, Padova, Italy,<sup>2</sup>Unidad de Genética Molecular, Hospital Ramón y Cajal and <sup>3</sup>Centro de Investigación Biomedica en Red de Enfermedades raras (CIBERER), Madrid, Spain, and <sup>4</sup>University of California, Irvine, California, USA**Abstract**

Auditory neuropathy (AN) is a hearing disorder characterized by disruption of temporal coding of acoustic signals in auditory nerve fibres resulting in impairment of auditory perceptions relying on temporal cues (1,2). Mechanisms suggested include both pre-synaptic and post-synaptic disorders affecting inner hair cell (IHC) depolarization, neurotransmitter release from ribbon synapses, spike initiation in auditory nerve terminals, loss of nerve fibres and impaired conduction, all occurring in the presence of normal physiological measures of outer hair cell (OHC) activities (otoacoustic emissions (OAEs) and cochlear microphonic (CM)). Disordered synchrony of auditory nerve discharge has been suggested as the basis of both the profound alterations of auditory brainstem responses (ABRs) and impairment of speech perception (3). We review how electrocochleography (ECoChG) can provide detailed information to help define objectively the sites of auditory neural dysfunction as affecting IHC receptor summing potential (SP) and compound action potential (CAP), the latter reflecting disorders of ribbon synapses and auditory nerve fibres.

**Key words:** cochlear potentials, ribbon synapses, inner hair cells, auditory nerve fibers

**Differential diagnosis of AN: neural and inner hair cell (IHCs) disorders**

The ECoChG response results from the superimposition of three components (4,5), two originating from receptor elements, the cochlear microphonic (CM) and summing potential SP (SP), and the other, the compound action potential (CAP), arising from auditory nerve fibres (Figure 1). CM potentials are believed to originate mainly from the sum of the extracellular components of receptor potentials arising from OHCs located in the basal portion of the cochlea (4). SP responses recorded from the promontory originate from the DC component of receptor potentials arising in the basal IHCs (6).

In ECoChG recordings evoked by click stimuli, CM appears as an oscillatory activity superimposed on the SP-CAP complex (4,5) (Figure 1). Since this activity is strictly related to the basilar membrane motion, the procedure of averaging the responses evoked separately by condensation and rarefaction stimuli is usually used to extract both SP and CAP (4,5,7). In normal hearing

ears the ECoChG waveform resulting from CM cancellation (Figure 1) begins with an abrupt negative deflection, the receptor summing potential (SP); this is followed by a negative peak, the neural compound action potential (CAP), which returns to baseline by 1.5–2 ms at high stimulus intensities. Both SP and CAP potentials are reduced in amplitude and delayed in latency at decreasing stimulation intensities, while the duration of the whole SP-CAP complex is slightly prolonged (4,5).

Auditory neuropathy (AN) has a wide range of aetiologies (genetic, infectious, toxic-metabolic, immunological) (1,8). Currently, definite aetiological factors can be identified in about half of patients (1). All forms of the disorder may be present in isolation or associated with multisystem involvement including peripheral and/or optic neuropathies (3,9). AN disorders associated with neurological diseases are invariably post-synaptic since alterations of auditory nerve fibres discharge result directly from neuronal loss and demyelination of peripheral and/

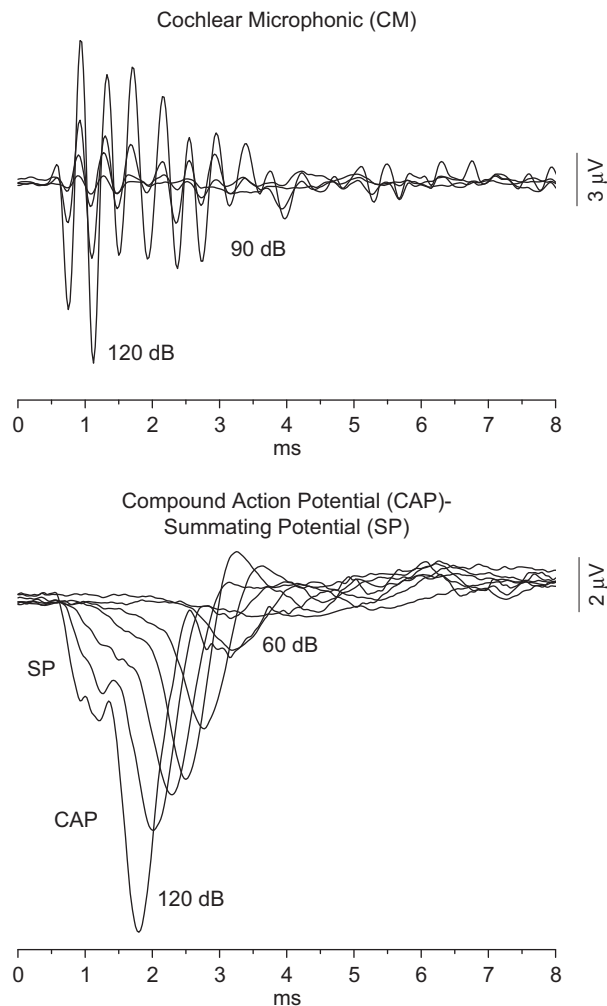


Figure 1. Cochlear potentials recorded by ECoG from one normal-hearing child. Cochlear microphonic (CM), summating potential (SP) and compound action potential (CAP) are displayed for decreasing stimulus levels.

or cranial nerves. ECoG recordings performed in these AN disorders show both CM and SP receptor potentials of normal amplitude consistent with preservation of cochlear function, while the neural CAP is decreased in amplitude and prolonged in duration compared to normal hearing ears (7). This ECoG pattern should be considered as distinctive of 'neural' AN. These forms are rarely seen in small children because in most patients the neuropathies affecting cranial or peripheral nerves begin in late childhood or adolescence (9).

In several forms of AN underlain by different aetiologies (genetic, immunological, metabolic) the cochlear potentials obtained after CM cancellation consist of a prolonged negative deflection that is attenuated in amplitude and markedly prolonged in duration compared to the CAP recorded from normally-hearing ears (7). One example is displayed in Figure 2 for one AN patient carrying the R445H

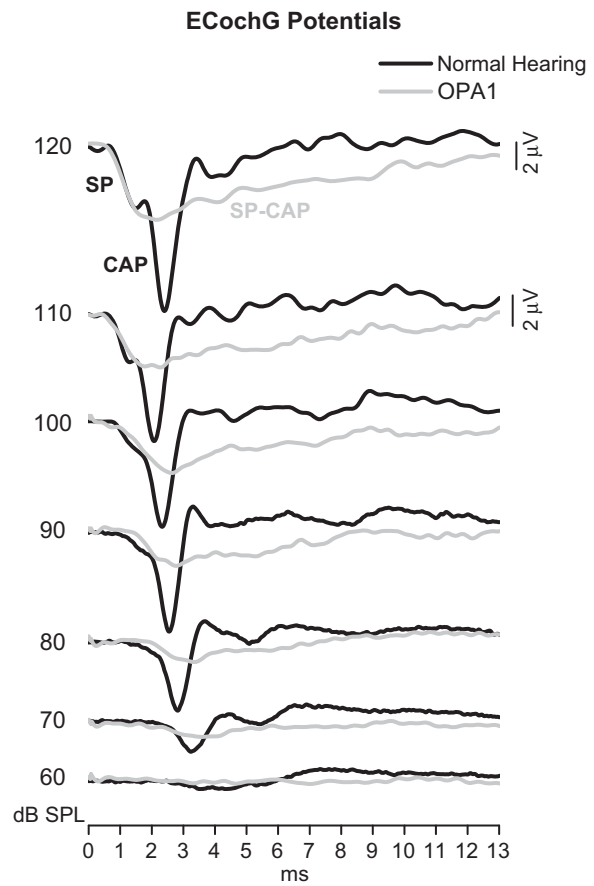


Figure 2. ECoG potentials from one patient with AN. ECoG waveforms recorded from one patient carrying the R445H mutation in the *OPA1* gene are superimposed on the corresponding recordings obtained from one normal-hearing child at decreasing stimulus intensities. In the normal ear, the response begins with negative SP followed by the CAP, which increases in peak latency and decreases in amplitude from 120 to 60dB SPL. The ECoG responses recorded from the AN patient consist of a low-amplitude negative potential showing increased peak latency and prolonged duration compared to the normal ear.

mutation in the *OPA1* gene (10). ECoG waveforms are superimposed on the ECoG recordings obtained from one normally-hearing child at decreasing stimulation intensities. The cochlear potentials recorded from the OPA1 patient consist of a prolonged negative deflection showing no separation between SP and CAP components. Compared to the normal ear, the amplitude of this response is reduced, the peak latency is delayed, while the duration appears remarkably increased.

In order to clarify whether the prolonged potentials originate from neural or receptor activations, we used a neural adaptation paradigm consisting of an initial click, followed 15 ms later by 10 clicks with an inter-stimulus interval of 2.9 ms. This sequence was repeated every 191 ms (5,7).

The potentials recorded in response to this stimulus sequence are displayed for 110dB SPL intensity

in Figure 3 for one normally-hearing child (as in Figure 2) and the AN patient carrying the R445H mutation in the *OPA1* gene. In the normally-hearing ear CAP amplitude shows a marked attenuation from the first (#1) to the second (#2) click of the stimulus sequence. Subsequently, further decrease in amplitude is observed during the following 3–4 clicks during train stimulation. As a result, CAP amplitude, as measured from baseline to the CAP peak, decreases on average to 53% at the end of the stimulus sequence (mean value from 34 normal ears 43%, range 25–58%). Also SP amplitude attenuates at high stimulus rate, but the amount of amplitude reduction was much smaller (78%; mean value from 34 normal ears 71%, range 45–100%).

In the *OPA1* patient, amplitude changes during adaptation were only measured over the whole SP-CAP response (5,7) due to the lack of separation between SP and CAP components. SP-CAP potentials decrease in amplitude from the initial click of the sequence (click #1) to the first click of the train (#2) and show further attenuation during the following 4–5 clicks. As a result, the size of the SP-CAP potential after adaptation (50%) equals the amplitude of the adapted SP-CAP response in normal ears (mean value from 34 normal ears 43%, range 25–58%). These findings indicate that the prolonged negative deflections recorded from this particular category of AN patient result from neural rather than receptor activation.

Different mechanisms may underlie the generation of the prolonged negative potentials in the various forms of AN. In subjects with neural AN such as those affected by Charcot-Marie-Tooth disease, demyelination of auditory nerve fibres is expected to induce slowed conduction velocity with reduced probability of synchronous firing, while the decrease in number of auditory nerve fibres would result in reduced auditory input. This may lead to prolonged duration and decreased amplitude of the neural CAP potential (5). Other mechanisms may be involved in the forms of AN showing no separation between SP and CAP components. In these AN disorders the reduction or absence of SPs in ECoChG recordings point to a pre-synaptic disorder of IHCs, which can occur in the presence of preserved function of OHCs as indicated by the detection of CMs with normal amplitude. Therefore, information provided by ECoChG recordings are relevant in that they help to identify the lesion site by distinguishing the AN disorders involving IHCs from the neural disorders, in which SPs are normal. This information may be of value in predicting the outcome of cochlear implantation. A good outcome is invariably expected in implanted patients affected by AN disorders involving IHCs, whereas the benefits of cochlear implantation in neural forms are strictly dependent on the number of spared auditory neurons.

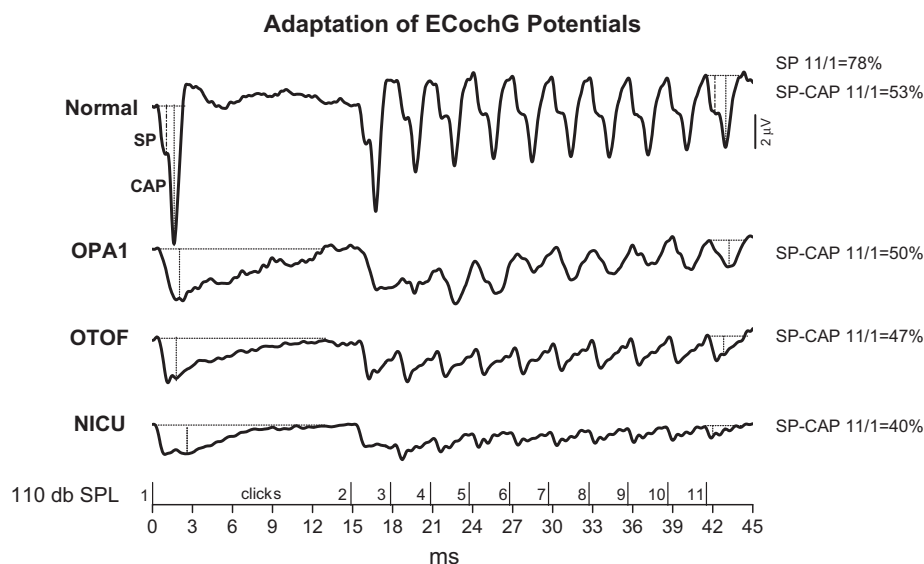


Figure 3. Adaptation of cochlear potentials. ECoChG recordings obtained at 110 dB SPL in response to the stimulus sequence reported at the bottom are displayed for one normal-hearing and three AN subjects, one young adult with the R445H mutation in *OPA1*; and two children, one carrying a biallelic mutation in the *OTOF* gene, and the other showing hearing impairment related to a difficult neonatal course. In the normal-hearing child, CAP amplitude was markedly attenuated after adaptation whereas SP attenuation was much smaller. In the three AN subjects, SP-CAP amplitude was markedly reduced after adaptation, and the amount of response attenuation was comparable with that calculated for the normal-hearing child.

### Cochlear potentials from children with mutations in the otoferlin gene: a ribbon synaptic disorder

Cochlear potentials have been recorded at our department from children with biallelic mutations in the *OTOF* gene as part of the standard assessment protocol for cochlear implantation (11).

Mutations in the *OTOF* gene (DFNB9) with a recessive pattern of inheritance are responsible for the most well-known form of isolated AN (12–15). This is considered a pre-synaptic disorder with preservation of auditory nerve fibres. The *OTOF* gene encodes otoferlin, a transmembrane protein belonging to the ferlin protein family, which contains several repeating C2 domains involved in calcium binding (16). Otoferlin plays a crucial role in vesicle release at the synapse between IHCs and auditory nerve fibres by interacting with syntaxin1 and SNAP25 (17), and it has recently been implicated in vesicle replenishment at the pre-synaptic membrane (18). It has been estimated that *OTOF* mutations are responsible for at least 3% of cases of prelingual non-syndromic hearing impairment in the Spanish population (12,14). To date, more than 50 pathogenic mutations of the *OTOF* gene have been identified (14). Most of them cause loss of otoferlin function, thus resulting in a very homogeneous phenotype of prelingual, profound hearing loss with absence, or marked threshold elevation, of ABRs. Over 50% of subjects carrying biallelic mutations in the *OTOF* gene also show preserved function of OHCs as indicated by OAEs recording (11,12,14). This is matter of concern when using

OAEs for detecting hearing impairment in universal screening programmes since children with profound hearing loss underlain by mutations in the *OTOF* gene may be missed by the screening procedure.

Mutations that do not fully inactivate the otoferlin protein result in a milder phenotype characterized by the classical picture of AN, which is apparent only in febrile subjects (19–21). This has been attributed to an instability of otoferlin, which develops when the body temperature rises (15).

In children with mutations in the *OTOF* gene, CMs are recorded with normal amplitude. The cochlear potentials obtained after CM cancellation show the prolonged negative deflection found in other forms of AN (11). The ECochG waveforms recorded from five children at 120dB SPL (corresponding to 90dB nHL, referred to the psychoacoustical threshold of normal hearing subjects) are reported in Figure 4 (left side) superimposed on the grand average of the ECochG recordings obtained from 26 normally-hearing children. In patients with *OTOF* mutations the ECochG response begins with a fast negative deflection with peak amplitude and latency consistent with SP. This is followed by a low-amplitude negative potential with markedly prolonged duration compared to the neural responses recorded from the normal hearing ear. Similar ECochG waveforms have been obtained by McMahon et al. (22) from a group of young children with AN. In some patients a small CAP is superimposed on this prolonged activity. Interestingly, the sustained negative potentials are recorded as low as 50–90dB below behavioural thresholds (Figure 4, right side).

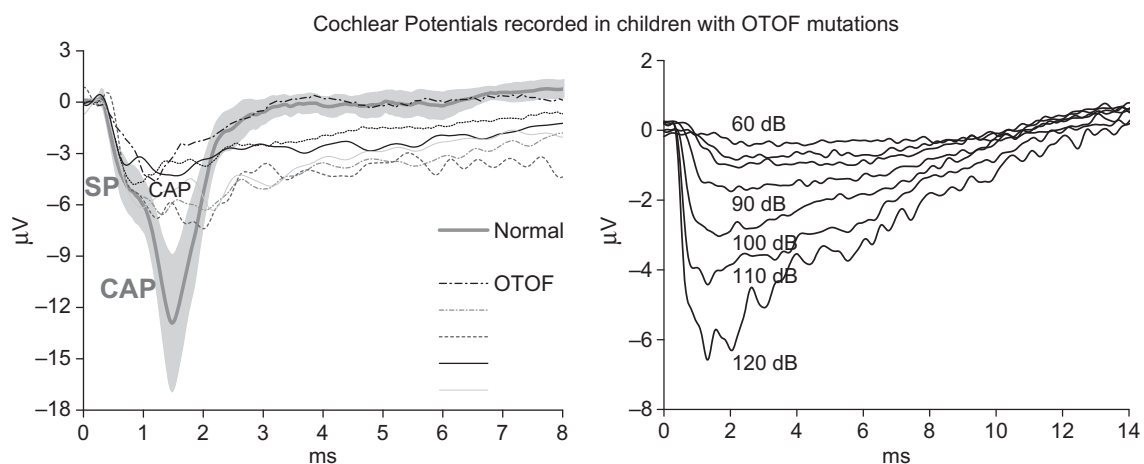


Figure 4. ECochG potentials from children with biallelic mutation in the *OTOF* gene. Cochlear potentials recorded from five children at 120dB SPL are reported on the right side superimposed on the grand average of the corresponding waveforms obtained from 26 normal-hearing ears. The shadowed area refers to 95% confidence limits. ECochG responses recorded from one representative child are displayed on the left side for decreasing stimulus levels. At high stimulus intensity ECochG responses begin with a fast negative deflection with peak amplitude and latency consistent with SP. This is followed by a low-amplitude negative potential with prolonged duration compared to the neural responses recorded from normal ears. This response is identifiable as low as 60dB SPL, which is about 50dB lower than behavioural threshold.

Moreover, stimulation at a high rate (Figure 3) induces an attenuation in amplitude of SP-CAP potentials (53% in the example of Figure 3), which is similar to that obtained for SP-CAP in normal-hearing ears (mean value from 34 normal ears 43%, range 25–58%) consistent with their neural generation.

The initial fast SP response recorded from children with mutations in the *OTOF* gene points to a normal activation of IHCs. This is followed by the prolonged neural potentials that seem analogous to the dendritic responses recorded by Sellick et al. (23) from the scala tympani of guinea pigs after blocking neural spiking in terminal dendrites of auditory nerve fibres. Similarly, the prolonged responses recorded from children with *OTOF* mutations may result from the sum of small dendritic potentials arising in the distal portion of the afferent fibres that are not followed by neural spiking. Abnormal dendritic activation, in turn, results from alteration of multivesicular release. A reduction in otoferlin activity may lead to reduced vesicle replenishment (18) and to abolition of the fast phase of exocytosis (17). The decrease of neurotransmitter release is likely to result in a decrease in amplitude of EPSPs with reduced synaptic reliability. Moreover, besides the reduction of neurotransmitter availability at the synaptic cleft, there is an impairment of multivesicular release leading to the generation of small EPSPs with abnormal morphology and dispersed in time, which only occasionally reach the threshold to trigger action potentials recorded as high-threshold CAP.

These mechanisms are relevant from the point of view of rehabilitation programmes for deaf children carrying mutations in the *OTOF* gene, since auditory nerve fibres are not believed to be directly involved by the disorder. This might explain the excellent outcome of cochlear implantation in restoring auditory function in this category of patients (24,25).

### **Cochlear potentials from AN children discharged from the Neonatal Intensive Care Unit (NICU): a neural or inner hair cells (IHCs) disorder?**

Infants admitted to the Neonatal Intensive Care Unit (NICU) are at increasing risk for sensorineural hearing loss due to exposure to many risk factors such as prematurity, low birth weight, respiratory distress, anaemia, noise and ototoxic drugs (26,27). The incidence of hearing loss ranges from 1.5% (28) to 3.2% (27). This variability is due to differences in the characteristics of the NICU population among hospitals, age at testing and variability in defining and assessing hearing loss (26). In these children, the combined effects of prematurity and other risk factors impinge on cochlear function, resulting in

various types and degree of damage (26). Variable degrees of sensorineural hearing loss have been reported in infants discharged from the NICU resulting from lesion of OHCs, IHCs or both.

About 5.6% of children failing newborn hearing screening show abnormal ABRs and presence of OAEs consistent with the electrophysiological profile of AN (26,28). Post mortem examination carried out on temporal bones of deceased neonates has shown extensive hair cell damage with a higher frequency of selective IHC loss in premature infants compared to full-term babies (29). Since no signs of auditory nerve damage were found, the dysfunction of IHCs has been proposed as the primary mechanism underlying AN in children discharged from the NICU.

In cooperative subjects clinical criteria for AN diagnosis include impairment of speech perception beyond that expected for the hearing loss, absence or marked abnormality of ABRs and preserved OHCs activities (OAEs and CMs). In newborn babies, the presence of AN relies only on the absence of ABRs associated with the detection of OAEs (26). However, no detailed information of cochlear nerve and hair cell activities could be provided by an ABR recording due to the low signal-to-noise ratio (7,24). In addition, in children discharged from the NICU, ABR abnormalities may result also from reduced synchrony occurring at any level from auditory nerve to brainstem generators. A reduced correlation between ABR and hearing thresholds has been documented in premature babies and in those suffering perinatal asphyxia (30–32). In these cases, alterations of ABRs might ensue from abnormal firing of brainstem generators, which retain little or no connection with the dynamics of auditory periphery activation. Recently, the use of intratympanic electrocochleography (ECochG) has been proposed for this category of patients to define the details of cochlear potentials (7,22) and, in general, to evaluate hearing threshold for rehabilitative purposes.

Twenty-three children from the NICU who showed the electrophysiological profile of AN (mean age 23.6 months) have been submitted to ECochG recording at our department from 2001 to 2012 because of reduced ability to perform in behavioural audiometry (5,24). All children showed one or more disabilities including cerebral palsy, delayed motor development and cognitive impairment. The cochlear potentials recorded by ECochG at decreasing stimulus levels are displayed for one representative patient in Figure 5, superimposed on the corresponding waveforms recorded from one normal hearing child. The ECochG profile obtained from children discharged from the NICU is indistinguishable from the most common pattern

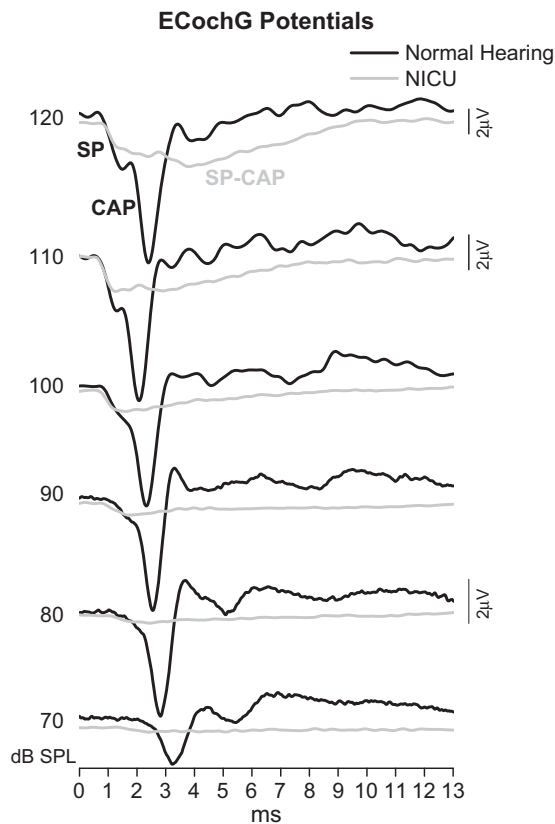


Figure 5. ECoChG potentials from one AN child discharged from the NICU. The waveforms recorded at decreasing stimulus levels are superimposed on the corresponding recordings obtained from one normal-hearing child. Cochlear potentials recorded from the child discharged from the NICU consist of an abrupt negative potential showing the same latency as the SP in normal ears but with reduced amplitude. This is followed by the prolonged negative response similar to that found in other forms of AN.

observed in patients with AN. Specifically, the response consists of an abrupt negative potential with the same latency as the SP in normal ears. This is followed by the prolonged negative response with reduced amplitude and delayed peak latency compared to the normal-hearing subjects. In this particular child, the amplitude of the SP potential is reduced compared to the normal ear. This result appears to be in accordance with the finding of a reduced number of IHCs in children discharged from the NICU who showed the electrophysiological profile of AN (29). In this perspective, the auditory dysfunction found in these children should be related to an abnormal activation of IHCs. Nevertheless, more extensive analyses of ECoChG recordings are needed to draw any definite conclusion.

Stimulation at high rate (Figure 3) is consistent with the prolonged potentials being generated by neural rather than receptor elements since the size of attenuation after adaptation was 60% and, thus, it was comparable to that obtained from normal ears

(mean value from 34 normal ears 43%, range 25–58%) (5).

The ECoChG findings collected from children discharged from the NICU point to an abnormal activation of auditory periphery. Specifically, the finding of prolonged potentials similar to those obtained in other forms AN is consistent with alterations of auditory nerve discharge. Whether this abnormal pattern of activation is entirely related to a presynaptic disorder associated with IHCs loss or, rather, to a combination of mechanisms acting at both pre- and post-synaptic levels, remains to be determined.

Surprisingly, the low-amplitude prolonged negative potentials were recorded also from children (59 subjects) discharged from the NICU who showed abnormal ABRs and no OAEs (5). Specifically, 61% of these children showed prolonged responses with no separation between SP and CAP; 13% had distinct SP and CAP associated with an increase of response duration; while 25% showed no response at the maximum stimulation intensity (120dB SPL). Overall, the ECoChG pattern observed in the majority of these children seems indistinguishable from that obtained from the group of infants with the electrophysiological profile of AN.

Figure 6 reports the distribution of SP-CAP thresholds in the two samples of children discharged from the NICU, one with OAEs (AN) and the other without OAEs (N-AN). It can be noted that patients showing the profile of AN show normal or moderately elevated ECoChG thresholds, whereas higher thresholds were found in children showing no OAEs. Threshold differences between the two groups of children may reflect different mechanisms and extension of damage at the level of the auditory periphery. Taking into account the high variability of risk factors acting in the NICU, it is likely that ECoChG threshold distribution result from a 'spectrum' of lesions consisting of different amounts of IHCs and OHCs loss, synaptic damage and depression of auditory nerve fibre activity. In this perspective, what really matters is not the hallmark of AN (absence of ABRs/presence of OAEs), but rather what ECoChG recordings tells us about the receptor potentials and neural response. Abnormal SPs followed by prolonged potentials are likely to be associated with IHCs disorders, whereas normal SP responses followed by the sustained potentials may result from synaptic dysfunction. However, the latter ECoChG pattern could be underlain by alternative mechanisms such as damage to the terminal dendrites as suggested for some forms of AN in humans (10) as well as for noise-induced trauma in guinea pigs (33).

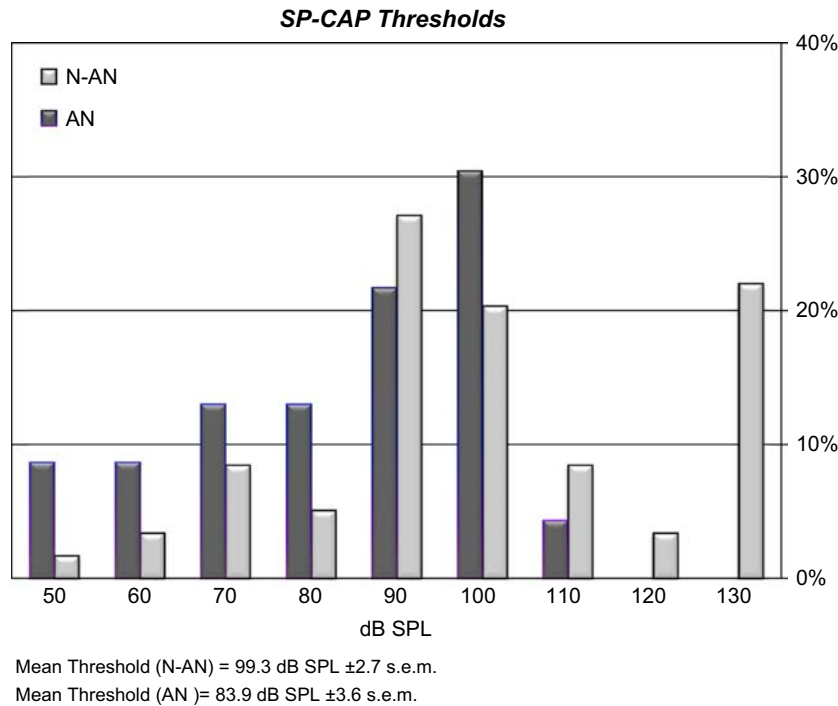


Figure 6. Distribution of SP-CAP thresholds in two groups of children discharged from the NICU, one with OAEs (AN) and the other without OAEs (N-AN). Children showing the profile of AN show normal or moderately elevated ECoChG thresholds, whereas higher thresholds were found in children showing no OAEs.

## Conclusions

ECoChG recordings collected from patients with AN can reveal abnormalities of both IHCs receptor potentials, and activation of auditory nerve fibres. This finding may be crucial to define the diagnosis in some forms of AN since OAEs are absent in over one-third of AN patients on retesting (1). Moreover, impairment of speech perception may be apparent only in the presence of noise in cooperative subjects (1), while it cannot be evaluated in newborn babies. In these cases the finding of abnormal cochlear potentials may help to refine the diagnosis of AN by identifying the site of lesion and by elucidating the underlying pathophysiological mechanisms. Moreover, ECoChG recordings are mandatory in children discharged from the NICU who show abnormal ABRs and reduced ability to perform at behavioural audiometry since no reliable information on the function of auditory periphery can be obtained through ABR recordings.

## Acknowledgements

The authors are deeply indebted to Pietro Scimemi and Roberta Rossi for their support in data analysis, and Fabio Saccomandi for technical assistance. The authors also thank the anaesthesiologists who performed general anaesthesia, and the nurses involved in child care.

**Declaration of interest:** The authors report no conflicts of interest. The authors alone are responsible for the content and writing of the paper.

## References

1. Starr A, Zeng F, Michalewski H, Moser T. Perspectives on Auditory Neuropathy: Disorders of Inner Hair Cell, Auditory Nerve, and Their Synapse. Volume 3: Audition. Elsevier; 2008. p. 397–412.
2. Zeng F-G, Kong Y-Y, Michalewski HJ, Starr A. Perceptual consequences of disrupted auditory nerve activity. *J Neurophysiol.* 2005;93:3050–63.
3. Starr A, Picton TW, Sininger Y, Hood LJ, Berlin CI. Auditory neuropathy. *Brain.* 1996;119:741–53.
4. Eggermont JJ. Basic principles for electrocochleography. *Acta Otolaryngol Suppl.* 1974;316:7–16.
5. Santarelli R, Arslan E. Electrocochleography. Disorders of Peripheral and Central Auditory Processing. *Handbook of Clinical Neurophysiology.* Amsterdam: Elsevier; 2013. p. 83–113.
6. Durrant JD. Are inner or outer hair cells the source of summing potentials recorded from the round window? *J Acoust Soc Am.* 1998;104:370–7.
7. Santarelli R, Starr A, Michalewski HJ, Arslan E. Neural and receptor cochlear potentials obtained by transtympanic electrocochleography in auditory neuropathy. *Clin Neurophysiol.* 2008;119:1028–41.
8. Starr A, Sininger YS, Pratt H. The varieties of auditory neuropathy. *J Basic Clin Physiol Pharmacol.* 2000;11: 215–30.
9. Santarelli R. Information from cochlear potentials and genetic mutations helps localize the lesion site in auditory neuropathy. *Genome Med.* 2010;2:91.

10. Huang T, Santarelli R, Starr A. Mutation of OPA1 gene causes deafness by affecting function of auditory nerve terminals. *Brain Res.* 2009;1300:97–104.
11. Santarelli R, del Castillo I, Rodríguez-Ballesteros M, Scimemi P, Cama E, Arslan E, et al. Abnormal cochlear potentials from deaf patients with mutations in the otoferlin gene. *J Assoc Res Otolaryngol.* 2009;10:545–56.
12. Rodríguez-Ballesteros M, del Castillo FJ, Martín Y, Moreno-Pelayo MA, Morera C, Prieto F, et al. Auditory neuropathy in patients carrying mutations in the otoferlin gene (OTOF). *Hum Mutat.* 2003;22:451–6.
13. Varga R, Kelley PM, Keats BJ, Starr A, Leal SM, Cohn E, et al. Non-syndromic recessive auditory neuropathy is the result of mutations in the otoferlin (OTOF) gene. *J Med Genet.* 2003;40:45–50.
14. Rodríguez-Ballesteros M, Reynoso R, Olarte M, Villamar M, Morera C, Santarelli R, et al. A multicentre study on the prevalence and spectrum of mutations in the otoferlin gene (OTOF) in subjects with non-syndromic hearing impairment and auditory neuropathy. *Hum Mutat.* 2008;29:823–31.
15. Moser T, Predoehl F, Starr A. Review of Hair Cell Synapse Defects in Sensorineural Hearing Impairment. *Otol Neurotol.* 2013 DOI:10.1097/MAO.0b013e3182814d4a.
16. Rizo J, Südhof TC. C2 domains, structure and function of a universal Ca<sup>2+</sup>-binding domain. *J Biol Chem.* 1998; 273:15879–82.
17. Roux I, Safieddine S, Nouvian R, Grati M, Simmler M-C, Bahloul A, et al. Otoferlin, defective in a human deafness form, is essential for exocytosis at the auditory ribbon synapse. *Cell.* 2006;127:277–89.
18. Pangrsic T, Lasarow L, Reuter K, Takago H, Schwander M, Riedel D, et al. Hearing requires otoferlin-dependent efficient replenishment of synaptic vesicles in hair cells. *Nat Neurosci.* 2010;13:869–76.
19. Varga R, Avenarius MR, Kelley PM, Keats BJ, Berlin CI, Hood LJ, et al. OTOF mutations revealed by genetic analysis of hearing loss families including a potential temperature sensitive auditory neuropathy allele. *J Med Genet.* 2006;43: 576–81.
20. Wang D-Y, Wang Y-C, Weil D, Zhao Y-L, Rao S-Q, Zong L, et al. Screening mutations of OTOF gene in Chinese patients with auditory neuropathy, including a familial case of temperature-sensitive auditory neuropathy. *BMC Med Genet.* 2010;11:79.
21. Wynne DP, Zeng FG, Bhatt S, Michalewski HJ, Dimitrijevic A, Starr A. Loudness adaptation accompanying ribbon synapse and auditory nerve disorders. *Brain.* 2013;136: 1626–1638.
22. McMahon CM, Patuzzi RB, Gibson WPR, Sanli H. Frequency-specific electrocochleography indicates that presynaptic and postsynaptic mechanisms of auditory neuropathy exist. *Ear Hear.* 2008;29:314–25.
23. Sellick P, Patuzzi R, Robertson D. Primary afferent and cochlear nucleus contributions to extracellular potentials during tone bursts. *Hear Res.* 2003;176:42–58.
24. Santarelli R, Rossi R, Arslan E. Assistive Devices for Patients with Auditory Neuropathy: Hearing Aid Use. *Semin Hear.* 2013;34:51–64.
25. Rouillon I, Marcolla A, Roux I, Marlin S, Feldmann D, Couderc R, et al. Results of cochlear implantation in two children with mutations in the OTOF gene. *Int J Pediatr Otorhinolaryngol.* 2006;70:689–96
26. American Academy of Pediatrics, Joint Committee on Infant Hearing. Year 2007 position statement: Principles and guidelines for early hearing detection and intervention programs. *Pediatrics.* 2007;120:898–921.
27. Hille ETM, van Straaten HI, Verkerk PH, Dutch NICU Neonatal Hearing Screening Working Group. Prevalence and independent risk factors for hearing loss in NICU infants. *Acta Paediatr.* 2007;96:1155–8.
28. Xoinis K, Weirather Y, Mavoori H, Shaha SH, Iwamoto LM. Extremely low birth-weight infants are at high risk for auditory neuropathy. *J Perinatol.* 2007;27:718–23.
29. Amatuzzi M, Liberman MC, Northrop C. Selective inner hair cell loss in prematurity: a temporal bone study of infants from a neonatal intensive care unit. *J Assoc Res Otolaryngol.* 2011; 12:595–604.
30. Kraus N, Ozdamar O, Stein L, Reed N. Absent auditory brainstem response: peripheral hearing loss or brain stem dysfunction? *Laryngoscope.* 1984;94:400–6.
31. Arslan E, Turrini M, Lupi G, Genovese E, Orzan E. Hearing threshold assessment with auditory brainstem response (ABR) and ElectroCochleoGraphy (ECochG) in uncooperative children. *Scand Audiol Suppl.* 1997;46:32–7.
32. Jiang ZD, Brosi DM, Shao XM, Wilkinson AR. Sustained depression of brainstem auditory electrophysiology during the first months in term infants after perinatal asphyxia. *Clin Neurophysiol.* 2008;119:1496–1505.
33. Lin HW, Furman AC, Kujawa SG, Liberman MC. Primary neural degeneration in the Guinea pig cochlea after reversible noise-induced threshold shift. *J Assoc Res Otolaryngol.* 2011; 12:605–16.