

Utility of Tissue Doppler Imaging in the Echocardiographic Evaluation of Left and Right Ventricular Function in Dogs with Myxomatous Mitral Valve Disease with or without Pulmonary Hypertension

M. Baron Toaldo, H. Poser, G. Mencioti, S. Battaia, B. Contiero, M. Cipone, A. Diana, E. Mazzotta, and C. Guglielmini

Background: In human medicine, right ventricular (RV) functional parameters represent a tool for risk stratification in patients with congestive heart failure caused by left heart disease. Little is known about RV alterations in dogs with left-sided cardiac disorders.

Objectives: To assess RV and left ventricular (LV) function in dogs with myxomatous mitral valve disease (MMVD) with or without pulmonary hypertension (PH).

Animals: One-hundred and fourteen dogs: 28 healthy controls and 86 dogs with MMVD at different stages.

Methods: Prospective observational study. Animals were classified as healthy or having MMVD at different stages of severity and according to presence or absence of PH. Twenty-eight morphological, echo-Doppler, and tissue Doppler imaging (TDI) variables were measured and comparison among groups and correlations between LV and RV parameters were studied.

Results: No differences were found among groups regarding RV echo-Doppler and TDI variables. Sixteen significant correlations were found between RV TDI and left heart echocardiographic variables. Dogs with PH had significantly higher transmitral E wave peak velocity and higher E/e' ratio of septal (sMV) and lateral (pMV) mitral annulus. These 2 variables were found to predict presence of PH with a sensitivity of 84 and 72%, and a specificity of 71 and 80% at cut-off values of 10 and 9.33 for sMV E/e' and pMV E/e', respectively.

Conclusions and clinical importance: No association between variables of RV function and different MMVD stage and severity of PH could be detected. Some relationships were found between echocardiographic variables of right and left ventricular function.

Key words: Canine; Cardiac disease; Echocardiography; right heart; tissue velocity; Ventricular interdependence.

From the Department of Veterinary Medical Sciences, Alma Mater Studiorum – University of Bologna, Ozzano Emilia (Baron Toaldo, Battaia, Cipone, Diana); and the Department of Animal Medicine, Production and Health, University of Padova, Legnaro, Italy (Poser, Mencioti, Contiero, Mazzotta, Guglielmini). Dr Mencioti is presently affiliated with Department of Small Animal Clinical Sciences, VA-MD Regional College of Veterinary Medicine, Virginia Tech, Blacksburg, VA; Dr Battaia is presently affiliated with Ospedale Veterinario I Portoni Rossi, Zola Predosa, Bologna, Italy.

Presented in part as an abstract at the 22nd Congress of the European Society of Veterinary Internal Medicine – Companion Animals, Maastricht, Nederland, 6th–8th September 2012.

This work was done at the Department of Veterinary Medical Sciences, Alma Mater Studiorum-University of Bologna and the Department of Animal Medicine, Production and Health, University of Padova.

No grant support.

Corresponding author: M. Baron Toaldo, Department of Veterinary Medical Sciences, Alma Mater Studiorum – University of Bologna, Via Tolara di Sopra 50, 40064 Ozzano Emilia (BO), Italy; e-mail: marco.barontoaldo@unibo.it.

Submitted October 22, 2014; Revised February 2, 2016; Accepted March 7, 2016.

Copyright © 2016 The Authors. Journal of Veterinary Internal Medicine published by Wiley Periodicals, Inc. on behalf of the American College of Veterinary Internal Medicine.

This is an open access article under the terms of the Creative Commons Attribution-NonCommercial License, which permits use, distribution and reproduction in any medium, provided the original work is properly cited and is not used for commercial purposes.

DOI: 10.1111/jvim.13940

Abbreviations:

2D	2-dimensional
a'	late diastolic mitral/tricuspid annular motion
Ao	aortic root
BW	body weight
CHF	congestive heart failure
CV	coefficient of variation
CW	continuous wave
e'	early diastolic mitral/tricuspid annular motion
FS	fractional shortening
LA/Ao	left atrium to aorta diameter
LA	left atrium
LV	left ventricle
MMVD	myxomatous mitral valve disease
PASP	pulmonary artery systolic pressure
PH	pulmonary hypertension
pMV	lateral/parietal mitral valve annulus
RA	right atrium
ROC	receiver operating characteristic
RV	right ventricle
Sa	systolic mitral/tricuspid annular motion
SD	standard deviation
sMV	medial/septal mitral valve annulus
TAPSE	tricuspid annular plane systolic excursion
TDI	tissue Doppler imaging
TR	tricuspid regurgitation
TV	tricuspid valve
VI	ventricular interdependence

Myxomatous mitral valve disease (MMVD) is the most common acquired cardiac disease in dogs. Typically it is associated with left ventricular (LV) remodeling, left atrial (LA) dilatation, and eventually congestive heart failure (CHF).^{1,2} In dogs with left-sided cardiac disease, the increased LA pressure may lead to reactive pulmonary arterial vasoconstriction and finally pulmonary hypertension (PH), specifically type 2 PH.³ In the most severe cases, right ventricular (RV) failure can be the ultimate *sequela* to PH.⁴ Some studies have evaluated the prognostic value of echocardiographic parameters in dogs with preclinical and overt MMVD, mainly focusing on the assessment of the LV and LA.^{5,6} In other studies conducted in dogs with MMVD, PH was evaluated as an indicator of the progression of left-sided heart failure,⁷⁻⁹ whereas a recent study evaluated RV function in dogs with PH of different origins, regardless of underlying left-sided heart disease.¹⁰ Therefore, only a few studies have investigated RV functional and morphological alterations in dogs with predominantly left-sided heart disease, and none of these studies tried to correlate RV and LV dysfunction.¹¹

In humans, some echocardiographically derived indices of RV function have proved to be strong independent predictors of outcome and adverse events in patients with CHF caused by left heart disease.¹²⁻¹⁴ This close relationship between RV and LV function might be explained by the so called ventricular interdependence (VI) phenomenon. Ventricular interdependence is defined as the forces that are transmitted from 1 ventricle to the other through the myocardium and pericardium, independently from neural, humoral, or circulatory effects.¹⁵ This phenomenon occurs both in diastole and systole and is the consequence of the close anatomic association between the 2 ventricles. Diastolic VI is more closely related to the displacement of the interventricular septum during volume overload of 1 ventricle and by pericardial constriction, whereas systolic VI mainly is related to the myocardial contractility, particularly that of the interventricular septum.^{15,16}

The first aim of our study was to investigate LV and RV systolic and diastolic function in dogs with MMVD at different stages and to evaluate noninvasively whether a correlation between LV and RV echocardiographic parameters is present in these dogs. A second part of the study was focused on assessing which of the echocardiographic variables related to the left-sided heart function are better predictors of the presence of PH.

Materials and Methods

Animals

Dogs were evaluated at the cardiology units of the Veterinary Teaching Hospitals of the Universities of Bologna and Padova for cardiac murmurs, clinical signs attributable to heart disease, breed screening, or pre-anesthetic assessment. Dogs were prospectively recruited from January 2010 to January 2012 and included in the study if they had clinical and echocardiographic signs typical for MMVD and body weight (BW) <21 kg. Dogs with cardiac diseases other than MMVD, or noncardiac systemic comorbidities evidenced by clinical examination or hematological and biochemi-

cal analyses were not included. Dogs were allowed to receive medications for CHF if deemed necessary. Healthy dogs were recruited from students, University staff, and private owners and used as control group. Dogs were considered clinically healthy on the basis of cardiovascular examination and complete transthoracic echocardiographic and echo-Doppler examination. Reference ranges for echocardiographic measurements were derived from the veterinary literature.¹⁷

Procedures

All dogs underwent complete clinical examination and cardiac auscultation. Complete transthoracic echocardiography was performed according to standard techniques¹⁸ by 2 investigators (MBT and HP) using dedicated ultrasound units^{a,b} and continuous ECG tracing. The diagnosis of MMVD was made on the basis of clinical examination and echocardiographic criteria including thickening, prolapse or both of the mitral valve leaflets on 2-dimensional (2D) echocardiography and mitral valve insufficiency on color Doppler examination.¹⁹ Left ventricular wall thicknesses and chamber diameters were obtained from 2D-guided M-mode images acquired from a right parasternal short axis view at the level of the papillary muscles. These linear measurements (LV wall thicknesses and diameter) were compared to weight-based reference values calculated as described elsewhere.¹⁷ Left atrial and aortic root (Ao) diameter were measured on 2D images obtained from a right parasternal short axis view at the level of aortic root as previously described, and a left atrial-to-aortic diameter (LA/Ao) <1.6 was considered normal.²⁰ Left and right ventricular diastolic inflows were recorded from the left apical 4-chamber view. The sample volume of the pulsed wave Doppler was kept unchanged (2 mm width) and placed just below the atrioventricular valves in the ventricular cavity. Spectral tissue Doppler imaging (TDI) was performed at the level of the medial (sMV) and lateral (pMV) mitral annulus from a left apical 4-chamber view, whereas tricuspid annular velocity was measured only at the level of the RV free wall, after optimizing the alignment of the ultrasound beam with the myocardium as previously described.^{7,21,22} Three different waves (systolic [Sa], early diastolic [e'], and late diastolic [a']) were recognized and their peak velocities were recorded.²³ Tricuspid regurgitation (TR) was evaluated from the right parasternal short axis view at the basilar level, optimized left apical view or both, and the highest regurgitant jet velocity, measured using continuous wave (CW)-Doppler, was chosen.^{4,24,25} A velocity >2.8 m/s in the absence of pulmonic stenosis was considered indicative of PH.³ The modified Bernoulli equation then was applied to calculate the right ventricle-to-right atrium (RV-to-RA) systolic pressure gradient across the tricuspid valve; no estimated pressure of the right atrium was added to obtain the pulmonary artery systolic pressure (PASP).⁸ Presence of pulmonic stenosis was excluded on the basis of morphologically normal pulmonic valve and annulus and a peak systolic transpulmonary blood flow velocity <2.25 m/s.²⁶ Measurements derived from 3 consecutive beats were averaged for each variable. The list of the variables used for the study is shown in Table 1. Thoracic radiography was performed in each dog with MMVD and echocardiographic evidence of LA dilatation to assess the presence of CHF. Only dogs in sinus rhythm were included in the study.

According to the modified guidelines for the diagnosis and treatment of MMVD,² dogs were divided into different groups as follows: control, healthy dogs (group H); dogs having MMVD without left heart enlargement (group B1); dogs having MMVD with LV enlargement, LA enlargement or both but without clinical and radiographic evidence of CHF (group B2); dogs with symptomatic MMVD and radiographic evidence of pulmonary edema, pleural effusion or both or dogs with at least 1 confirmed episode

Table 1. Morphological, echo-Doppler, and PW-TDI variables obtained from the left and right ventricle in a population of 28 healthy dogs and 86 dogs with myxomatous mitral valve disease (MMVD) at different stages.

Variable	H (n = 28)	B1 (n = 36)	B2 (n = 28)	S (n = 22)	Overall P Value
Conventional					
LA (cm)	2.1 ± 0.53	2.2 ± 0.49	2.7 ± 0.64**,\$§	3.0 ± 0.56**,\$§,##	<.001
Ao (cm)	1.6 ± 0.38	1.6 ± 0.40	1.5 ± 0.36	1.5 ± 0.48	.661
LA/Ao	1.3 ± 0.18	1.4 ± 0.19	1.8 ± 0.17**,\$§	2.2 ± 0.50 **,\$§,##	<.001
FS (%)	34.3 ± 6.86	40.5 ± 8.52	45.9 ± 5.87**	50.1 ± 5.51**,\$§	<.001
PV vel (cm/s)	88.3 ± 14.86	91.3 ± 20.98	85.6 ± 21.14	74.9 ± 20.04	.05
TR vel (cm/s)	NA	262.8 ± 50.70	302.6 ± 58.71	349.9 ± 63.07\$§	<.001
RV-to-RA (mmHg)	NA	28.6 ± 10.06	38.0 ± 13.30	50.5 ± 18.69\$§	<.001
MV E vel (cm/s)	73.1 ± 13.95	81.4 ± 19.99	108.9 ± 32.77**,\$§	148.0 ± 28.86**,\$§,##	<.001
MV A vel (cm/s)	61.1 ± 16.77	70.9 ± 25.30	87.0 ± 16.62**	58.4 ± 12.50**,\$§	<.001
MV E/A	1.3 ± 0.32	1.2 ± 0.43	1.3 ± 0.08	1.7 ± 0.56**,\$§,##	<.001
TV E vel (cm/s)	57.8 ± 13.2	50.60 ± 12.97	54.6 ± 15.20	64.1 ± 14.32	.094
TV A vel (cm/s)	46.2 ± 15.21	49.9 ± 2.35	54.9 ± 15.58	58.4 ± 12.50	.024
TV E/A	1.3 ± 0.37	1.2 ± 0.32	1.0 ± 0.32	1.1 ± 0.27	.263
TDI					
pMV Sa (cm/s)	10.62 ± 3.05	10.3 ± 2.68	11.3 ± 2.68	11.9 ± 2.13*,\$§	.005
pMV e' (cm/s)	10.3 ± 2.63	9.6 ± 2.31	11.8 ± 1.80*,\$§	11.6 ± 2.92**,\$§	<.001
pMV a' (cm/s)	8.7 ± 2.18	11.0 ± 4.07	11.8 ± 2.05	10.2 ± 3.56	.010
pMV e'/a' (cm/s)	1.2 ± 0.48	0.9 ± 0.33	0.9 ± 0.19	1.3 ± 0.56\$§,##	<.001
pMV E/e'	7.4 ± 1.83	8.7 ± 2.32	9.9 ± 2.71	13.3 ± 4.19**,\$§,##	<.001
sMV Sa (cm/s)	9.5 ± 2.26	9.7 ± 2.35	10.8 ± 3.03	11.4 ± 2.64**	.002
sMV e' (cm/s)	7.3 ± 1.58	8.0 ± 2.38	9.0 ± 2.64	11.0 ± 3.87**,\$§	<.001
sMV a' (cm/s)	7.6 ± 1.60	8.7 ± 2.81	9.5 ± 1.88	9.4 ± 3.46	.140
sMV e'/a'	1.0 ± 0.26	1.0 ± 0.41	1.0 ± 0.27	1.2 ± 0.58	.044
sMV E/e'	10.4 ± 2.95	10.8 ± 3.23	12.3 ± 3.80	14.7 ± 4.81\$§	.006
TV Sa (cm/s)	12.7 ± 3.94	15.0 ± 3.94	15.5 ± 5.04	15.3 ± 3.90	.107
TV e' (cm/s)	9.5 ± 2.18	11.1 ± 2.47	11.1 ± 2.96	12.5 ± 3.77*	.009
TV a' (cm/s)	10.8 ± 3.07	13.4 ± 3.45	15.2 ± 3.93*	13.9 ± 4.52	.009
TV e'/a'	0.9 ± 0.18	0.8 ± 0.23	0.8 ± 0.25	1.0 ± 0.38	.046
TV E/e'	6.3 ± 1.57	5.5 ± 1.17	5.2 ± 1.67	5.7 ± 2.94	.368

Data are expressed as mean ± SD. In bold values with statistical differences.

LA, left atrium; Ao, aorta; LA/Ao, left atrium to aorta ratio; FS, fractional shortening; PV vel, pulmonic valve peak systolic velocity; TR vel, tricuspid regurgitation maximal velocity; RV, right ventricle; RA, right atrium; MV E vel, peak early diastolic mitral valve velocity; MV A vel, peak late diastolic mitral valve velocity; TV, tricuspid valve; pMV, lateral mitral valve annulus; sMV, septal mitral valve annulus; vel, velocity; Sa, systolic mitral/tricuspid annular motion; e', early diastolic mitral/tricuspid annular motion; a', late diastolic mitral/tricuspid annular motion; TDI, tissue Doppler imaging; H, healthy control group; B1, dogs with MMVD without cardiac enlargement; B2, dogs with MMVD and cardiac enlargement; S, dogs with MMVD and clinical signs due to congestive heart failure.

*P < .01 compared with group H.

**P ≤ .001 compared with group H.

\$P < .01 compared with group B1.

\$§P < .001 compared with group B1.

#P < .01 compared with group B2.

##P ≤ .001 compared with group B2.

of CHF in the past (classes C + D, named group S). From the MMVD population, only dogs having TR jet measurable using CW-Doppler, were sub-classified as group 0 (no PH) and group 1 (presence of PH).

Statistical analysis

Descriptive statistics were used for age, sex, and BW. Residual plots of all dependent variables were inspected to test the appropriateness of the linear model hypotheses. Preliminary analyses on factors and covariates to be included as predictors in the following ANCOVA model were assessed. To evaluate group effect (H, B1, B2, and S), a 1-way ANOVA was performed on the continuous variables (BW and age) and a chi-square test was performed on the percentage ratio between categorical data (sex, breed). Normal distribution of the echocardiographic, echo-Doppler, and TDI

variables was assessed using a Shapiro–Wilk test. An ANCOVA model was used to test the fixed effects of sex, breed (mixed breed vs pure breed), group of dogs, center of investigation, as well as the continuous variables BW and age on the echocardiographic, echo-Doppler, and TDI parameters. The same model was applied to test the effect of the presence (group 1) or absence (group 0) of PH on these parameters in dogs with MMVD and measurable TR.

A posthoc *t*-test with Bonferroni correction was applied. The correlation between RV-TDI variables and the other echocardiographic, echo-Doppler, and LV-TDI measurements was tested with a Pearson correlation index and considered significant for *P* < .001 and *r* > 0.3.²⁷ Data are reported as means ± standard deviation (SD).

Tissue doppler imaging variables with a significant difference between dogs with MMVD with (group 1) and without PH (group 0)

were linearly regressed against the Doppler-derived RV-to-RA systolic pressure gradient. The ability of these TDI variables to distinguish between dogs with MMVD and PH from those with MMVD without PH was evaluated by receiver operating characteristic (ROC) curve analysis. In particular, the sensitivity and specificity were calculated at various cut-off points.

All statistical analyses were performed using commercial dedicated software.^{c,d} An overall value of $P < .01$ was considered significant.

To assess interobserver measurement variability, 6 echocardiographic datasets from the same number of dogs enrolled into the study were randomly selected. For each study, 2 operators (MBT and HP) analyzed and measured the TDI variables obtained by the spectral TDI profiles recorded at the level of the sMV, pMV, and tricuspid valve (TV). The variability then was quantified for each variable as the coefficient of variation (CV) by use of the equation $CV = (\text{mean difference between measurements}/\text{mean of measurements}) \times 100$, and expressed as a percentage. The degree of variability was arbitrarily defined as follows: $CV < 5\%$, very low variability; 5–15%, low variability; 16–25%, moderate variability; or $>25\%$, high variability.²⁸

Results

General characteristic of the study population

One-hundred and fourteen dogs met the inclusion criteria. Of these dogs, 28 (24%) were clinically healthy (group H), 36 (32%) had MMVD without cardiac enlargement (group B1), 28 (25%) had MMVD with

cardiac enlargement (group B2), and 22 (19%) had symptomatic MMVD (group S). The mean age of dogs was significantly lower in group H (6.1 ± 3.4 years) compared to group S (12 ± 1.6 years; $P < .001$). Mean BW was <21 kg in dogs of groups B1, B2, and S, whereas it ranged from 3 to 33 kg in dogs of group H. Male dogs were overrepresented in groups B1, B2, and S, whereas female dogs were overrepresented in group H, but these differences were not significant. Mixed breed dogs were overrepresented, followed by miniature Poodles, Cocker Spaniels, Cavalier King Charles Spaniels, and Yorkshire terriers. However, no significant group effect was detected between mixed breed and pure breed dogs. Descriptive characteristics of the study population are summarized in Table 2.

Of the 86 dogs with MMVD, 74 had combined mitral and tricuspid regurgitation. Of these, 26 (35%) dogs did not have Doppler-derived evidence of PH (group 0), and 48 (65%) had PH (group 1). From the 74 dogs with TR, the TR peak velocity was recorded from the optimized left apical view and the right parasternal short axis view at basilar level in 72 and 2 dogs, respectively, according to the sharper Doppler profile with a higher peak velocity obtained.

All drugs used in dogs of this study that could have an impact on hemodynamic variables are listed for each group of dogs in Table 2.

Table 2. Demographic data from 114 dogs used in this study.

Variable	H	B1	B2	S	Overall P Value
No. of dogs	28	36	28	22	
Age (years)	6.1 ± 3.4	9.6 ± 3.8**	11.1 ± 2.2**	12 ± 1.6**	<.001
Body weight (kg)	13.1 ± 7.3	11.1 ± 6.2	9.3 ± 5.8	8.1 ± 4.0	.019
Sex (male/female)	11/17	20/16	16/12	14/8	.335
Breed (No. of dogs)	Mixed breed (10) Cocker Spaniel (5) Maltese, AST (2) Other breeds (9)	Mixed breed (17) Yorkshire Terrier, CKCS (3) Miniature Poodle, Epagneul Breton, English setter, Dachshund (2) Other breeds (12)	Mixed breed (15) Miniature Poodle, Maltese, Shih-tzu (2) Other breeds (20)	Mixed breed (11) Miniature Poodle, Yorkshire Terrier, Miniature Pinscher (2) Other breeds (5)	.723
Medications received (No. of dogs) [mean dose received]	None	ACE-inhibitor (1) Enalapril [0.5 mg/kg q12 h]	ACE-inhibitor (8) Benazepril [0.32 mg/kg q24 h] Ramipril [0.16 mg/kg q24 h] Pimobendan (1) [0.25 mg/kg q12 h] Spironolactone (1) [2 mg/kg q24 h] Furosemide (4) [1.1 mg/kg q12 h]	ACE-inhibitor (18) Enalapril [0.4 mg/kg q12 h] Benazepril [0.34 mg/kg q24 h] Ramipril [0.2 mg/kg q24 h] Pimobendan (14) [0.24 mg/kg q24 h] Spironolactone (2) [2.4 mg/kg q24 h] Furosemide (18) [1.9 mg/kg q12 h]	

Data are expressed as mean ± SD. In bold values with statistical differences.

H, healthy control group; B1, dogs with myxomatous mitral valve disease (MMVD) without cardiac enlargement; B2, dogs with MMVD and cardiac enlargement; S, dogs with MMVD and clinical signs due to congestive heart failure; AST, American Staffordshire Terrier; CKCS, Cavalier king Charles spaniel.

** $P < .001$ compared with group H.

Echocardiographic variables in all dogs and correlation analysis between left and right cardiac chambers variables

All of the variables were normally distributed. Six of the 13 morphological and echo-Doppler variables were significantly different (Table 1) between dogs with MMVD at different stages and healthy dogs. In particular, a progressive increase in LA dimension, fractional shortening (FS), E wave velocity, and E/A ratio from dogs of group H to those of group S was observed (overall $P < .001$ for all variables). Moreover, TR velocity and RV-to-RA systolic pressure gradient were significantly higher in dogs of group S compared to those of groups B1 ($P < .001$). No statistical difference was found regarding RV E and A waves, and their ratio, among the 4 groups of dogs.

Regarding TDI variables, pMV e' and sMV e' were significantly greater in dogs of group S compared to those of groups H and B1 (overall $P < .001$). The pMV E/e' was significantly different between dogs of group S and those of all the other groups (overall $P < .001$), whereas for sMV E/e' a significant difference was found between dogs of group S and those of group B1 ($P < .01$). Moreover, sMV Sa was higher in dogs of group S compared to those of group H ($P < .01$). Among the RV-TDI variables a significant difference was found for TVe' between the H and S groups ($P < .01$) and for TVa' between the H and B2 groups ($P < .01$).

Results of the ANCOVA model indicated a statistically significant effect of investigation center for only 2 of the 28 measured variables (i.e., MV A vel and pMV

Sa). Body weight had a significant positive effect for 4 of 28 variables (i.e., LA, Ao, pMV Sa, and sMV Sa) and significant negative effect for 1 variable (i.e., FS). Age had a significant negative effect for 3 of 28 variables (i.e., PV vel, pMVe', and pMVe'/a'). Breed significantly affected 2 variables (i.e., TVe' and TVa') with higher values in the mixed breed dogs, whereas sex had no significant effect.

The correlation analysis identified several positive and negative correlations between the 5 tested RV-TDI variables and morphological, echo-Doppler, and TDI variables of the LA and LV. Sixteen significant correlations ($P < .001$) with values of $r > 0.3$ were found between RV TDI and left heart echocardiographic variables (Table 3).

Echocardiographic variables in dogs with MMVD with or without PH and prediction of PH on the basis of LV-TDI parameters

Left atrial diameter and MV peak E wave velocity were significantly higher in dogs of group 1 compared to those of group 0. Regarding TDI parameters, values of pMV E/e' and sMV E/e' were higher in dogs of group 1 compared to those of group 0 ($P = .001$ and $P < .001$, respectively; Table 4). These 2 variables were significantly positively correlated with RV-to-RA systolic pressure gradient ($r = 0.241$ and $r = 0.339$, respectively; Fig. 1). Results of ROC curve analysis to predict the presence of PH using these 2 variables are shown in Figure 2 and listed in Table 5. The variable sMV E/e'

Table 3. Correlation analysis between RV TDI variables and left heart echocardiographic parameters in a population of 114 dogs used in this study.

Variable	TV Sa		TV e'		TV a'		TV e'/a'		TV E/e'	
	r	P	r	P	r	P	r	P	r	P
Conventional										
LA (cm)	0.262	.005	0.365	< .001	0.171	.072	0.157	.098	-0.153	.106
Ao (cm)	0.183	.054	0.161	.089	0.055	.565	0.065	.493	-0.173	.067
LA/Ao	0.090	.346	0.232	.013	0.127	.181	0.105	.271	0.022	.820
FS (%)	0.186	.050	0.227	.016	0.399	< .001	-0.192	.043	-0.023	.807
MV E vel (cm/s)	0.243	.010	0.432	< .001	0.320	.001	0.114	.229	-0.165	.083
MV A vel (cm/s)	0.196	.038	0.312	.001	0.470	< .001	-0.201	.034	-0.091	.339
TDI										
pMV Sa (cm/s)	0.432	< .001	0.446	< .001	0.275	.005	0.138	.164	-0.220	.025
pMV e' (cm/s)	0.236	.016	0.274	.005	0.071	.479	0.227	.021	0.006	.951
pMV a' (cm/s)	0.382	< .001	0.384	< .001	0.440	< .001	-0.121	.221	-0.280	.004
pMV e'/a' (cm/s)	-0.165	.095	-0.094	.344	-0.298	.002	0.255	.009	0.189	.055
pMV E/e'	0.071	.477	0.277	.004	0.225	.022	0.028	.777	-0.116	.244
sMV Sa (cm/s)	0.541	< .001	0.363	< .001	0.245	.011	0.055	.572	-0.087	.374
sMV e' (cm/s)	0.315	.001	0.418	< .001	0.065	.508	0.342	< .001	-0.143	.147
sMV a' (cm/s)	0.327	.001	0.410	< .001	0.511	< .001	-0.195	.046	-0.249	.011
sMV e'/a'	0.092	.355	0.089	.369	-0.316	.001	0.468	< .001	0.010	.921
sMV E/e'	-0.003	.980	0.118	.230	0.299	.002	-0.170	.082	-0.005	.960

In bold variables with significant correlation ($P < .001$ and $r > 0.3$).

RV, right ventricle; TDI, tissue Doppler imaging; LA, left atrium; Ao, aorta; LA/Ao, left atrium to aorta ratio; FS, fractional shortening; MV E vel, peak early diastolic mitral valve velocity; MV A vel, peak late diastolic mitral valve velocity; pMV, lateral mitral valve annulus; sMV, septal mitral valve annulus; vel, velocity; Sa, systolic mitral/tricuspid annular motion; e', early diastolic mitral/tricuspid annular motion; a', late diastolic mitral/tricuspid annular motion; TV, tricuspid valve.

Table 4. Morphological, echo-Doppler, and TDI variables obtained from the left and right ventricle in a population of 74 dogs with myxomatous mitral valve disease without (group 0) and with (group 1) pulmonary hypertension.

Variable	Group 0 (n = 26)	Group 1 (n = 48)	Overall P Value
Conventional			
LA (cm)	2.5 ± 0.67	2.7 ± 0.63	.007
Ao (cm)	1.6 ± 0.34	1.5 ± 0.39	.461
LA/Ao	1.5 ± 0.39	1.9 ± 0.49	.034
FS (%)	40.6 ± 8.23	46.7 ± 7.37	.067
PV vel (cm/s)	89.3 ± 23.72	79.4 ± 19.58	.221
TR vel (cm/s)	235.6 ± 43.32	334.6 ± 47.98	<.001
RV-to-RA (mmHg)	22.9 ± 7.24	45.7 ± 14.09	<.001
MV E vel (cm/s)	82.3 ± 24.42	124.2 ± 38.21	<.001
MV A vel (cm/s)	68.3 ± 22.55	86.7 ± 23.57	.010
MV E/A	1.2 ± 0.29	1.5 ± 0.56	.028
TV E vel (cm/s)	57.3 ± 16.44	57.8 ± 13.34	.916
TV A vel (cm/s)	48.6 ± 16.53	56.9 ± 12.35	.108
TV E/A	1.2 ± 0.35	1.0 ± 0.29	.097
TDI			
pMV Sa (cm/s)	10.7 ± 2.67	11.3 ± 2.61	.157
pMV e' (cm/s)	10.4 ± 2.67	10.8 ± 2.36	.429
pMV a' (cm/s)	11.2 ± 4.04	11.1 ± 3.32	.641
pMV e'/a' (cm/s)	1.0 ± 0.28	1.1 ± 0.47	.574
pMV E/e'	8.2 ± 1.82	11.6 ± 3.83	.001
sMV Sa (cm/s)	10.7 ± 3.32	10.6 ± 2.44	.446
sMV e' (cm/s)	9.2 ± 3.41	9.4 ± 3.08	.590
sMV a' (cm/s)	8.5 ± 2.71	9.5 ± 2.83	.182
sMV e'/a'	1.1 ± 0.39	1.0 ± 0.47	.742
sMV E/e'	9.4 ± 2.30	13.6 ± 4.09	<.001
TV Sa (cm/s)	15.6 ± 4.31	15.0 ± 4.58	.837
TV e' (cm/s)	11.4 ± 3.16	11.6 ± 3.12	.543
TV a' (cm/s)	13.1 ± 3.38	14.6 ± 4.19	.501
TV e'/a'	0.9 ± 0.28	0.8 ± 0.30	.986
TV E/e'	5.4 ± 1.79	5.3 ± 1.95	.495

Data are expressed as mean ± SD. In bold values with statistical differences.

TDI, tissue Doppler imaging; LA, left atrium; Ao, aorta; FS, fractional shortening; PV, pulmonic valve; TR, tricuspid regurgitation; RV, right ventricle; RA, right atrium; MV, mitral valve; MV E vel, peak early diastolic mitral valve velocity; MV A vel, peak late diastolic mitral valve velocity; TV, tricuspid valve; pMV, lateral mitral valve annulus; sMV, septal mitral valve annulus; vel, velocity; Sa, systolic mitral/tricuspid annular motion; e', early diastolic mitral/tricuspid annular motion; a', late diastolic mitral/tricuspid annular motion.

had the highest accuracy (area under the ROC curve = 0.820, at the threshold value of 10), whereas a slightly lower value was found for pMV E/e' (area under the ROC curve = 0.794, at the threshold value of 9.33).

Interobserver measurement variability

Interobserver measurement variability for the 9 TDI variables tested was always very low or low. The CV were as follows: <5% for pMV Sa, sMV Sa, sMV a', and all of the TV TDI variables (TV Sa, TV e', and TV a') and between 5 and 15% for pMV e', pMV a', and sMV e'.

Discussion

We evaluated different echocardiographic systolic and diastolic parameters from both ventricles in dogs with MMVD at different stages of disease, with or without PH. The major findings include: the absence of statistical difference among MMVD classes and PH groups regarding RV systo-diastolic function; the linear correlation between the analyzed echocardiographic parameters of LV and RV function; the direct correlation between some diastolic parameters of the LV (specifically the MV E/e' ratio), and the calculated RV-to-RA systolic pressure gradient.

Regarding the morphological variables of the left heart, our results are similar to those previously reported.^{5,6} The degree of LA dilatation increased with progression of the disease as expected because of the progression of MMVD and myocardial remodeling.^{5,6}

Regarding MV annulus TDI parameters, our findings are similar to previous observations reported in a similar cohort of dogs.²⁹ In particular, a progressive increase in MV e' peak velocity with the progression of disease and an increase in MV e'/a' ratio were found in the dogs of our study. The change in these diastolic parameters can be a consequence of the hyperkinetic LV that occurs secondary to mitral regurgitation, with subsequent enhanced relaxation properties and improvement in overall diastolic ventricular function.³⁰

Pulmonary hypertension might affect RV performance by increasing wall stress and decreasing systolic function.^{7,10} However, no statistical difference was found among groups regarding RV echo-Doppler and TDI parameters. Decreased tricuspid annular Sa wave velocity and decreased e'/a' ratio have been reported previously.⁷ This discrepancy can be explained by the different technique employed to measure cardiac tissue velocity,²¹ color-coded TDI and PW-TDI in the previous study and our study, respectively. Right ventricular systolic dysfunction has been identified in dogs with PH of different origin by measuring the tricuspid annular plane systolic excursion (TAPSE).¹⁰ This parameter of longitudinal RV contractility has been found to correlate with RV ejection fraction and to predict survival with good accuracy in human patients with PH.^{31,32} Conversely, no significant correlation between TAPSE and PH severity was found in dogs with MMVD,³³ but neither TAPSE nor other echocardiographic indicators of RV systolic function (e.g., the isovolumic contraction time at TDI of the TV)³¹ were measured in dogs of our study. In humans with advanced left heart failure caused by ischemic myocardial disease, dilated cardiomyopathy, or valvular regurgitation, RV dysfunction usually is present and represents an important prognostic criterion to stratify patients.^{12,13,34,35} The severely decreased LV systolic function found in human patients with left-sided cardiac disorders likely is responsible for the decreased contractile properties of the interventricular septum, which directly affect the RV function and lead to biventricular failure.^{15,16} Results of our study suggest the absence of significant right heart dysfunction even in the advanced stages of MMVD in dogs. A

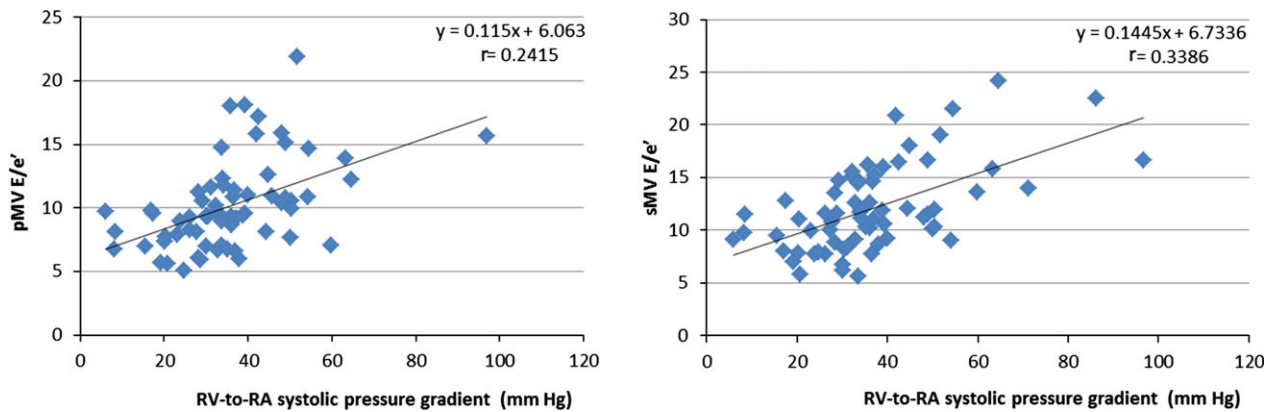


Fig 1. Regression analysis between the right ventricle-to-right atrium (RV-to-RA) systolic pressure gradient and the tissue Doppler imaging variables (**left panel**) ratio between mitral valve peak E wave velocity and mitral annular early diastolic velocity at the level of the lateral wall (pMV E/e'), and (**right panel**) ratio between mitral valve peak E wave velocity and mitral annular early diastolic velocity at the level of the interventricular septum (sMV E/e').

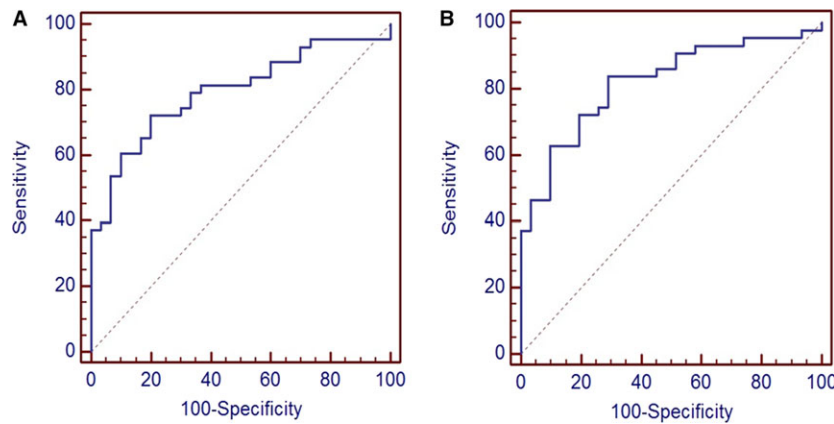


Fig 2. Receiver operating characteristic (ROC) curves of 2 tissue Doppler imaging parameters to predict presence of pulmonary hypertension in 74 dogs with myxomatous mitral valve disease and tricuspid regurgitation. (A) The ROC curve of the ratio between mitral valve peak E wave velocity and mitral annular early diastolic velocity at the level of the lateral wall (pMV E/e'). (B) The ROC curve of the ratio between mitral valve peak E wave velocity and mitral annular early diastolic velocity at the level of the lateral wall (sMV E/e').

Table 5. Sensitivity and specificity of 2 TDI left ventricular variables to predict presence of pulmonary hypertension in 79 dogs with MMVD.

Independent Variable	Area Under ROC Curves	95% CI	Cut-off Points	Se	Sp	P
sMV E/e'	0.820	0.713–0.900	≥5.6	1.00	0.00	<.001
			>10.0	0.84	0.71	
			>14.7	0.37	1.00	
pMV E/e'	0.794	0.683–0.880	≥1.7	1.00	0.00	<.001
			>9.3	0.72	0.80	
			>11.6	0.37	1.00	

In bold cut-off points with the best accuracy in predicting presence of pulmonary hypertension. TDI, tissue Doppler imaging; MMVD, myxomatous mitral valve disease; sMV, septal mitral valve annulus; pMV, parietal mitral valve annulus; ROC, receiver operating; Se, sensitivity; Sp, specificity.

certain degree of RV abnormality could have been detected by evaluating other echocardiographic parameters of myocardial function, such as TAPSE, strain, and strain rate, or using magnetic resonance imaging.

In our study, we found several significant but weak correlations between left and right echocardiographic functional parameters. In particular, the highest (i.e.,

$r > 0.4$) positive correlations were observed for the diastolic variables MV E wave peak velocity and TV e' wave peak velocity, MV A wave peak velocity and TV a' wave peak velocity, and MV and TV e' and a' waves peak velocity and their ratios (e'/a'). Moreover, a positive correlation was found between the systolic parameters of the 2 ventricles expressed by TDI annular peak

systolic velocities (Sa waves). Whether these correlations are a consequence of the mechanism of VI or secondary to the effect of the autonomic nervous system, which affects similarly both ventricles, could not be completely assessed. However, a detrimental effect on RV performance secondary to left heart failure probably is minimal or not identifiable with echocardiography in dogs with MMVD because clinically relevant systolic dysfunction rarely is observed in these dogs.¹

In our study, the TDI parameters pMV E/e' and sMV E/e' at the cut-off values of 9.33 and 10, respectively, were moderately accurate in predicting PH in dogs with MMVD and TR. Previous studies conducted in human patients and dogs with experimentally induced mitral regurgitation showed that MV E/e' ratio strongly correlates with mean LA pressure.^{29,36,37} However, this seems not to be true in dogs with naturally occurring MMVD.³⁸

Our study had some limitations. First, echocardiographic estimation of PASP was not confirmed by cardiac catheterization and direct measurement of arterial pressures. In humans, the use of Doppler-derived estimation of PASP may be inaccurate in individual patients, leading to an underestimation of actual PASP, whereas overestimation of pulmonary pressure >10 mmHg is very common.³² Therefore, PH cannot be reliably defined by a cut-off value of Doppler-derived pulmonary artery systolic pressure. Consequently, estimation of PASP based on Doppler transthoracic echocardiography measurement is not suitable for screening for mild, asymptomatic PH in people.³² Recently, echocardiographic and invasive estimation of PASP were compared in a canine model of acutely induced PH.²⁴ Despite a significant correlation between noninvasive estimates and invasive measurements of PASP, the relationship between the 2 subsets of values was highly variable.²⁴ The cut-off value of 2.8 m/s for TR peak systolic velocity has been arbitrarily proposed in veterinary medicine to diagnose PH in dogs, although it is not always accurate in predicting an actual increase in PASP.^{3,4,24} Misdiagnosis of PH in some dogs of our study could not be completely excluded and may have led to an underpowered correlation analysis. Moreover, the peak velocity of TR was recorded from the right parasternal short axis view at basilar level instead of from the optimized left apical view in 2 of 74 dogs because of higher TR peak velocity recorded from the former compared to the latter view. This approach was considered best to avoid underestimation of the RV-to-RA systolic pressure gradient because Doppler can underestimate but not overestimate blood flow velocity. Second, the echocardiographic parameters we used to assess RV performance may not have been sensitive enough to detect mild systolic dysfunction. Tricuspid annular plane systolic excursion is known to be a better indicator of decreased contractility of the RV in humans.³² However, because TAPSE is a dimensional parameter that varies among dogs according to BW, it is less suitable for a statistical comparison of a heterogeneous population of dogs of different breeds and body sizes.¹⁰ Another factor that

might have influenced our results is the effect of the drugs used for heart failure treatment on PH and ventricular function. The dogs enrolled in the study were treated following proposed guidelines for the management of MMVD.² A higher number of dogs in group 1 compared to those of group 0 received pimobendan and furosemide, because dogs in more advanced classes of heart disease are more prone to develop PH.²⁷ Pimobendan can induce pulmonary arterial vasodilatation,³⁹ but its effectiveness in decreasing PASP in dogs with MMVD is only mild.⁴⁰

Some differences in the demographic characteristics of the 4 groups (H, B1, B2, and S) might also have influenced our results. In particular, BW, age, and breed affected only 4, 3 and 2 of 28 echocardiographic parameters we investigated, respectively. Therefore, the comparison of some variables (i.e., LA, Ao, pMV Sa, sMV Sa, and FS) between group H and S should be considered with caution. Finally, dogs described in this study were enrolled at 2 different centers and were examined by 2 operators using different ultrasound units. An independent echocardiographic evaluation of a subset of dogs by each observer was not feasible. However, standardized echocardiographic scan planes were employed in each center and the ANCOVA analysis indicated a very limited center effect on the measured echocardiographic variables.

In conclusion, we were not able to identify a significant deterioration of RV systolic or diastolic function with the progression of severity class in dogs with naturally occurring MMVD and different degrees of PH. Transthoracic echocardiography appeared useful to recognize some relationships between functional variables of the RV and LV at different stages of disease.

Footnotes

^a iU22 ultrasound system, Philips Healthcare, Monza, Italy

^b Zone Ultra, Zonare, Mountain View, CA

^c SAS version 9.3, SAS Institute Inc., Cary, NC

^d MedCalc[®] version 12.6.1.0, MedCalc Software, Ostend, Belgium

Acknowledgments

Conflict of Interest Declaration: Authors declare no conflict of interest.

Off-label Antimicrobial Declaration: Authors declare no off-label use of antimicrobials.

References

- Olsen LH, Häggstrom J, Petersen HD. Acquired valvular heart disease. In: Ettinger SJ, Feldman EC, eds. *Textbook of Veterinary Internal Medicine*, 7th ed. St. Louis, MO: Saunders Elsevier; 2010:1299–1319.
- Atkins C, Bonagura J, Ettinger S, et al. Guidelines for the diagnosis and treatment of canine chronic valvular heart disease. *J Vet Intern Med* 2009;26:1142–1150.

3. Kellihan HB, Stepien RL. Pulmonary hypertension in dogs: diagnosis and therapy. *Vet Clin North Am Small Anim Pract* 2010;40:623–641.
4. Kellihan HB, Stepien RL. Pulmonary hypertension in canine degenerative mitral valve disease. *J Vet Cardiol* 2012;14:149–164.
5. Borgarelli M, Savarino P, Crosara S, et al. Survival characteristics and prognostic variables of dogs with mitral regurgitation attributable to myxomatous valve disease. *J Vet Intern Med* 2008;22:120–128.
6. Borgarelli M, Crosara S, Lamb K, et al. Survival characteristics and prognostic variables of dogs with preclinical chronic degenerative mitral valve disease attributable to myxomatous degeneration. *J Vet Intern Med* 2012;26:69–75.
7. Serres FJ, Chetboul V, Tissier R, et al. Doppler echocardiography-derived evidence of pulmonary arterial hypertension in dogs with degenerative mitral valve disease: 86 cases (2001–2005). *J Am Vet Med Assoc* 2006;229:1772–1778.
8. Stepien RL. Pulmonary arterial hypertension secondary to chronic left-sided cardiac dysfunction in dogs. *J Small Anim Pract* 2009;50:34–43.
9. Guglielmini C, Civitella C, Diana A, et al. Serum cardiac troponin I concentration in dogs with pre-capillary and post-capillary pulmonary hypertension. *J Vet Intern Med* 2010;24:145–152.
10. Pariaut R, Saelinger C, Strickland KN, et al. Tricuspid annular plane systolic excursion (TAPSE) in dogs: reference values and impact of pulmonary hypertension. *J Vet Intern Med* 2012;26:1148–1154.
11. Carlsson C, Häggström J, Eriksson A, et al. Size and shape of the right heart chambers in mitral valve regurgitation in small-breed dogs. *J Vet Intern Med* 2009;23:1007–1013.
12. Meluzin J, Spinarová L, Hude P, et al. Prognostic importance of various echocardiographic right ventricular functional parameters in patients with symptomatic heart failure. *J Am Soc Echocardiogr* 2005;18:435–444.
13. Dokainish H, Sengupta R, Patel R, et al. Usefulness of right ventricular tissue Doppler imaging to predict outcome in left ventricular heart failure independent of left ventricular diastolic function. *Am J Cardiol* 2007;99:961–965.
14. Guendouz S, Rappeneau S, Nahum J, et al. Prognostic significance and normal values of 2D strain to assess right ventricular systolic function in chronic heart failure. *Circ J* 2012;76:127–136.
15. Santamore WP, Dell'Italia LJ. Ventricular interdependence: significant left ventricular contributions to right ventricular systolic function. *Prog Cardiovasc Dis* 1998;40:289–308.
16. Taylor RR, Covell JW, Sonnenblick EH, et al. Dependence of ventricular distensibility on filling of the opposite ventricle. *Am J Physiol* 1967;213:711–718.
17. Gonçalves AC, Orton EC, Boon JA, Salman MD. Linear, logarithmic and polynomial models of M-mode echocardiographic measurements in dogs. *Am J Vet Res* 2002;7:994–999.
18. Thomas WP, Gaber CE, Jacobs GJ, et al. Recommendations for standards in transthoracic two-dimensional echocardiography in dogs and cats. *J Vet Intern Med* 1993;7:247–252.
19. Chetboul V, Tissier R. Echocardiographic assessment of canine degenerative mitral valve disease. *J Vet Cardiol* 2012;14:127–148.
20. Rishniw M, Erb HN. Evaluation of four 2-dimensional echocardiographic methods of assessing left atrial size in dogs. *J Vet Intern Med* 2000;14:429–435.
21. Wess G, Killich M, Hartmann K. Comparison of pulsed wave and color Doppler myocardial velocity imaging in healthy dogs. *J Vet Intern Med* 2010;24:360–366.
22. Visser LC, Scansen BA, Brown NV, et al. Echocardiographic assessment of right ventricular systolic function in conscious healthy dogs following a single dose of pimobendan versus atenolol. *J Vet Cardiol* 2015;17:161–172.
23. Chetboul V. Tissue Doppler imaging: a promising technique for quantifying regional myocardial function. *J Vet Cardiol* 2002;4:7–12.
24. Soydan LC, Kellihan HB, Bates ML, et al. Accuracy of Doppler echocardiography estimates of pulmonary artery pressures in a canine model of pulmonary hypertension. *J Vet Cardiol* 2015;17:13–24.
25. Boon JA. The two-dimensional echocardiographic exam. In: Boon JA, ed. *Veterinary Echocardiography*, 2nd ed. Chichester, West Sussex, UK: Wiley-Blackwell; 2011:37–99.
26. Bussadori C, Amberger C, Le Bobinec G, et al. Guidelines for the echocardiographic studies of suspected subaortic and pulmonary stenosis. *J Vet Cardiol* 2000;2:15–22.
27. Curtin F, Schulz P. Multiple correlation and Bonferroni's correction. *Biol Psychiatry* 1998;44:775–777.
28. Bland M. Clinical measurement. In: Bland M, ed. *An Introduction to Medical Statistics*, 3rd ed. Oxford, UK: Oxford University Press; 2000:268–293.
29. Tidholm A, Ljungwall I, Höglund K, et al. Tissue Doppler and strain imaging in dogs with myxomatous mitral valve disease in different stages of congestive heart failure. *J Vet Intern Med* 2009;23:1197–1207.
30. Oyama MA, Sisson DD, Bulmer BJ, et al. Echocardiographic estimation of mean left atrial pressure in a canine model of acute mitral insufficiency. *J Vet Intern Med* 2004;18:667–672.
31. Rudski LG, Lai WW, Afilalo J, et al. Guidelines for echocardiographic assessment of the right heart in adults: a report from the American society of echocardiography. *J Am Soc Echocardiogr* 2010;23:658–713.
32. Galìè N, Hoepfer MM, Humbert M, et al. Guidelines for the diagnosis and treatment of pulmonary hypertension. *Eur Heart J* 2009;30:2493–2537.
33. Tidholm A, Ljungvall I, Häggström J, et al. Diagnostic value of echocardiographic variables to identify pulmonary hypertension in dogs with myxomatous mitral valve disease. *J Vet Intern Med* 2015;29:1510–1517.
34. Dini FL, Conti U, Fontanive P, et al. Right ventricular dysfunction is a major predictor of outcome in patients with moderate to severe mitral regurgitation and left ventricular dysfunction. *Am Heart J* 2007;154:172–179.
35. Ghio S, Recusani F, Klersy C, et al. Prognostic usefulness of the tricuspid annular plane systolic excursion in patients with congestive heart failure secondary to idiopathic or ischemic dilated cardiomyopathy. *Am J Cardiol* 2000;85:837–842.
36. Nagueh SF, Middleton KJ, Kopelen HA, et al. Doppler tissue imaging: a noninvasive technique for evaluation of left ventricular relaxation and estimation of filling pressures. *J Am Coll Cardiol* 1997;30:1527–1533.
37. Ommen SR, Nishimura RA, Appleton CP, et al. Clinical utility of Doppler echocardiography and tissue Doppler imaging in the estimation of left ventricular filling pressures: a comparative simultaneous Doppler-catheterization study. *Circulation* 2000;102:1788–1794.
38. Schober KE, Hart TM, Ster JA, et al. Detection of congestive heart failure in dogs by Doppler echocardiography. *J Vet Intern Med* 2010;24:1358–1368.
39. Fuentes VL. Use of pimobendan in the management of heart failure. *Vet Clin Small Anim Pract* 2004;34:1145–1155.
40. Atkinson KJ, Fine DM, Thombs LA, et al. Evaluation of pimobendan and N-Terminal pro-brain natriuretic peptide in the treatment of pulmonary hypertension secondary to degenerative mitral valve disease in dogs. *J Vet Intern Med* 2009;23:1190–1196.