



Contents lists available at ScienceDirect

## International Journal of Surgery Case Reports

journal homepage: [www.casereports.com](http://www.casereports.com)

## Atypical localizations of calcific deposits in the shoulder

G.B. Vinanti<sup>a</sup>, D. Pavan<sup>b</sup>, A. Rossato<sup>a</sup>, Carlo Biz<sup>b,\*</sup><sup>a</sup> Saint Rocco Clinic, via dei Sabbioni 24, 25050 Ome, Brescia, Italy<sup>b</sup> Orthopaedic Clinic, Department of Surgery, Oncology and Gastroenterology DiSCOG, University of Padua, via Giustiniani 2, 35128 Padova, Italy

## ARTICLE INFO

## Article history:

Received 3 January 2015

Received in revised form 20 March 2015

Accepted 3 April 2015

Available online 8 April 2015

## Keywords:

Shoulder calcific tendinopathy

Atypical calcification

Arthroscopy

Painful shoulder

## ABSTRACT

**INTRODUCTION:** Calcific tendinopathies of the shoulder are due to inflammation around deposits of calcium within periarticular tendineal structures.

**PRESENTATION OF CASES:** We present three cases of atypical localization of calcium deposits in the shoulder. All of the cases have been treated with arthroscopic excision, followed by post-operative rehabilitation, regaining excellent results. Patients were evaluated 6 months after surgery using the Visual Analogue Scale (VAS), the Simple Shoulder Test (SST) and the UCLA modified shoulder rating.

**DISCUSSION:** Calcific tendinopathy is a self-limiting condition or is successfully treated with conservative therapy especially during the early phases of the pathology. If conservative measures fail, removal of calcium deposits is recommended. Arthroscopic management showed good results in our three cases.

**CONCLUSION:** We suggest that arthroscopic treatment of calcific tendonitis guarantees good results even when calcium deposits are in atypical locations.

© 2015 The Authors. Published by Elsevier Ltd. on behalf of Surgical Associates Ltd. This is an open access article under the CC BY-NC-ND license (<http://creativecommons.org/licenses/by-nc-nd/4.0/>).

## 1. Introduction

Calcific tendinopathies of the shoulder are due to inflammation around deposits of calcium hydroxyapatite crystals [1–8] within periarticular tendineal structures. These conditions represent 6.8% of all painful shoulders. Mean age of onset varies between 40 and 60 years [2]. Females are more affected than males (57–76%) [2] and, typically, calcifications are more frequent in the dominant shoulder. The prevalence reported of asymptomatic calcifications in the rotator cuff is about 2.7–20% [1].

The most commonly affected tendon is the supraspinatus tendon at about 1.5 cm from its insertion on the humerus trochanter (critical zone), being involved in 51–82% of cases. More rarely, it is located on the infraspinatus (15–30%), the subscapularis (10%), or the teres minor (<10%). Calcifications in the region of the long head of the biceps tendon have rarely been detected [3].

We present the case reports of three patients with calcium deposits in atypical locations of the shoulder.

## 2. Presentation of cases

## 2.1. Case 1

A 48-year-old woman, a professional teacher, had experienced pain in her right (dominant) shoulder for 11 years with exacer-

bation of symptoms in the two months prior to the first visit and severe functional impotence. The MRI showed a massive shoulder calcium deposit in the supraspinatus muscle belly and widespread hypertrophic subacromial bursitis (Fig. 1a and b). The patient underwent a series of 10 sessions of physiokinetic therapy to improve the static and dynamic scapular posture, with the recovery of the propriocectivity, and manual treatment of contractures affecting cervical paravertebral muscles and the scapular elevator muscle. Furthermore, she underwent a series of local physical therapy, including tecar (capacitive and resistive energy transfer) therapy and ultrasound during 8 sessions and an infiltration of Depomedrol. After the failure of the conservative therapy and the persistence of pain and functional impotence, surgery was carried out. Arthroscopic surgery was then performed to remove the calcium deposit from the muscle belly and for bursectomy (Fig. 2a–c). Post-operatively, the patient wore a brace for the shoulder in abduction of 15° for 14 days with gradual removal for 10 additional days and started a program of assisted physiotherapy from the 5th post-operative day. The physical therapy included articular mobilization of the shoulder and shoulder girdle, assisted mobilization of the shoulder, manual therapy, reinforcement exercises of the periscapular muscles and active mobilization of the elbow and wrist. Later, starting from the 9th week, the intensity of muscular work was increased by the introduction of resistance exercises, water exercises, spiral movements, enhancement of the frequency of the therapeutic exercise, perturbed closed kinetic chain exercises, standing on unstable surfaces, throwing, dynamic stabilization, reproduction of specific gestures, and swimming.

\* Corresponding author. Tel.: +39 049 8211209/3239.

E-mail addresses: [gbvinanti@tin.it](mailto:gbvinanti@tin.it) (G.B. Vinanti), [dadepava@hotmail.it](mailto:dadepava@hotmail.it) (D. Pavan), [rossatoalberto@virgilio.it](mailto:rossatoalberto@virgilio.it) (A. Rossato), [carlo.biz@unipd.it](mailto:carlo.biz@unipd.it) (C. Biz).

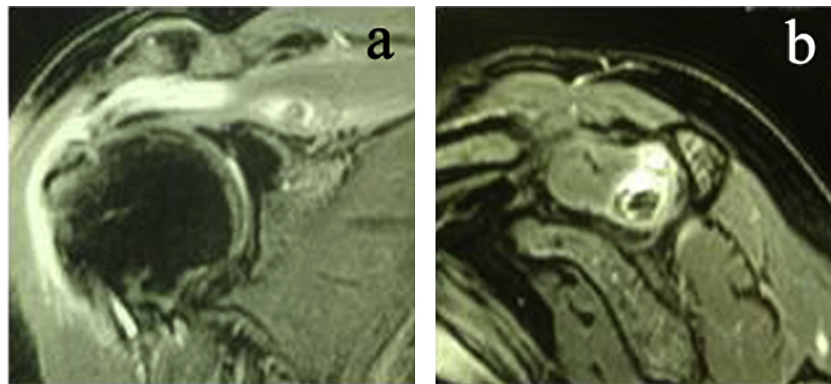


Fig. 1. (a, b) MRI images of calcific supraspinatus intramuscular deposit.

2.2. Case 2

A 58-year-old businessman, who practiced sports (body-building, fitness and skiing), had experienced pain in his left (non-dominant) shoulder for about 6 months, especially at night and during movements of abduction. Clinical evaluation revealed a diagnosis compatible with supraspinatus insertional pain and suffering of the long head of the biceps. X-ray and MRI showed a lesion of the supraspinatus and the presence of a calcium deposit located in the biceps anchor (Fig. 2e and f). The patient underwent a series of 12 sessions of physiokinetic therapy to improve the static and dynamic scapular posture, achieving the recovery of the proprioceptivity. Furthermore, he underwent a series of local physical therapy (laser therapy and ultrasound) during 6 sessions and an infiltration of Depomedrol followed by 3 infiltrations of low molecular weight hyaluronic acid. After the failure of the conservative therapy and the persistence of pain and functional impotence, arthroscopic surgery was carried out on the tenotomy of the long

head of the biceps, as well as removal of the calcium deposit associated with reconnection of the supraspinatus with two metal anchors (Fig. 3b–e). Post-operatively, the patient wore a brace for his shoulder in abduction of 15° for 34 days with a gradual removal in the subsequent 10 days. He began a program of assisted physiotherapy from the 20th post-operative day, according to the same protocol described in the previous case. The post-operative X-ray showed the disappearance of the calcification and the presence of two metal screws (Fig. 3f).

2.3. Case 3

A 43-year-old woman, a professional agent, who practiced sports (swimming and cycling), had experienced pain in her right (dominant) shoulder for about 4 months, especially at night and in the movements of internal rotation of the shoulder. The MRI showed the presence of a massive calcium deposit in the most cranial intra-articular component of the subscapularis tendon (Fig. 4a

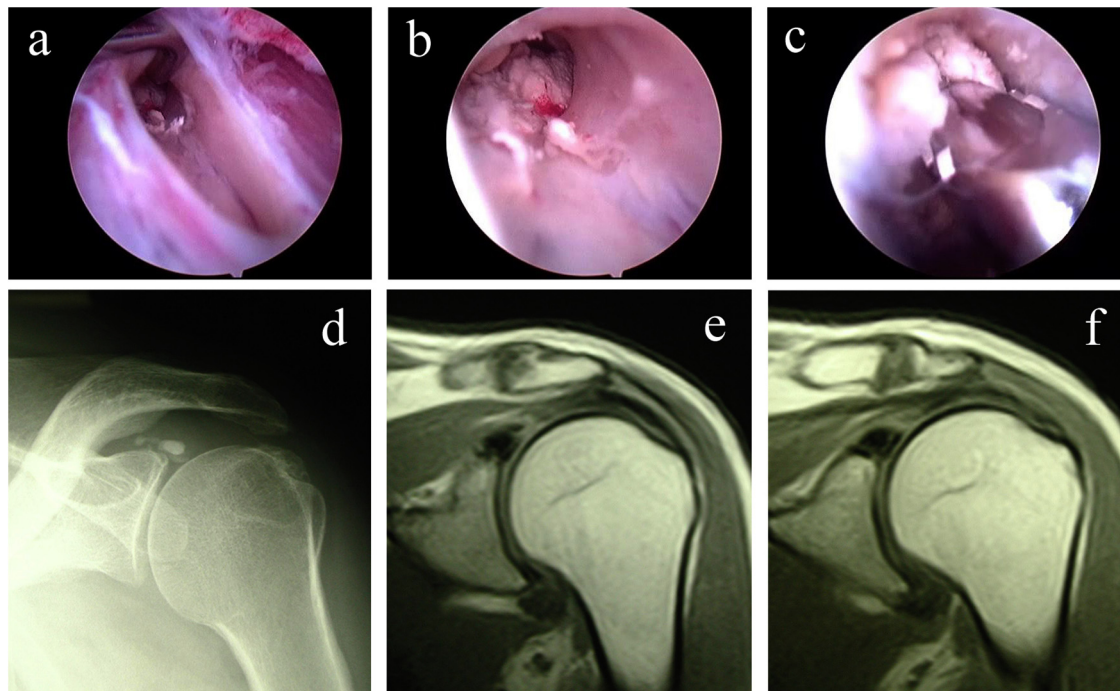
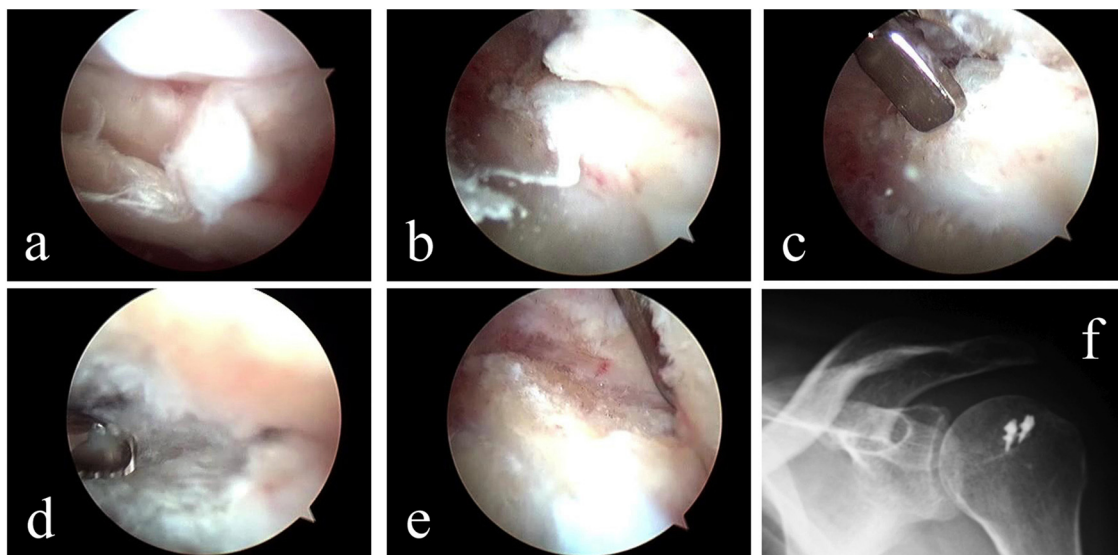


Fig. 2. (a) Arthroscopic image of the bursal side of the supraspinatus muscle: with the aid of a tracer, introduced from the posterior access port with a lateral optical port, the intramuscular space that contains the calcium deposit is detected after performing an accurate bursectomy using a motorized shaver. In this picture, the calcium deposit is visible below the tip of the tracer. (b) Intramuscular arthroscopic image: the calcium deposit can be identified. (c) Intramuscular arthroscopic image: procedure for the removal of the calcium deposit using motorized drill. (d) X-ray of calcification at the biceps anchor. (e, f) MRI pictures of calcification in the bicipital anchor.

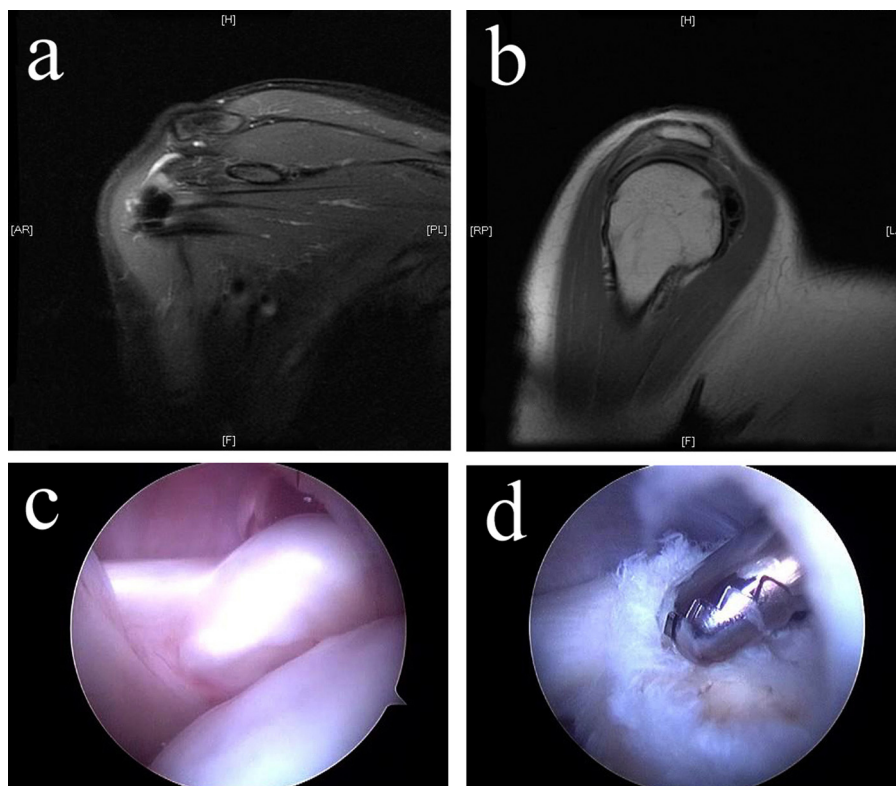


**Fig. 3.** (a) Intra-articular arthroscopic image: there is a massive flap of supraspinatus tendon and a partial lesion of the long head of the biceps. (b) Calcified deposit that tends to emerge from the place of collection. (c) The most superficial portion of the cranial superior labrum is removed using the basket. (d) The removal of the calcified deposit is completed with motorized drill. (e) Final vision after completing the removal of the calcium deposit. (f) The post-operative X-ray shows the complete removal of the calcium deposit.

and b). At first, the treatment chosen was physiokinetic therapy associated with a course of injections with hyaluronic acid, resulting in only partial benefit. Therefore, arthroscopic surgery was proposed for the removal of the calcium intratendinous deposit. Arthroscopic examination revealed a non-conventional localization of the calcium deposit at the cranial extremity of the subscapularis resulting in a bulge of its profile, highly-visible in the intra-articular section of the tendon (Fig. 4c and d). Post-

operatively, the patient wore a brace for her shoulder in abduction of 15° for 16 days with gradual removal for an additional 10 days and started a program of assisted physiotherapy from the 4th post-operative day.

All surgeries were performed by the same surgeon (V.GB.) using the arthroscopic technique. For the evaluation of the results, measures used included the Visual Analogue Scale (VAS), the Simple Shoulder Test (SST), and the Modified UCLA Rating Scale.



**Fig. 4.** (a, b) Picture of the intratendineal calcification MRI of the subscapularis. (c) Intra-articular arthroscopic image: there is a noticeable swelling at the cranial extremity of the subscapularis caused by a calcium deposit. (d) Using motorized drill for complete removal of the calcium deposit.

**Table 1**

Pre-operative evaluation. Data show a severe deficiency in terms of pain and function. VAS is a visual pain scale that goes from 0 (absence of pain) to 10 (maximum pain). SST is a dichotomous functional scale with a total score of 12 items: 2 concerning function related to pain, 7 concerning function/strength, and 3 concerning range of motion. A score of 12 indicates preserved function, while a score of 0 indicates completely eliminated function. The Modified UCLA Rating Scale has a maximum score of 35 points to investigate pain, active forward flexion, strength of forward flexion, function, and satisfaction of the patient. A score <27 (fair/poor) stands for unsatisfactory results while a score >27 good/excellent stands for satisfactory results.

	VAS	SST	Modified UCLA
Case 1	10	5	11
Case 2	8	6	13
Case 3	9	5	14

**Table 2**

Post-operative evaluation. Data show a complete healing in terms of pain and function. VAS is a visual pain scale that goes from 0 (absence of pain) to 10 (maximum pain). SST is a dichotomous functional scale with a total score of 12 items: 2 concerning function related to pain, 7 concerning function/strength and 3 concerning range of motion. A score of 12 indicates preserved function while a score of 0 indicates completely eliminated function. The Modified UCLA Rating Scale has a maximum score of 35 points to investigate pain, active forward flexion, strength of forward flexion, function, and satisfaction of the patient. A score <27 (fair/poor) stands for unsatisfactory results while a score >27 good/excellent stands for satisfactory results.

	VAS	SST	Modified UCLA
Case 1	0	12	35
Case 2	0	12	34
Case 3	1	12	35

Pre-operative evaluation (Table 1) showed severe pain in all three cases (values from 8 to 10 of the VAS) and moderate-severe dysfunction of the shoulder (values 5 or 6 of the SST). The Modified UCLA Rating Scale indicated very unsatisfactory results in terms of pain, active forward flexion, strength of forward flexion, function and satisfaction of the patients. Post-operative evaluation (Table 2) was performed at 6 months after surgery. The pain almost totally regressed (values 0 or 1 of the VAS), and function was completely regained as shown by SST. All items analysed in the Modified UCLA Rating Scale indicated very satisfactory results in all three patients.

### 3. Discussion

The calcification of the rotator cuff is due to the deposition of hydroxyapatite crystals. Pathogenesis of calcifications is still under discussion and several classifications are available to describe it [1,8,9]. Uththoff and colleagues [4] described precalcific, calcific, and postcalcific stages. During the precalcific stage, there is a fibrous metaplasia of the tenocytes, and avascular areas are detectable. The calcific stage consists of three phases: formative, resting, and resorptive. Formative and resting phases are chronic, and the deposition of calcium crystals can lead to an impingement syndrome because of a focal thickening of the tendon. During the resorptive phase, the spontaneous reabsorption of calcium takes place, and patients can manifest an acute inflammatory syndrome caused by the spread of calcium crystals at the level of the near subacromial bursa inside the tendons or even in the adjacent bone. Finally, during the postcalcific stage, the repair of the tendon takes place by the remodelling by fibroblasts and the development of new vascular canals.

Often, calcific tendinopathy is a self-limiting condition or is successfully treated with conservative therapy. During the formation and resting phases of the pathology, conservative treatment is to be preferred at first; it includes therapeutic exercise, analgesic drugs like NSAIDs, infiltrations of steroids, and shock wave therapy. At present, ultrasound-guided washing [6] is used. If

conservative measures fail, removal of calcium deposits is recommended [7]. The arthroscopic treatment showed good results with significant improvement in shoulder functionality after 24 months and a progressive decrease of pain levels up to one year after surgical procedure. Soft-tissue needle-sparing and intraoperative use of fluoroscopy is a conventional method for removing calcific deposits; however, it would be difficult when the calcific deposits are diffusely and extensively present in the tendons. This technique would also result in a large rotator cuff tear and long exposure to ionizing radiation. In these cases, a complete removal of the calcifications through a surgical incision at the tendon insertions could be performed, ensuring that no residual calcified deposits remain, and subsequently the detached tendons would have to be repaired using the suture-anchor technique [10].

Our study presents three cases of calcific tendonitis in atypical locations. Only a few case reports have described the surgical treatment of calcifying tendonitis of the subscapularis tendon [10,11] and the biceps anchor [12,13]. In these cases, conservative treatment (such as nonsteroidal anti-inflammatory drugs, physical therapy, and subacromial steroid injections) was performed without benefit, while the complete arthroscopic removal of calcific deposits with the eventual subsequent repair of the detached tendons lead to a good long-time clinical outcome. To the best of our knowledge, no cases of calcifications in the supraspinatus muscle belly have been reported previously. We believe that such a calcification could be due to a previous traumatic or microtraumatic damage of the supraspinatus muscle belly followed by the deposition of calcium crystals within the hematoma that developed after the trauma. Arthroscopic management showed effectiveness also in these cases.

### 4. Conclusion

We believe that calcific tendinopathy, if not responsive to conservative treatment, should be treated surgically, even in cases in which the calcification is located in unconventional positions. As shown in our studies, the complete surgical removal of the deposit, performed arthroscopically, is able to ensure an optimal clinical outcome both in terms of pain and functionality.

### Conflict of interest

The authors declare that they have no conflict of interest related to the publication of this manuscript, and they have not received benefits or financial funds in support of this study.

### Sources of funding

The authors declare that they have no conflict of interest related to the publication of this manuscript, and they have not received benefits or financial funds in support of this study.

### Ethical approval

As it is a case report series, only the patients gave their oral and written consent to be included in this report.

### Consent

The patients gave their oral and written consent to be included in this report as well as for publication of these cases, anonymous data and pictures.

**Author's contribution**

G.B. Vinanti: study concept and design.  
 D. Pavan: data collection.  
 A. Rossato: writing the paper.  
 C. Biz: data analysis and interpretation.

**Guarantor**

All the authors G.B. Vinanti, D. Pavan, A. Rossato and C. Biz accept full responsibility for the work and/or the conduct of the study, had access to the data, and controlled the decision to publish. They declare that this case report series represents honest work.

**Manuscript approval**

The manuscript has been read and approved by all the authors: G.B. Vinanti, D. Pavan, A. Rossato and C. Biz.

**Manuscript authenticity**

We declare that this article represents honest work.

**References**

- [1] F. Ioppolo, M. Tattoli, L. Di Sante, T. Venditto, L. Tognolo, M. Delicata, R.S. Rizzo, G. Di Tanna, V. Santilli, Clinical improvement and resorption of calcifications in calcific tendinitis of the shoulder after shock wave therapy at 6 months' follow-up: a systematic review and meta-analysis, *Arch. Phys. Med. Rehabil.* 94 (September (9)) (2013) 1699–1706.
- [2] N.J. Bureau, Calcific tendinopathy of the shoulder, *Semin. Musculoskelet. Radiol.* 17 (February (1)) (2013) 80–84.
- [3] A.B. Goldman, Calcific tendinitis of the long head of the biceps Brachii distal to the glenohumeral Joint, *AJR Am. J. Roentgenol.* 153 (November (5)) (1989) 1011–1016.
- [4] H.K. Uhtoff, J.F. Loehr, Calcifying tendinitis, in: C.A. Rocwood, F.A. Matsen III (Eds.), *The Shoulder*, Saunders Company, Philadelphia, 1998, pp.971–991.
- [5] C.R. Garcia, J.S. Scibek, Causation and management of calcific tendonitis and peri-arthritis, *Curr. Opin. Rheumatol.* 25 (March (2)) (2013) 204–209.
- [6] L.M. Sconfienza, S. Viganò, C. Martini, A. Aliprandi, P. Randelli, G. Serafini, F. Sardanelli, Double-needle ultrasound-guided percutaneous treatment of rotator cuff calcific tendinitis: tips & tricks, *Skeletal Radiol.* 42 (January (1)) (2013) 19–24.
- [7] D. Maier, M. Jaeger, K. Izadpanah, N.P. Suedkamp, P. Ogon, Arthroscopic treatment of calcific tendinitis of the shoulder, *Am. J. Sports Med.* 40 (July (7)) (2012) NP12–3, <http://dx.doi.org/10.1177/0363546512453459>, author reply NP13.
- [8] F. Oliva, A.G. Via, N. Maffulli, Physiopathology of intratendinous calcific deposition, *BMC Med.* 10 (1) (2012) 95.
- [9] J. Gärtner, B. Simons, Analysis of calcific deposits in calcifying tendinitis, *Clin. Orthop. Relat. Res.* 254 (1990) 111–112.
- [10] Y. Mitsui, M. Gotoh, R. Tanesue, I. Shirachi, H. Shibata, K. Nakama, T. Okawa, F. Higuchi, K. Nagata, Calcific tendonitis of the rotator cuff: an unusual case, *Case Rep. Orthop.* 2012 (2012) 806769, <http://dx.doi.org/10.1155/2012/806769>, Epub 2012 Mar 24.
- [11] F. Franceschi, U.G. Longo, L. Ruzzini, G. Rizzello, V. Denaro, Arthroscopic management of calcific tendinitis of the subscapularis tendon, *Knee Surg. Sports Traumatol. Arthrosc.* 15 (December (12)) (2007) 1482–1485, Epub 2007 May 12.
- [12] J.H. Ji, M. Shafi, W.Y. Kim, Calcific tendinitis of the biceps-labral complex: a rare cause of acute shoulder pain, *Acta Orthop. Belg.* 74 (June (3)) (2008) 401–404.
- [13] K.C. Kim, K.J. Rhee, H.D. Shin, Y.M. Kim, A SLAP lesion associated with calcific tendinitis of the long head of the biceps brachii at its origin, *Knee Surg. Sports Traumatol. Arthrosc.* 15 (December (12)) (2007) 1478–1481, Epub 2007 Apr 25.

**Open Access**

This article is published Open Access at [sciedirect.com](http://sciedirect.com). It is distributed under the [IJSCR Supplemental terms and conditions](#), which permits unrestricted non commercial use, distribution, and reproduction in any medium, provided the original authors and source are credited.