

*Università degli Studi di Padova*

*Padua Research Archive - Institutional Repository*

Munchausen's Syndrome in Plastic Surgery: An Interdisciplinary Challenge

*Original Citation:*

*Availability:*

This version is available at: 11577/3192056 since: 2016-07-08T11:20:46Z

*Publisher:*

*Published version:*

DOI: 10.1097/GOX.0000000000000378

*Terms of use:*

This article is made available under terms and conditions applicable to Open Access Guidelines, as described at <http://www.unipd.it/download/file/fid/55401> (Italian only)

(Article begins on next page)

# Munchausen's Syndrome in Plastic Surgery: An Interdisciplinary Challenge

Chiara Pavan, MD, PhD\*  
 Carlotta Scarpa, MD, PhD†  
 Franco Bassetto, MD‡  
 Mariafrancesca Azzi, MD\*  
 Vincenzo Vindigni, MD,  
 PhD‡

**Summary:** Munchausen's syndrome is a rare psychiatric disease. We report a case in which we have collaborated with the psychiatrist for the diagnosis and also propose a diagnostic flowchart. (*Plast Reconstr Surg Glob Open* 2015;3:e428; doi: 10.1097/GOX.0000000000000378; Published online 22 June 2015.)

**W**e report a case of a young man recurrently hospitalized in Plastic Surgery Unit for chronic skin ulcer and osteomyelitis of lower limbs that led to several surgical treatments ending in amputation of the left leg (Figs. 1 and 2). During the admission, a nurse surprised him tampering with the gauzes and injecting sodium hypochlorite into the contralateral leg. Since that moment, we suspected Munchausen's syndrome.

We performed a psychiatric evaluation based on MINI International Neuropsychiatric Interview, Rorschach Test, and Minnesota Multiphasic Personality Inventory (MMPI).

MINI International Neuropsychiatric Interview resulted positive only for a major depressive episode at 20 years old.

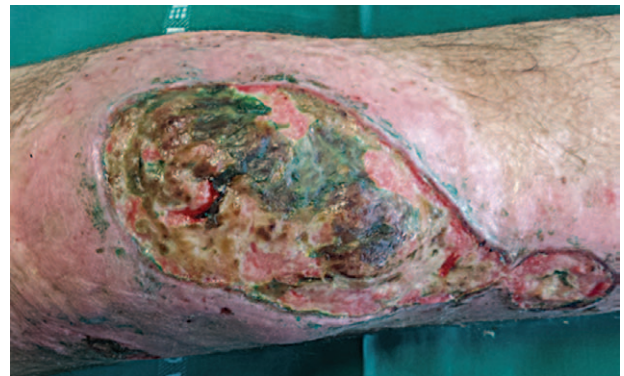On the MMPI, he scored high on hypochondriasis, hysteria, Social Introversion, and depression scales. MMPI often shows elevations on the hysteria and hypochondriasis scales; together, these constitute somatization defined as patients converting emotional distress into bodily complaints.

*From the \*Unit of Psychiatry, Department of Neurosciences NPSRR, University of Padova, Padova, Italy; †Unit of Plastic Surgery, Department of Neurosciences NPSRR, University of Padova, Padova, Italy; and ‡Unit of Plastic Surgery, Department of Neurosciences NPSRR, University of Padova, Padova, Italy.*

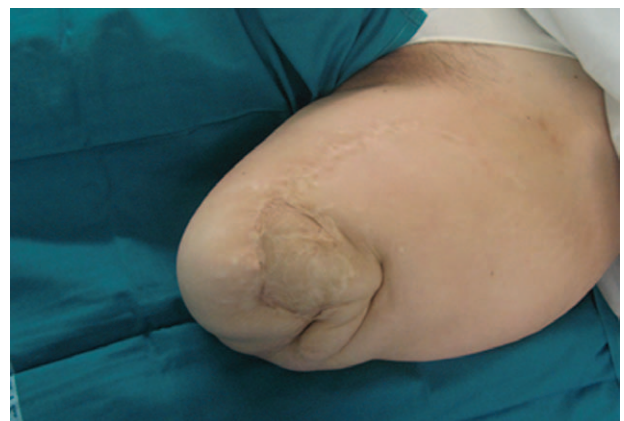*Received for publication November 19, 2014; accepted April 13, 2015.*

*Copyright © 2015 The Authors. Published by Wolters Kluwer Health, Inc. on behalf of The American Society of Plastic Surgeons. All rights reserved. This is an open-access article distributed under the terms of the Creative Commons Attribution-NonCommercial-NoDerivatives 3.0 License, where it is permissible to download and share the work provided it is properly cited. The work cannot be changed in any way or used commercially.*

DOI: 10.1097/GOX.0000000000000378

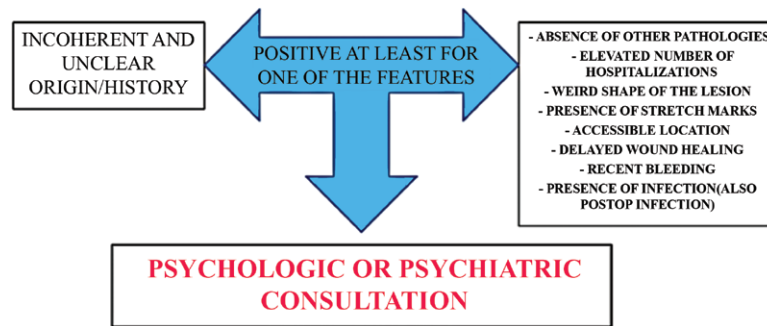


**Fig. 1.** Chronic nonhealing skin ulcer of the left knee. The green color of the necrotic tissue suggests an improbable correlation with common causes of skin ulcer. The perfect design of the margins of the ulcer could reveal an iatrogenic cause.



**Fig. 2.** The left lower limb was amputated.

**Disclosure:** The authors have no financial interest to declare in relation to the content of this article. The Article Processing Charge was paid for by the authors.



**Fig. 3.** Flowchart for early recognition and management of Munchausen's syndrome.

The Rorschach protocol showed a low productivity and aspects of insecurity. The global cognitive functioning was unstable.

The affections appeared poorly controlled by rationality, and the subject presented aspects of lability with a depressive core base. The prevailing relational methods seemed to fit an archaic level, which was dominated by symbiotic needs, dependency, and passivity. The impulsiveness and aggressiveness were expressed intensely linked to the oral phase of psychoaffective development. The aggressiveness was unconsciously directed toward self, and it highlights a risk of acting out in the sense of an aggressive attack against the body. The data set highlighted a psychotic mental functioning, with adaptive-conformist (that justified the “good” global performance at MMPI), dependent and passive-aggressive traits which never did lead to clinically psychotic positive symptoms.

### DISCUSSION

Munchausen's syndrome is described as a factitious disorder. For a correct diagnosis, we can distinguish it from the other disorders considering the consciousness of the patient, the intentional production or feigning of physical or psychological signs or symptoms, and the absence of an economical interest.<sup>1,2</sup> Munchausen's syndrome affects more women than men (20:1), with prevalence ranging from 0.3% to 0.8% and a high rate of suicide (30–70%).<sup>3,4</sup> The patients are also described as mentally affected by dependency needs, low self-esteem, social isolation, history of depression, personality disorders, and element of unconscious sadomasochism.<sup>3,5</sup>

It has been reported<sup>6</sup> that the patient takes 2 approaches: (1) a sadistic one from which he/she derives satisfaction and (2) a masochistic one that drives him/her to continuous hospitalization.

The factitious disorder can be present in any surgical and medical specialization, but it is difficult to diagnose and treat, increasing the financial costs of the hospital and the morbidity/mortality of the

patients.<sup>1–14</sup> Of course, even if the patient is often an “enemy” for the surgeon, the clinical history of the injury should allow the correct diagnosis and treatment, but, in our opinion, it should also allow early recognition of the factitious disorder.

From the psychological point of view, this is the first patient who was evaluated with Rorschach test, and the characteristics found seem to confirm the hypothesis that considered Munchausen's syndrome a type of personality disorder needing both surgical and psychiatric treatment, as we have summarized in the flowchart (Fig. 3).

Considering the economic impact resulting from a late diagnosis, it is required to take into consideration a factitious disorder whenever there is no correspondence between the signs and symptoms. For this reason, in our opinion, an interdisciplinary treatment, with the psychiatrist as the point of reference of all therapy, is absolutely mandatory.

### SUMMARY

Munchausen's syndrome is a rare psychiatric disease. We report a case in which we have collaborated with the psychiatrist for the diagnosis and also propose a diagnostic flowchart.

**Carlotta Scarpa, MD, PhD**  
Cannaregio 2649  
30121 Venezia, Italy  
E-mail: carlotsc@tin.it

### REFERENCES

1. Canogullari G, Ulupinar E, Teyin M, et al. A forensic case of Munchausen's syndrome. *J Forensic Leg Med.* 2007;14:167–171.
2. Eisendrath SJ, Telischak KS. Factitious disorders: potential litigation risks for plastic surgeons. *Ann Plast Surg.* 2008;60:64–69.
3. Lad SP, Jobe KW, Polley J, et al. Munchausen's syndrome in neurosurgery: report of two cases and review of the literature. *Neurosurgery* 2004;55:1436.
4. Schober P, Schwarte LA, Boer C, et al. Fatal outcome of Munchausen's syndrome. *Resuscitation* 2008;78:99–100.

5. Lazzeri D, Romeo G, De Rosa M, et al. Plastic surgery and Munchausen's syndrome: 'surgeon, beware!'. *J Plast Reconstr Aesthet Surg*. 2010;63:e319–e320.
6. Nardella D, Sohawon MS, Heymans O. Munchausen's syndrome in plastic surgery practice: a bewildering situation! *Indian J Plast Surg*. 2007;40:194–198.
7. Acartürk TO, Abdel-Motleb M, Acar F. How to kill a flap: Munchausen syndrome—a silent trap for plastic surgeons. *J Hand Microsurg*. 2014;6:42–44.
8. Lin JL, Servat JJ, Bernardino CR, et al. Bilateral corneal perforations and autoproposis as self-induced manifestations of ocular Munchausen's syndrome. *Orbit* 2012;31:252–255.
9. Livaoglu M, Kerimoglu S, Hocaoglu C, et al. Munchausen's syndrome: a rare self-mutilation syndrome. *Dermatol Surg*. 2008;34:1288–1291.
10. Lauwers R, Van De Winkel N, Vanderbruggen N, et al. Munchausen syndrome in the emergency department mostly difficult, sometimes easy to diagnose: a case report and review of the literature. *World J Emerg Surg*. 2009;4:38.
11. Hagglund LA. Challenges in the treatment of factitious disorder: a case study. *Arch Psychiatr Nurs*. 2009;23:58–64.
12. Anderson LG. Munchausen syndrome: hospital hobo of the 1990s. *Plast Surg Nurs*. 1994;14:220–224, 230.
13. de Fontaine S, Van Geertruyden J, Preud'homme X, et al. Munchausen syndrome. *Ann Plast Surg*. 2001;46:153–158.
14. Ryan CJ, Shaw T. BIID is not BDD—comment on Kwok-Kwan Chan *et al*. *J Plast Reconstr Aesthet Surg*. 2011;64:8–9; discussion 9–10.