



106th Congress of the Italian Society of Otorhinolaryngology Head and Neck Surgery

Official report

Edited by E. Zanoletti, A. Mazzoni, A. Martini

Editorial Committee: G. Marioni, D. Cazzador, L. Girasoli

Surgery of the lateral skull base: a 50-year endeavour

Chirurgia della base del cranio laterale: 50 anni di impegno

E. Zanoletti, A. Mazzoni, A. Martini, R.V. Abbritti, R. Albertini, E. Alexandre, V. Baro, S. Bartolini, D. Bernardeschi, R. Bivona, M. Bonali, I. Borghesi, D. Borsetto, R. Bovo, M. Breun, F. Calbucci, M.L. Carlson, A. Caruso, P. Cayé-Thomasen, D. Cazzador, P.-O. Champagne, R. Colangeli, G. Conte, D. d'Avella, G. Danesi, L. Deantonio, L. Denaro, F. Di Berardino, R. Draghi, F.H. Ebner, N. Favaretto, G. Ferri, A. Fioravanti, S. Froelich, A. Giannuzzi, L. Girasoli, B.R. Grossardt, M. Guidi, R. Hagen, S. Hanakita, D.G. Hardy, V.C. Iglesias, S. Jefferies, H. Jia, M. Kalamarides, I.N. Kanaan, M. Krengli, A. Landi, L. Lauda, D. Lepera, S. Lieber, S.L.K. Lloyd, A. Lovato, F. Maccarrone, R. Macfarlane, J. Magnan, L. Magnoni, D. Marchioni, J.P. Marinelli, G. Marioni, V. Mastronardi, C. Matthies, D.A. Moffat, S. Munari, M. Nardone, R. Pareschi, C. Pavone, E. Piccirillo, G. Piras, L. Presutti, G. Restivo, M. Reznitsky, E. Roca, A. Russo, M. Sanna, L. Sartori, M. Scheich, W. Shehata-Dieler, D. Soloperto, F. Sorrentino, O. Sterkers, A. Taibah, M. Tatagiba, G. Tealdo, D. Vlad, H. Wu, D. Zanetti




PACINI
EDITORE
MEDICINA

Volume 39 • Supplement 1
June 2019

3

www.actaitalica.it



*Official Journal of the Italian Society
of Otorhinolaryngology Head and Neck Surgery*
Organo Ufficiale della Società Italiana
di Otorinolaringoiatria e Chirurgia Cervico-Facciale

Former Editors-in-Chief:

C. Calearo, E. de Campora, A. Staffieri, M. Piemonte, F. Chiesa, G. Paludetti

Italian Scientific Board

M. Alicandri-Ciuffelli
Policlinico, Modena
G. Bellocchi
Ospedale "San Camillo", Roma
A. Bertolin
Presidio Ospedaliero, Vittorio Veneto
F. Dispenza
Policlinico "Paolo Giaccone", Palermo
M. Falcioni
Azienda Ospedaliera, Parma
F. Fiorino
Ospedale "Mater Salutis", Legnago
J. Galli
Policlinico Gemelli, Roma
G. Giourgos
Ospedale "Papa Giovanni XXIII", Bergamo
A. Greco
Policlinico "Umberto I", Roma
G. Marioni
Azienda Ospedaliera, Padova
A. Murri
Ospedale "Guglielmo Da Saliceto", Piacenza
P. Petrone
Ospedale "San Giacomo", Monopoli
C. Piazza
Istituto Nazionale dei Tumori, Milano
N.A.A. Quaranta
Policlinico, Bari
R. Teggi
Ospedale "San Raffaele", Milano
D. Testa
Seconda Università, Napoli

International Scientific Board

J. Betka
Charles University, Prague Czech Republic
P. Clement
ENT Department, University Hospital, Brussels, Belgium
M. Pais Clemente
Department of Otolaryngology, University of Porto, Portugal
R.W. Gilbert
Otolaryngology H&N Surgery, University of Toronto, Canada
M. Halmagyi
Royal Prince Alfred Hospital, Camperdown, Australia
L.P. Kowalski
A C Camargo Cancer Center, Sao Paulo, Brazil
R. Laszig
Universitäts-HNO-Klinik, Freiburg, Germany
C.R. Leemans
VU University Medical Center, Amsterdam, The Netherlands
F. Marchal
Hopitaux Universitaires, Geneva, Switzerland
G. O'Donoghue
ENT Department, Queen's Medical Centre, Nottingham, UK
M. Remacle
CHL Clinique d'Eich, Luxembourg
R.J. Salvi
Center for Hearing and Deafness, Buffalo, NY, USA
B. Scolia Yurrita
Hospital General Universitario G. Marañón, Madrid, Spain
J. Shah
Memorial Sloan Kettering Cancer Center, New York, USA
H. Stammberger
Medical University, Graz, Austria
H.P. Zenner
Universitäts Hals-Nasen-Ohren-Klinik, Tübingen, Germany

Editorial Board

Editor-in-Chief:

M. Ansarin
President of S.I.O.:
C. Vicini

Former Presidents of S.I.O.:

L. Coppo, A. Ottaviani, P. Puxeddu, M. Maurizi,
G. Sperati, D. Passali, E. de Campora,
A. Sartoris, P. Laudadio, M. De Benedetto,
S. Conticello, D. Casolino, A. Rinaldi Ceroni,
M. Piemonte, R. Fiorella, A. Camaioni, A. Serra,
G. Spriano, R. Filippo, C.A. Leone, E. Cassandro

Editorial Staff

Editor-in-Chief:

M. Ansarin
Division of Otolaryngology Head & Neck Surgery
European Institute of Oncology
Via Ripamonti, 435 - 20141 Milan, Italy
Tel. +39 02 57489490 - Fax +39 02 94379216
actaitalicaorl@ieo.it

Associate Editors:

E. De Corso
*Fondazione Policlinico Universitario A. Gemelli IRCCS,
Università Cattolica del Sacro Cuore, Roma, Italy*
eugenio.decorso@policlinicogemelli.it

M.G. Ruguì
SOC ORL, Azienda Universitaria Integrata di Udine, Italy
mrguiauactaorl@gmail.com

E. Zanoletti
Otorinolaringoiatria, Ospedale-Università di Padova, Italy
ezanolettiactaorl@gmail.com

Editorial Coordinator:

F. Chu
*Division of Otolaryngology Head & Neck Surgery
European Institute of Oncology, Milan, Italy*
francesco.chu@ieo.it

Scientific Secretariat:

G. Pietrobon
*Division of Otolaryngology Head & Neck Surgery
European Institute of Oncology, Milan, Italy*
giacomo.pietrobon@ieo.it

Editorial Assistant:

P. Moore

Copy Editor:

L. Andreazzi - landreazzi@pacinieditore.it

Treasurer:

F. Pagella - tpagella@libero.it

**Argomenti di Acta
Otorhinolaryngologica Italica**

Editor-in-Chief: M. Ansarin
Editorial Coordinator: M. Tagliabue
*Division of Otolaryngology Head & Neck Surgery
European Institute of Oncology, Milan, Italy*
marta.tagliabue@ieo.it

© Copyright 2019 by

Società Italiana di Otorinolaringoiatria
e Chirurgia Cervico-Facciale
Via Luigi Pigorini, 6/3 - 00162 Rome, Italy

Managing Editor

M. Ansarin

Publisher

Pacini Editore Srl
Via Gherardesca, 1 - 56121 Pisa, Italy
Tel. +39 050 313011 - Fax +39 050 3130300
info@pacinieditore.it - www.pacinimedica.it

Acta Otorhinolaryngologica Italica is cited in Index Medicus, MEDLINE, PubMed Central, Science Citation Index Expanded, Scopus, Open-J Gate, Free Medical Journals, Index Copernicus, Socolar

Journal Citation Reports: Impact Factor 1.196

Acta Otorhinolaryngologica Italica is available on Google Scholar



PACINI
EDITORE
MEDICINA

Volume 39 • Supplement 1
June 2019

3

www.actaitalica.it

Contents

106th Congress of the Italian Society of Otorhinolaryngology Head and Neck Surgery

Official report

Edited by E. Zanoletti, A. Mazzoni, A. Martini

Editorial Committee: G. Marioni, D. Cazzador, L. Girasoli

Surgery of the lateral skull base: a 50-year endeavour

Chirurgia della base del cranio laterale: 50 anni di impegno

E. Zanoletti, A. Mazzoni, A. Martini, R.V. Abbritti, R. Albertini, E. Alexandre, V. Baro, S. Bartolini, D. Bernardeschi, R. Bivona, M. Bonali, I. Borghesi, D. Borsetto, R. Bovo, M. Breun, F. Calbucci, M.L. Carlson, A. Caruso, P. Cayé-Thomasen, D. Cazzador, P.-O. Champagne, R. Colangeli, G. Conte, D. d'Avella, G. Danesi, L. Deantonio, L. Denaro, F. Di Berardino, R. Draghi, F.H. Ebner, N. Favaretto, G. Ferri, A. Fioravanti, S. Froelich, A. Giannuzzi, L. Girasoli, B.R. Grossardt, M. Guidi, R. Hagen, S. Hanakita, D.G. Hardy, V.C. Iglesias, S. Jefferies, H. Jia, M. Kalamarides, I.N. Kanaan, M. Krengli, A. Landi, L. Lauda, D. Lepera, S. Lieber, S.L.K. Lloyd, A. Lovato, F. Maccarrone, R. Macfarlane, J. Magnan, L. Magnoni, D. Marchioni, J.P. Marinelli, G. Marioni, V. Mastronardi, C. Matthies, D.A. Moffat, S. Munari, M. Nardone, R. Pareschi, C. Pavone, E. Piccirillo, G. Piras, L. Presutti, G. Restivo, M. Reznitsky, E. Roca, A. Russo, M. Sanna, L. Sartori, M. Scheich, W. Shehata-Dieler, D. Soloperto, F. Sorrentino, O. Sterkers, A. Taibah, M. Tatagiba, G. Tealdo, D. Vlad, H. Wu, D. Zanetti

1. Introduction (<i>A. Martini</i>)	S2
2. Generalities on skull base surgery	S3
2.1. Surgery of the skull base as it relates to pathology (<i>E. Zanoletti</i>)	S3
2.2. Evidence-based therapy in diseases of the skull base (<i>A. Mazzoni</i>)	S5
3. The lateral approaches: principles and highlights	S5
3.1. The translabyrinthine approach (<i>E. Zanoletti</i>)	S5
3.2. The transcochlear approach (<i>G. Restivo, G. Danesi</i>)	S6
3.3. The modified transcochlear approaches (<i>L. Lauda, A. Taibah, V. Mastronardi, R. Albertini, M. Sanna</i>)	S8
3.4. The middle cranial fossa approach (<i>M. Scheich, R. Hagen</i>)	S11
3.5. The pterional approach (<i>V. Baro, A. Landi, L. Sartori, L. Denaro, D. d'Avella</i>)	S14
3.6. The infratemporal A (and B, C, D) approach (<i>R. Pareschi</i>)	S16
3.7. The petro-occipital transigmoid approach (POTS) (<i>A. Mazzoni, D. Cazzador, E. Zanoletti</i>)	S19
3.8. Presigmoid retrolabyrinthine approach and variation (<i>I.N. Kanaan</i>)	S21
3.9. Occipital approaches, retrosigmoid approach (<i>A. Mazzoni, D. d'Avella, E. Zanoletti</i>)	S24
3.10. The suprameatal approach and the transpetrous-transapex approach (<i>M. Tatagiba, S. Lieber, F.H. Ebner</i>)	S26
3.11. The extreme lateral approach: highlights on the key steps of surgical technique (<i>R.V. Abbritti, P.-O. Champagne, S. Hanakita, E. Roca, S. Froelich</i>)	S29
3.12. En bloc resections of the temporal bone (<i>A. Mazzoni, E. Zanoletti</i>)	S31
3.13. Totally endoscopic and combined endo-microscopic approaches in lateral skull base surgery (<i>D. Marchioni, M. Bonali, D. Soloperto, F. Maccarrone, G. Ferri, L. Presutti</i>)	S33

4.	Advancements and open issues	S36
4.1.	Acoustic neuroma	S36
4.1.1.	Observation in vestibular schwannomas - a systematic review (<i>M. Reznitsky, P. Cayé-Thomasen</i>)	S36
4.1.2.	Radiotherapy in acoustic neuroma (<i>M. Krengli, L. Deantonio</i>)	S41
4.1.3.	Vestibular schwannoma: surgery after radiotherapy (<i>G. Piras, A. Russo, A. Caruso, A. Giannuzzi, M. Sanna</i>)	S47
4.1.4.	Complications in acoustic neuroma surgery (<i>V. Baro, A. Landi, L. Denaro, D. d'Avella</i>)	S50
4.1.5.	Hearing Preservation Surgery (HPS) with the retrosigmoid approach (<i>A. Mazzoni, E. Zanoletti, D. Borsetto, D. Cazzador</i>)	S51
4.1.6.	Assessing hearing to orient the choice of treatment for acoustic neuroma (<i>R. Bovo, F. Sorrentino</i>)	S52
4.1.7.	Vestibular schwannomas and cochlear implant (<i>E. Piccirillo, G. Piras, M. Guidi, D. Vlad, M. Sanna</i>)	S57
4.1.8.	The hearing-focused therapy in acoustic neuroma: hearing preservation surgery, hearing rehabilitation with CI, observation (<i>E. Zanoletti, D. Cazzador, L. Girasoli, C. Pavone, L. Denaro, D. d'Avella, A. Martini, A. Mazzoni</i>)	S59
4.1.9.	Current molecular knowledge on sporadic VIII cranial nerve schwannoma (<i>G. Marioni, N. Favaretto, A. Martini, E. Zanoletti</i>)	S62
4.2.	Tympano-jugular paraganglioma	S64
4.2.1.	Treatment options for sporadic tympano-jugular paraganglioma (TJPGL) (<i>A. Mazzoni, E. Zanoletti, D. Cazzador, A. Martini</i>)	S64
4.2.2.	Radical surgery in jugular foramen paragangliomas: indications and results (<i>R. Pareschi</i>)	S65
4.2.3.	Primary radiotherapy in paraganglioma: indications and results (<i>L. Deantonio, M. Krengli</i>)	S67
4.2.4.	Partial surgery in paraganglioma: indications and results (<i>R. Bivona, M. Nardone, E. Zanoletti, G. Danesi</i>)	S70
4.2.5.	Management of internal carotid artery in skull base paraganglioma surgery (<i>M. Sanna, E. Piccirillo, G. Piras, L. Lauda, A. Caruso</i>)	S76
4.3.	Other lesions	S79
4.3.1.	Chordoma and chondrosarcoma (<i>E. Zanoletti, R. Colangeli, S. Munari, A. Mazzoni</i>)	S79
4.3.2.	Endolymphatic sac tumours (<i>G. Tealdo, L. Girasoli, D. Borsetto, E. Zanoletti</i>)	S82
4.3.3.	Posterior fossa meningiomas: the neuro-otologist perspective (<i>G. Danesi, R. Bivona, V.C. Iglesias, D. Lepera, R. Pareschi</i>)	S83
4.3.4.	Lateral skull base meningiomas: the neurosurgeon's perspective (<i>F. Calbucci, I. Borghesi, A. Fioravanti, S. Bartolini, R. Draghi</i>)	S87
4.3.5.	Primary squamous cell carcinoma of the temporal bone (<i>G. Marioni, A. Lovato, A. Mazzoni, E. Zanoletti</i>)	S90
4.3.6.	Petrous bone cholesteatoma (<i>D. Zanetti, G. Conte, L. Magnoni, F. Di Berardino</i>)	S91
5.	The view of the expert: a free choice topic	S96
5.1.	Petrous apex and surrounding areas lesions: clinical and surgical management (<i>M. Sanna, A. Taibah, A. Russo, E. Piccirillo, G. Piras</i>)	S96
5.2.	The evolving evidence based algorithm in vestibular schwannoma management (<i>D.A. Moffat, D.G. Hardy, S.L.K. Lloyd, S. Jefferies, R. Macfarlane</i>)	S101
5.3.	Management of NF2: from vestibular schwannoma microsurgery to hearing restoration (<i>M. Kalamarides, H. Jia, H. Wu, O. Sterkers, D. Bernardeschi</i>)	S107
5.4.	When preservation of auditory function is a must: technique and outcome in a series of neurofibromatosis type II (<i>C. Matthies, M. Breun, W. Shehata-Dieler, R. Hagen</i>)	S109
5.5.	Endoscope-assisted microsurgery of trigeminal, facial and auditory nerves (<i>J. Magnan</i>)	S117
5.6.	Modern shifts in the clinical epidemiology of sporadic vestibular schwannoma and its implications (<i>J.P. Marinelli, B.R. Grossardt, M.L. Carlson</i>)	S121
5.7.	Preventing surgical morbidity in jugular paraganglioma (<i>A. Mazzoni</i>)	S125
6.	Conclusions (<i>A. Mazzoni</i>)	S126
	References	S127

How to cite this article: Zanoletti E, Mazzoni A, Martini A, et al. *Surgery of the lateral skull base: a 50-year endeavour*. Acta Otorhinolaryngol Ital 2019;39(Suppl.1):S1-S146. <https://doi.org/10.14639/0392-100X-suppl.1-39-2019>

Address for correspondence: E. Zanoletti, Department of Neuroscience DNS, Otolaryngology Section, Padova University, Padova, Italy.
E-mail: elisabetta.zanoletti@aopd.veneto.it

This work is dedicated to Ugo Fisch

Ugo Fisch is honouring our report with his “Microscope and the ear. The origin of Microsurgery”.

*The members of our Society can freely download it at the following link:
<https://www.fimf.ch/pdf-special-book-microscope-and-ear-origin-microsurgery>*

**106th Congress of the Italian Society of Otorhinolaryngology Head and Neck Surgery****Official report****Surgery of the lateral skull base:
a 50-year endeavour***Chirurgia della base del cranio laterale: 50 anni di impegno*

E. ZANOLETTI¹, A. MAZZONI¹, A. MARTINI¹, R.V. ABBRITTI², R. ALBERTINI³, E. ALEXANDRE¹, V. BARO⁴, S. BARTOLINI⁵, D. BERNARDESCHI^{6,7}, R. BIVONA⁸, M. BONALI⁹, I. BORGHESI¹⁰, D. BORSETTO¹, R. BOVO¹, M. BREUN¹¹, F. CALBUCCI¹⁰, M.L. CARLSON^{12,13}, A. CARUSO³, P. CAYÉ-THOMASEN^{14,15}, D. CAZZADOR^{1,16}, P.-O. CHAMPAGNE², R. COLANGELI¹, G. CONTE¹⁷, D. D'AVELLA⁴, G. DANESI⁸, L. DEANTONIO^{18,19}, L. DENARO⁴, F. DI BERARDINO^{20,21}, R. DRAGHI¹⁰, F.H. EBNER²², N. FAVARETTO¹, G. FERRI⁹, A. FIORAVANTI⁵, S. FROELICH², A. GIANNUZZI³, L. GIRASOLI¹, B.R. GROSSARDT²³, M. GUIDI³, R. HAGEN²⁴, S. HANAKITA², D.G. HARDY²⁵, V.C. IGLESIAS⁸, S. JEFFERIES²⁶, H. JIA²⁷, M. KALAMARIDES^{6,7}, I.N. KANAAN²⁸, M. KRENGLI^{18,19}, A. LANDI⁴, L. LAUDA³, D. LEPERA²⁹, S. LIEBER²², S.L.K. LLOYD³⁰, A. LOVATO³¹, F. MACCARRONE⁹, R. MACFARLANE²⁵, J. MAGNAN³², L. MAGNONI^{20,21}, D. MARCHIONI³³, J.P. MARINELLI³⁴, G. MARIONI¹, V. MASTRONARDI³, C. MATTHIES¹¹, D.A. MOFFAT³⁵, S. MUNARI¹, M. NARDONE³⁶, R. PARESCHI²⁹, C. PAVONE¹, E. PICCIRILLO³, G. PIRAS³, L. PRESUTTI⁹, G. RESTIVO³, M. REZNITSKY¹⁴, E. ROCA², A. RUSSO³, M. SANNA³, L. SARTORI⁴, M. SCHEICH²⁴, W. SHEHATA-DIELER²⁴, D. SOLOPERTO³³, F. SORRENTINO¹, O. STERKERS^{6,7}, A. TAIBAH³, M. TATAGIBA²², G. TEALDO¹, D. VLAD³, H. WU²⁷, D. ZANETTI^{20,21}

¹ Department of Neuroscience DNS, Otolaryngology Section, Padova University, Padova, Italy; ² Department of Neurosurgery, Lariboisière Hospital, University of Paris Diderot, Paris, France; ³ Gruppo Otologico, Piacenza-Rome, Italy; ⁴ Academic Neurosurgery, Department of Neuroscience DNS, University of Padova Medical School, Padova, Italy; ⁵ Neurosurgery, Bellaria Hospital, Bologna, Italy; ⁶ AP-HP, Groupe Hôpital-Universitaire Pitié-Salpêtrière, Neuro-Sensory Surgical Department and NF2 Rare Disease Centre, Paris, France; ⁷ Sorbonne Université, Paris, France; ⁸ ENT and Skull-Base Surgery Department, Department of Neurosciences, Ospedale Papa Giovanni XXIII, Bergamo, Italy; ⁹ Otolaryngology-Head and Neck Surgery Department, University Hospital of Modena, Italy; ¹⁰ Neurosurgery, Maria Cecilia Hospital, Cotignola (RA), Italy; ¹¹ Department of Neurosurgery, Julius Maximilians University Hospital Würzburg, Bavaria, Germany; ¹² Department of Otolaryngology-Head and Neck Surgery, Mayo Clinic, Rochester, MN, USA; ¹³ Department of Neurologic Surgery, Mayo Clinic, Rochester, MN, USA; ¹⁴ The Department of Otorhinolaryngology, Head & Neck Surgery and Audiology, Copenhagen University Hospital, Rigshospitalet, Copenhagen, Denmark; ¹⁵ Faculty of Health and Medical Sciences, University of Copenhagen, Copenhagen, Denmark; ¹⁶ Department of Neuroscience DNS, Section of Human Anatomy, Padova University, Padova, Italy; ¹⁷ Department of Neuroradiology, Fondazione IRCCS Ca' Granda, Ospedale Maggiore Policlinico, Milano, Italy; ¹⁸ Department of Radiation Oncology, University Hospital Maggiore della Carità, Novara, Italy; ¹⁹ Department of Translational Medicine, University of Piemonte Orientale, Novara, Italy; ²⁰ Unit of Audiology, Department of Clinical Sciences and Community Health, University of Milano, Italy; ²¹ Department of Surgery, Fondazione IRCCS Ca' Granda, Ospedale Maggiore Policlinico, Milano, Italy; ²² Department of Neurosurgery, Eberhard Karls University Tübingen, Germany; ²³ Division of Biomedical Statistics and Informatics, Department of Health Sciences Research, Mayo Clinic, Rochester, MN, USA; ²⁴ Department of Otorhinolaryngology, Plastic, Aesthetic and Reconstructive Head and Neck Surgery, "Julius-Maximilians" University Hospital of Würzburg, Bavaria, Germany; ²⁵ Department of Neurosurgery, Cambridge University Hospital, Cambridge, UK; ²⁶ Oncology Department, Cambridge University Hospital, Cambridge, UK; ²⁷ Department of Otolaryngology Head and Neck Surgery, Shanghai Ninth People's Hospital, Shanghai Jiatong University School of Medicine, China; ²⁸ Department of Neurosciences, King Faisal Specialist Hospital & Research Center, Alfaisal University, College of Medicine, Riyadh, KSA; ²⁹ ENT & Skull-Base Department, Ospedale Nuovo di Legnano, Legnano (MI), Italy; ³⁰ Department of Neuro-Otology and Skull-Base Surgery Manchester Royal Infirmary, Manchester, UK; ³¹ Department of Neuroscience DNS, Audiology Unit, Padova University, Treviso, Italy; ³² University Aix-Marseille, France; ³³ Otolaryngology-Head and Neck Surgery Department, University Hospital of Verona, Italy; ³⁴ Mayo Clinic School of Medicine, Rochester, MN, USA; ³⁵ Department of Neuro-otology and Skull Base Surgery, Cambridge University Hospital, Cambridge, UK; ³⁶ ENT Department, Treviglio (BG), Italy

SUMMARY

Disregarding the widely used division of skull base into anterior and lateral, since the skull base should be conceived as a single anatomic structure, it was to our convenience to group all those approaches that run from the antero-lateral, pure lateral and postero-lateral side of the skull base as “Surgery of the lateral skull base”. “50 years of endeavour” points to the great effort which has been made over the last decades, when more and more difficult surgeries were performed by reducing morbidity. The principle of lateral skull base surgery, “remove skull base bone to approach the base itself and the adjacent sites of the endo-esocranium”, was then combined with function preservation and with tailoring surgery to the pathology. The concept that histology dictates the extent of resection, balancing the intrinsic morbidity of each approach was the object of the first section of the present report. The main surgical approaches were described in the second section and were conceived not as a step-by-step description of technique, but as the highlighting of the surgical principles. The third section was centered on open issues related to the tumor and its treatment. The topic of vestibular schwannoma was investigated with the current debate on observation, hearing preservation surgery, hearing rehabilitation, radiotherapy and the recent efforts to detect biological markers able to predict tumor growth. Jugular foramen paragangliomas were treated in the frame of radical or partial surgery, radiotherapy, partial “tailored” surgery and observation. Surgery on meningioma was debated from the point of view of the neurosurgeon and of the otologist. Endolymphatic sac tumors and malignant tumors of the external auditory canal were also treated, as well as chordomas, chondrosarcomas and petrous bone cholesteatomas. Finally, the fourth section focused on free-choice topics which were assigned to acknowledged experts. The aim of this work was attempting to report the state of the art of the lateral skull base surgery after 50 years of hard work and, above all, to raise questions on those issues which still need an answer, as to allow progress in knowledge through sharing of various experiences. At the end of the reading, if more doubts remain rather than certainties, the aim of this work will probably be achieved.

KEY WORDS: Lateral skull base surgery • Lateral approaches to the skull base • Skull base surgery • Benign tumors of the skull base • Malignant tumors of the skull base

RIASSUNTO

La base del cranio non è anatomicamente divisa in anteriore e laterale, ma è per semplicità che comunemente si intendono i corridoi chirurgici con direzione antero-laterale, laterale pura e postero laterale come “Approcci chirurgici della base del cranio laterale”. Una relazione con titolo “Cinquant’anni di impegno”, di sforzo o di dedizione, vuole essere il riconoscimento a questa chirurgia che nel corso degli anni ha sviluppato interventi sempre più complessi con una morbilità sempre minore. Il principio della chirurgia della base del cranio laterale si fonda sulla possibilità di “fare spazio”, esporre adeguatamente, rimuovere osso per salvaguardare il cervello, insieme alla possibilità di preservare la funzione e adattare l’approccio chirurgico all’istologia della lesione. Il concetto che l’istologia detta l’entità della resezione chirurgica, bilanciando la morbilità intrinseca di ciascun approccio, è oggetto di trattazione nella prima sezione di questa relazione. Nella seconda sezione sono descritti i principali approcci chirurgici, intesi non come descrizione tecnica di ciascun tempo chirurgico, ma dei principi che sono alla base di ciascun approccio. La terza sezione è dedicata alle questioni aperte, quelle ancora irrisolte, inerenti alcuni tumori ed il loro trattamento. L’argomento del neurinoma sporadico dell’ottavo nervo cranico è trattato riportando l’attuale dibattito sulla osservazione, la chirurgia di preservazione dell’udito, la riabilitazione con l’impianto cocleare, la radioterapia e le ricerche recenti su marcatori tumorali predittivi di crescita. Il paraganglioma del forame giugulare è trattato nel contesto della chirurgia radicale, chirurgia parziale, osservazione e radioterapia. La terapia dei meningiomi della base del cranio analizza il punto di vista specifico dell’otocirurgo e del neurochirurgo. Cordomi e condrosarcomi, tumori del sacco endolinfatico, carcinomi dell’orecchio e colesteatoma della rocca sono le altre lesioni affrontate. Infine, nella quarta sezione è proposto un contributo a libera scelta ad autori di riconosciuta esperienza. Lo scopo di questa relazione è stato quello di fornire un aggiornamento della chirurgia della base del cranio laterale dopo 50 anni di duro lavoro e, o forse soprattutto, di permettere alle tante questioni irrisolte, alle domande che ancora non hanno risposta, di trovare espressione, affinché il dibattito ed il progresso possano continuare con la condivisione di esperienze. Se al termine della lettura vi saranno più domande che risposte, potremo dirci che l’obiettivo di questa relazione è stato raggiunto.

PAROLE CHIAVE: Chirurgia della base cranio laterale • Approcci laterali alla base del cranio • Chirurgia della base del cranio • Tumori benigni della base del cranio • Tumori maligni della base del cranio

1. Introduction

A. Martini

It is my pleasure to thank the Italian Society of Otorhinolaryngology Head and Neck Surgery for the task I was entrusted. The previous report on the topic was assigned 42 years ago... to one of the present three authors and this makes me particularly happy.

It has been a hard work, since the subject of the lateral skull base surgery is so fascinating and so demanding that only a humble, caparbiuous attitude to improve knowledge and expe-

rience may lead to progress. This was the case of these 50 years where the role of the surgeon of the skull base has been witnessing a more and more comprehensive surgery, where expertise in microsurgery, otology, oncology, head and neck surgery combines to approach the various diseases of the skull base.

My special thanks are to both the foreign and Italian authors who contributed to the present work. To Antonio Mazzoni, who some years ago decided to share his knowledge and experience in the lateral skull base surgery to train younger colleagues in our group in Padova, for the progress of such demanding field.

The concept of a team is of tremendous importance in the skull base surgery and this report shows how every topic may be treated from different points of view, how many problems and different perspectives are encountered in a therapeutic choice. Many thanks to the readers who will comprehend the effort we made and will excuse us if some of their expectations will not be satisfied. We tried all to do our best.

2. Generalities on skull base surgery

2.1. Surgery of the skull base as it relates to pathology

E. Zanoletti

Introduction

The skull base is a bony diaphragm separating the brain from the face and neck. Skull base surgery runs across the bone and adjacent areas of neck and face to reach the lesions lying in bone, and/or in the exo- and endocranial regions or both. A lesion may be endocranial or exocranial, or both and be accessed through the skull base. The route taken for the surgical procedure runs from an opening to a target, thus delineating an “approach”.

The deep target is exposed by creating a gateway for entering the skull and a corridor by removing, retracting, or bypassing tissues and organs. The gate is wider than both the corridor and the target in order to enable structures to be visualized, and to allow for precise surgical maneuvers. The surgical cavity is cone-shaped and wide enough to accommodate instruments, allow for their handling, and afford multiple angles of view with different magnification systems (microscope, endoscope).

The boundaries of the access are often organs that are not expendable, whereas the width of the access can be significantly enhanced if a structure can be sacrificed. The extent and boundaries of the approach are defined by the nature of the lesion.

Ergonomics

Understanding the principles behind the surgical procedures, and the basic skills needed to perform them are prerequisite for the skull base surgeon. Given that surgery is a mechanical action performed on tissues by hand, or using hand-held instruments, and that microsurgery relies on the use of stereoscopic optical enlargement and dedicated instruments, surgeon's training should preferably begin at a young age, enabling him/her to gain sufficient experience to ensure a smooth and natural communication between mind and target.

Surgeon sits up straight on a seat with back support, so as to be comfortable with the arms, the chair is easily adjusted up and down, both feet on the floor. There are no foot pedals. Support is needed for the surgeons' forearm, the ulnar side of the hand, the fingers, and sometimes the instrument shaft. The patient's body and head provide support, and the bony margins of the entry gate can be used.

Principles of skull base surgery

The lateral skull base is conceived as a connection between different compartments – the neck and face on its exocranial side, brain on its endocranial side – and it is crossed by vessels and nerves running through bony orifices or canals.

These three levels of tissues – brain, skull base, and face and neck – interact differently with the various histologies and present different clinical and radiological features, as well as suggesting several different therapeutic approaches. The choice of surgical approach depends on the histology of the lesion.

It is important to preliminarily focus on the multiple problems to be considered in planning and performing skull base surgery.

- The correlation between pathology and resection concerns different tissues, each featuring its own interface with the skull base. Tumors have own ways of interacting with tissues and influencing the resection. In short, skull base surgery carries to a higher degree the problems common to any form of oncological surgery as regards the variable effects of tumor histology, site and size, the extent of the lesion and the tissues invaded.
- The spaces in the skull base and adjacent sites where tumors can grow are narrow, limited by bone, major vessels and nerves. In this setting, surgery has to gain its own space to complete tumor resection safely.
- The skills required for the various surgical approaches can make it difficult to choose the most appropriate one, and the choice is often erroneously related more to the size of the tumor than to its nature.
- Surgical resections must be planned so as to achieve oncologically safe margins, depending on the type of neoplasm involved. The same approach cannot be equally suitable for schwannoma, meningioma, chordoma, chondrosarcoma, carcinoma, etc. Even within the same pathological diagnoses, different aspects of a given histotype of tumor can make a lesion more or less aggressive.
- Despite the nature of a tumor is fundamentally important, biopsies of skull base tumors are unfortunately rarely obtained, as the diagnosis is commonly established from radiological and clinical findings. The reliability of such a diagnosis is questionable, but it is often the only feasible option. Preoperative biopsy is recommended when it might change aim of surgery and choice of approach and when clinical-radiological diagnosis is missing.

Tumors of the lateral skull base

Tumors of the lateral skull base may originate from the bone, endocranial nervous tissues, or various tissues of the face and neck, and then cross the skull base to spread into surrounding areas.

The natural history of a tumor varies, depending on several factors:

1. Histopathology, which not only differentiates between benign and malignant lesions, but also identifies a lesion's risk of loco-regional aggressiveness, recurrence, and distant metastasis, and often dictates whether multiple treatment strategies are needed.
2. Site of origin, as a tumor may be a primary lesion of the skull base, or a secondary lesion from adjacent sites.
3. Behavior: tumors have different growth patterns at different locations. The same neoplasm can have an expansive growth in the soft tissues, but be erosive or infiltrative in bone or nerve tissues. It can behave differently with the dura mater, displacing it at some interfaces, infiltrating it at others. It may infiltrate the brain or grow undisturbed until it prompts late signs of compression (in the cerebellopontine angle, for instance, it finds some free space to occupy before causing any symptoms). It can encase vessels with or without infiltration of their walls or erode their bony channels. Shortly, most types of neoplasm show different growth patterns as they spread through the three compartments of the skull base region, and resections must adapt accordingly.
4. Degree of aggressiveness, i.e. whether it is well or poorly differentiated. All tumors have their own potential for hidden, undetectable diffusion, so completeness of resection and oncological radicality can mean different things. The degree of differentiation also influences the foreseeable response to adjuvant/neo-adjuvant therapies, and consequently affects how surgery is planned.
5. Sporadic or syndromic disease: skull base tumors are treated differently if the lesions are sporadic or part of a syndrome. Syndromic cases are generally more aggressive, develop more quickly and at an earlier age. They may occur in association with other multiple concomitant tumors, involve a greater risk of malignant transformation after radiotherapy and functional issues relating to the not infrequent presence of bilateral disease.

Diagnosis

Skull base tumors are diagnosed by high-resolution, contrast-enhanced MRI, and high-resolution bone CT scan, occasionally replaced by cone-beam CT. Further imaging (angioMRI or the less-reliable angioCT) helps to clarify venous drainage, sinus involvement or infiltration of the walls of arteries and veins. Angiography enables the diagnosis of vascular tumors as well as pre-surgical embolization. Contrast-enhanced CT scanning has a very limited role, if any.

Biopsy should be performed whenever feasible, although rarely,

as it enables appropriate, case-specific treatment planning (based on the tumor's histology and aggressiveness, the compartments involved, potential for spread hidden diffusion) and can suggest the oncological safe resection. Biopsy should be performed before any treatment as surgery hardly relies on the often erroneous results of intraoperative frozen section.

When imaging is the only tool available, it should be planned under the best possible conditions in terms of technique and expertise. The clinical onset of signs and symptoms and the course of the disease also contribute to establishing the diagnosis.

Treatment

Treatment is planned and adjusted throughout the course of the disease. When surgery is chosen (as a single treatment or combined with other neo- or post-operative adjuvant radiotherapy/chemotherapy), the oncological margins required must be considered during the planning of the resection, as single or multiple approaches may be needed. If a combination of approaches is indicated, the postoperative complications (CFS leaks, infections, other) should be taken into account: in some cases, they can be prevented by planning staged surgery. When neck and brain compartments are broadly communicating due to an extensive resection of the skull base, staged procedures are preferable in order to limit infections and CSF leakage into the soft tissues.

In principle, the choice of surgical approach should ensure:

1. the lowest morbidity on the cranial nerves (the factors with the greatest influence on postoperative course and quality of life);
2. the highest chance of achieving a complete resection (the oncological margins are dictated by tumor histology and established preoperatively);
3. the goal of surgery (to cure the disease, for symptom relief, or as a preliminary step before other, more effective therapies), striking for the best balance between tumor factors and patient factors;
4. functional rehabilitation. The predictable morbidity of each surgical approach cannot disregard the options available for the rehabilitation after surgery of functions such as hearing, facial mimicking, and swallowing. This makes extensive surgery more feasible than in the past and allows a better chance of achieving oncologically safe resections;
5. the availability of alternative/complementary therapies, considering the patient's treatment as a whole. The role and timing of adjuvant therapies such as traditional radiotherapy, stereotactic or multi-fractionated therapy, or protons, may suggest a planned subtotal surgery if the pathological prognosis is not affected;
6. the surgeons' experience of using the different approaches: is the choice of surgical approach tailored to the tumor, the patient or the surgeon?

2.2. Evidence-based therapy in diseases of the skull base

A. Mazzoni

The treatment of lesions of the skull base has two striking features in clinical practice: one is the high level of the diagnostic process thanks to the use of advanced technologies, such as imaging; the other concerns the lack of a consensual approach to the treatment of the growing number of cases diagnosed early on. The options range from surgery to radiotherapy, to observation, but none of them have been the object of rigorous, randomized clinical trials to compare them, often because patients have the inalienable right to choose how they wish to be treated. Even the most accurate non-randomized studies have produced only level three evidence. This situation is a real obstacle to advances in surgery, which can improve in terms of technique, but not in its indications. One way to escape this impasse of unpredictable duration may be to opt for a given therapy once several different studies concur in favor of it, albeit with a low level of evidence. This would demand a preliminary effort to define a common method for the therapy in question, and to use validated instruments to assess the methodological quality of the studies^{1,2}. As for the contribution from surgeons, it is worth noting that most papers on surgical procedures fail to explain the crucial steps in sufficient detail, and the authors seem to forget that any surgical technique needs to be clear in every respect before it can be discussed and shared.

3. The lateral approaches: principles and highlights

3.1. The translabyrinthine approach

E. Zanoletti

The principle of the translabyrinthine approach (Tlab)¹⁻⁴ is removing the bone from the lateral surface to the internal auditory canal and petrous dura. No cerebellar and temporal retraction is required and the cerebellopontine angle (CPA) is straightforwardly reached.

This access route through the skull base involves the drilling out of the temporal bone to the sigmoid sinus, and a portion of retrosigmoid occipital squama and temporal squama. After completion, the osseous boundaries are: anteriorly, the posterior wall of the external auditory canal and the mastoid Fallopius canal; inferiorly, the jugular bulb and IX cranial nerve; medially, the internal

auditory canal (IAC), around 270° of its circumference, the vestibule and the superior vestibular nerve; superiorly, the superior petrosal sinus and temporal dura; and posteriorly, the retrosigmoid dura and occipital squama for an extent depending on tumor size and anatomy of the temporal bone. In small tumor, the Tlab approach involves only a mastoidectomy and labyrinthectomy. In large tumours bone removal is more extensive both in temporal and retrosigmoid squamous bone.

Tumor removal: this is done via a centrifugal resection from the brainstem to the IAC and, for medium-to-large tumors, it involves repeated steps of intracapsular debulking, dissection and removal of the fragments detached. The goal of this piecemeal procedure is to create the best conditions for freeing nerves, vessels and brainstem. The facial nerve, and the cochlear nerve in some cases, are the pivot of the procedure, the aim of which is to visualize and dissect the nerve from the brainstem to the meatal porus. The facial nerve is first exposed at its brainstem root, then followed up to where it crosses the cerebellopontine angle from the tumor to the meatus. This is the most vulnerable portion of the nerve and should dictate the course of the procedure. Direct or indirect stretching is limited as the procedure is progressing from angle to periphery, freeing the facial nerve along with piecemeal removal up to the porus, then dissecting towards the center from the fundus. Salient steps are:

- The opening in the dura is wide, especially for large tumors, and extends to one millimeter away from the sigmoid, superior petrosal sinus and jugular bulb.
- The cisternal arachnoid involves most of the tumor, and provides a free surgical plane along the tumor's surface.
- The first part of the tumor to be exposed is the posterior surface, which has to be inspected to check for any exceptional course of the facial nerve, before the tumor is extensively coagulated, then incised and debulked.
- The first landmarks are the roots of the VIII and VII nerves, which are found after debulking, on retracting the inferior pole of the tumor.
- Repeated steps of coagulation, debulking and removal reduce the volume of the tumor and allow for the dissection of nerves, vessels and brainstem.
- Tumor removal proceeds in a proximal-to-peripheral direction toward the superior pole and meatus, and ends with a strip of tumor extending from the brain to the meatus and carrying the facial nerve.
- The facial nerve gradually comes into view on one of the tumor meridians, usually on its anterior aspect, and running more or less directly to the meatus, or to the superior pole and from there to the meatus. Beware of any sudden change of course with a sharp angle.
- Dissection of the facial and cochlear nerves proceeds in a proximal-to-distal direction up to the vicinity of the meatus, then goes from there to the meatal fundus. Here

the dissection becomes centripetal. The facial nerve is exposed by lifting the superior vestibular nerve from its canal (Sanna method), or by adding the pink line of the Fallopius. The vulnerable portion of nerve from the porus to the tumor can be freed by converging from both directions.

- Monitoring the facial nerve makes it easier to identify and helps to control dissection-related trauma, up to the final excitability measure, which is of prognostic relevance. Loss of excitability coincides with loss of the ability to monitor the nerve proximal to the site of injury.

Translabyrinthine-transapical approach

A correct Tlab approach to 270° of the circumference of the canal affords adequate access to the CPA, but can be improved by adding a transapical extension. This is convenient in the case of large tumors or an unfavorable anatomy, such as a contracted mastoid, low-lying temporal dura, anterior sigmoid sinus, or high jugular bulb. It may be recommended when, on axial and coronal MRI, large tumors extend beyond the projection in the CPA of the anterior and superior walls of the canal. The transapical approach involves removing the petrous bone anteromedial to, and including, the anterior wall of the canal, up to the vicinity of the horizontal carotid artery. It provides a wider route and exposes the anterior CPA at the beginning of the procedure. This early visual control enables the facial nerve to be assessed better than with the Tlab approach. Having three facial nerve landmarks – the canal fundus, the tumor's supero-anterior aspect, and the root on the brainstem – makes this approach especially useful for cystic and medial tumor.

Limitations of the translabyrinthine approach

It is extremely unusual for the jugular bulb and sigmoid sinus complex to be an insurmountable obstacle and necessitate switching to the retrosigmoid approach. On the other hand, it is not uncommon for the Tlab approach to be so narrow that it demands additional expertise. An unfavorable anatomy is not easily appreciated on current imaging, in terms of suggesting the change of the approach to the retrosigmoid. While the sigmoid sinus can be displaced, the jugular bulb is too fragile to withstand instrumental retraction. Thrombosis of the sinus can be caused by aggressive maneuvers, coagulation of the sinus wall to induce retraction, or the placement of fragments of surgical wax on the wall. There are usually no clinical signs of thrombosis of the sinus, and the rate of its occurrence is not known. The absence of clinical symptoms may relate to the fact that this approach entails little or no retraction on the cerebellum.

3.2. The transcochlear approach

G. Restivo, G. Danesi

Described for the first time in 1976 by House and Hitselberger, the transcochlear approach was designed for large intradural median lesion, petroclival lesions and cerebellopontine angle (CPA) tumors with an anterior and medial extension in respect to the internal auditory canal. These lesions are difficult to handle with other approaches and until 1976 were considered inoperable because of the obstacles represented by the brainstem and the cerebellum. The original transcochlear approach was idealized as an anterior extension of the classic translabyrinthine approach, performed through various steps: the posterior transposition of the facial nerve, the removal of the cochlea and of the petrous apex's bone through a corridor created by removing the latter structure. This approach was then modified by Brackman in 1987, who proposed a removal of the external auditory canal, the skin of the canal, the tympanic membrane together with the ossicles and a blind sac closure of the auditory external canal. These steps granted a greater control of very anterior and medial lesions and of those lesions involving the intrapetrous tract of the carotid artery.

Surgical technique

A C-shaped retroauricular incision of skin and subcutaneous tissues is performed to elevate the anterior flap. T-incision of the muscle-periosteum flap is to expose the mastoid and then used as a second layer in the closure of the obtained surgical cavity. Subsequently the skin of the external auditory canal is incised at the level of the bony-cartilaginous junction. The skin of the cartilaginous external auditory canal is dissected for at least one centimeter towards the concha. Once everted, the skin will be closed with non-absorbable stitches. The residual skin of the bony external auditory canal and the tympanic membrane with the ossicles are then removed. An enlarged mastoidectomy with skeletonization of the dura of the middle and posterior fossa for about 2-3 cm posteriorly to the sigmoid sinus, is then performed. The facial nerve is identified and skeletonized along its course, from the stylo-mastoid foramen until to the geniculate ganglion and to the great petrosal nerve. Only a thin layer of bone covers the nerve at the end of the latter step. An open mastoidectomy is performed by removing the posterior and superior walls of the external auditory canal. The jugular bulb is now skeletonized and the labyrinthectomy starts from the lateral and posterior semicircular canals. Opening of the vestibule is performed on its floor, at the level of the fundus, where it is possible to identify the superior and inferior vestibular nerves divided by the horizontal crest. More laterally and anteriorly to

the latter structures lies the facial nerve, protected by the vertical crest (Bill's bar). Skeletonization of the internal auditory canal (IAC) with a diamond burr reaching up to the internal acoustic meatus is now performed. The tympanic bone must be removed, and the anterior auditory bony canal is then drilled at the level of the tubal ostium. The vertical tract of the internal carotid artery, which lies on the medial wall of the Eustachian tube in front of the cochlea, is now identified and skeletonized. Following steps include removal of the cochlea together with the cochleariform process and skeletonization of the genu of the carotid by removing the bone, including bone that lies between the cochlea and the geniculate ganglion; dissection then continues with the aggressive removal of the tympanic bone until the dura of the middle fossa is reached. The thin layer of bone previously left on the facial nerve is now removed using a dissector. Skeletonization of the labyrinthine portion of the facial nerve represents the point with the highest risk of iatrogenic injury, as an acute angle with the ganglion is created. Skeletonization of the facial nerve continues until the emergence of the VII cn from the fundus is reached. Facial rerouting begins at the level of the geniculate ganglion, after bipolar coagulation and section of the greater superficial petrosal nerve. The geniculate ganglion and the labyrinthine portion of the facial nerve are released for about 180° from the underlying bone and are then detached from it by using angled instruments. At this point usually the nerve becomes electrically non-stimulable, as a consequence of vascular compromise. Subsequently, detachment of the tympanic and the mastoid portion of the facial nerve is performed. In order to be able to completely mobilize the facial nerve and to maintain the protection offered by the dura of the internal auditory canal, the superior vestibular nerve and inferior vestibular nerve and cochlear nerve are interrupted at their emergence from the fundus by using an angled hook, completely freeing the facial nerve from the bone below. It is now possible to carry out the posterior transposition of the facial nerve, included in the dura of the IAC, which will be housed in the corner between the sigmoid sinus and the jugular bulb on the dura of the middle cranial fossa. Is very important to remove all the bone at the stylomastoid foramen, because incomplete removal would not allow a complete mobilization of this portion of the facial nerve. The bone from the residual fallopian canal is removed with a rongeur. Now that the facial nerve is no longer present in the operative field, it is possible to complete the skeletonization of the internal carotid artery, of the cochlea and of the petrous apex which lies medially to the carotid artery. The lower limits of the skeletonization are represented by the inferior petrosal sinus and the jugular bulb, the upper boundaries go from the superior petrosal sinus up to the Meckel

cave and the medial boundary is the clivus. The anterior wall of the bony meatus is then removed, exposing the temporomandibular joint. The mandibular condyle is dislocated forward by using a Fish's infratemporal fossa retractor, in order to allow exposure of the carotid artery for 270°, or even up to 360° when its complete mobilization is required. By further drilling of the bone of the petrous apex, the lateral portion of the clivus is reached. When the bone-dura interface straightens, the posterior aspect of the clivus on the midline has been reached. Thus a dural "triangular window" is obtained. Anatomical boundaries of this triangular window are the internal carotid anteriorly, the superior petrous sinus superiorly and the inferior petrous sinus infero-medially. The apex of the triangle lies under the Meckel's cave. Usually the drilling of the apex bone causes an important venous bleeding that requires use of Surgicel and bone wax. The incision of the dura is then carried out anteriorly to the porus of the internal auditory canal, from the superior petrosal sinus to the inferior petrosal sinus. The facial nerve is usually found on the posterior surface of the tumor. After the nerve is dissected from the tumor's surface, the rerouting is completed by protecting the nerve with cottonoids soaked in saline solution. The incision of the dura can be dangerous as cranial nerves VII and VI could be damaged in correspondence of the internal acoustic porus. The approach allows a wide exposure of the anterior CPA together with the lateral and anterior surfaces of the pons. Other exposed structures are the V, VII, VIII, IX and XI cranial nerves and both the VI cranial nerves, the clivus, the basilar and vertebral arteries, and even the contralateral cranial nerves. This large exposure allows removal of the wide tumor implantation base and control of the arterial vascularization coming from the internal carotid, which is particularly important for the treatment of meningiomas. The large cavity obtained needs to be filled by placing a single large piece of autologous abdominal fat, after obliteration of the tuba with autologous temporal muscle or fat, with possible further reinforcement with bone wax. Finally, the periosteal and muscular flaps and the skin are sutured. A compressive dressing is carried out and must be maintained for 5 days. The abdominal surgical field will require a suction drainage.

Indications for the transcochlear approach are represented by extensive lesions of the CPA extended to the prepontine cistern whose epicenter is anterior and medial to the internal auditory canal such as: petroclival meningiomas, meningiomas anterior to the brainstem, intradural clival lesions, congenital cholesteatomas of the apex, epidermoid tumors anterior to the internal auditory canal, chordomas of the clivus and chondrosarcomas.

The advantages of the transcochlear approach are the following: the approach does not require retraction

of the cerebellum or of the temporal lobe, it allows a wide exposure of the anterior, medial and median CPA, together with the control of the intrapetrous tract of the internal carotid, the basilar and both vertebral arteries. The transcochlear approach can also be associated with a transtentorial approach for lesions that originate from the tentorium or that extend to the peri-mesencephalic cistern. Disadvantages of this technique are represented by associated comorbidities: the posterior rerouting of the facial nerve determines a post-operative paresis up to a House-Brackman grade III.

3.3. The modified transcochlear approaches

L. Lauda, A. Taibah, V. Mastronardi, R. Albertini, M. Sanna

The transcochlear approaches

The original transcochlear approach described by House and Hitselberger (1976) includes internal auditory canal identification, posterior rerouting of the facial nerve and removal of the cochlea and petrous apex with preservation of the middle ear and external auditory canal ¹.

Fisch (1978) described the transotic approach in which the external auditory canal and middle ear are removed but the facial nerve is left in situ ².

The modified transcochlear approach, on the other hand, combines the removal of the external auditory canal and middle ear together with the posterior rerouting of the facial nerve, thus eliminating the major obstacle to the anterior extension of the approach. This wider surgical corridor allows better control of the vertical and horizontal intrapetrous portions of the internal carotid artery and eases a complete removal of the petrous apex ³. The extensive anterior bone removal provides an excellent control of the ventral surface of the brainstem without the need of cerebellar and brainstem retraction.

The modified transcochlear approaches

Classification

We have further classified this approach into four types according to its extension. Type A approach is the basic approach (Fig. 3.3.1), whereas types B, C and D indicate the anterior, superior and inferior extensions, respectively ⁴.

Type A modified transcochlear approach (the basic type)

Indications

- *Extradural lesions:* extensive petrous apex lesions with preoperative facial nerve and inner ear impairment, e.g.:
 - massive petrous bone cholesteatoma of the infral-

abyrinthine, apical and (less commonly) supralabyrinthine types;

- recurrent acoustic neuroma with petrous bone invasion;
- extensive facial nerve tumors;
- cholesterol granuloma (only with preoperative facial and hearing impairment).
- *Intradural lesions:*
 - large clival and petroclival lesions lying ventral to the brainstem, e.g. petroclival meningiomas;
 - previously irradiated petroclival meningiomas;
 - residual or recurrent non-acoustic lesions of the posterior fossa with anterior extension into the prepontine cistern, particularly those with encasement of the vertebrobasilar artery and/or perforating arteries, e.g. huge posterior fossa epidermoids;
 - recurrent acoustic neuromas with facial nerve paralysis.
- *Transdural lesions:*
 - lesions invading the petrous apex as en plaque meningiomas or primary clival or temporal bone lesions with secondary posterior fossa extension as chordomas, chondrosaromas and extensive glomus jugulare tumors.

Surgical technique

1. A wide C-shaped post-auricular incision is made. The incision starts 3 cm above the auricle, curves posteriorly to about 4-5 cm posteriorly to the retroauricular sulcus and ends inferiorly at the level of the mastoid tip.
2. The skin and subcutaneous tissues are elevated,

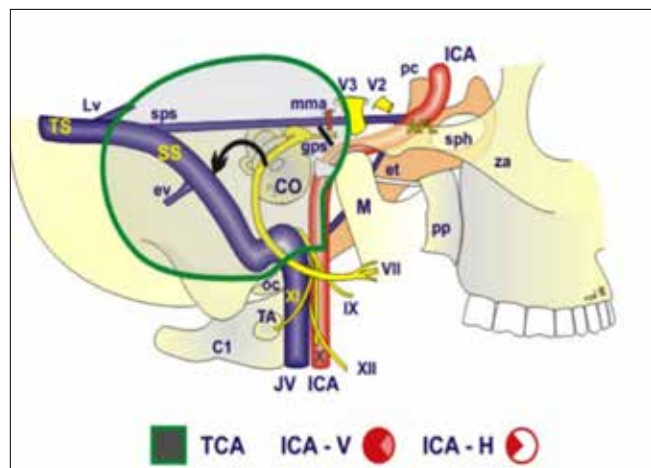


Fig. 3.3.1. Schematic drawing showing the outlines of the modified transcochlear approach type A. About 3/4 of the vertical portion of the internal carotid artery (ICA-V) are exposed in contrast to only 1/4 of the horizontal portion of the internal carotid artery (ICA-H) by using this approach.

the musculoperiosteal layer is incised in a T-shaped fashion. A small Palva flap based anteriorly is outlined.

3. The external auditory canal is transected and closed as a cul de sac. The anterior skin flap is retracted using skin hooks, whereas the musculoperiosteal layer is raised and kept retracted by using 1/0 silk sutures.
4. An extended mastoidectomy is performed, with removal of bone 2-3 cm posteriorly to the sigmoid sinus and over the dura of the middle fossa. The external auditory canal (posterior and superior walls) is drilled and the facial nerve is skeletonized. The inferior tympanic bone is also drilled. Labyrinthectomy is therefore performed and the internal auditory canal is identified as previously described.
5. The facial nerve is skeletonized from the stylomastoid foramen until the geniculate ganglion. Using a diamond burr, the greater superficial petrosal nerve is identified by drilling anteriorly to the geniculate ganglion. Next, the middle fossa dura is gently retracted with suction-irrigation and the labyrinthine segment of the nerve is identified. A small diamond burr is used at this crucial step. Drilling proceeds carefully parallel to the direction of the nerve with the direction of rotation being away from the nerve.
6. The last thin layer of bone over the facial nerve is removed using a rasp. The facial nerve is released for about 270 degrees in its mastoid and tympanic parts and for about 180 degrees in the area of the geniculate ganglion and the labyrinthine segment.
7. The greater superficial petrosal nerve and its accompanying vessels are identified and cut after bipolar coagulation.
8. Using an angled pick, the geniculate ganglion and the labyrinthine portion of the facial nerve are carefully separated from the underlying bone. The tympanic segment is carefully freed. The mastoid segment is then freed using sharp dissectors to cut the through adhesions at this level.
9. The nerve is rerouted posteriorly together with all the contents of the internal auditory canal. The superior vestibular, inferior vestibular and cochlear nerves are torn away at the fundus of the canal and all the contents of the canal are rerouted posteriorly together with the facial nerve. The nerve is then fixed to the posterior fossa dura just anteriorly to the sigmoid sinus using fibrin glue.
10. The fallopian canal is now removed with a rongeur.
11. The cochlea is drilled and the vertical segment of the internal carotid artery is identified. The petrous apex is drilled until the level of the midclivus exposing the dura on the posterior surface of the temporal bone.
12. For extradural lesions, tumor removal proceeds. In case of intradural lesions, the posterior fossa dura is incised and the pathology is managed.

13. At the end of the procedure, the eustachian tube is closed with a muscle plug and the cavity is obliterated with a single piece of abdominal fat. The musculoperiosteal flap is repositioned and sutured with Vicryl 1/0 and the wound is closed in 2 layers. A tight dressing is applied and no drainages are inserted.

Advantages

1. Wide exposure of the cerebellopontine angle and prepontine cistern without need for cerebellar and brainstem retraction.
2. Removal of invaded dura and bone is allowed.
3. Excellent control of the intrapetrous internal carotid artery.
4. The approach can be extended according to the extent of the disease.
5. In cases of meningioma, the blood supply of the tumor is controlled before dural opening.

Disadvantages

1. Sacrifice of ipsilateral hearing.
2. Facial nerve rerouting leads to postoperative paralysis which usually recovers up to House-Brackmann grade III (rarely to grade II).
3. Lengthy procedure. However, wide exposure greatly shortens the time needed for tumor removal.

Type B modified transcochlear approach

This type of transcochlear approach incorporates Fisch's infratemporal fossa approaches of type B or C into the modified transcochlear approach type A. In addition to the wide exposure of the infratemporal fossa, this type also allows an additional access to anteromedial tumors lying ventrally to the brainstem (Fig. 3.3.2) ⁵.

Indications

- *Extradural lesions* with circumferential involvement of the internal carotid artery (e.g. clival chordomas and some cases of infralabyrinthine apical and massive petrous bone cholesteatomas).
- *Intradural lesions*: petroclival lesions passing the midline with limited contralateral extension (e.g. meningiomas, epidermoid cysts, etc.).
- *Transdural lesions* involving the parapharyngeal spaces (e.g. extensive clival chordomas or en-plaque meningiomas with extracranial extension). In these cases, the procedure is usually staged to avoid the risk of post operative cerebrospinal fluid leakage. The extradural portion of the lesion is first removed, while the removal of the intradural component of the lesion is performed in a second-stage procedure.

Surgical steps

1. A wide post-auricular incision is performed as in the type A approach. However, the incision extends more anteriorly up to the lateral margin of the orbit.
2. The modified transcochlear approach type A is

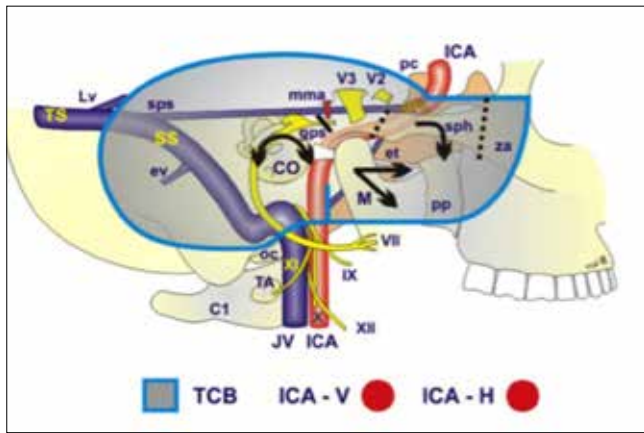


Fig. 3.3.2. Schematic drawing showing the limits of the transcochlear approach type B. Note the complete circumferential exposure of the vertical (ICA-V) and horizontal (ICA-H) segments of the internal carotid artery.

performed as previously described. In addition, the mandibular condyle is displaced inferiorly using a Fisch infratemporal fossa retractor, after removal of the articular capsule. The glenoid and the base of the middle fossa are drilled. The bony part of the eustachian tube is drilled until the isthmus is reached. This provides complete control of the vertical segment of the internal carotid artery. The middle meningeal artery is then identified.

3. After bipolar coagulation, the middle meningeal artery is sectioned; the mandibular nerve is also transected after bipolar coagulation.
4. Meckel's cave can be opened if it is involved by the tumor.
5. If more exposure is required, the internal carotid artery can be mobilized anteriorly in order to create more space for tumor exposure.

The type C modified transcochlear approach

Certain posterior fossa tumors (particularly petroclival meningiomas) can extend to the middle fossa either by direct tentorial invasion or through Meckel's cave or the tentorial notch. The type C approach allows control of both the infratentorial and the supratentorial parts of the tumor lying ventral to the pons and midbrain, as well as removal of the infiltrated tentorium with only minimal temporal lobe retraction (Fig. 3.3.3).

Indications

Petroclival lesions with supratentorial extension (e.g. petroclival meningiomas).

Surgical steps

1. The skin incision is performed as in the type B approach. The approach is performed as previously described in the type A approach. However, the middle fossa dura is

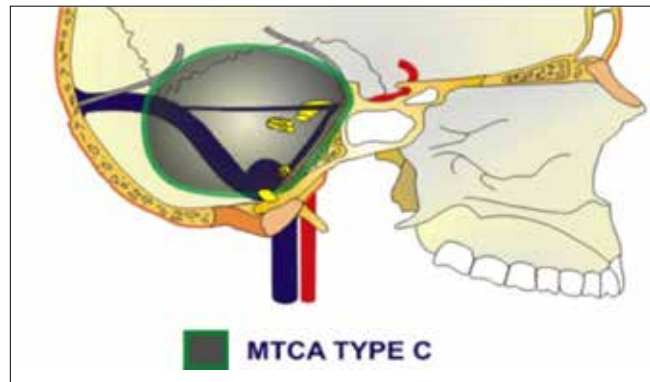


Fig. 3.3.3. Schematic drawing showing the extent of the modified transcochlear type C approach. Note the superior extent of the craniotomy and the cut of the tentorium.

widely uncovered. Bone removal at this level is much wider than in the type A approach.

2. The dura of the middle fossa is incised 3-4 mm above and parallel to the superior petrosal sinus.
3. The superior petrosal sinus is opened and coagulated or packed with Surgicel. The tentorium is cut with microscissors anteromedially starting just in front of the junction between the superior petrosal sinus and the sigmoid sinus.
4. Cutting of the tentorium is continued until the tentorial notch is reached. If the tentorium is involved by tumor as in cases of meningiomas, it is completely excised and removed.

The type D modified transcochlear approach

The major limitation of the type A approach is the limited access to tumors extending into the lower clivus and jugular foramen region. The type D approach is designed to overcome this limitation by combining the type A approach with the petro-occipital trans-sigmoid (POTS) approach, thereby obtaining excellent control of these areas (Fig. 3.3.4).

Indications

Lesions of the middle and lower clivus, e.g., chordomas with involvement of the lower clivus, some cases of petroclival meningiomas, and extensive lower cranial nerve schwannomas.

Surgical steps

1. The incision is performed as in the type A approach. The lower limb of the incision extends inferiorly to about 2 cm below the mastoid tip.
2. An inferiorly based U-shaped musculoperiosteal flap is raised as described in the POTS approach. Anteriorly, a small Palva flap is created to form the second layer after a cul-de-sac closure of the external auditory canal.
3. The approach is performed as described in the type A. In

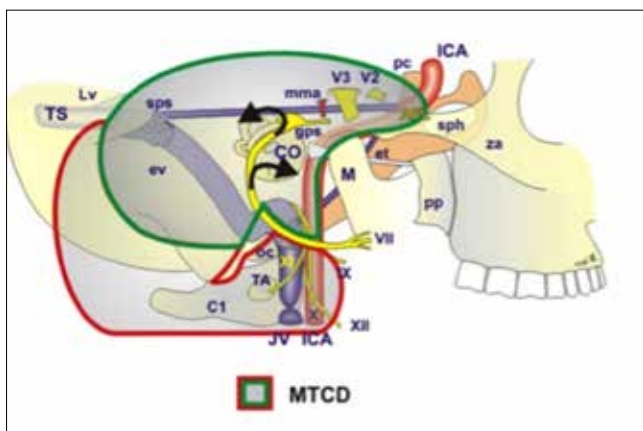


Fig. 3.3.4. Schematic drawing showing the modified transcochlear approach type D. The red outline shows the additional bone to be removed.

addition, a wider removal of the occipital bone posteriorly and inferiorly to the sigmoid sinus is performed.

4. The sigmoid sinus is closed extraluminally at the junction with the transverse sinus. The sinus is then opened and intraluminally packed with large pieces of Surgicel®. The internal jugular vein is identified in the neck and ligated twice. The dura is opened as previously described with the additional opening of the jugular bulb as described in the POTS approach.

3.4. The middle cranial fossa approach

M. Scheich, R. Hagen

Introduction

Microsurgery for vestibular schwannomas can be performed via several different approaches. The middle cranial fossa (MCF) corridor is an extradural approach that was first described as early as 1904, but the beginning of its widespread use dates back to the description made by William House in 1961¹². The clinical application of this approach was facilitated after the introduction of the operating microscope from middle ear surgery into modern otoneurosurgery. Various modifications have been carried out over the past several years (e.g. Fisch 1969³, Brackmann 1994⁴), but the basic principles remain the same. The technique can also be enlarged as proposed by Wigand et al.⁵ or even extended as described by Kanzaki et al.⁶ for larger tumours.

The major indication for the middle fossa approach is the resection of small intra-/ extracanalicular vestibular schwannomas without contact to the brainstem (Fig. 3.4.1) in patients with good hearing. Another less frequent indication is vestibular neurectomy or decompression of

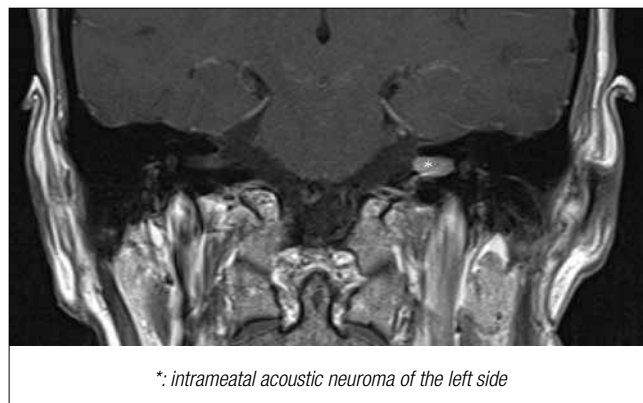


Fig. 3.4.1. Coronal MRI (T1 sequence with contrast enhancement). Dpt. of Neuroradiology, University Hospital of Würzburg, Germany; Chair: Prof. Dr. M. Pham.

the internal auditory canal (IAC) in neurofibromatosis 2 (NF2) patients.

Hearing and facial nerve preservation

The middle fossa procedure is a hearing-preservation approach. It has been shown that hearing preservation is possible for the vast majority of patients, with about two thirds of the patients keeping their good hearing (class A+B according to AAO-HNS⁷) function postoperatively⁸⁻¹⁰. Besides preservation of good functional hearing, the preservation of facial nerve function is also very important. In small tumours using hearing preservation procedures, about 90-95% of the patients retain good facial nerve function (class HB1+2 according to the House-Brackmann scale¹¹)^{12,13}. Due to necessary microsurgical manipulations during separation of tumour tissue from the facial nerve, early postoperative facial nerve weakness is common (in about 30% of the cases directly postoperatively^{10,12-16}), but this resolves in most cases within the first three months.

These excellent results in function preservation were enabled by appropriate intraoperative monitoring techniques. We use continuous facial nerve monitoring with fine wire needle electrodes placed into the m. orbicularis oris and m. orbicularis oculi (e.g. Neurosign 100, Magstim Company Ltd., Whitland, UK). Auditory Brainstem Response (ABR) monitoring is also continuously recorded via self-adhesive electrodes during surgery (e.g. Nicolet Viking, Viasys Healthcare, Madison, WI, USA/Höchberg, Germany). In-ear speakers that are fixed in the outer ear canal with a silicone compound are used to perform acoustic stimulation. If ABR are getting worse during surgery, or if preoperative waves are too small, we extend the monitoring and use a ball electrode (Fig. 3.4.2) for cochlear nerve action potentials (CNAP) after removal of the tumour (e.g. Tyrek® Roll; Johnson & Johnson

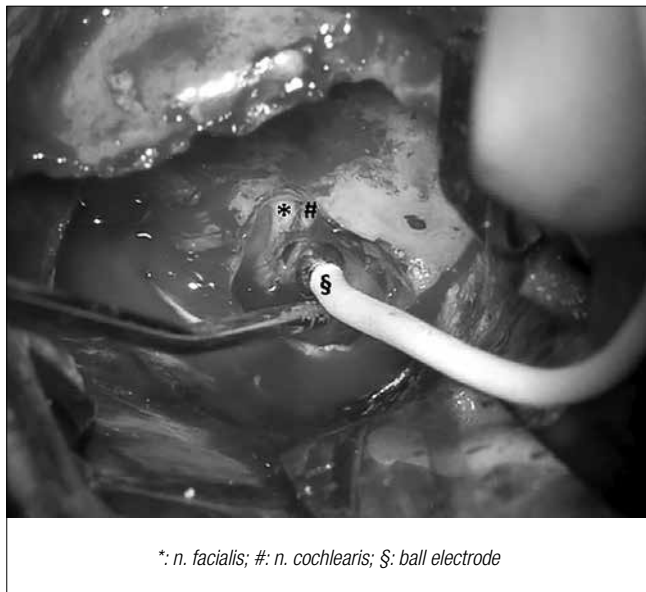

Fig. 3.4.2. Intraoperative CNAP measurements after tumour removal.

Company, Division of Ethicon Inc.; Bridgewater, NJ, USA). This can provide additional important information about the success of hearing preservation¹⁷.

Surgical procedure

The patient is placed in a supine position with the head turned; fixation in a Mayfield head holder is not necessary for a safe MCF procedure. Preoperatively we inject about 15 ml of articain (1%) mixed with epinephrin (1:200,000) for local anaesthesia and reduction of bleeding. Perioperative antibiotic prophylaxis is applied according to current guidelines (usually 2 gr of cefazolin and 500 mg of metronidazole), which can be repeated after 3 hours of surgery. After sterile disinfection, the middle cranial fossa approach begins with a (reverse) question mark-shaped, curved skin incision (also called “lazy S”) starting anterior to the tragus. After incising the fascia, a temporal muscle flap is elevated off the calvarium and rotated laterally using a raspator. Sometimes the temporal artery needs to be ligated. The flaps can be easily retracted with stay sutures. It can also be useful to wrap the skin and muscle flaps in moist gauze to prevent desiccation. At this time, one can already harvest a piece of muscle and store it for closure of the inner ear canal later. At this point in the surgery, 250 ml of mannitol (20%) are applied intravenously by the anaesthesiologist to reduce intra-cranial pressure. After exposure of the squamous part of the temporal bone, a craniotomy of 4 × 3 cm is performed superior to the zygomatic root. The craniotomy is placed two thirds anteriorly and one third posteriorly to the outer ear canal. Various instruments can be used to perform the craniotomy.

We prefer a large cutting burr to thin out the bony cortex, and then a diamond burr is used until the dura is exposed. Alternatively, also a piezo surgical instrument or a classical saw can be used. The extracted bone flap is set aside and stored in a bowl covered with moist gauze together with the extracted muscle graft. The graft should not be stored in saline solution, as this would elute the tissue. The sharp edges of the craniotomy should be smoothed using a diamond burr or luer-rongeur forceps to keep the retractors from rocking. After extraction of the bone, the dura of the middle fossa has to be detached from the temporal bone from in a postero-anterior fashion with a sharp raspator or the tip of sharp scissors. Bipolar cautery can also be used to shrink and contract the dura. Usually this step can be performed very easily without applying too much force. In some cases, the dura is very adherent and extreme attention must be paid in order not to stretch it too much to avoid cerebrospinal fluid (CSF) leakage. Undesirable lateral venous bleeding can be stopped by temporarily applying neurosurgical swabs soaked with articain/epinephrin, or by packing the bleeding vessels with oxidized cellulose (e.g. Tabotamp®). Afterwards, the self-retaining retractor can be placed. We use the House retractor modified by Ugo Fisch to lift the temporal lobe. The blade of the retractor is placed at the margo superior of the petrous bone sparing the superior petrosal sinus and then fixed to the retractor. At this stage, the most important two landmarks have to be identified: the canal of the major petrosal nerve and the superior semicircular canal, which is often outlined by the so-called arcuate eminence. The bone of the superior semicircular canal is carefully removed using a diamond burr until the perilymphatic space (“blue line”) is identified. Sometimes the exposition of the blue line is impeded by a missing acute eminence due to compact surrounding bone or pneumatized cells^{18 19}. Opened cells have to be carefully sealed before completing the surgery in order to avoid CSF leakage. Anterior to the blue line, the geniculate ganglion can be exposed, if necessary. The roof of the internal auditory canal is completely removed from the fundus to the porus and the intrameatal dura is exposed. Particular care must be taken when dissecting the lateral end of the IAC since the basal turn of the cochlea is very close. An additional bony landmark should be identified at the fundus of the IAC, the crista verticalis (“Bill’s Bar”), which separates the beginning of the facial canal and the area of the superior vestibular nerve. Subsequently, the intrameatal dura is incised and dissected up to the cerebellopontine angle. Now the facial nerve can be visually and electrically identified using the stimulation probe. Depending on the origin of the tumour, which can arise either from the superior or – much more often – the inferior vestibular nerve, the surface of the tumour comes into vision. In very small

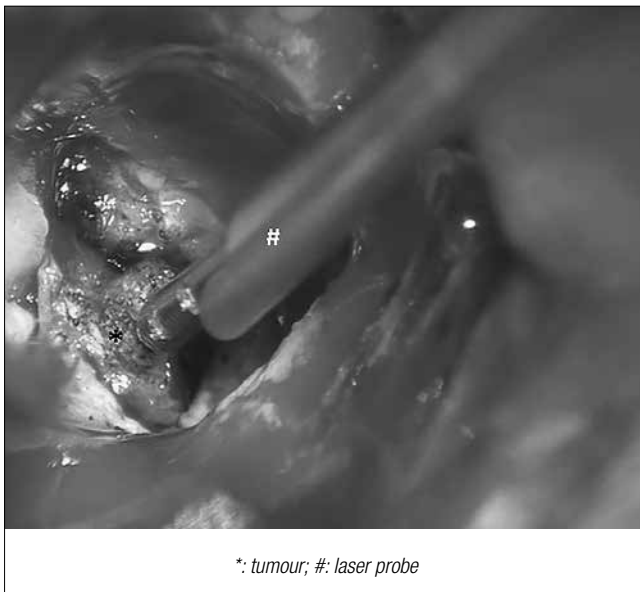

Fig. 3.4.3. Intraoperative contactless laser resection.

tumours, the superior vestibular nerve can be separated and preserved. In larger tumours the facial nerve already might be flattened or thinned out by the growing tumour. The cochlear nerve is always inferior to the facial nerve, but cannot be visualized at this point of the surgery as the tumour mass blocks the direct view to the nerve in most cases. A representative portion of the tumour should always be assessed for histopathological examination. Next, the tumour mass is debulked. This procedure can be done using classical bipolar ring forceps. Alternatively we prefer to use a flexible CO₂ laser fibre (Omniguide® Inc., Lexington, MA, USA), as this allows for a contactless tumour resection (Fig. 3.4.3) without damaging the facial or the cochlear nerve, which run alongside the surface of the tumour²⁰. Parts of the tumour can be luxated using a small 45° hook. Residual tumour parts contacting the facial and the cochlear nerve have to be sharply dissected with neurectomy scissors or a sickle knife.

If intraoperative monitoring of hearing is not possible due to poor ABR preoperatively, or if a relevant reduction in the morphology of the elicited waves during tumour removal occurs, direct cochlear nerve action potentials (CNAP) can be registered using a small ball electrode.

Finally, intracranial haemostasis has to be ensured before closure of the site. The inner ear canal is sealed with a piece of temporal muscle or abdominal fat in combination with fibrin glue. It is still very controversial whether fat²¹⁻²³ or muscle²⁴⁻²⁶ is better in this task. The selection of materials depends on both surgeon's preference and experience. In our opinion, muscle is safe enough and efficacious in MCF cases in which only small defects have to be plugged. All

opened temporal bone cells have to be sealed meticulously using either bone wax or fibrin patches to avoid CSF leakage. Furthermore, the bony flap has to be replanted. Fixation of the flap can be performed with titanium microplates, resorbable sutures or plates, or simply by sticking it back into position with the help of fibrin glue and fibrin sealant patches (e.g. Tachosil®). When extensive drilling was necessary to enlarge the craniotomy, the flap sometimes does not cover the defect completely. Some authors recommend using porous polyethylene implants (e.g. Medpor®) in this situation, but we avoid to use any synthetic material. In fact, we observed that even larger gaps close spontaneously by osteogenesis over the course of time.

To allow an adequate postoperative wound drainage, a small suction drain is placed between the dura and the bone. Wound closure is performed by continuous sutures of the temporal muscle in two layers, followed by interrupted sutures of the subcutaneous tissue and a continuous skin closure. Finally, a soft pressure dressing is applied. The patient is monitored at the intensive care unit for one night. The suction drain is removed on the second or third postoperative day.

Complications

Although complications are rare, it is very important to know how to deal with them routinely, especially since hearing preservation surgery is increasingly recommended for small tumours. The most common complication of the MCF approach is cerebrospinal fluid leakage, which can occur in more than 10% of patients²⁷⁻³⁰. In most cases, it starts within the first few postoperative days, but sometimes there is a delay of even several weeks after discharge of the patient. CSF leakage is observed as a leakage into the wound or suction-drainage, or more often as posterior rhinorrhoea. It is typically the result of spinal fluid escaping through aerated petrous bone cells. The existence and opening of well-pneumatized temporal bone cells above the IAC and the superior semicircular canal is a reliable predictor for postoperative liquorrhoea³¹. In contrast to others³²⁻³³, we could demonstrate that stepwise conservative treatment is successful in most cases³¹. This includes bedrest, pressure dressings and i.v. antibiotics, and leads to spontaneous suspension of liquorrhea in up to 70% of cases³¹. If not, the next step would be to place a spinal lumbar drainage. Only if these nonsurgical steps are unsuccessful, surgical re-exploration is indicated. Fortunately, more severe complications such as haemorrhage, meningitis or pulmonary embolisms that can be lethal are very rare. Overall, mortality following MCF surgery for acoustic neuroma removal decreased within the last 5 decades below 1%, which was confirmed in different large series²⁷⁻³⁴⁻³⁶.

Conclusions

Middle cranial fossa approach offers a safe access for removal of small acoustic neuromas without contact to the brainstem. By consequent use of important technical refinements (e.g. monitoring, laser) it became possible to achieve excellent functional results in hearing and facial nerve preservation over the last decades.

3.5. The pterional approach

V. Baro, A. Landi, L. Sartori, L. Denaro, D. d'Avella

Introduction

Pterional craniotomy is one of the most long-lived approaches in neurosurgical practice, thus representing an cornerstone of the anterior and medial cranial fossa surgical corridor. Its history started in the early '900 when Heuer ¹ developed the first frontotemporal craniotomy. Furthermore, across many decades, this elegant cranial approach incurred several modifications and finally has been popularized by Yasargil ² in the second half of the last century ³.

This approach is one of the most versatile and useful in neurosurgery because it limits brain manipulation and retraction, reducing complications ^{4,5}. In fact, this approach cleverly exploits cerebrospinal fluid (CSF) pathways to reach the surgical target located in the skull base: the Sylvian fissure and the adjoining basal cisterns.

Indications

This approach enables the exposure of lesions affecting the frontal and temporal lobes, the insula, the uncus and the Sylvian fissure; the circle of Willis and the cavernous sinus area; the anterior and middle cranial fossa (orbit, sphenoidal and ethmoidal regions); sellar and suprasellar lesions and the mesencephalus ⁶.

- Aneurysms and vascular malformations arising mostly from the anterior part of the Willis polygon and, less commonly, from the posterior circulation (e.g. basilar apex aneurysm).
- Anterior skull base meningiomas (e.g. olfactory groove meningioma, tuberculum sellae meningioma, sphenoid wing or plenum sphenoidalis meningioma, cavernous sinus meningioma) or deep Sylvian fissure meningioma.
- Diffuse gliomas or metastases located in the frontal lobe, temporal lobe and insula.
- Selective amigdalohyppocampectomy for refractory epilepsy.
- Congenital pathologies of the frontotemporal region (e.g. arachnoid cysts).

Positioning and preparation

The patient is placed supine with the shoulders at the edge of the surgical table. A three-pin fixation device is used to affix the head to the table. The single pin of the head fixator may be placed in the contralateral frontal area (forehead) or, alternatively, above the ipsilateral mastoid process with the two pins in the frontal area (at a similar height). In general, the pin(s) should not be placed near the skin incision or into the temporalis muscle (TM). Then there are three movements to position the head: lifting, rotation and extension. First, the head is lifted above the level of the heart to facilitate venous drainage. Rotation and extension movements depend to the location and type of lesion: 30 degrees of rotation are needed for posterior exposure (e.g. posterior communicating artery, carotid bifurcation, and basilar tip aneurysms), 45 degrees of rotation allow a middle exposure (e.g. middle cerebral artery aneurysms whereas 60 degrees of rotation are required for an anterior exposure (e.g. anterior communicating artery aneurysms, suprasellar tumors). The extent of rotation also determines the need for ipsilateral shoulder lift to reduce neck torsion and therefore jugular vein occlusion. The final maneuver places the zygoma as the highest point in the surgical field, tilting the vertex backward toward the floor.

Skin flap

The skin incision extends from the root of the zygoma, approximately 1-1.5 cm anterior to the tragus to the midline in a curvilinear fashion, just behind the hairline (Fig. 3.5.1).

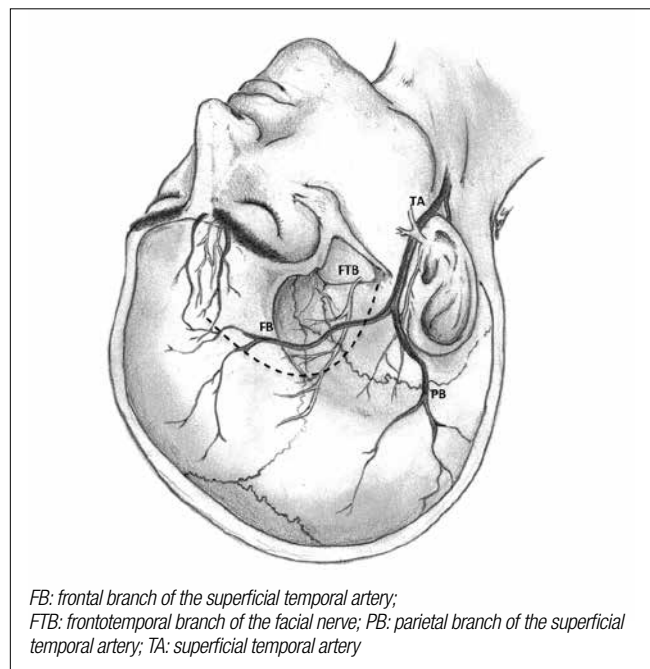


Fig. 3.5.1. This drawing shows the skin incision with the relevant neurovascular anatomy.

We usually shave only a corridor of hair 2 cm along the planned incision line, combing the hair with chlorhexidine. The skin incision is made with a scalpel as deep as the superficial layer of the temporalis fascia (STF), carefully at the level of the zygoma, to preserve the common trunk of the superficial temporal artery (STA) ⁷. It is crucial to preserve some blood supply (at least one of the major trunks of the STA) to the TM to reduce the risk of muscle atrophy, masticatory dysfunction and temporomandibular joint pain ⁸. When the STA is needed for a bypass, the artery and its main branches are mapped with Doppler ultrasonography (or with neuronavigation system) before the incision. Another insidious structure is the frontotemporal branch (FTB) of the facial nerve, which is exposed to damage both by direct injury during the approach, and by traction due to the retraction of the skin flap. Its damage could be disfiguring because the FTB innervates the orbicularis oculi, frontalis, and corrugator supercilii muscles, resulting in a paralysis of the eyebrow ⁹⁻¹¹. Indeed, one of the goal of modern neurosurgical approaches is to ensure the best functional and cosmetic results for the patients.

Temporalis muscle dissection

This step hides some neurovascular pitfalls, as previously highlighted. Currently, there are three main techniques used to dissect safely the temporal muscles: the interfascial dissection, the myofascial (one-layer) technique and the osteoplastic craniotomy.

Interfascial dissection

This technique is used especially when a wide anterior exposure, toward the zygomatic arch, is needed. The dissection starts approximately 4 cm above the lateral orbital rim, at the upper edge of the interfascial fat pad. The incision extends in depth all the way to the deep layer of the TM fascia, parallel to the ascending part of the skin incision. The fat pad, which contains the FTB, is carefully dissected and reflected anteriorly over the skin flap. The deep layer of the fascia is incised at the same level, from the root of the zygoma to the superior temporal line (STL) ¹²⁻¹⁴. Generally, a superior cuff of fascia is preserved over the STL on the bone. In fact, this will enable re-approximation of the TM during closure. The incision is carried inferiorly and finally the TM, its adherent fascia and periosteum are dissected, using a periosteal elevator or a Penfield dissector. Monopolar cautery should not be used to preserve the vascularization of the subperiosteum, preventing TM atrophy ¹⁵.

Myofascial (one-layer) technique

The TM is incised from the ascending limb of the skin incision down to the bone, the incision is then carried along the STL and finally downwards. The TM is dissected from the bone, as previously mentioned, and reflected anteroinferiorly together with the skin flap. The bulk of the

TM could limit the inferior exposure but the retraction with fishhooks usually reduces this drawback ^{16,17}. Preservation of a superior cuff of fascia, together with a blunt dissection, are considered necessary measures to achieve a proper muscular healing ¹⁵.

Osteoplastic craniotomy (OC)

This technique has been developed to answer the crescent need for excellent cosmetic results, especially in elective surgery and in young patients. The TM is retained over the bone but dissected and elevated only from its frontozygomatic attachment. The craniotomy is then performed from a burr hole placed anteriorly and superiorly to the STL, encircling the TM and ending at the posterior zygomatic root. The final osteotomy is carried under the subperiosteal tunnel and finally the osteoplastic flap is reflected anteroinferiorly, hinged on the frontozygomatic attachment of the TM ¹⁸⁻²⁰.

Craniotomy

The purpose of the craniotomy is to widely expose the Sylvian fissure and the surrounding frontal and temporal lobes. The burr holes required for the craniotomy vary between various authors, ranging from one ^{16,21} to three ²². The number of holes also depend from the underlying pathology: 1) between the STL and the frontozygomatic suture, behind the orbital rim (key hole); 2) at the inferior temporal fossa, just above the root of the zygoma; 3) at the posterior part of the STL (if a greater exposure of the fissure is needed, e.g. for middle cerebral artery aneurysms).

The dura mater is dissected at the level of the burr holes with a Penfield dissector n. 3 and the craniotome is used to cut the bone flap, joining the burr holes (Fig. 3.5.2). Usually the sphenoid ridge is too prominent, stopping the craniotome from advancing. In the latter case, superficial drilling of the lateral surface of the greater sphenoid wing allows fracturing of the bone with a periosteal elevator. The free bone flap is carefully separated from the underlying dura and removed. The next step involves drilling, which completes the extent of bony removal. The dura mater is dissected off the sphenoid wing and the sphenoid ridge and thus removed with a high-speed drill towards the superior orbital fissure. The extent of drilling is different depending on the pathology. Extradural drilling may include an anterior clinoidectomy and the removal of the remaining part of the squama temporalis.

Dural opening

The dura mater is incised in a curvilinear, anteriorly based fashion. Peripheral dural sutures are placed to lift up dural edges in order to prevent ooze bleeding from the epidural space. It is important to limit dural coagulation and to keep the dura wet with irrigation during the surgery, to minimize its retraction.

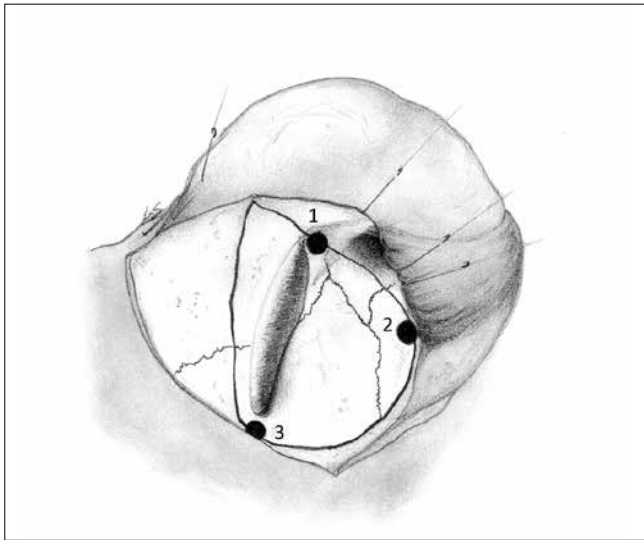
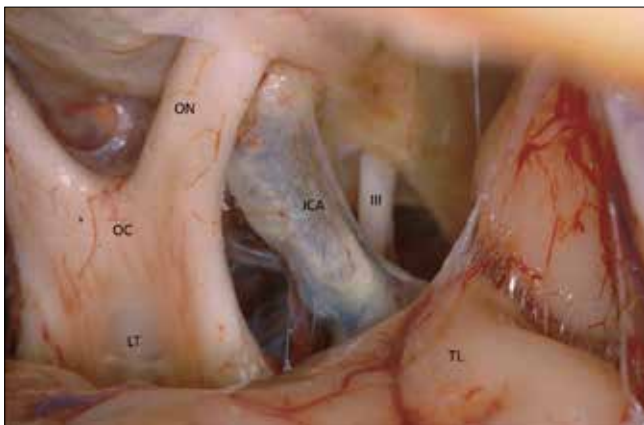


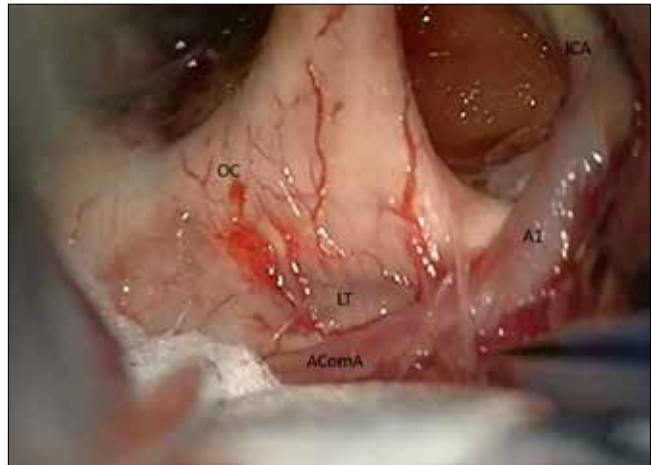
Fig. 3.5.2. Exposure of the pterional region afforded by inferior retraction of the musculocutaneous flap with the three burr holes, immediately before the realization of the bone flap. 1: the key hole burr hole, 2: the temporobasal burr hole, 3: the burr hole placed at the posterior part of the superior temporal line. A superior cuff of temporalis fascia is preserved over the bone to ease muscular suture during closure.

The approach proceeds under microscopy, with the opening of the Sylvian fissure and the basal cisterns to relax the brain by removing CSF. This step is fundamental to minimize the use of retractors and to ease the splitting of the fissure. The quantitative dissection of the Sylvian fissure depends from the underlying pathology. Figure 3.5.3 (cadaveric) and Figure 3.5.4 (intraoperative) show a view of the anterior cranial fossa, reached after the complete opening of the fissure.



III: third cranial nerve; ICA: internal carotid artery; LT: lamina terminalis; OC: optic chiasma; ON: optic nerve; TL: temporal lobe

Fig. 3.5.3. Cadaveric picture showing the neurovascular anatomy after the opening of the Sylvian fissure, anterior exposure.



A1: anterior cerebral artery; A-ComA: anterior communicating artery; ICA: internal carotid artery; LT: lamina terminalis; OC: optic chiasma

Fig. 3.5.4. Intraoperative view showing the neurovascular anatomy after the opening of the Sylvian fissure, anterior exposure.

Closure

Dura mater is closed with running 4-0 not absorbable suture in a watertight fashion, after abundant irrigation of the surgical field in order to check final hemostasis and to reduce pneumocephalus. The closure should be strengthened with dural substitutes or with galea capitis grafting and fibrin glue when a complete closure is not possible (mostly due to dura retraction during surgery or for extensive bipolar coagulation). Circumferential tack-up sutures are placed through small holes at the bony edges and a central tack-up suture is placed in the bone flap, to prevent epidural bleeding. The bone flap is reattached with a titanium plate (at least three) and screws. The bony defect created from the removal of the inferior temporal bone can be filled with bony substitutes (hydroxyapatite, methyl methacrylate) or with a titanium mesh. The TM and fascia are reapproximated in separated layers.

3.6. The infratemporal A (and B, C, D) approach

R. Pareschi

This approach allows a wide access to the jugular foramen, the infralabyrinthine area, the vertical intrapetrous carotid artery (C1 and C2 segments) and the upper retrostyloid spaces. It can be enlarged anteriorly to the petrous apex and to the middle-lower clivus by drilling out the cholea and the bone located medially to the internal carotid artery, or posteriorly into the cerebello-pontine angle by transecting the dura of the posterior cranial fossa.

This approach is indicated for extensive extra-intradural tumors involving the aforementioned anatomical regions.

The cornerstone of the approach is the anterior rerouting of the facial nerve, from the geniculate ganglion to its main intraparotid branches.

Neurovascular surgical anatomy

- The vertical tract of the facial nerve runs straight down from its second turn to the stylo-mastoid foramen and is centred on the jugular bulb, which lies medially and anteriorly to the nerve.
- The periostium of the skull-base forms a thick ring around the internal jugular vein as the latter structure exits the jugular foramen.
- The medial aspect of the jugular bulb is a wall of periostium presenting multiple entrances of the inferior petrosal sinuses.
- The condylar emissary vein drains into jugular bulb in 2/3 of the cases. It is exposed together with the hypoglossal nerve when drilling out the condylar process of the occipital bone.
- The lower cranial nerves (IX, X, XI), run together through the medial thick wall of the jugular bulb (pars nervosa) when exiting from the skull-base into the upper neck.
- The IX cranial nerve is the most lateral and anterior while the XI cranial nerve is the most medial and posterior.
- The ascending pharyngeal artery passes through the jugular foramen to supply the dura of the posterior fossa.
- The IX cranial nerve crosses anteriorly the internal carotid artery.
- The XII cranial nerve turns inferiorly to run together with the X cranial nerve for a short tract in the upper neck. More inferiorly the XII cranial nerve crosses the external carotid artery to then move anteriorly towards the tongue. The X cranial nerve runs between the internal jugular vein and the internal carotid artery.
- The XI cranial nerve crosses the lateral wall of the internal jugular vein in 50% of the cases, anterolaterally to C1.
- The styloid process and the muscles inserted on it are lateral to the internal carotid artery at its entrance at the foramen caroticum.

Surgical technique

- A retroauricular “C” shaped incision is made from 3 cm above the helix to 2 cm below the tip of the mastoid (Fig. 3-6.1).
- The external auditory canal is transected at the bony-cartilaginous junction. The skin of the canal is raised from the cartilage and the edges are reverted and sutured as a cul de sac. In addition, a pedicled tragal flap is created as a second layer for the closure of the external auditory canal (Fig. 3.6.2)
- A wide reversed “U” shaped mioperiosteal flap with a

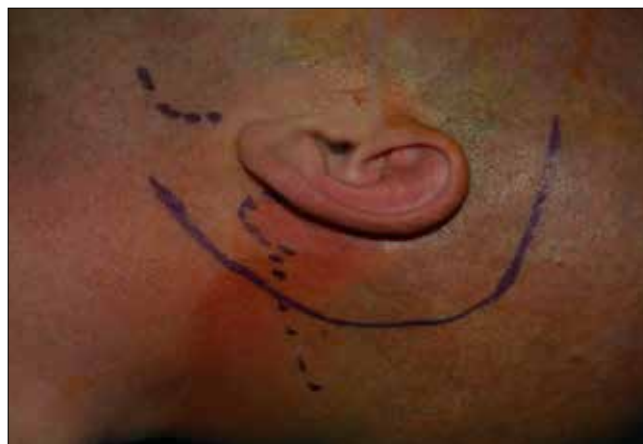

Fig. 3.6.1. The retroauricular “C” shape incision. The extension to the neck is interrupted at 2 cm below the mastoid tip.

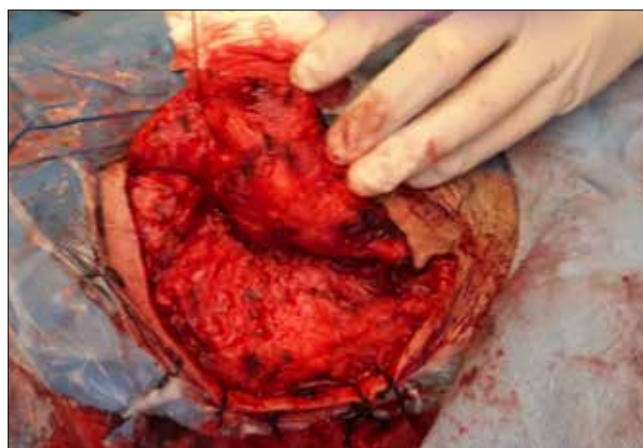


Fig. 3.6.2. Closure of the external auditory canal with a pedicled tragal flap.

cervical root is raised. The flap is formed by the nuchal and mastoid insertions of the posterolateral muscles of the neck and by the periosteum and galea of the petro-occipital region. The temporal muscle is left in place.

- The facial nerve is found at its exit from the stylo-mastoid foramen and dissected from the parotid tissue until the main branches of the nerve are identified.
- The posterior belly of the digastric muscle is elevated from the digastric groove. The internal jugular vein and internal and external carotid arteries, the IX, X, XI and XII cranial nerves are identified in the neck and followed upwards until their exit from the skull-base after the removal of the styloid process and the anterior dislocation of the muscles inserted on it.
- The skin of the external auditory canal, the tympanic membrane, the malleus and incus are removed.
- A wide radical mastoidectomy is performed and the

bone that lies anteriorly, superiorly and posteriorly to the sigmoid sinus is completely drilled out from to expose the transverse sinus until the jugular bulb.

- The facial nerve is skeletonised from the stylo-mastoid foramen to the geniculate ganglion by removing all the overlying bone.
- The tympanic bone, the mastoid tip and the bone between the posterior semicircular canal and the jugular bulb is widely drilled out.
- The sigmoid sinus, the jugular bulb and the internal jugular vein are put in continuity by removing the bone located inferiorly to the jugular bulb (condylar process of the occipital bone).
- A new bony canal is drilled in the root of the zygoma.
- The facial nerve is freed at the stylomastoid foramen leaving the surrounding soft tissue around it.
- The mastoid and tympanic segments of the nerve are now elevated from the fallopian canal until the geniculate ganglion is reached.
- The anterior rerouting of the facial nerve is completed in continuity with the intraparotid tract (Fig. 3.6.3). This delicate manoeuvre is the key point of the infratemporal approach type A. It allows access to the medial compartments of the petrous bone (the infralabyrinthine and inframeatal area, the vertical and horizontal canal of the carotid artery, the petrous apex and the lower and middle clivus).
- The mandibular condyle is anteriorly displaced and separated from the anterior wall of the external auditory canal that is completely drilled out to expose the vertical portion of the internal carotid artery.
- The internal jugular vein in the neck is ligated and transected whilst the sigmoid sinus is packed with intraluminal surgicel.
- The internal jugular vein is elevated upwards without

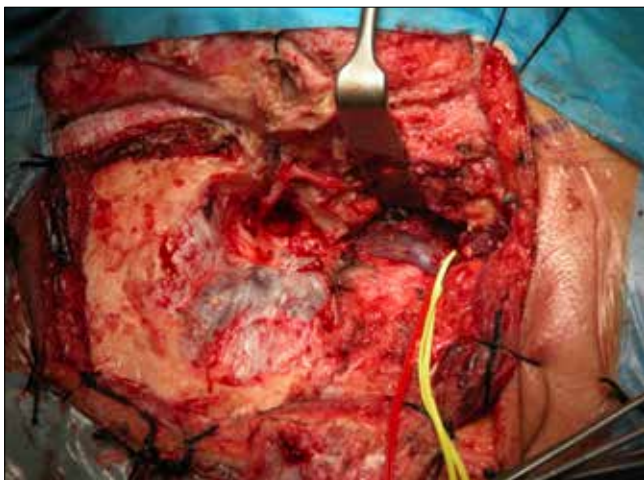


Fig. 3.6.3. Surgical field after the rerouting of the facial nerve.

injuring the lower cranial nerves under the XI cranial nerve.

- The lateral wall of the jugular bulb is opened and bleeding occurring from the opening of the inferior petrosal sinus is controlled with surgicel.
- Particular attention must be taken in not injuring the medial wall of the jugular bulb where the lower cranial nerves are located at their exit from the skull base.
- At this point tumour removal begins. The infiltrated bone of the fallopian canal and of the tympanic bone is drilled out and the tumour is removed from the posterior dura. The tumour is removed from the jugular bulb area and the infiltrated infralabyrinthine cells are drilled. The sigmoid sinus and the internal jugular vein are now opened and the tumour, if present, is removed. The tumour, when possible, is separated from the lower cranial nerves. This can be accomplished for small C1 tumours. For C2-C3 tumours, the sacrifice of the lower cranial nerves is necessary if total removal is the goal of surgery.
- The internal carotid artery must be identified after extensive drilling of the infiltrated tympanic bone and bipolar cauterization of the tumour around the artery is necessary. Further drilling of the infiltrated infralabyrinthine apical cells, and of the clivus allows a complete exposure of the tumour that is bluntly dissected from the artery following a subperiosteal plane (between the periosteum of the carotid canal and the adventitia of the artery). Sub-adventitial dissection must be strongly discouraged to avoid dangerous pseudoaneurisms of the vessel which may lead to subsequent thrombosis.
- The posterior dura is now opened and even a huge (> 2 cm) intradural portion of the lesion can be removed in a single-stage fashion together with the extradural tumour.
- A translabyrinthine extension, which would allow further medial and superior exposure is unnecessary. A petro-occipital trans-sigmoid approach (POTS, the combination of a retrolabyrinthine petrosectomy and a suboccipital craniectomy) is adequate.
- The posterior dura is then transected and the tumour is rather easily dissected from the anterior inferior cerebellary artery (AICA), posterior inferior cerebellary artery (PICA), vertebral artery and from the facial-acoustic bundle (Fig. 3.6.4). Dissection of the lower cranial nerves from the tumour, even if their anatomical preservation is achieved, will result in a pharyngolaryngeal palsy.
- The major risk of opening the intracranial compartments and putting them in continuity with the petro-occipital area and the spaces of the upper neck is to have a subcutaneous collection of cerebro-spinal fluid (CSF) and/or a cutaneous CSF leak at this level. The latter fact could lead to life-threatening infectious complications.

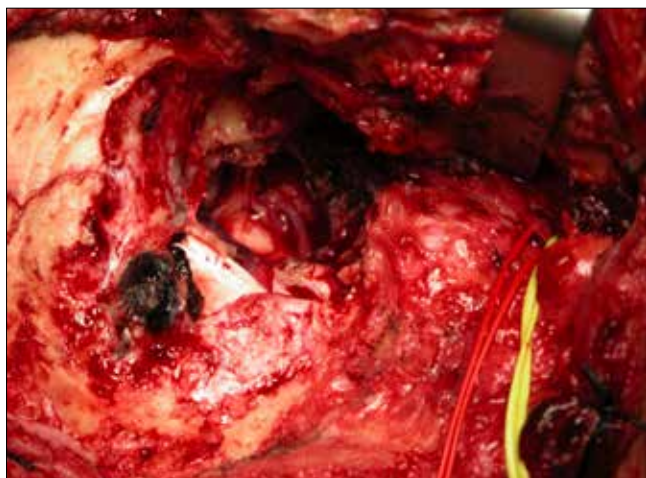

Fig. 3.6.4. Surgical field after the transection of the posterior fossa dura.

This risk can be avoided by taking care to: 1) minimize the exposure of the upper neck. The incision must stop 1-2 cm below the mastoid tip. The internal jugular vein is ligated just anteriorly to C1 and the internal carotid artery must be exposed at the level of the styloid process; 2) watertight closure of the “U” shaped muscular-periosteal flap raised at the beginning of the procedure.

Infratemporal B, C, D approaches (ITb, ITc, ITd)

While the ITa approach extends dorsally from the carotid artery up to the petrous bone, the cerebello-pontine angle and the parapharyngeal space, the ITb and ITc extend ventrally from the carotid artery to the petroclival bone, the rhinopharynx and the infrasphenotemporal space. These are extradural approaches and do not allow intradural work. Their gate of entry excludes the external auditory canal and the tympanum together with the Eustachian tube in order to reach the vertical and horizontal segments of the carotid artery, and thus the petrous apex, the clivus (b) or the rhinopharynx (c). A temporal craniotomy opens the surgical corridor superiorly. The facial nerve is left in situ. Chordomas of the clivus, which require large bony removal, or residual-recurrent carcinomas of the rhinopharynx are the common indications to infratemporal B and C approaches, respectively. The preauricular subtemporal-infratemporal approach was described by Sekhar, and it is also called infratemporal type D approach. It runs anteriorly to the external auditory canal and preserves the Eustachian tube. It is directed to the lateral infratemporal fossa, the pterygopalatine fossa and the orbital apex.

3.7. The petro-occipital transigmoid approach (POTS)

A. Mazzoni, D. Cazzador, E. Zanoletti

Generalities on the jugular foramen in skull base surgery

The jugular foramen (j.f.) is the largest transition channel from the intradural endocranium to esocranial skull base face and neck. It is composed by different tissues, each one having different interaction with the histotypes of the different lesions. Meningioma, paraganglioma, schwannoma interact differently with bone, nerves, dura and vessels. This involves a specific modality of surgery both as approach and resection. Bone, that is the petro-occipital bone, is the place where the variable relation between histology and site of lesion is most obvious.

The infratemporal approach type A is the traditional corridor to the jugular foramen (Fig. 3.7.1). It allows resection of tumors located in the jugular foramen, a wide connection with the neck, a good control of the vertical carotid artery up to its first genu and the beginning of its horizontal tract. The anterior transposition of the facial nerve, the exenteratio of the middle ear and drilling of the labyrinth are the planned surgical steps which allow, as well as the visualization of structures, the adequate working space so as to drill as much of bone as required by the pathology. The lateral corridor of the infratemporal A may be replaced

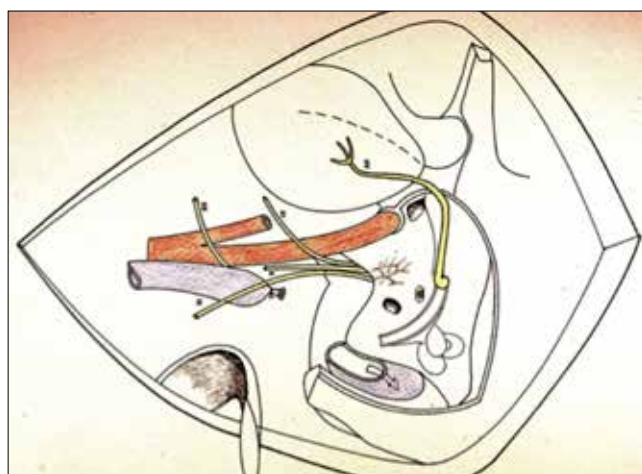


Fig. 3.7.1. The left infratemporal A approach involves the removal of the external auditory canal, the middle ear, the anterior transposition of the facial nerve from the fallopian canal. The labyrinth may be left in place or removed, if required. This allows a complete visualization of the jugular foramen, the vertical carotid artery and space is left for surgical manoeuvres in the jugular foramen area. The sigmoid sinus is transected and the presigmoid dura may be opened to enter the posterior fossa. The connection with the petrous cavity and the neck is wide and allows control of the tumor in the soft tissues and in the bone.

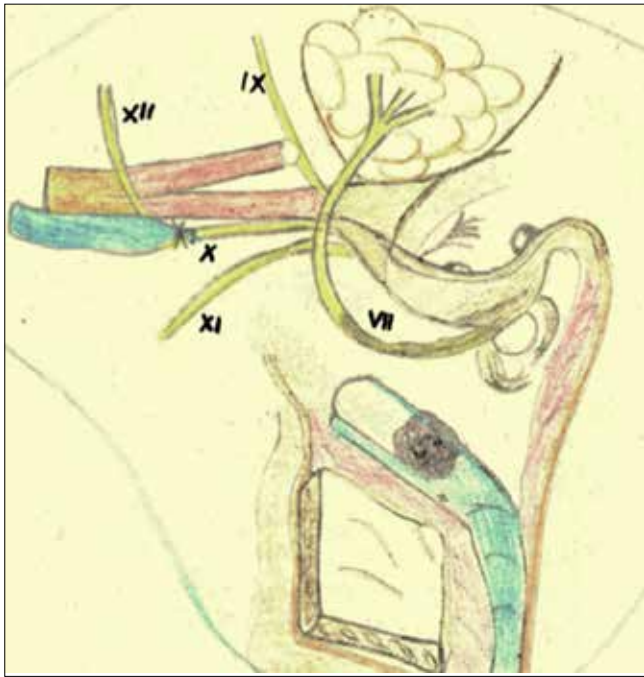


Fig. 3.7.2. The left POTS approach involves the preservation of the external auditory canal, the middle ear, the facial nerve in its Fallopian canal. The labyrinth is left in place. This allows a visualization of the jugular foramen, the vertical carotid artery is hidden and the space left for surgical manoeuvres in the jugular foramen area is reduced, by the presence of the posterior wall of the external ear and the facial nerve in situ. The sigmoid sinus is transected and the presigmoid dura may be opened to enter the posterior fossa. The connection with the petrous cavity and the neck is wide and allows control of the tumor in the soft tissues and in the bone. This more posterior and conservative approach needs the addition, as described in the text, of a retrosigmoid craniotomy to widen the corridor and allow exposure of the posterior fossa.

by a more posterior corridor, which does not involve the sacrifice of the middle ear, and labyrinth, the cul-de-sac closure of the external auditory canal and the anterior transposition of the facial nerve (Fig. 3.7.2). This reduces enormously the morbidity of the approach to the jugular foramen, since the facial nerve is left in situ and hearing is completely preserved as well as the natural aesthetic contour of the ear and head. The drawbacks of this less extensive and more conservative approach is not the visualization of the jugular foramen, neither the connection with the neck, but the working space in the bone around the jugular foramen, which is reduced and prevented by the facial nerve, the external and middle ear and labyrinth in situ. The amount of bone which is to be removed is dictated by the pathology. In paraganglioma is more than the involvement of the neurovascular structures of the jugular foramen and extensive drilling requires a wider exposure than as allowed by petro-occipital trans-sigmoid (POTS) approach. The internal carotid artery may be reached by

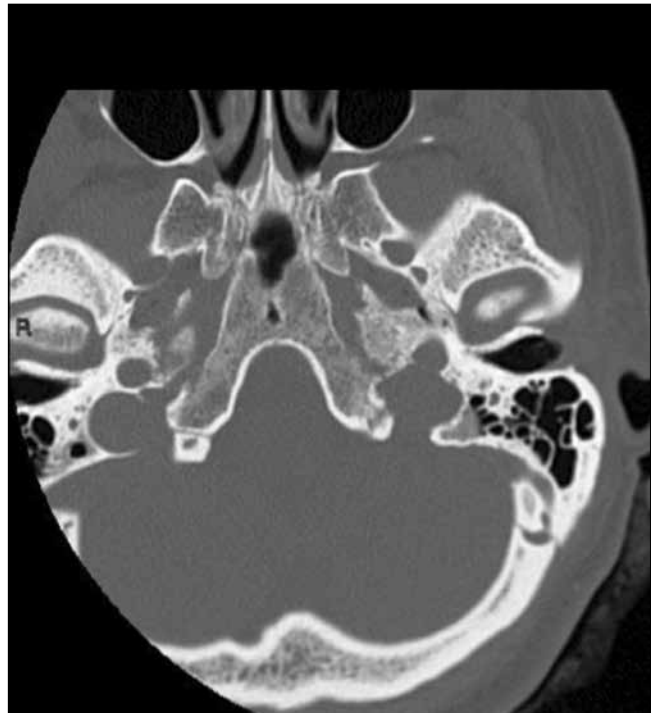

Fig. 3.7.3. Jugular foramen paraganglioma, C2. The CT bone scan shows erosion of the vertical tract of the carotid artery: this should orient the surgeon to consider infratemporal A approach to allow an adequate resection of tumor with the least risk of microscopic residual disease. A POTS approach is feasible, when a planned deliberate incomplete removal is considered or the risk of microscopic disease is accepted.

POTS too, visualized (Fig. 3.7.3), but drilling up to its genu is endangered by the posterior wall of the external auditory canal, the labyrinth and the facial nerve in situ. This is why a C1 paraganglioma might be approached by a POTS, but C2 paraganglioma (which involves erosion of the bone of the vertical tract of the internal carotid artery) cannot be removed around the carotid artery without the risk of residual disease. When the diagnosis is schwannoma of the jugular foramen, or low-aggressive chondrosarcoma, or meningioma, the amount of bone which should be drilled is less than in paraganglioma and POTS approach may be the choice. Being the jugular foramen paraganglioma the most frequent lesion to be treated at this site, the choice between infratemporal A and POTS depends on the C1-C2 classification of the tumor. The N (neck) and intracranial (D) extra (De) or intradural (Di) extensions of the tumor are not conditioning factors in favour of one approach or to the other one, since both approaches allow intradural resection of tumor in the posterior fossa, also at its lower aspect. In principle, the intradural resection of tumor may be performed in a single stage procedure in POTS, while a staged approach is advised in infratemporal A, since a wide connection between the neck and the

intradural compartment exposes the latter more to the risk of CFS leak.

When the disease is benign and slow growing and the morbidity of surgery on the lower cranial nerves has been balanced, the use of POTS today finds its role in the planned subtotal resections, in partial targeted surgery, even in radical surgery where we accept a higher risk of microscopic residual. The conventional and new percutaneous techniques of embolization of tumors, like in jugular foramen paraganglioma, allow safe and almost bloodless resections of hypervascularized tumors thus increasing the application of this more conservative approach.

Petro-occipital transigmoid approach (POTS a)^{1 2}

The POTS a presents a postero-lateral entry, while the ITa has a lateral entry. This oblique antero-medial direction allows to leave the external auditory canal, tympanum and facial nerve at their natural place. The approach is centered on the jugular foramen and the endocranial and cervical spaces where the lesion grows from the foramen. It is essentially made of a retrosigmoid craniotomy, a retrolabyrinthine petrosectomy and a jugulo-carotid cervicotomy, all combined in a single surgical field. The watertight closure to CSF is obtained by placing a single piece of fat in the petrous cavity. The fat does not migrate to the neck as it is held by the isthmus between the transverse process of C1 and the tympanic bone. The approach exposes the jugular foramen, cerebello-pontine angle, petrous bone, occipital condyle and low clivus, the jugulo-carotid space in the neck. The petrous bone boundary of the surgical space is the posterior wall of the external auditory canal, mastoid Fallopius, posterior aspect of labyrinth and vertical internal carotid artery. Salient steps are as follows:

- wide C shaped retroauricular skin flap, and U shaped fibro-muscular flap rooted at level of C1;
- mastoidectomy with exposure of jugular bulb and sigmoid sinus; the posterior side of the labyrinth and the dura medial to sigmoid are exposed; the condyle can be removed up to its posterior half if required by the lesion;
- lower aspect of mastoid is opened to the neck and the jugulo-carotid space is dissected in continuity with the foramen; this communication is the canon of a cervico-temporal approach;
- the cerebellopontine angle is entered by horizontal sectioning of the dura from the jugular foramen to close the acoustic porus;
- resection of the lesion depends on the histology; from neck to petrous area or viceversa; in transdural lesions, the extradural is mostly removed first, the intradural follows;

- dura is closed with interrupted suture, the fat is placed on the residual dural window corresponding to the jugular foramen, the muscular flap is sutured back.

This single stage transcervical transpetrous approach is a prioritarian choice for schwannoma, meningioma, chondrosarcoma. It involves however a limitation, this is the scarce control of the carotid artery in paraganglioma, which requires a large drilling of the osseous bed of the tumor and a safe control of the latter connection with the carotid wall.

The POTS approach in extradural lesions can enlarge the transit to the neck by drilling the process of C1. Several approaches (transcondylar = drilling the occipital condyle and transjugular = drilling the jugular tubercle) were described in the nineties, all being already contained within the POTS approach, as part of the enlargement of the surgical field.

The advantage of this single stage cranio-cervical transpetrous approach involves a limitation. This is the scarce control of the carotid artery, which is sufficient for schwannoma, meningioma and other lesions^{1 2}, but it is not adequate for paraganglioma, which requires a large drilling of the osseous bed of the tumor and a safe control of the latter connection with the carotid wall.

The POTS approach in extradural lesions assure the transit to the neck by drilling the process of C1. Other approaches (trancondylar, transjugular) were described, all being a part of and contained within the POTS approach.

3.8. Presigmoid retrolabyrinthine approach and variation

I.N. Kanaan

Introduction

The retrosigmoid (RS) approach is the most popular and versatile corridor used for management of a wide spectrum of neoplastic and vascular lesions confined to the cerebellopontine angle (CPA) and its surrounding structures. Most common indications are schwannomas, meningiomas, epidermoids and vascular compressions. This technique represents an evolution of the unilateral suboccipital approach that was credited first to Balance in 1894 and Thomas Annandale for the removal of a vestibular schwannoma in 1895¹. It was successfully performed by Krause using an osteoplastic flap in 1903² and popularized by Dandy in 1934 with a reduction in its related mortality^{3 4}. The approach was refined by McKenzie and Alexander⁵ using a seated position and eventually perfected by Kunze and Rand in 1965 using the microscope. The technique was then complemented with a transmeatal approach in 1965^{6 7}. Middle fossa and

translabyrinthine approaches were promoted by William House in 1961⁸.

The presigmoid-retrolabyrinthine approach was first described by H. Silverstein in 1980⁹ and eventually refined and adopted by other pioneer skull base surgeons for direct access to CPA tumors, treatment of Meniere's disease and placement of auditory brainstem implants¹⁰.

The retrosigmoid (RS) and retrolabyrinthine (RL) approaches can be used independently or combined together with other established approaches such as in the combined presigmoid petrosal approach described by Hakuba¹¹ (later refined and popularized by Fukushima and Almefty among others) to provide a panoramic exposure of Meckel's cave, of the tentorial notch, the petroclival region, the anterolateral aspect of the brainstem and the basilar artery¹²⁻¹⁸. The neuronavigation and the hybrid use of endoscopy jointly with microscope surgery have reduced the need for complex skull base exposures.

Approach selection

The main factors that influence the choice of the surgical approach to CPA lesions are: nature, location, size and extent of the lesion, presence of intra-canalicular growth, baseline hearing function as well as patient's and surgeon's preference and experience. Variation of temporal bone anatomy, its aeration, the measure of Trautmann's triangle, the petrous slope, and position of the sigmoid sinus may impact the choice for a presigmoid retrolabyrinthine (RL) approach in favor of a combined presigmoid approach^{19,20}.

Indication

CPA region may be affected directly or indirectly by various neoplastic or vascular lesions. The name of the anatomical site was coined by Hellenberger and Kock in 1800 and was later named the "bloody angle" by Harvey Cushing, referring to its surgical complications²¹. The detailed cisternal and 3D-anatomy of the CPA were elegantly described by Yasargil and later by the masterpiece work of Rhoton^{22,23}. Retrosigmoid approach (RS) with hybrid use of endoscopy or the combined presigmoid retrolabyrinthine petrosal approach are the most commonly used neurosurgical approaches for successful treatment of the following conditions.

Surgical steps

Presigmoid-retrolabyrinthine combined petrosal approach (Modified Hakuba Approach).

Position

The author favors the park bench position (Fig. 3.8.1), the same as for the retrosigmoid approach but with no head flexion. This position facilitates gravitational CSF leakage, minimizes blood pooling in the surgical field and

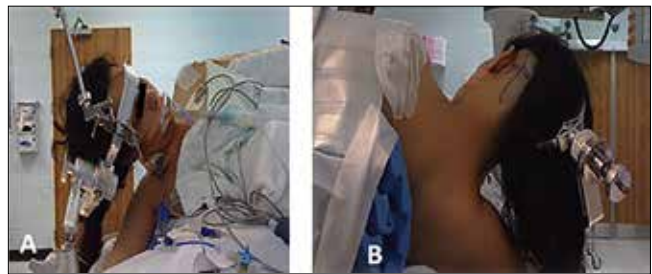


Fig. 3.8.1. A), B): modified park bench position adopted by the author.

provides a clear surgical field because of better venous drainage. It is also more comfortable for the surgeon.

Exposure

The exposure entails a combination of retrolabyrinthine-presigmoid, retrosigmoid and sub-temporal avenues. An inverted J-shape skin incision is fashioned from the zygomatic arch at the pre-tragal region curving up 2 cm above the pinna and descending posteriorly and inferiorly behind the mastoid process as in the presigmoid approach. The temporalis muscle fascia is incised and reflected inferiorly in continuity with the sternocleidomastoid muscle and fascia. The temporalis muscle is released and reflected inferiorly. Localization of the lateral and sigmoid sinuses are defined by using the aforementioned landmarks and supported by the use of the neuronavigation. The bony exposure includes three steps:

- *Step 1.* A temporal-suboccipital bone flap is elevated in one or two pieces using 2 burr holes spanned on both sides of the transverse sinus just lateral to the asterion with special attention not to injure the lateral sinus (or vein of Labbé).
- *Step 2.* A simple mastoidectomy is performed by elevating a triangular mastoid cortical flap which is extended from the supramastoid ridge to the mastoid tip using a pediatric oscillating saw or B1 Midas Rex cutter. This procedure is followed by drilling out the mastoid air cells and the antrum using a mm burr to expose the presigmoid dura (Trautman triangle) and skeletonize the sigmoid sinus down to the jugular bulb. The latter maneuver is crucial in allowing maximal mobilization of the sigmoid sinus after opening the tentorium.
- *Step 3.* The presigmoid dura and the temporal-basal dura are opened toward the superior petrosal sinus. While performing the latter steps, special attention must be taken to preserve the vein of Labbé. The superior petrosal sinus is then coagulated, double ligated and cut. The tentorium is now incised parallel to the petrous ridge dorsal to the tentorial incisura, where the entry of the IV nerve is seen.

Intervention

This approach provides a direct anterior and superior multi-channel access to large tumors of the CPA region, of Meckel's cave with supratentorial extension or of lesions deeply located in the petroclival region and of the anterior brainstem. It entails minimal cerebellar retraction and short working channels free of cranial nerves to work through, as they are posteriorly located. The steps of tumor resection follow the same aforementioned principles including: maintenance of the subarachnoid plane for dissection, mass devascularization, internal decompression, segmental resection using fine microsurgical techniques, cavitron ultrasonic surgical aspirator (CUSA), copious irrigation, minimal vascular compromise and special attention to venous drainage. The author has used the stimulation probe as a dissection tool during the final stage of tumor capsule removal. This tool is also of great value during resection of large epidermoid lesions growing along multiple cisterns and around intervening cranial nerves. In recent years, we decided not to treat residual tumors invading the posterior cavernous sinus as treatment of these lesions is associated with a relatively high incidence of ocular paresis. In these cases we follow the "wait and see" principle and advise for adjuvant therapy if any sign of progression is reported (Fig 3.8.2).

Closure

Primary closure of the temporal dura is usually feasible

but may be challenging at the presigmoid level. When primary closure was not achievable, we have successfully used a small patch of autologous tissue taken from the temporal muscle fascia or, alternatively, artificial dura. Dural repair is supported. This procedure can be performed with a fat graft or rotating a flap of the posterior third of the temporal muscle down to fill the bony defect in the mastoid and pack any potential patent air cells. The mastoid cortical flap is fixed to the craniotomy flap using low profile mini titanium plates. The intervention is completed with multilayer closure of the surgical site and a gentle compressive dressing.

Special considerations

All patients should have comprehensive preoperative MRI studies including magnetic resonance angiography and venography (MRA & MRV) to guide the selection of the best approach and anticipate potential pitfalls. Intraoperative neurophysiology monitoring is a vital part of these approaches in order to guarantee a safe surgical intervention, minimize potential complications and achieve better clinical outcomes.

Patients with large tumors and risk of associated hydrocephalus may be considered for simple preoperative CSF diversion procedure.

Dural sinus thrombosis and venous injury are of concern during these interventions. Meticulous review of the preop-

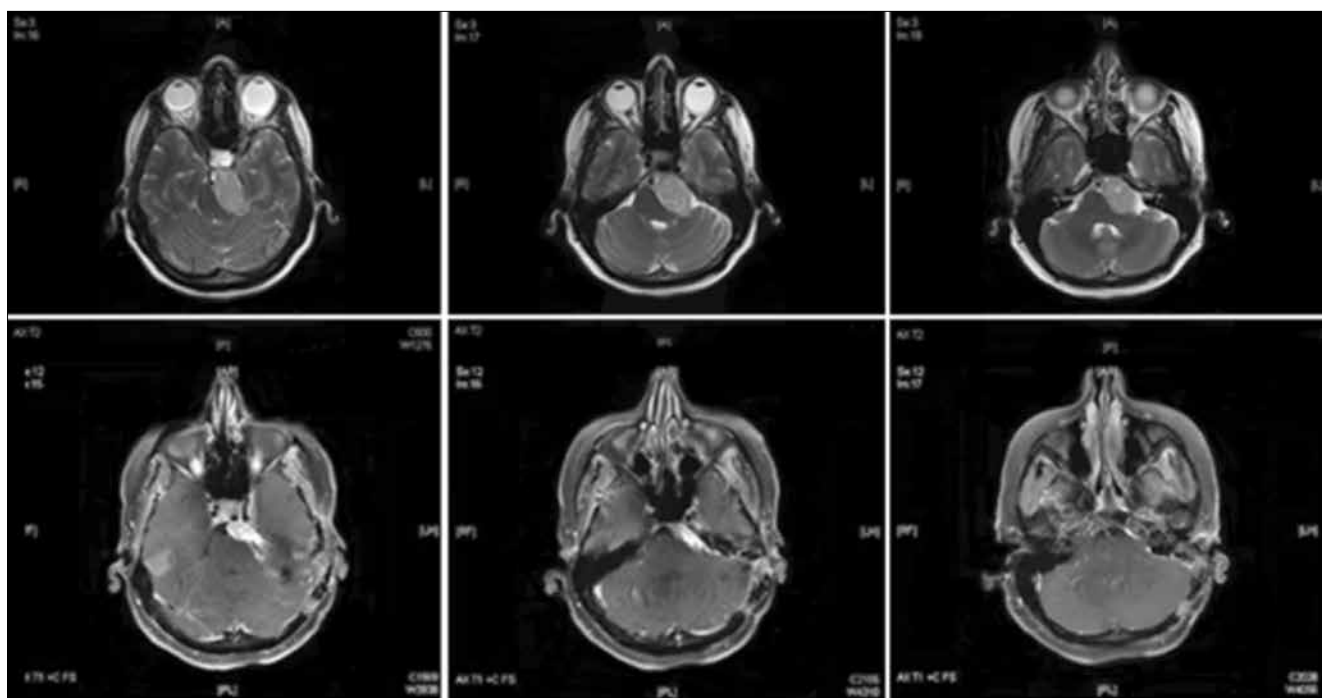


Fig. 3.8.2. Pre and post-operative MRI (T1 + Gadolinium) showing petroclival meningioma with superior extension and subtotal resection leaving small residual severely adherent to 3 and 6 cranial nerves. The surgical approach selected was the modified "Hakuba" presigmoid retrolabyrinthine combined approach.

erative MRI and MRV images is a prerequisite for selection of the proper approach and safest intervention. An attempt is made to protect the dural sinuses and their patency during their exposure. A constructive repair of iatrogenic tearing is mandatory, as should be avoidance of their compression or ablation. It is important to maintain the integrity of the vein of Labbé during the combined approach and to limit the number of sacrificed cerebellar bridging veins including the petrosal vein to prevent resultant hemorrhagic edema of the cerebellum and the brain stem.

Measures taken to prevent CSF leakage include: sealing of the exposed air cells of the mastoid using bone wax, muscle or fat graft; watertight closure of the dura, supported with biological or artificial dural graft and Tisseel tissue glue and meticulous soft tissue closure when needed. CSF conversion procedure may be unavoidable in some preexisting hydrocephalus cases, as a transient or long term measure.

Conclusions

The presigmoid retrolabyrinthine approach offers an anterolateral extension of the retrosigmoid approach with shorter working channels and lesser cerebellar retraction. This approach often entails significant bone drilling and increases operative time together with associated complications. The integration of this approach into the modified presigmoid combined petrosal approach (Fig. 3.8.2) provides wide panoramic exposure of large lesions in the CPA and petroclival region with transtentorial extension yet maintains the preexisting integrity of hearing and facial nerve function. We select this approach in patients with giant petroclival meningiomas and chordomas in order to achieve a more radical resection and a better long term outcome. Recently, the hybrid use of endoscopy coupled with an inferior incision of the tentorium and potential negotiation along the suprameatal route have fostered the solo use of the retrosigmoid approach for microsurgical management of such lesions and limited the need for complex skull base bony exposure (Fig. 3.8.3). The value of emerging adjuvant treatment in interventional neuroradiology, stereotactic radiation and medical oncology should not be underestimated but rather considered as new useful tools in the decision making process of complex comprehensive care management.

3.9. Occipital approaches, retrosigmoid approach

A. Mazzoni, D. d'Avella, E. Zanoletti

There are two basic approaches across the occipital squama, the posterior and the lateral occipital approach. The posterior occipital approach involves a posterior, median

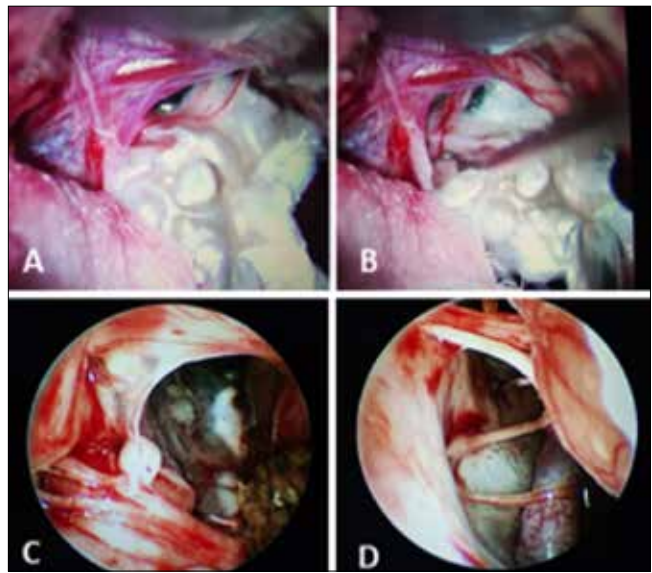


Fig. 3.8.3. A), B): intraoperative photograph of left CPA epidermoid; C), D): endoscopic view depicting residual deposits followed by complete removal.

craniotomy and a corridor which is retro-infracerebellar, or supracerebellar. The lateral occipital approach involves a craniotomy on the lateral aspect of the occipital bone and currently includes the suboccipital approach with a craniotomy close to the foramen magnum and the patient preferably in semisitting position (or else the supine position); and the retrosigmoid approach. The direction of the surgical corridor varies according to the entry window and the position of the head, that is supero-medial direction for the suboccipital and medial direction for the retrosigmoid approach.

The cerebellum retracts following the cerebrospinal fluid (CSF) drainage, it also can be displaced with an autostatic retractor or with the dissecting instruments.

The resection of the tumor occurs in a single or few pieces with the small tumor, it usually involves a succession of inner debulking and outer piecemeal removal. In acoustic neuroma, the sequential steps include the dissection on the cerebellum-tumor interface, inferior pole of the tumor, roots of the VII-VIII nerves, brainstem, the tumor superior pole, having the inner-outer piecemeal removal as the method and the VII-VIII nerves as the phulcrum of advancing the procedure, in much the same way as the translabyrinthine approach.

The internal auditory canal lies in a different plane than the cerebellopontine angle and requires a $> 30^\circ$ change of the direction of view, which is obtained by angling the microscope and/or changing the head orientation by rotating the table.

Meatotomies

Approaching the internal auditory canal meets some critical conditions:

1. the lumen of the canal is completely occupied by tumor and nerves with no room left for vision and instruments;
2. the cochlear nerve more than the facial is overvulnerable to surgical maneuvers such as pressure and stretching either direct or transmitted;
3. the bulge of the labyrinth is an obstacle to viewing the lateral half of the canal;
4. the fundus of the canal is occupied in half of the cases by tumor which is adherent to it in one quarter.

Solution of this problems involved two different techniques:

- Drilling of the petrous bone to remove the posterior wall of the canal limited to the proximal seven millimeters in order to preserve the labyrinth. Control of the lateral half of the canal is precarious especially on the fundus. An angled endoscope allows visual control and elementary maneuvers with dissectors and forceps.
- Maximal bone removal around the canal with the retrolabyrinthine meatotomy as follows.

Retrolabyrinthine meatotomy (RLM)

The RLM is performed as a part of the retrosigmoid approach and requires the lateral or prone position. The rationale of the RLM is twofold, the control of the full internal auditory canal and a wide, multiangled exposure for handling of tissues and instruments. This is obtained with two steps. First, the occipital craniotomy of the retrosigmoid approach is to be extended enough posteriorly to afford the oblique view bypassing the bulge of the labyrinth up to the fundus. Second, drilling the petrous bone up to the blue line of the labyrinth allows the maximal removal of bone around the canal with a multiangled view and room for instruments. The RLM essentially involves a three-dimensional microsurgical corridor from a postero-medial gate on the occipital squama running adjacent to the tentorium to the retrolabyrinthine petrous bone, and thereon following the labyrinthine landmarks to the roof of the canal like an interdural route between the middle cranial fossa and the internal auditory canal. It exposes the fundus at the orifices of the superior vestibular and facial nerves.

The RLM ¹ involves successive steps from the first landmark of the vestibular aqueduct to the last one of the dural transition to the Fallopius canal at the fundus. The entry of the aqueduct on the posterior side of the petrous bone marks the area to be drilled. The architecture of the bone is here illustrated by the axial bone window CT and itself leads to the ivory bone of the labyrinth. The blue line of the posterior canal leads to the superior canal which is

the landmark leading to the dura of the fundus roof where the facial nerve enters the Fallopius canal (Fig. 3.9.1). The orifice of the cochlear nerve is lying below the crista transversalis. The drilling of the remaining bone ring overhanging the fundus affords the control of the area of the Fallopius orifice and the vestibular orifice. This crucial step deserves a detailed description. The drilling is targeted to the portion of fundal roof overhanging like a ring the bony plate of fundus with its orifices. A probe is to assess the width of remaining bone to be drilled with a 2 mm diamond burr. Successive “probe and drill” steps will expose the area of the vestibular channel and the Fallopius orifice (Fig. 3.9.2).

The drilling is to be strictly limited to the roof as only there it does not risk to hit the labyrinth. The labyrinth does not overlap the fundus as it is separated from it by bone thick enough to accommodate a 2 mm burr. The bone becomes thinner while passing from roof to posterior wall. Note that the vestibular orifice is seen by a sideview and the Fallopius orifice with a more favorable view, and both orifices are masked by their nerves. The orifice of the vestibular nerve can be masked by the common crus and superior semicircular canal, but its exposure is exceptionally necessary as the distal portion of tumor is already under view and can be lifted off. The orifice can be exposed if the angle of view is increased by enlarging 5 mm medially the craniotomy on a small spot close to its superior limit.

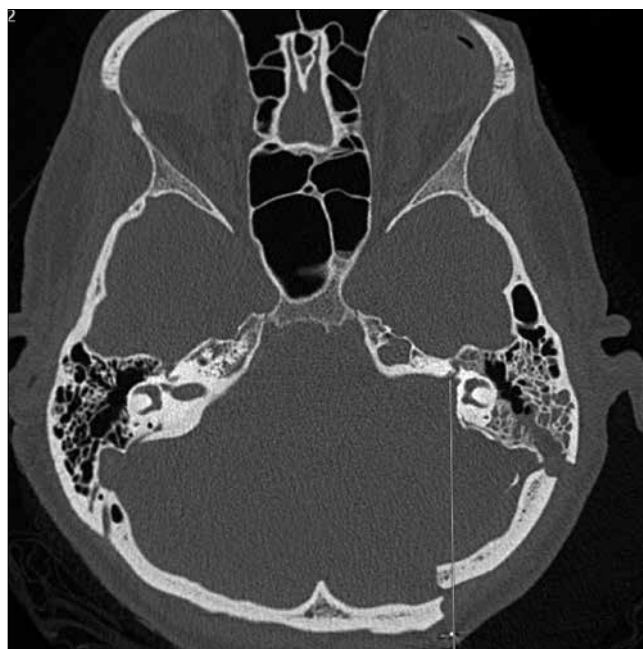


Fig. 3.9.1. Axial bone window CT scan, the surgical corridor from craniotomy to Fallopius in retrosigmoid RLM, left.

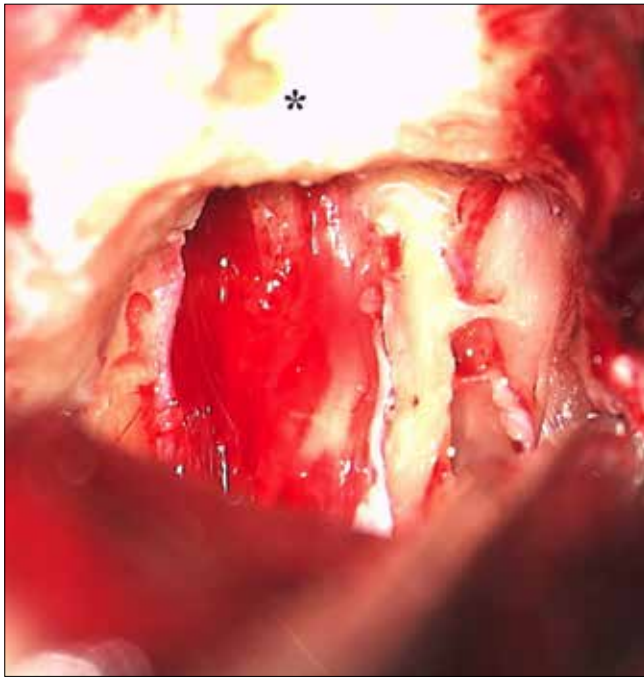


Fig. 3.9.2. Operative picture showing transverse crista (*), facial nerve running up to Fallopius on the right of crista, cochlear nerve on left up to cochlear quadrant.

The meatotomy is completed by removing the bone which extends from the labyrinth to the canal porus and all around the canal close to 180° of its section. At the end of tumor resection, the opened air cells are easily appreciated and sealed with bone wax.

3.10. The suprameatal approach and the transpetrous-transapex approach

M. Tatagiba, S. Lieber, F.H. Ebner

Introduction

The retrosigmoid approach provides straightforward access to the cerebellopontine angle (CPA) and to the petroclival region. The approach can be extended in different ways:

- inframeatally for tumors originating from within or growing into the jugular foramen;
- transmeatally for tumors involving the inner auditory canal;
- suprameatally for tumors located in the ventral posterior fossa or those extending from the CPA into the middle fossa.

In this chapter we provide a technical description of the retrosigmoid intradural suprameatal approach (RISA) with a focus on its practical aspects.

Historically, Samii introduced the RISA in 1983 and reported the surgical technique and outcomes for petroclival meningiomas¹. Seoane and Rhoton described the anatomical aspects of the approach².

Technical description

We position the patient for the RISA either supine with the head turned to the contralateral side or semisitting. This depends mainly on the characteristics of the addressed pathology: in case of large, well-vascularized tumors (e.g. petroclival meningiomas) we take advantage of the reduced intracranial pressure, the clean operative field and the optimized caudo-cranial perspective provided by the semisitting position. However, if the lesion is small (petrous apex meningioma) or avascular (epidermoid cyst) the supine position is usually sufficient to resect the pathology avoiding the drawbacks of the semisitting position. In our opinion intraoperative electrophysiological monitoring is mandatory. It routinely comprises bilateral somatosensory evoked potentials (SEP) and motor evoked potentials (MEP) of the extremities, auditory evoked potentials (AEP), free running EMG, motor evoked potentials of the facial nerve (FMEP), and direct facial nerve stimulation. Depending on the growth pattern of the tumor free running EMG, direct nerve stimulation and MEPs are extended to the lower cranial nerves, and/or cranial nerves III, IV and VI.

For both the semisitting and the supine position we rotate the patient's head only after obtaining/recording a SEP baseline. A decrease of the SEPs > 50% requires an immediate repositioning in order to avoid complications related to the head's rotation or flexion with compression of the spinal cord due to degenerative spinal changes or concomitant intraspinal tumors (as in neurofibromatosis type II).

Remarks for the semisitting position: gravity is the key concept of the semisitting patient position. It reduces the pressure inside the posterior fossa, continuously drains CSF, and allows for copious irrigation of the operative field, thus gravity greatly facilitates the microsurgical dissection of cleavage planes and neurovascular structures. The main concerns regarding the semisitting position are venous air embolism and paradoxical air embolism (in case of a patent foramen ovale) and their respective cardiopulmonary and neurological sequelae.

However, operating on large and vascularized tumors the advantages of the semisitting position optimize surgical results, reduce operating times, and outweigh their disadvantages. As a matter of course, an interdisciplinary and experienced team is mandatory to guarantee patient safety.

First of all, we do not position the patient sitting, but

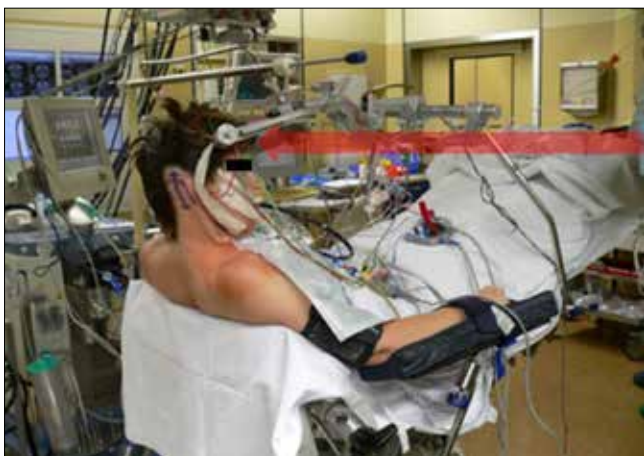

Fig. 3.10.1. See text.

semisitting. That means, that the legs are raised to the level of the head (Fig. 3.10.1). This elevates central venous pressure and thereby reduces the risk of air embolism.

The diagnostic preparation of the patients includes:

- *Thin-slice bone window CT scan.* Position and diameter of the emissary veins?
- *Clinical and radiological evaluation of the cervical spine.* Instability?
- *Transthoracic echocardiography.* Patent foramen ovale?

In the OR the anesthesiological monitoring comprises:

- *Transesophageal echocardiography.* Air bubbles?
- *Continuous measurement of end-tidal CO₂.* Entrance of air in the veins causing drop of CO₂?
- *Continuous arterial pressure monitoring.* Cardiovascular instability?

The Tübingen classification of venous air embolism is based on these criteria.

A slightly curvilinear incision is placed two fingers behind the ear, extending from the upper end of the ear lobe to the level of the mastoid tip. Bony exposure comprises the landmarks: the asterion, the mastoid tip and the horizontal part of the occipital squama. Depending on the age of patient we either perform a lateral suboccipital craniotomy (< 50 years) or a craniectomy (> 50 years). It is crucial to expose the lower border of the transverse sinus and the posterior border of the sigmoid sinus. This facilitates entering the posterior fossa tangentially to the posterior surface of the petrous bone and thereby minimizes cerebellar retraction.

We open the dura with a straight incision parallel to the sigmoid sinus with the option of extending it medially parallel to the transverse sinus to provide access also to the so-called supracerebellar route.

The first intradural step consists in opening the lateral

cerebellomedullary cistern to release cerebrospinal fluid (CSF). This maneuver relaxes the intracranial structures. Gentle elevation of the collapsed cerebellum in a cranio-medial direction exposes the CPA with the respective pathology. The cranio-medial elevation of the cerebellum avoids tension and possible rupture of the superior petrosal vein complex.

As a general concept, the neurovascular structures inside the CPA are displaced depending on the lesion's origin. This means, that the corridors between CN IX/X/XI and CN VII/VIII, between CN VII/VIII and CN V, and between CN V and the tentorium respectively can be widened, narrowed, or obliterated, and the CN displaced posteriorly, anteriorly, caudally or cranially. As skilled neurosurgeons trained in microsurgical techniques, it is feasible to cross these nerves using the respective corridors and follow the tumor from the posterior to the middle fossa. The expansile growth of the tumor itself might enlarge the working space. We progressively debulk the tumor to create space between the respective structures. This allows for dissection of the capsule from the neurovascular structures in the classical three-hand plus technique in semisitting position: the main surgeon dissects the arachnoid cleavage plane using tumor grasping and dissecting forceps, the assistant intermittently irrigates and gravity cleans the field.

Once the tumor in the posterior fossa has been removed there are four options to address the supratentorial tumor component depending of the patient's anatomy:

1. the tumor created a corridor sufficient in size to access the supratentorial compartment;
2. a prominent suprameatal tubercle hinders access to the ventrally located structures and thus has to be drilled;
3. the tentorium has to be incised parallelly to the superior petrosal sinus to gain access to the supratentorial space;
4. the techniques 2) and 3) have to be combined.

The suprameatal bone is located superiorly to the internal auditory canal (IAC) and exhibits significant individual variation³. Whenever its removal is necessary, we advise drilling with diamond burrs under continuous irrigation. A small piece of rubber may be placed on the CN VII/III for protection of the neurovascular complex during this maneuver. The extent of drilling is indeed an individual matter depending on the anatomical situation and the surgical access required⁴. Once the approach is accomplished, Meckel's cave is opened, the trigeminal nerve mobilized and the tumor further debulked. Stepwise resection of the tumor leads through the ambient and crural cisterns up to the middle fossa. Opening of the tentorium posteromedially to the entrance of CN IV into the posterior petroclinoidal fold further widens the access to the supratentorial compartment. In

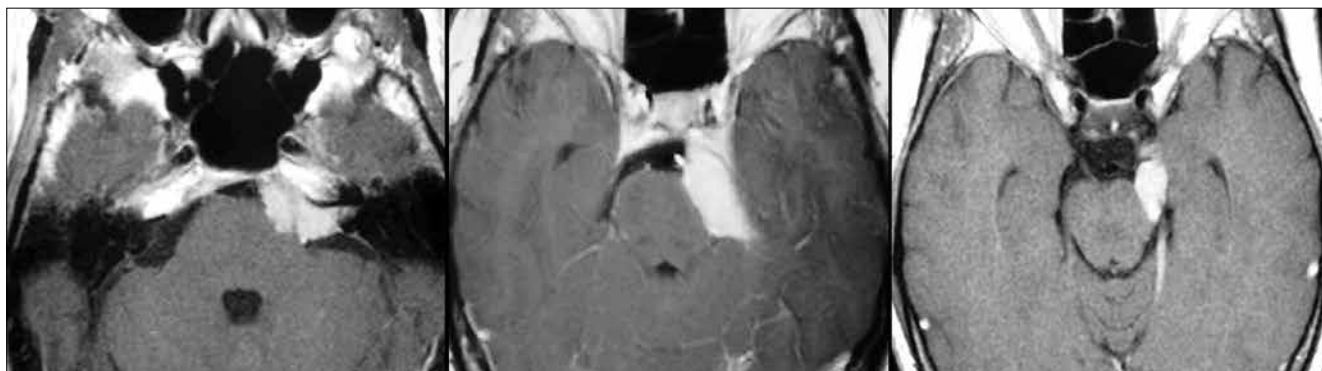


Fig. 3.10.2. See text.

cases lacking significant displacement of the brainstem and neurovascular structures, an endoscope-assisted technique facilitates access to and visualization of the middle fossa ⁵. In case of adequate tumor consistency (in terms of avascular and soft consistency), this technique allows for the removal of supratentorial tumor parts with angled instruments despite the overall limited access.

At the end of surgery two aspects are crucial:

- meticulous sealing of intradural – at the level of the drilled suprameatal tubercle – and extradural – at the level of the mastoid – potentially opened air cells with bone wax and a free muscle transplant with fibrin glue in order to avoid a postoperative rhinoliquorrhea;
- repeated jugular vein compression before closing the dura in case of the semisitting position to check for venous oozing and therefore avoid postoperative venous bleeding.

Optimal results can be achieved with this approach in demanding tumors like petroclival meningiomas ⁶.

Illustrative case

Figure 3.10.2 shows the axial T1wi MRI after contrast of a 45-year-old woman complaining about facial hypoesthesia on the left side. The meningioma involves the inner auditory canal, petroclival region and extends to the supratentorial compartment and posterior cavernous sinus. Histologically it was a meningotheliomatous meningioma WHO I.

Figure 3.10.3 provides the intraoperative microscopic view into the left cerebellopontine angle (A). The patient is in semisitting position. We performed retrosigmoid craniotomy on the left. The meningioma can be seen ventrally to the prominent suprameatal tubercle. (B) Drilling of the suprameatal tubercle with the high speed diamond burr. Microsurgical dissection and resection of the meningioma superiorly to the trigeminal nerve (C, D, E). Opening of the tentorium posteromedially to the entrance of the trochlear

nerve inside the posterior petroclinoidal fold (F, G). (H) Microscopic view to the supratentorial compartment after resection of the meningioma. (G) Postoperative overview from the posterior to the middle fossa.

The MRI with contrast two years after surgery documents the good removal of the tumor (Fig. 3.10.4). The patient

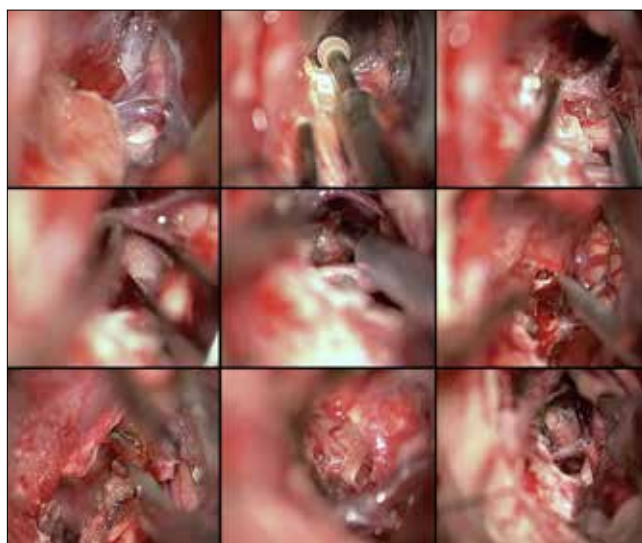


Fig. 3.10.3. A), B), C), D), E), F), G), H) from left to right.

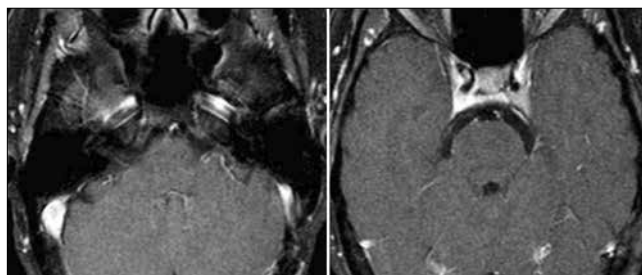


Fig. 3.10.4. See text.

has no neurological deficits. The remnant inside the cavernous sinus is stable. We recommend radiosurgery in case of documented tumor growth.

3.11. The extreme lateral approach: highlights on the key steps of surgical technique

R.V. Abbritti, P.-O. Champagne, S. Hanakita, E. Roca, S. Froelich

Introduction

Access to lesions located at the anterolateral aspect of the cranio-vertebral junction (CVJ) remains challenging because of their deep location and relationship with critical neurovascular structures¹. Lesions at these regions can be treated through anterior, posterior or lateral approaches. The anterior routes, such as trans-nasal or trans-oral, have been mainly used for extradural lesions of the anterior CVJ, since they bear a potentially higher risk of cerebrospinal fluid (CSF) leak and infection with opening of the dura. From the anterior corridor, the surgical view can also be limited laterally by the atlanto-occipital joint, internal carotid artery (ICA), hypoglossal canal, and lower cranial nerves². The posterior approaches, mostly based on a lateral sub-occipital trajectory, are generally selected for intradural lesions, particularly those located laterally and posteriorly to the foramen magnum and CVJ³. The conventional posterolateral access to these sites is the far-lateral approach, which provides a direction behind the sternocleidomastoid muscle (SCM) and medial to the vertebral artery (VA) and occipital condyle (OC)¹. The concept of an extreme lateral route was introduced and refined by several authors⁴⁻⁶ who reported a variety of definitions and variations, including other names such as the anterolateral. The aim of this chapter is to present the key steps of the extreme lateral approach (ELA), highlighting its indications and limitations.

Surgical landmarks

V3 segment of vertebral artery (VA)

The V3 segment of the VA begins at the transverse foramen of C2 and runs until the dura mater of the foramen magnum⁷. It is located at the centre of the sub-occipital triangle which is delineated medially by the rectus capitis posterior major, cranially and laterally by the superior oblique, and caudally and laterally by the inferior oblique⁸.

Occipital condyle

The occipital condyle forms, together with the jugular

tubercle, the most lateral bony wall of the foramen magnum and the inferior wall of the hypoglossal canal⁹.

Hypoglossal canal

The hypoglossal canal is divided into an intracranial and extracranial part. The intracranial part is located at the junction of posterior and middle third of the OC below the jugular tubercle; the extracranial part is above the junction of the anterior and middle third of the occipital condyle medially to the jugular foramen¹⁰.

C1 vertebra

C1 is a ring-shaped vertebra consisting of two arches and two thick lateral masses located at its anterolateral aspect. The posterior arch in its upper-outer surface presents the groove on which the V3 segment of VA lies. Between the lateral mass and the transverse process of C1 lies the transverse foramen inside of which the VA courses.

Key steps of the extreme lateral approach (ELA)

The ELA allows direct access to extradural bony lesions anteriorly to the lower brainstem and located into lower clivus, occipital condyle, C1 lateral mass, odontoid process, lateral mass and body of C2, and prevertebral space. It requires the control and mobilization of V3, control of the lower cranial nerves, jugular vein (IJV), and ICA^{4,7,8}. ELA can be confused with the far lateral approach (FLA). The main difference between ELA and FLA lies in the direction of the approaches. In the FLA, exposure is done medially at first, then extending toward a more lateral corridor, making the condyle resection and the VA transposition supplements of the approach. FLA is dedicated to intradural lesions located anteriorly or antero-laterally to the lower brainstem. In case of tumours, the drilling of the condyle is most often unnecessary, as the surgical corridor is created by the tumour volume itself. On the other hand, the ELA allows a more direct lateral corridor to the extradural anterior bony structures, being centred on the occipital condyle, C1 and C2 lateral masses.

Position and skin incision

The patient lies supine, the head is rotated as needed to the contralateral side with some degree of extension. Lateral or park bench positioning have also been described for this approach. Monitoring of the facial nerve and lower cranial nerves are systematically used. An incision is made along the anterior border of the SCM and over the mastoid process, and then turned posteriorly along the superior nuchal line (Fig. 3.11.1). The incision can be tailored depending if a retrosigmoid craniotomy or mastoid drilling are contemplated. Other types of skin incision such as a retroauricular curvilinear C-shaped skin

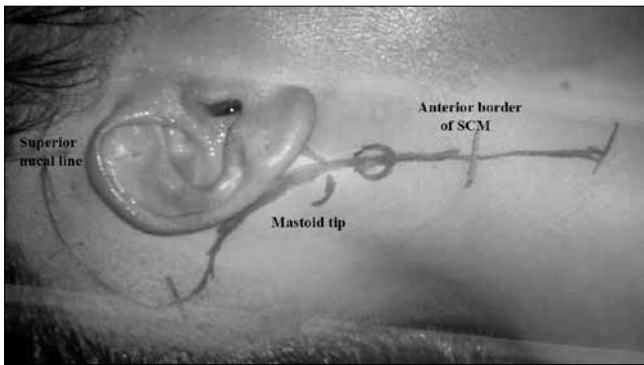


Fig. 3.11.1. Skin incision marked 6 cm below the mastoid tip, along the anterior border of the SCM, and curving superiorly toward the superior nuchal line.

incision, starting approximately 2 to 3 cm posteriorly to the upper border of the ear, can be also considered ^{11 12}.

Muscular dissection

The SCM is detached from the mastoid process and reflected infero-medially. The longissimus capitis is also detached from the nuchal line and mastoid process and reflected posteriorly. The digastric muscle is identified in the retromastoid groove and followed anteriorly. The tip of the transverse process of C1, which is a major landmark to locate the XI cranial nerve (c.n.) is palpated about 1 cm below the mastoid tip.

Control of the lower cranial nerves, IVJ and carotid artery

The IJV is then exposed inferiorly. The internal and external carotid artery (ICA, ECA), vagus and hypoglossal nerve with its descending branch are also identified.

Identification of the XI cranial nerve

The XI c.n. courses over the transverse process of C1 or, more often, immediately below it. It runs obliquely in a posterior and inferior direction toward the inferior surface of the SCM and is embedded into a fat pad located under the muscle. Once the XI c.n. is identified, the fat pad located above the nerve is dissected and elevated from the deep muscles and used to gently retract the XI inferiorly.

Exposure of the prevertebral space

The IJV, ICA, hypoglossal nerve and X c.n. are retracted all together medially and elevated in order to expose the prevertebral space and the lower aspect of the lesion. The sympathetic chain is identified along the anterior surface of the longus colli and is also retracted medially and elevated with the previously mentioned neurovascular structures. The connections between the sympathetic chain and the cervical nerve roots are sectioned. The longus colli is identified together with the anterior aspect of the anterior arch of C1, and the C2 and C3 vertebral bodies.

In order to access the exit zone of the jugular foramen, the

digastric muscle (DM) has to be detached from its groove and retracted inferiorly. The facial nerve lies anteriorly to the insertion of the DM; care must be taken to remain behind the anterior aponeurosis of the muscle.

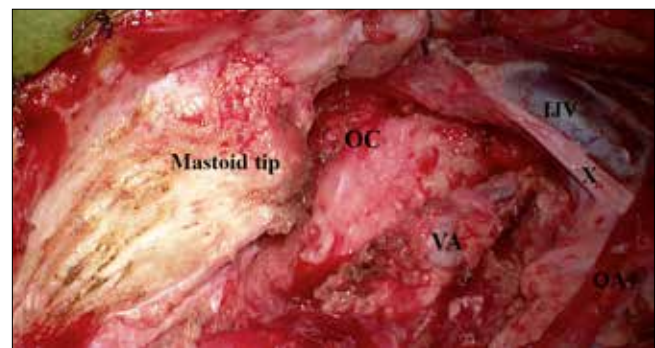
The occipital artery can be identified, running on the surface of the sub-occipital triangle. The latter structure can be dissected, released and mobilized inferiorly if needed for further revascularization procedures.

Exposure of the sub-occipital triangle

Deeply to the fat pad, the sub-occipital triangle is identified. The insertions of the muscles to the C1 transverse process, including the superior and inferior oblique, the levator scapulae and the cervicalis are progressively coagulated and cut to free the transverse process. Care must be taken not to open the venous plexuses around the VA. Once the muscles are detached, the posterior aspect of the transverse process and C1 lamina are subperiosteally exposed.

Exposure and transposition of the VA

One of the crucial steps in the ELA is the transposition of the VA. The VA is identified in the C1 groove. The proximal control of V3 between C2 and C1 is also achieved. This is mandatory to take into consideration because of the rotation of the head. The C2-C1 segment of the VA is identified immediately below and almost parallel to C1 lamina. Once the transverse foramen of C1 is identified, the tip of the transverse process and the transverse foramen of C1 are removed and opened with a Kerrison rongeur, respectively. The VA is then freed subperiosteally from the foramen and transposed posteriorly (Fig. 3.11.2). Particular care must be taken not to leave pieces of bone on the posterior margin of the foramen that could injure the VA during the transposition. Transposition of the VA exposes the atlanto-occipital joint and the lateral mass of C1, creating a wide corridor towards these structures and the odontoid process. Additionally, the exposure of the VA can be extended inferiorly toward the



OC: occipital condyle; OA: occipital artery; X: 10th cranial nerve; IJV: internal jugular vein

Fig. 3.11.2. VA transposition from its groove after unroofing and removal of the transverse process.

transverse process of C2. The C2 nerve root runs over the C2-C1 segment of the VA and is therefore identified. The transverse process of C2 can be removed and its transverse foramen opened, in order to expose and further mobilize the VA if needed.

Bony resection and ELA variants

The bony resection of the ELA usually involves drilling of the lateral structures of CVJ such as the occipital condyle and the lateral masses of C1 and C2, giving a direct lateral access to the odontoid process and body of C2, and contralateral condyle. The limit of the bony resection is the contralateral VA on the other side of it. Anterior access can be gained via further drilling of the occipital condyle and C1 lateral mass, keeping in mind that the hypoglossal nerve and canal lie at the junction of the middle and anterior third of the condyle at that point. Depending on the lesion's location, bony resection can be tailored. To access lesions infiltrating the inferior clivus, drilling of the mastoid process, identification of the fallopian canal, infralabyrinthine drilling and removal of the mastoid tip might be needed. The sub-occipital craniectomy is completed by exposing the sigmoid sinus and jugular bulb. Opening of the jugular foramen can also be added depending on the pathology and tumour extension (Fig. 3.11.3).

Although the ELA offers a great lateral window on the CVJ and on the upper cervical spine, with the advantage to tailor the bony resection to the targeted region, a higher risk of VA injury is reported ⁶, compared to the FLA. Conversely, the rate of lower cranial nerve injury, especially of the hypoglossal nerve, is slightly inferior due to the early exposure of the latter at the beginning of the procedure, compared to other posterolateral approaches. Another neurosurgical issue regarding the ELA is CVJ instability. Several authors recommend an occipito-cervical fixation after unilateral occipital condyle drilling of > 50% ¹³, while others reported that the stability can be preserved even after complete unilateral condyle resection ¹⁴, stressing on the importance of ligamentous elements. However,

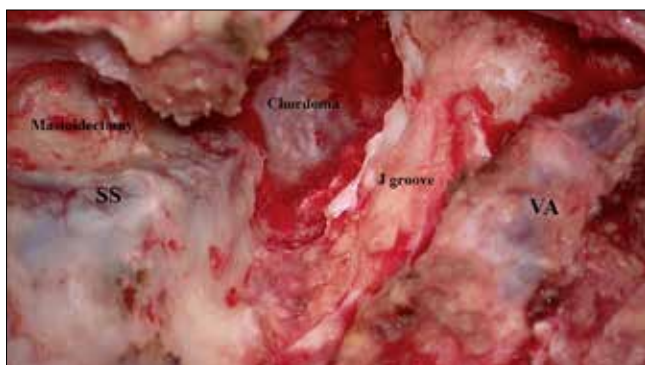


Fig. 3.11.3. Tumor exposure through the ELA approach: after completing the mastoidectomy, the sigmoid sinus (SS) is unroofed and exposed to allow the drilling of the occipital condyle.

fusion is mandatory when unilateral occipital condyle, C1 lateral mass or C0-C1 facets are removed entirely, and the contralateral bony complex is involved by the lesion. Cement can be used to transiently ensure a sufficient CVJ stability waiting for a posterior fixation.

In conclusion, the ELA provides an excellent surgical route to access extradural lesions located to the anterior brainstem, lower clivus, upper portion of the CVJ, the lateral complex of C0-C1 and C1-C2 vertebrae, and intradural-extradural lesions invading the more medial aspect of the aforementioned regions. The classical concept of a higher morbidity compared to the posterolateral approaches has actually changed due to both technical refinements, and tailored surgical steps related to the tumour extension.

3.12. En bloc resections of the temporal bone

A. Mazzoni, E. Zanoletti

There are two en-bloc resections of the temporal bone, the lateral block resection and the subtotal block resection; and the “piecemeal” resection.

The SCC of the external auditory canal arises from the skin of the canal and spreads to the temporal bone and the surrounding sites, mastoid, periauricular soft tissues, parotid gland and temporo-mandibular joint. The carotid canal, jugular foramen, dura, middle and posterior cranial fossae are invaded in advanced stages. Planning of surgery involves identifying the sites and subsites of tumor growth as well as the safe margins for resection. En-bloc lateral temporal bone resection (LTBR) and en-bloc subtotal temporal bone resection (STBR) combine the widest safe margins with a clear and reproducible approach. The “piecemeal” resection, as performed by the majority of authors, includes a block LTBR and a drilling out of the remaining petrous bone to follow the tumor diffusion.

In the LTBR ¹, the block of the outer ear canal is contoured with an extended mastoidectomy and freed through a temporal craniotomy. The same craniotomy enables the carotid artery to be exposed by drilling off its vertical canal and displacing it from canal down to the neck. The osteotomy from the carotid canal to the glenoid fossa makes it possible to free the tympanic block and preserve continuity with the soft tissues of the parotid and neck dissection.

The STBR ^{1,2} requires freeing the bone from dura, carotid artery and jugular foramen, and involves temporal and occipital craniotomies, the first one to free the carotid as mentioned under LTBR, and four osteotomies to deliver the block, as follows. One osteotomy from the carotid canal to the glenoid fossa (Figs. 3.12.1, 3.12.2) through the

temporal craniotomy. A second osteotomy on the antero-superior (Fig. 3.12.2) and the posterior (Fig. 3.12.3) side of the petrous bone with transection of the internal auditory canal. A third osteotomy (Fig. 3.12.3) through the occipital craniotomy from the previous cut on the petrous bone to the jugular foramen and preserving its medial wall with the low cranial nerves. A fourth and final osteotomy goes from the jugular fossa to the carotid canal (Fig. 3.12.4). The block remains continuous with the neck dissection and the parotid without violating the safe margins.

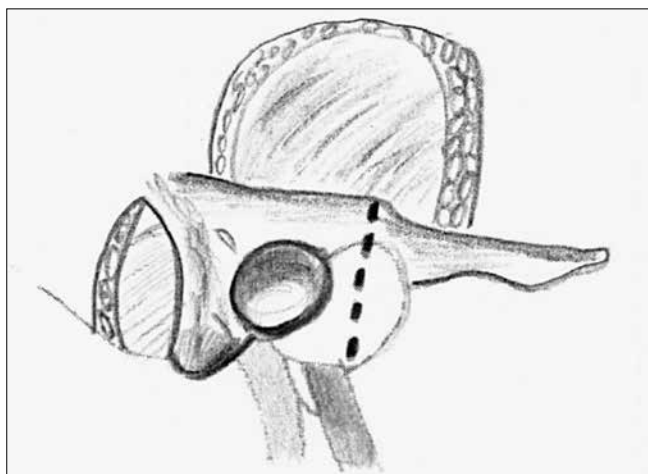


Fig. 3.12.1. The vertical carotid canal represents the axis of the en bloc subtotal temporal bone resection, as it carries both the start and the end of the bone cuts. Right temporal bone, lateral side. Temporal and retrosigmoid craniotomies allow to free the bone block from dura of the temporal and petrous sides, to close the sigmoid-jugular complex and to free the vertical carotid artery by drilling off its bone canal up to the neck.

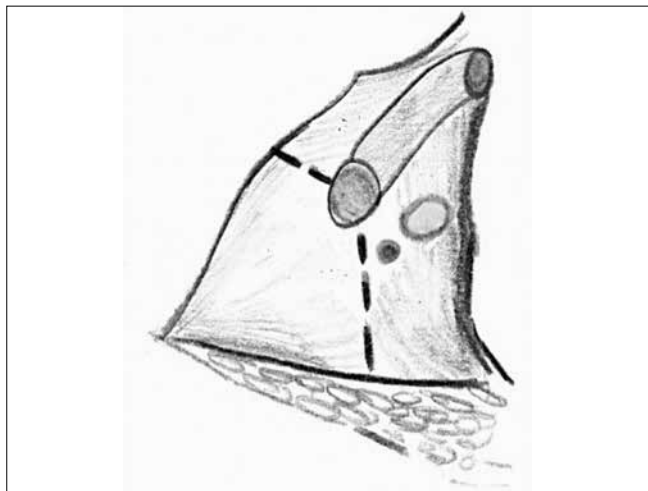


Fig. 3.12.2. First cut from vertical carotid canal to glenoid fossa (broken line) as seen from the temporal craniotomy. First part of the second cut (see at Fig. 3.12.3).

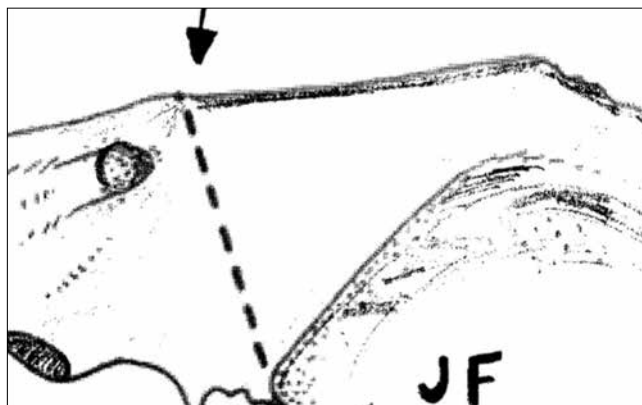


Fig. 3.12.3. Posterior side of petrous bone as seen from the retrosigmoid craniotomy. Second cut from carotid canal all across the anterosuperior (Fig. 3.12.2) and posterior side of the petrous bone, and cutting through the internal auditory canal. The cut from the petrous ridge (arrow) down to the jugular fossa (JF).

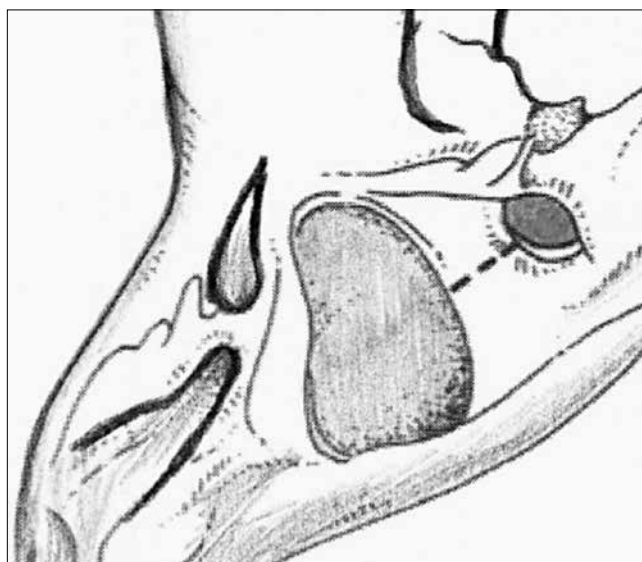


Fig. 3.12.4. Low side of the temporal bone. Final cut from the jugular fossa to vertical carotid canal.

Retrograde parotidectomy is indicated in both LTBR and STBR, total parotidectomy in cases of anterior growth beyond the anterior wall of the external auditory canal, superficial parotidectomy as a prophylactic measure on the intraparotid nodes in tumors limited to the external auditory canal (T1, T2). The neck is treated in both LTBR and STBR with elective selective dissection for clinically negative neck, and a modified type III radical neck dissection in clinically positive lymphnodes. Condyle of mandible, temporo-mandibular joint, and dura are resected if indicated. With tumor confined to the lateral canal with no bone erosion, the LTBR lies lateral to the ear drum. General principles regulate handling of the facial

nerve, which is to be included in the resection when clinical data or imaging indicate involvement by tumor, or when the safe resection margin includes the Fallopius.

Our experience can be conveyed with few points. The surgical failures were only due to local recurrence. The amount of bone involvement by tumor correlated with local recurrence. For example, T1-2 tumors which present little growth in the tympanic bone had a fairly good prognosis. Larger tumors had a different outcome depending on the amount of bone involvement. T 3-4 tumor growing full thickness on the anterior wall of the tympanic bone and thereon into the parotid demonstrated a significant less dismal prognosis than a similar sized tumor growing in the larger bone bed of the mastoid. The incontrollable diffusion seemed to take the numerous channels of the bone. Radiotherapy at full dosage follows surgery in T3-T4 tumors.

Recurrence after en-bloc resection most often occurred in the soft tissues corresponding to the low aspect of the temporal bone, thus suggesting that the bony channels, which become larger and numerous towards the low side of the bone, were the way of diffusion of the tumor to the periosteum and soft tissues³.

In our experience, enlarging the block resection to include jugular foramen, carotid artery and their adjacent soft tissues on the exocranial base were to imply such a burden of acute losses that it did not support its hypothetical benefit.

3.13. Totally endoscopic and combined endo-microscopic approaches in lateral skull base surgery

D. Marchioni, M. Bonali, D. Soloperto, F. Maccarrone, G. Ferri, L. Presutti

The lateral skull base and the internal auditory canal (IAC) can be considered as one of the most inaccessible spaces to visualize and to operate in otoneurosurgery. Limited access to these regions has prompted investigators to innovate methods for the creation of an adequate surgical corridor while limiting the damage and sacrifice of surrounding structures.

As for any surgical procedure, an adequate window of visualization is the key to provide operative success. Microscopic surgical approaches have been developed to remove pathologies located in the IAC and cerebellopontine angle (CPA) (retrosigmoid, translabyrinthine and middle cranial fossa approaches).

However, these techniques require brain, meningeal and vascular manipulation to obtain an adequate surgical corridor, increasing the possibility of complications.

This associated morbidity has led the surgeons to try to use the endoscope during lateral skull base accesses. Endoscopic surgery to the skull base may obviate many of the drawbacks

of the open approaches. The deep and complex nature of CPA anatomy makes this region an attractive candidate for endoscope-assisted surgery and, in selected cases, for exclusive endoscopic surgery.

Thanks to endoscopic visualization of anatomical structures lying in the tympanic cavity, anatomical knowledge is steadily improving, pushing surgical indications from the middle to the inner ear and to the lateral skull base, using the external auditory canal (EAC) as a natural corridor to reach lesions.

Regarding endoscopic techniques for inner ear surgery, and in particular for acoustic neuroma removal, there has been the development of transcanal transpromontorial approaches, and, in particular, the exclusive endoscopic transcanal transpromontorial approach (EndoTTA) and the expanded endo/microscopic transcanal transpromontorial approach (ExpTTA).

Other transpromontorial approaches to the lateral skull base are represented by the infracochlear route and the suprageniculate route.

Transcanal approaches are illustrated specifically as follows:

Transcanal transpromontorial corridor (Fig. 3.13.1)

Following this corridor, the fundus of the IAC is reached by passing through the promontory for diseases located in the vestibule, cochlea, and/or IAC. With this surgical approach, hearing loss is expected, because of the extirpation of the promontory area to create a corridor through the cochlea to finally reach the IAC.

The indications for this approach are:

- tympanic cavity cholesteatoma with medial extension toward inner ear structures (cochlea, vestibule, IAC);
- small symptomatic or growing acoustic neuromas with exclusive extension to IAC fundus;

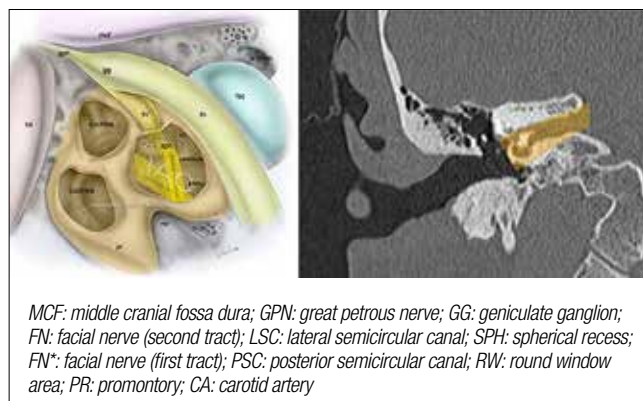


Fig. 3.13.1. Left side: schematic drawing showing anatomical details of the transcanal endoscopic transpromontorial approach of the left ear. The orange area indicates the bony area which may be removed to reach the internal auditory canal (IAC) passing through the cochlea and the vestibule. Right side: computed tomography scan (coronal view), showing the working area and the bony removal (yellow area), to reach the fundus of the IAC.

- cochlear schwannomas with or without IAC involvement. The surgical steps are the following: first, a wide canalplasty is created, the incus and the malleus then are removed, before the section of the tensor tendon. Using a hook, the stapes is removed to expose the vestibule. An inferior enlargement of the oval window opening is performed with a micro-curette. This procedure leads to the complete exposition of the spherical recess in the saccular fossa. This area appears like a thin cribriform plate and is the site of medial termination of the inferior vestibular nerve. It is also the anatomical barrier between the vestibule and the fundus of the IAC representing a crucial anatomical landmark for the fundus of the IAC.

The cochlea is then endoscopically identified removing the promontory. The tegmen of the round window is removed and the basal, middle, and apical turns of the cochlea are exposed by drilling over the promontory region.

After identification of the anatomical landmarks, as the tympanic segment of facial nerve together with the geniculate ganglion and the cochlea, the position of the labyrinthine tract of the VII cranial nerve can be identified through an imaginary line that arises from the geniculate ganglion, passing just above the apical turn of the cochlea and entering into the fundus of the IAC in the same plane of the spherical recess. When the disease is located in the cochlea, a gentle dissection of the tumor is performed, trying to avoid CSF leakage. When the tumor is located in the IAC, the fundus of the IAC is carefully opened through the cochlea just below the vestibule and the spherical recess, thus exposing the lesion in the IAC. During this surgical maneuver, an outflow of cerebrospinal fluid occurs. By gently maneuvering the tumor mass, the facial nerve is detected endoscopically, and the tumor mass is dissected from the IAC and from the facial nerve, paying careful attention not to damage the nerve. Afterwards, a final inspection of the surgical cavity and the IAC is made to confirm complete removal of the mass. Closure of the IAC is performed with abdominal fat, packing the promontorial defect and closing the communication between the inner and middle ear. Fibrin glue is used to secure the sealing of the promontorial defect, and a cul-de-sac closure of the skin of the EAC is performed.

Transcanal infracochlear approach (Fig. 3.13.2)

This approach allows removal of diseases located in the petrous apex below the IAC with limited extent, preserving hearing function. The corridor to the inferior portion of the petrous apex is created by drilling the bone between the cochlea superiorly, the carotid artery anteriorly, and the jugular bulb inferiorly. The ossicular chain is preserved and the hearing function is left intact.

The inferior limit of the promontory with the anatomical structures forming the round window niche (the posterior pillar, the tegmen and the anterior pillar with the finiculus bone) is detected endoscopically. Furthermore, under the finiculus bone, a subcochlear canaliculi is identified when

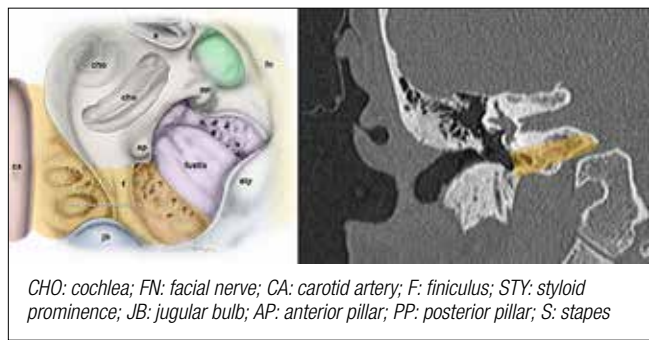


Fig. 3.13.2. **Left side:** schematic drawing showing anatomical details of the transcanal endoscopic infracochlear approach of the left ear. The orange area indicates the bony area which may be removed to reach the petrous apex under the cochlea. Main landmarks of this area are the cochlea superiorly, the carotid artery anteriorly, and the jugular bulb inferiorly. **Right side:** computed tomography scan (coronal view), showing the working area and the bony removal (yellow area) needed to reach the petrous apex cells.

present and well pneumatized, showing the route to reach the petrous apex cells. The jugular bulb is thus identified below the finiculus bone in the floor of the hypotympanum, and identification of the vertical tract of the carotid artery is performed by drilling the protympanic cells just below the Eustachian tube orifice. Drilling of the medial aspect of the tympanic cavity into the round window fossa, of the hypotympanic and protympanic cells between the jugular bulb, carotid artery and basal turn of the cochlea, is performed with a diamond burr. The removal of the aforementioned bony anatomical triangle allows to reach the disease in the petrous apex, which lays below the IAC and medial to the vertical portion of the internal carotid artery.

Transcanal supragenicolate corridor (Fig. 3.13.3)

This approach allows removal of diseases located between the geniculate ganglion and the second portion of the facial nerve inferiorly, the middle cranial fossa (MCF) superiorly, and the labyrinthine block posteriorly. Working above the cochlea and labyrinth allows sensorineural hearing function preservation, although an ossiculoplasty is required after disease removal.

This approach is indicated for diseases with limited extension into the supragenicolate area, like cholesteatomas or hemangiomas. This area can be endoscopically reached by a transcanal route avoiding a middle cranial fossa approach. After obtaining a good exposure of the medial wall of the tympanic cavity, removal of the incus and of the head of the malleus is required to expose the entire second portion of the facial nerve, which goes from the second genu to the geniculate ganglion and involves the greater petrosal nerve area. The cog and the cochleariform process are identified endoscopically and used as an anatomical landmark for the geniculate ganglion area because of the close anatomical relationship between the

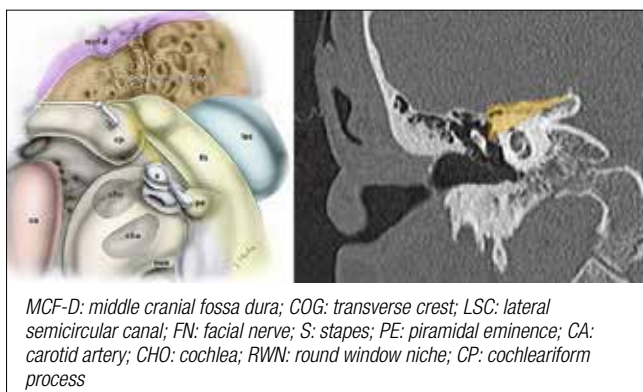


Fig. 3.13.3. **Left side:** schematic drawing showing anatomical details of the transcanal endoscopic suprageniculate approach of the left ear. The orange area indicates the bony area, which may be removed to reach the petrous apex in the suprageniculate region. Main landmarks of this area are the middle cranial fossa superiorly, the facial nerve and geniculate ganglion inferiorly and the labyrinthine block posteriorly. **Right side:** computed tomography scan (coronal view), showing the working area and the bony removal (yellow area) needed to reach the suprageniculate area.

geniculate ganglion and the mentioned structures. The dura of the MCF is exposed by removing bone from the tegmen of the anterior epitympanum, and represents the upper surgical limit. The lateral semicircular canal is also endoscopically detected in its posterior and superior aspects, with respect to the second genu of the facial nerve, representing the posterior limit of the surgical field. The cog is gently removed using a microcurette, increasing the exposure of the geniculate ganglion area, and, when required, the greater petrosal nerve is also exposed just anteriorly to the geniculate ganglion. Based on the extent of the disease, a diamond burr or a Piezoelectric device (Mectron, Carasco/Genova, Italy) is used to remove the bone between the MCF superiorly, the labyrinthine block posteriorly, and the facial nerve inferiorly, reaching the pathological tissue in this area. After disease removal, a fragment of temporal muscle is used to obliterate the cavity created, an ossicular chain reconstruction is performed, and the tympanomeatal flap is replaced.

Expanded transcanal transpromontorial approach

In 2013, the exclusive endoscopic transcanal transpromontorial technique has been introduced to treat Koos stage I and II vestibular schwannoma (VS) thanks to a higher magnification and a direct visualization of all the structures in the IAC and CPA. Recently, an expanded transcanal transpromontorial approach has been developed. This approach is a combined endoscopic and microscopic technique, used for the treatment of tumors that occupy the IAC involving the CPA (Koos stages II-III). This technique allows bimanual dissection with direct control of the tumor and neurovascular structures, as well as a reduction in surgery time.

Surgical procedure

The patient lies in the supine position, with the head slightly rotated contralaterally. A retro auricular incision similar to that of traditional microscopic techniques is made and the dissection of the soft tissues is performed to reach the EAC. A circular incision of the external auditory canal is performed about 1.5 cm from the tympanic annulus, and the distal part of the skin is removed with the tympanic membrane. Under microscopic view, the bone is drilled to gain better access to the tympanic cavity. Removal of the incus and the malleus is then performed. The tympanic tract of the facial nerve, the geniculate ganglion, and the cochleariform process are exposed. The following landmarks are clearly detectable at the end of this step: the carotid artery anteriorly below the tympanic tube orifice, the jugular bulb inferiorly, and the third tract of the facial nerve posteriorly.

The vestibule and the spherical recess are identified in the saccular fossa after removal of the stapes. The oval window is enlarged and the promontorial bone is removed with a progressive exposure of the basal, medial, and apical turns of the cochlea, preserving the modiolar structure of the cochlea and the cochlear nerve. The IAC is exposed by drilling the bone between the vestibule and the basal turn of the cochlea while maintaining the integrity of the middle and apical turns. The IAC is skeletonized as far as the porus by removing the bone circumferentially and exposing the dura of the IAC posteriorly and inferiorly. The dura along the IAC is then opened to reach the tumor, which is removed in a piecemeal fashion with traditional microscissors. The endoscope is used during this step as a complementary instrument for better identification of surgical landmarks and to safely dissect the facial nerve from the VS. The CPA portion of the tumor is visualized and removed after enlarging of the approach at the level of the fundus of the IAC with a burr following the acoustic-facial bundle toward their entry zone.

The microscopic view of the CPA is limited; consequently, complete removal of the tumor is performed and checked with the endoscope (Fig. 3.13.4). Facial function is evaluated

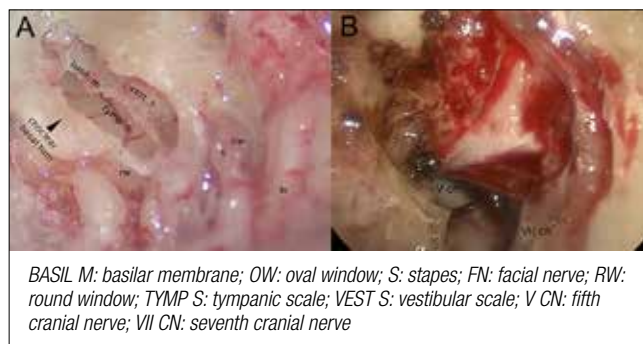


Fig. 3.13.4. **Left ear:** **A)** microscopic view during ExPTTA approach, showing drilling of the cochlear turns; **B)** endoscopic view after tumor removal, with final check of the anatomical structures.

with the intraoperative monitoring system. The defect in the inner and middle ear is closed using abdominal fat and fibrin glue. The Eustachian tube is closed with muscle fragments and bone dust. A blind sac closure of the residual skin of the external auditory canal concludes the surgery.

In our opinion the transcanal endoscopic approaches to the lateral skull base have proven to be successful for removal of lesions involving the fundus, IAC, cochlea, petrous apex, and geniculate ganglion region, providing a low risk of complications and allowing a good quality of life for the patients. With the development of future technologies, and the progressive improvement in surgical skills, this endoscopic corridor will likely represent one of the main approaches to treat lateral skull base diseases, together with the traditional techniques.

4. Advancements and open issues

4.1. Acoustic neuroma

4.1.1. Observation in vestibular schwannomas - a systematic review

M. Reznitsky, P. Cayé-Thomasen

Introduction

Evidence-based management of vestibular schwannomas (VS) depends on knowledge of the natural history of the disease. VS is a benign tumour of the VIII cranial nerve and comprises 90% of cerebellopontine angle (CPA) tumours and 8% of all intracranial tumours¹. The incidence is increasing and ranges from 11 to 19 VS/million/year and a number of studies report that the tumours are being diagnosed earlier, i.e. the tumour size is decreasing^{2,3}. Tumour growth percentages vary from 30 to 90%, partly due to varying lengths of observation⁴. Available treatment modalities are observation, radiotherapy or microsurgery, and although other factors may be present, the choice of treatment is most often based on the size of the tumour, on occurring tumour growth, and/or the hearing level of the patient.

Surgery is usually the first choice in patients with a large VS, as a large intracranial tumour may be associated with serious – at times life threatening – complications. Success of treatment is usually considered as control of tumour growth and preservation of a serviceable hearing level in patients presenting with a hearing worthy of preservation, with no or minimal treatment side effects. The definition of hearing worthy of preservation is debatable. Some authors

advocate that as long as the speech discrimination (SD) score is better than 50%, hearing is considered serviceable. This is because hearing aids can be used with some benefit. However, most authors use the AAO-HNS class A hearing (PTA < 30 dB and SD > 70%) as definition of good hearing and class A-B (PTA < 50 dB and SD > 50%)⁵ as definition of serviceable hearing, thus worthy of preservation. The AAO-HNS classification system is used in this review, as it is the most widely reported in literature.

The surgical approach or the radio-therapeutic strategy may include hearing preservation as a goal. In addition, preserved hearing may itself be an indication to perform surgery, even in smaller or non-growing tumours or in case the only hearing ear is on the tumour side⁶. However, in order to justify an active treatment based on hearing acuity, the outcome of the strategy should be superior to that of the natural course of the disease, as hearing is one of the most important aspects for the patient, as compared to dizziness, tinnitus or facial weakness⁷. The treatment strategy for VS has gradually changed during recent decades, as several studies (including larger series of patients), report a significant proportion of VS that remained stable in size after diagnosis, which justifies the increasing numbers of diagnosed and subsequently observed-only patients with VS^{3,4,8-10}. Importantly, hearing at diagnosis is reported as increasingly better, with an increasing number of patients presenting with close-to-normal hearing at diagnosis¹¹.

Only a detailed knowledge of the spontaneous course of VS will allow a comparison with, and a proper evaluation of, the outcome of any active treatment. Accordingly, this systematic review addresses the natural history of tumour growth and hearing through repeated MRI scans and audiometries in patients observed with a unilateral, sporadic VS.

Materials and methods

A research on PubMed, Embase, Medline, Cochrane library and CINAHL using the keywords “vestibular schwannoma”, “acoustic neuroma”, “growth”, “hearing”, “natural history”, alone and in combination was performed. The research yielded 121 papers with no early date limit and included publications up to September 2018. All papers were read and their references minutely checked for additional papers not occurring in the original search, yielding 103 additional papers. From their references further 21 papers were added.

Pubmed search syntax

((“neuroma, acoustic”[MeSH Terms] OR (“neuroma”[All Fields] AND “acoustic”[All Fields]) OR “acoustic neuroma”[All Fields] OR (“vestibular”[All Fields] AND “schwannoma”[All Fields]) OR “vestibular schwannoma”[All Fields]) OR (“neuroma, acoustic”[MeSH Terms] OR (“neuroma”[All Fields] AND “acoustic”[All Fields]) OR “acoustic neuroma”[All Fields] OR

((“acoustic”[All Fields] AND “neuroma”[All Fields])) AND ((“growth and development”[Subheading] OR (“growth”[All Fields] AND “development”[All Fields]) OR “growth and development”[All Fields] OR “growth”[All Fields] OR “growth”[MeSH Terms]) OR (“hearing”[MeSH Terms] OR “hearing”[All Fields])) AND (“natural history”[MeSH Terms] OR (“natural”[All Fields] AND “history”[All Fields]) OR “natural history”[All Fields]) AND (hasabstract[text] AND (“0001/01/01”[PDAT] : “2018/09/30”[PDAT]))).

Paper inclusion criteria

The 245 identified papers were screened using the following criteria:

- Clinical articles reporting original data. Reviews, meta-analyses and conference abstracts were thus excluded.
- Observational studies based on case series/cohorts and repeated MRIs and/or audiometries.
- Sporadic/unilateral vestibular schwannomas, excluding NF2-associated tumours.
- More than 30 patients included.
- Reported mean/median follow-up.
- Reported definition of tumour growth (directly or indirectly).
- Use of MRI only or predominantly (excluding studies based on CT).
- Use of AAO-HNS guidelines for classification of hearing⁵ and reported class A and/or class A-B hearing.

175 papers did not fulfill one or more of these inclusion criteria and were therefore discarded. This selection left 64 papers for inclusion concerning natural history of tumour growth and 18 papers (of which 12 also included tumour growth) for inclusion regarding hearing. Two of the papers regarding hearing were discarded, as they included patients from previously published papers. An overview of included papers regarding tumour growth and hearing are listed by number of included patients and presented in Tables 4.1.1.I, 4.1.1.II, respectively. The quality of all studies was evaluated using the Grading of Recommendations Assessment, Development and Evaluation (GRADE) system¹².

Results

Data on the natural history of VS growth was collected from almost 7,800 patients, as reported in 64 papers (Table 4.1.1.I). Data on hearing in patients with VS was collected from more than 2,200 patients, reported in 18 papers (Table 4.1.1.II). Regarding growth, weighted calculation based on the number of included patients in each paper shows a mean follow-up of 3.4 years, ranging from 0.5 to 10 years. Only 6 papers, representing 539 patients, have ≥ 5 -years follow-up (5.0, 5.5, 5.7, 6.7, 9.5 and 10 years, respectively)¹³⁻¹⁸. Weighted calculation on the occurrence of growth show that 36.7% of tumours grow within a mean observation period of 3.4 years (Table 4.1.1.I).

For what concerns data on hearing, weighted calculation showed a mean follow-up of 4.9 years, ranging from 2.6 to 9.5 years. Only three papers, representing a total of 390 patients, have a follow-up that exceeds 5 years (6.8, 8.3 and 9.5 years)^{17 19 20}. Weighted calculation of hearing preservation showed that 50.3% of patients presenting with good hearing at diagnosis will preserve this within 4.9 years of observation, whereas 55.1% of patients with serviceable hearing at diagnosis preserve this within the same period of observation (Table 4.1.1.II).

All papers are subject to some degree of selection bias concerning tumour size, as most larger tumours were excluded (typically operated). All but six papers^{4 11 17 21-23} involved potential referral bias (patients may not be representative for the general VS population) and the majority of studies have patient selection bias related to age and co-morbidities. A number of studies have an additional selection bias related to symptoms (usually vertigo/dizziness and hearing loss).

Some of the reporting centres have published more than one paper on their patient cohort/series, mostly as updates on the same patients, or with addition of new patients. Thus, an unspecified number of patients have been included more than once in Table 4.1.1.I.

In Table 4.1.1.II, nearly half the patients are presented in the 2010 paper by Stangerup et al.¹¹. Some of these patients are also included in the 2008 paper by Stangerup et al.²³ and this paper was therefore disregarded in the analysis. The 2007 paper by Cayé-Thomasen et al.²² is likewise excluded from the analysis, as the patients in this paper are part of the prospective cohort included in the most recent publication from 2017 by Kirchmann et al.¹⁷.

Most studies do not distinguish between purely intrameatal (IM) tumours and tumours with an extrameatal (EM) extension, whereas some do (often influencing the definition of growth). In addition, most studies define a small- to medium-sized tumour to have a largest EM diameter of less than 20 mm (not including the IM part of the tumour). Definition of growth is specified directly or indirectly in all papers, according to the paper inclusion criteria of the review. The definition varies, which introduces additional bias, either under- or overestimating the occurrence of growth. Most of the early studies are not considering error of measurements, as they use > 0 mm tumour enlargement as a growth definition. Knowledge regarding the error of measurement was later introduced to the research community and the literature, so that more recent studies have used > 1 mm, > 2 mm or even > 3 mm enlargement as a growth definition. Linear measurement of the largest EM tumour diameter has been used by most authors, although some have used linear measurement of the total tumour diameter, including the portion within the internal acoustic canal (IAC). Yet others have used volume rendering or Bayesian methods for the evaluation of growth. The partial use of CT in some of the

Table 4.1.1.I. Selected papers on natural history.

Author	Year	Study design	Patients (number)	Mean follow-up (years)	Growth (%)	Growth definition	Grade quality of evidence	Grade strength of recommendation
Hunter ³⁴	2016	Retro cohort	564	1.9	41%	≥ 2 mm	Moderate	Strong
Stangerup ⁴	2006	Pro cohort	552 322 EM 230 IM	3.6	29 17	> 2 mm Growth to CPA	Moderate	Strong
Moffat ³⁵	2012	Pro cohort	381	4.2	33	> 2 mm	Moderate	Strong
Lees ³⁶	2018	Retro cohort	361 129 EM 232 IM	4.1	48	≥ 2 mm	Moderate	Strong
Bakkouri ³⁷	2009	Retro cohort	325	1.0	12	≥ 3 mm	Low	Weak
Martin ³⁸	2009	Pro cohort	276	3.6	22	> 2 mm	Moderate	Strong
Artz ³⁹	2009	Pro cohort	243	2.3	58	≥ 1 mm	Moderate	Strong
Suryanarayanan ⁴⁰	2010	Pro cohort	240	3.6	32	≥ 1 mm	Low	Weak
Al Sanosi ⁴¹	2006	Retro cohort	197	3.4	28	> 0 mm	Very low	Weak
Caye-Thomasen ²¹	2006	Pro cohort	196 IM	4.4	19	Growth to CPA	Moderate	Strong
Breivik ¹⁰	2012	Pro cohort	186	3.6	40	> 2 mm	Moderate	Strong
Agrawal ⁴²	2010	Retro cohort	180	2.7	37	≥ 1 mm/year	Low	Weak
Varughese ⁴³	2012	Pro cohort	178 (88% IM)	3.6	29	≥ 1 mm/year	Moderate	Strong
Ferri ⁴⁴	2013	Cohort	161	0.5	36	≥ 2 mm	Very low	Weak
Kirchmann ¹⁷	2017	Pro cohort	156	9.5	37	≥ 2 mm	Moderate	Strong
Patnaik ¹³	2014	Retro cohort	154	5	45.5	≥ 1 mm	Very low	Weak
Ferri ⁴⁵	2008	Pro cohort	123	4.8	35	≥ 2 mm	Moderate	Strong
Quaranta ⁴⁶	2003	Retro cohort	122	3.5	40	> 2 mm	Low	Weak
Fucci ⁴⁷	1999	Retro cohort	119	2.5	30	> 2 mm	Very low	Weak
Roehm ⁴⁸	2007	Retro cohort	114 (> 65y)	3.0	50	> 0mm	Very low	Weak
Fayad ³³	2014	Retro cohort	114	4.8	38	≥ 2 mm	Very low	Weak
Battaglia ⁴⁹	2006	Retro cohort	111	3.2	50	> 0 mm	Very low	Weak
Grayeli ⁸	2005	Retro cohort	111	2.8	47	> 0 mm	Very low	Weak
Solares ⁹	2008	Retro cohort	110	2.6	21	> 2 mm	Very low	Weak
Hoistad ⁵⁰	2001	Retro cohort	102	2.4	44	> 1 mm	Very low	Weak
Kishore ⁵¹	2003	Retro cohort	100	3.2	29	> 1 mm	Very low	Weak
Flint ⁵²	2005	Retro cohort	100	2.2	36	> 0 mm	Very low	Weak
Remenyi ³²	2009	Retro cohort	95	3.7	23	> 2 mm	Low	Weak
Jethanamest ⁵³	2015	Retro cohort	94	2.9	38	≥ 1 mm	Very low	Weak
Whitehouse ⁵⁴	2010	Retro cohort	88	3.7	51	> 1 mm	Very low	Weak
Shin ⁵⁵	2000	Retro cohort	87	2.6	53	> 0 mm	Very low	Weak
Kandathil ⁵⁶	2016	Retro cohort	86	4.4	51	> 20% change	Very low	Weak
Moller ⁵⁷	2003	Pro cohort	82	3.0	43	> 0 mm	Low	Weak
Rosenberg ⁵⁸	2000	Retro cohort	80	4.4	58	> 0 mm	Very low	Weak
Nutik ⁵⁹	2001	Retro cohort	75	4.1	41	> 0 mm	Very low	Weak
Tschudi ⁶⁰	2000	Retro cohort	74	2.9	31	> 0 mm	Very low	Weak
Alvarez-Morujó ⁶¹	2014	Retro cohort	73	3.0	12	≥ 2 mm	Low	Weak
Hajjoff ¹⁸	2008	Pro cohort	72	10.0	35	> 1 mm	Low	Weak
Walsh ⁶²	2000	Retro cohort	72	3.2	36	> 0 mm	Low	Weak
Bederson ⁶³	1991	Retro cohort	70	2.2	53	> 0 mm	Low	Weak
Quaranta ⁶⁴	2007	Retro cohort	70	2.8	40	> 2 mm	Very low	Weak

Author	Year	Study design	Patients (number)	Mean follow-up (years)	Growth (%)	Growth definition	Grade quality of evidence	Grade strength of recommendation
Godefroy ⁶⁵	2009	Pro cohort	70	3.6	36	≥ 2 mm	Low	Weak
Deen ⁶⁶	1996	Retro cohort	68	3.4	29	> 0 mm	Low	Weak
Mirz ⁶⁷	2000	Pro cohort	64	3.6	23	> 1 mm/year	Low	Weak
Raut ¹⁶	2004	Pro cohort	61	6.7	50	> 1 mm/year	Low	Weak
Hughes ¹⁵	2011	Retro cohort	59	5.7	76	> 2 mm	Very low	Weak
Wiet ⁶⁸	1995	Retro cohort	53	2.2	40	> 0 mm	Very low	Weak
Strasnick ⁶⁹	1994	Retro cohort	50	2.3	68	> 0 mm	Very low	Weak
Herwadker ⁷⁰	2005	Pro cohort	50	1.5	42	> 3 x error, Bayesian	Low	Weak
Nedzelski ⁷¹	2008	Retro cohort	50	3.5	48	≥ 1 mm	Low	Weak
Pennings ⁷²	2011	Retro cohort	47 IM	3.6	38	Growth to CPA	Low	Weak
Régis ⁷³	2010	Pro cohort	47 IM	3.7	74	> 0 mm	Very low	Weak
Modugno ⁷⁴	1999	Retro cohort	47	3.0	36	> 0 mm	Very low	Weak
Reddy ³¹	2014	Retro cohort	45	3.0	24	> 2 mm	Low	Weak
Stipkovits ⁷⁵	2001	Cohort	44	3.5	18	> 0 mm	Very low	Weak
Tomita ⁷⁶	2015	Retro cohort	43	4.1	51	> 10% change	Very low	Weak
O'Reilly ⁷⁷	2000	Retro cohort	43	2.6	30	> 0 mm	Very low	Weak
Perry ⁷⁸	2001	Retro cohort	41 (> 65 y)	3.5	51	> 0 mm	Very low	Weak
Vokurka ⁷⁹	2002	Pro cohort	38	1.0	32	> 3 x error, Bayesian	Very low	Weak
Martin ¹⁴	1994	Retro cohort	37	5.5	30	> 2 mm/year	Very low	Weak
Van de Langenberg ⁸⁰	2011	Retro cohort	36	1.7	42	> 20% change	Very low	Weak
Glasscock ⁸¹	1997	Retro cohort	34	2.4	55	> 2 mm/year	Very low	Weak
Lee ⁸²	2014	Retro cohort	31 IM	2.6	23	≥ 2 mm	Very low	Weak
Sakamoto ⁸³	2001	Retro cohort	31	2.8	45	> 1 mm/year	Very low	Weak
All studies, n = 64	-	-	7783	3.4	36.7	-	-	-

early studies is also a source of potential bias, as CT is less accurate than MRI, when estimating tumour size.

Discussion

Very few studies on observation of VS growth and hearing have a long-term follow-up (i.e. beyond 5 years). Nearly 8,000 patients have been observed for tumour growth and data exist for more than 2000 patients concerning hearing outcome. In addition to the potential aforementioned biases, a few more could potentially influence the result of this systematic literature review.

The choice of a specific number of patients as an inclusion criteria in the selection of papers (see Material and Methods) is an obvious factor. A minimum of 30 patients had to be observed (only one paper failed to meet this criterion)²⁴. Excluding papers reporting on tumor growth without a clear definition of growth, or not reporting a mean/median time of follow-up, meant that some papers

including larger patient series were not accounted for. Especially, the otherwise excellent studies by Malhotra et al.²⁵ and Timmer et al.²⁶, which included 202 and 240 patients, respectively, had to be excluded, as they did not define growth or report follow-up period. Other studies were primarily excluded due to the lack of a growth definition. All together, the excluded papers included 614 observed patients, four cohorts being retrospective and three prospective²⁴⁻³⁰.

In regards to hearing, the choice of excluding publications not using the AAO-HNS classification of hearing⁵ and reporting class A and/or class A-B hearing was made, as the majority of published studies use the AAO-HNS classification system. This enables comparisons and overall conclusions to be made. However, studies using other classification systems (e.g. the Gardner-Robertson system) have indeed been published^{27,31}. It should be noted that an international consensus on the reporting of hearing

Table 4.1.1.II. Selected papers on hearing preservation.

Author (reference)	Year	Study design	Patients (number)	Mean follow-up (years)	Preservation of good hearing (%) > 70%ds < 30 db pta	Preservation serviceable hearing (%) > 50% ds < 50 db pta	Grade quality of evidence	Grade strength of recommendation
Stangerup ¹¹	2010	Pro cohort	932	4.7	51	56	Moderate	Strong
Stangerup ²³	2008	Pro cohort	548	3.9	52	55	Moderate	Disregarded
Breivik ¹⁰	2012	Pro cohort	186	3.6	Nr	63	Moderate	Strong
Kirchmann ¹⁷	2017	Pro cohort	156 IAC	9.5	17	34	Moderate	Strong
Caye-Thomasen ²²	2007	Pro cohort	156 IAC	4.6	47	47	Moderate	Disregarded
Tveiten ²⁰	2015	Retro cohort	148	8.3	62	67	Moderate	Strong
Breivik ⁸⁴	2013	Pro cohort	124	4.6	Nr	24	Moderate	Strong
Grayeli ⁸	2005	Retro cohort	105	2.8	52	57	Low	Weak
Lin ¹⁹	2005	Retro cohort	86	6.8	Nr	43	Low	Weak
Jethanamest ⁵³	2015	Retro cohort	75	2.9	Nr	76	Very low	Weak
Godefroy ⁶⁵	2009	Pro cohort	70	3.6	Nr	57	Moderate	Strong
Quaranta ⁶⁴	2007	Retro cohort	70	2.8	71	60	Low	Weak
Ferri ⁴⁵	2008	Pro cohort	56	3.6	Nr	73	Moderate	Strong
Roehm ⁴⁸	2007	Retro cohort of elderly > 65	48	3.0	33	38	Very low	Weak
Pennings ⁷²	2011	Retro cohort	47 IAC	3.6	65	74	Moderate	Strong
Fayad ³³	2014	Retro cohort	43	4.8	67	63	Very low	Weak
Régis ⁷³	2010	Pro cohort	40 IAC	3.3	69	68	Low	Weak
Lee ⁸²	2014	Retro cohort	31 IAC	2.6	45	Nr	Very low	Weak
All studies, n = 18	-	-	2217	4.9	50.3%	55.1%		

in patients with a VS does not exist and is accordingly warranted.

A few larger studies show that normal speech discrimination at diagnosis indicates that good hearing will be maintained for many years ^{11 22 23 32} and some studies show a faster decline of hearing acuity in patients with growing tumours ^{17 22 33}, while others do not.

Although most studies show that growth usually occurs

within a few years after diagnosis, long-term observational studies are needed to provide evidence on long-term growth occurrence and the spontaneous course of hearing.

When using the GRADE classification system of study quality, “moderate quality” is the highest level achievable for observational studies. In this systematic review, it is clear that the level of evidence according to this system differs between tumour growth (Table 4.1.1.I) and hearing preservation

(Table 4.1.1.II). The level of evidence is generally low when concerning tumour growth and moderate when concerning hearing. The strength of recommendation is weak for a number of studies, but fortunately relatively high in most of the studies with large cohorts. This generates a fairly strong overall recommendation concerning conclusions in regards to both tumour growth and hearing outcome, and ultimately to the overall validity of the present review.

Conclusions

This systematic literature review of the natural history of VS shows that on average, 37% of patients diagnosed with a small- or medium-sized unilateral/sporadic VS will exhibit tumour growth within 3.4 years of observation. 55% of patients will preserve serviceable hearing and 50% of patients presenting with good hearing at diagnosis will preserve this within 4.9 years of observation.

Based on these data, we believe that an active treatment of small- and medium-sized VS should await documented tumour growth, in order to avoid overtreatment and treatment side effects which could be worse than the spontaneous course of the disease itself. However, individual considerations or symptoms may justify active treatment without documented tumour growth, e.g. severe, variable dizziness/vertigo, or an aim to preserve hearing.

When considering active treatment to preserve hearing in patients with a small- or medium-sized VS it should always be recognized that good and/or serviceable hearing is preserved spontaneously in at least half of the patients within 4.9 years of observation, especially if the speech discrimination is normal at diagnosis. If active treatment is indeed chosen, the results should be published and compared to the present data.

4.1.2. Radiotherapy in acoustic neuroma

M. Krengli, L. Deantonio

Introduction

Neuromas or schwannomas are benign Schwann cell-derived tumours. When occurring in the vestibular portion of the eighth cranial nerve, they are called acoustic neuromas or vestibular schwannomas. This tumour is the most common of the cerebellopontine angle (90%) accounting for approximately 6% of all intracranial neoplasms. The incidence is approximately less than 1 per 100,000 persons/year¹. The natural history of acoustic neuroma is a slow growth with an unpredictable pattern, or no growth at all, and hearing decline, which takes place inexorably over the years in an unforeseeable manner and despite tumor growth. Recent studies on observation showed that intrameatal tumours may stop growing in more than 70% of the cases^{2,3}. During the last decades, the incidence of acoustic neuroma seems to be increasing. This is caused by

improvement of audiology tests, increasing access to magnetic resonance imaging (MRI) and significant longer and healthier lifetime of the population⁴. For these reasons, the tumour size at diagnosis has been decreasing and treatments such as surgery and radiotherapy have improved the chance of hearing and facial nerve function preservation².

The main management options for acoustic neuromas are observation, surgical resection, and radiation therapy. Each choice is a balance between the expected morbidity of the tumour and of the therapy. In medium-size tumours, where growth control is the main goal, surgical resection or radiotherapy give good results in terms of disease control and functional nerve preservation (V, VII, IX, X, XI, XII cranial nerves): surgery is generally recommended for younger and healthy patients while radiotherapy for all the other cases⁴. The aim of the present article is to review the most recent literature data of radiotherapy results in terms of local control and side effects and to discuss the role of radiation treatment and the optimal technical approach.

Material and methods

Literature search was performed by using the databases of Pubmed and Scopus. The key words “acoustic neuroma”, “vestibular schwannoma”, “radiosurgery”, and “fractionated stereotactic radiotherapy” were used for searching publications. We considered the articles published in the last 10 years. The relevance was assessed based on the numerosness of the sample size (at least 50 patients), the length of follow-up (median/mean 5 years), the completeness of analysis of technical data, and outcome results in terms of local control and side effects.

Results

In total, 574 articles were found. The initial review was based on the title and on the abstract. The articles inadequate regarding cohort size and follow-up, or duplicated cohort were discarded. Finally, 32 articles fulfilled all inclusion criteria.

Since the first radiation treatment conducted by Leksell in 1969, several clinical series were published reporting the use of radiotherapy for acoustic neuroma. No randomized trial was conducted. Few clinical retrospective series were found. Although the power of these clinical series did not allow to formulate strong evidence, we could find some evidence that can help physicians during treatment decision making on the following issues: radiotherapy technique, total dose and fractionation, tumour control and clinical outcome including toxicity, treatment at recurrence, and potential risk of malignant transformation.

The articles analysing large series with adequate follow-up are summarized in Tables 4.1.2.I, 4.1.2.II, 4.1.2.III.

The recent largest series of stereotactic radiosurgery reported quite detailed data in terms of local control, hearing preservation, and side effects. Boari et al.¹¹ reported a local

Table 4.1.2.I. Outcome using stereotactic radiosurgery.

Author	Level of evidence	N. pts	Technique	Median dose	Mean/median volume	Median/mean follow-up time	Local control	Hearing preservation	Toxicity		
									VII	V	Other
Berkowitz 2017 ⁵	III	353	GKRS	13 Gy	0.5 cc	63 months	99%	29.7% self-reported	Nr	Nr	12% vertigo
Akpinar 2016 ⁶	III	88	GKRS	12.5 Gy	0.72 cc	75 months	90%-95%	55%-88%	3.4%	Nr	Nr
Watanabe 2016 ⁷	III	183	GKRS	12 Gy	2 cc	114 months	96% 5 years	49% 5 years	3%	1%	Nr
Klijn 2016 ⁸	III	420	GKRS	11 Gy	1.4 cc	5.1 years	91.3% 5 years 84.8% 10 years	42% 5 years	4%	3.1%	Nr
Ellenbogen 2015 ⁹	III	50	SRS	12.5 Gy	2.4 cc	5.8 years	94%	50%	4%	4%	Nr
Mindermann 2014 ¹⁰	III	215	GKRS	12.9 Gy	1.85 cc	62.4 months	93%	Na	Na	Na	Na
Boari 2014 ¹¹	III	379	GKRS	13 Gy	1.3 cc	75.7 months	97.1%	49%	1.1%	1.8%	7.9% vertigo 4.7% tinnitus 5.3% hydrocephalus
Wangerid 2014 ¹²	III	128	GKRS	Mean 12.3 Gy	1.6 cc	104 months	92%	Nr	3%	2%	3% hydrocephalus
Hasegawa 2013 ¹³	III	440	GKRS	12.8 Gy	2.8 cc	12.5 years	93% 5 years 92% 10 years	43% 5 years 34% 8 years	2.2%	0.5%	0.2-0.7%
Lunsford 2013 ¹⁴	III	829	GKRS	13 Gy	2.5 cc	10 years	97% 10 years	50-77%	1%	3%	Nr
Kim 2013 ¹⁵	III	60	GKRS	Mean 12.2 Gy	0.34 cc	62 months	88% radiological 100% clinical	55% 5 years	Nr	Nr	Nr
Pollock 2013 ¹⁶	III	293	SRS	13Gy	Nr	60.9 months	94% 7 years	Nr	Nr	Nr	Nr
Yomo 2012 ¹⁷	III	154	GKRS	Mean 12.1 Gy	1.6 cc	60 months	94.8%	Nr	0	11.7	Maximum cochlear dose < 4 Gy was the sole prognostic factor for hearing preservation
Roos 2011 ¹⁸	III	84	SRS	12 Gy	Diameter 22 mm	65 months	97.6%	38%	Nr	Nr	Nr
Hsu 2010 ¹⁹	III	75	SRS	14 Gy median	1.5 cc	97.8 months	92% 10 years	94.7%	8%	Nr	9% complications
Fukuoka 2009 ²⁰	III	152	GKRS	12 Gy	2 cc	5 years	94% 5 years 92.4% 8 years	71%	0%	2%	2% dizziness 5.3% hydrocephalus

Nr: not reported; Pts: patients; GKRS: Gamma Knife radiosurgery; SRS: stereotactic radiosurgery.

Table 4.1.2.II. Outcome using fractionated stereotactic radiotherapy, hypofractionated and conventional fractionation.

Author	Level of evidence	N. pts	Technique	Median dose	Mean/median volume (cc)	Median/mean follow-up	Local control	Hearing preservation	Toxicity		
									VII	V	Other
Aoyama 2013 ²¹	III	200	Linac FSRT	50 Gy/2 Gy	Diameter 20 mm	72 months	79%	63.9%	9.5%	11.4%	Nr
Wolf 2013 ²²	III	93	Linac FSRT	52.5 Gy/25 fr	Diameter 19.6 mm	5.7 years	93% 5 years	93%	1%	1%	4% hydrocephalus
							92% 10 years				1% radiation brainstem necrosis
Litre 2013 ²³	III	155	Linac FSRT	50.4 Gy/28 fr	2.45 cc	60 months	99.3% 3 years	54%	2.5%	3.2	2.5% hydrocephalus
							95.2% > 7 years				2.1% tinnitus
Tsai 2013 ²⁴	III	117	CyberKnife	18 Gy/3 fr	4.7 cc	61.1 months	99.1%	81.5%	Nr	Nr	Nr
Vernimmen 2009 ²⁵	III	51	Proton beam	26C Gy/3 fr	3.45 cc	71 months	98% 5 years	42%	9.5%	7%	Nr

Pts: patients; Nr: not reported; FSRT: fractionated stereotactic radiotherapy.

Table 4.1.2.III. Selected series of acoustic neuroma comparing stereotactic radiosurgery (SRS) and fractionated stereotactic radiotherapy (FSRT).

Author	Class of evidence	N. pts	Technique	Median dose	Mean/median volume (cc)	Median/mean follow-up	Local control	Hearing preservation	Toxicity		
									VII	V	Other
Combs 2015 ²⁶	III	158	SRS	13 Gy	1	67 months	94% 10 years	86%	< 1%	1.8%	3% gait uncertainty
		291	FSRT	57.6 Gy/32 fr	3.5	67 months	94% 10 years	84%	1%	14%	
Anderson 2014 ²⁷	III	48	SRS	12.5 Gy	0.66 cc	83.6 months	97% 5 years	60%	2%	4.2%	2.1% tinnitus
		37	HSRT	20 Gy/5 fr	1.85 cc	43.1 months	90.5% 5 years	63.2%	0%	2.7%	2.7% tinnitus
		19	FSRT	45-50 Gy /1.8 Gy		53.6 months	100% 5 years	44.4%	0%	0%	
Puataweepong 2013 ²⁸	III	39	SRS	12 Gy	0.9 cc	61 months	95% 5 years	75% 5 years	< 1%	0%	< 1% hydrocephalus
		79	FSRT	25 Gy/5 Gy	3.9 cc	61 months	100% 5 years	87% 5 years	< 1%	0%	< 1% hydrocephalus
		28		45-50 Gy /2 Gyr	9.5 cc		95% 5 years	63% 5 years			
Collen 2011 ²⁹	III	78	SRS	12.5 Gy	0.83 cc	62 months	95%	59%	16%	3.7%	Nr
		41	FSRT	50 Gy/2 Gy	5.7 cc			82	3%	1%	

Pts: patients; SRS: radiosurgery; FSRT: fractionated stereotactic radiotherapy; HSRT: hypofractionated stereotactic radiotherapy; nr: not reported.

control rate of 97.1% with a tumour volume downsizing of 82.7% after 6.5 years follow-up, in 523 patients treated with Gamma Knife stereotactic radiosurgery to a median margin dose of 13 Gy. Treatment-related complications consisted only in a transient worsening of pre-existing symptoms, and the overall rate of serviceable hearing was 49%. Watanabe et al.⁷ reviewed the results of 183 patients treated with Gamma Knife radiotherapy to a median dose of 12 Gy. The actuarial 5-year progression-free survival rate was 96%. The rate of facial nerve palsy was 3%. On the other hand, Hasegawa et al.¹³, with a progression-free survival rate of 92%, found an actuarial 10-year rate for preservation of VII nerve function of 97% in the marginal dose group (> 13 Gy) and of 100% in the marginal dose group (< 13 Gy).

For what concerns fractionated stereotactic radiotherapy, Tsai et al.¹⁴ reviewed the results in 117 patients treated with Cyber Knife. A total dose of 18 Gy in 3 fractions was prescribed to a median tumour volume of 4.7 cc. Local control rate was 99.1% with a serviceable hearing preservation rate of 81.5%. A French experience²³ reported outcomes in 155 acoustic neuromas treated with conventional fractionation. Patients received a dose of 50.4 Gy with daily fractions of 1.8 Gy. Local tumour control rate was 95.2% after 7-years follow-up. Facial and trigeminal palsies were observed in 2.5% and 3.1% of patients, respectively. In regards to particle therapy, we found a retrospective study by Vernimmen et al.²⁵, who used protons to a total dose of 26 Gy (RBE) in 3 fractions

with mean minimum tumour dose of 21.4 Gy (RBE). After a mean follow-up of 60 months, the cohort of 51 patients achieved a 5-year local-control rate of 98% with a hearing preservation of 42%, a facial nerve preservation of 90.5% and a trigeminal nerve preservation of 93%.

Suggested treatment volumes, doses, and dose constraints are reported in Tables 4.1.2.IV, 4.1.2.V.

Discussion

During the last decades, the role of radiotherapy in the management of acoustic neuromas has been progressively established thanks to technologic improvements and the availability of long term follow-up data regarding local control and adverse effects.

The studies analysed the results of stereotactic radiotherapy delivered in a single fraction (i.e. stereotactic radiosurgery) or in multiple fractions (i.e. fractionated stereotactic radiotherapy), with standard fractionation or hypofractionation.

In terms of technical aspects, stereotactic radiosurgery can be performed with Gamma Knife (Elekta AB, Stockholm, Sweden), with linear accelerators (LINACs) equipped with micromultileaf collimators, and with Cyber Knife (Accuray, Sunnyvale, CA, USA), a LINAC mounted on a robotic arm. LINAC and Cyber Knife can also be easily used for fractionated treatments. Most of the studies used Gamma Knife, however, no study compared the various technologies in terms of outcome.

Table 4.1.2.IV. Suggested target volumes and radiation doses for acoustic neuroma.

Target volume	Definition	Dose
GTV	Tumour volume defined as the outer edge on post-contrast T1 - w MRI	
CTV	CTV = GTV	
PTV	CTV + no margin in case of GKS	GKS: 12-13 Gy to the tumour volume in a single session prescribed to the 50% isodose (40-100%)
	CTV + 0.5-2.0 mm depending on setup system in case of SRS	LINAC-based SRS: 12-13 Gy to the 80-90% isodose
	CTV + 1.5-2.0 mm depending on setup system and reproducibility of patient positioning in case of FSRT	LINAC-based FSRT: 45-54 Gy, 1.8 Gy/fr to the 95% isodose (or hypofractionation)

GTV: gross tumour volume; CTV: clinical target volume; PTV: planning target volume; GKS, Gamma Knife surgery; LINAC: linear accelerator; FSRT: fractionated stereotactic radiotherapy; fr: fraction.

Table 4.1.2.V. Normal tissue dose constraints for conventional fractionation and stereotactic radiosurgery³⁰.

Critical structures	Conventional fractionation	SRS	Event
Spinal cord	Dose max < 50 Gy	Dose max 13 Gy	Myelopathy
Brainstem	Dose max < 55 Gy	Dose max 12.5 Gy	Permanent cranial neuropathy or necrosis
Cochlea	Dose max 55 Gy Mean dose < 45 Gy	Dose max 12-14 Gy	Sensory neural hearing loss
Ventral cochlear nucleus		≤ 9 Gy	
Modiolus and the basal turn of the cochlea		Ideally < 4-5.3 Gy	

Nowadays, radiotherapy is used as radical treatment or after subtotal resection for large lesions (> 3 cm) at excessive risk of neurological impairment or in case of disease recurrence after surgery³¹. Medium size (2-3 cm in the cerebellopontine angle) and large tumours (> 3 cm) need an active treatment (surgery or radiotherapy) while smaller tumours can be treated or just observed. In this regard, we found two retrospective studies comparing a “wait and see” approach with an active treatment^{6,32}. In both studies, patients were treated with Gamma Knife radiosurgery to a median dose of 12 Gy. Breivik et al.³² reported a serviceable hearing loss in 64% patients treated compared to the 76% in the observational group. Moreover, a highly significant percentage of patients required treatment following initial observation ($p < 0.001$). In contrast, Akpınar et al.⁶, comparing patients who underwent Gamma Knife early (< 2 years from diagnosis) or late (> 2 years after), found higher hearing outcome (88%) in patients treated earlier. Up to now, based on literature data, the “wait and see” policy is considered the best initial option for not growing acoustic neuromas smaller than 1.5 cm, as far as quality of life is good. Therefore, stereotactic radiosurgery should be considered only in case of large and unresectable/inoperable lesions or in small but growing lesions.

Stereotactic radiosurgery for acoustic neuroma (Figs. 4.1.2.1, 4.1.2.2, 4.1.2.3) is usually prescribed to a

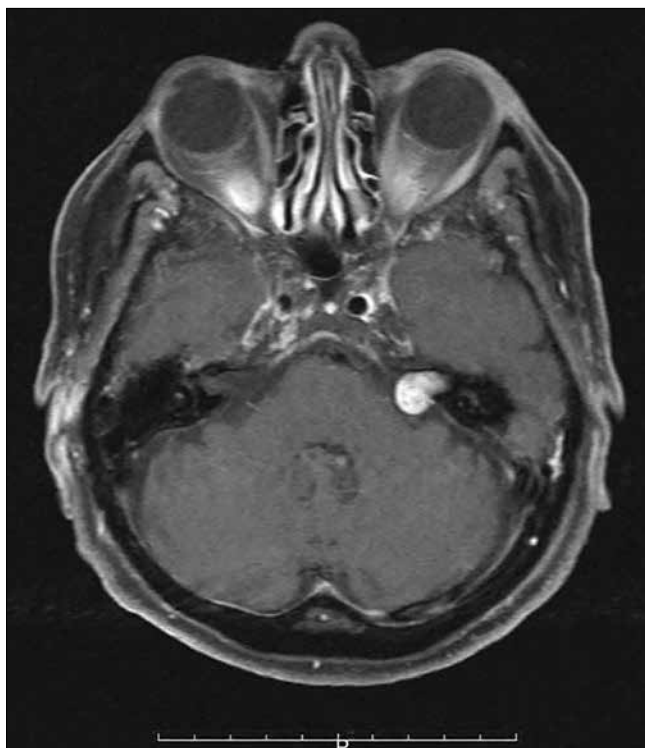


Fig. 4.1.2.1. Axial T1-weighted post contrast MRI demonstrate a post contrast enhancing small acoustic neuroma in the left cerebellopontine angle.

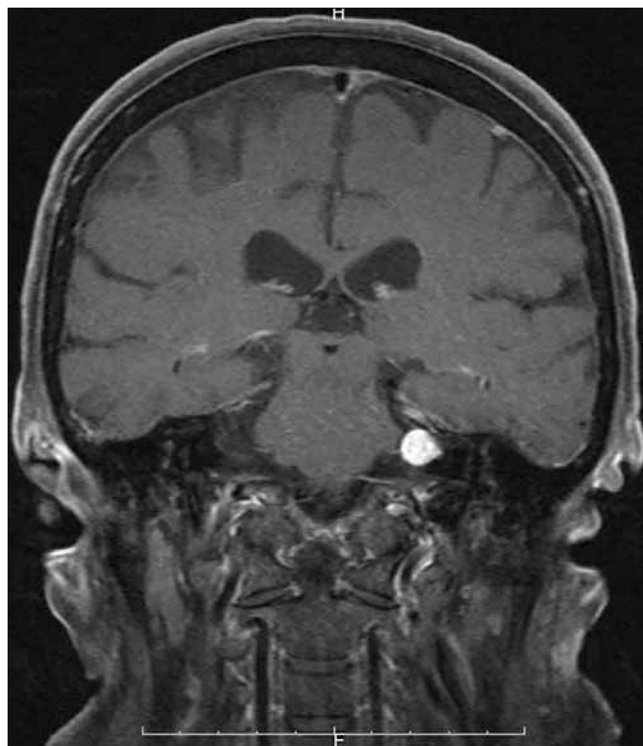


Fig. 4.1.2.2. Coronal T1-weighted post contrast MRI demonstrate a post contrast enhancing small acoustic neuroma in the left cerebellopontine angle.

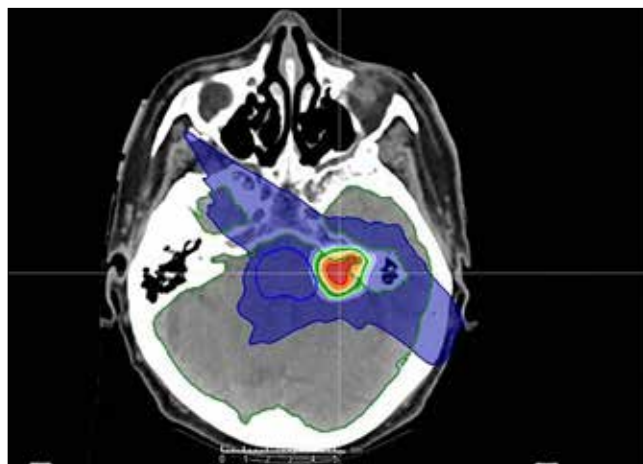


Fig. 4.1.2.3. Radiosurgery treatment plan with volumetric-modulated arc therapy (VMAT). The red colour wash volume is encompassed by the isodose of 95% (dose prescription to 13 Gy).

median marginal dose of 12-13 Gy and can provide good local control, with a progression-free survival rate of 95% after a median follow-up of 5-10 years. The average hearing preservation rate after treatment is nearly 55%. In most studies, facial and trigeminal nerve deterioration rates are nearly 3% and 6%, respectively.

A fractionated schedule is currently used in case of large tumours compressing and displacing the nervous structures when surgery is not feasible for local or general patient condition or for patient refusal. A total dose of 45-55 Gy in 20-30 fractions, or an equivalent dose with hypofractionation is usually recommended in case of fractionated stereotactic radiotherapy. In case of hypofractionation, dose prescription can be in the range of 18-25 Gy in 3-5 fractions^{24 27 28}. In this regard, fractionation can be useful compared to single fraction in case of close proximity to, or compression of, the brainstem and cerebellar hemisphere since it reduces the risk of late damage in relation with the low alpha/beta value (i.e. sensitivity to large dose per fraction) of the nervous tissue, which was estimated of about 3 Gy using the linear quadratic model, compared to a quite similar value (2.4 Gy) for acoustic neuroma³³. Fractionated stereotactic radiotherapy adopted in several literature studies provided a high local control grade, with only 4.8% loss of tumour control in long-term follow-up series²⁶⁻²⁸. The risk of neurological deterioration in terms of hearing quality and facial deficit was similar to that of stereotactic radiosurgery.

As far as radiation therapy is concerned, no randomized controlled studies comparing the safety and efficacy of stereotactic radiosurgery and fractionated stereotactic radiotherapy have been published. However, studies comparing patients with similar tumour characteristics showed that results are very similar in terms of local control and peripheral nerve toxicity (Table 4.1.2.III). The risk of facial and trigeminal nerve deterioration was less for patients treated with radiosurgery series compared to patients receiving fractionated stereotactic radiotherapy, while the chance of preserved hearing showed no difference between the two treatment groups³⁴. In this regard, we found a remarkable different study number between the two groups, in favour to stereotactic radiosurgery, with also a shorter follow-up for fractionated stereotactic radiotherapy series.

For what concerns radiation dose, literature studies did not show relevant differences in tumour control using different dose levels and currently doses ≤ 13 Gy for the single fraction can be recommended in order to facilitate hearing preservation. Moreover, no difference in local control can be observed by using a single session (radiosurgery) or multiple sessions (fractionated radiotherapy). From the data analysed, we can underline that fractionated schedules were used in cases of larger tumour volume (> 2.5 cc).

Proton therapy may be an option for the treatment of acoustic neuroma due to the proximity of radiosensitive organs at risk. The rapid fall of the dose to zero beyond the Bragg peak offers a theoretical advantage in this tumour setting³⁵. Since there is only one study looking at the outcome with proton therapy²⁵, we cannot formulate recommendations about this treatment modality.

One more open question is about the role of stereotactic

radiotherapy for retreatment³⁶. We did not find studies of retreatment after a first stereotactic radiosurgery which satisfied our inclusion criteria because of the low patient number and short length of follow-up. In contrast, we found two retrospective studies, where patients were treated with stereotactic radiosurgery because of a tumour progression after a gross total resection or a partial resection^{19 37}. The larger one treated 90 patients to a median dose of 13 Gy by Gamma Knife³⁷, achieving a tumour control rate of 90%. At a mean follow-up of more than 6 years, the complication rate was low, and persisting facial nerve deficit and trigeminal nerve impairment was 3.3% in both cases.

Although the scarce available data in case of recurrence/progression after surgery came from retrospective studies, we may recommend stereotactic radiosurgery as a potentially safe and effective treatment.

A controversial issue is the potential risk of malignant transformation in acoustic neuromas after stereotactic radiosurgery. We found only one report¹³ which described 1 malignant transformation in a retrospective cohort of 440 acoustic neuromas (0.3%) after a median follow-up of 12 years. Annual incidence of malignant transformation was 0.02%. Based on that, we could conclude that the risk of malignant transformation is minimal.

The main limit of the present review is related to the absence of clinical randomized trials comparing different radiation therapy approaches and series treated with radiation vs. surgery. Literature data are only available from retrospective observational studies. Moreover, a remarkable number of reports were excluded from our analysis because of the short follow-up. Long-term observation is actually essential in benign tumours to detect not only recurrence but also treatment related toxicity that may affect patient's quality of life.

Conclusions

Radiation therapy approaches that have been used in patients with acoustic neuromas include stereotactic radiosurgery and fractionated stereotactic radiotherapy with photon and proton beams as well. The present literature review concludes that similar local control can be achieved with each of these approaches and that treatment decision could be based upon the availability of expertise and technology, as well as patient specific factors. Inoperable medium size (2-3 cm), large tumours (> 3 cm), and recurrent neuromas can be safely treated with radiosurgery and with stereotactic radiotherapy, while smaller tumours can undergo observation until a growth is detected and an active treatment, which can include surgery or radiation, is needed. In any case, the treatment choice should be based upon the balance between the expected morbidity of the tumour and of the therapy, taking into account patient's preference.

4.1.3. Vestibular schwannoma: surgery after radiotherapy

G. Piras, A. Russo, A. Caruso, A. Giannuzzi, M. Sanna

Introduction

Vestibular schwannoma (VS) is a tumor that arises from Schwann cells of the vestibular nerve. The incidence ranges from 10 to 20 per million/year and it accounts for 75% of cerebellopontine angle tumors, 10% of intracranial tumors, and 5% of such tumors occur in patients with neurofibromatosis type 2 (NF2) ¹.

The cornerstone treatment is complete surgical resection that requires an experienced surgical team. With the advances in microsurgical techniques and intraoperative monitoring tools, excellent outcomes have been achieved in terms of preservation of the facial nerve (FN) and, whenever possible, serviceable hearing. In 1969, Leksell introduced the use of stereotactic radiation therapy for VS treatment ². Since then, the use of radiation therapy (RT) became largely widespread because it seems less invasive than surgery. In many centers it becomes the modality of treatment for symptomatic elderly patients, medically unfit for surgical therapy, patients who refuse surgery, tumors occurring in the only hearing ear and in some recurrent or residual growing tumors.

The main disadvantage of radiation therapy is the non-removal of the tumor that retains the risk of growth and thus requires long term follow-up.

Role and controversies of radiotherapy in vestibular schwannoma

There are two main different modalities of radiation therapy in the treatment of vestibular schwannoma:

- The single session protocol or Stereotactic Radiosurgery (SR) that consists of delivering to the tumor a single high-dose of radiation. The skull should be rigidly immobilized to a frame. The radiation beams can be delivered by a modified linear accelerator machine or a Leksell Gamma Knife machine which is more commonly used in the treatment of vestibular schwannoma.
- The fractionated type or Stereotactic Radiotherapy (FSR) consists of giving the required radiation dose over several sessions. This technique is performed through a linear accelerator machine with a relocatable frame (Novalis, Radionics) or with a frameless image-guided, robotic system (Cyberknife).

Regardless the source of radiation in stereotactic radiotherapy (proton, photon, neutron, or ion beams), the tumor center receives the maximal radiation dose (isodose) that gradually decreases in the periphery and surrounding structures. The effect of radiation therapy is not shown until 4-6 weeks after treatment when the acute inflammatory reaction starts to appear with a progressive focal edema and an increase in the

volume of the tumor that might become 26-280% larger than the initial size ³.

Pollock et al. noted three types of VS enlargement after radiation surgery: type 1 showed tumor regression to the initial size or even less. In type 2 the tumor remained stable after the initial enlargement and the patient remained asymptomatic with no need of any treatment. Type 3 was devoted for the tumor that continued to enlarge with subsequent risk of compressive symptoms and need for further intervention ³.

On magnetic resonance imaging (MRI), a loss of central enhancement is found in 93% of the tumor. Multi-septated cyst formation is also common after radiation therapy secondary to tumor necrosis and protein leak from the intratumoral vessels. This reaction remains active till 12-18 months after radiotherapy when the chronic inflammation starts to resolve and be replaced by glial formation to the surrounding structures. The excessive scarring of the tumor to the adjacent nerves in addition to the direct toxic effect of the radiation with the surrounding vasculitis elucidates the delayed occurrence of radiation-induced neuropathies and even demyelination of the nerves ⁴.

In the light of the fact that wait and scan has given us the opportunity to study the natural history of VS, which proves that a section of VS shows indolent growth or do not grow at all ⁵, it is now important to review the results of RT to find out if at least a portion of the success of RT can be attributed to the natural biology of the tumor itself. The literature on RT shows results in terms of tumor stabilization without taking into consideration pretreatment spontaneous arrest of growth ⁶. Very few authors reporting on the success of RT have emphasized on the policy of wait and scan to determine the natural progression of tumor, and many of their selection criteria have been arbitrary. Many reports lack consideration of the age or size of tumors, which has a strong correlation to tumor growth. Moreover, inclusion of NF II, previously treated patients (surgery or RT), referral bias, variations in dose and the RT tool (SR or FSR), and short follow-up have added to the discrepancies of reporting of the results of RT. Most RT authors still report the size of the tumors and the hearing results according to old classifications like the Koos' classification ⁷ and the Gardner-Robertson's classification ⁸, respectively, instead of the newer and more comprehensive guidelines presented in the report of the Tokyo Consensus Meeting on Systems for Reporting Results in Acoustic Neuroma ⁹. A recent study by Han et al. ¹⁰ has observed that the guidelines have made a significant impact on standardization of reporting in RS. It can be noted that most series on RT have an arbitrary approach to irradiation of tumors without a systematic selection criteria or wait-and-scan protocol before initiation of RT. All sizes of tumors have been irradiated. This also includes intrameatal tumors that have shown to demonstrate an indolent growth pattern

and for which wait and scan is recommended¹¹⁻¹³. It is well accepted that wait and scan is an ideal policy in the elderly age group with smaller tumors. The age of patients in our wait-and-scan series and RT series is the same⁵, which indicates that many of the irradiated patients may have benefitted from wait and scan. If it were to be assumed that patients subjected to RT had tumors that showed prior growth, then it becomes important to define the rate of growth and the size of tumors that will prompt an initiation into RT, which is absent in most reports. For instance, tumors that show slow growth rates of 1 to 2 mm/yr should not be a matter of concern in an elderly patient, as such patients can be included in a wait and scan protocol. Also, SR is indicated in small tumors because of the high tumor dose, whereas FSR is indicated for larger tumors¹⁴. But the comparisons show that RS has also been used for large tumors. The maximum and minimum size of tumors that can be irradiated is yet to be defined.

On the other hand, studies have stated that microsurgery is better than RT for tumors larger than 2.5 cm¹⁵⁻¹⁹ because of increased associated morbidity with RT in such cases¹⁷⁻²⁰⁻²³. Other discrepancies in reporting like including patients with previous surgery, NF II, improper classification of tumor sizes, and short follow-ups diminish the validity of reports. The definition of tumor control is also highly variable between series, with some claiming no additional surgical intervention to mean tumor control, which is incorrect²⁴⁻²⁹. As mentioned in our previous study⁵, our wait-and-scan series shows that a tumor shows no growth in 54%, regression in 4% (total of 58%), and progression in 42% of tumors (of which 28% showed slow growth). Compared with this, the successes of RT ranges from 79% to 99%. If this were to be reasoned with our wait-and-scan results, it could be inferred that between 21% and 41% of the tumors actually could have benefitted from RT.

For the benefit of the patient, both the surgeons and the radiotherapists have to be willing to apply the policy of wait and scan to suitable patients before subjecting them to any definitive treatment. Once this commonality is achieved, the efficacy of RT with respect to microsurgery can be then compared among the subsets of patients who are not suitable for wait and scan or those who have failed wait and scan. This must be the direction of future studies that will enable us to draw meaningful conclusions. Also, standardized reporting criteria as suggested by Battaglia et al.³⁰ are recommended.

Complications and salvage surgery after radiotherapy

The complication of radiation therapy is underestimated and has not been properly addressed in the literature³¹. The most common complications are hearing loss, trigeminal hypoesthesia and facial nerve paralysis with an incidence that ranges from 25% to 89%, 19% to 34% and 8% to 32% respectively³²⁻³⁴. These complications can occur up to 28 months post radiotherapy even without tumor growth³⁴.

The pathophysiology of hearing loss following radiotherapy could be explained by several mechanisms:

- damage to the auditory pathways even from direct effect of the radiation or secondary to a decrease in blood flow due to vasculitis and hyalinization of vessel walls;
- compression of the cochlear nerve in the internal auditory canal secondary to the tumor enlargement;
- acute intracochlear hemorrhage.

Less common complications are ataxia, cerebral edema, hemifacial spasm, quadriplegia, hydrocephalus and malignant transformation of the VS³⁵.

The incidence of hydrocephalus secondary to radiotherapy ranges from 4% to 14%. It can occur even without evidence of increase in the tumor size or compression by the tumor. The pathophysiology of communicating hydrocephalus following radiotherapy is explained by tumor necrosis that results into elevation of CSF protein that obstructs the arachnoid granulations with subsequent CSF malabsorption³⁶.

A publication by Jeon et al.³⁶ showed that nine of 90 patients who received radiotherapy as primary treatment of VS developed communicating hydrocephalus whereas only one of 146 patients (0.68%) who underwent primary surgical resection of the tumor developed this complication.

Up to this date, our experience with VS surgery revealed 2 out of 3,500 patients (0.0006) who developed postoperative communicating hydrocephalus after surgical resection of their tumor.

Malignant brain tumor following stereotactic radiotherapy of VS has been reported in several studies. It occurred from 6 months to 19 years after radiation therapy³⁵. Ron and Sadetzki reported that brain tissue exposure to radiation doses as low as 1 Gy was sufficient for the development of a secondary tumor. Radiation induced malignant brain tumor has been reported in solitary schwannoma as well as in NF2³⁵. Warren et al. demonstrated that VS removed from NF2 patients previously irradiated had more chromosomal anomalies than non-irradiated tumors. Besides this, Baser et al. mentioned that NF2 patients who have received radiotherapy had a 14-fold increased risk of developing malignant brain tumors³⁷. Despite its low incidence, the risk of radiation induced malignant brain tumor and de novo benign cerebral tumors should be considered in the counseling and the decision making process of VS treatment. Since 1993, in order to decrease the incidence of radiosurgery complications, the doses of radiation have been reduced to 15-25 Gy of isodose and 10-15 Gy of marginal dose³⁸.

Radiation therapy is abused in some centers who recommend such treatment for all VS regardless the age of the patient, the size of the tumor, the presence of a cystic component and without clear evidence of tumor growth³⁹⁻⁴⁰.

It is generally accepted that radiation therapy should not be

given for tumors greater than 3 cm because of two reasons:

- to avoid compressive symptoms following normal expected growth that occurred within the first year;
- to prevent the morbidity related to radiation therapy, due to the fact that such large tumors need a higher therapeutic dose.

Our experience in VS surgery with a tumor size less than 3 cm shows excellent outcomes in regards to functional preservation of the facial nerve (93.5% grade 1-3) as well as preservation of serviceable hearing in cases of small tumors (< 1.5 cm) with non-enlarged internal auditory canal (36.4%). Complete resection of the tumor was achieved in 96.2% of these patients with minimal morbidity and no recurrent tumor was encountered after at least 3 years of follow-up³¹.

Excellent results are also reported by other specialized referral skull base and neuro-otology centers that showed no major benefits of radiotherapy on surgery⁴¹. The rate of tumor control with radiotherapy might be overestimated in the literature. As written before, in many centers, stereotactic radiotherapy is performed before the proof of any tumor growth; so, the good result following radiotherapy might be attributed to the natural course of the disease and not to the efficacy of the radiation⁵. In almost all the publications that reported good control of the tumor growth following radiation therapy, the mean follow-up period ranged from 2 to 5 years, which is considered as an inadequate period in comparison to the follow-up needed to define the success of radiation therapy in the treatment of benign brain tumors (pituitary tumor, meningioma). Breen et al. reported that tumor control rate following radiotherapy for nonfunctional pituitary adenoma decreases with time even after 20 years of follow-up⁴². Therefore, long term follow-up studies (up to 2 decades) using the small radiation dose are necessary to prove the efficacy of such modality of treatment.

As mentioned previously a tumor enlargement within 1 year after radiotherapy is a normal finding and should not be considered as an indication to surgery unless the patient has compressive symptoms or severe complications secondary to tumor growth (brainstem compression, hydrocephalus).

The cranial nerves during this period are very vulnerable to be injured during surgical manipulation.

Most authors agreed that removal of VS is more difficult in a patient who received radiation therapy when compared to a patient who had not⁴¹.

Difficulties in tumor dissection ranged from 43% to 100% of the cases. Most common difficulties included a loss of the peritumoral arachnoidal plane with thickening of the arachnoid, scarring adjacent to the facial nerve, trigeminal nerve and brainstem. Other intraoperative difficulties were adherence of the tumor to the cerebellum, lower cranial nerves, anterior inferior cerebellar artery and excessive intraoperative bleeding. The postoperative facial nerve

function outcomes varied from a report to another depending on the completeness of tumor removal, but in all the cases the results were much worse than in patients who had not received previous radiation therapy. Iwai et al. found that 33% of their patients had worsening of the facial nerve function after at least 11 months of follow-up even though in all cases the internal auditory canal was not opened and residual tumors were left on the facial nerves⁴³. Friedman et al. recommended subtotal resection of irradiated tumor when this is adherent to the facial nerve⁴¹. Despite this protocol, these patients had poorer facial nerve function outcomes than the non-irradiated group. Regardless of the approach and whether the tumor was totally or subtotally removed, no single case was encountered with preserved postoperative serviceable hearing. We prefer to perform the enlarged translabyrinthine, transotic or transcochlear approaches to ensure total removal of the tumor because in most of our cohort, the tumor size was greater than 1.5 cm or the patients had a poor hearing status.

In our series complete tumor removal was achieved in 84.2% of the cases. Residual cystic walls of the tumor were left in two VS with no sign of growth after a follow-up period of 3 y and 6 y respectively. Around 73.3% of our patients had worsening of FN function postoperatively, and 63.6% of those who complained from this deterioration had HB facial nerve grade 2-3³¹.

These relatively poor facial nerve outcomes are attributed not only to the loss of plane between the tumor and the nerve but also to the reduction of the neural regeneration secondary to radiation therapy. This deficit in neural regeneration and the capacity of spontaneous recovery from surgical trauma could be attributed to the decrease in blood supply of the nerve following radiation therapy⁴¹. According to our experience we believe that complete tumor resection is the gold standard therapy to prevent a second salvage surgery that will be much more difficult with a higher morbidity rate and to avoid the risk of malignant tumor transformation.

We recommend subtotal or near total resection only in cases of elderly patients or with cystic tumor when the cyst wall could be left on vital and neurovascular structures⁴⁴.

Conclusions

Radiation therapy should not be considered as an optional treatment of vestibular schwannoma without a clear and documented evidence of tumor growth. The patients should be made aware of its complications and risk of failure, especially in young patients and NF2 cases.

Surgical resection of VS after failed radiotherapy is very challenging with relatively poor facial nerve outcomes and very difficult hearing preservation.

4.1.4. Complications in acoustic neuroma surgery

V. Baro, A. Landi, L. Denaro, D. d'Avella

Introduction

The first surgery for vestibular schwannoma (VS) was performed by Sir Charles Balance in the second half of 19th century¹. At the beginning of this surgery the mortality rate was as high as 80-90% and it has remarkably decreased especially in the second half of the last century, thanks to the introduction of microsurgical techniques and of dedicated oto-neurosurgical teams². Nowadays the mortality is less than 1%³⁻⁹ but the rate of complications is still considerable, ranging from 13% to 28.2% in recent series⁶⁻¹⁰, although permanent deficits remain in a minority of patients⁶. Several risk factors have been identified such as tumor size, craniectomy instead of craniotomy, park bench position, surgical approach, comorbidities and low surgeon case-load^{6 10-12}. In this paper, we analyze the complications that plague VS surgery not related to facial and cochlear nerves.

Life-threatening complications

Cerebrospinal fluid leakage and meningitis

Cerebrospinal fluid (CSF) leakage is the most common complications encountered in VS surgery. Its incidence has decreased during the last decades thanks to an increased awareness of this issue and to the introduction of technical refinements for its prevention. In recent series it ranges from 2% to 10.6%^{3-11 13 14} and it can present with otorrhea, rhinorrhea and wound swelling with or without leakage from the incision. According to some authors the risk for CSF fistula has been considered higher in the retrosigmoid approach^{8 9 11 13} although Sughrue et al. found that translabyrinthine approach is more likely to cause CSF leak¹³. Moreover, in some cases, tumour size has been associated with a higher incidence^{9 15} but there is not a general consensus neither for the correlation between CSF leakage and surgical approach nor with tumour dimensions. The violation of the mastoid and retrolabyrinthine or apical cells and difficulties encountered during dura mater closure are the main responsible for leakage. Many strategies have been developed to reduce this risk, such as the combined use of the endoscope to properly check the surgical field, the obliteration of all the opened cells with bone wax and the obliteration of the cavity with abdominal fat, then strengthened with a vascularized muscle flap placed over it. The re-placement in situ of the bony flap is associated with a lower risk of leakage and the closure of the tegumental tissues can be reinforced with temporal fascia and stitches instead of staples^{4 6 8 10 11}. A conservative management can be successful, involving head elevation, pressure dressing with or without puncture, supplementary stitches. In case of failure, invasive procedures entail lumbar drain placement

and revision surgery^{4 8 11}. Some authors advocate a more aggressive treatment in order to avoid more dangerous complications, such as intracranial infection⁴. In fact, the occurrence of meningitis is mostly related to CSF leakage¹⁴, ranging from 9.85% to 0.14%^{3-10 13}. Reports of aseptic meningitis are not so rare. Avoiding hemorrhage during surgery with blood flowing into the arachnoid space and reducing the use of heterologous materials (bone wax, hemostatic agents, glue) can reduce this risk^{4 5 16}.

Intracranial hemorrhage

Hemorrhagic complications occur within hours or days after surgery, mostly within the first 24 hours⁴, representing the most serious postoperative complication and the leading cause of death in this group of patients⁹. The incidence has reduced significantly in the last decades, ranging from 0.6% to 2.7% in recent series³⁻¹⁰, and requires surgery in a half of the cases¹⁷.

It can present with pontocerebellar angle hematoma, epidural hematoma, subdural hematoma, subarachnoid haemorrhage, intracerebellar or brainstem hematoma. The major responsible for these complications include: incomplete hemostasis during tumour removal, tearing of bridging veins, major sinuses or jugular bulb bleeding or bleeding from the temporalis muscles^{4 8 17}. The warning symptom is mainly a progressive deterioration of consciousness that should be promptly recognized and managed urgently. A delayed identification of this condition may result in cerebellar oedema, acute hydrocephalus, cerebral herniation and brainstem damage, leading to devastating consequences *quod valetudinem* and, as mentioned above, *quod vitam*. Surgical intervention entails wound opening while the patient is in the intensive care unit, to decrease intracranial pressure before CT scan, hematoma evacuation and external ventricular drain placement (EVD)^{8 9}. In general, during the first 24-48 hours after VS surgery, a strict neurologic monitoring is strongly recommended and the patient should be awakened and extubated as soon as possible⁸. Several recommendations should be followed in order to reduce the risk of postoperative bleeding. A careful haemostasis during tumour removal should be performed also to obtain a clear vision of surgical field, especially in the farthest area or near the brainstem where the haemostasis could be difficult to achieve. Some haemostatic agents could be very helpful in this setting to achieve valid control of ooze bleeding in prohibitive regions¹⁸. SNC parenchyma decompression (obtained by the opening of basal cisterns or by tumour removal) should not be rapidly performed to avoid bleeding from bridging veins and small arteries. At the end of surgery the surgical field should be abundantly irrigated and a Valsalva manoeuvre should be performed to exclude a venous hemorrhage^{4 8}.

An association between intracerebral hemorrhage and large

VS has been described in literature^{8,10}, whereas its relation with surgical approach and patients' positioning is still debated¹⁷.

Cerebellar oedema

Cerebellar oedema is predominantly a direct consequence of cerebellar manipulation during surgery, especially in case of excessive retraction of the cerebellar lobe. This complication occurs in less than 1.5% of the cases^{4,6-9} and it can lead to obstructive hydrocephalus, requiring surgical drain placement¹⁹. The treatment includes proper patient positioning, hyperventilation, steroids, mannitol and diuretics, CSF drainage (EVD) and wound opening^{6,19}. Limiting extensive coagulation during tumour removal is extremely important to avoid perforating artery interruption which would lead to brainstem ischemia. Coagulation of distal branches of the anterior inferior cerebellar arteries is less harmful but the persistence of cerebellar dysfunction is usually related to vascular injuries to the cerebellar peduncles¹⁷.

Acute hydrocephalus

The occurrence of de-novo hydrocephalus after VS removal is less than 5%, as a result of other complications such as cerebellar swelling, haemorrhage, CSF absorption impairment (due to blood products or infection) and brainstem stroke. Postoperative hydrocephalus usually presents with symptoms of intracranial hypertension and its treatment entails the resolution of the underlying cause and EVD^{3,7,9,19}. Delayed hydrocephalus, requiring permanent shunting is rare, occurring in less than 1.6% of patients^{4,6,9}.

Lower cranial nerve dysfunction

Lower cranial nerves dysfunction is not a negligible drawback, leading to severe complications as aspiration pneumonia, which still represents a cause of death in these patients. Lower cranial nerve dysfunction affects up to 8.2% of patients³⁻⁸ but permanent deficits afflict only less than 1% of patients^{4,6,8,12}.

Non life-threatening complications

Postoperative headache

Postoperative headache is a common complication in VS surgery, affecting up to a quarter of patients, typically decreasing one year after surgery. Even if it is classified as a not life-threatening complication, it may have an important impact on postoperative quality of life²⁰. This complication has been associated with the retrosigmoid approach, especially without bone flap replacement^{3,11,20}. Several explanations have been proposed for persistent postoperative headache, among these: chemical meningeal irritation from the dust generated from the drilling of the internal acoustic canal, occipital nerve injury, fibrous adhesion between the dura mater and the muscles in case of craniectomy and scar tissue. Bone flap replacement or cranioplasty to repair the

bony defect can reduce its incidence. The treatment entails the use of analgesia (e.g. paracetamol or nonsteroidal anti-inflammatory drugs, NSAIDs) and in severe cases also narcotics. More aggressive approaches include cranioplasty, occipital nerve resection or local anaesthetics²⁰.

Cerebellar dysfunction

Postoperative symptoms that can be ascribed to cerebellar dysfunction occur in up to 35% of patients. The majority of these recovered over time without need of rehabilitation, which is required in a limited number of cases^{3,4,6,8}. As previously mentioned, the persistence of this complication is generally due to a vascular insult to cerebellar pathways at the cerebellar peduncles¹⁷.

4.1.5. Hearing Preservation Surgery (HPS) with retrosigmoid approach

A. Mazzone, E. Zanoletti, D. Borsetto, D. Cazzador

HPS has acquired a central role in the management of acoustic neuroma, as it offers a coherent line of hearing conservation/rehabilitation with respect to, and integrating with, the alternative therapies. HPS initiated over 50 years ago and had a slow and difficult course with empirical development of indications and evaluation of outcome, not to mention the operative technique which included both otological and neurological surgery and could not be learned with laboratory training. The late alternative therapies of observation and radiotherapy made more complicated the way to a consensual management. The inalienable principle of the patient's choice of therapy excluded the randomization necessary to a clinical study and allowed only a progress based on third level evidence.

It is noteworthy that the first cases of HPS were separately reported in the neurological and otological fields. The pioneers were Elliot and McKissock in 1954¹ who reported on two successful cases of tumor removal with suboccipital approach. Pertuiset², Smith³, Bremond⁴ and Sterkers⁵ followed. In 1984 Jannetta⁶ gave a detailed description of surgical and neuromonitoring technique and reported on the hitherto papers on hearing preservation surgery. In the otoneurological field, in 1961 House⁷ described the middle fossa approach to the internal auditory canal and in the following years preserved hearing in few intracanalicular cases⁸. Glasscock et al.^{9,10} contributed to setting the bases of HPS with both the middle cranial fossa and the retrosigmoid approach. There ensued the diffusion of intraoperative monitoring, the classification of hearing, the long debate on the exposure of the full canal up to its fundus and the years of popularization ending in more realistic expectations. Today, the practice of hearing focused management is a goal of all the three approaches, HPS, observation and radiotherapy,

and remains the object of inconcluded discussion due to the lack of high evidence studies as well as a universal measure of quality of the preserved hearing.

This aspect is seen also in our experience with HPS, which started in 1976 with the retrosigmoid approach and adopted admission criteria increasingly restrictive¹¹ as suggested by the ongoing experience, from tumor ≤ 3 cm size and 50 PTA/50 SDS, to reach the final parameters of 10 mm and 30 PTA/70 SDS and little altered auditory brainstem response (ABR). The surgical technique of retrosigmoid approach with retrolabyrinthine meatotomy had a stepwise increase of labyrinthine landmarking from the only vestibular aqueduct to the semicircular canals, to the transition of dura to Fallopius canal¹¹⁻¹³. The outcome in the series of 100 cases with parameters of < 10 mm size and 30 PTA/70 SDS had a success rate ranging from 54 to 85% depending on the modality of evaluation; deafness occurred in 9%. For cases exceeding the parameters, the outcome was remarkably worse and confirmed that HPS was advisable only for small tumors with good hearing. The plain correlation of therapy vs outcome of the current papers was investigated in depth by searching the quantitative measure of predictivity of the preoperative hearing and size with statistical methods (unpublished, Zanoletti et al.). It came out that the cut off for success was PTA 21 or 27 for the AAO-HNS class A and the Tokyo classes A-B, respectively. The cut-off size was 6 mm in the cerebello pontine angle, the ABR was with delayed but present waves.

Translating these parameters to the surgeon's point of view, that is the physical condition of the tumor-nerves complex, the limited hearing loss means a limited loss of auditory fibers and cells, while the size implies a loss caused by the size itself as well as by the trauma of dissection. This concept of nerve loss is important because a surgical procedure involves a loss of auditory cells and fibers and impacts on hearing depending on the auditory reserve on which it acts.

The same predictors of hearing preservation were found also in observation and radiotherapy, thus implementing the motto "good nerve withstands better the effect of surgery, time and radiation".

There seems to be, however, a difference among therapies as to long term outcome. While surgery involves an immediate loss in a number of cases and a little loss with passing of time, observation and radiotherapy have almost no loss at short term and continual sustained loss at mid- and long term in such a way that hearing is worse to a significant extent after 10 years and more^{14,15}. It is here pertinent to mention that the factors for hearing decline are differently present in the three therapies. In HPS, factors affecting hearing preservation are surgical trauma and time, in observation they are time, tumor presence and tumor growth, in radiotherapy they are time, tumor presence, tumor growth, and effects of radiation.

The maintenance of hearing with the feasibility of an electric

rehabilitation is universally seen as the challenge posed by the early diagnosis. None of the three therapies have a convincing answer, although there seems to be the mentioned more favorable long-term outcome with hearing preservation surgery¹⁴ but the lack of level one evidence leaves us with the weak level three studies to face the mounting number of cases. The necessary "here and now" approach is a sort of eclectic guideline taking in the best of every therapy applied to the parameters of the individual case, which meant for us the multi-optional hearing focused therapy¹⁶. Within this frame, the HPS can be recommended for cases of favorable size and hearing as mentioned, but conversely it loses its preeminence in favor of observation with cases off these parameters.

4.1.6. Assessing hearing to orient the choice of treatment for acoustic neuroma

R. Bovo, F. Sorrentino

Introduction

In patients with a preserved hearing function, we have three options for managing acoustic neuroma: 1) observation; 2) early hearing preservation surgery; or 3) early preservation surgery and, in the event of this failing to preserve hearing, rehabilitation with a cochlear implant (CI). In terms of preserving hearing function, the outcome of any of the above treatments is always partial. The results are better when the patients' hearing function is better beforehand and, more importantly, if their neural anatomical structures are better preserved. This means that the first issue for audiologists is how to ensure a thorough assessment of hearing function in order to be able to predict the outcome of any therapy. This includes considering the degree to which any deterioration in hearing function would affect the patient's quality of life. In particular, the clinical indication for hearing preservation surgery (HPS), which is the more complex and difficult surgical option, has to take into account the realistic feasibility of preserving hearing, and the likely impact of a preserved hearing function in a given patient. Hearing preservation takes priority in the case of surgery involving the only hearing ear, or when hearing deterioration in the contralateral ear is likely, as in patients with NF2. If possible, HPS is strongly indicated in such cases. The choice is less clear-cut when the contralateral ear retains a normal hearing function or benefits from a hearing aid, and there is no risk of hearing declining in the future. In this case, we have to balance between a more complex surgery VS the chance to maintain a binaural hearing. It should also be noted, that the postoperative auditory impairment mainly consists in the onset of the head shadow effect when acoustic stimuli come from the less well functioning ear. Although not very detrimental, this can affect hearing in daily activities, and

patients need to be informed about such a possibility. Before planning any HPS, it is essential to provide appropriate counseling, taking into consideration individual patients' needs and lifestyle, and assessing their acceptance and motivation concerning a possible rehabilitation with hearing aids or CI in the future.

Finally, in the event of a total or partial failure of HPS, audiologists should assess their patient's residual hearing in order to establish whether they would benefit more from a hearing aid or CI. The same type of audiological assessment is also indicated for patients who undergo early surgery without hearing preservation and are fitted with a CI. In our opinion, cases in which an initially good hearing function is deliberately not preserved should be extremely rare.

Issue 1: how does initial hearing influence the chances of preserving auditory function?

To deal with this first issue, audiologists should use a set of audiometric, electrophysiological and imaging tests¹ to obtain information about the anatomical and functional condition of the cochlea, cochlear nerve, and central acoustic pathways. This poses a challenge for clinicians because numerous histopathological studies have shown that acoustic neuroma per se, as well as any surgery or radiotherapy to deal with it, can cause various cochlear and neural lesions, which are often connected, as shown in Table 4.1.6.I. This often makes it really difficult to establish a differential diagnosis or identify the site of the damage. Even 3 Tesla MRI and a full audiological examination do not always produce reliable conclusions.

Acoustic neuromas can cause cochlear damage with loss of hair cells, but the correlation between hearing loss and cochleograms (corresponding to the correlation between pure tone threshold in life and the extent of hair cell loss along Corti's organ at post-mortem examination) varies

considerably. Damage involving up to 75% of internal hair cells (IHCs) does not result in a significant increase in the pure tone threshold as long as the outer hair cells (OHCs) are intact. On the other hand, total destruction of the OHCs can lead to a maximum tonal loss of 50-60 dB, but even limited damage can cause a severe loss of frequency selectivity and distortion, meaning a significantly worse speech intelligibility or hearing impairment with competitive noise. Synaptic damage to high-frequency, low-threshold type 1 neurons is often seen in response to oxidative stress, such as noise-induced hearing loss, presbycusis, and exposure to ototoxic drugs. It is reasonable to assume that oxidative stress can occur in vestibular schwannoma too, due to cochlear hypoxia caused by vessel compression, for example. It was recently suggested that the factor causing the most damage to the cochlear nerve might be the extracellular vesicles secreted by vestibular schwannoma^{2,3}. Tumor necrosis factor (TNF α) would act as an ototoxic molecule, while fibroblast growth factor 2 (FGF2,) would have a protective role for the molecules secreted by vestibular schwannoma. Cochlear damage may or may not be associated with a reduction in the population of spiral ganglion neurons and/or in their connections within the ganglion, and/or with damage to the cochlear nerve fibers probably caused by ischemia or compression. In addition to structural damage, there may also be functional alterations, such as a decline in neural conduction velocity or auditory processing. The auditory system is characterized by high speed and precision timing. A precise temporal encoding is maintained on multiple levels within the central nervous system. A loss of speed and temporal precision is probably one of the first effects of a neuroma exerting pressure on the cochlear nerve fibers. On the other hand, aging may also coincide with a decline in the speed and accuracy with which we process peripheral information at central level, as happens for other sensory

Table 4.1.6.I. Histopathological cochlear and neural damage secondary to neuroma and/or its treatments. Cochlear damage can aggravate the neural damage as a result of retrograde degeneration, while the neuroma's compression of the internal auditory canal, in addition to causing neural damage, can aggravate the cochlear damage due to an ischemic effect resulting from compression of blood vessels. Ototoxic molecules seem to be secreted by schwannomas through extracellular vesicles.

Cochlear damage		Neural damage
Internal hair cells	➔	Reduction of ganglionic neurons and their synapses
Vascular stria		
Spiral ligament	Retrograde degeneration	
Endolymphatic hydrops	Vascular damage	Compression and fiber reduction
Eosinophils and proteins precipitated in the perilymphatic spaces	Extracellular vesicles with ototoxic molecules	
Upregulation of genes that favor neuroma and cochlear damage	➔	Ischemia, intraneural hemorrhage

systems, and for the central nervous system as a whole. The association between aging and a declining temporal processing function was well described by Humes et al. ⁴ in their systematic review. For the same pure tone threshold, it is not easy to distinguish between the loss of speed and temporal processing capacity due to cochlear nerve fiber damage and that due simply to aging.

A slower conduction velocity due to synaptic damage, loss of neural fibers or lesser myelination reduces the amount of neural patterns, or the information that can be transmitted per unit of time. The diversity of the peripheral histopathological and functional damage largely explains the different outcomes – in terms of speech perception – seen in patients with similar tonal audiograms, as well as the sometimes very different results obtained with hearing aids or a CI.

The association between a good hearing before surgery and a better hearing preservation afterwards has been observed in large series ⁵. Unfortunately, there is a considerable inter-individual variability, and the predictive value of these tests for individual patients is limited.

Preoperative hearing assessments traditionally include auditory brainstem responses (ABR), pure tone and vocal audiometry. A test battery that also involves assessing speech intelligibility in quiet and sensitized conditions (such as the Matrix test), and a temporal discrimination test might be more sensitive and specific. The aim would be to obtain statistical confirmation of how this battery of preoperative tests correlates with the patients' follow-up, and the different treatments adopted for acoustic neuroma.

Issue 2: how severely does the damage caused by the various treatment options affect the patient's daily listening abilities and quality of life?

As mentioned previously, significant differences can be seen between tonal threshold and speech intelligibility – in conditions of quiet and even more of noise – as a result of neuromas and their treatment. There are no conclusive data in the literature on the quality of any preserved hearing function, especially in relation to the different therapeutic options adopted.

Generally, when the threshold asymmetry between the two ears exceeds 40 dB, the more impaired ear does not contribute any subjectively perceptible benefit. In the case of such a hearing loss it is likely that only a hearing aid will be able to correct the impairment.

During pretreatment counseling, patients should be informed that even a partial failure of HPS can prompt quite a significant deterioration in subjective hearing function, though this can generally be overcome with a hearing aid. It is impossible to rule out the risk of neural damage, however, which can cause qualitative alterations involving distortions and impaired temporal functioning, with a consequently worse outcome even with a hearing aid. If HPS fails completely, resulting in

profound or total deafness, then the general considerations on single-sided deafness (SSD) could be applied. The disadvantages of monaural as opposed to binaural hearing have been amply described in the literature, but how best to solve the problems involved is still a controversial issue. On the one hand, there is agreement on the effects of unilateral deafness on infants and children, which include aural preference syndrome, a reduction in incidental learning, and difficulty listening in school class. On the other hand, the consequences of SSD for adults are still widely debated and clinical considerations are discordant: there may be the head shadow effect, when the primary signal comes from the hypoacoustic side, and loss of the benefits of binaural hearing (binaural masking release, spatial localization, and loudness addition). In recent times, the clinical solutions for these problems have gone from air conduction CROSS systems to bone-anchored hearing implants (BAHI), and the most recent, a CI. In this last case, opinions on the cost-benefit ratio vary considerably, with much of the debate concerning whether recommending a CI in the SSD is clinically justified and, if so, whether the costs should be covered by public. The discussion stems from the fact that it is difficult to assess residual hearing and functional outcomes after CI, especially when the contralateral ear is “normal”, as in the case of SSD, or markedly asymmetric hearing loss.

Issue 3: how to assess residual hearing after unsuccessful HPS for the purposes of any rehabilitation with a hearing aid or CI

A first problem concerns the limits of masking during audiometric tests, especially when using a free-field signal presentation, as in the case of audiometry with a hearing aid or CI. We need to bear in mind that verbal signals have intensity oscillations of 30 dB, as shown in Fig. 4.1.6.1. So, if speech in a free field is sent at 65 dB HL, for example, and masking with headphones or inserts on the best ear is sent at 65 dB SL, the latter ear will retain a 50% audibility of the verbal signal.

The attenuation of any device reaches a maximum level imposed by bone transmission, which is frequency-specific: for instance, it is about 40 dB for 2,000 Hz ⁶. HPD soundproofing headphones afford an attenuation of about 30 dB. Patients cannot tolerate a masking noise with an intensity in excess of 70 dB SL for more than 1-2 minutes. With maximum possible masking, a 50% intelligibility for a verbal message is often achieved by a normal-hearing ear. For a complete report on the audiological study of SSD, see a recent consensus document ⁷.

The hypothesis of assessing the functional results of a CI in SSD with electric vocal audiometry still poses numerous difficulties. Patients with a CI benefit from rehabilitation with games and exercises in the form of apps for tablets or smartphones connected wirelessly to their CI. Such material

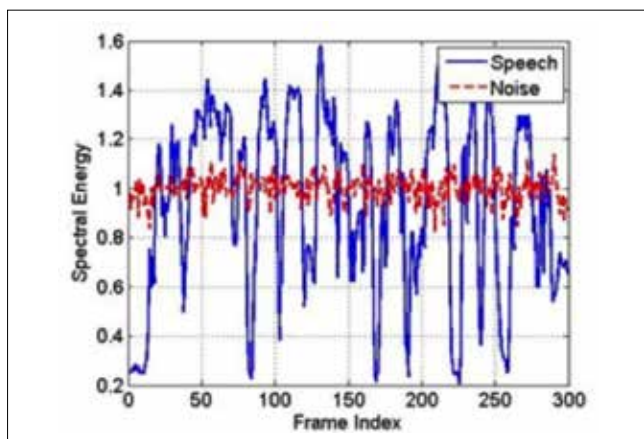


Fig. 4.1.6.1. Spectral energy of speech and noise.

cannot be used for the purposes of vocal audiometry, however, because it is impossible to quantify the electrical stimulation and correlate it with an acoustic intensity in dB. In short, it is not yet possible to apply such a method to judge the benefit of a CI in terms of everyday hearing in conditions resembling a free field.

In patients whose HPS failed, the benefit of a hearing aid or CI may be significantly lower than expected in relation to their residual tonal threshold as a consequence of neural damage, as mentioned previously. In particular, patients may have significant speech perception difficulties, and a more limited prosthetic benefit in noisy and/or reverberant acoustic environments. Specific tests can help to reveal these difficulties, such as competitive speech audiometry, or time discrimination and frequency tests. These methods can help clinicians choose the best type of hearing rehabilitation, by avoiding a bilateral HA when binaural interference is suspected, for example. Such audiometric tests can be useful when fitting the hearing aid too: for example, a reduced gain can be adopted on frequencies less important to speech perception, and any dead zones can be identified. Specific strategies can be applied to CI mapping too, such as the use of short pulses and low stimulation rates. As mentioned previously, some authors only consider it important to focus intraoperatively on preserving the integrity of the cochlear nerve, regardless of the HPS method adopted, even in early surgery for patients with good initial hearing, based on the assumption that rehabilitation with a CI can deal with the residual total deafness.

We disagree with this approach because restoring hearing with a hearing aid in the event of HPS failing usually achieves a better functional result than a CI, as a first-line solution. Intraoperative cochlear nerve preservation is certainly important, but the whole peripheral auditory system forms a tightly-knit unit in terms of function and damage response. There is consequently some debate as to whether preserving

the cochlear nerve alone, or even the cochlea, is important. The most effective electrical stimulation sites for a CI are still not known exactly. All the following structures could have an important role: residual IHCs; their distal synapses and dendrites; the body of ganglion neurons; and/or the Ranvier nodes immediately proximal or distal to the soma. Unfortunately, we do not know where electrical stimulation is most effective, and that is why we believe it is better to keep all structures of the peripheral auditory system as intact as possible to enable their electrical stimulation. Translabyrinthine surgery certainly causes damage to the peripheral auditory system as a whole, whereas retrosigmoid or middle cranial surgery preserves the cochlear structures much better. It should also be noted that we still know little about the influence of various types of surgery and RT for acoustic neuroma, and subsequent CI rehabilitation, on the natural history of the peripheral auditory system. To give an example, data in the literature on the timing and frequency of cochlear ossification after translabyrinthine surgery are extremely variable, with cochlear ossification reportedly occurring in 15% to 78% of patients⁸⁻¹⁰. Referring to findings after CI surgery, more than 30% of patients requiring a modest drill-out of the cochlea subsequently experienced worsening perceptive outcomes due to progressive ossification. Another point in favor of hearing preservation in acoustic neuroma surgery (supporting the conviction that it is always better to try to preserve hearing rather than plan a CI from the start) lies in that CI cannot restore a normal auditory function. It is true that children fitted early on with a CI can achieve communication skills very similar to those of their normal-hearing peers, but inter-individual variability is wide and the CI still has numerous drawbacks when it comes to hearing in noise, or listening to music, as well as a strong technological dependence, high costs and other issues. In short, focusing on preserving hearing, with the option of a hearing aid if necessary, usually achieves better functional results than opting for a CI as a first-line approach.

Limits of currently-available hearing classifications for HPS

Audiological assessments should measure auditory function as reliably as possible in individual patients and homogeneous groups, in order to orient treatment strategies, which may involve observation alone, radiotherapy, and/or surgery, with or without a preserved hearing function. It is only by using standardized and comparable tests that we will be able to collect significant data to support clinical guidelines on appropriate therapies. Five classifications are currently used to assess auditory function in patients with acoustic neuroma: the Gardner-Robertson¹¹, the American Academy of Otolaryngology-Head and Neck Surgery¹², the Sanna, the Tokyo¹³ and the Word Recognition Score (WRS)¹⁴. Hearing function is classified by pure tone averages (PTA),

and speech discrimination scores (SDS), obtained from tonal and vocal audiometry, respectively. For the Gardner-Robertson classification, the PTA is calculated as the mean for the frequencies 500 - 1,000 - 1,000 - 2,000 Hz (by adding the threshold value for 1,000 Hz twice). The AAO-HNS classification adds a fourth frequency, 3,000 Hz, but in its European version this fourth frequency is 4,000 Hz (PTA2), and this same frequency is used for the Tokyo classification. SDS are quantified in terms of the percentage of correctly recognized words and, in the WRS classification, this is the only criterion used to distinguish between four different classes of increasingly severe hearing function. The term “speech discrimination” would be inappropriate in its current usage because discriminating involves drawing a distinction between pairs of stimuli, whereas vocal audiometry for the purposes of classifying a patient’s hearing involves repeating open sets of words from a list of numerous different items. It is therefore more appropriate to speak of word recognition scores (WRS).

Vocal audiometry can be used to assess speech detection (SDT), perception (SRT) and intelligibility thresholds, but it also enables us to examine the complete intelligibility function, which takes the shape of an “S” in Italics on the audiometric graph, in normal-hearing individuals at least. Properly conducted with an adequate number of stimuli, vocal audiometry gives us a precise idea of a patient’s speech perception in quiet, and can point to possible distortion phenomena. It is not one of the variables considered in today’s hearing classifications, however.

When recording WRS, it is not clear what intensity should be used to present the verbal message. Normal-hearing subjects generally reach a maximum intelligibility for speech already at an intensity of between 25 and 40 dB SL (25-40 dB above the tonal threshold expressed in PTA). That is why the WRS (defined as the maximum percentage of correctly repeated words) is often measured at 40 dB SL, presenting the word list at a fixed intensity. Some laboratories use an intensity 40 dB above the speech detection threshold (SDT + 40), instead of the PTA, probably obtaining significantly different results. In fact, PTA does not coincide with a degree of speech detection, as seen in Table 4.1.6.II.

On the other hand, patients with hearing loss are more likely to reach their WRS at the discomfort threshold minus 5 dB (uncomfortable listening level [UCL] - 5 dB) or, more rarely,

at the maximum comfort level (MCL). Some authors have used verbal material at an intensity of 40 dB above the SRT (speech reception threshold), i.e. 40 dB above the intensity at which patients correctly repeat 50% of the words they hear. There is clearly a marked discrepancy between the various measurement methods, and this makes it difficult to compare published data. There can be significant differences, not only in WRS scores, but also in the standard deviation (SD) of test-retest differences. It has been calculated that the average test-retest difference in WRS drops from -3.63% at 10 dB SL to 0.05% at 40 dB SL. The test-retest SD likewise falls gradually from 10.8 at an intensity of 10 dB SL to 5.6 at 40 dB.

Proposal for a full battery of audiological tests

A battery of tests - including not only tonal audiometry, vocal audiometry and ABR, but also the Matrix test, and a temporal discrimination test, could be more useful in clinical practice. The Matrix test is a form of vocal audiometry with competitive noise that automatically measures the adaptive type of s/n needed to obtain 50% of correct answers, which represents the speech perception threshold (SRT). Matrix tests generally use 20 syntactically correct, but semantically unpredictable sentences. The five words in a sentence are extracted from a 50-word matrix, so there are 10 alternative words for each position in the sentence. The answers are on the open list. Up to a patient PTA of about 47 dB HL, the SRT is measured with noise; in cases of more severe hearing loss, the message is necessarily presented in quiet. In the former case, the primary message is presented against a fixed noise at 65 dB and an automatic standard adaptive method is used ¹⁵.

The advantages of the Matrix test lie in the computerized analysis of the answers (which reduces the risk of operator error), and the automatic calculation of the slope of the curve at the threshold. It is a method used in many countries, but the speech material is standardized for each language, and perfectly balanced and calibrated, so test results are comparable across different languages. The adoption of laboratory norms is strongly recommended as this enables data to be compared with those obtained elsewhere.

As reported in Table 4.1.6.II, the SRT in quiet is generally the same as the PTA. Differences between a patient’s PTA and SRT may be secondary to extrinsic and/or intrinsic causes. The former include calibration errors between the tonal and verbal stimuli, and stimulus presentation or test recording errors. The latter may involve patients’ unwillingness to cooperate or inability to understand the task, alterations in their synchronization and neural speed conduction, auditory processing anomalies or impairments in their cognitive, memory or attentional functioning, as well as a steeply sloping audiogram. In such cases, it would be better to calculate the PTA only on the two best frequencies (between

Table 4.1.6.II. Correlation between PTA, SRT and SDT in dB HL.

PTA	Expected SRT	Expected SDT
0 dB HL	From -8 to +6 dB HL	From -20 dB to -6 dB
25	17-31	5-9
40	32-46	20-34
67	59-73	47-61

500-1000 and 2,000 Hz). In our initial experience, a marked discrepancy between PTA and SRT is likely in neuroma secondary to dyssynchrony and a reduced conduction velocity, and it seems to correlate with a worse prognosis after HPS. Inter-individual variability is unfortunately high and our findings are not yet significant.

Temporal resolution is generally measured by presenting three signals, one lasting longer than the others, and asking the subject to identify the more persistent signal. Gap detection is another test of time-related discrimination. The stimulus used for gap detection is generally a pair of noises separated by a very short interval of variable duration. Subjects are asked to say whether or not they perceive a gap, and the shortest discernible gap corresponds to their gap detection threshold. Though our data are not statistically significant, we have seen a tendency towards a correlation between temporal discrimination test results and the prognosis after HPS.

Conclusions

The correlation between a good initial hearing and a better preserved hearing after surgery has proved statistically significant in large case series, but audiological tests are of limited value in predicting the outcome after HPS in individual patients. A battery of tests that includes speech audiometry with competitive noise and time discrimination tests may be more sensitive and specific, and consequently more useful in clinical practice. We have already noticed a trend towards an association between the results of Matrix and temporal discrimination tests and the prognosis for patients undergoing HPS. The currently-used classifications of hearing preservation all have significant weaknesses. The potential benefit of CI in cases of SSD is also still a controversial issue, and it is not easy to adopt recently-published protocols in clinical practice. The functional outcome of CI is better when not only the nerve, but the whole peripheral auditory system has been preserved.

Early surgery aiming for hearing preservation, and subsequent CI in the event of HPS failing, is probably a better solution than either taking a wait-and-see approach until auditory function deteriorates and then referring patients for CI surgery, or opting for translabyrinthine surgery with simultaneous CI in patients who still have a good hearing function.

4.1.7. Vestibular schwannomas and cochlear implant

E. Piccirillo, G. Piras, M. Guidi, D. Vlad, M. Sanna

Vestibular schwannoma (VS) patients represent a challenge both from surgical and audiological points of view. Whichever modality of management is chosen, the chances of preserving serviceable hearing in the affected ear in the long term are

small ¹. Even when utilizing hearing preservation surgery, the chances of maintaining a social serviceable hearing in the short term range from 0 to 37% in the most experienced hands ^{2,3}. Patients with neurofibromatosis type 2 (NF-2) or VS in the only or better hearing ear deserve a separate consideration, as they are at special risk of developing bilateral anacusia, either as a consequence of treatment or from the natural course of the disease ⁴.

Cochlear implantation (CI) has recently emerged as a reasonable therapeutic option for patients with bilateral VS or sporadic VS in the only or better hearing ear, when anatomical integrity of the cochlear nerve during tumor excision is maintained. Since Hoffmann reported the first case of ipsilateral CI in a patient with NF2 ⁵, approximately 85 cases have been reported ^{6,7}. In addition, many case series have been published regarding the role of CI in patients with a VS in the only hearing ear ⁸. Results of ipsilateral CI in NF2 patients and VS in the only hearing ear are promising. Most patients benefit at least from sound awareness and aid lip reading, with many of them achieving open-set discrimination ability. In certain cases outcomes are comparable to those of post-lingual implanted non-tumor patients.

Surgical procedure

VS resection is performed by a modified translabyrinthine approach (MTLA) (Fig. 4.1.7.1) associated with posterior tympanotomy for CI. Alternatively, MTLA can be associated with middle ear obliteration and removal of the posterior wall of the external auditory canal (EAC) with blind sac closure of the EAC to avoid CSF leakage or to simplify the insertion of the array into the round

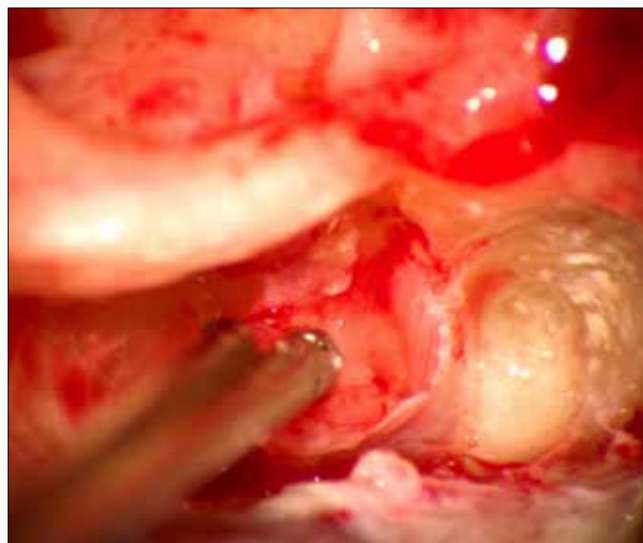


Fig. 4.1.7.1. Tumor removal through a modified translabyrinthine approach with middle ear obliteration.

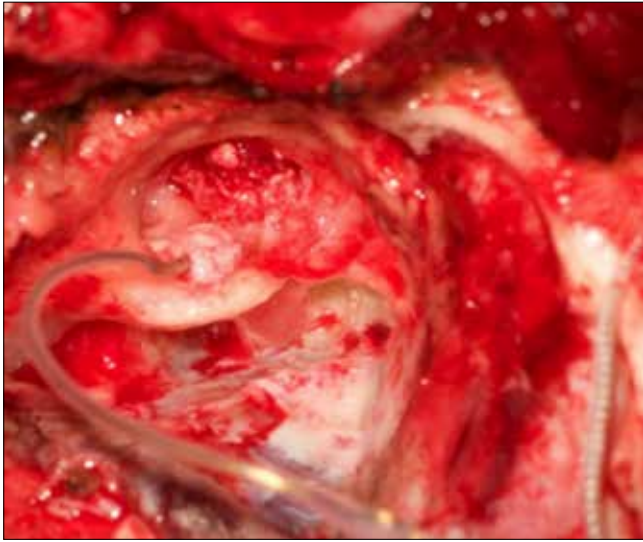


Fig. 4.1.7.2. Array insertion through the round window.

window (Fig. 4.1.7.2). We perform a single-stage technique in order to avoid the risk of cochlear ossification following VS removal. The surgical incision used is an inverted S shape with a superior extension. Intraoperative X-ray with Stenvers reconstruction confirms the correct positioning of the intracochlear electrodes. Post-operative CT scan can confirm the exact position of the array and the absence of intracranial complications (Fig. 4.1.7.3). CI activation is

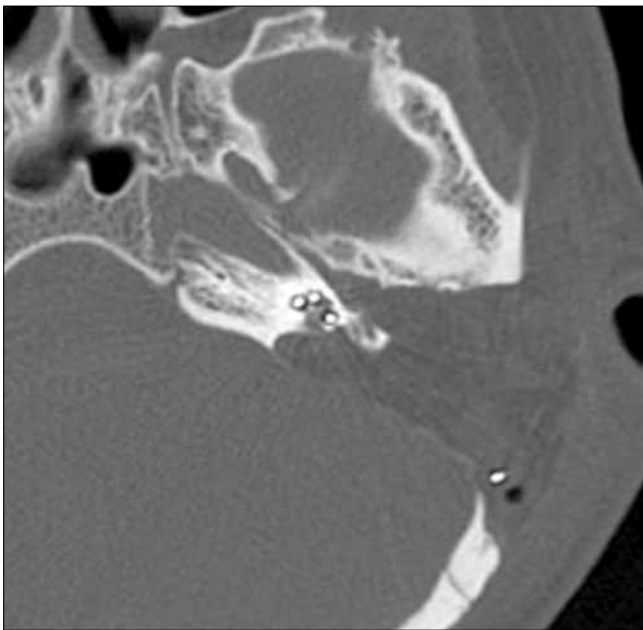


Fig. 4.1.7.3. Post-operative CT scan confirms the correct position of the array. The surgical cavity is filled with abdominal fat.

then performed on the first postoperative follow-up visit 4 weeks after surgery.

Indications and audiological protocol

Indications for VS resection and simultaneous CI are:

- intracanalicular tumor with limited extension to the cerebello-pontine angle ($\leq 0,5$ cm);
- intracanalicular tumors with no enlargement of the internal auditory canal (IAC) or invasion of the cochlea.

Intraoperatively, after VS removal the CI integrity is evaluated through:

- surgeons' subjective evaluation of the vascular supply and anatomical integrity of the cochlear nerve (CN);
- electrophysiological tests for the evaluation of the CN integrity: e-ABR, e-CNAP with a dedicated intracochlear test electrode inserted into the scala tympani and stapedial reflex. All these parameters are matched each other in order to decide if to perform CI.

Once the decision has been taken, CI is performed through a posterior tympanotomy.

Outcomes

In 3 previous studies⁴⁸⁹ we analyzed results of simultaneous VS removal and CI in different clinical situations.

CI in in patients with sporadic VS in the only or best hearing ear and in patients with NF2

Most patients undergoing cochlear implantation in the same side of a VS, either after surgical removal or after RT treatment, benefit from their device and are users. In a multicentric study of 15 patients⁴, closed-set discrimination was possible in 86% of the patients with a mean discrimination score of $70 \pm 38\%$, whereas open-set discrimination was achieved by 64% of patients with a mean postoperative score of $41 \pm 33\%$. At the last follow-up, 10 out of 15 patients were CI users. Interestingly, no difference was found between the NF2 and the sporadic VS groups in terms of audiological outcomes.

Hearing results after implantation in an ear with VS vary dramatically as demonstrated in previous studies¹⁰. Several prognostic factors have been proposed, including: duration of deafness, prolonged time between VS resection and implantation, cochlear ossification, and hearing in the contralateral ear.

The presence of contralateral residual hearing has been stated as a negative prognostic factor for cochlear implantation in patients with VS. Some authors¹⁰ have suggested that integration of the signal from the CI with the contralateral natural hearing may be a difficult task for some patients.

Variability in auditory performance depends ultimately on the status of the cochlear nerve. The mechanisms underlying hearing loss in patients with VS include vascular compression of the internal auditory artery, intratumoral bleeding, biochemical changes in the inner ear, and direct

compression of the cochlear nerve. Surgery may also cause mechanical or thermal injury of the cochlear nerve or of the labyrinthine artery. It has been suggested that a vascular compromise causing hearing loss may lead to successful outcomes following CI, whereas significant neuronal injury due to tumor growth, RT or surgical trauma may be associated with poorer outcomes¹⁰. In recent years different electrophysiological tests have been used to determine intraoperative candidacy for CI. Nevertheless, positive responses do not ensure good CI performance whereas patients with negative responses may obtain some benefit from the device. Therefore, the decision of implantation is usually taken on an anatomical basis.

The presence of a VS in the only or best hearing ear represents a clinical challenge.

The main difficulty in these cases is to decide the optimal time for therapeutic intervention. Tumor resection may lead to bilateral total deafness, whereas a wait and scan policy may lead to tumor growth, VIII nerve compression, and deterioration of hearing. Cochlear implantation appears as a reasonable option for these cases. Deciding whether to implant first the deaf side or the tumor side is a difficult task, which must be discussed with the patient. In a previous study⁸ on ten patients with VS in the only hearing ear and cochlear implant on the other side, three patients reported a remarkable increase in their CI performance after tumor removal, thus what implied loss of hearing in what had been their only hearing ear. This could be explained by the fact that the auditory cortex gives precedence to the best hearing pathway, or that the improvement of the deprived auditory pathway via electrical stimulation is hampered by the normal hearing. So, once the hearing starts to deteriorate, the performance of the CI seems to improve dramatically.

Both strategies can be considered. As a general policy, in a deaf ear with no contraindications and no tumor it seems more reasonable to implant this one first, before VS removal. However, a long duration of deafness and a deterioration of hearing on the tumor side hearing may be a valid reason to implant the tumor side first. In any case the patient should be informed about both possible approaches and discuss the pros and cons with the surgeon.

Conclusions

Cochlear implantation in patients with bilateral VS or VS in the only or best hearing ear may be an effective support for communication, providing open speech perception in selected cases. In light of our results and data from previous studies, cochlear implantation should be considered as the default strategy in VS patients with an intact ipsilateral cochlear nerve. Proper preoperative counseling and realistic expectations are mandatory. Although it is difficult to establish recommendations or protocols, even in patients with NF2 and large tumors, the possibility of sparing the cochlear nerve should be considered. Unfortunately, to date there are

no electrophysiological tests that can be really predictable of CN integrity. In case of anatomical and vascular preservation of CN integrity, CI should be preferred to ABI even in case of doubtful electrophysiological data, due to the lower hearing performance¹¹.

4.1.8. The hearing-focused therapy in acoustic neuroma: hearing preservation surgery, hearing rehabilitation with CI, observation

E. Zanoletti, D. Cazzador, L. Girasoli, C. Pavone, L. Denaro, D. d'Avella, A. Martini, A. Mazzoni

Introduction

The best management of small acoustic neuroma in patients with well-preserved hearing is still a debated matter. While different therapies provide similarly good results in terms of control of disease, neurological and facial nerve function, hearing loss is not avoidable in the majority of cases. Unilateral deafness is associated with loss of speech understanding especially in noise, lack of directionality of sound, chronic daily fatigue, and a loss of quality of life, and thus outlines the problem of prevention and rehabilitation of hearing.

Observation, hearing preservation surgery (HPS), traditional surgery and radiotherapy are the available options, but their impact on hearing preservation is different. The current debate is between observation and HPS in small acoustic neuroma with good hearing, as well as the role of cochlear implant to rehabilitate hearing in case of deafness due to natural course of the disease or its therapy.

The hearing-focused approach is a multi-optional strategy adopting the treatment with the best chances to preserve or rehabilitate hearing, with all the available options. Observation, hearing preservation surgery, hearing rehabilitation with cochlear implant after translabyrinthine surgery or in case of HPS failures, are all to be considered and must belong to the cultural and technical background of the oto-neurosurgical team. Radiotherapy is not considered a method to prevent hearing loss.

Methods and results

Our recent experience of hearing focused approach in small acoustic neuroma involved careful evaluation of hearing at the diagnosis as well as other tumor parameters. The choice of therapy which followed was a balance between the different available options and the patient's will.

Our ongoing-series¹ included all the currently available therapies, i.e. observation (O), radiotherapy (RT), HPS, and conventional surgery, which were used according to the guidelines in Table 4.1.8.I. HPS replaced O when it had a high probability of success, e.g. in patients with the mentioned good hearing at diagnosis.

Table 4.1.8.I. Sporadic small acoustic neuroma: hearing focused management (from Martini et al. 2017¹⁹, mod.).

Acoustic neuroma size (mm in the CPA angle)	Decision factors	Treatment
< 10 mm	Good hearing (< 30 dB, > 70% SDS, normal or slightly modified ABR)	Hearing preservation surgery or observation* (HPS failures: rehabilitation with CI as a post-operative option)
	Good hearing (< 30 dB, > 70% SDS, normal or slightly modified ABR) + surgical risk/unwillingness to undergo surgery	Observation*
	Poor hearing (> 30 dB, < 70% SDS)	Observation* or surgery (+ hearing rehabilitation with CI)

*: active treatment (surgery or RT) in the event of tumor growth to > 15 mm, or vertigo, or VII cranial nerve impairment.

Homogeneous O and HPS groups of “small tumor and good hearing” were available for comparison. Hearing was measured according to the Tokyo classification². Outcomes measures to be compared were: the outcome of O, including failures leading to active therapy; the results of HPS; the time course of hearing function in O vs HPS; the time course of hearing function after secondary RT.

At the diagnosis, O was adopted in 71% of cases, HPS in 22%, excision via a translabyrinthine approach in 7%.

The O approach failed due to tumor growth in 28% of cases, over a median period of 25 months (range 9-48 months): 25% were switched to active treatment (surgery in 20%, radiotherapy in 5%), while O continued for 3%. The tumors submitted to RT showed no further growth, but the only case with good hearing at diagnosis was no longer in class A after 27 months. In the group under O with class AB hearing (24 cases), a decline in hearing was evident in 42% of cases (10 cases) over a mean follow up of two years. The group of cases treated with HPS, as a first choice or after a period of O, had two different outcomes depending on tumor size and hearing function. When favorable factors were present, i.e. tumor less than 10 mm in size in the CPA, hearing function of at least PTA 30 - SDS 70, with normal or slightly altered ABR (Auditory Brain Response), hearing was preserved (Tokyo class AB) in 77% of cases, with an overall 85% of cases of serviceable hearing (Tokyo class ABC). The failure rate was 15%, with poor hearing or deafness, but in the subgroup whose hearing function and tumor size were even slightly outside the favorable limits, the success rate was 33%.

The decline in hearing function in the O vs HPS groups was as follows:

- the patients with good hearing submitted to O showed a hearing deterioration rate of 42% after a median follow-up of 25 months (range 9 to 48 months), class A-B hearing was thus maintained in 58% of cases;
- among the cases in the HPS group with favorable factors (tumor size and hearing function), failures (class C-F) occurred in 23% of cases, while 77% of cases preserved a good hearing function in the short term. After a mean two years of follow-up (range 9 to 78 months), 1 patient's hearing

had deteriorated (from class A to C), and the rate of preserved class AB hearing was 69%, class A was lost in 10% of cases.

Discussion

The two groups of O and HPS were homogeneous in terms of hearing parameters, but the choice of O or HPS was made by the patient. In principle, O afforded a better hearing preservation rate than HPS in the short term because of the early hearing loss when surgery fails. The progressive decline in hearing function under O gradually led to much the same rate of hearing loss for both O and HPS over time: after two years of follow-up, the rate of preservation of the “good” hearing function was 58% in the O group and 69% in the HPS group. 90% of the hearing preserved cases maintained their hearing after two years. The longer follow-up which is required to evaluate the natural course of hearing during observation and the stability of the preserved hearing after hearing-preservation surgery will help to understand which options is more hearing sparing over time. Similarly, hearing rehabilitation with cochlear implant in case of tumor-induced or surgical-induced deafness would probably expand its indications.

HPS aims at the preservation of an intact cochlear nerve, which in case of failure will be able to receive a cochlear implant, whereas translabyrinthine surgery involves postsurgical deafness. In both cases this does not prevent hearing rehabilitation with cochlear implant, which is a fact today and changes the possibilities of therapy of vestibular schwannoma.

Options of therapy

Observation is believed to offer the best chance of preserving long-term hearing and combines with the fact that the majority of small tumors spontaneously do not grow or stop growing. The wait-and-see policy, however, is clearly associated with two issues: hearing inexorably declines and, when partially preserved, it is of poor quality.

In a representative paper², observation for intrameatal tumors is associated with a progressive hearing decline over the years, with a long-term good hearing preservation rate of 17% at ten years. In the most favorable condition of patients

with intrameatal tumors and a SDS of 100%, hearing was reportedly preserved in 73% of cases at 10 years, with a SDS > 70%, but there is no mention of the sound level at which this speech discrimination was achieved.

Whether an early diagnosis can avoid the patient any further hearing loss with currently-available therapies is the object of debate in literature, with such diverging statements: “Early risk of deafness is likely to be greatest with microsurgery, followed by radiosurgery and observation, but the greatest number of serviceable hearing years comes with observation compared with proactive treatment”^{4,5}. HPS has “predictable and satisfactory results”⁶. “The postoperative preserved hearing can be considered durable hearing preservation as it is unlikely to change markedly”⁷. Small tumors in patients with good hearing are “preferably observed” and only submitted to radiotherapy in the event of growth⁶. The spontaneous arrest in the tumor’s growth and the long-term hearing preservation enabled by observation alone “makes it the benchmark with which every other therapy should be compared”³. The present report moves from this comparison recommended by Kirchmann³.

A Danish study³ on observation reported that good hearing (class A) was preserved at 10 years in 17% of cases (5/29), and class A-B hearing in 34% (25/75 cases). The hearing loss in these two groups amounted to 83% and 67% respectively. The subgroup of 27 cases with SDS 100% at diagnosis retained a remarkably better long-term hearing, with the reported average PTA of 46 dB and a SDS of 73%, which coincides with AAO-HNS class B.

Radiotherapy appears to be effective in stopping tumor growth⁸, with a still unknown rate of success in growing vs non-growing tumors^{9,10}. Hearing is preserved in the short term, but declines inexorably in the longer term, with only a 23% rate of preservation of good hearing at ten years^{4,5}, 24 and 12% at 10 and 15 years respectively¹¹ according to recent reports. Hearing preservation surgery (HPS) is attributed such different success rates¹² that comparison with other therapies is possible if only the subcategory of small tumors is considered¹³⁻¹⁵.

The option of hearing rehabilitation with cochlear implant

In recent years the indications to the cochlear implant (CI) have extended also in vestibular schwannoma, if the cochlear nerve is preserved. Some authors propose positioning the CI with the intent of hearing recovery without the surgical removal of schwannoma itself, or as rehabilitation after radiotherapy. In our experience, we consider the placement of CI in vestibular neuroma only in case of failure of HPS or in translabyrinthine surgery with cochlear nerve preservation. Anatomical preservation of the cochlear nerve during the microsurgical removal of a small tumor can be more or less difficult; the experience in hearing preservation surgery as well as the use of electrophysiological intraoperative

monitoring can help the functional results of a well-handled cochlear nerve. If hearing is lost, a cochlear implant is indicated. Translabyrinthine tumor resection with hearing nerve preservation in combination with cochlear implantation can be performed as a single-stage procedure or staged surgeries. The risk of early partial cochlear fibrosis after translabyrinthine resection of vestibular schwannoma can affect more than half of patients¹⁶; in order to allow hearing rehabilitation, it is advisable to insert a dummy electrode carrier or performing synchronous cochlear implantation.

Although cochlear implantation is possible in both bilateral and sporadic schwannoma, most series analyzing audiological results include only NF2 patients and do not specify the method to test the speech recognition. The extensive and recent review by Lloyds¹⁷ on hearing outcomes in NF2 showed a speech discrimination score in quiet without lip reading equal to 42.2% in 21 cases with CI after failed HPS and 38.2% in 16 cases with CI after cochlear nerve preserving translabyrinthine surgery. The status of the contralateral ear, as well as the methods of testing are important when measuring the cochlear implant outcome.

It seems that in sporadic VS the audiological outcome is better when compared to NF2. The CI performances between NF2 and sporadic VS groups have been analyzed in a recent multi-center study¹⁸: in CI-only condition, 71% of patients with sporadic VS achieved open-set discrimination (mean SDS = 55.8%), whereas only 50% of patients with NF2 achieved open-set discrimination (mean SDS = 30%).

Personal experience of hearing rehabilitation with CI

In our experience of 14 patients with CI after VS surgery, with a minimum follow-up of one year, the percentage of patients achieving open-set discrimination was 60% for the sporadic group and 22.2 % for the NF2 group. The CI was performed in a heterogeneous group of patients: 6 cases was planned in translabyrinthine surgery and 8 cases in HPS failures. The single-side-deafness patients who were implanted were NF2, the other cases of sporadic tumors were patients with poor contralateral hearing. No difference was found in terms of audiological outcomes between HPS group and cochlear nerve-preserving translabyrinthine surgery group. It is evident that the methods of outcome measures for cases with any contralateral hearing are different, and differently should be interpreted when judging CI results.

Several prognostic factors for hearing results after implantation in VS have been proposed, but the current literature shows conflicting results and lack of evidence. Some studies have investigated preoperative hearing, duration of deafness, tumor size, surgical approach, timing approach (synchronous vs staged), contralateral hearing, status of the cochlear nerve¹⁸.

In our philosophy, whenever possible, hearing preservation comes first and hearing rehabilitation only if poor hearing

is already present at the diagnosis or in cases of failure of HPS. In principle, no case of small tumor with good hearing is addressed primarily to a translabyrinthine approach and synchronous cochlear implant. It is a fact that cochlear implantation during or after tumor resection¹⁹, both in cochlear nerve-preserving translabyrinthine approach and in failures of HPS, is a valid option for hearing rehabilitation. This is particularly important in the perspective of NF2 patients, where “cochlear implantation rather than auditory brainstem implantation should be used whenever possible as this offers significantly better auditory outcomes”²⁰.

Conclusions

Early imaging today allows diagnosis of small vestibular schwannoma with good hearing. But does early diagnosis mean better prognosis for the patient? In principle, a better prognosis is achieved when no further losses are to be expected after diagnosis. There is a general consensus that the currently available therapies offer similarly good results concerning neurological losses, facial nerve preservation, and cure or control of the disease, but hearing function generally suffers a more or less severe deterioration. Hearing loss, or deafness, is therefore the residual morbidity confronting the therapy or abstention of therapy of an early diagnosis of small vestibular schwannoma.

Within the weaknesses of the clinical studies, including our own experience, due to referral and selection biases, the comparison between the O and HPS groups shows that:

- At short term, observation offers a better hearing function than HPS, because the latter presents cases with immediate postoperative hearing loss.
- The course of hearing deterioration is inexorable under observation as it reflects the natural history of the disease. The outcome of HPS is more durable, in favorable series with good results, despite some decline in hearing function over time, but pays the price of the immediate postoperative failure. The hearing/time diagram for observation versus HPS shows a convergence after around two years, then the decline in hearing function continues at a faster rate under observation. The difference between the two options becomes considerable at 5 and 10 years.
- Patients with SDS of 100% at the diagnosis maintain high levels of speech recognition⁹, although only their mean PTA (0.5 to 4 kHz) can qualify the SDS and should always be reported to assess the quality of preserved hearing. Those outcome measures which disregard the PTA are not representative.

Our experience has reached some provisional indications¹ as shown in Table 4.1.8.I, which suggest that active treatment with HPS, unlike observation alone, can offer a better chance of mid to long-term hearing preservation when favorable parameters are present. In case of failures, rehabilitation with cochlear implant, or hearing aid when hearing is still

present, is feasible. When there are no favorable conditions at the diagnosis for hearing preservation surgery, observation alone is still the best provisional option.

4.1.9. Current molecular knowledge on sporadic VIII cranial nerve schwannoma

G. Marioni, N. Favaretto, A. Martini, E. Zanoletti

Introduction

The last 30 years have seen a rising incidence of VIII cranial nerve (CN VIII) schwannomas, involving smaller tumors¹, less severe hearing loss at diagnosis, and more patients diagnosed at an older age². These findings are presumably due to more accessible high-quality contrast-enhanced imaging, and more widespread screening protocols for asymmetric sensorineural hearing loss². Recent research set the incidence of CN VIII schwannomas at 1.09/100,000 person-years from 2004 to 2010 based on the US Central Brain Tumor Registry, and at 1.1/100,000 in 2004-2011 based on the Surveillance, Epidemiology and End Results program³. As more vestibular schwannomas are diagnosed early on, there are more patients with good hearing. Our understanding of the natural history of these tumors has changed over time, and has modified their clinical management. The options of therapy range from active treatment, with traditional surgery, hearing preservation surgery or radiotherapy, to a wait-and-see approach⁴.

Molecular changes occurring before any visible morphological changes are responsible for a neoplasm's biological behavior and prognosis. Ideal molecular markers should be strongly related to the tumor's biological/pathological features and behavior, and easy to assess with a standardized test. In clinical practice, such markers should have a prognostic role, predict the efficacy of specific treatments, and serve as therapeutic targets. Among the issues in CN VIII schwannoma management today, the clinical use of tumor biomarkers is an intriguing but still scarcely explored option⁵. This brief critical review explores the available knowledge on molecular markers involved in the biology of sporadic CN VIII schwannomas that show clinical and prognostic potential.

The Merlin gene

Merlin is a tumor suppressor protein encoded by a gene on chromosome 22q12.2. Sequence alignment revealed its significant homology with a family of proteins including moesin, ezrin, radixin, talin, and members of the protein 4.1 superfamily (or ERM family)⁶. Merlin is mainly localized on the plasma membrane and interacts with several membrane proteins. It exerts its tumor suppressive effects on multiple mitogenic signaling pathways by modulating interaction with growth factor receptors⁷. Merlin turns off the YAP/TAZ-mediated expression of genes involved in proliferation and anti-apoptosis⁸. In surgical specimens from 36 consecutive sporadic

CN VIII schwannomas, Martini et al.⁵ found a significant direct correlation between TAZ expression and tumor volume calculated with a Multi-Planar Reformation Computer Volume application on latest preoperative contrast-enhanced MRI.

Merlin gene silencing is a molecular feature shared by unilateral sporadic vestibular schwannomas and bilateral vestibular schwannomas associated with NF2. In sporadic cases, somatic bi-allelic merlin gene inactivation seems essential to tumor formation⁹. Merlin gene mutations consist of insertions, deletions, and single-base substitutions resulting in frameshifts and nonsense mutations. They mainly prompt the synthesis of truncated proteins^{9,10}. NF2 gene inactivation results in total merlin loss, and has been detected in 27% to 61% cases of sporadic vestibular schwannoma¹¹.

There is a strong interplay between merlin, p53 (a classic tumor suppressor gene), and MDM2: p53-MDM2 dysregulation mediates merlin-deficient tumor growth, featuring nuclear accumulation of stabilized MDM2, and contributing to nuclear export of p53 for degradation. In vitro and in vivo studies revealed effects of the MDM2 inhibitor Nutlin-3 on schwannomas: it seems to block schwannoma cell proliferation via a cooperative recovery of merlin and p53, and a shuttling of both proteins from the cytoplasm to the nucleus¹². The p14ARF/MDM2/p53 pathway is crucial to normal cell cycle progression. There is nearly always loss of p14ARF expression at both mRNA and protein levels in human merlin-deficient sporadic CN VIII schwannoma, and p14ARF/MDM2/p53 pathway disruption is fundamental to their onset¹³. Merlin reportedly exerts some or all of its anti-proliferative effect by maintaining the expression of p21 (a negative cell progression regulator), and loss of p21 is a prominent feature of merlin-deficient schwannoma¹⁴.

DNA methylation

Sporadic vestibular schwannomas contain no functional merlin, though up to 40% of these tumors have an intact wild-type merlin gene. Aberrant methylation of the merlin gene promoter regions in schwannomas has been explored as a potential explanation for the lack of functional merlin. Methylation of other genes important to tumor onset, angiogenesis and apoptosis has also been investigated⁹.

Loss of heterozygosity

Several mechanisms may account for loss of heterozygosity (LOH), such as deletion resulting in loss of a chromosome segment, mitotic recombination, translocation, and gene conversion. LOH is a frequent feature of sporadic vestibular schwannoma, and therefore likely to be involved in its onset and maintenance⁹. On whole-exome sequencing, whole transcriptome expression profiling (mRNA-Seq), and mate-pair analysis on fresh-frozen tumor and matched peripheral blood leukocytes from 23 patients with sporadic vestibular schwannoma, Carlson et al.¹⁵ found 13 tumors with loss of one chromosome 22, 4 with copy-neutral 22q loss of

heterozygosity, plus 31 unique small NF2 gene variants (10 essential splice site, 11 frameshifts, 7 stop gain, 2 missense, and 1 in-frame mutation). Several other large chromosomal aberrations were discovered too, including 2 tumors with loss of a chromosome 21, 3 with loss of an X or Y chromosome, 1 with copy-neutral loss of heterozygosity in chromosome 15, and 1 with loss of 18p and 16q.

Other genes

There are few large studies on global gene dysregulation in vestibular schwannoma, but several focusing on selected genes⁹. Cayé-Thomasen et al.¹⁶ examined gene expression in human vestibular nerve versus sporadic vestibular schwannoma tissue (16 cases) using microarray technology, finding 87 probe sets (representing 78 genes) significantly up- or down-regulated in tumor tissue. Eight of the up-regulated genes are involved in cell cycle regulation, 6 in cell morphogenesis, 8 in cell development, 11 in cell differentiation, 6 in cell death, 13 in cell adhesion, 9 in extracellular matrix, and 50 in protein binding (overlapping occurring). In 16 sporadic vestibular schwannomas, Sass et al.¹⁷ investigated global gene expression concentrating on signal transduction pathways and functional molecular networks associated with growth. In total 109 genes were deregulated in relation to tumor growth rate. Specific genes involved in apoptosis, cell growth, and proliferation, e.g. neural cell adhesion molecule 1, Erbin, platelet-derived growth factor C, and phosphatidylinositol 3-kinase (PI3K), were dysregulated in fast-growing tumors. Fourteen pathways were associated with tumor growth, including PRPs, paxillin, integrin, P21-activated kinase (PAK) signaling, and myeloid cell signaling (TREM1). The functional networks generated underscored the importance of the PI3K family, among others. When Agnihotri et al.¹⁸ studied gene expression in vestibular schwannomas, they found PI3K/AKT/mammalian target of rapamycin (mTOR) signaling networks overexpressed. They tested this pathway for targeted therapy with the compounds BEZ235 and PKI-587, and the dual inhibitors of PI3K and mTOR both attenuated tumor growth in a preclinical cell line model of schwannoma (HEI-293). Pharmacological PI3K/AKT/mTOR pathway inhibition with next-generation compounds reduced cell viability and increased cell death in vitro.

Although CN VIII schwannomas grow relatively slowly, they need angiogenesis to progress beyond a certain size. Among multiple angiogenesis-stimulating factors identified, the best known is Vascular Endothelial Growth Factor (VEGF): it is expressed by vestibular schwannoma cells, and the degree of its expression has been correlated with clinical parameters such as tumor growth, volume, and microvessel density¹⁹. Anti-VEGF bevacizumab has been associated with a shrinkage of most growing vestibular schwannomas. Not all patients respond and hearing improvement is often transient, however, and there is no

direct evidence of the effects of anti-VEGF treatment on nerve function. Hence the need to clarify how anti-angiogenic therapy affects tumor-bearing nerve function ²⁰.

Conclusions

Merlin gene mutations are not found in all tumors, so other gene dysregulations, and post-transcriptional silencing probably play a part in CN VIII schwannoma pathogenesis and growth ⁹. For a rational choice of early surgery or a wait-and-scan policy, we need further studies on larger prospective series to seek easily and non-invasively measurable biological factors influencing tumor proliferation ⁵. Strategies involving global gene expression profiling, whole genome sequencing and/or large-scale proteomic analyses seem appropriate in an effort to identify new molecular candidates for predicting tumor growth ¹⁷. A better understanding of CN VIII schwannoma molecular pathobiology may lead to novel targeted therapies capable of inhibiting the tumor’s growth, or even prompting its regression ^{9 21} while minimizing morbidity ⁶. The growing knowledge on the molecular biology will help the choice of therapy and has led to the first attempts of targeted medical treatment to prevent schwannoma growth.

4.2. Tympano-jugular paraganglioma

4.2.1. Treatment options for sporadic tympano-jugular paraganglioma (TJPGL)

A. Mazzoni, E. Zanoletti, D. Cazzador, A. Martini

TJPGL management may involve observation (O), radiotherapy (RT), and surgery (S) to achieve various degrees of tumor removal, from complete to deliberately incomplete, to partial. The choice between O and active therapy is driven by the need to strike the right balance between the morbidities associated with the two options. There is a set of converging criteria guiding this choice that relate to the function of the IX and X cranial nerves, the tumor’s growth rate, and the patient’s age (Table 4.2.1.I).

TJPGL is a slow-growing, largely benign tumor. It may spare or gradually damage the nerves in the area (usually the IX and X cranial nerves), causing pharyngolaryngeal paralysis. Compensatory mechanisms limit the disabling effect of this damage, whereas they are less effective when acute paralysis is caused by surgery on a normally-functioning nerve, especially in the elderly. This is why surgery is not recommended in older patients with no cranial nerve symptoms. The surgical loss of the IX and X cranial nerves is disabling at any age, and even the compensatory mechanisms that younger patients can acquire may deteriorate with aging,

as does the good facial function of HB class 2, when aging or other negative factors (such as dysmetabolism) take their toll on a “borderline” nerve function. The value of O is supported by the preceding considerations. In clinical practice ^{1 2}, O is indicated for patients with a normal IX and X cranial nerve function, unless they are young, in which case early tumor resection is believed to prevent more severe morbidity. Cases remaining under O are monitored using imaging and switched to active treatment in the event of IX and X nerve paralysis, or tumor growth extending to sites at risk, such as the petrous apex or cerebellopontine angle (CPA) Another factor in favor of O, regardless of any IX and X cranial nerve paralysis, is the surgical risk or short life expectancy related to patients’ age or comorbidities, even in the case of large tumors.

Surgery relies essentially on the infratemporal approach, type A (ITa), and seldom on the infratemporal approach, type B approach. It involves a transient facial paresis and closure of the external auditory canal, with loss of conductive hearing (though this will have already been caused by the tumor). The ITa approach affords the highest rate of complete tumor excision from the neck to the petro-occipital base, and to the c.p.a. The loss of one or more cranial nerves is frequently the price to pay for radicality on structures that may be the site of microscopic invasion. Closure of the external auditory canal, and depression of the auriculo-temporal area are unsightly side effects of the approach. It may be necessary to complete the ITa approach in successive stages when large tumors demand a wide opening between cerebellopontine angle and petrous-neck field. The suboccipital approach can be added to the petrous field in a second stage.

The role of surgical procedures involving deliberately incomplete (partial or subtotal) resections in an effort to preserve the nerves is not yet clear. It is difficult to predict the outcome in terms of nerve function, and its value awaits the test of time, as does the utility of RT on residual tumor.

Table 4.2.1.I. Criteria of therapy in sporadic jugular foramen paraganglioma.

Cranial nerve status	Growth	Age	Therapy
Normal	No growth	Any age	O
		< 40	S
	Growth	40-60	S* or RT
Paralysis	No growth	> 60	RT
		< 60	O or S*
	Growth	> 60	O
		< 60	S
		> 60	RT

*C3 class S is first option regardless cranial nerves function to prevent growth beyond petrous apex. Partial targeted Surgery in cases under O and tumor on facial nerve, or compressing the brain stem, or surfacing and bleeding in outer ear canal. *: age and/ or high surgical risk favor O or RT over S; O: observation; S: surgery; RT: radiotherapy.*

RT carries very little or no morbidity in the short term^{3,4}, but the follow-up in studies on its value has been judged too short for the type of lesion considered⁵. The few long-term reports^{3,6} are of dubious statistical significance due to the small samples involved, and modern imaging to assess tumor growth was not available in earlier reports⁴. Despite these issues, it is generally accepted that RT may stabilize tumor for a considerable period of time⁷, and can have a role in its treatment, especially in the elderly and cases of multifocal disease^{4,7}. That said, only time will tell just what part RT has to play in this setting.

Partial targeted surgery⁸ involves a limited tumor excision in cases previously under O. The resection targets portions of tumor in areas at risk, such as the Fallopius canal or the brainstem, or bleeding tumors growing in the external auditory canal. It can prevent impending damage to facial nerve or brain stem, or else repair actual damage to the facial nerve, or deal with hemorrhage. It enables a return to O afterwards, striking the right balance between the morbidity risk associated with active therapy as opposed to O. Very large intradural growths can pose a therapeutic quandary relating to the surgical dissection needed to deal with extensive neurovascular involvement, and the risk of acute brainstem compression by edema if the tumor is irradiated. A coherent use of the principles of skull base surgery can provide the solution in such cases. Extensive bone removal all around the dura to which the tumor is rooted enables a preemptive coagulation of the main blood supply to the tumor and the removal of an ischemic mass⁹.

In closing this overview, we wish to point out that the lack of randomized trials still prevents us from saying which is the most appropriate approach, surgery, RT or O. On the other hand, falling back on the popular concept of “surgery tailored to individual patients” can be misleading, unless this means combining expertise with available modalities, rather than resorting to numerosity to mask planning inconsistencies and biased case material.

4.2.2. Radical surgery in jugular foramen paragangliomas: indications and results

R. Pareschi

Jugular foramen paragangliomas (JFPs) are tumours that involve the jugular bulb with different relationships with the carotid artery and lower cranial nerves; JFPs are classified as type C according to the Fisch classification¹. In ¼ of the cases these tumors present an intracranial extension and are thus classified as Fisch type D. Open issues still remain concerning the treatment of JFPs, these regard their growth rate, the role of the radiotherapy, the wait and scan policy, the role and the indications of radical or partial surgery, the surgical approach, the long term results and the management of the facial nerve, of lower cranial nerves and of the internal carotid artery (ICA).

From January 1993 to March 2014, 257 patients affected by temporal bone paraganglioma referred to the ENT Department of Legnano Hospital (Milan). According to Fisch classification, 142 patients (55.3%) were affected by a Fisch type C or D JFPs and were treated with surgery; 28 (10.9%) underwent RT or a wait-and-scan policy because of their age (> 65) and/or poor general status, or because they refused surgery.

Only few reports are present in literature concerning the natural history of JFPs. According to the study of Jansen et al., approximately 60% of paragangliomas present an evidence of growth during follow-up with a median increase in dimension of 0.83mm/year after a mean follow-up of 4.2 years². Focusing our attention on our cases of JFPs, Fisch type C and D tumors were stable in 86.7% of cases after 5 years of follow-up, while this rate decreased to 60.0% between 5 and 10 years of follow-up. Prasad et al. reported similar results³. It is important to underline that there is a trend toward higher rates of tumor progression in patients who had a longer follow-up, in fact the tumor control rates dramatically slope down to 33.3% after more than 10 years of follow-up in the present study, and similar data have been reported by Carlson et al.⁴. Another important aspect is that some tumors have a faster growth rate, that can reach 2 mm/year. Patients that present JFPs before age 30 (about 15% of all cases) usually have faster growing tumors.

Radical surgery is the only treatment that permits to change the natural history of JFPs. Both preoperative angiographic evaluation and intraoperative bleeding do not show any difference when comparing irradiated and not irradiated tumors; nevertheless, RT makes the removal of the intracranial component of the tumor extremely difficult. In our experience, RT reported slightly better long-term rates of tumor control when compared with the wait-and-scan group. The downside of RT is the presence of new neurological deficits, which appear in 20.0% of patients whereas no cases of new CNs deficit were reported in the wait and scan group. It therefore seems reasonable to state that radiotherapy does not modify the natural history of JFPs (Table 4.2.2.I). It is important to underline how in literature, particularly for RT treated groups, tumors are rarely classified according to the Fisch classification. Usually, there appear to be reported based on tumor size, or according to the Glasscock-Jackson classification. The latter fact creates difficulties when comparing different treatment groups.

For selected cases, a conservative jugulo-petrosectomy could

Table 4.2.2.I. Tumor control rate for radiotherapy and wait-and-scan between 1992 and 2014.

Follow-up	Tumor control rate 1992-2014	
	Wait and scan	Radiotherapy
0-5 years	86%	92%
5-10 years	60%	69%
10-20 years	33%	38%*

*: 20% of new neurological deficit.

be performed. In our experience, the infratemporal type A approach of Fish (ITFA) was chosen as the elective surgical procedure in more than 90% of cases. Several approaches have been attempted in order to preserve the external and middle ear and protect the facial nerve, but the ITFA appears to be the only approach that guarantees a safe and complete exposure of the jugular foramen and of the intrapetrous carotid artery³. In our experience, this wide exposure allows a complete removal of the tumor in more than 90% of cases with a recurrence rate of 4.7% after total resection. Similar results are reported in literature with radical resection rates ranging between 72 and 100% and a recurrence rate from 0 to 28.1%⁵. From C1 to C4 tumors the chances to achieve a radical resection progressively slope down. C1 and C2 tumors are often radically resected (100% for C1 and 96% for C2) and the long-term tumor control is clearly superior to radiotherapy⁶. On the other hand, when treating C4 tumors, which present cavernous sinus invasion, persistent disease is always left at this level due to the high risk of ophthalmoplegia (Table 4.4.2.II), despite important advances in perioperative management, otoneurosurgical techniques and technologies in the last decades. Fisch's type D JFPs are tumors with an intracranial extension. The intracranial surgical resection in non-irradiated patients is usually relatively easy since the tumor is easily detachable from the intracranial neurovascular structures. This allows a complete resection of 100% of the tumor's extradural component and of 87% of its intradural component in our series. After radiotherapy instead, the tumor and dura become firmly attached to the brainstem and to the cerebellum, making further resection extremely dangerous. Considering the high risk of a growing intracranial tumor, the high rate of radical resection of the tumor's intracranial portion prior to radiotherapy, and the risk of post-radiation salvage surgery, an upfront surgical resection is clearly advisable.

The facial nerve (FN) is the main obstacle for a correct exposure of the jugular foramen and of the carotid canal. Its function is at risk in every surgical procedure for TJPs. The FN function must be evaluated with the House-Brackmann Scale (HB), because it is related with the morbidity of the palsy. Management of the FN includes simple exposure, a partial or complete mobilization or a segmental resection. In our series, 7.7% presented with a preoperative FN palsy. Postoperatively a HB grade I-II deficit was reported in 73.2% of patients. Consequently there was 19.1% of new FN palsy. The anterior rerouting of the FN (from the geniculate ganglion to the intraparotid main division branches) represents the key point of the infratemporal approach type A. This approach is, in our opinion, the gold standard for the management of jugular foramen tumors

Table 4.2.2.II. Rate of radical resection according to Fisch classification.

Class	C1	C2	C3	C4	D1	D2
Rate of radical resection	100% (62/62)	96% (51/53)	75% (15/20)	0% (0/7)	100% (20/20)	90% (14/16)

because it permits, with the delicate transposition of the FN, a wide exposure, the radical removal of the tumor, a good control of bleeding and the management of major vessels (i.e. ICA) and nerves. Radical removal of the tumor along with reduction of major postoperative complications are our goals. Following the rerouting of the FN, postoperative rates of HB grade I-II palsies ranged between 24% and 100% in extant literature, with most series ranging from 60% to 90%⁷. In our experience, at 1 year of follow-up, HB grade I and II palsies were reported in 69% of cases and 25% reported a grade III after FN anterior rerouting. Non-rerouting approaches permitted the preservation of the facial nerve function in all patients of the present series. A recent review of the literature reported HB grade I-II in 95% of the non-rerouting approaches at the cost of a significant increase of persistence⁷. Consequently, even if conservative approaches could be performed in selected C1 TJPs, the rerouting of the nerve allows an acceptable functional and cosmetic result in 69% of the cases and should be therefore always performed (Table 4.2.2.III).

The most frequently damaged CNs are the IX and X, with a pharyngo-laryngeal unilateral paralysis. Sudden deficit of preoperative functioning LCNs is the most feared complication since it is related with dysphagia, aspiration, and dysphonia. The position of the LCNs – covered by the medial wall of the jugular bulb – and the fact that TJPs usually arise from the superolateral aspect of the bulb make preservation of LCNs possible in small tumors. Particular attention must be given to the inferior petrosal sinuses, which run between the lower cranial nerves with several anatomical variations. Even if the internal jugular vein is ligated and the sigmoid sinus closed, the inferior petrosal sinuses continue to bleed and need to be packed with haemostatic agents. With this manoeuvre, even a simple compression of the nerves on the rigid walls of the jugular foramen could bring to a postoperative deficit. Consequently, whenever the jugular bulb is opened, a risk for LCNs palsy must be considered. The preservation of the function of IX and X CNs in C1 paraganglioma was 74% and 80%, respectively, in our series of patients. This rate dramatically slopes down to less than 20% for C2 paragangliomas. This is in agreement with literature reporting the overall incidence of one or more new postoperative lower cranial nerve (LCN) deficits between 2.8

Table 4.2.2.III. Postoperative facial nerve function.

House-Brackmann	Left in falloppian canal	Trasposed	Cut and sutured	Late palsy
I	100%	69%	0	0
II			0	0
III	0	25%	70%	0
IV	0	3%	30%	0
V	0	3%	0	0
VI	0	0	0	0

Table 4.2.2.IV. Postoperative neurological defects.

Class	VIII n.c.	IX n.c.	X n.c.
C1	80%	75%	80%
C2	35%	17%	25%
C3	0	0	0
C4	0	0	0

and 59%⁸. LCN primary dysfunction leads to alterations in swallowing, speech, and airway protection. Most patients often compensate with speech therapy, and better functional results are expected in patients with a preoperative palsy⁸. Careful preoperative consideration is necessary in elderly patients that need to undergo surgery. In this group of patients, rehabilitation of swallowing may be impossible when it is a result of the combined loss of these nerves⁹. With the cut-off of 65 years old, no patients in our experience reported ab-ingestis recurrent pneumonia, permanent tracheostomy or gastrostomy (Table 4.2.2.IV).

Preoperative evaluation of the efficacy of the collateral arterial circulation in case of deliberate or accidental ICA sacrifice is mandatory. Without any preoperative selection of patients the incidence of stroke after permanent occlusion of the artery ranges from 17% to 30%¹⁰ and mortality reaches 10%. Preliminary evaluation of the Circle of Willis without an endovascular procedure (Matas test)¹¹ is performed in all C2-3-4 cases. A preoperative balloon occlusion test of the ICA is not considered necessary. Only in the presence of a good cross filling, the patients will be scheduled for a balloon occlusion test of the ICA. This is indicated in case of involvement of the carotid wall by the tumor and/or if the tumor receives multiple vessel vascular supply from the ICA itself that cannot be reduced by the embolization. We performed a permanent occlusion of the ICA in 14 cases without any residual neurological deficit.

The endovascular stenting, in alternative to the PBO, is an attractive procedure although the risk of ICA rupture in case of wall vessel infiltration is still high, and the vascular flow from feeding vessels is not influenced by the stent¹². Consequently, when needed, the PBO of the ICA is preferable because, in our opinion, it increases the rates of radical resections and avoids accidental intraoperative ICA ruptures or postoperative pseudoaneurisms.

Conclusions

The management of jugular paragangliomas is challenging, highly controversial and evolving. Wait-and-scan management represents the default initial strategy for small- to medium-sized tumors and for all patients unsuitable for surgery. Radical surgery represents our choice in patients with small tumors (C1). For more advanced lesions (C2, C3, C4, D1, D2) we discourage surgery only in patients in precarious general conditions and/or older than 65. Over the last decade there has

been a shift to partial resection with staged radiosurgery, or to exclusive radiosurgery, but there is a need for more adequate follow-up.

4.2.3. Primary radiotherapy in paraganglioma: indications and results

L. Deantonio, M. Krengli

Introduction

Paragangliomas represent highly vascular neuroendocrine tumours arising from the extra-adrenal autonomic paraganglia, which derive from embryonic neural crest. They differ in their anatomic distribution and clinical presentation and can arise from either parasympathetic or sympathetic paraganglia. The majority of parasympathetic paragangliomas grow in the head and neck district. However, head and neck paragangliomas represent a rare entity, accounting for approximately 0.6% of head and neck tumours and approximately 0.03% of all tumours¹. They are in general benign, slow growing and non-functional. They can frequently involve the carotid body, the jugular bulb, the vagal ganglia and the temporal bone. Less than one third of paragangliomas have a malignant behaviour. This minority usually arise from carotid body and vagal nerve. The metastatic spread to regional lymph-nodes or less frequently to distant sites are the only indicators of their malignant behaviour^{2,3}.

Surgical resection or radiotherapy represent the loco-regional treatment options in case of head and neck paragangliomas. In general, surgery is the first-line therapy of choice for carotid body tumours and is selectively preferred in case of symptomatic bulky tumours. Moreover, surgery is more widely performed for other locations below the head and neck district and in secreting paragangliomas. In contrast, radiotherapy is the first-line option for jugular and vagal paragangliomas and is often employed in case of recurrence or persistence after non-radical surgery in relation with the anatomic challenges of the head and neck district^{4,5}.

A multidisciplinary evaluation is anyway highly recommended for paragangliomas, because of the clinical scenario and the various treatment options. A single-modality treatment should be encouraged in order to achieve long-term symptom recovery and high local control rates⁵.

The aim of the present article is to review the most recent literature data of radiotherapy in terms of local control and side effects and to discuss the role of radiation treatment in the management of head and neck paragangliomas.

Materials and methods

Literature search was performed by using the databases of Pubmed and Scopus. The key words “head and neck paraganglioma”, “paraganglioma”, “primary radiotherapy”, “radiotherapy”, “radiosurgery”, and “stereotactic radiation

therapy” were used for searching literature articles. We considered the papers published in the last 10 years. The relevance was assessed based on the numerosness of the sample size (at least 10 patients), the length of follow-up (median/mean of at least of two years), the completeness of analysis of technical data, and the outcome in terms of local control, survival and side effects.

Results

In total, 304 articles were found. The initial review was based on the title and the second one on the abstract. The articles that resulted inadequate regarding cohort size and follow-up or reported on duplicated cohorts were discarded. Finally, 14 articles fulfilled all inclusion criteria.

No randomized trials were found, and the reported results are based on clinical retrospective series.

We reviewed the 13-series including 575 patients treated with primary radiotherapy, 229 of which with stereotactic radiotherapy. In Table 4.2.3.I, we summarized the principal data of the selected studies.

For radiation treatment delivery, patients were immobilised with customized thermoplastic masks and personalized rest neck. Then, a 1 mm slice computed tomography (CT)-scan was performed and fused with T1- and T2-weighted sequences⁸. Target volumes were identified as follows: gross tumour volume (GTV) was defined according to the area of contrast enhancement on CT and magnetic resonance imaging (MRI) (Fig. 4.2.3.1). In case of fractionated treatment, clinical target volume (CTV) was defined by adding a 7 mm margin to the gross target volume along the main vessels. Planning target volume (PTV) was generated by adding a 3 mm homogeneous margin to the CTV. In case of radiosurgery, CTV corresponded to GTV, and a median margin of 3 mm was outlined to generate PTV, based on the machine used for delivery and on the accuracy of the immobilization system and imaging modality used to verify patient set-up^{8 16}.

In case of conventional treatment, a median dose of 45 Gy with standard daily fractionation of 1.8 Gy was adopted^{12 13 16}, while in case of stereotactic radiotherapy, a protocol mostly with dedicated machines (i.e. Gamma-knife and Cyberknife) delivered a median prescription dose of 12-18 Gy in a single shot (radiosurgery) or 25 Gy in 3-5 fractions^{7 8 15}.

For what concerns conventionally fractionated radiotherapy, Gilbo et al. reviewed their 45-year experience on 156 paragangliomas treated with external beam radiotherapy to a median total dose of 45 Gy, achieving tumour control in 96% of cases at 10 years, with no severe complications¹³. In terms of stereotactic radiotherapy, Marchetti et al. recently reported on 21 patients treated with Cyberknife⁹: paragangliomas with a median volume of 3.6 cc were treated with a single session of 12 Gy, while paragangliomas with a median volume of 16 cc received a total dose of 25 Gy in 3-5 fractions. At a median follow-up of 35 months, all

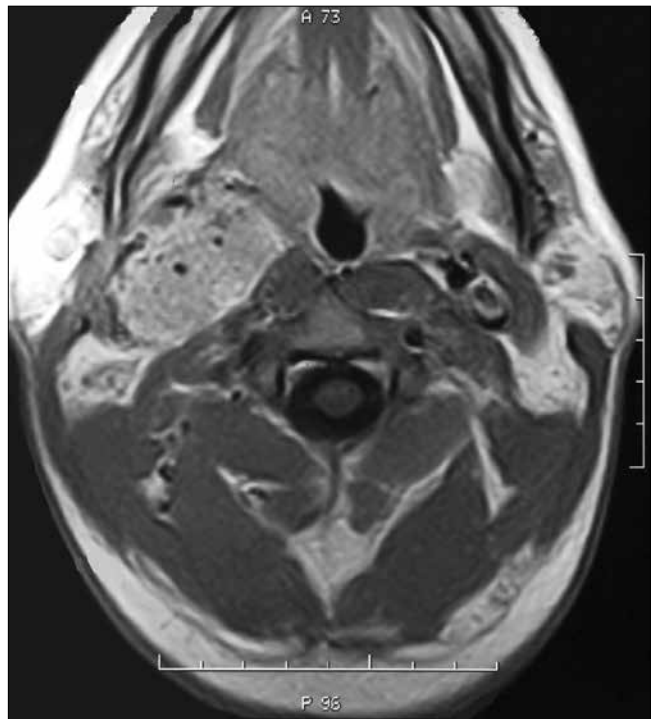


Fig. 4.2.3.1. T1-weighted magnetic resonance imaging showing the typical salt-and-pepper pattern of the malignant paraganglioma.

patients achieved tumour shrinkage or a stable disease and in 50% of patients symptom improvement was present.

In such benign tumours, disease control, generally defined as radiographic stability or decrease in size after treatment, was achieved in 96-100% of patients after a median follow-up time of 2-years. Moreover, clinical control, defined as improvement or no-change of symptoms, was reported by 60-100% of cases in the selected studies^{7 18}.

The risk of radiotherapy-induced toxicity was generally mild and manageable and long-term sequelae have been improved by modern radiation planning and treatment techniques. In this regard, the selected clinical series reported a low incidence of cranial nerves impairment (< 3%)¹². Moreover, Patel et al. showed that the risk of progression to non-serviceable hearing following radiosurgery was 9% at 1 year and 20% at 5 years⁷. A small recent study on fractionated stereotactic radiotherapy reported neither acute nor late toxicity⁸.

Discussion

Since paragangliomas represent rare benign tumours, all results are based on retrospective single cohorts. Although the power of the present studies does not allow to formulate strong statements, we may find some evidence that can help physicians in treatment decision-making on the following issues: radiotherapy modality with conventional fractionation or single fraction (SRS) or multiple fractions (FSRT), tumour

Table 4.2.3.I. Outcome using stereotactic radiosurgery, SRS.

Author	Class of evidence	N. pts	Origin	Technique	Median dose	Mean median V	Median/mean follow-up time	Tumour control	Symptom control %	Complications /toxicity
Cao 2018 ⁶	III	10 (6 exclusive RT)	Various	Proton beam	50.4 GyE	Nr	Median 24.6 months	100%	70%	50% G1 fatigue 30% G1 headaches 20% G1 dizziness 10% G1 dysphagia
Patel 2018 ⁷	III	85	Jugular glomus	GKRS	16 Gy	Median 7 cc	Median 37 months	Nr	60%	9% at 1 year
Tosun 2018 ⁸	III	12	Various	SRS CyberKnife	24 Gy/3 fr	Median 35.5 cc	Median 30 months	100%	100% (No clinical progression)	0%
Marchetti 2017 ⁹	III	21	Various	SRS CyberKnife	12 Gy 25 Gy/3-5 fr	Median 3.6 cc Median 16.1 cc	Median 46 months	100%	50% improved 30% unchanged	15%
Dobberpuhl 2016 ¹⁰	III	12	Jugular glomus	GKRS	15 Gy	8.42 cc	Median 27.6 months	100%	80%	1 case of facial paresis
Schuster 2016 ¹¹	III	14	Jugular glomus	SRS FSRT	15-18 Gy 3-7 Gy/3-15 fr	3.78 cc	Median 28.8 months	92.9%	Nr	Nr
Smee 2015 ¹²	III	34	Various	SRS EBRT	14 Gy 45 Gy/25 fr	< 3.5 cm > 3.5 cm	Median 3.5 years	100%	97%	3% c.n. deficit
Gilbo 2014 ¹³	III	131	Various	RT	45 Gy/25fr	Nr	Median 8.7 years	99% at 5 years 96% at 10 years	Nr	0% severe complications 20% mild complications
Galland-Girodet 2014 ¹⁴	III	130	Jugolotympanic, carotid body tumour Vagal glomus	RT	Mean 52.2 Gy	Nr	Median 7.6 years	96% at 5 years 85% at 10 years	70%	30% not severe
Chun 2014 ¹⁵	III	31	Jugular glomus	FSRT CyberKnife	25 Gy/5 fr	Nr	Median 24 months	100%	90%	G1-2 19% G3 0%
Dupin 2014 ¹⁶	III	66 (46 exclusive RT)	Various	EBRT	45 Gy	Median 17 cc	Median 57.4 months	100% at 5 years 98.7% at 10 years	Nr	Acute: G3 19.5% Late: G3 6.5% 2 cases secondary tumour
Chen 2010 ¹⁷	IIb	15	Jugular glomus	GKRS	Mean 14.6 Gy	Mean 7.4 cc	Median 35 months	80%	90%	20% neurological pulsity
Ganz 2009 ¹⁸	III	14	Jugular glomus	GKRS	Mean 13.6 Gy	Mean 14.2 cc	Mean 28 months	100%	100%	Transient facial palsy (1)

Pts: patients; SRS: radiosurgery; FSRT: Fractionated Stereotactic Radiotherapy; GKRS: Gamma-knife radiosurgery; EBRT: External-Beam Radiotherapy; Nr: not reported.

volumes, dose prescription, tumour control and clinical outcome, role of retreatment and risk of complications.

Based on the available data, a conventional fractionated treatment with a schedule at a median dose of 45 Gy is considered an optimal approach for primary treatment of larger paragangliomas or in case of residual/recurrent tumour after surgery^{13 16 19}. The safety of this approach is suggested by Gilbo et al. that did not report any severe complication in 156 treated paragangliomas with intensity modulated radiation therapy or conventional photon fields. Slightly higher late severe complications (6.5%) were reported by Dupin et al., but the authors analysed a smaller sample of 66 patients treated with 60Co-machine¹⁶.

In the last years, several studies reported tumour control outcomes similar or superior to those of conventionally fractionated radiotherapy by using stereotactic radiotherapy, together with lower toxicity rates²⁰. For jugular paragangliomas, which are more challenging from a surgical point of view, stereotactic radiotherapy has been used with increasing frequency and satisfactory results^{7 8}. Literature data suggest that the choice between a stereotactic approach in 1 or 3-5 fractions may be based on tumour volume, being larger tumours (> 3.5 cm) better treated by conventionally fractionated radiotherapy.

The brilliant results (which in some series reached 100%) of stereotactic radiotherapy for both tumour and clinical control may support a radiobiologic concept: we do not know radiosensitivity and in general express this as α/β ratio in the linear-quadratic model, but as these tumours are a slow-growing benign entity, the α/β ratio might be considered as low as those of meningiomas ($\alpha/\beta = 3.76$ Gy) or vestibular schwannomas ($\alpha/\beta = 2.4$ Gy)^{21 22 23}.

The reported high tumour control rates suggest performing stereotactic radiotherapy as a treatment of choice in case of bilateral paragangliomas, where a surgical approach for on neck sides is at high risk of sequelae. In such cases, surgery may be performed for bulky or secreting paragangliomas and on the opposite side, a radiotherapy treatment may be delivered¹⁴. Alternatively, the neck could bilaterally be treated with fractionated stereotactic radiotherapy⁹.

Interesting results also came from proton therapy although only one study fulfilling the selection criteria was found in literature search⁶. Cao et al. analysed 10 patients who performed the treatment, and all achieved tumour control. Only grade 1 late toxicity was reported and in 50% of cases in terms of fatigue. The limited literature data on proton therapy, despite satisfactory results, do not allow to make any strong recommendation in this regard.

An interesting issue is the risk of developing a secondary malignant tumour in paraganglioma after radiotherapy. We found only one report which described 2 cases of subsequent tumours in a retrospective cohort of 46 paragangliomas. Both patients developed a meningioma 15 and 18 years after

radiotherapy, respectively¹⁶. Based on this, we could argue that the risk of malignant transformation is limited although this finding in the literature is related to the length and accuracy of follow-up.

The main limitation of the present review is related to the absence of clinical randomized trials comparing different radiation therapy approaches. In fact, literature data are only available from retrospective studies sometimes with limited number of patients and relatively short follow-up.

Conclusions

This literature review on primary radiotherapy for head and neck paragangliomas covered the most relevant studies of the last 10 years. It showed that radiotherapy which can be used with different treatment schedules (including radiosurgery, fractionated stereotactic radiotherapy and conventionally fractionated radiotherapy) can achieve satisfactory control tumour rates even in the long-term with a limited incidence of acute and late toxicity. Prospective clinical trials on the role of primary radiotherapy are expected to better clarify the role of radiotherapy compared to that of surgery and to identify the optimal radiation technique in terms of dose and fractionation, based on long-term results of local control and side effects including the risk of secondary tumours.

4.2.4. Partial surgery in paraganglioma: indications and results

R. Bivona, M. Nardone, E. Zanoletti, G. Danesi

Introduction

Although benign and slow-growing lesions, tympano-jugular paragangliomas have potential severe morbidities by aggressive and extended involvement of the skull base. The ideal primary treatment of these lesions is surgery with the aim of a radical resection, which can be associated with postoperative morbidity and sometimes can worsen pre-existing symptoms¹. Since 1977, surgery of the jugular foramen has been standardized by the description of the infratemporal approach². Though more conservative approaches^{3 4} have been developed through the years, data to validate and standardize the surgical strategy of these tumors are still lacking. The main problems of achieving a standardized and universally accepted treatment strategy for these lesions are their relative rarity, their rich vascularization, the scarce knowledge of their natural history along with the necessity of dealing with nearby vital structures in the skull base which make surgery demanding and potentially dangerous. Very high morbidity and mortality were the price to pay through the years to achieve a total or grossly total resection⁵. Neurological sequelae and other complications have a significant impact in the patients' quality of life, particularly in the elderly who may have great difficulties in

postoperative rehabilitation ⁶. For young patients, recovery and rehabilitation are easier, but these subjects will need to bear with sequelae of surgery all of their life together with the perspective of developing a recurrence, because as the lifespan is longer, the possibility to develop a recurrence is higher. Most glomus tumors grow very slowly and the median doubling rate of the tumors is considered to be four years. This supports the theory of a watchful-wait policy for small non-symptomatic tumors in older patients, but does not add much contribute in the management of young patients, for whom a treatment is generally required. The potential permanent postsurgical disability, along with an increasing concern on quality of life, has drawn attention to alternative treatments, particularly to radiotherapy. Conventional fractionated radiotherapy has been associated with high risk of several long-term complications such as: brain stem damage, temporal bone necrosis, internal carotid artery thrombosis with stenosis together with a still confusing rate of secondary malignancies ⁷. Moreover, the effect of radiotherapy on paraganglioma tissue is not well understood and glomus cells themselves are generally considered to be radioresistant, though a long-term control of tumor growth is reported ⁸. For these reasons, external beam radiation is rarely used as a primary treatment of glomus tumors, except for inoperable recurrences or for old patients with advanced tumors and comorbidities. Over the past years, radiosurgical techniques have emerged as promising alternatives to traditional surgery, both as a primary treatment or as an adjuvant treatment following surgery ⁹. Radiosurgery has currently three main techniques: gamma knife, Linac and cyber knife. All of these techniques are refinements of conventional radiation therapy and are conceived and tailored to the particular characteristics of the tissue and to the site of glomus tumors ¹⁰. Results are promising and document the stability of tumor growth with no new neurological deficits in several reports ¹¹. These facts make radiosurgery an interesting treatment to be considered in selected cases as an alternative or as a complementary instrument to surgery. Moving from the promising results of radiosurgery and the unquestionable unbearable morbidity related to extensive surgery, particularly in old patients with a normal preoperative neurological status, in recent years we have been trying to adapt the treatment to the characteristics of the tumor (site, size, potential aggressiveness, growth rate) and to the patient (age, state of cranial nerves, symptoms, comorbidities, consensus) in order to set when surgery is necessary and which kind of surgery to propose. The over 30-year-long experience of our department on surgical treatment of jugular paraganglioma also supported the necessity to make an effort to seek for a viable, low morbidity and more modern treatment ⁷. We think that progresses in the knowledge of the natural history of the tumor in the radiosurgical field cannot be ignored, though we are aware

that the promising results of radiosurgical reports have sometimes unacceptable short follow-ups ¹² and that the criteria of success between radiotherapy and surgery differ in their nature, since radiotherapy aims to prevent any further growth of the tumor, and surgery aims to remove the tumor and completely eradicate the disease. Nevertheless, we found in literature and in our experience enough arguments to support the proposal of a new way of management of tympanojugular paraganglioma, leading to an algorithm of treatment which has been currently applied on our patients. The controversial aspects found in literature and in our experience will be discussed further on, along with the new protocol of treatment we have adopted and proposed.

Material and methods

Patients

This is a prospective study of all our patients with paragangliomas in class C1-C2-C3 treated from 2004 to 2017. Epidemiological and clinical data, surgical and histological reports, preoperative and postoperative images, complications, data on adjuvant therapy and follow-up information were reviewed. 76 patients have been included in the present analysis. These were 44 females and 26 males with age ranging from 19 to 78 years old. The mean age is 45,2 years old. Tympanojugular paragangliomas were staged according to Fisch and Mattox classification (Table 4.2.4.I). Perioperative sequelae were recorded. Follow-up was defined as the period of time from surgery to the most recent evaluation. Patients with less than 1 year of follow-up were excluded from the study. Complications, recurrences, or any other relevant data were analyzed during follow-up. Preoperative radiological

Table 4.2.4.I. Classification of jugulotympanic paragangliomas according to Fisch and Mattox.

Class	Location and extension of paraganglioma
A	Paragangliomas that arise along the tympanic plexus on promontory
B	Paragangliomas with invasion of the hypotympanon; cortical bone over the jugular bulb is intact
C ₁	Paragangliomas with erosion of the carotid foramen
C ₂	Paragangliomas with destruction of the vertical carotid canal
C ₃	Paragangliomas with involvement of the horizontal portion of the carotid canal; foramen lacerum intact
C ₄	Paragangliomas with invasion of the foramen lacerum and of the cavernous sinus
De _{1/2}	Paragangliomas with intracranial but only extradural extension; De _{1/2} according to displacement of the dura (De ₁ = less than 2 cm; De ₂ = more than 2 cm)
Di _{1/2/3}	Paragangliomas with intracranial and intradural extension; Di _{1/2/3} according to depth of invasion into the posterior cranial fossa (Di ₁ = less than 2 cm; Di ₂ = between 2 and 4 cm; Di ₃ = more than 4 cm)

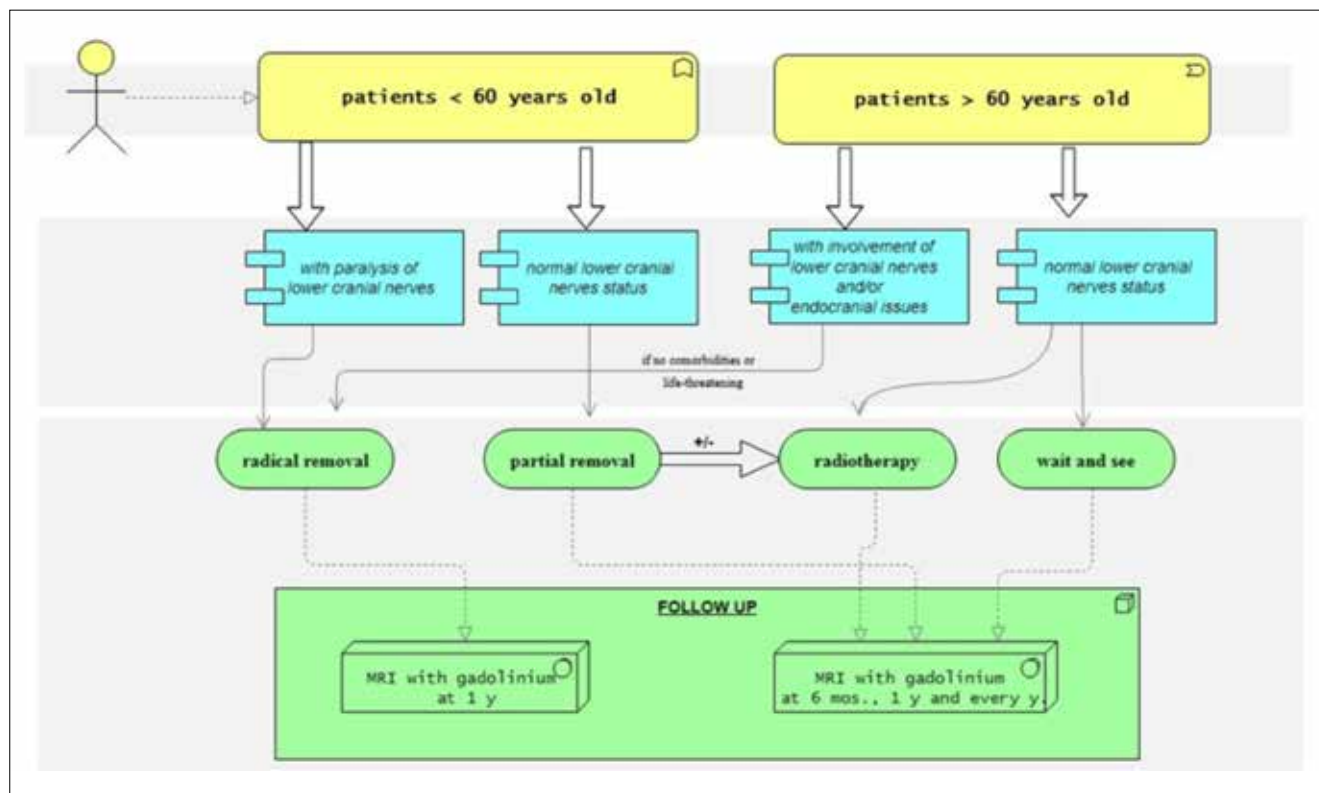


Fig. 4.2.4.1. Algorithm of treatment of tympano-jugular paraganglioma.

evaluation includes high-resolution CT and gadolinium-enhanced MRI. Additionally, tumor embolization is performed 2 days before surgery by neuroradiologists.

More specifically, the protocol states that patients aged less than 60 years old with paralysis of lower cranial nerves are treated with radical removal. If the lower cranial nerves status is normal these patients undergo partial removal which can be followed or not by radiotherapy. Patients aged more than 60 years old are treated with radiotherapy or observation (wait and see behavior) unless they develop an involvement of lower cranial nerves and/or endocranial issues (in Di extension). These conditions may require surgery if no comorbidities are described or are life-threatening (Fig. 4.2.4.1). Surgery has been performed in 67 out of 76 patients with C class paragangliomas. 6 patients have not been treated and are under observation. 22 cases showed a D class extension. Patients' lesion characteristics are shown in Table 4.2.4.II.

Table 4.2.4.II. Patients'lesion characteristics.

Class	N. of cases
C ₁	15/76
C ₂	53/76
C ₃	6/76

Classification

Classification of jugulotympanic paragangliomas according to Fisch and Mattox is shown in Table 4.2.4.I.

Surgical approaches

Tympanojugular paragangliomas have always presented a challenge for surgeons as these tumors are vascular, locally aggressive, and involve important neurovascular structures, as the jugular bulb, the internal carotid artery (ICA), the facial and the lower cranial nerves (CNs; IX, X, XI and XII). These lesions usually do not imply hearing impairment. The selection of the surgical approach (Table 4.2.4.III) was tailored according to the location and the extension of the tumor. Various patient factors were also taken into account, such as: age, general health condition and preoperative cranial nerve dysfunction. Surgical strategy can be outlined as:

- infratemporal fossa approach type A (ITF A);
- petroccipital-transigmoid approach (POTS);
- lateral petrosectomy with facial bridge (transotic approach).

Table 4.2.4.III. Surgical approaches.

Surgical approach	Patients
ITF A	9
POTS	17
Transotic	44

The primary approach used in most cases was a lateral petrosectomy with facial bridge.

The objective of the infratemporal fossa type A approach is exposure of the infralabyrinthine and apical compartments of the temporal bone, of the mandibular fossa and posterior infratemporal fossa by subtotal petrosectomy and anterior transposition of the facial nerve. It is a cranio-temporo-cervical approach requiring a combination of otoneurosurgical and head and neck surgery techniques. The type A approach is used for removal of tumors involving the jugular foramen, primarily class C and D glomus temporale tumors. The pars vascularis and pars nervosa can be exposed, together with the vertical tract and part of the horizontal tract of the internal carotid artery. The incision is extended into the neck to expose the vessels and the cranial nerves in the neck¹³. The POTS approach has been developed for removing tumors situated in the jugular foramen together with their local extension into the adjacent parts of the skull base, the cerebellopontine angle (CPA) and the parapharyngeal space (PPS). The POTS approach involves a posterolateral exposure and an anteromedially directed surgical axis which allows the surgeon to leave the external and middle ear complex, together with the facial nerve, entirely undisturbed. Single-stage removal of intra- and extradural lesions extending from the CPA to the PPS can be achieved with minimal risk of cerebrospinal fluid (CSF) leak. In essence, the POTS approach is the combination of a retrolabyrinthine petrosectomy and a retrosigmoid craniotomy. The external ear canal, tympanic cavity, and facial nerve are left in situ¹⁴.

The transotic approach to the CPA was first introduced in response to the limitations of the translabyrinthine technique. The objective of this approach is to obtain a direct lateral exposure and the widest possible access to the CPA through the medial wall of the temporal bone, from the superior petrosal sinus to the jugular bulb, and from the internal carotid artery to the sigmoid sinus. The tympanic and mastoid portions of the fallopian canal are left in situ. As a natural extension of subtotal petrosectomy, the transotic approach was initially designed for acoustic neuromas and has then expanded to include other pathologies like temporal paragangliomas¹³.

The treatment of intradural extension of these pathologies is tailored according to depth of invasion into the posterior cranial fossa.

Statistical analysis

A p value less than 0.05 was considered as significant. Mann-Whitney U test was applied to evaluate if radiotherapy is more valuable rather than a wait and see behavior on residuals after partial surgery. No difference was found ($p = 0.9229$) (Fig. 4.2.4.2).

Results

Patients underwent surgical resection via different approaches. Tumor resection can be partial or total. Surgery

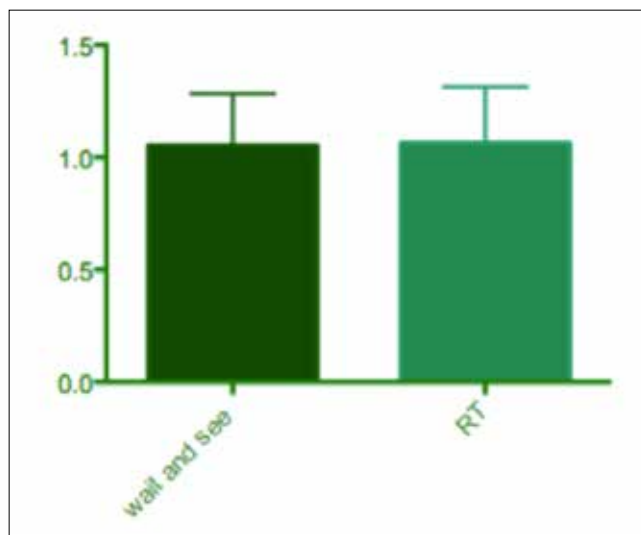


Fig. 4.2.4.2. Comparison between the two groups of patients with residual tumor after partial surgery.

has been performed in 67 out of 76 patients. A deliberate incomplete removal was performed in 53 cases. In 14 patients a radical removal was obtained. 3 patients undergone exclusive radiotherapy. Preoperative cranial nerve status was related with tumor extension and is shown in Table 4.2.4.IV. Post-operative morbidity rates are satisfying. Main complication was hearing loss which is present in 89% of cases, a new deficit of lower cranial nerves was described in 2% of patients. No cases of meningitis is reported. Moreover, there was 1 case of temporary ischaemia and 1 death. In 13 patients (19%) a facial nerve deficit was described. 6 cases underwent facial nerve grafting, of these cases: 3 showed a III grade HBS, 2 showed a IV grade HBS and 1 case did not recover nerve function despite grafting.

Preliminary results show a stability of residual tumor for 87.5% of patients who underwent radiotherapy after partial surgery and for 91.9% of patients who are enrolled in the wait and see group after partial surgery. Most of the patients who underwent partial removal have a residual which is monitored with post-operative serial imaging with MRI with gadolinium at six months after surgery and after a year. Subsequent follow-up provides a MRI with gadolinium once a year.

Table 4.2.4.IV. Pre-operative cranial nerve status related with tumor extension.

	C ₁	C ₂	C ₃
None	4	10	
CN's IX-X-XI-XII		7	4
CN VII	2	5	2
Hearing loss, tinnitus, vertigo	6	19	6
Hydrocephalus			1

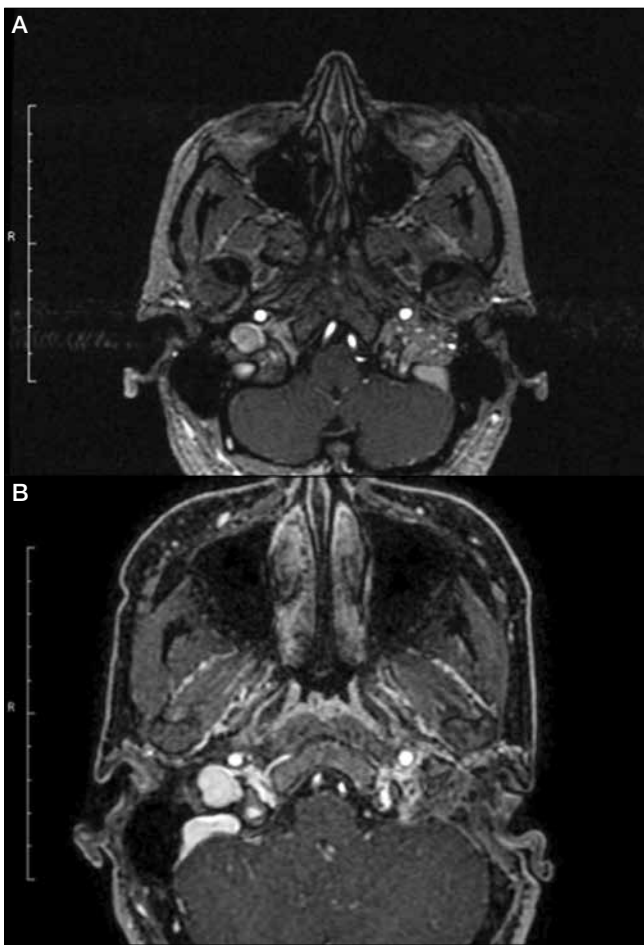


Fig. 4.2.4.3. A) A case of C2; B) Post-op. after partial surgery.

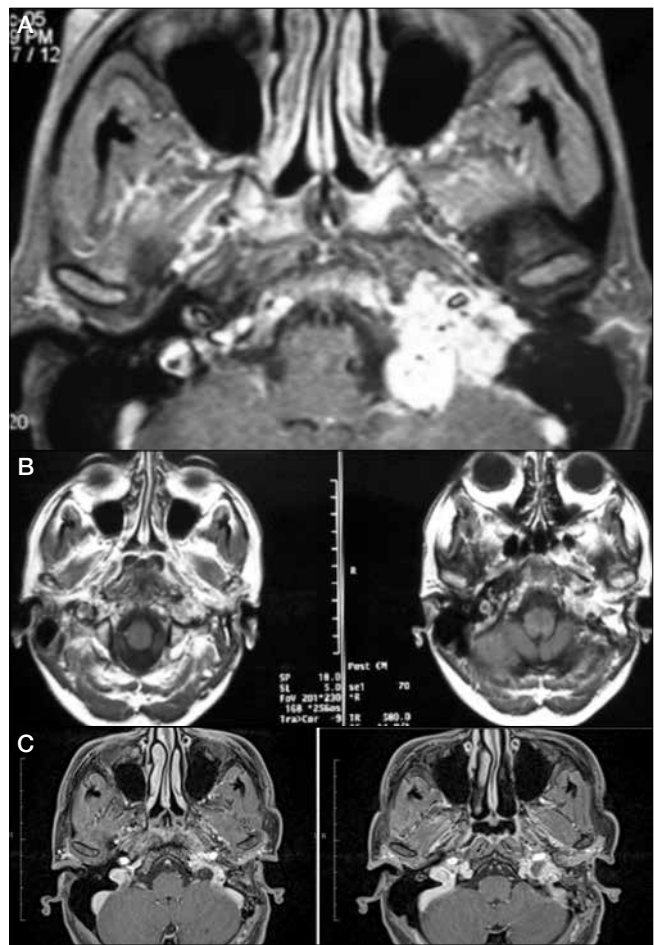


Fig. 4.2.4.4. A) A case of C2 D2e; B) Stable at 4 years of follow-up; C) Stable at 7 years of follow-up.

No significant results were found in this preliminary report. The most obvious limitation in this research was the small sample size. Further studies are needed to verify our hypothesis and, as previously stated, a prospective cohort study is ongoing to assess whether radiotherapy is more valuable when compared to a wait and see behavior on tumor residuals after partial surgery and to confirm the validity of our protocol.

Case 1

A case of C2 (Figs. 4.2.4.3A, B).

Case 2

A case of C2 D2 (Figs. 4.2.4.4A, B, C).

Discussion

Treatment of jugular paragangliomas remains controversial. Surgery has been considered the gold standard since it offers a radical removal of the tumor despite its morbidity. Nevertheless, functional consequences of postoperative complications and long-term sequelae are so wide to doubt

the necessity of an extensive skull base surgery in some cases. In literature, the most successful experiences¹⁻¹⁵ report an unexpected 10% rate of recurrences in total (or gross total) removal. Other reports¹⁶ have a rate of recurrences around 70%. Two aspects must be considered when reporting surgical outcomes of tympano-jugular paraganglioma: the mean length of follow-up and its modality. This defines the minimum length of an acceptable follow-up and the instrumental way of assessment of the residual/recurrent disease. When angiography is performed at two years of follow-up (shorter follow-up should not be accepted as a mean to assess the outcome of surgery) a minimal recurrence becomes evident, and it reported. The same recurrence might take more time to become evident at an MRI. The latter fact is relevant because it reveals how total removal is often a gross total removal, with unexpected and underestimated residual disease, although this does not necessarily affect the therapeutic attitude towards the recurrence. In this setting, the enthusiasm for outcome success despite its morbidity should be faced with more criticism.

The rate of residual/recurrent disease assessed by yearly MRIs, varies from 30% with a range of follow-up of 2,5-13 years to 10%¹ with a range of follow-up of 3-144 months. 50% of recurrences¹⁶ was not treated and remained stable at the follow-up. A good rate of stable residuals was observed in our experience. The relative stability of the residual disease represents a contribute to the concept of planned subtotal resection to preserve function, though some authors¹⁵ state that *“the temporary benefit to the patient of avoiding a facial nerve weakness, or lower cranial nerves palsy, should be balanced against the possibility that, because of the infiltrating nature of paraganglioma, tumoral remnants may spread along the dural surfaces and the spongy bone, reaching areas where they become unresectable”*. Actually, most authors agree that residual/recurrent disease may be treated with success by radiosurgery when the size is not more than 3 cm^{12 13 17-19}. Partial removal + radiosurgery is thus advocated in bigger residual lesions^{17 19}. A watchful wait and scan policy^{16 19} is also adopted in case of small residual with no growth.

All the different attitudes towards the residual and, more importantly, towards a previously treated primary tumor, cannot avoid to consider the problem of the functional status of the cranial nerves. When cranial nerve deficit is present before the treatment, the therapeutic balance is undoubtedly in favor of a radical-extensive surgery, when radicality can be achieved without exposing vital structures to an excessive risk. When cranial nerves are normal (which does not necessarily mean that they are not involved by the tumor), other options should be discussed, as post-surgical acquired cranial nerve palsies are scarcely tolerated, especially in elderly patients. In some cases, the natural history of an untreated tumor will lead to the same functional imbalance, but those issue are much more tolerated because they occur progressively and not as an acute post-surgical iatrogenic event¹⁹. Preoperative neurological deficits make the surgical decision easier, and adopting a conservative approach in asymptomatic patients seems to be reasonable. Not all authors agree that the preoperative function of the lower cranial nerves should impact on the therapeutic choice¹. A rate of 55% of surgically-acquired lower cranial nerve disfunction (with preoperative normal cranial nerves) does not seem to justify the need of discussing and proposing new therapeutic strategies in order to reduce morbidity. A lack of data about pre-treatment status of the lower cranial nerves is observed both in surgical and radiosurgical series.

While the presence of a preoperative paralysis simplifies the therapeutic choice, whilst the normal status of lower cranial nerves demands more close attention, therefore a wait and scan policy has been proposed, along with exclusive radiotherapy or planned partial resection followed by radiosurgery⁷. All described options must be also correlated

to another important factor: patient's age. There is a general agreement that elderly patients should not undergo extensive surgery^{17 18 20 21} because of the difficulties of post-surgical rehabilitation and the presence of comorbidities which adds problems to the recovery. The problem is to define which is the cut off age to separate “young” patients from “old” patients, along with all elderly patients who are biologically younger and may be good candidates for surgery and viceversa. Young patients usually have no medical factors contraindicating aggressive surgery and cope more easily with postoperative neurological deficit recovery. In case of recurrence, radiation can be offered with success rather than salvage surgery, which is generally more complicated in a treated field. Moreover, in the setting of a shorter lifespan and a lower possibility of developing recurrences, radiotherapy (radiosurgery) could play its role as first line treatment for elderly patients. By stating this, we do not mean that recent radiosurgical techniques are superior to surgery in treating jugular paragangliomas. We have already mentioned the two basic biases of radiosurgical reports: the shortness of follow-up and the criterion of success, which is different between the two kinds of treatment. Radiosurgical literature, in some cases, does not make distinction between carotid body and jugular glomus tumors, giving cumulative rates of success. Similarly, no distinction is made between the treatment of primary tumors and post-surgical recurrences. Our aim was to seek for a strategy for management of jugular paraganglioma which might have offered the safest treatment from both oncological and functional points of view, trying to use all the treatment modalities that are available nowadays. Radical surgery, radiosurgery, observation, and planned subtotal surgery are all viable options which can be applied according to the characteristics of the tumor and of the patient. It is within this setting that we have developed our algorithm, which we have been using for 13 years, with a rate of local control of 91.9%.

The protocol was applied to our case material and it is described in details in Figure 4.2.4.1. The value of this protocol will be discussed after adequate follow-up of at least 10 years for each patient. At the moment our experience is valuable as a preliminary report, and this “preliminary” aspect should be applied also to all those reports, both surgical and radiosurgical, which aim to draw conclusions with a range of follow-up which sometimes is even less than 1 year.

The natural history of the disease, the impact of post-surgical morbidity on the patient's quality of life, along with a rate of total removal (which is often more a gross total removal rather than a total removal as long as the time of follow-up increases), should lead to a serious reflection about the need to find a common strategy which could be more respectful for nerve function along with good oncological

results. Radiotherapists and surgeons should no longer debate about the best treatment for jugular paragangliomas: their knowledge must be shared to set the best treatment strategy for each patient, which could be either be surgical, radiotherapeutic or an integration of both.

Conclusions

The value of this protocol will be discussed after an adequate follow-up of at least 10 years for each patient. At the moment, preliminary post-operative clinical data are quite satisfying with acceptable post-operative complications and stability of tumor residual. A prospective cohort study is ongoing to assess whether radiotherapy is more valuable rather than wait and see behavior on residuals after partial surgery and to confirm the validity of our protocol.

4.2.5. Management of internal carotid artery in skull base paraganglioma surgery

M. Sanna, E. Piccirillo, G. Piras, L. Lauda, A. Caruso

The surgical management of skull base paragangliomas is particularly challenging as a result of their complex anatomical location, the local major neurovascular structures, and the proximity of intracranial structures. The internal carotid artery (ICA) is often involved by tympanojugular paragangliomas (TJPs) in its upper cervical and petrous portions^{1,2}. Similarly, carotid body paragangliomas and vagal paragangliomas are also intimately related to the ICA.

We have developed the application of preoperative stenting of the ICA in the management of TJPs since 2003 to avoid preoperative closure or bypass procedures and to protect and preserve integrity of the ICA during surgery^{3,4}. Preoperative stent insertion also permits an aggressive ICA dissection with significant reduction of surgical risks³⁻¹¹. In class C3 and C4 tumors, major encasement of the ICA is usually found at the inferomedial wall of the horizontal petrous segment.

Curative treatment necessitates aggressive removal of the bone in the region of the carotid canal and dissection of the arterial wall in class C3 and C4 tumors. We have noted that most recurrences were localized to the area around and medial to the petrous ICA⁶. Preoperative endovascular intervention in the form of intra-arterial stents in the cervical and petrous (vertical and horizontal) segments of the ICA allows total tumor clearance in these areas without compromising the artery. In our experience of over 30 cases, stenting of the ICA has transformed the therapeutic management in cases of advanced TJPs, dramatically reducing the number of inoperable TJPs.

Preoperative assessment of the ICA

The goals of preoperative assessment are to: 1) determine the degree and extent of involvement of the artery by the

tumor; 2) to assess the efficacy of the collateral circulation in maintaining a correct perfusion of the areas that would be affected by the manipulation or sacrifice of the artery. The investigations used for this purpose include high-resolution CT and angio-CT scans, MRI with gadolinium enhancement, magnetic resonance angiography (MRA), and digital subtraction angiography. Narrowing and irregularities of the arterial lumen are strongly suggestive of infiltration of the ICA wall. To determine the efficacy of collateral circulation, four-vessel angiography with manual cross-compression test, xenon-enhanced computed tomography cerebral blood flow, single-photon emission computed tomography, and carotid stump pressure management are used.

The indications for preoperative endovascular intervention of the ICA are:

1. encasement of the distal cervical and petrosal vertical segments of the ICA between 270 and 360°, as shown by CT and MRI in the axial plane;
2. evidence of stenosis and irregularities of the arterial lumen of the distal cervical and petrosal segments of the ICA as determined by angiography;
3. all class C3 and C4 TJPs, vagal and carotid body paragangliomas;
4. extensive blood supply from ICA branches as seen on angiography;
5. previous surgery with ICA manipulation and/or previous radiotherapy.

In these situations, the options include: preoperative permanent balloon occlusion (PBO), external-internal carotid artery bypass followed by PBO or reinforcement with intra-arterial stents. In this chapter, we will briefly discuss PBO and stenting of the ICA.

Preoperative endovascular management of the ICA

Permanent balloon occlusion

A balloon occlusion test (BOT) is performed if there is good cross-filling from at least one of the two communicating systems. A PBO can be performed if the patient tolerated the BOT and angiographic data demonstrated good cross-flow. The BOT-PBO procedure is performed under local anesthesia with mild sedation and systemic heparinization. A bilateral femoral approach is employed in which an 8F guiding catheter is inserted into one femoral artery and positioned in the ICA that will be occluded. The contralateral femoral artery puncture is used for angiographic evaluation. To permanently occlude the ICA, a 16 gold-valve balloon mounted on a chronic indwelling Foley catheter (Minyvaxis, Gennevilliers, France) is used. The first balloon is usually placed into the cavernous segment of the ICA just proximal to the origin of the ophthalmic artery and two more balloons are located at the carotid foramen and in the neck just distal to the bifurcation. After balloon inflation, occlusion of the ICA

is confirmed angiographically by injection of contrast into the guiding catheter, followed by confirmatory angiography to establish that adequate crossflow is achieved, with special attention to the symmetry of the arterial, capillary, and venous phases on either side. The patient's physical and mental status is then monitored for 20 min. The first balloon is then detached. If balloon occlusion is not tolerated, the balloon is deflated immediately. In most cases this is evident very quickly, in the first few minutes after carotid occlusion. If asymmetry (> 1 s) in the capillary and venous phases of the angiogram is identified, angiography is repeated a few minutes later. If this asymmetry does not correct, the balloon is deflated and alternatives must be considered. After PBO, the patient is monitored for 24 h in an intensive care unit. Surgery is scheduled only after 3-4 weeks.

Intra-arterial stenting

The introduction of preoperative reinforcement of the ICA with stents is a significant advancement in the surgical management of patients who are at risk of damage to this vessel. Stent insertion reinforces the artery and allows a more aggressive carotid dissection while reducing the possibility of intraoperative injury to the ICA. To reduce the risk of thromboembolic complications, antiplatelet therapy is introduced 5 days before the stent insertion using a combination of clopidogrel (75 mg/day) and aspirin (100 mg/day). This therapeutic regimen is administered for 1-3 months after stenting and then reduced to single-drug treatment with aspirin only. Antiplatelet agents are stopped and low molecular weight heparin (LMWH) commenced 5 days before surgery. Antiplatelet agents are introduced 2 days after surgery and LMWH is stopped 3 days after surgery. The patient then is placed on lifelong antiplatelet therapy. Reinforcement with stents is performed under general anesthesia as a separate procedure following diagnostic angiography. Three different types of self-expanding nitinol stents are used: Xpert Stent System (Abbott Laboratories Vascular Enterprises, Dublin, Ireland), Neuroform 3 (Boston Scientific, Fremont, CA), and LEO (Balt Extrusion, Montmorency, France). We consider the Xpert stent the most suitable for reinforcement of both the cervical and intratemporal portions of the ICA because of its diameter (4 or 5 mm) and length (20, 30, or 40 mm). To reduce the possibility of injuring the ICA at the stent-tumor border, at least 10 mm of tumor-free vessel wall must be reinforced with the stent, both proximally and distally.

To achieve this, it is necessary to insert up to two or even three stents. Each stent is carefully selected and tailored to the individual patient. It is difficult to negotiate the stent between the vertical and horizontal portions of the carotid canal and in arteries that are coiled or kinked in the neck, and great care must be taken while this is being performed. In such situations, softer and more flexible stents must be chosen, to reduce the risk of dissection of the ICA. If a stent placement is technically impossible, a PBO is the next option.

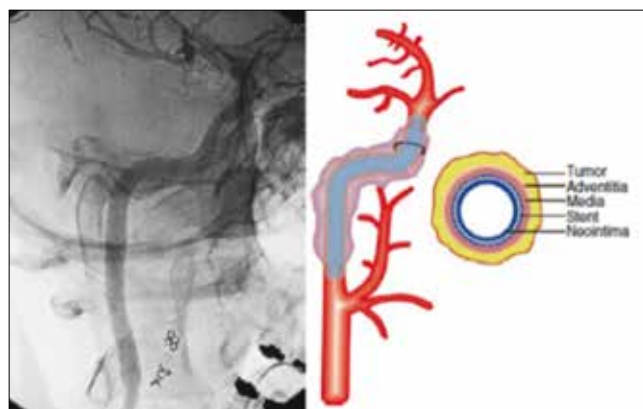


Fig. 4.2.5.1. Stenting of the ICA, as shown by the angiogram (left picture).

The timing of reinforcement with stents also plays an important role; an interval of at least 4-6 weeks is advocated between stenting and surgery. This allows the formation of a stabilized neointimal lining on the luminal surface of the stent. In the presence of significant blood supply from the ICA, a bare stent is ineffective in reducing the vascular supply to the tumor. In such situations, the use of PBO, preoperative embolization with particles during temporary balloon occlusion of the ICA, and insertion of covered stents are possible alternative solutions. Present literature suggests that covered stents have several theoretical disadvantages, increased thrombogenicity, rigidity, and greater difficulty in positioning at arterial angles, when compared to bare stents.

One month after the stent insertion, the neointimal layer is developed and subsequent subadventitial dissection can be safely performed (Fig. 4.2.5.1).

Intraoperative management of the ICA

Intraoperatively, the ICA may require the following types of intervention, depending on degree of involvement: 1) decompression with or without partial mobilization of the artery; 2) subperiosteal dissection; 3) subadventitial dissection; 4) subadventitial dissection with stent coverage; 5) arterial resection (after preoperative PBO).

Simple decompression

This technique is employed when the tumor is around the ICA but not adherent to the artery (i.e., Fisch class C1 TJPs). Decompression of the ICA is performed after identifying it medial to the Eustachian tube by drilling out the tympanic bone. A large diamond burr is used parallel to the course of the artery. Drilling is advanced both laterally and medially to the artery. By removing the bone anterior to the ICA, the artery can be displaced laterally or medially, by manipulating it with the tip of the suction tube while drilling is being performed. If additional drilling around the ICA is required, a vessel loop is wrapped around the artery to enable a wider range and better control.

Subperiosteal dissection

This technique is indicated when the tumor involves the periosteum of the carotid canal without reaching the adventitia. In this technique, a plane of dissection is developed between the adventitia of the ICA and the periosteum of the carotid canal. This is relatively easier and safer in the vertical petrous segment, as the ICA is thicker and more accessible when compared to the horizontal segment. The dissection of the tumor is started at the cervical level, from an uninvolved extratemporal segment of the ICA, where a good plane of dissection is easily identified. The bone of the carotid canal around the ICA from its entrance into the temporal bone is drilled out along with the tumor infiltrating the bone and periosteum. Gentle displacement of the ICA, from its entrance in the skull base to at least the genu of its horizontal segment, is required if the tumor has extended anterior to the artery. There could be areas where the tumor may extend into the adventitia of the artery, and subadventitial dissection may be required.

Subadventitial dissection

This technique is applied to tumors that infiltrate the adventitia without reaching the muscular layer (media) of the ICA. Subadventitial dissection consists of separating the adventitia from the muscular layer. The wall of the ICA at the level of the vertical segment is 1.5-2.0 mm thick with the adventitia being approximately 1 mm thick. The adventitia is absent in the horizontal portion. Therefore, subadventitial dissection can only be executed in the vertical portion.

The intraoperative risk of a vascular injury is especially high in irradiated or previously operated cases. Small lacerations to the arterial wall, or any avulsion of the carotic-tympanic branches, can often be controlled with judicious use of bipolar cautery. For small to medium defects, direct suture repair is recommended. Double-armed vascular sutures are used while temporary occlusion is applied. Taking care to evert the edges of the artery while suturing is important to avoid stenosis. The postoperative risks of subadventitial dissection include weakening of the vessel leading to subsequent blowout or to dilatation and delayed aneurysm formation.

Dissection and resection following permanent balloon occlusion

Following balloon occlusion of the artery, dissection is started in its cervical tract directed upwards. It is ligated immediately proximally to the proximal balloon using a large vascular clip, followed by en bloc resection of the artery with the surrounding tumor. Care must be taken to identify the distal segment of the occluded artery and transection must be performed here to avoid excessive traction on the cavernous sinus segment during final tumor removal. In rare cases with failed tumor embolization due to tumor high flow blood supply, permanent balloon occlusion can be performed even in cases with stent insertion.

Intraoperative internal carotid artery injury

Prevention of injury to the ICA must be achieved at all costs. However, in rare occasions, a vascular injury may be encountered. In such cases, the presence of proximal and distal control allows temporary occlusion, while a primary repair is carried out. A primary principle in such situations is to achieve an adequate visualization.

Temporary compression or occlusion is quickly achieved by using previously placed control tapes. A variety of atraumatic vascular clips can also be used. Back-bleeding is a reassuring sign indicating some degree of collateral flow and allowing repair to be carried out in a timely fashion. Once the controls are achieved proximally and distally, small lacerations to the arterial wall or avulsion of the caroticotympanic branches can often be controlled with judicious use of bipolar cautery. Fine tips are used to approximate the edges in the longitudinal direction of the laceration. A low energy pulse is applied, and the forceps are advanced. The process is repeated until the laceration is sealed. The occlusion is partially and then fully released to ensure closure. A layer of Surgicel® is placed over the repair and reinforced with fibrin glue. For small to medium defects, direct suture repair is recommended. Double armed vascular sutures are used while temporary occlusion is applied. Care to evert the edges is important as to avoid significant stenosis, as previously stated. Patch grafting and bypass using saphenous vein are options in extreme situations. In case of a stented ICA, the greatest risk is potential injury at the transition point of the stented and non-stented artery. It is imperative to use minimal traction at this point. Facilities for rapid transfer of the patient to the neuroradiology unit once temporary control is gained are essential, with the options of emergency balloon occlusion or covered stent placement. Apart from repair of the artery, important resuscitation principles must also be adhered to. Judicious volume replacement, estimation of blood loss, and consideration of component therapy are made. Following repair, normotension and adequate circulating volume must be maintained to ensure adequate repair and neuroprotection. Any injury to the internal carotid artery or subadventitial dissection must be followed up radiographically due to the risk of pseudo-aneurysm formation. Vasospasm of the ICA can also occur while manipulating the ICA. The etiology can be multifactorial but includes mechanical trauma, thermal changes, desiccation, and prolonged exposure to blood. Therefore, irrigation with warmed saline and a gentle technique are essential to minimize this risk. It has been reported that younger patients are more prone to this complication due to increased vascular tonicity and reactivity. If the surgeon notices any segmental reduction in the ICA, manipulation must stop, and papaverine is placed onto the artery. The surgeon must wait till normotension or mild hypertension is achieved.

Conclusions

ICA involvement is no longer considered a limiting factor in TJP surgery, but requires an accurate preoperative neuroimag-

ing evaluation of the extent of ICA invasion by the tumor and appropriate perioperative management. Decompression of the ICA and subperiosteal dissection are relatively simple surgical procedures that can be used in cases where the adventitia of the ICA is free of involvement. Preoperative endovascular intervention in the form of intra-arterial stents in the cervical and petrous segments of the ICA has transformed the therapeutic management in cases of advanced TJPs. Stenting of the ICA avoids the need for potentially troublesome maneuvers like PBO, bypass procedures, and arterial repair or reconstruction. PBO is currently limited to those patients in which stent placement is technically impossible or in patients with tumors that derive significant blood supply from the ICA. No major perioperative complications, related either to preoperative stenting or intraoperative surgical management of the ICA, have been reported to date in our series of patients.

4.3. Other lesions

4.3.1 Chordoma and chondrosarcoma

E. Zanoletti, R. Colangeli, S. Munari, A. Mazzoni

Chordoma

Introduction

Chordomas are malignant lesions with a locally aggressive behavior that grow in the central skull base with a median localization. Patients' mean age at presentation is 60 years, though some cases have been reported in younger people and even in the pediatric population¹⁻³.

These lesions arise from the remnants of undifferentiated notochord tissue⁴. Skull base chordomas account for only 0.1% to 0.2% of all intracranial tumors⁵. The growth pattern differs, depending on the tissue where the tumor is located: it is expansive with macroscopic growth in soft tissues and the intradural compartment, or infiltrative and destructive in bone. Although chordomas are considered histologically low-grade malignancies⁶, they carry a poor prognosis and tend to recur, even after extensive surgery and post-operative adjuvant radiation therapy. They are locally destructive with a variable pattern of invasion and a considerable metastatic potential: disease spreading to the lung (58-60%), liver (20-22%), bone (18%), soft tissue and lymph nodes has been reported in up to 65% of patients, especially among those with advanced disease⁷⁻⁹. The reported overall survival rate is of 50-60% at 5 years and 30-40% at 10 years¹⁰⁻¹³, with a mean 50% rate of disease progression. Chordomas are diagnosed on contrast-enhanced MRI and bone CT, with an intermediate-low signal on T1- and a high signal on T2-weighted images, and a moderate to high contrast enhancement. Bone CT is useful for ascertaining bone erosion due to the lytic nature of the lesion^{14 15}.

Treatment

The optimal therapy should offer the best chance of survival and involves radical surgery plus adjuvant radiotherapy. The more extensively the tumor is removed, the better the prognosis. Completeness of resection is considered the most important prognostic factor¹¹, but there is the problem of preserving function which feasibility depends on the subsites affected by the tumor and the intrinsic morbidity of the surgical approach. The cranial nerves may be damaged both by the disease and by the surgical approach: cranial nerve VI, when the disease is in the petrous apex or crossed by the surgical corridor; the lower cranial nerves from IX to XII, when the tumor extends infero-laterally in the jugular foramen, lower clivus and condyle, or when surgery requires extensive drilling in the medial aspect of the jugular foramen. The nerves in the cavernous sinus may be affected by the disease, but rarely by the surgical procedure because chordoma in the cavernous sinus is unlikely to be referred for surgery. When a pure lateral approach is chosen, generally combined with the anterior surgical route, it may run across cranial nerves VII and VIII and whether they are sacrificed or preserved depends on the extent of the tumor and the boundaries of an oncologically safe resection. The nerve VII may be transposed if a wider exposure is required in the jugular foramen or along the intrapetrous vertical carotid artery.

Surgery involves anterior approaches to the median-central skull base (which nowadays are mainly performed endoscopically), combined with lateral approaches to remove the lateral, infero-lateral or supero-lateral extensions of the tumor. The goal of surgery should be the removal of all macroscopic tumor, since it is generally agreed that this is the most important factor influencing survival. Adjuvant radiation is the rule after surgery, even in cases where no macroscopic residual tumor is evident^{5 11 12 14 15}.

There has been debate in the recent literature concerning the need for extensive surgery and the related degree of morbidity, which differs for each approach. The clivus region is reached by anterior surgical corridors, using a microscopic or endoscopic transnasal approach¹⁵⁻²³. The endoscopic transnasal route was recently developed with a view to reducing the morbidity vis-à-vis the more extensive transfacial or combined transcranial approaches. It often led to less complete resections, however, when exclusively endoscopic transnasal procedures were used. Whether this negatively affected prognosis is still being debated. Combined approaches to the clivus involve transcranial routes and lateral approaches, all of them may be performed to reach the different areas of the upper-, mid-, lower clivus and the surrounding sites. The extradural corridors may be used to resect also intradural localizations.

After the completion of anterior approaches, the more frequent lateral extensions of the tumour are in the petroclival area, the rhinopharynx up to the petrous apex, the jugular foramen, the foramen magnum, with or without the transdural component in the cerebello pontine angle, the prepontine cistern.

Staging or combining the approaches involves:

- the infratemporal C for the rhinopharynx, para-clival and para-sphenoid area;
- the infratemporal B (or C + B) for the petroclival area;
- the infratemporal A to the jugular foramen and the Petro-occipital trans-sigmoid approach (POTS) to resect a limited tumour in the jugular foramen, or as an extradural corridor to remove intradural lesions in the lower aspect of the cerebello pontine angle²⁴⁻²⁷;
- the far-lateral approach to the foramen magnum.

A sub-temporal approach with temporal craniotomy may be combined with the mentioned approaches to resect tumour extensions in the middle cranial fossa. A comprehensive surgery may thus involve one or more surgeries after the anterior approach, combined or staged, to accomplish a bony resection as much complete as possible.

Open issues

Some aspects that influence prognosis need to be borne in mind when planning surgery for chordoma, moving from our knowledge of the disease's aggressiveness and the need for its radical removal. Whatever the chosen surgical approach, it should allow the resection of tumor in the soft tissues and extensive drilling in the bone, as bony margins are difficult to assess for infiltration. Staged surgery is a viable option when using combined approaches, such as extensive extradural surgery followed by the removal of intradural tumor, with a view to preventing the risk of CSF leak.

Reports on the outcome of surgery for chordoma are not easy to compare because data are heterogeneous, and numerous aspects thus remain unclear. Outcome data should distinguish between primary and recurrent cases and specify the number of surgical procedures performed for each patient, the surgical approaches used, the percentage of intradural invasion, the adjuvant radiotherapy administered, the rate of recurrence or residual disease, the overall and disease-free survival rates at 5 and 10 years calculated according to the Kaplan-Meier method the length of follow-up.

The most appropriate extent of surgical resection is also a matter of debate: different ways are used to define it, meaning different degrees of residual disease. It has to be distinguished from disease recurrence and progression. The most often used, but somewhat imprecise, classifications of the extent of resection refer to: gross total resections (no visible, or small questionable tumor remnants); subtotal resections (more than 90% of the tumor removed); and partial resections (less than 90% of the tumor removed and biopsies).

Although there is agreement on the need to report the above-mentioned details, the literature often lacks such relevant outcome data. Overall and disease-free survival rates are scarcely reported and, when available, they should be correlated with the length of follow-up and the completeness of resection. The majority of authors reported only on their patients' short-term

follow-up (at six months at best), which is hardly informative for a slow-growing malignant disease. As well as being the most influential prognostic factor, assessing completeness of resection is important because there are differences between the concepts of residual disease, recurrence and progression. This is an issue that negatively influences the reliability of reports from an oncological perspective and, when an exclusive anterior endoscopic approach is suggested as the main treatment, it is evident how misleading the conclusions might be.

Conclusions

In our experience, combining anterior and lateral approaches enables an extensive, macroscopically complete resection with ample bone drilling in the clivus, but probably cannot manage microscopically invisible bone infiltration in the clivus and adjacent bone. Removal to this extent is mandatory to achieve good disease control in view of the adjuvant radiation, which is recommended to eradicate microscopic disease, in macroscopically free surgical fields. The intrinsic morbidity of a given approach should be neither disregarded nor exaggerated, since our knowledge of the range of approaches to the skull base allows us to strike the right balance between their various pros and cons. Each procedure should be considered from an oncological perspective. Aggressive treatment aiming for little or no residual disease should be achieved at the first resection. Planning to leave residual tumor in areas that are critical when using the anterior approach is acceptable, when the removal can be completed with a combined or staged transcranial/lateral procedure. Staging the approaches may also allow for a more efficient and safer removal of the intradural component, to prevent CSF leak. The intradural tumor is not an inoperable site in principle, but neither is it susceptible to radiation because of the risks to the nervous tissues and resection should be preferred.

Chondrosarcoma

Introduction

Chondrosarcomas are rare cartilaginous tumors. Only 1% of chondrosarcomas occur in the skull base²⁸, typically arising from skull base synchondroses, such as the petroclival (66%), petro-occipital, sphenoccipital, and sphenopetrosal synchondroses²⁹⁻³¹. Chondrosarcomas tend to develop at the end of the fourth decade of life, with a slight female predominance. Most of these tumors are sporadic, though they have been associated with diseases of endochondral formation including Ollier disease and Maffucci syndrome³². Chondrosarcoma manifests as a destructive, mineralized mass that invades bone and extends into soft tissues. Lesions typically show an infiltrative pattern, replacing normal marrow elements and spreading through the Haversian canals²⁹⁻³³. Histologically, they can be of the conventional, mesenchymal, clear-cell, or dedifferentiated type. Almost all skull base

chondrosarcomas are of the conventional type, while the mesenchymal type is only occasionally reported (<10%)³⁴.

Chordoma and chondrosarcoma were historically grouped together because they share similar clinical, radiological and pathological features, and they were managed surgically in the same way³⁵⁻³⁹, but this can be misleading. Both lesions are rare, accounting for less than 1% of intracranial lesions, and both pose a challenge for their effective treatment due to their proximity to the cranial nerves, the brainstem and the skull base vessels, but these are probably the only aspects they have in common.

Despite being localized in the same area (the mid-central skull base), in small lesions it is clear that chordoma originates from the midline, and chondrosarcoma from a paramedian or more lateral site. They also differ in histopathology and prognosis, and their surgical treatment should differ too.

The diagnosis of chondrosarcoma is radiological. Biopsy would be useful to differentiate between more and less malignant lesions, but it is scarcely feasible when the lesion is located in the central or paramedian skull base. Moreover, when there are clearly different clusters of differentiation in the same lesion, the findings on any biopsy risk being inconclusive. Chondrosarcoma shares some radiological features with chordoma: they are both lytic mass that destroy bone, with similar T1W and T2W characteristics on MRI (intermediate-to-low T1-weighted signal intensity, classically high T2-weighted signal intensity, heterogeneous enhancement after gadolinium), but chordoma is a midline clival lesion while chondrosarcoma arises mainly along the lateral margin of the clivus in the petro-occipital fissure, not in the midline clivus. In addition, chondrosarcoma may show characteristic chondroid calcification within the tumor matrix in about 50% of cases⁴⁰.

Yeom et al. retrospectively analyzed conventional and diffusion-weighted MRI findings in 19 patients with histologically-confirmed chordomas and chondrosarcomas: the conventional imaging features were similar for the two tumors, but poorly-differentiated chordomas revealed a significantly lower T2-weighted signal intensity. Diffusion-weighted imaging seems a very promising method for distinguishing between these tumors because chondrosarcomas were found associated with a higher ADC (apparent diffusion coefficient) than classic or poorly-differentiated chordomas⁴¹.

Pathology shows different degrees of aggressiveness, pointing to different treatment options: a surgical resection appropriate for a low-grade chondrosarcoma cannot be applied as is to a high-grade lesion.

Low-grade chondrosarcoma is known to be scarcely radiosensitive and, especially in younger patients, any treatment that falls short of curing the disease would mean having to manage residual disease in years to come. Balancing the goal of complete resection against the

morbidity of surgery thus becomes particularly important. When the localization and extent of the disease allow for a conservative approach, this is to be preferred for low-grade disease, whereas high-grade tumors warrant extensive removal of bone surrounding the tumor, a necessity that generally makes attempting conservative surgery unfeasible.

Treatment

Since the site of involvement is the mid-lower clivus laterally extending to the jugular foramen, the petro-occipito-trans-sigmoid (POTS) surgical approach is judged to be more conservative than other lateral approaches to these areas (the infratemporal approaches A and B)⁴². The POTS approach⁴³⁻⁴⁵ leaves the facial nerve in place and preserves the middle ear, while affording direct access to the jugular foramen and adjacent areas, also providing a surgical corridor to the petro-clival junction, the neck, and the intradural extension of the tumor into the posterior fossa. The tumor's degree of differentiation (G1, G2, G3) strongly influences the management strategies and prognosis: this enhances the need for extensive removal plus adjuvant radiation therapy, whereas low-grade tumors may be cured with radical surgery alone. Endoscopic tumor resection may be a valid alternative, but it affords a more limited access, and may be oncologically questionable if the approach cannot assure a safe, complete resection of the tumor when otherwise feasible with other approaches.

Open issues

There is no general consensus on the role of radiotherapy in chondrosarcoma of the skull base, though it is increasingly used for palliative purposes, or as an adjuvant therapy in the case of residual disease⁴⁶⁻⁴⁸. It has generally been considered pointless for low-grade chondrosarcoma, but strongly recommended⁴⁹ for high-grade tumors. Instead of conventional radiotherapy, proton beam therapy has reportedly been used with promising results in this setting⁵⁰. That said, an inadequate follow-up and the pooling of results for chordoma and chondrosarcoma (without distinguishing between low-, medium-, and high-grade chondrosarcoma, or between total, gross total, and partial resections) make these results unreliable for the purposes of judging the efficacy of proton beam therapy, especially for low-grade chondrosarcoma.

Since partial removal is now accepted as a way to strike a balance between the goals of achieving a cure and limiting the morbidity of treatment, the significance of partial, subtotal, and gross total removal is still being debated. It is not clear where surgery should stop, and how small a residual should be for it to be considered curable with postoperative radiotherapy. Low-grade tumors are locally aggressive, but slow-growing and rather radioresistant, making the combination of partial surgery plus radiotherapy highly questionable^{29 51}.

Endoscopic approaches to chondrosarcoma of the petrous

apex have also been proposed, but some concern has been voiced over the safety and efficacy of this procedure. The boundaries of resection cannot always run along free margins, and, in principle, a gross total removal is already considered a success in this setting ⁵².

The reported 10-year survival rates for chondrosarcoma are 83%, 64%, and 29% for grades 1, 2 and 3, respectively (i.e. low-, medium-, and high-grade tumors, or well-, moderately-, and undifferentiated CS). A 10-year follow-up is considered essential to assess real disease control and obtain reliable survival rates because a 5-year follow-up may not always accurately reflect whether or not a patient is tumor-free ⁵¹.

Conclusions

Since low-grade chondrosarcoma grows slowly but continuously, an attempt to cure the disease, or at least control its progression, is mandatory. Surgical removal offers the best chance of cure, though radical surgery is often technically demanding, and associated with morbidities. It is important to strike the right balance between the goals of treatment and a patient's quality of life, but the complexity of surgery involving the central skull base should not tip the balance in favor of alternative treatments of still dubious efficacy.

The proposed new partial resections and adjuvant treatments must still face the test of time, since the meaningful follow-up of low-grade tumors takes longer than in the case of high-grade malignancies. When radical removal is feasible via an approach that carries a limited morbidity, the aim should be to cure the disease. Staged surgery is another viable option to cure extra- and intradural tumors.

Adjuvant therapies involving various forms of radiation are mandatory for high-grade tumors, hopefully not only as a complement to oncologically unsafe resections. In patients with a favorable prognosis, the disease can be cured with radical surgery alone, saving radiation therapy for the management of any late recurrences.

4.3.2. Endolymphatic sac tumours

G. Tealdo, L. Girasoli, D. Borsetto, E. Zanoletti

Endolymphatic sac tumor (ELST) is a rare malignancy occurring in the inner ear, on the posteromedial wall of the temporal bone originating from endolymphatic epithelium within intraosseous portion of duct or sac. ELST is a slow-growing low-grade malignancy with local aggressiveness (invasive growth pattern with infiltration of the petrous bone, destruction of the labyrinth and dura involvement) but low risk of distant metastases.

ELST is a highly vascularized tumor and is histopathologically characterized by papillary and glandular architecture; it was historically classified as primary adenomatous tumor of the

temporal bone and for years it was often misinterpreted as paraganglioma, metastatic renal cell carcinoma, choroid plexus papilloma, ceruminous gland adenocarcinoma, or aggressive papillary tumor. The first case of ELST was described in 1984 by Hassard et al. during sac decompression surgery for hydrops ¹; in 1989, Heffner reviewed 20 cases and established that papillary tumor of the temporal bone originated from the endolymphatic sac epithelium, referring to it as a "low-grade adenocarcinoma" ². The term "endolymphatic sac tumor" was first used by Li et al. in 1993 and afterwards recognized by World Health Organization tumor classification ³.

ELSTs may be sporadic or associated with von Hippel-Lindau (VHL) disease, a genetic disorder inherited as an autosomal dominant trait with a variable expression and caused by inactivation of the VHL tumor suppressor gene on the short arm of chromosome 3. Patients with VHL disease could present ELST from 3% to 24% of cases and they are also more likely to have bilateral ELST ⁴. VHL disease predisposes patients to multiple tumors and cysts in many organs that most frequently appear during young adulthood, such as hemangioblastomas in the central nervous system, clear cell renal carcinoma, pheochromocytoma, ELST, retinal angioma and pancreatic cystadenoma ⁵.

Common symptoms caused by ELST are sensorineural hearing loss, tinnitus, vertigo, dizziness, aural fullness, balance disturbances, ear pain, and facial nerve palsy. Hearing loss is the most frequent symptom and may be sudden or progressive, tending to develop at an early stage and is almost always irreversible. According to some studies, the development of a progressive hearing loss seems to correlate to a characteristic audiological pattern: in fact it has been suggested that a low-frequencies hearing loss is associated with small ELST while larger tumor are associated with profound sensorineural hearing loss that affect all frequencies ⁶. The audiovestibular morbidity in ELST is caused by various pathophysiological mechanisms: direct invasion of the otic capsule and inner ear apparatus, intralabyrinthine hemorrhage, and endolymphatic hydrops ⁵. However, ELST can also occur with normal hearing and remains relatively asymptomatic until significant surrounding tissue destruction has occurred. Late-onset symptoms are relating to tumor growth and invasion, toward cerebellopontine angle, medial cranial fossa, jugular foramen, fallopian canal, petrous apex or cavernous and sphenoid sinuses; the severity of the related functional impairment depends on the sites and subsites affected by the tumor's extension. Regional or distant metastases are very uncommon but a few metastatic cases in the spinal canal have been reported ⁷.

Neuroimaging is the gold standard in ELST diagnosis, including contrast-enhanced high-resolution magnetic resonance imaging (MRI) of the inner ear and computed

tomography (CT) of the temporal bone with thin-slice-bone algorithm. Specific radiological findings in MRI include hyperintense focal signals on T1-weighted unenhanced scan (due to hypervascularity), a markedly heterogeneous enhancement after gadolinium, and a heterogeneous signal on T2-weighted sequences. CT scan often demonstrates a focal erosion of the retrocochlear posteromedial border of the petrous temporal bone, with intratumoral spiculated calcifications⁴. Arteriography can provide further information on the involvement of intracranial vessels and may be useful in extensive tumors in order to plan a safe surgical procedure. Despite the fact that the slow growth of this tumor makes it difficult to diagnose early on, in recent years there has been an increase in number of reported ELST cases, that could be attributed to improvements in imaging methods and screening of VHL patients. The international recommendations on screening for ELST in VHL patients vary widely, although there is a common agreement on the importance of periodical neuroimaging (contrast-enhanced MRI and/or bone CT scan). The role of tonal audiometry to screen VHL patients for early diagnosis of ELST is still controversial; according to Lonser et al.⁸, audiometric examination is useful to integrate radiological data and to show the concomitant presence (or progression) of hearing loss.

Early and complete tumor resection is widely regarded as the treatment of choice in all cases of ELST. Total resection with adequate bone removal around the area of macroscopically evident tumor often leads to long disease-free intervals, while subtotal surgery involves persistence of the disease with a high risk of progression. Early treatment is crucial to prevent tumor recurrence in critical sites, where surgery would involve higher morbidity. VHL patients, who often suffer from blindness and impaired balance due to concomitant retinal and cerebellar hemangioblastomas, should be cured before other neurological impairment establishes as consequence of the ELST or of its late surgical removal. The “wait and see” strategy may be a temporary solution in VHL patients to enable the treatment of other concomitant tumors⁴ but carries the risk of delayed major surgery with increased morbidity.

Small ELST, when early diagnosis is followed by early surgery, is often related to hearing loss, without further surgical morbidity. This principle can be considered valid both with and without preoperative serviceable hearing, since it is difficult to ensure the removal of a small tumor within the endolymphatic sac and vestibular aqueduct without hearing loss or impairment. There are reports in the literature of small tumors being removed in which hearing was spared. For small ELSTs either a transmastoid-retrolabyrinthine approach or a retrosigmoid approach can be proposed, with preservation of inner ear structures and VII-VIII cranial nerves⁶.

Drilling of the petrous bone at the entrance of the

endolymphatic sac is crucial. Surgical treatment of extensive ELST requires the use of different lateral skull base approaches chosen according to tumor localization, tumor size, and invasion pathways⁴:

- translabyrinthine approach, for extension through labyrinth and/or intradurally in the posterior fossa;
- lateral or subtotal petrosectomy, for involvement of the middle ear;
- trans-sigmoid petro-occipital approach (POTS), for extension to the jugular foramen but preservation of the middle ear⁹;
- type A infratemporal approach, for involvement of the jugular foramen along the intrapetrous vertical carotid artery;
- transmastoid-transpetrous approach combined with a subtemporal/middle cranial fossa approach, for involvement of petrous apex or middle cranial fossa.

Before attempting a complete removal of an extensive ELST, surgeon should consider the intrinsic morbidity of each planned approach, the existing preoperative morbidity, the probability of complete tumor resection, the expected short-term and long-term prognosis and the life expectancy of the patient⁴.

Rehabilitation with cochlear implant may be proposed in all the cases where it has been surgically preserved the otic capsule and the cochleovestibular nerve, although the surgical trauma associated with tumor’s removal may prevent the proper functioning of cochlea. When ELST is bilateral (about in 30% of VHL patients) the cochlear implantation is the best solution that can be offered to the patient⁴.

The role of radiotherapy (stereotactic or fractionated) is still unclear and has been restricted by the limited available data. Radiotherapy should be considered in tumor recurrence, unresectable tumor, residual disease after subtotal resection, or in poor surgical candidates; in these cases, salvage radiotherapy might have a positive impact in terms of tumor control/tumor progression-free survival¹⁰.

Late recurrences are not so rare, therefore long follow-up is necessary to assess efficacy of treatment.

4.3.3. Posterior fossa meningiomas: the neuro-otologist perspective

G. Danesi, R. Bivona, V.C. Iglesias, D. Lepera, R. Pareschi

Introduction

Posterior fossa meningiomas (PFM) are a surgical challenge with high morbidity and potential mortality due to the surrounding vital structures, the encasement of nerves and vessels, the common large size at diagnosis, and their potentially invasive behavior. The natural history of these lesions suggests progressive growth with gradual neurological deterioration until death^{1,2}. Even if

total resection remains the gold standard for patients, the complete removal within the restrictions of acceptable morbidity is not always achievable.

Classification

Between 1996 and 2017 we treated 90 PFM in our two tertiary skull-base centers (Legnano and Bergamo - Italy). They were classified as retromeat, perimeatal and premeatal, according to the relationship between the main dural attachment and the IAC.

Retromeat meningiomas (posterior petrous bone (PB) meningiomas) originate from the dura of the posterior PB, between the posterior wall of the IAC and the groove of the sigmoid sinus. They occupy the posterior part of the cerebellar-pontine angle (PCA), usually dislocating antero-superiorly the acoustic-facial bundle. We diagnosed 21 cases of retromeat meningiomas; 18 patients presented an inframeatal extension encroaching the jugular foramen. In 2 cases the tumor extended extracranially into the neck and in 18 cases the dural attachment involved the tentorium with a transtentorial extension.

Perimeatal meningiomas arise from the dura in the contest of IAC and the dislocation of the nerves is unpredictable. We reported 19 perimeatal meningiomas.

Premeatal meningiomas (anterior PB meningiomas) arise from the dura around the porus trigeminalis (petrous apex (PA) meningiomas) or from the dura of the petroclival (PC) junction or directly from the clivus (PC meningiomas). They occupy the anterior part of the CPA and dislocate postero-inferiorly the acoustic-facial bundle, immediately behind the dura of the posterior PB. Premeatal meningiomas are more difficult to remove because the cranial nerves are located between the surgeon and the tumor. We reported 50 cases of retromeat meningiomas. Fifteen meningiomas of this group presented a tentorial or a transtentorial extension, with the invasion of the Meckel cave in 11 cases. In 9 cases, the invasion of the cavernous sinus, upper clivus and middle cranial fossa was evident.

Symptoms

Trigeminal symptoms (dysaesthesia and neuralgia) and abducent nerve palsy were more frequent in the premeatal group. Hearing and vestibular symptoms predominantly occurred in association with retromeat and perimeatal tumors. Others symptoms like headache, cerebellar signs had similar distribution between premeatal and retromeat groups.

Surgical approaches

The selection of surgical approaches (Table 4.3.3.I) were tailored according to the location and the extension of the tumor, growth direction, form and size, the main symptoms related to the invaded vital structures and on the basis of

Table 4.3.3.I. Selection of surgical approach according to the location and the extension of the tumor.

Retromeat	Premeatal	Perimeatal
RS	9	TLabTAp 20
TLab	7	TC 18
POTS	3	TLab+FAR LATERAL 1
RLabST	2	Combined petrosal 11

patient factors, such as age, general health, preoperative cranial nerve dysfunction, and preoperative hearing.

Common finding is that the retrosigmoid approach is perhaps one of the most commonly used surgical approaches for removing skull base meningiomas³. Considerations must be given to tumor invasion of the cavernous sinus and IAC, to their tentorial attachments, and their anterior expansion towards the jugular foramen. Retrosigmoid approach in such cases leads to residual tumor that is usually managed with radiosurgery. Since radiosurgery does not guarantee the prevention of the recurrence of tumors, complete surgical resection is still the main strategy. Transpetrous approaches requires a dedicated long-lasting training and a deep knowledge of the complex anatomy of the PB but have important advantages when compared to the retrosigmoid (RS) approaches:

1. The wide surgical field, a shorter working distance between the craniectomy and the tumor, and a better orientation toward the lateral and ventral brain stem, limiting the brain retraction.
2. The early resection of the osteo-dural insertion of the meningioma, with coagulation of the tumor's feeding vessels.
3. The early identification and control of the facial nerve before any dissection or removal of the tumor, and an increased protection of the anatomical and functional integrity of the facial nerve (except for the TCA).

For *retromeat meningiomas* the surgical approaches were: RS, translabyrinthine (TLab), petroccipital-transigmoid (POTS) and retrolabyrinthine-subtemporal (RLabST).

- The *RS approach* was indicated in all cases with a normal or socially useful preoperative hearing (Class A or B of Tokyo Classification)⁴. The size and the intrameatal extension of the tumor did not influence the choice of this approach. A standard lateral RS approach with the patient in park-bench position was used in this group. The RS approach is a versatile type of craniotomy extending from the sigmoid and the transverse sinus to the occipital squama. Opening of the dura and retraction of cerebellum gives a wide access to the CPA after an early drainage of the cerebellomedullary cistern. Retrolabyrinthine meotomy allows exposure of the IAC for the removal of

the intrameatal extension of the tumor with a high rate of hearing preservation.

- The *TLab approach* is indicated in all cases with a significant deterioration of the hearing (Class C, D or E of Tokio classification) ⁴ or in elderly patients with huge symptomatic tumors. The access of this approach is the mastoid and the target is the IAC and CPA. After a wide conservative mastoidectomy is performed, the occipital pre- and retrosigmoid dura along with the dura of the temporal lobe are exposed thus allowing for the retraction of sigmoid sinus with a significant widening of the surgical field. The posterior wall of the external auditory canal, the tympanic cavity, the cochlea and the facial nerve are left in place. The posterior labyrinth is completely drilled out together with the bone that is lateral, superior and inferior to the IAC. The canalicular dura is completely uncovered until the fundus and the facial nerve entering in the fallopian canal is evident. Once the approach is performed, the jugular bulb is the inferior limit and the temporal dura with the superior petrous sinus are the superior limits. The presigmoid dura is transected and the CPA is widely exposed.
- The *POTS approach* has been developed for removing tumors located in the jugular foramen together with their local extension into the adjacent parts of the skull base, the CPA, and the parapharyngeal space (PPS). POTS approach involves a posterolateral exposure and an anteromedially directed surgical axis which allows the surgeon to leave the external and middle ear complex, together with the facial nerve, entirely undisturbed. Single-stage removal of intra- and extradural lesions extending from the CPA to the PPS can be achieved with minimal risk of cerebrospinal fluid (CSF) leak. In essence, the POTS approach is the combination of a retrolabyrinthine petrosectomy and retrosigmoid craniotomy. The external ear canal, tympanic cavity, and facial nerve are left in situ ⁵.
- The *RLabST* is one of the most limited of the transpetrosal approaches of the posterior fossa. After a wide conservative mastoidectomy is performed the sigmoid sinus is skeletonized inferiorly through the infralabyrinthine air cells to the jugular bulb. Complete skeletonization of the facial nerve is unnecessary. All three semicircular canals are therefore skeletonized but preserved. Removal of the bone plates on the middle and posterior fossa dura mater and the sigmoid sinus completes the extradural part of the retrolabyrinthine approach. This approach provides exposure of the CPA but does not give the surgeon adequate visualization of the anterior brainstem or petroclival region ⁶.

For *perimeatal meningiomas*, the TLab surgical approach was performed.

For *premeatal meningiomas*, the surgical approaches

performed were mainly the translabyrinthine/transapical approach (TLabTAp) and the transcochlear approach (TC), only one case initially treated with a TLab surgery then requested a far lateral approach, in 11 cases combined petrosal approaches were performed.

- The *TLabTAp* is an anterior extension of the TLab in which the internal auditory canal is exposed 360° around its circumference. The cornerstone of this approach is the postero-inferior transposition of the acoustic-facial bundle in continuity with the intracisternal tract that, for premeatal meningiomas, is usually located in the interface between the posterior PB dura and tumor. This maneuver respects the functional integrity of the facial nerve (if it is not infiltrated by the tumor) allowing for the complete drilling out of the bone and the exposure of the dura around the porus trigeminalis (PA). The postero-inferior dislocation of the acoustic-facial bundle opens a corridor to the anterior CPA through which the removal of large PA and PC meningiomas is possible. The limit of this access is the midline extension of the tumor. An extension beyond this line should be treated by a TC approach.
- The *TC* represents the widest available access to the posterior fossa. It allows for the exposure of the omolateral CPA, prepontine area and contralateral CPA. This approach is indicated for giant PA, PC or clival meningiomas extending beyond the mid-line, between the clivus and the pons. Compared with the TLabTAp, TC approach presents some additional surgical steps: 1) the removal of outer ear canal and tympanic cavity with closure of the external ear canal; 2) total petrosectomy extended to the middle and lower clivus located medially to the cochlea and the vertical tract of the petrous internal carotid artery (ICA); and 3) the postero-inferior transposition of the intratemporal facial nerve along with its intrameatal tract. This maneuver does not allow the functional integrity of the facial nerve. After surgery, a grade III facial palsy (according to the House Brackmann Classification) ⁷ is the best result that can be obtained and this is the most important draw-back of this approach.
- *Combined petrosal approaches* actually describe numerous surgical approaches to the petroclival area well suited for these tumors. The transtentorial step was necessary in ten of them where the dura of the middle fossa above the superior aspect of the petrosal bone and the tentorium over the trigeminal nerve are resected. Indications to the transtentorial approach are: lesion extending from the PF to the midbrain, lesions extending from the middle fossa to the PF and lesions arising from the tentorium.

Tumor resection

It is clear that a complete resection is important, as the extent of resection influences the rate of recurrence, which in turn influences the prognosis. However, deliberate residuals must

Table 4.3.3.II. Extent of tumor resection.

	Description	Retromeatal	Premeatal	Perimeatal
Simpson Grade 1-2	GTR ($p < 0.001$)	20/21 (95.2%)	38/50 (76%)	19/19 (100%)
Simpson Grade 3	NTR	0/21 (0%)	4/50 (8%)	0/19 (0%)
Simpson Grade 4-5	PTR	1/21 (4.7%)	8/50 (16%)	0/19 (0%)

be taken into account, and pieces of tumor are deliberately left in situ when pia mater, jugular foramen, cavernous sinus and Gasser ganglion are infiltrated. The extent of tumor resection was defined by the intraoperative findings using the Simpson Classification ⁸. The Simpson Grade 1 and 2 corresponded to a gross total resection (GTR). Simpson Grade 3, 4 or 5 are related to a non-total resection (near total or partial resection).

GTR was achieved in 69/90 patients, 77%. In retromeatal meningiomas, a total resection was obtained in 20/21 cases (95%). In perimeatal meningiomas GTR was obtained in all cases. In premeatal meningiomas, GTR was 76%, reflecting their difficult surgical treatment. A Grade 3 (near total resection) was evident in 4/90 patients (4%), and Grade 4-5 (partial resection) in 9/90 patients (10%) (Table 4.3.3.II; Fig. 4.3.3.1). The main tumor residual was represented by the transtentorial extension (20%) and the involvement of jugular foramen (8.8%), the gasser ganglion and the cavernous sinus (1% respectively). Moreover, the consistency, bleeding and adherence of the tumor to the brain stem and to vessels prevented their total removal, permitting only brain-stem decompression.

The GTR according to the surgical approach is reported in Table 4.3.3.III.

Morbidity

Many surgery-related morbidities worry both patients and surgeons. Thanks to the different surgical approaches, a HB

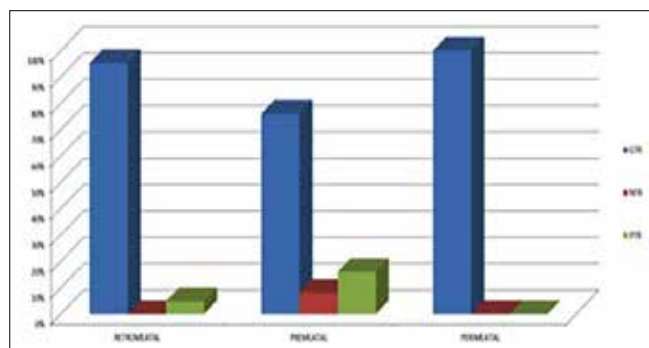


Fig. 4.3.3.1. Rate of GTR, NTR, partial resection.

Table 4.3.3.III. GTR according to the surgical approach ⁶.

GTR according to the approach	
TLabTAp	18/20 (90%)
TC	13/18 (72.2%)
RS	9/9 (100%)
POTS	1/3 (33.3%)
TLab+FL	0/1 (0%)
TLab	19/26 (73%)
RLabST	2/2 (100%)
Combined petrosal	7/11 (63.6%)

Grade 1-2 was achieved in 69% of our patients. Choosing a different approach for the 3 categories led us to achieve a low rate of morbidity, particularly in retromeatal and perimeatal groups. 90% of patients in these groups lacked complications. Retromeatal tumors represented the more accessible tumors in our series. A postoperative HB Grade 1-2 was achieved in all cases except in one TLab approach (Table 4.3.3.IV).

Premeatal tumors are the most critical due to their anatomical correlations, with facial nerve function affected in half of the patients. However, despite of the high surgical risks in treating these tumors, we eventually achieved a 24% lack of complications.

Hearing function interestingly is not as deeply considered as facial nerve function in the literature. Transcochlear and translabyrinthine approaches require a sacrifice of hearing but often the decision to proceed with these approaches is made because of large tumor extension involving the IAC, petrous ridge, clivus, or cavernous sinus, or because of brainstem compression or basilar artery involvement. Moreover, as previously shown, these approaches let us achieve a very high rate of GTR accounting about 73% for TC and TLab approach themselves. In retromeatal meningiomas, a postoperative Class A-B (Tokyo classification) was obtained in 12 out of 14 patients (85.7%). In premeatal and perimeatal meningiomas hearing preservation was attempted only in 11 patients with small or middle size premeatal meningiomas, with the largest diameter of maximum 2.5 cm. This goal was achieved managing the tumor by a combined petrosal approach.

Additionally, we reported 9/90 (10%) cases of IV, V and VI c.n. palsy, and 4/90 (4.4%) cases of lower cranial nerves palsy (Table 4.3.3.V). In 1 case we reported an ab-ingestis pneumonia and no cases of perioperative death, cerebrospinal fluid leakage or meningitis occurred.

Conclusions

Total resection is the only way to cure patients affected by PFM. GTR is the aim of surgery as the extent of resection influences the rate of recurrence, which in turn influences the prognosis. We aimed to show how different surgical approaches might help to reach GTR and low morbidity,

Table 4.3.3.IV. Postoperative facial nerve function.

HB in retromental	TLab	POTS	RLabST	RS
I-II HB	6/7 (85.7%) (p < 0.001)	3/3 (100%)	2/2 (100%)	9/9 (100%)
III HB	1/7 (14.2%)	0/2 (0%)	0/2 (0%)	0/9 (0%)
IV-V-VI HB	0/7 (0%)	0/2 (0%)	0/2 (0%)	0/9 (0%)
HB in perimeatal		TLab		
I-II HB	17/19 (89.4%) (p < 0.001)			
III HB	2/19 (10.5%)			
IV-V-VI HB	0/19 (0%)			
HB in Premeatal	TLabTAp	TC	TLab + FL	Combined petrosal
I-II HB	16/20 (80%) (p < 0.001)	0/18 (0%)	0/1 (0%)	9/11 (81.8%)
III HB	2/20 (10%)	15/18 (83.3%)	0/1 (0%)	0/11 (0%)
IV-V-VI HB	2/20 (10%)	3/18 (16.6%)	1/1 (100%)	2/11 (18.1%)

Table 4.3.3.V. Postoperative morbidity.

	Retromental	Premeatal	Perimeatal
None	17/21 (80.9%)	12/50 (24%)	17/19 (89.4%)
CN's IX-X-XI-XII	3/21 (14.2%)	1/50 (2%)	0/19 (0%)
CN's IV-V-VI	0/21 (0%)	9/50 (18%)	0/19 (0%)
CN VII	1/21 (4.7%)	25/50 (50%)	2/19 (10.5%)
Trigeminal signs	0/21 (0%)	2/50 (4%)	0/19 (0%)
Cerebellar signs	0/21 (0%)	1/50 (2%)	0/19 (0%)

especially on facial nerve function. In this study, we reviewed a large sample size of 90 patients with PFM. Though it is generally considered challenging to resect tumors at this location, different approaches bring satisfactory results with an excellent extension of resection, preservation of cranial nerves, and low complication rates in our two centers.

4.3.4. Lateral skull base meningiomas: the neurosurgeon's perspective

F. Calbucci, I. Borghesi, A. Fioravanti, S. Bartolini, R. Draghi

Lateral skull base meningiomas involve middle and posterior cranial fossae. They develop mainly from the lesser sphenoid wing and from the petrous bone. Most medial forms of both these locations typically involve arteries and cranial nerves, and may even involve the cavernous sinus, making tumor removal particularly challenging and, in some cases, incomplete.

On the contrary, in the case of meningiomas which develop and grow more laterally, control and removal of the lesion is usually far more simple.

Sphenoid wing meningiomas

These tumors are traditionally divided into meningiomas of the medial, middle and lateral third of the lesser sphenoid wing. Medial third meningiomas, usually known as anterior clinoid meningiomas, can extend to the cavernous sinus and the orbit. Meningiomas of the middle and lateral thirds of the lesser sphenoid wing are the simplest to remove. These tumours grow mainly in the middle cranial fossa displacing the frontal and temporal lobes and involve the middle cerebral artery and its branches to a greater or lesser extent, depending on their size.

Pterional craniotomy is the most suitable approach. More complex approaches, such as fronto-orbital and, all the more so, fronto-orbital-zygomatic craniotomy, are not indicated as the tumor itself creates enough room to allow a good control of the lesion and of the neurovascular structures with no need to extend the craniotomy, if not to the sphenoid wing. This makes it possible to 'transform' a basal tumour into a convex meningioma, which is far easier to remove.

Their removal has a very low morbidity and mortality rate¹. Although the resection of medial sphenoid wing meningiomas is more problematic, wider craniotomies are not really indicated. For these lesions, it is debated whether there is an advantage in unroofing the optic canal before tumour resection, in order to allow a safer manipulation of the optic nerve and to control any extension of the lesion into the canal itself. Visual alterations are, in fact, the main symptom of medial sphenoid wing meningiomas.

If the cavernous sinus is involved, current practice prefers to avoid removing this part of the lesion in favour of subsequent treatment with radiosurgery²⁻⁴.

Given the involvement of the optic nerve as well as of the major branches and, above all, of the smaller branches of the internal carotid artery, the outcome of the resection of these meningiomas is associated with a higher rate of complications and incomplete removal³⁻⁶.

Petrous bone meningiomas

Petrous bone meningiomas arise from the posterior surface of the petrous bone i.e. from its infratentorial aspect. Very infrequently do these meningiomas extend to the middle fossa, on the supratentorial surface of the petrous bone, but, when they do, the lesion often grows simultaneously on both sides of the petrous bone (Fig. 4.3.4.1).

Surgical resection of a tumour growth on the middle cranial fossa is not so difficult, given the absence of important vessels and cranial nerves. Nevertheless, it requires the elevation of the temporal lobe and manipulation of the basal temporal veins, including the vein of Labbé. The inferior

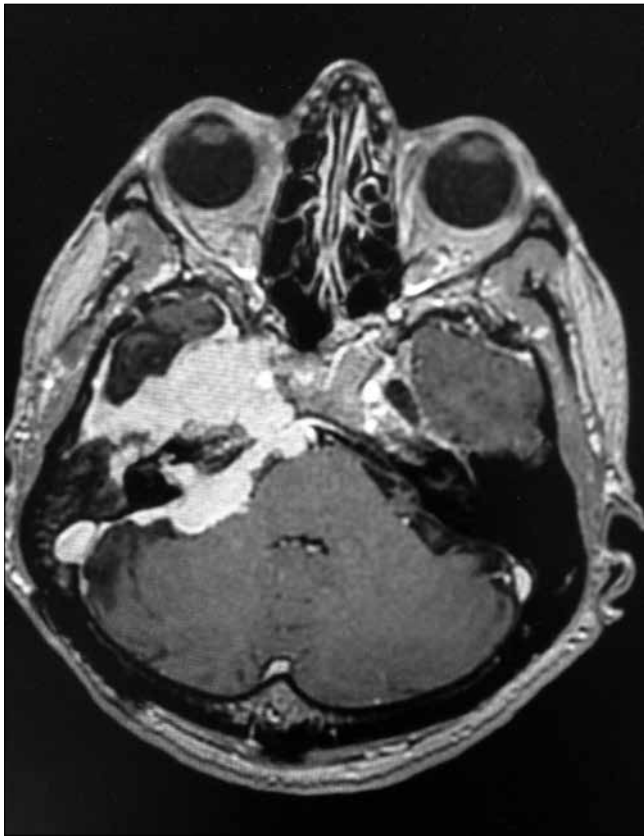


Fig. 4.3.4.1. Meningioma arising on both sides of the petrous bone (middle and posterior fossae).

border of the posterior temporal craniotomy must be as near as possible to the middle fossa floor to minimize brain manipulation, as in subtemporal approaches to the internal acoustic meatus (although this is an extradural route) or to the clivus (Kawase’s approach).

Petrous bone meningiomas are generally considered to be the tumours arising from the posterior aspect of the petrous bone, once known as Cerebellopontine Angle Meningiomas. Currently, the latter term is no longer acceptable since these lesions are by no means a homogeneous group of tumours. Surgical difficulties and outcomes greatly depend on the site of origin of the meningioma. For this reason, several classifications have been proposed in the literature, taking this heterogeneity into account⁷⁻⁹.

Our group has adopted a useful classification, taken in part from the literature but mostly from first-hand experience of more than 120 patients operated on, which divides meningiomas into four groups (Fig. 4.3.4.2).

- A – Meningiomas developing from the petrous bone, posterior to the Internal Acoustic Meatus (IAM). These lesions are often large, but technically do not present many surgical difficulties as the tumour is not in close relation to the cranial nerves, which are pushed forwards

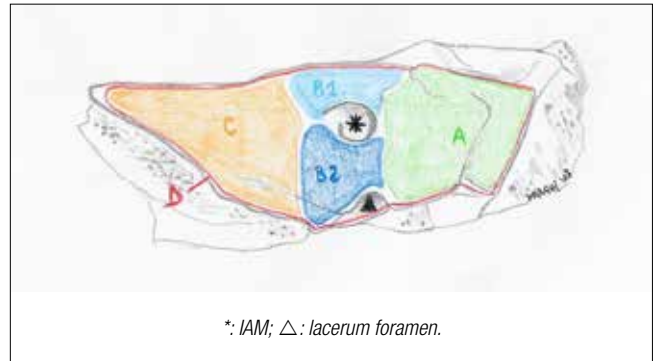


Fig. 4.3.4.2. The dural origin of the different groups of petrous bone meningiomas: A group, green; b1 subgroup, light blue; b2 subgroup, blue; C group, orange; D group, area included in the red line.

(V, VII and VIII) or inferiorly (lower cranial nerves) and protected by a generally well-preserved arachnoid layer. In the majority of cases, cleavage from the cerebellum is simple. The main vessels are not significantly involved. The dural attachment can be removed.

- B – Meningiomas arising from the dura mater around the IAM. These tumours are surgically more challenging due to their extremely close proximity to cranial nerves and vessels. These lesions, in turn, are divided into meningiomas growing between the IAM and the tentorium (b1 subgroup) and those developing between the IAM and lacerum foramen (b2 subgroup).
 - b1 – Given the dural attachment and growth direction of the lesions, these meningiomas displace the VII and VIII nerves inferiorly, adhering to or encasing them. Similarly, the IV and V nerves are usually pushed forwards and upwards, to varying degrees. The Superior Cerebellar Artery (SCA) and the Anterior Inferior Cerebellar Artery (AICA) are frequently involved. Adhesions to the tentorium are not usually firm, while the removal of the dural attachment is not easy to achieve. Surgical outcomes are often associated with cranial nerve deficits. Vascular damage to arteries as well as veins (in particular the petrous vein) may have severe consequences.
 - b2 – Removal of these meningiomas, growing between the IAM and lacerum foramen, is far more challenging as they involve the lower cranial nerves. The VII and the VIII cranial nerves are usually pushed upwards, but the lower cranial nerves can be encased by the tumor and their bundles variously separated and adherent to the lesion. The Posterior Inferior Cerebellar Artery (PICA) is often involved. Surgical removal in these cases is frequently partial or subtotal and associated with more severe neurological deficits.
- C – These are a group of small meningiomas which develop medially to the IAM. They are not called

“petroclival meningiomas” as tumours medial to the IAM are generally defined, because, given their small size, they are confined to the apex of the petrous bone. For this reason, they are also known as “petrous apex meningiomas”.

These can cause severe trigeminal neuralgia which is difficult to treat and which often disappears after tumour resection. These meningiomas are not difficult to remove, if it weren't for their deep position and proximity to the IV and V nerves.

- D – These tumours are defined as “broad-based meningiomas”. Their attachment spreads over most of the posterior surface of the petrous bone, hence, they are the most difficult to remove. They are generally large in size and surgical removal carries the same difficulties and risks as all the previous groups. Partial removal and poor control of dural attachment are not infrequent.

Pre-operative MRI can establish different meningioma types and assess the likelihood of success, together with the potential risks of surgery. However, the extent of resection and surgical outcome also depend on a very important variable, which cannot be assessed before surgery: the consistency of the meningioma, which can worsen the outcome of surgery if the tumour is fibrous.

Retrosigmoid craniotomy is the best procedure in all described groups. Transpetrous approaches have no real advantage and are rarely used in these cases ^{7 10}.

Petroclival meningiomas

Petroclival skull base meningiomas are the most difficult to treat and carry the highest surgical risks. By definition, these lesions develop from the clivus and grow towards the petrous bone, medially to the IAM and upwards, to the upper third of the clivus. They often involve the cavernous sinus and middle fossa (Sphenopetroclival meningiomas).

These tumours can be very large, although onset symptoms are frequently mild (e.g. slight instability, hearing loss, facial hypo-dysesthesia).

Most posterior fossa cranial nerves, the cerebellar arteries, the basilar artery and its perforating branches, are often involved.

Given the deep-seated nature of these lesions, beyond the cranial nerves of the cerebellopontine angle, surgeons are forced to operate in very narrow spaces between the nerves. Thus, as already mentioned, the resection of these meningiomas is challenging and involves a significant risk of damage to the cranial nerves and brainstem vessels ¹¹.

In order to reduce these risks and increase the extent of resection, several approaches have been studied and adopted in order to obtain the best surgical exposure and good control of the tumor and of the neurovascular structures. These procedures include transpetrous, subtemporal, one-step or multi-step supra and infratentorial, combined, retrosigmoid

and frontotemporal approaches with tentorium incision and, more recently, endoscopic transnasal approaches ^{12 13}.

To date, there is no general consensus as to the best approach or as to whether there is a single approach which can be suitable in all cases. After years of debate and an ever wider range of treated cases, it is now generally agreed that the simplest and technically least difficult approach with the lowest risk of approach-related complications is to be preferred, ensuring at the same time the easiest and safest tumour removal.

It is also important to mention adjuvant treatment such as radiosurgery, which has proven to be effective in many cases in the event of remnants or tumour recurrence ^{14 15}.

In conclusion, we may suggest this algorithm for the treatment of petroclival meningiomas ¹⁶.

In meningiomas limited to the posterior cranial fossa which extend laterally to the petrous bone, the retrosigmoid approach is the best choice, ensuring total tumour control. The approach is simple, quick and carries a low risk. Furthermore, any small supratentorial components can be removed by incising the free edge of the tentorium and/or drilling the upper border of the petrous apex ^{17 18}.

If the meningioma extends significantly to the middle fossa, the presigmoid transpetrous approach (which preserves the labyrinth and divides the superior petrous sinus and tentorium) is useful to gain access to and control the lesion in both its supra and infratentorial components. However, it must be pointed out that the elevation of the posterior temporal lobe and manipulation of its basal veins, especially on the left side, entails some risks.

In meningiomas with main extension to the median clivus – for which the extended endoscopic transsphenoidal approach is currently an option of great interest – the transpetrous approach can be performed, with possible removal of the labyrinth to achieve a better and wider control of the deep-seated lesion, especially if hearing is already damaged. The transcoclear approach, which has a very high risk of facial nerve damage ^{19 20} and very few advantages compared to the previously described approaches, is not indicated.

In sphenopetroclival meningiomas (with the involvement of the sphenoid wing, middle fossa, cavernous sinus, tentorium, clivus and petrous bone) a two-step removal of the supratentorial portion (with a pterional approach) and of the infratentorial portion (with a retrosigmoid approach), combined with radiosurgery treatment of cavernous sinus remnant can be considered a safe and undemanding therapeutic option. Nevertheless, several authors still recommend a one-step combined supra and infratentorial approach ^{21 22}.

Finally, we should never forget that, after the approach comes the most important part of surgery: removal of the tumour, which often encases vessels and nerves, displaces the brainstem, requiring strenuous and long hours of work.

4.3.5. Primary squamous cell carcinoma of the temporal bone

G. Marioni, A. Lovato, A. Mazzoni, E. Zanoletti

Introduction

Squamous cell carcinoma (SCC) originating from the external auditory canal and extending into the temporal bone is an aggressive malignancy accounting for under 0.2% of all head and neck tumors¹.

This critical analysis concerns temporal bone SCC (TBSCC), its rational preoperative assessment and staging, the efficacy of different treatments by tumor stage, the main currently-used and promising prognostic factors.

Diagnosis

TBSCC is usually diagnosed late because early signs and symptoms are not specific. Most patients initially complain of symptoms that are frequently attributed to inflammatory ear diseases. Facial nerve palsy at presentation is considered a sign of advanced disease¹. Early diagnosis is crucial to prompt treatment.

Micro-otoscopy with extensive, multiple biopsies is essential to the diagnosis and histological characterization of TBSCC. The primary tumor is assessed by combining temporal bone high-resolution computed tomography (CT) with contrast-enhanced magnetic resonance imaging (MRI). High-resolution CT is mandatory for its sensitivity in detecting early bone erosion (often the first sign of the disease spreading locally). Contrast-enhanced MRI shows the tumor's extent and better differentiates it from non-neoplastic soft tissue; it can reveal petrous apex or temporomandibular joint involvement, dura mater invasion or intracranial spread^{2,3}. Cervical metastases are confirmed in about 18% of cases, often involving the intra-parotid lymph nodes as well as neck levels I and II^{4,5}. CT and MRI are generally reasonably reliable for detecting nodal metastases, and for planning curative neck dissection⁶. Distant metastases of TBSCC are rather unusual and believed to occur late, with deposits in lung, bone, liver, and brain⁴. They should be ruled out with total-body positron emission tomography (PET) before planning any treatment⁷.

Staging

No internationally-accepted staging system is available for TBSCC. Classifications have been proposed, but none have been endorsed by the International Union Against Cancer or the American Joint Committee on Cancer. Moody et al.⁸ suggested updating the Pittsburgh system to focus on clinical facial nerve involvement, based on the assumption that nerve palsy indicates the middle ear's medial wall or mastoid invasion. This is the most often used system for staging TBSCC for now, as recently recommended by the

UK's Multidisciplinary Guidelines on lateral skull base cancer management³.

Treatment

Surgery on primary tumor

Radical surgery is the mainstay of TBSCC treatment, and negative surgical margins a fundamental prognostic factor. Clinical research has focused on two main surgical options: en bloc resection along anatomical planes of dissection through normal tissue, or piecemeal removal of the tumor until normal tissue is found. En bloc temporal bone resection may be lateral, subtotal or total and, unlike the piecemeal approach, it provides a full specimen for histology, enabling correlations between clinical and pathological features, and outcomes⁹. Curative surgery for TBSCC is contraindicated in cases of cavernous sinus involvement, massive intracranial invasion, unresectable neck disease, distant metastases, and poor general health. Dura mater infiltration does not contraindicate surgery (which can be done without further morbidity), but it carries a dismal prognosis¹⁰.

Neck surgery

The external ear canal and middle ear are drained by the parotid and periparotid, pre- and postauricular, submandibular, upper deep cervical and retropharyngeal lymph nodes. Clinically positive necks must always be treated in patients with TBSCC, but whether and how to treat clinically negative necks is still debated. Lymph node involvement in TBSCC is relatively uncommon (10-23%), with levels I and II the most often affected⁵. Elective neck dissection (preferably a selective neck dissection [I-III]) is recommended in all patients with locally-advanced TBSCC and clinically negative nodes¹.

Parotid gland surgery

TBSCC may extend directly into the parotid gland, or involve the gland's first-line draining nodes. Parotid involvement reportedly occurs in 10-62% of cases¹¹. Some surgeons routinely include a superficial parotidectomy in en bloc resections for TBSCC, even in patients with no clinical or radiological signs of salivary gland involvement or close margins^{3,5}.

Other treatments

Radiotherapy (RT) alone is rarely curative, but most authors advocate total doses of 65-75 Gy for inoperable patients¹². Common side effects of RT include bone and/or soft tissue necrosis. RT seems a reasonable palliative option for unresectable disease extending beyond the dura mater.

Adjuvant postoperative RT is indicated for advanced (T3-T4) TBSCC, intracranial invasion, or aggressive pathological features such as perineural/vascular invasion, close (< 5 mm) or positive surgical margins, lymph node metastases, or extracapsular spread¹³. Though not all agree, numerous authors advocate postoperative RT for T2 TBSCC too, given its aggressiveness⁵.

The value of chemotherapy is still not clear, but it seems to have a role in advanced (especially T4) disease, residual disease, and metastases^{2,14}. Nakagawa et al.¹⁵ reported using preoperative chemo-radiotherapy (CRT) for TBSCC, and others have since done so too¹⁶. Various anticancer drugs (including cisplatin, carboplatin, fluorouracil, and docetaxel) were used in very small case series of TBSCC, but recent findings suggest that TPF (docetaxel, cisplatin, and 5-fluorouracil) is safe and effective as the first option in this setting^{17,18}.

Prognosis

TBSCC patients' prognosis and overall survival vary considerably, depending on disease stage at diagnosis, treatments, and oncological radicality of surgery. The primary tumor's extent (T stage) is a very important prognostic factor, even more than N stage. Medial or posterior spread to the otic capsule, mastoid, infra-labyrinthine area, para-pharyngeal spaces, and dura mater carries a worse prognosis. A literature review (spanning 1976-2008) by Higgins and Antonio (19) pointed to facial nerve involvement as a negative prognostic factor. Most studies found no correlation between prognosis and pathological grade¹, whereas positive surgical margins at histology⁵, and distant metastases carry a poor prognosis¹.

Recurrent TBSCC treatment and prognosis

Disease-related mortality rates are high for TBSCC recurring after treatment. A literature review spanning 1995-2013 found a disease-specific survival of 18% to 65% for stages III-IV. Salvage surgery with curative intent might be feasible for early recurrences if radicality is still achievable¹. A preliminary investigation supported other palliative treatments (chemotherapy, RT, or specialist care) in cases of loco-regionally advanced recurrent TBSCC⁷.

Follow-up

There is a paucity of precise guidelines on the follow-up of surgically-treated TBSCC patients. Zanoletti et al.⁷ recently recommended at least: clinical examination and contrast-enhanced head and neck MRI every 2 months in the 1st year, every 4 months in the 2nd, and every 6 months in the 3rd to 5th years. In a cohort of patients with recurrent TBSCC, the same authors found that distant metastases were diagnosed 6 to 15 months after primary treatment. In 2001, Sasaki⁴ recommended annual chest CT to detect distant metastases in patients with TBSCC. Nowadays, total-body PET could be used to detect loco-regional TBSCC recurrences and distant metastases.

Diagnostic and therapeutic prospects

Molecular changes in malignancies occur before any morphological changes are visible, and are responsible for prognosis, and response to primary therapy. Biomarkers that might reflect the biological features of TBSCC are now being

investigated²⁰. CD105 expression (in tumor vessel endothelial cells) and MASPIN cytoplasmic expression (in carcinoma cells) were found directly and inversely related, respectively, with TBSCC recurrence rates^{21,22}, and epidermal growth factor receptor (EGFR) expression was found significantly associated with a poor survival²³. A case of advanced TBSCC treated with the EGFR inhibitor cetuximab and RT, achieving a complete response and a disease-free two-year follow-up has recently been reported²⁴.

Conclusions

Managing TBSCC is a challenge, even at expert centers adopting precise guidelines on its diagnosis, staging, treatment and follow-up. TBSCC should be managed by multidisciplinary teams of oto-neurosurgeons, head and neck surgeons, plastic surgeons, oncologists, radiotherapists, dedicated radiologists, and pathologists (at least), particularly in advanced cases. Prospective, randomized, multi-institutional (and preferably international) studies are needed to compare TBSCC treatment outcomes and develop appropriate guidelines.

4.3.6. Petrous bone cholesteatoma

D. Zanetti, G. Conte, L. Magnoni, F. Di Bernardino

Introduction

Petrous bone cholesteatoma (PBC), also defined as "invasive" or "medially extensive" cholesteatoma, is a lesion located medial to the otic capsule. It accounts for 10% of the lesions involving the petrous pyramid^{1,2}. Compared to middle ear cholesteatoma it is rare, representing less than 4% of all temporal bone cholesteatomas; its incidence has remained stable during the last 4 decades².

PBC can be congenital, arising from ectodermal embryonic remnants within the otic capsule, acquired (post-otic), or iatrogenic, after failure of previous middle ear surgery³. Histologically the 3 etiological variants are indistinguishable: they all present as a collection of desquamated epithelium, keratin, and cellular debris, sharing similar histologic features with odontogenic keratocysts and epidermal cysts.

After remaining silent for years, they manifest with either otorrhea, vertigo, otalgia or their combination, followed by facial nerve weakness and tinnitus^{2,4}; in Danesi's⁵ series no patient complained of vertigo pre-operatively, possibly due to long-standing vestibular areflexia related with the advanced extension of the disease at the time of surgery, often associated with multiple fistulas. In Álvarez's⁶ series of 25 patients, ¾ presented with facial paresis. Intracranial suppurative complications, such as recurrent aseptic meningitis⁷ are frequently encountered in PBC, especially in populations living in lower socio-economic conditions.

A classification of the site and extension of PBCs was initially proposed by Fisch, who separated supra- and infra-

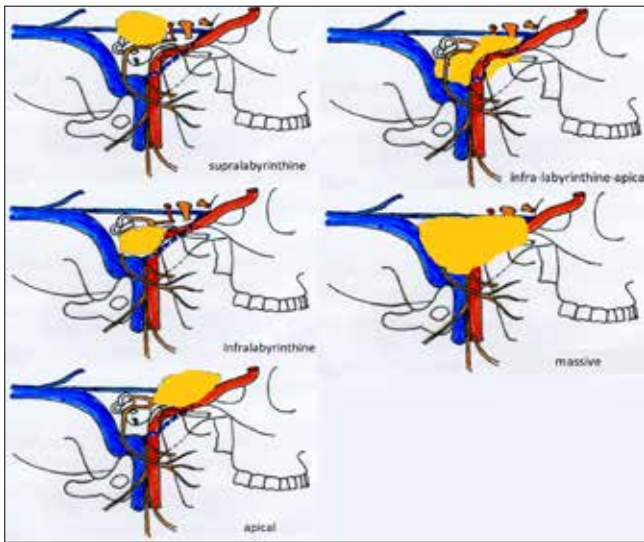


Fig. 4.3.6.1. Schematic drawing of Sanna's classification of PBC (see text for detailed description).

labyrinthine lesions. In 1993 Sanna et al categorized petrous bone cholesteatomas into 5 Classes: Class I, supralabyrinthine; Class II, infralabyrinthine; Class III, infralabyrinthine-apical; Class IV, massive; and Class V, apical (Fig. 4.3.6.1). Later on, the same Authors⁴ added another stage for disease extending beyond the borders of the temporal bone.

Despite its slow-growing habit, the osteolytic capacity of PBC leads to exposure and adhesion to relevant anatomical structures such as the facial nerve, carotid artery and dura mater. In Danesi et al.⁵ series of 81 patients, a labyrinthine erosion/fistula was evident at surgery in 83% (infralabyrinthine/apical) to 100% (apical and massive) cholesteatomas. A cochlear erosion appeared again in all cases of massive PBC, while it was less frequent in other stages of the disease; erosion and infiltration of the internal auditory canal (IAC) was present in 100% of massive and ¾ of the infralabyrinthine/apical cholesteatomas. Conversely, an intracranial erosion and CSF leak occurred rarely.

Surgery is the only accepted treatment. Given the complex anatomy of the petrous bone, surgical removal of these lesions can be very challenging. A single best approach has not yet been identified.

Frequent post-operative complications or sequelae include cerebrospinal fluid (CSF) leaks, facial nerve palsies and anacusis⁸; recurrence is highly likely⁶.

Advances in imaging

Multisection computed-tomography (MSCT) is the traditional technique of choice when cholesteatoma is clinically suspected, providing a spatial resolution of 0.4 x 0.4 mm in plane and 0.5 mm in slice thickness. In the last years the use of flat-panel CT (FPCT) has taken place in clinical practice,

being preferred for its higher spatial resolution and lower radiation dose^{9,10}. Typically, PBC appears as an expansive soft-tissue mass in the apical portion of the petrous bone, with large areas of bone reabsorption (Fig. 4.3.6.2). CT yields high negative predictive value in diagnosing cholesteatoma, ruling out the presence of cholesteatoma when the tympanic cavity is well pneumatized. Conversely, CT has a low specificity because it cannot easily differentiate cholesteatoma from other soft-tissue masses¹¹. Typical CT findings associated to a soft-tissue mass within the petrous apex that suggest a PBC (even if the tympanic membrane is normal at otomicroscopy) are the erosion of the tegmen tympani, the posterior and inferior wall of the petrous pyramid, the carotic canal and, sometimes, the upper clivus. In literature, bony erosion has been reported from 50 to 97% of CT scans of patients with histologically-proven cholesteatoma, thus resulting as a reliable (but not perfect) imaging marker¹¹. The density values of cholesteatoma are not significantly different from those of the other petrous bone lesions. Thus, CT is unable to differentiate cholesteatoma from inflammatory or scar tissue. Its value is the high spatial resolution that allows defining the localization and extension of the PBC and the signs of erosion of relevant bony structures such as the tegmen, the Fallopian canal, the labyrinth and cochlea, the internal carotid artery (ICA), the jugular bulb (JB) and the sigmoid sinus.

Magnetic Resonance Imaging (MRI) usually provides complementary information compared to CT. It is superior in differentiating cholesteatoma from mimicking lesions but it is inferior in defining its localization and extension because of the lower spatial resolution. For these reasons, MRI is indicated after CT, when the latter and the clinical examination are not conclusive in the diagnosis or when a recurrence is suspected after surgery. MRI protocol for PBC includes multiplanar conventional T1-weighted and T2-weighted sequences, and diffusion-weighted (DW) sequences (Fig. 4.3.6.3)

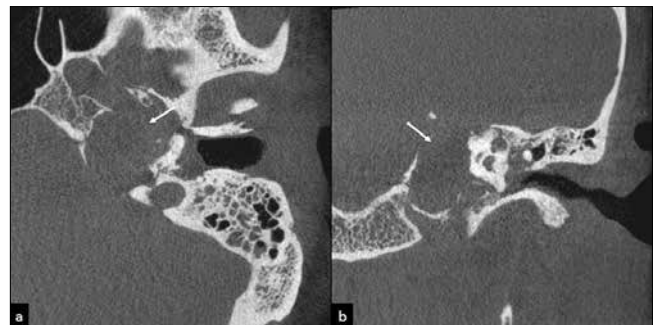

Fig. 4.3.6.2. A 38 years-old male with recent vertigo and recurrent otorrhea. Flat-panel CT scans (a: axial; b: coronal) showed a soft-tissue mass occupying the left petrous apex (arrow), determining a large erosion of the anterior, superior and posterior surface of the petrous pyramid, suggesting the presence of an invasive cholesteatoma.

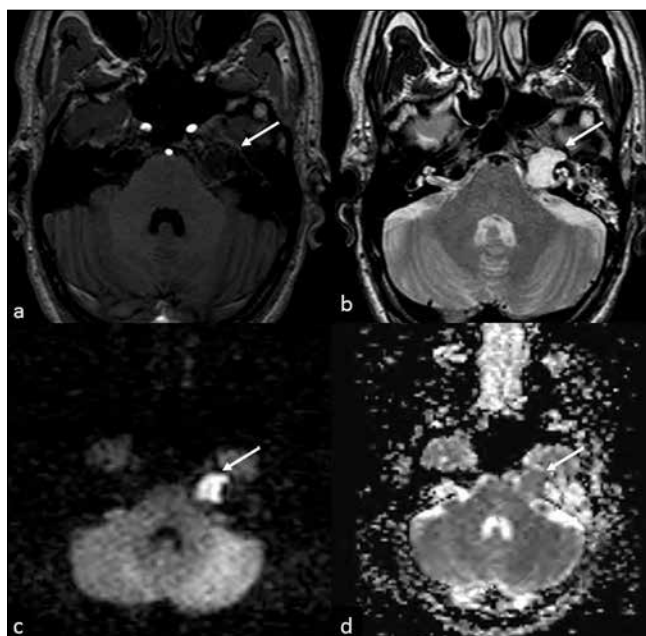


Fig. 4.3.6.3. MRI in the axial plane showed a soft-tissue mass in the left petrous apex (arrows) with low signal on T1-weighted sequence **A**), high signal on T2-weighted sequence **B**), high signal on DWI **C**) with corresponding low ADC (Apparent Diffusion Coefficient) **D**). MRI findings unequivocally confirm the suspicion of PBC.

Cholesteatomas show a high signal intensity on DW sequence attributed to an impeded diffusion of water molecules and a T2 shine-through effect¹². In the literature, the DW sequence was associated with an excellent specificity and positive predictive values (up to 100%) in patients with or without history of previous surgery¹². Cholesterol granuloma and inflammatory/scar tissue do not show high signal on DW sequence. On pre-contrast T1-weighted sequences a PBC has a low signal intensity, easily differentiable from cholesterol granuloma which has a high signal. On T2-weighted sequences it appears with an intermediate signal, while inflammatory or scar tissue are characterized by a high signal intensity. After contrast-agent administration cholesteatoma does not show enhancement because it is a non-vascularised tissue; however, sometimes a thin peripheral rim of enhancement can be seen on T1-weighted images after intravenous administration of gadolinium because of the presence of epithelial (matrix) and granular (perimatrix)

layers¹³. On early post-contrast T1-weighted sequences, slow-enhancing inflammatory/scar tissue can be misdiagnosed as cholesteatoma, causing false positive results. The acquisition of late (45 min) post-contrast T1-weighted sequences can differentiate non-enhancing and avascular cholesteatoma from slow enhancing inflammatory/scar tissue¹⁴. Table 4.3.6.I summarizes the MRI characteristics of cholesteatoma and its mimicking lesions. It should be acknowledged that post-contrast sequences are not usually needed because pre-contrast sequences are sufficient for the diagnosis.

Approaches and surgical issues

The medial portion of the petrous bone and the petrous apex are difficult-to-access regions, owing to the anatomical boundaries represented by the ICA, JB, middle (MCF) and posterior cranial fossa (PCF) dura. Furthermore, all lateral skull base surgical trajectories come across the facial nerve, labyrinth and cochlea; despite wide bone removal and careful mobilization of the facial nerve and of the JB, some deep areas such as the medial surface of the ICA will remain a blind spot¹⁵.

Traditional lateral skull base approaches, either transmastoid/transtemporal or through middle cranial fossa craniotomy, are usually performed under magnification by an operative microscope. They include the transcochlear, the modified transcochlear and the transotic approach¹⁵.

The first two approaches imply the mobilization of the facial nerve from the Fallopian canal (“re-routing”); in all 3 techniques, the destruction of the labyrinth and of the cochlea are inevitable surgical steps, followed by Eustachian tube plugging and blind-sac closure of the external auditory canal (EAC). The surgical cavity is then filled with adipose tissue harvested from the peri-umbilical region.

Most surgeons address PBC on the basis of their personal experience and surgical skills¹⁶; in tertiary referral Skull Base/Neuro-Otology centers these lesion are more often managed by a systematic approach^{14 17}; nevertheless, an approach tailored on the location and extension of the disease observed with current imaging modalities and accounting for the pre-operative functional status is reasonable.

A non-conventional transmastoid subarcuate approach was developed by Van Dinther et al.¹⁸ in order to remove a small PBC through the center of the superior semicircular arch, preserving its integrity and sparing hearing function.

Table 4.3.6.I. Signals of cholesteatoma and mimicking lesions on MR sequences.

	T1-weighted	T2-weighted	Diffusion-weighted	Late post-contrast T1-weighted*
Cholesteatoma	Low	Intermediate	High	Low
Inflammatory/scar tissue	Low	High	Low	High
Cholesterol granuloma	High	High	Low	High

*: 45 minutes after intravenous contra-agent administration.

Obviously enough, this peculiar approach is limited to small and very selected supralabyrinthine cholesteatomas.

Kojima et al.¹⁹ removed a supra- and infracochlear PBC through an extended middle cranial fossa approach with the assistance of endoscopy. Although acceptable in terms of functional sparing, in our opinion this approach should be reserved to cases with locations and extension hardly accessible through the more conventional routes, owing to possible higher morbidity.

As an alternative to the invasive lateral skull base procedures, a totally endoscopic trans-sphenoidal approach has been proposed by few Authors with the purpose of avoiding a craniotomy, promoting faster recovery and reducing postoperative morbidity^{20,21}. Unfortunately, the experiences remain very limited and the outcomes uncertain.

Whatever the selected approach, a few basic surgical pitfalls have been derived from cumulative experiences, especially by leading Skull Base centers:

1. Facial nerve

The main hurdle to the surgical access to the petrous apex is the Fallopian canal.

The facial nerve can be exposed, thinned and already damaged at the time of surgery in a relevant percentage of PBC. In a reported series⁵ it was found interrupted in 35% of cases. This occurred in $\frac{3}{4}$ of the apical lesions, half of the massive cases and $\frac{1}{3}$ of the supra- and infralabyrinthine cholesteatomas. Half of these patients suffered a post-operative House-Brackmann grade V or VI facial palsy.

When the facial canal is intact, it represents an obstacle to complete visualization of deep and medial areas. The traditional solution to gain better access is represented by facial nerve “rerouting”, usually in a posterior position by first skeletonizing and uncovering the bony shell of the canal, then sectioning the greater superficial petrosal nerve and translocating the nerve to the posterior edge of the petrosectomy cavity. Even delicate manipulations of the nerve lead to an inevitable transient palsy.

The transotic approach, which preserves the integrity of the bony Fallopian canal, combined with the use of endoscopes anterior and posterior to the canal to work “beyond the blind corner” (Fig. 4.3.6.4) is an effective mean to avoid post-operative paresis. Care must be taken to prevent heating of the facial canal with the drill and with the endoscope.

2. ICA

Invasive cholesteatoma may erode the cortical bone of the carotic canal, exposing the adventitial layer of the intrapetrous carotid artery, without infiltrating it. Careful dissection of the adherent matrix from the carotid wall is essential to avoid relapses. The thickness of the adventitia is usually sufficient to prevent accidental tearing of the wall, which can result fatal to the patient; carotid

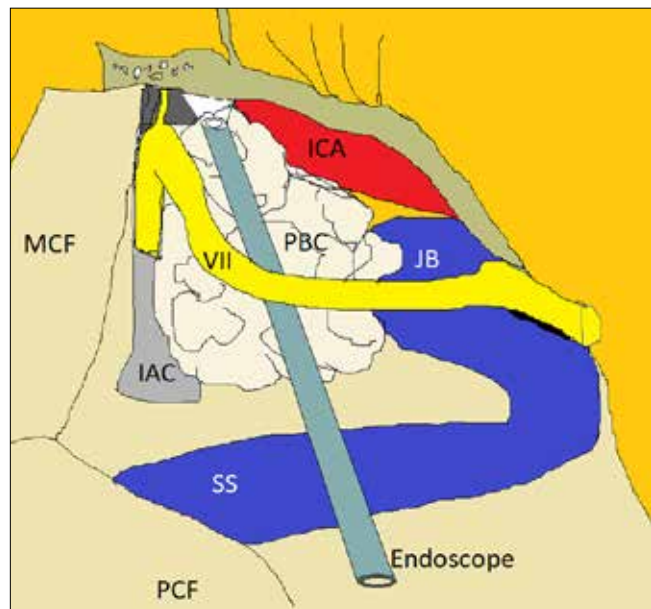


Fig. 4.3.6.4. Schematic drawing of transotic approach to right the petrous apex with representation of the use of an endoscope to access blind spots (MCF: middle cranial fossa dura; PCF: posterior cranial fossa dura; IAC: internal auditory canal; JB: Jugular bulb; VII: Fallopian canal; ICA: internal carotid artery; SS: sigmoid sinus).

stenting is usually not necessary, since no cases of severe hemorrhage are reported in the PBC literature^{1,2,17}.

For PBC extending beyond the ICA, its gentle mobilization may widen the surgical view of the medial surface under the microscope, but, again, it should only be performed cautiously.

3. Dura mater

In PBC, the matrix is usually tightly adherent to the meninges and a loose perimatrix is missing. Bipolar coagulation of dural portions helps removing it or avoiding relapses^{1,3,4}. In our personal experience, the local application of solutions of mucolytic agents followed by brushing with neurosurgical cottonoids has been proven helpful. In case of inadvertent dural breakdown with CSF leakage, immediate sealing with a dural patch is required, with careful avoidance of intracranial penetration of keratinized epithelium.

Outcomes

The main aim of surgery of PBC is the radical removal of the disease with absence of recurrence. The latter should have a priority over an unpredictable preservation of hearing or even over the risk of facial palsy, although this aspect is still a subject of debate.

In agreement with other Authors¹⁶ an individualized surgical treatment of PBC should strive to achieve the least recurrence rate as well as the facial functional outcome, at the price of sacrificing hearing.

Hearing and equilibrium

Post-operative vestibular impairment is rather unusual, which is not surprising, considering the very low incidence of pre-operative vestibular symptoms.

The chance of preserving the residual hearing is very low, although a few reports claim it is feasible²², by means of modifications of the surgical techniques, such as partial (selective) ablation of the semicircular canals in the so-called modified translabyrinthine approach²³.

At the time of surgery, cholesteatoma has often already invaded the inner ear structures²⁴ and hearing is largely compromised or anacusis is already present.

Nevertheless, in those rare cases with preserved hearing and normal inner ear anatomy, a labyrinthectomy and a cochleostomy might be sidestepped and a more conservative approach considered. Conversely, no question about sacrificing the hearing remnants should rise in case of massive or inaccessible cholesteatoma^{16,23}.

In the rare instances in which the PBC arises in the only hearing ear, the surgeon may elect either one of the following two solutions: 1) performing an “open” (canal wall down) technique in which the disease is simply exteriorized and its evolution can be easily followed-up without endangering the inner ear⁶; 2) the contralateral ear is rehabilitated with a cochlear implant (if feasible) and the PBC is addressed soon after²⁵.

In the era of cochlear implants, the opportunity of rehabilitating hearing has to be integrated in the pre-operative planning. Proven the contralateral hearing is at least partially compromised, a cochlear implant would certainly be beneficial to the patient who will lose hearing after PBC removal²⁵. Quite obviously, the cochlea should be intact and free from disease in order to insert the array, and the implant would be buried under the final cavity obliteration. Then, the question of the timing of the implantation rises: simultaneous implantation would provide the greatest speech perception results and would spare the patient a second operation; however, it would also hamper the chance to follow-up the potential recurrence by means of MR imaging. On the other side, a delayed implantation might not be feasible because of potential ossification of the cochlear lumen after surgical trauma.

Facial nerve

Even if the nerve is intact, the surgical manipulations needed to reach the most difficult areas can endanger it. Facial nerve function is more likely to be preserved in patients with preoperative facial palsy mild or moderate; an early diagnosis by current imaging methods is essential.

When preoperative facial palsy is present, a decompression of the Fallopian canal from the first genu to the silo-mastoid foramen is required. In the event of nerve interruption, its repair through either primary neuroorrhaphy or nerve

grafting, with great auricular or sural nerve²⁴, based on the length and location of the injured nerve segment, can be performed simultaneously. In case of long-standing palsies, a hypoglossal-facial nerve transfer is preferred¹⁶. In all procedures, a recovery not exceeding House-Brackmann grade III can be expected^{1,4,5,24}, with the exception of primary direct anastomosis.

Cholesteatoma recurrence

Recurrences can develop from remnants of the cholesteatoma matrix adherent to the facial nerve, dura mater or ICA⁴ and can also lead to postoperative complications.

The recurrence rate for the classical trans-mastoid routes ranges between 5 and 28% in literature^{1,3,4,6,17}; long-term observation is needed because relapses have been observed even 8 years after surgery.

“Exclusion” of the petrosectomy cavity by blind sac closure of the external auditory canal and plugging of the Eustachian tube orifice, combined with filling of the cavity with adipose tissue grafts and additional musculo-periosteal flaps is the universally accepted surgical solution to minimize the risks of CSF leaks and infection, which also warrants adequate protection of the neurovascular structures. The drawback is the absence of control of the cavity in the event of a possible recurrence of the disease, which must then rely upon imaging. To partially overcome this issue fibrin glue can be used instead of fat and muscle to fill the operative field, in order to pneumatize the cavity and improve postoperative imaging.

Alternatively, an “open” surgical technique can be selected in order to allow periodical inspection of the petrosectomy cavity; although the latter technique can expose the patient to a higher chance of post-operative complications and it is not clear if the recurrence rate is lowered⁶. In open techniques, the reinforcement of the dura with full thickness cartilage palisades with attached perichondrium in an underlay fashion, covered by a posteriorly based periosteal flap, can be recommended².

Endoscopy vs microscopy

One recent advance in lateral skull base surgery has been the introduction of endoscopes. Although the microscope offers a wide field of view, with different degrees of magnification and an excellent illumination, deep recesses within the temporal bone may remain out of sight. In recent years, endoscopic surgical techniques applied to the ear have gained respect and widespread use, increasing knowledge and refining their outcomes^{26,27}.

A variety of endoscopes that differ in size (4 mm vs 2.7 mm), length (8-15-20 mm) and angle of view (0°, 30°, or 70°) can assist surgery for PBC, allowing access to areas such as the medial or anterior wall of the ICA, the infralabyrinthine compartment, the anterior part of the internal auditory canal and even the sphenoid sinus¹⁵.

The sets of instruments specifically designed for endoscopic middle ear surgery can be too short for reaching the petrous apex, but modified sinus surgery (longer) tools or neurosurgical instruments can effectively replace them.

The main drawback of endoscopy is that one-hand surgical procedures somehow limit an adequate drilling of the temporal bone¹⁵. The advantage of bimanual dissection under the microscope can be compensated by a second operator holding the endoscope, and, if needed, also a second suction tube (such as in endoscopic surgery of the anterior skull base).

Nowadays, endoscopes are commonly employed to assist conventional petrous bone microscopic procedures, as they allow inspection of hidden areas and guarantee a more reliable radical removal of the cholesteatoma.

Some Authors claim that an exclusively endoscopic approach can achieve complete eradication of the cholesteatoma in a less invasive fashion, reducing the risk of residuals, and lowering the risk of lesions of the dura, of the major vessels and of the facial nerve^{15 28}.

These approaches seem very promising in terms of functional preservation, but up to now, the experiences are limited and long-term results are lacking, especially for what concerns the recurrence rate.

5. The view of the expert: a free choice topic

5.1. Petrous apex and surrounding areas lesions: clinical and surgical management

M. Sanna, A. Taibah, A. Russo, E. Piccirillo, G. Piras

Introduction

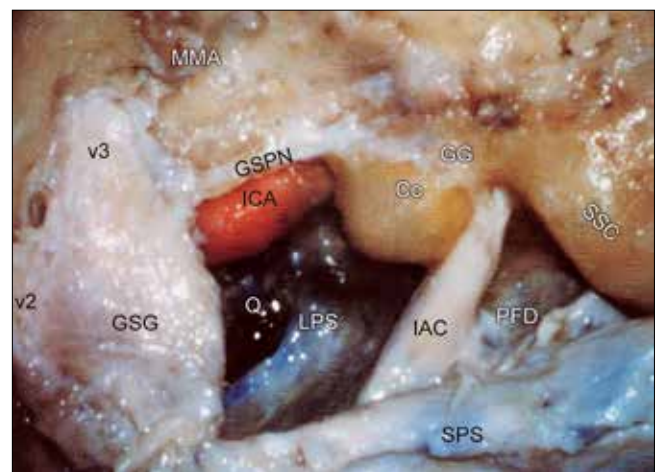
The petrous apex (PA) is a pyramid shaped part of the temporal bone that is surrounded by the brain, complex neurovascular structures, and the organ of hearing. Multiple pathologic processes may affect the PA which range from infections like petrous apicitis to complex tumors like chondrosarcomas. Diseases affecting the PA not only tend to have serious morbidities as they affect important structures in the surrounding area, but they are also surgically difficult to approach due to the deep location in the skull base. The presence of the internal carotid artery (ICA) and the facial nerve which lie close to the PA render surgery even more challenging. The treating surgeon must have a thorough understanding of the anatomy, clinical pathology and skull base approaches to

effectively deal with such lesions. In the last decade, rapid advances have been made in lateral and endoscopic skull base surgery in terms of accurate mapping of the anatomy of the PA and the surrounding areas and formulation of appropriate surgical approaches. Facial nerve monitoring and interventional neuroradiology have greatly improved the safety of surgical procedures.

Management of the diseases of the PA is also complicated because of the delayed and variable presentation of symptoms. Due to the variability of symptoms, it is difficult to diagnose them based on clinical findings alone and hence they remain undetected for many months or years before a diagnosis is made. With the advent of modern skull base surgery, advances in neuroimaging, and neuroanesthesia, it is today possible to precisely locate and extirpate almost all types of tumors¹.

Anatomy of the petrous apex

The PA is a part of the central skull base and is defined as the portion of the petrous temporal bone anteromedial to the bony labyrinth and lateral to the petro-occipital fissure¹⁻³. The anteromedial margin of the PA forms the posterior limit of the middle cranial fossa (MCF). The PA is divided into two compartments: a larger anterior triangular (principally consisting of bone marrow or air cells) one and a smaller posterior quadrangular one (derived from the dense bone of the otic capsule) (Fig. 5.1.1). At the junction of the PA with the sphenoid and occipital bone, the PA is separated from the clivus by an ovoid horizontal gap, the foramen



GsG: Gasserian Ganglion; V2: Maxillary branch of Trigeminal Nerve; V3: Mandibular branch of Trigeminal Nerve; MMA: Middle Meningeal Artery; GSPN: Greater Superficial Petrosal nerve; ICA: Internal Carotid Artery; IPS: Inferior Petrosal Sinus; SPS: Superior Petrosal Sinus; PFD: Posterior Fossa Dura; SSC: Superior Semicircular Canal; Co: Cochlea; IAC: Internal Auditory Canal. GG: Geniculate ganglion.

Fig. 5.1.1. The petrous apex is divided into an anterior triangular and a posterior quadrangular (Q) compartment.

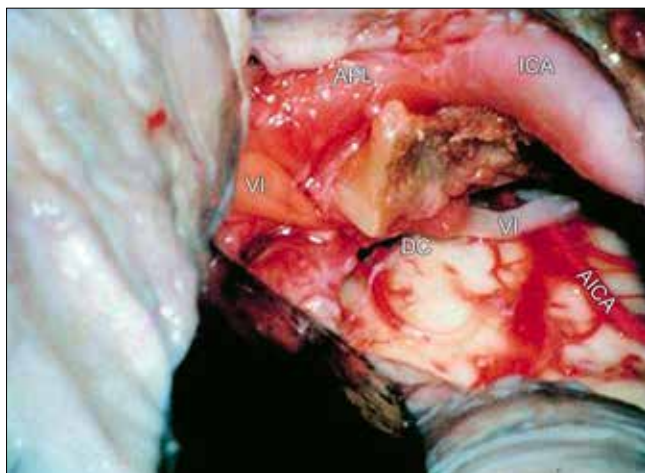


Fig. 5.1.2. The course of the right petrous internal carotid artery (ICA) and the anterior foramen lacerum (AFL) can be identified in this dissected specimen. Other visible structures are the abducens nerve (VI) in the Dorello's canal (DC) and the anterior inferior cerebellar artery (AICA).

lacerum, which contains a bridge of dense fibrous tissue and cartilage. Above the foramen lacerum, the petrous ICA exits the medial opening of the carotid canal to continue as the cavernous portion. On the superomedial surface of the PA there is an important landmark, a shallow depression on which lies the trigeminal ganglion within the Meckel's cave. Trigeminal symptoms are often associated with lesions in this area because of the latter relationship between the nerve and the PA. Dorello's canal carries the sixth cranial nerve from the dural margin along the petroclival junction to the posterior cavernous sinus (Fig. 5.1.2). Lesions of the PA or petroclival junction are notorious for invading or compressing Dorello's canal therefore leading to sixth cranial nerve palsy and diplopia. The inferior extracranial surface of the PA is intimately related to the nasopharynx. The posteromedial margin of the PA meets the clivus, which is formed by the basiocciput and the sphenoid. Invasive neoplasms of the nasopharynx, thus, can traverse the sinus of Morgagni and readily gain access to anatomical structures of the bony skull base, including the PA. In approximately one-third of cases, the PA has aerated cells which are in communication with the middle ear by anatomical tracts (peritubal, posteromedial, and subarcuate) extending superiorly and inferiorly³.

The ICA is the most prominent structure in the PA. The petrous ICA enters the temporal bone into the carotid canal and extends till the foramen lacerum. It has three sections: a vertical portion, the genu, and the horizontal portion. At its entrance, the vertical ICA lies anterior to the cochlea. The anteromedial part of the roof of the horizontal ICA is formed by a thin plate of the bone that separates the artery from the trigeminal ganglion.

Pathologies affecting the petrous apex

A variety of diseases affect the PA and these can arise from the bone, meninges, pneumatized air cells, middle ear, cranial nerves, endolymphatic sac, or from the paraganglionic chemoreceptors of the jugular bulb at the skull base. Razek et al.⁴ proposed a classification of the lesions of the PA based on the type of lesions. In the following sections, we will discuss some of the most important lesions and the most relevant surgical approaches.

Petrous apex cholesterol granuloma (PACG)

A PACG is a lesion that primarily develops as a result of a foreign body-giant cell response to cholesterol deposits. This lesion becomes a cavity with a fibrous lining and is filled by a golden to brownish yellow fluid that contains lipids and cholesterol crystals. It is surrounded by foreign body-giant cells, reactive fibrous tissue, vascular proliferation, and chronic inflammation. Cholesterol granulomas are the most common lesions arising in the PA. Classically, they occur in patients with a pneumatized PA and a long-standing history of otitis media. Pneumatization of the PA has been reported in about 9-30% of temporal bones and this partially explains the rarity of the disease. There are two theories to explain the origin of PACG: the older obstruction-vacuum theory and the newer theory proposed by Jackler et al of marrow exposure⁵. The exposed marrow theory has been supported by evidence from recent studies⁶. Clinical features of PACG may overlap with some of the other inner ear pathologies, therefore radiological diagnosis is often crucial in supporting the diagnosis. Many times the diagnosis is incidental. In our series⁷ the following symptoms were noted: hearing loss (60%), vertigo and tinnitus (27%), diplopia (40%), headache (27%), facial paresthesia (13%), trigeminal neuralgia (7%), and hemifacial spasm (7%). Other signs like seizures and signs of brainstem compression may appear in larger lesions. Magnetic resonance imaging (MRI) is a reliable tool for the diagnosis of this lesion. Although most other PA lesions have low or intermediate signal intensity on T1-weighted images, PACG is usually hyperintense on both T1- and T2-weighted images. Computed tomography (CT) scan will show an isodense lesion, with evidence of bone erosion.

Management of PACG can be conservative or surgical. Small lesions that are asymptomatic or those that are discovered incidentally can be managed by a wait-and-scan policy. In our series of 30 patients, 13 were managed with the latter policy and in this group only one lesion showed growth of the lesion during the follow-up. Larger lesions or those that induce symptoms must be operated.

The main goal of surgery is drainage and ventilation of the cavity after removal of the lesion. There are several surgical approaches that have been proposed in literature including the MCF approach, suboccipital approach, infralabyrinthine (IL) approach, infracochlear (IC) approach, transotic

(TO) approach, infratemporal fossa approach (ITFA) type B, and the transnasal-transsphenoidal approaches. The factors influencing the choice of surgical approach are: preoperative hearing function, location and extent of the lesion, relationship with neurovascular structures, and patients' anatomical variations (e.g. high jugular bulb). We do not favor MCF approaches because of the limited control on the ICA, the difficulty in placing a drain through this approach (especially when aeration of the cavity becomes important in subtotal removals), and because of the risk of developing meningitis by contamination of the subarachnoid spaces by the fluid content of the cyst. In case of preoperative serviceable hearing, IL and IC approaches are appropriate choices. The IL approach is the best option in serviceable hearing because it does not involve manipulation of the tympanic membrane (TM) and ossicular chain as the drainage tube is positioned in the mastoid cavity. The risk of injury to the ICA is minimal and revision surgery, when necessary, can be easily accomplished with a postauricular incision without having to manipulate the TM and the ossicular chain. Complications include sensorineural hearing loss and facial nerve injury. The IC approach provides adequate access to the PA, but has certain drawbacks. It requires maneuvers on the TM, enlargement of external auditory canal followed by reconstruction of the tympanic plate with bone patè. There is also a risk of ICA injury during exposure. The catheter is positioned close to the TM and revision surgery requires the elevation of the TM. The main downside in both the IL and IC approaches is evident in cases in which the jugular bulb is high. To avoid injury to the jugular bulb, particularly when it is dominant, we prefer to approach the lesions using an ITFA type B. This approach presents excellent exposure, complete control of the intrapetrous ICA, and the possibility of complete cyst removal from the clivus and sphenoid sinus. The disadvantages of ITFA type B are a blind sac closure of the external auditory canal which leads to a loss of conductive hearing and the retraction of the mandibular condyle with sacrifice of the mandibular (V3) branch of the trigeminal nerve, which leads to difficulties in mastication. The translabyrinthine (TL) and TO approaches are used for patients without serviceable hearing and huge lesions. These approaches allow a wide and direct exposure of the PA. We recommend combining the ITFA type B with the TL or TO approach for those lesions extending anteriorly to the ICA and eroding the clivus to achieve complete removal of the cyst wall. If the PACG extends into the sphenoid sinus or abuts its posterior wall, a transnasal endoscopic approach is indicated.

Petrous bone cholesteatoma (PBC)

The PBC is an epidermoid cyst of the petrous portion of the temporal bone. The PBC of the PA is less frequent than a

secondary cholesteatoma and the slow-growing nature of this lesion leads to a delayed diagnosis. Apart from this, congenital PBC presenting with sudden onset facial palsy is often misdiagnosed as a Bell's palsy due to a normal otoscopy. Sanna et al.^{8,9} proposed a classification for PBC that is widely used. Of the categories in the classification, the infralabyrinthine-apical, massive, and apical PBC affect the PA. The PBCs can be either congenital or acquired. The term congenital cholesteatoma is used to describe lesions that are believed to arise from epithelial cell remnants within the temporal bone. The acquired type is the result of a medial invasion of cholesteatoma from the tympanomastoid region. Supralabyrinthine PBCs were the most common type with 92 (45.8%) cases, followed by massive PBCs in 72 (35.8%) cases. Apical PBCs were rare with just four (2%) of cases in the series. Two of the main differentiating factors between congenital and acquired PBC are the following: while in acquired PBC, the cavity is connected to the external auditory canal and is therefore at risk for secondary bacterial invasion, in the congenital form the lesion is essentially sterile. Second, the mastoid will be more sclerosed in the acquired form due to long-standing infection in comparison to congenital PBC where pneumatization is normal. The most common clinical presentation of PBC is hearing loss and facial palsy and is common in both congenital and acquired cholesteatomas. In one of the largest series of PBC published (n = 246)¹⁰, we found an incidence of 64% of hearing loss and 53% of facial palsy. The commonest sites for the involvement of the facial nerve in our series were the tympanic portion (94%), geniculate ganglion (84%), and the labyrinthine portion (69%). The facial nerve was involved in multiple segments in most of the patients. On CT scan, PBCs appear as a nonenhancing, expansive lesions with bony destruction. On MRI they show an intermediate to low-signal intensity on T1-weighted images and high-signal intensity on T2-weighted images. There is no enhancement after contrast administration. Diffusion-weighted imaging is useful in diagnosing cholesteatomas, as the lesions often show a restricted diffusion, a feature that can be particularly beneficial in detection of recurrent cholesteatomas after surgical resection.

The main factors to be taken into consideration while treating PBCs are complete eradication of the disease, preservation of facial nerve function, prevention of cerebrospinal fluid leak (and thus meningitis), cavity obliteration, and hearing preservation whenever feasible. The choice of the surgical approach has evolved from a radical petromastoid exenteration with marsupialization of the cavity, to closed and obliterative techniques following complete eradication. The decision regarding the surgical approach depends on several factors, of which the most significant are the extent of the disease and preoperative facial nerve function¹⁰. The approach is chosen depending on the type of PBC and its

extent, which should be determined according to CT scan and MRI findings.

Meningioma involving the petrous apex

Meningiomas involving the PA and the adjacent clivus are some of the most difficult lesions to manage in this area. The petroclival and posterior petrous face meningiomas involve the PA. Petroclival meningiomas arise from the clivus or petroclival junction medially to the trigeminal nerve. They may extend along the petrous pyramid, middle fossa, or into the cavernous sinus. Large tumors displace or encase the basilar artery or its branches. As with most other lesions of the PA, in our series, hearing loss (76.5%), tinnitus (44.4%), instability (51.8%), and vertigo (22.2%) were the most common presenting complaints. Other features include facial paresis, ataxic gait, trigeminal neuralgia, facial anesthesia, and headaches. On CT, meningiomas appear to be hyperattenuating to brain, iso-to hypointense on T1-weighted images, and iso-to hyperintense on T2-weighted images. They also demonstrate postcontrast enhancement. Meningiomas may cause hyperostosis of the PA, a finding that is most evident on CT. Angiography of both vertebral and ICA is performed to determine the major arterial branches and the blood supply to the tumor. The adoption of a particular approach for petroclival meningiomas depends on the location of the tumor. Tumors of the upper and middle clival area tend to involve the PA. Upper clival tumors can be approached by the frontotemporal orbitozygomatic approach or the middle fossa transpetrous approach as described by House et al. in 1986¹¹. Tumors of the middle clivus can be adequately approached by modified transcochlear, retrolabyrinthine, suboccipital, or TL approaches, of which the modified transcochlear approach type A is the safest. The modified transcochlear approach offers a wide and safe exposure, needs no cerebellar or brainstem retraction, permits removal of the invaded dura or bone, and can be extended to afford excellent control of anterior, superior, or inferior tumor extensions. Disadvantages of this approach are the sacrifice of hearing function and facial nerve impairment. Hearing preservation surgeries, however, provide restricted access to the tumor and also involve retraction of the cerebellum. Posterior petrous face meningiomas can be divided into lesions lying anterior, posterior, or centered on the internal auditory canal. Lesions lying anterior to the internal auditory canal tend to involve the PA and they can be approached in the following ways: small lesions are managed by a middle fossa transpetrous approach and larger lesions not reaching the midline can be managed with a retrolabyrinthine subtemporal transapical approach with or without transtentorial extension.

Paraganglioma involving the PA

Tympanojugular paragangliomas (TJPs) are benign tumors involving the middle ear cleft and the skull base. Fisch

class C3 and C4 tumors are generally considered as large tumors and these tumors have the potential to involve the PA¹². As TJPs grow out of the jugular foramen, they tend to follow two paths; the first one extends either into the carotid canal, the PA, and the clivus and the second one into the intradural space through the medial wall of the jugular bulb, thus involving the lower cranial nerves in the process. As a rule, ITFA type A with a transcondylar-transtubercular extension can be used for C2-C4 tumors. If the tumor involves the clivus or foramen magnum, additional procedures such as a modified transcochlear approach or the extreme lateral transcondylar approaches are necessary. If TJPs involve the cavernous sinus, a residual disease should be intentionally left at this level to avoid compromising cranial nerves III, IV, and VI. For tumors extending to the foramen magnum and lower clivus, a modified transcochlear approach type D or the extreme lateral approach may be used. Tympanojugular paragangliomas frequently involve the ICA due to their close anatomical proximity. When indicated, the tumor must be dissected from the arterial wall. This can be accomplished by subperiosteal and subadventitial dissection. When the tumor encapsulates the artery causing stenosis, manipulation without proper endovascular intervention may be complicated by severe bleeding, incomplete removal, or cerebral vascular accident. An ICA balloon occlusion is performed in the case where the ICA is infiltrated by the tumor and the collateral blood flow is sufficient. In cases with insufficient collateral blood flow, we have developed the technique of intra-arterial stenting of the ICA^{12,13}. This technique reinforces the ICA so that the surgeon can easily establish a cleavage plane on the external surface of the stent and more aggressively remove the tumor without the risk of ICA tearing. This new technique can allow reappraisal of selected cases previously suited only for subtotal resection.

Chordoma and chondrosarcoma

Chordomas are a rare and unusual group of malignant tumors that are believed to arise from the persistent rests of the embryonal notochord. These are believed to be more frequent in the male gender. The pathogenesis of chordomas remains unclear. Chondrosarcomas of the skull base are rare slow growing locally aggressive malignant tumors that constitute 0.15% of all intracranial neoplasms. It has been hypothesized that cranial base chondrosarcomas may originate from multipotential mesenchymal cells or from embryonal cartilage remnants of skull synchondroses. The most common tumor sites of origin of both these entities nearly overlap and have been reported to be the petroclival, petro-occipital, sphenoccipital, and the sphenopetrosal synchondroses. Both chordomas and chondrosarcomas cause symptoms primarily related to cranial nerve involvement as:

dysfunction of extraocular movement with diplopia, hearing loss, dizziness and tinnitus, sensory disturbances of the face, and dysphagia. Pain and headache may be present due to erosion of bone or pressure due to the tumor. The CT most commonly reveals bone destruction and a soft tissue mass with tumoral calcification, which is encountered in 56% of tumors. On T1-weighted MRI, chondrosarcomas have a low-to-intermediate signal intensity and are isointense or hypointense compared to the gray matter. On proton density and T2-weighted images, they have a high-signal intensity and are hyperintense compared the gray matter. Contrast enhancement is typically heterogeneous. A radiologic distinction between chondrosarcoma and chordoma is usually not possible.

Surgery is considered the standard of care in the treatment of skull base chordomas and chondrosarcomas. Proton beam radiotherapy or radiosurgery is often used as adjuvant therapy. The surgical intervention needs to be aggressive in these lesions. Small lesions with good preoperative hearing can be managed by the middle fossa transpetrous approach with extensive removal of the bone of the PA. Larger lesions with involvement of the vertical or the inferolateral aspects of the horizontal ICA necessitate a wider approach such as the ITFA type B or its combination with a TO approach. If preoperative hearing is good, then a retrolabyrinthine subtemporal transtentorial approach can be used. Extensive transdural cases will necessitate the addition of a modified transcochlear approach.

Facial nerve neuroma

Facial nerve neuromas are uncommon benign neoplasms of Schwann cells. They represent only the 0.8% of all intrapetrous lesions. Although these tumors involve all portions of the facial nerve, the geniculate ganglion is the commonest site and hence these lesions are also most likely to involve the PA. Symptoms in facial nerve neuroma have an insidious onset that also depends on the location and extent of the lesion. Progressive or sudden facial palsy is a common symptom. In our series of 103 facial nerve tumors, only 76% of our patients presented with the classic gradual facial palsy¹⁴. Other presentations included sudden or recurrent hemifacial palsy. Facial nerve function was normal in 9.5% of the cases. Facial nerve neuroma is found to be the cause in approximately 5% of patients presenting with Bell's palsy. Due to the proximity of the tumor to the cochlea, a sensorineural or conductive hearing loss can occur, depending on whether the tumor originates proximal or distal to the geniculate ganglion. CT scan shows enlargement of the facial canal, bone erosion, or an enhancing soft tissue mass while MRI shows hypo- or isointense tissue on T1-weighted imaging, hyper or isointense tissue on T2-weighted imaging with marked contrast enhancement¹⁵.

Therapeutic options for patients with facial nerve neuromas include surgical intervention, observation, and radiotherapy¹⁴. Nowadays, surgical resection with facial nerve repair is usually the standard management for patients with poor facial function [House-Brackmann (HB) grade III or worse]. In patients presenting with normal or near-normal facial nerve function, initial observation with periodic examination and imaging is usually recommended. However, in rare occasions, surgeons can face a situation in which the decision-making process is particularly challenging. In these complex cases treatment should be individualized. We recommend early surgical intervention regardless of the preoperative facial and hearing functions in the following cases: intratemporal facial nerve neuromas extending with a large tumor component into the parotid, multiple-segment tumors extending in both the cerebellopontine angle and the MCF, fast-growing tumors, and large tumors with temporal lobe compression. The surgical approaches of tumors involving the PA include MCF-transpetrous approach, combined MCF-transmastoid approach, transcochlear approach, or the TL approach. In most of the cases, it becomes necessary to reconstruct the cut sections of the nerve after tumor removal. We prefer to use the sural nerve as a cable nerve graft to replace the lost segment of the nerve. A maximum recovery of the postoperative facial nerve function to HB grade III can be expected after nerve grafting^{14 15}.

Trigeminal schwannoma

These are rare tumors of the Schwann cells. This is one of the important lesions involving the Meckel's cave area. Naturally, clinical presentation corresponds to a trigeminal nerve dysfunction: neuralgia, neurasthenia, or numbness. If the lesion is large, then mass effect symptoms may be present. Depending on their location they can be classified as:

- *Type I.* Predominantly middle fossa tumors; the approach in these cases is the frontotemporal orbitozygomatic.
- *Type II.* Predominantly posterior fossa tumors with limited middle fossa involvement; modified transcochlear approach type C, retrolabyrinthine subtemporal transtentorial approach (for hearing preservation), or the middle fossa transpetrous approach are utilized for these lesions.
- *Type III.* Significant middle and posterior fossa components; combined frontotemporal orbitozygomatic and transpetrous approaches are recommended.
- *Type IV.* Extradural tumors involving the infratemporal fossa and surrounding structures; the approach used is an infratemporal transzygomatic approach (ITFA type D).

Osteoclastoma (Giant Cell Tumor, GCT)

Giant Cell Tumors are a group of rare benign neoplasms that are most commonly found in the epiphysis of long bones.

Of the total 1-2% of these lesions present in the head and neck with the skull base being a commonly reported site (temporal, sphenoid, and ethmoid bones). In the skull base the temporal bone is a common site of occurrence of GCTs. Although benign, these tumors have a locally destructive character that can be potentially dangerous in the presence of intricate nervous and vascular structures of the temporal bone and skull base. Hearing loss, tinnitus, and subcutaneous masses are the most commonly reported symptoms in GCTs of the skull base. The TM is often intact as the tumor is anteromedial to it. The radiological picture of a GCT is an osteolytic lesion. Both CT and MRI are essential for tumor staging and management. Although CT is superior to MRI in outlining tumor extent and bony destruction of the skull base, MRI is currently the best imaging modality for GCT because of its superior contrast resolution and multiplanar imaging capabilities that allow accurate tumor delineation. The GCT shows low intensity on T1 and heterogeneous high intensity on T2-weighted images. Gadolinium enhancement reveals areas of hypervascularity and enhancement with a very heterogeneous signal pattern.

The surgical approach depends on the position and extent of the tumor. Since most GCTs are found involving the temporal bone and the infratemporal fossa, the ITFA types B and D provide an ideal approach and exposure to these tumors with a blind-sac closure of the EAC. For tumors involving the MCF with or without dural invasion, a MCF craniotomy must be performed. For additional exposure any skull base procedures may be added. Posterior extensions into the posterior cranial fossa (PCF), although rare, can be aggressive and extremely challenging to treat.

Conclusions

The PA is a complex area surrounded by vital neurovascular structures and the brain. Pathologies lying in this area are a diagnostic and surgical challenge. A variety of diseases, especially neoplasms, affect the PA and the skull base. Surgery is the treatment of choice for all neoplastic lesions. In the past, surgical excision of lesions of this area were hampered with serious complications and morbidities. However, in the era of modern skull base surgery, this is no longer the case due to the evolution of excellent surgical approaches aided by advances in neuroradiology, neuroanesthesia, and microsurgery. Modern imaging studies have also greatly increased the ability to diagnose lesions, especially in spite of an often vague symptomatology associated with these lesions. Tumors involving the temporal ICA are no longer deemed inaccessible or inoperable due to the development of appropriate surgical approaches and the technique of stenting. In quaternary referral skull base centers across the world, PA as well as other skull base pathologies are routinely performed with minimal morbidities or complications.

5.2. The evolving evidence based algorithm in vestibular schwannoma management

D.A. Moffat, D.G. Hardy, S.L.K. Lloyd, S. Jefferies, R. Macfarlane

Introduction

Our fascination with the vestibular schwannoma continues unabated over many centuries. Persig¹ reported on an excavated skeleton of a 5 yr old boy from as long ago as 2,300 years BC which clearly demonstrated tumour widening of the left internal auditory canal (IAC) and widening of the hypoglossal canal which almost certainly meant that the child had neurofibromatosis type 2 (NF2).

Diagnosis

Sandifort in 1777² was the first to report a vestibular schwannoma at autopsy and Sir Charles Bell was the first to diagnose one in 1830³. It was not until 1895 that Thomas Annandale⁴ undertook the first successful operation in Edinburgh on May 3rd of that year. Previously there was no treatment for vestibular schwannoma and patients succumbed eventually from raised intracranial pressure and brainstem compression. There was no imaging and the diagnosis could only be made when the neurological signs of a large mass at this site were present. Although vestibular schwannoma was the most likely diagnosis other pathologies existed in this anatomical region but could not be differentially diagnosed.

In the 1960s an audiometric test battery was used to differentiate cochlear and retrocochlear deafness and Jerger reported on hearing tests in otological diagnosis in 1962⁵. Speech audiometry in vestibular schwannoma cases⁶ often revealed distortion for phonetically balanced speech sounds presumably due to asynchronous neuronal firing due to tumour compression and a disproportionately poor speech discrimination score (SDS) compared with the pure tone audiometric threshold (PTA) threshold. Tone decay was a retrocochlear feature as was stapedial reflex decay. Fowler's alternate loudness balance test assessed the degree of recruitment⁷. Bekesy audiometry⁸ proved disappointing in differentiation between sensory and neural deafness but the SISI or small increment sensitivity index was better, recruiting deafness allowing the small increments to be heard but not in retrocochlear deafness⁵. In the 1960s and early 1970s this full test battery was used but the results of a study of this in 500 cases of acoustic neuroma by Johnson 1977⁹ revealed that the number of positive results for retrocochlear deafness was disappointingly low. Stapedial reflex decay proved to be the most effective in differentiation but by itself audiometry was not as clinically useful as we had wished. Our hopes turned to auditory evoked potentials (AEP).

Electrodiagnostic tests, both transtympanic electrocochleography (ECoChG) and auditory brainstem responses

(ABR) were exciting advances enabling us with the former to study the electrical responses in the outer hair cells and first order cochlear neurones and in the latter the brainstem auditory pathway. Electrocochleography was not very helpful and rarely was the marked widening of the action potential (Kiang potential)¹⁰ seen and it was difficult to obtain a response probably due to asynchronous neuronal firing caused by the tumour stretching the nerve. That is not to say that Kiang's experiment in blowing up a balloon in the IAC of an anaesthetised cat to mimic tumour compression of the cochlear nerve and producing this wide potential was not extremely elegant.

ABR proved to be a good test and delay in the fifth wave (J5) and the J3-5 interval produced, according to a recent Danish study, a sensitivity of 80% and a specificity of 77%. "Stacked" ABR (Don and Brackmann 1997¹¹ allowed small tumours to be diagnosed. The problem was that in 53% of cases no recording could be made because of a dead ear or no consistent response. This led to the employment of the "rule of three" where 2 out of three positives of widening of the IAC on Xray, absence or hypofunction of the labyrinth on caloric testing, and abnormal ABR would lead to a high suspicion of VS triggering CT with air meatography if necessary.

The evolution of definitive diagnostic imaging was remarkable. A number of views of the IAC on plain Xrays were developed in order to demonstrate widening of the canal and in particular Stenver's view which was described in 1917. Although Dandy described pneumoencephalography in 1919¹² it was not until much later that it was refined to image the posterior fossa. The importance of the position of anterior inferior cerebellar artery (AICA) led to the use of vertebral angiography in 1956. The advent of hypocyloid tomography in 1959 gave a clearer view of the IACs and made it more likely that tumour widening could be detected. Myodil cisternography could diagnose larger tumours. The advent of CT following its discovery by Hounsfield in 1973¹³ allowed imaging of extrameatal tumours but as bone has a positive signal intrameatal tumours could not be seen. This led on to air meatography in 1975 and a small intracanalicular vestibular schwannoma could present as a non-filling IAC mass of soft tissue density.

MRI is now our "gold standard" diagnostic tool either by T2 weighted MRI or by T1 weighted image enhancement with Gadolinium DTPA (Fig. 5.2.1). The increasing resolution of MRI has enabled tumours as small as 3 mm to be detected.

Management

The evolution of surgical management

The evolution of the surgical management of vestibular schwannoma is remarkable. Sir Charles Ballance was said to be the first surgeon to successfully remove an acoustic

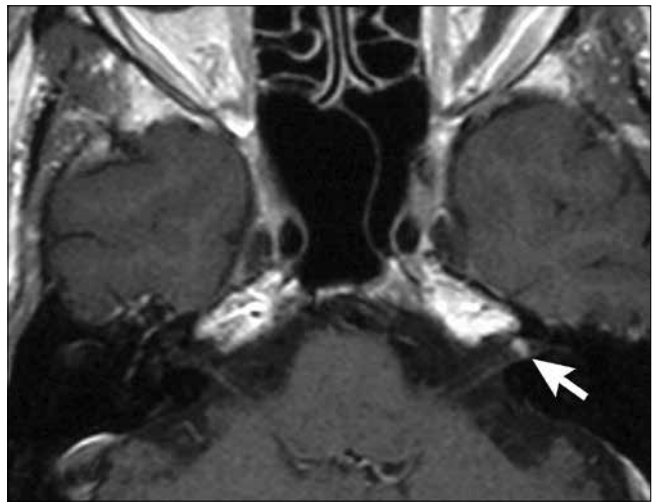


Fig. 5.2.1. Axial T1 Weighted image enhanced with Gadolinium DTPA revealing a 3mm vestibular schwannoma at the fundus of the left IAC (white arrow).

neuroma in 1894¹⁴ but it is now thought to have been a meningioma and that Thomas Annandale was the first in 1895⁴.

Harvey Cushing, the father of American neurosurgery was a true pioneer. In 1917 Cushing published his work on acoustic neuroma based on 30 cases¹⁵. He used a subcapsular resection and he sewed the edges of the tumour remnant together. The mortality from other series around that time was 70% and Cushing was able to reduce the mortality to 15% which was outstanding. Walter Dandy was previously Cushing's trainee and pre-eminent at that time and he had a great battle with Cushing over the treatment of acoustic neuromas. Dandy¹⁶ was the first to show that they could be removed in their totality rather than by intracapsular removal as proposed by Cushing.

William House the modern fore-father of otoneurological surgery, in his landmark paper of 1963¹⁷ described the use of the middle fossa approach for a variety of conditions. He also revitalised interest in the translabyrinthine approach to acoustic neuromas first described and proposed by Panse in 1904¹⁸.

With this the modern era was born with the three main surgical approaches, translabyrinthine, retrosigmoid and middle fossa. Any size of vestibular schwannoma can be excised via a translabyrinthine approach but hearing preservation procedures are either by the retrosigmoid or middle fossa approach.

The evolution of watch, wait and rescan management

Observation is non-invasive but we need to know what happens over time to these patients. They still have their tumour and their symptoms. This management option was proposed by Thomsen and Tos¹⁹ and emerged in 1988

largely following the Danish studies on tumour growth from their National database.

The evolution of stereotactic radiotherapy

Stereotactic radiosurgery (SRS) was first developed in 1949 by the Swedish neurosurgeon Lars Leksell²⁰ and given as a single high dose fraction of radiation. The compact gamma knife was developed in 1968 and by then stereotactic proton beams had replaced the x-rays and the heavy particle beam presented as an excellent replacement for the surgical knife and hence the terms gamma knife and radiosurgery were coined. Radiotherapy can also be given by multiple fractions by LINAC (the linear accelerator) and called fractionated stereotactic radiotherapy (FRST). The dose is usually 50 Gray in 30 fractions over 6 weeks.

Methods

The design was an original cohort study using prospectively collected clinical and surgical data of patients with sporadic unilateral vestibular schwannomas. The detailed clinical records of the surgical patients and those in the watch, wait and rescan groups were obtained from a 230 point database initially established on Filemaker Pro 5 software in 1985 and latterly on Filemaker Pro 13*. In the watch, wait and rescan group linear measurements were used to assess tumour size and two or more magnetic resonance scans were included. The slice providing the most representative part of the tumour was identified in the axial and coronal planes. Maximal tumour size was measured in three axes, medio-lateral, antero-posterior and cranio-caudal. For tumours with extracanalicular extension, maximal medio-lateral measurements were made along the long axis of the internal auditory canal and included the intracanalicular portion of the tumour. Antero-posterior measurements were made in an axis parallel to the posterior face of the temporal bone. Axial images were used for these measurements. Cranio-caudal size was assessed using coronal images. The point of growth and pattern of growth progression were assessed. Based on the literature investigating inter-observer error, tumour growth was defined as greater than 2 mm increase in the maximal tumour diameter in a direction parallel to the internal auditory canal on subsequent scans²¹. Data was analysed using appropriate statistical techniques. The data from the stereotactic radiotherapy group was retrieved from the Department of Oncology.

The evolving algorithm for treatment is dependent now on detailed studies of outcome producing an evidence base for each management option.

* Filemaker, Inc. is a subsidiary of Apple Inc.

Results

These are the outcomes of the three modalities for managing vestibular schwannoma in our Departments at Cambridge University Hospital.

Outcome of unilateral sporadic vestibular schwannoma surgery

There were 1,056 surgical cases operated on over a 30 year period.

All patients had a histologically proven unilateral sporadic vestibular schwannoma.

In this series 923 (87%) of the tumours were excised via a translabyrinthine approach and 132 (13%) were retrosigmoid operations.

One patient had a combined translabyrinthine /retrosigmoid approach in 1982.

Patient demographics

There were 523 male patients and 533 females in the series.

The age range was 13-86 years with a median of 53.8 years and standard deviation of 12.6 years. The majority of patients presented in their 6th and 7th decades.

Tumour size (n = 1,044)

Tumour size was the maximum medio-lateral measurement in centimetres in the axial plane through the IAC and can be seen in the histogram in Figure 5.2.2.

Only 19% (195) had tumours less than 1.5 cm. The largest group was 1.5 to 2.4 cm, 36% (375) of tumours and there were 23% (245) with tumours 2.5-3.4 cm, 15% (154) between 3.5 and 4.4 cm and 7% with tumours greater than 4.5 cm. Thus 45% of tumours were greater than 2.5 cm.

Tumour excision (n = 1,032)

10% (99) of tumours were significantly adherent to the brainstem reflecting the significant proportion of large tumours in this series. 95% (985) had a total excision, 4% (41) had a near

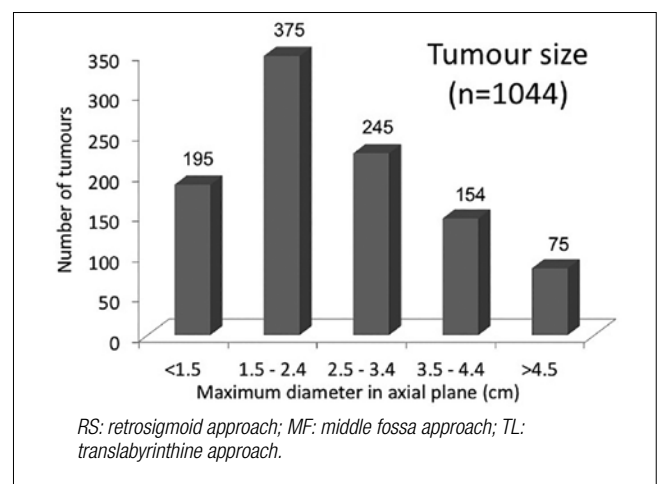


Fig. 5.2.2. Histogram of tumour size in the surgical series (n = 1,044).

total excision leaving capsular remnants usually on a cranial nerve in order to preserve neurological function. Only 1% (6) had a subtotal excision with 95% or more of the tumour being excised. No patients had a partial excision.

Mortality (n = 1,056)

There was a zero operative mortality and a 0.76% perioperative mortality. There were 8 deaths 7 of which were in the first 250 cases in the first decade of the surgery. There has only been one death in the last 20 years of surgery.

Facial nerve state at surgery (n = 1,002)

In 40% (402) of patients the nerves were intact and normal at surgery. In 58% (577) the facial nerve was significantly thinned by tumour compression and 2% (23) were lost at surgery.

Facial nerve outcome (n = 1,056)²²

The data analysis of the facial nerve results for the whole series over 30 years since 1982 reveals that for small tumours, less than 1.5 cm, 81% have normal function or a House Brackmann I or II result and 96% have a HBI to III or satisfactory outcome.

For tumours of 1.5 to 2.4 cm, 71% have a normal face and 95% have a satisfactory result. Tumours of 2.5 to 3.4 cm, 53% are normal and 85% satisfactory.

Tumours of 3.5 to 4.4 cm, 43% are normal and 75% satisfactory. For giant tumours larger than 4.5 cm, 39% are normal and 71% satisfactory.

Figure 5.2.3 shows the current facial nerve outcome of the last 200 operations. The facial nerve outcomes are even better than the series as a whole reflecting the effect of long term surgical experience.

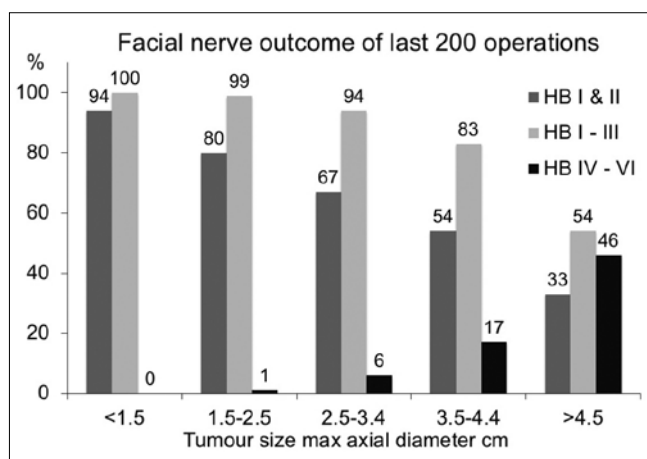


Fig. 5.2.3. Facial nerve outcome of the last 200 surgical cases. The facial nerve outcome for tumours less than 1.5 cm in maximal diameter was 94% with a normal face or House Brackmann I or II result and 100% had a HBI to III or satisfactory outcome. For tumours of 1.5 to 2.4 cm, 80% had a normal face and 99% a satisfactory result and in tumours of 2.5 to 3.4 cm, 67% were normal and 94% satisfactory. In tumours of 3.5 to 4.4 cm, 54% were normal and 83% satisfactory and tumours larger than 4.5 cm it was 33% normal and 54% satisfactory.

Hemifacial spasm (n = 879)

The incidence of significant hemifacial spasm at 3 months postoperatively was 4.6% in this series but as you would expect with continuing nerve regeneration this increases to 11% at 12 months and then does not significantly increase thereafter enabling us to advise our patients accordingly.

Cerebrospinal fluid (CSF) leak (n = 1,056)

The CSF leak rate over this whole series was 6.5% with a control rate of 3.1% with lumbar drainage and 3.4% requiring re-exploration. An analysis of the re-exploration rate over time revealed that 9 cases or 25% of all leaks were re-explored in the first 100 cases. This improved over time as the surgical closure technique evolved and is now at 1% for the last 200 cases.

Meningitis (n = 881)

The overall meningitis rate was 1.3% (14 cases).

Headache at 12 months postoperative (n = 781)

Generalised headache was slightly less after the retrosigmoid approach at 5% as compared with 9% for the translabyrinthine approach but localised headache was four times more frequent in the retrosigmoid approach at 8% compared with 2% in the translabyrinthine cases. Occipital neuralgia was five times more frequent after the retrosigmoid approach at 15% compared with 3% in the translabyrinthine approach.

Quality of life (QoL)

Surgical outcome with regards to hearing, tinnitus and dizziness are important parameters of quality of life for the patient in VS. We have studied the postoperative change in the hearing²³, tinnitus²⁴ and vestibular handicap inventories²⁵. This has altered the way we counsel patients pre-operatively and led to, for example, instituting pre-operative vestibular rehabilitation exercises.

Other complications (n = 1,047)

The other complications are what might be expected in major intracranial surgery and are listed in Table 5.2.I.

Residual and recurrent tumour

- *Retrosigmoid* (n = 132). Recurrent or residual tumour

Table 5.2.I. Other complications of vestibular schwannoma surgery (n = 1,047).

Deep venous thrombosis (DVT)	1.2% (12)
Pulmonary embolism	0.9% (9)
Respiratory infection	1.7% (18)
Scalp wound infection	1.2% (12)
Thigh wound	
– infection	1.5% (16)
– haematoma	4% (42)
Myocardial infarction	0.6% (6)
Temporary dysphagia	2% (20)
Trigeminal numbness at 3 months	2.5% (26)
VI nerve palsy at 24 months	1% (11)

was present in 3.8% (5 patients) of retrosigmoid approach cases. This is very unlikely to grow if it is only a small volume of tumour and we have not had to re-operate on any of these patients. Linear enhancement in the IAC was present in 5.3% and it can be difficult to know whether this is postoperative surgical change or residual tumour. These patients require interval scanning for a few years to establish the situation.

- *Translabrynthine* ($n = 510$). Recurrent or residual tumour was only seen in 0.6% (3 patients) of the translabyrinthine cases where total excision was attempted. Enhancement not thought to be tumour occurred in 3.5% (18 patients) and of these 18 patients:
 - linear enhancement of the IAC or dura was seen in 12;
 - enhancement around the fat plug in 3;
 - hyperintensity at the fundus in 2;
 - a small nodule of doubtful significance in one patient.

Outcome of watch, wait and rescan management

There were 381 patients with sporadic unilateral vestibular on the database with at least two MRI scan results.

Patient demographics

There were 175 males (46%) and 206 females (54%). The mean age at diagnosis was 60.9 years (SD 12.1). The age range was 26 to 98 years. There were 187 right sided tumours (49%) and 194 left sided tumours (51%). The mean interval between first and last scans was 4.2 years (SD 3.2; range: 0.5 to 17 years).

*Growth characteristics of vestibular schwannoma*²¹

A summary of the analysis of this data can be seen in Table 5.2.II.

*Hearing change in watch, wait and rescan management*²⁶

A summary of the analysis of this data can be seen in Table 5.2.III.

Since 1988 there has been an increasing number of patients opting for observation of their tumours by watch, wait and rescan management compared with microsurgical excision (Fig. 5.2.4).

Outcome of fractionated stereotactic radiotherapy treatment (FSRT)

Tumour growth control rate ($n = 70$)

The results of fractionated stereotactic radiotherapy for vestibular schwannoma treated with a dose of 50 Gray in 30 fractions over 6 weeks revealed a tumour control rate of 97%. All tumours were growing pre-treatment as it was not our policy to irradiate non-growing tumours.

Preservation of serviceable hearing ($n = 70$)

57% preservation of serviceable hearing defined as AAO-HNS class A or B or Gardner-Robinson class 1 or 2.

Malignant change ($n = 70$)

There was no induction of malignant change in this series (0%).

Table 5.2.II. Vestibular schwannoma growth data ($n = 381$).

67% overall did not grow
59% no growth - 8% involute
33% of tumours grew in this series.
The patterns of growth are totally variable over time
Growth is usually slow with an annual rate of 2.3 mm
10% grow rapidly (> 5mm/annum)
10% of tumours showed growth even after 5 years
Growth characteristics are unpredictable
There are no factors that predict growth in our series

Table 5.2.III. VS under observation - Change in hearing over time ($n = 381$).

Hearing outcomes significantly worse in tumour ear
Hearing deteriorates faster in growing tumours
Hearing deteriorates faster than by presbycusis alone even in non-growing tumours
Class A hearing in intracanalicular tumours may be preserved
Hearing preservation rates in watch and wait patients should be compared with hearing preservation surgery and radiotherapy
Loss of candidacy for hearing preservation surgery by 50/50 rule
30% after 3 years - 50% after 5 years

VS: vestibular schwannoma.

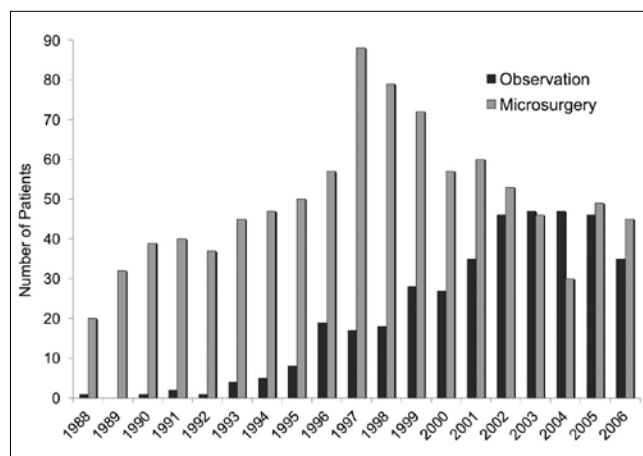


Fig. 5.2.4. Histogram illustrating illustrating the increasing number of patients undergoing observation of their unilateral sporadic vestibular schwannomas compared with those undergoing microsurgical removal.

Complications of FRST ($n = 70$)

The complications of FSRT can be seen in Table 5.2.IV.

Discussion

Sackett et al stated in 1995²⁷ that “evidence based medicine (EBM) is the conscientious, explicit and judicious use of current best evidence in making decisions about the care of individual patients”. He also said that “because the randomised

Table 5.2.IV. Complications of fractionated stereotactic radiotherapy for VS (n = 70).

3% hydrocephalus VP shunt (ventriculo-peritoneal shunt)

3% trigeminal neuralgia

3% facial palsy (recovered)

VS: vestibular schwannoma.

trial is so much more likely to inform us and so much less likely to mislead us it has become the “Gold standard” for judging whether a treatment does more harm than good”.

It has become clear that the resultant creation of the current levels of evidence for treatment and the randomised trial as the “gold standard” is more applicable to medicine than surgery where it is difficult to achieve more than level 3 evidence. Recently a new schema for evidence based surgery has been proposed²⁸ called the “expertise-based randomized trials” extolling the virtues of comparing two different surgical procedures for the same pathology.

The evolving algorithm for the management of vestibular schwannoma is dependent now on detailed studies of outcome producing an evidence base for each management option enabling the patient to give true informed consent to treatment based on this.

The overall risk/benefit analysis of any treatment is multifactorial and detailed surgical outcome data informs this but critically the patient needs to know their likely quality of life postoperatively related to morbidity if they are going to opt for this treatment. Our Cambridge study using the European Organisation for Research into the Treatment of Cancer (EORTC)²⁹ concluded that patients with tumours less than 1.5cm had a significantly better outcome than larger tumours. A second study using a modified SF36 questionnaire concluded that reduced quality of life (QOL) after surgical treatment coupled with minimal preoperative symptoms and a 67% chance of no growth in smaller tumours supported a conservative approach to patient management in small tumours³⁰.

Gamma knife QoL has been reported as better than surgery in papers using the Penn Qual for Acoustic neuroma and also the Myrseth Group³¹ from Norway.

Thus a critical comparison of the outcome of surgery with stereotactic radiotherapy is vital if consent to treatment is to be fully informed. We do not believe in treating non-growing tumours with SRS but some centres will irradiate non-growing tumours and therefore since 67% of small to medium sized VS are not growing in any case the high percentage of tumour control reported from these centres with SRS will be spurious if two thirds of the tumours are not growing. Also, the patients need to be informed of the risk of SRS treatment with regard to malignant transformation. The exact risk in VS is not known but we quote a malignancy rate of 1% per decade from the pituitary adenoma study.

Patients will also want to know the outcome of SRS in comparison with FSRT so that they can make an informed decision on which form of radiotherapy they would prefer to have.

A systematic review or meta-analysis of papers reporting outcome of SRS and FSRT was attempted by Persson et al.³² but unfortunately no randomised controlled trial was identified and therefore a meta-analysis was not possible and a case series comparison only could be reported and even then there were 19 papers on long-term tumour control for SRS but only 2 papers reporting outcome from FRST. There was a tumour growth control rate 95% for SRS and 95.2% with FSRT. The mean deterioration ratio for serviceable hearing was 49% in SRS and 45% for FSRT.

Facial nerve deterioration occurred in 3.6% for SRS and 11.2% for FSRT. Trigeminal nerve deterioration occurred in 6.0% for SRS and 8.4% for FSRT.

Watch, wait and rescan management is obviously an attractive non-invasive option for patients but they still have their tumour and their symptoms and outcome is important and they need to know what will happen over time. The data shows that their hearing will deteriorate faster than by presbycusis alone even if their tumour does not grow and a proportion, 30% after 3 years and 50% after 5 years, will lose their candidacy for hearing preservation surgery. This is an important consideration especially if the hearing is not normal in the contralateral ear. Vestibular disturbance can be markedly deleterious to quality of life in a small proportion of cases and it may be necessary to consider gentamicin ablation of the labyrinth or become an indication for surgery. There is also some discussion as to when MRI scanning can be stopped in non-growing tumours. Our data suggests that up to 10% can start growing after 5 years and there is, therefore, an indication to continue scanning every 3 or 5 years in the longer term. Our protocol in this group is to scan at 6 months after diagnosis and then every year for 3 years, then every 2 years for 6 years and then every 3 years thereafter.

The outcome of surgical excision of these tumours continues to improve with advances in neuro-anaesthesia, neurosurgical intensive care and the use of ultrasonic cavitrons, lasers and endoscopy as well as cranial nerve monitoring.

It is, however, major intracranial surgery and patients must be given a detailed account of all aspects of surgical outcome in order to make an informed choice of management. Neuro-otologists are rightly concerned about total loss of hearing with the translabyrinthine approach and retention of socially useful hearing with the retrosigmoid approach has been disappointingly low but recent reports on the hearing outcome of the middle fossa approach have been more encouraging. However, there should be an awareness that in unilateral VS the patients main concern is dizziness more than hearing especially if the contralateral ear has normal hearing.

A detailed study of the outcome of each of the three current modalities of treatment enables the practice of evidence

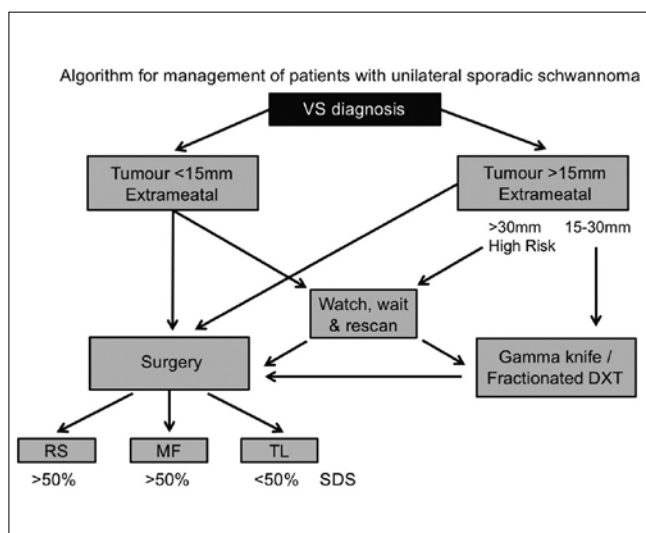


Fig. 5.2.5. The current management algorithm for patients with a unilateral sporadic vestibular schwannoma.

based tumour management and the creation of an algorithm for most patients with a vestibular schwannoma (Fig. 5.2.5). In small tumours less than 15 mm extrameatal diameter the options are watch, wait and rescan or surgery by the retrosigmoid hearing preservation approach if the maximum speech discrimination score is better than 50% and there is no tumour in the fundus of the IAC. The middle fossa approach if the tumour is intracanalicular and laterally arising and by the translabyrinthine approach if the maximum speech discrimination is less than 50%. We only offer stereotactic radiotherapy for growing tumours. Growing tumours are offered SRS (fractionated LINAC or gamma knife) or surgical excision. Growing tumours after stereotactic radiotherapy are offered surgery. Tumours larger than 15 mm extrameatal are recommended to have surgery or offered SRS if no larger than 30 mm. In patients with tumours larger than 30 mm and in whom there is a very high risk then watch, wait and rescan management is adopted with the possibility of the insertion of a ventriculo-peritoneal shunt.

In the future this algorithm may change with the possibility of treating unilateral VS with the anti-vascular endothelial growth factor drug Bevacizumab from which the early results of a national study have been encouraging in neurofibromatosis type 2 (NF2) patients in the United Kingdom.

The creation of a videoconferenced multidisciplinary team clinic both for unilateral sporadic VS and separately for tumours in NF2 has optimised patient care and management and facilitated the development of clinical databases and the measurement of outcome and audit. There is now a UK National Database for both which enables the establishment of an evidence base for the developing algorithm for the management of acoustic tumours.

Conclusions

The publication of outcome and audit data from a detailed analysis of clinical databases within a multidisciplinary skull base unit in Cambridge has enabled the establishment of an evidence base for the three current modalities of treatment in the management of unilateral sporadic vestibular schwannoma. It has optimised patient care and validated informed consent to treatment and has allowed an evidence based algorithm in tumour management to evolve.

5.3. Management of NF2: from vestibular schwannoma microsurgery to hearing restoration

M. Kalamarides, H. Jia, H. Wu, O. Sterkers, D. Bernardeschi

Introduction

Neurofibromatosis type 2 (NF2) is a genetic disorder which occurs with a birth incidence of approximately 1 in 25000 with a dominant pattern of inheritance. Bilateral vestibular schwannomas (VS) appear in 90-95% of NF2 patients, as well as other benign nervous system tumors¹. Various managements, including “Wait and Scan” (periodic radiological and audiological evaluations), surgical treatment (decompression of internal auditory meatus; partial, sub-total, or total VS removal), radiation-based therapy (single-fraction stereotactic radiosurgery, SRS, and fractionated stereotactic radiotherapy, FRST), and chemotherapy (Bevacizumab) have been proposed for these patients whose disease burden is quite heterogeneous. Because most patients suffer bilateral sensorineural hearing loss (SNHL), the restoration of a serviceable hearing by acoustic amplification (hearing aid, HA), or rehabilitation by electrical stimulation applied to the remaining auditory structures in the cochlea (cochlear implant, CI) or directly to the cochlear nucleus (auditory brainstem implant, ABI) are also an essential goal of the treatment. In order to make a better decision for each individual with overall consideration of symptoms, tumor size and life threat, surgical risks, and natural history of tumor growth, a multidisciplinary medical team has been set up in NF2 reference centers including otologists, neurosurgeons, audiologists, speech therapists, neuro-radiologists, geneticists and psychologists².

VS management and hearing preservation

Wait and scan

VS in NF2 are usually slow growing tumors although individual observation provided a wide growth range (0.4-10 mm/year). In our series, 25% of 92 VS in 46 patients showed a fast growth rate (> 3 mm/year). This subgroup was mostly represented by young individuals³. This result

suggested that the first magnetic resonance imaging (MRI) should be performed 6 months after diagnosis and then annually. Meanwhile, spontaneous shrinkage or no growth of VS could also be observed in a part of cases (14% in our series). It should be emphasized that after removing one-sided large VS, contralateral VS may appear to grow more rapidly, because presumably of the repositioning of the displaced brainstem toward the operated side, as the non-operated sided tumor less is compressed to the cerebellopontine angle (CPA) ⁴.

Vestibular schwannoma growth was not correlated to hearing loss in small samples of NF2 patients ³. For what concerns tumor growth rates, this was observed in 31%, 64%, and 79% of cases at 1, 2, and 3 years from diagnosis, respectively. Hearing deterioration was observed in 5%, 13%, and 16% of cases at 1, 2, and 3 years from diagnosis, respectively ⁵. Useful hearing was still present in 65 to 74% of NF2 patients after more than 6 years from diagnosis ³.

As a consequence, the “wait and scan” policy can be recommended as a “natural hearing preservation” strategy, especially in middle age or older patients with small or mid-sized tumors, because the VS growth might be, if present, rather slow, and hearing function may be maintained at a useful level for a long period of time in the majority of these NF2 patients.

Radiation therapy

Radiation therapy is an alternative treatment for NF2 which includes two main techniques (SRS and FRST) whose radiation schedules and doses are different. Up to now, their outcomes still remain controversial. Some institutions reported that small and mid-sized tumors are well controlled with a 5-year local control rate of about 75~87%, although still growing VS may be considered as under control ⁶. Furthermore, in most reported series, the natural growth rate of VS was not described before treatment and was not analyzed in the results. Lloyd et al., in a meta-analysis of 9 papers, concluded that generally 41.1% patients maintained serviceable hearing on long-term follow up with a mean tumor control rate of 81.4% ⁷. It should be recalled that a risk of malignant transformation of NF2 both VS and meningiomas exists with radiation therapy ⁸.

Vestibular schwannoma microsurgical resection

Microsurgical resection of small or mid-sized VS with an attempt to preserve hearing could be achieved either by middle cranial fossa approach (MFA) or retro-sigmoid approach (RS), depending on the size of VS and invasion of the fundus of the internal auditory meatus (IAM). Recent improvements in endoscope-based skull base surgery allowed for tumor removal from the fundus under direct vision and relieved the major drawbacks of RS. With the development of intraoperative facial nerve monitoring,

the risk of facial nerve paralysis in small and mid-sized VS remains low, at a rate of less than 10% at 1 year post-surgery ⁹.

With modern intraoperative cochlear nerve monitoring, hearing preservation became more frequent than before. This is now achieved in 60-70% of patients via MFA and in 30-40% of patients via RS ¹⁰. No predictive factors for hearing preservation were identified in sporadic VS although hearing appeared to be better preserved in cases in which PTA is not – or only moderately – altered with a normal ABR, if the tumor does not invade the cochlear fossa for MFA, or if the IAM fundus is free of tumor for RS. However, a higher rate of VS recurrence has been reported after tumor removal through MFA than through RS ¹⁰.

Decompression of the internal auditory meatus

As hearing preservation by microsurgical resection showed various rates of success and cannot be precisely anticipated, a surgical technique which involves less trauma to the auditory nerve and its surroundings has been developed. It involves a decompression of the IAM through a MFA. An image-guided navigation system has been adapted to this technique to accurately and safely open the roof of IAM ¹¹. With this technique, hearing preservation was achieved in approximately 90% of NF2 patients, which is mandatory in case only one hearing ear is present. Further, cochlear implantation could still be possible if these patients lose their hearing later on, as the auditory nerve and the inner ear vascularization have not been previously damaged during the surgical manipulations of IAM decompression.

Chemotherapy

Nearly all VS express vascular endothelial growth factors (VEGF, MGF-A). Bevacizumab, a humanized immunoglobulin G monoclonal antibody which binds to VEGF with high specificity, was applied in trials for NF2 patients. Short-term usage showed good efficacy for controlling tumor growth as well as preserving useful hearing, although its side effects appeared with a long term use ¹². Additionally, it seems that treatment effect was transient and that the benefits could be reversed when discontinuing discontinuing the drug. A prospective protocol study aimed at minimizing side effects by administering low bevacizumab dosages on a small sample of patients ¹⁴ demonstrated a hearing response in at least 1/3 of patients for 3 months ¹². This hearing response was correlated to biomarkers indicating a reduced tumor-associated oedema and an improved oxygenation that impacted on tumor volume. Patients treated with other drugs are too few to conclude about drug efficacy although some patients preserved hearing by long-term treatment with Everolimus ¹³.

Hearing rehabilitation in NF2

Hearing aid

Hearing aids deliver an amplified sound passing through the damaged cochlea and auditory nervous pathways to the brain. In NF2 patients with moderate to severe hearing loss, conventional hearing aid could be proposed as a transient but low risk and atraumatic management. Most of the patients prefer not to adopt this solution because sounds usually appear distorted and sound intelligibility in noisy conditions is poor.

Cochlear implant (CI)

Because a functional integrity of the auditory nerve cannot be guaranteed during surgery, cochlear implantation in NF2-related VS was not considered until recently. The main reasons might be an insufficient benefit and a mild performance obtained with ABI, together with a lack of ABI availability in some medical centers or countries. In these situations, best effort was taken to preserve the cochlear nerve. Intraoperative auditory monitoring is useful in this situation to aid intraoperative decision-making for either CI or ABI. The absence of intraoperative responses imply a post-operative non-functional auditory nerve, although a good response cannot guarantee hearing preservation. Because of poor and uncertain rates of hearing preservation through the retro-sigmoid approach, some authors suggested to remove the tumor through a trans-labyrinthine approach despite preoperative hearing level. This is because the latter approach allows early identification of the cochlear nerve and visualization of it all along the IAM and CPA. During the same surgical procedure, it is possible to implant a CI electrode array into the scala tympani of the cochlea¹⁴⁻¹⁶. In order to ensure the maximum integrity of the auditory nerve, cochlear implantation without tumor removal was proposed and especially applied in older patients with sporadic VS, whose tumors were stable or slowly growing.

Indeed, CI in NF2 patients show better performances than ABI, although audiological features, tumor features and age of the two populations were different¹⁴⁻¹⁸. With recent technological developments, either CI or ABI do not preclude postoperative radiological evaluations with MRI at 1.5 T or 3.0 T for purposefully-built devices. Furthermore, a previous SRS does not contraindicate the placement of CI or ABI.

Auditory brainstem implant (ABI)

In most cases, ABI was implanted on the only hearing side, although in some cases it was implanted on the first side with the device switched off until contralateral total hearing loss was present (Sleeper ABI)¹⁶. The ABI showed the expected auditory benefit with lip-reading aid in most cases. Intelligibility with ABI remains uncertain and few NF2 patients presented good open set performance without lip-reading^{14 17 18}. Indeed, positron emission tomography

scan demonstrated that auditory cortex is well activated though ABI¹⁹, suggesting that coding strategies which were developed for CI but not for ABI might not be properly adapted to mapping of the cochlear nucleus.

However, ABI could be recommended in young NF2 patients whose VS are growing rapidly and are often large at diagnosis, because no other therapeutic option is available. Probably because of the high brain plasticity in younger population, ABI performances appear to be better than in other populations.

Conclusions

The combination of different management options should be now considered to improve both hearing preservation and tumor volume control. Decompression of IAM and chemotherapy, mainly Bevacizumab, are today the best options to preserve useful hearing in NF2 patients especially as NF2 related VS are generally growing tumors. To restore hearing, older patients with no or slow growth of small and mid-sized VS are candidate for CI without tumor resection, while young patients with large and growing VS are candidates for ABI with tumor resection. Because of small size samples and large individual differences, no prospective and randomized data could be completed in NF2 patients. Further studies might be focused on these topics to draw conclusions with higher confidence.

5.4. When preservation of auditory function is a must: technique and outcome in a series of neurofibromatosis type II

C. Matthies, M. Breun, W. Shehata-Dieler, R. Hagen

Introduction

Bilateral auditory perception of our surroundings, of noises at different intensities, of harmony and modulation of voices and music, of sounds arriving at different angles, are essential data to our notion, as individuals, of being present within the world we live in. Slight unilateral changes, due, for instance, to presence of water in an external ear canal under the shower or music tone modulation as very early signs, and increasing or sudden hypo-acusis as intermediate signs of a developing acoustic tumor are irritating experiences for everyone. Though the majority of neoplasms of the vestibulo-cochlear nerve or in its proximity are generally histologically benign, they do compress, stretch and finally destroy the functions of this complex nerve. Any tissue growth near these pre-damaged nerves is frequently followed by further hearing decline or loss.

By comparing the symptoms of these diseases and the likelihood of further hearing function deterioration, it is

difficult for the doctor to suggest the most appropriate patient-tailored strategy: should the patient undergo a wait and scan observation strategy in order to enjoy hearing function as long as the nature of the disease allows it and accept its “natural” decline and final loss? Or should the underlying disease be treated with partial tumor reduction by radiation or by surgical tumor enucleation with the aim of nerve decompression? Or, furthermore, is complete tumor resection with the goal of nerve decompression and eradication from the disease the best treatment option?

The problem may further be more complex at times as statistically, 5 to 7% of patients with a vestibular schwannoma, present with bilateral lesions and an underlying genetic disease: neurofibromatosis type 2 (NF2). The danger of bilateral deafness is a lifelong problem in this condition, also because auditory function is endangered much earlier in life, usually below 30 years (and often below 20 years of life) when comparing these patients with subjects with sporadic vestibular schwannomas.

Any recommendation depends on the patient’s individual anatomy and his personal attitude towards the problem.

Some patients rate their interest in keeping some of their natural hearing as the most important goal. Therefore, both general and individual guidelines are necessary on what policy is best to follow, especially if preservation of auditory function is a must for the patient and thus more appreciated than any other goal.

In this study, we intended to collect all the technical methods and tools that enable hearing preservation, from the indication of the type of therapy to technical aspects in performance.

Materials and methods

Patients

A prospectively and continuously collected series of patients with vestibular schwannomas in NF2 – operated by the first author or jointly with the senior author – was analyzed for tumor extension by Hannover Tumor Extension Classification, auditory function before and after surgery by Hannover Auditory Classification as well as for the types of applied technical tools. Special focus was on those measures that enable or ensure auditory preservation, and these are outlined in detail and are illustrated by typical case presentations.

Diagnosics and preparation of surgery

Patients with a serviceable hearing function are generally interested in a hearing preservation surgery. These patients were preoperatively investigated by pure tone audiometry, speech discrimination testing and evoked response audiometry. In addition, facial nerve function was documented by standardized photo and video-graphics and by electrophysiological tests of blink reflexes. Bone window CT, enhanced MRI, and x-rays of the cervical spine at ante-

and retroflexion were the routine imaging techniques used. In case of unusual findings, additional diagnostics such as electrophysiology or spine MRI are performed. All patients were investigated with a neck provocation test which included tilting and rotating the patient’s head on both sides and keeping it in position for at least 30 seconds to investigate for eventual sensory or motor disturbances related to nervous compression.

Neuro-monitoring

Before patient positioning, neurophysiological monitoring is set up. This routinely consists of: bilateral auditory brainstem responses, bilateral EMG and MEP of the facial nerve (*Orbicularis oris*) and unilaterally for *Orbicularis oculi*. Additionally, in severe compression of the brainstem or cranio-cervical junction or cervical stenosis/ disc disease, M-SEP are performed to control positioning of the patient and later on dissection close to the brainstem.

Multi-modality monitoring of auditory function is individually indicated and may involve additional non-invasive electro-cochleography and/or direct brainstem (D-ABR) and/or nerve recording (D-NAP).

Surgery

Microsurgery is performed via a retro-sigmoid trans-meatal approach in the semi-sitting position with the head rotated toward the tumor side or in a supine position with the head rotated contra-laterally. Patients above 65 years of age or patients with advanced cerebrospinal fluid spaces are usually selected for the supine position. Further, an indirect Valsalva maneuver is performed during examination by trans-oesophageal Doppler sonography to identify a patent foramen ovale, a further indication for the supine position.

Pre-surgical fluid loading with 1,000 ml Ringer solution infusion is scheduled for all patients operated in the semi-sitting position. Prophylactic medications include single shot cefuroxime or cefazolin (repeated at 6 hours during surgery) and methylprednisolone which is initially administered at 16 mg in a single shot, then 8 mg twice a day for three days and finally gradually reduced.

Surgical approach is performed via a slightly curved skin incision, followed by blunt separation of soft tissues, paying attention not to cut short head muscles. Finally, a 5 cm osteoplastic craniotomy within the angle of the transverse and sigmoid sinuses is performed. In-apparently opened veins are identified and sealed under jugular venous compression.

Dura opening is C-shaped, laterally convex. After releasing CSF, the cerebellum is covered by moist cotton and held medially. Sharp dissection of the arachnoid leads to identification of cranial nerves and vessels (Figs. 5.4.1A, B).

Special measures with regard to audition: at the medial junction of the VIII cranial nerve with the brainstem, a nearfield electrode is placed and its position may be secured by placing some moist gelfoam and cotton around it.

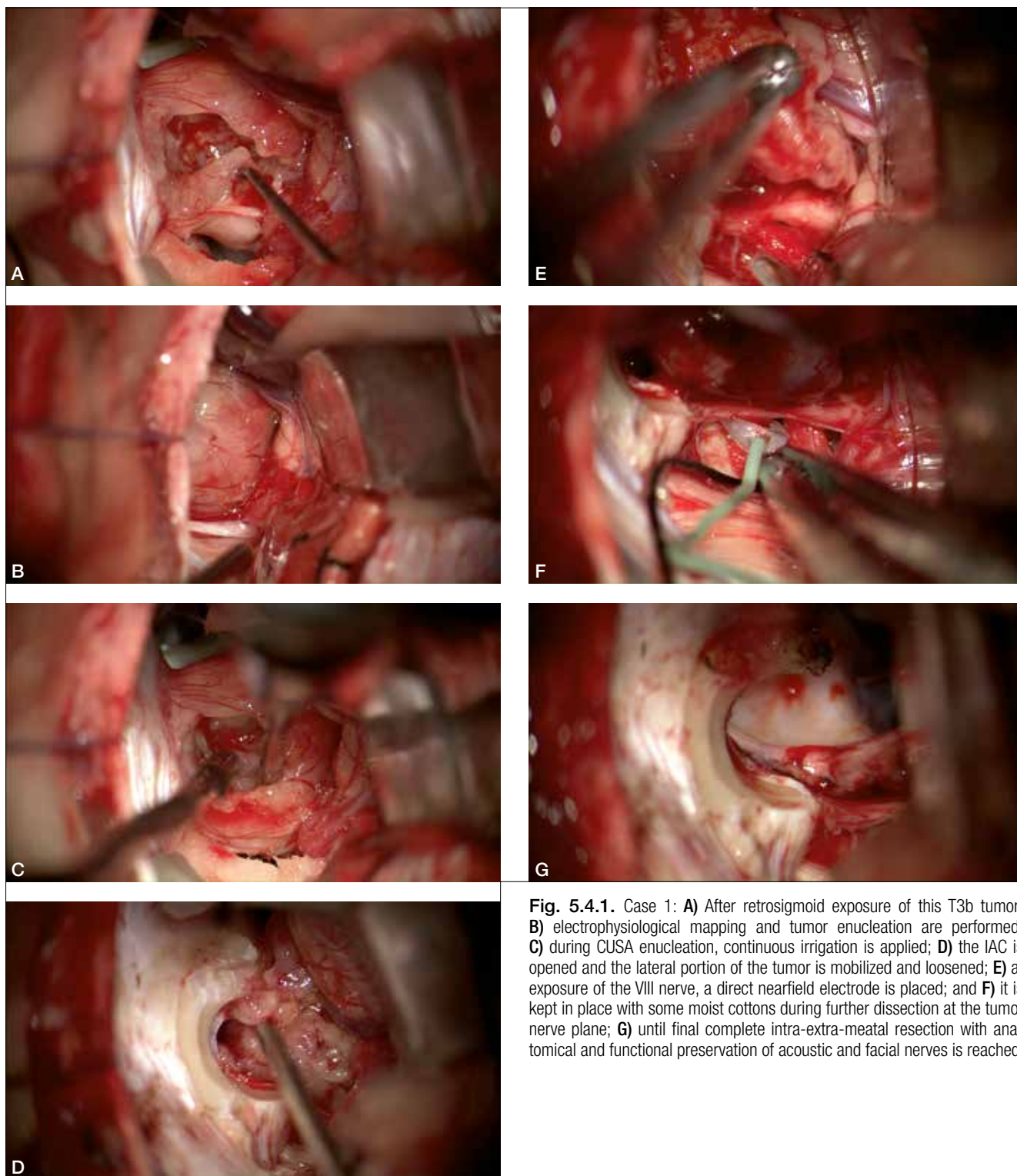


Fig. 5.4.1. Case 1: **A)** After retrosigmoid exposure of this T3b tumor; **B)** electrophysiological mapping and tumor enucleation are performed; **C)** during CUSA enucleation, continuous irrigation is applied; **D)** the IAC is opened and the lateral portion of the tumor is mobilized and loosened; **E)** at exposure of the VIII nerve, a direct nearfield electrode is placed; and **F)** it is kept in place with some moist cottons during further dissection at the tumor nerve plane; **G)** until final complete intra-extra-meatal resection with anatomical and functional preservation of acoustic and facial nerves is reached.

Further, under the course of the VIII cranial nerve, gelfoam soaked with diluted vasodilative medication is placed to accompany the nerve and its vasa nervorum.

The sequence of microsurgical steps follows the following

principle: to minimize pressure and elongation of the involved cranial nerves. The main steps involve the internal auditory canal (IAC) (Fig. 5.4.1D), the tumor within the cerebellopontine angle (CPA) (Figs. 5.4.1A-C), the tumor

relation with the brainstem and vessels, the tumor relation with the nerves inside and outside the IAC (Figs. 5.4.1D-F). *Handling of the IAC tumor part* (Fig. 5.4.1D): the dura over the posterior aspect of the meatus is incised and resected in a C-shape and conserved between moist cotton layers for future manipulation. The medial entrance to the IAC, the upper and lower borders are visible and may be palpated by a slim hook. The posterior wall of the meatus is removed layer-wise by sharp diamond burrs with repeated intervals of at least 15 seconds to control hearing. If the region is strongly pneumatized, for prevention of substantial fluid entering the air cells and preventing air conduction during microsurgery, sealing of the cells with synthetic wax is an option. While resecting the posterior wall, the semicircular canals, the vestibulum and the jugular bulb are respected and preserved; neuro-navigation or calculation by bone window CT scans and measuring with slim hooks a defined length will support this endeavor. In general, the preservation of 3.5 mm of the lateral wall of the IAC will ensure vestibular system preservation. Meticulous drilling around vestibular structures¹ is also possible with complete survey of the IAC and preservation of function.

The intra-meatal dorsal dura layer is split and resected by using micro-scissors. Partial intra-meatal enucleation may be performed by using the micro-CUSA. By sliding underneath and along the upper vestibular nerve with a hook this part of the tumor is loosened. Anteriorly the facial nerve can be now identified by mechanic or electric activation. Sliding between the inferior vestibular nerve and the tumor then allows to mobilize the lateral part of the tumor as well; this will mostly pop out and show a completely even and round surface. If the lateral part is still adherent, it is left in situ and the more medial parts of the tumor are removed using delicate movements in a medial to lateral direction. Then the intra-meatal healthy parts of the acoustic and facial nerves are exposed, at least in their medial and middle thirds. The most lateral third may be lifted out now or later, depending on hearing functional status.

Tumor resection within the CPA (Figs. 5.4.1A-C) is preceded by electric mapping for motor nerve fascicles. The arachnoid, together with the adjacent vessels is now moved upwards or downwards from the posterior tumor surface and the enucleation is performed with micro-scissors, platelet shaped knives and CUSA. Instead extensive use of bipolar cautery of small vessels, the surgical field is kept clean by continuous irrigation (Fig. 5.4.1C) with tempered Ringer solution, which prevents closure of essential vasa nervorum as well as heat development.

Dissection of tumor remnants from nerve fascicles may be accomplished after sufficient volume reduction and identification and cutting of either both vestibular nerves or of the one from which the tumor originates. With a fine hook, the border between the tumorous inferior vestibular nerve

and the acoustic nerve will be visible. The tumor remnant is then lifted and the arachnoid covering and accompanying the acoustic nerve is moved away allowing a complete elevation of the tumor upwards (Fig. 5.4.1F). Some moist gel-foam is placed in between the structures to keep a clear separation. Then the tumor is lifted in an upward-lateral direction away from the brainstem and the arachnoid cover is moved away from the tumor. Here, the junction of the acoustic nerve with the brainstem first, and, subsequently, the origin of the facial nerve are met. By holding the tumor remnants more lateral, the superior medial cleavage plane between tumor and fascicles can be separated. Here, all fascicles should be conserved primarily at the medial site, as in a postero-anterior direction the superior vestibular nerve, the intermedius nerve and most anterior the facial nerve fascicles will be found, respectively. When the cleavage plane with the tumor is evident, dissection at the upper border towards the internal auditory canal is feasible. At this point, the direction of dissection will need to change from medial to lateral. In view of the strong arachnoid adhesion at the level of the porus, the tumor has to be lifted upwards again and to be moved and rolled softly upwards away from the facial fascicles, until final sharp dissection from the arachnoid/connective tissue and complete anatomical preservation of the healthy nerve fascicles (Fig. 5.4.1G) is accomplished.

Before closure, extensive inspection for displaced tumor remnants and for insidious bleeding sites is mandatory, under elevated venous pressure. The cranial nerves are covered with a light layer of moist gel-foam. Sealing of the meatal mastoid air cells may be performed by synthetic wax or by autologous pieces of fat or muscle.

Counteracting any deterioration of ABR, D-ABR and D-NAP Systematic measures are undertaken and, if necessary, repeated throughout the tumor removal up to the final closure measures. The following steps are always carried out, with very few exceptions (see below) at reporting of amplitude reduction, latency increase or disappearance of ABR components:

- Stop of action, release of structures.
- Irrigation with body temperature Ringer solution.
- Exchange with the neuro-anesthesiologist on current body temperature and systemic perfusion pressure; request to use plasma expanders/ lift arterial blood pressure by 10 to 30 mmHg, depending on general constitution.
- Observation for signs of recovery.

If recovery comes up quickly (5 to 15 seconds), continuation of surgery is possible.

If recovery comes up slowly/partially (15 to 60 seconds), additional irrigation with vasoactive solutions may be tried.

If recovery comes up, but takes 2 to 4 minutes and remains partial, a permanent quality drop in hearing function is likely. Therefore, a decision on whether to stop the procedure or to continue under strict guidelines has to be taken.

If recovery does not come up, but deterioration continues, specific actions may be attempted: tumor remnants are lifted upwards and held in this position for several seconds to minutes; any downward or posterior stretch is avoided. Additional flooding of the surgical field with warm Ringer solution may be helpful. If recovery comes up, soaked gel-foam pieces are put along the nerve course and microsurgery may be continued.

If signs of recovery come up quickly, quick continuation of microsurgery is possible.

Deterioration with short breaks and recovery may be repeated many times.

Despite repeated breaks and repeated recoveries, the acoustic system may become more vulnerable and at a sudden point, recovery may be scarce or lacking.

If signs of recovery come up only slowly and remain incomplete, further resection may be tried with utmost care, but at the slightest further deterioration, a direct stop is indicated and possibly a complete stop of any further action has to be considered.

Based on a pre-surgical clear-cut compromise agreed on with the patient, hearing preservation or completeness of resection is set first or second on the list of goals and intraoperative management is accordingly decided.

In general, in a viable acoustic nerve with reliable auditory monitoring, complete resection may be feasible.

In more advanced neurophysiological compromises, the range of tolerated actions is smaller. Especially when final dissection of tumor remnants (“capsule”) from the nerves is accomplished, critical ABR changes may prevent completeness of resection. At this point, a “gross total resection” may be achieved with minimal seeds of tumor at some sites along the nerve course.

In late stages of the disease, decompressive surgery with opening of the IAC and partial intra-meatal and CPA resection may be possible. Still, this result, mainly due to the reduction of pressure, may allow some stable hearing preservation for many years.

A further option for a critical situation such as unilateral deafness and repeated hearing drops on the tumor side, may solely be bony decompression and opening of the meatal dura.

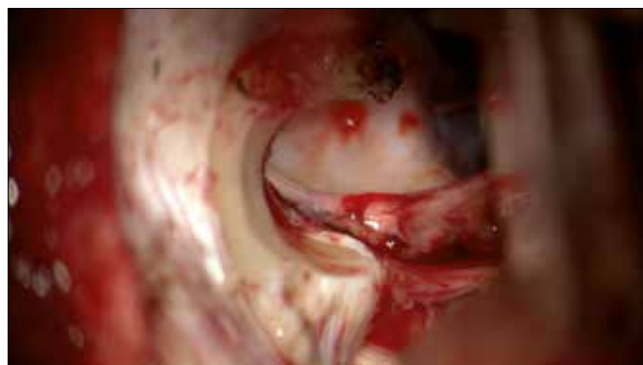Results

There were 76 VS operations performed in 57 patients as outlined above.

Tumor extensions were: small T1 and T2 (intra- extra-meatal tumors) in 5 cases, medium sized tumor T3a (partial filling of the cistern) in 14 patients and large tumors in 57 cases: 11 with T3b (broad brainstem contact and filled cistern), 16 with T4a (moderate brainstem compression, 16 with T4b (severe brainstem compression) and 14 with T5 (tumor growth over the midline). (Table 5.4.I, Fig. 5.4.2).

Table 5.4.I. Tumor extension by Hannover classification in NF2 series.

Extension class	T1	T2	T3a	T3b	T4a	T4b	T5
N	1	4	14	11	16	16	14



Small to medium tumor classes T1, T2 and T3a were present in 25%, while 75% of tumors at the time of surgery showed brainstem involvement (T3b) or compression (T4a, T4b), or severe dislocation with growth over the midline (T5).

Fig. 5.4.2. Tumor extension by Hannover classification in NF2 series.

Pre-surgical function showed some preserved hearing in 14 cases with small to medium tumors and in 26 cases with large tumors (Table 5.4.II).

Post-surgical auditory function was documented in 7 of the 14 small to medium tumors (50%) and in 9 of the 26 large tumors (35%) (Table 5.4.II).

All patients expressed that the retained auditory function was useful to them. In some of the patients with very large tumors, before surgery an agreement for an auditory brainstem implant was found and implanted successfully in 26 cases; one patient received a well-functioning Cochlear implant; 3 patients had been implanted with ABI before and retained the function during tumor recurrence surgery (Fig. 5.4.3).

With regards to postpone further surgery and to maintain a currently useful residual hearing or facial function, 4 patients are currently under trial treatment with Bevacizumab.

Case presentation #1

After an early onset of NF2, this female opted for microsurgery with an attempt of hearing preservation. Complete resection under multimodality monitoring was successfully carried out. Critical phases were greatly supported by nearfield recording. She has been free of any recurrence for 2 years and has become a mother of a healthy boy (Fig. 5.4.1).

Case presentation #2

At the age of 19, this female suffered from ataxia and bilateral repeated hearing losses with partial recovery. This continued despite partial tumor shrinkage under Bevacizumab trial. A decision for surgery of the small left sided tumor with realistic

Table 5.4.II.

II.a. Small and medium-sized vestibular schwannomas in NF2.

Auditory function by Hannover classification system							
	H1	H2	H3	H4	H5	H6	
Pre-op.	6	4	2	2	1	4	
Post-op.	2	0	3	2	0	12	
							7 of 14 50%

II.b. Large vestibular schwannomas in NF2.

Auditory function by Hannover classification system							
	H1	H2	H3	H4	H5	H6	
Pre-op.	9	7	8	2	1	30	
Post-op.	4	3	1	1	0	48	
							9 of 26 35%

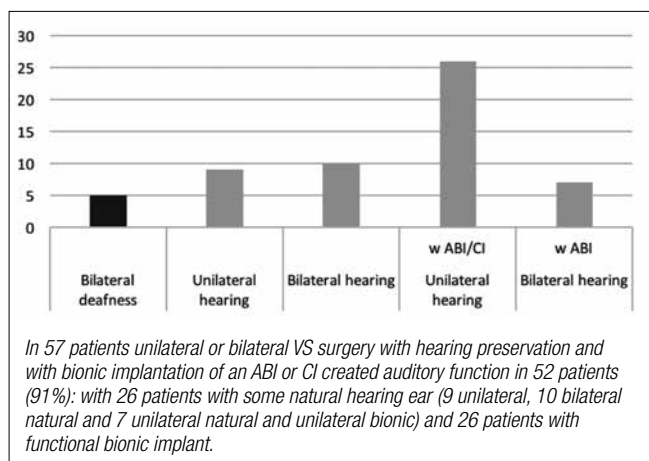


Fig. 5.4.3. Preserved natural and rehabilitated bionic hearing function in 52/57 patients.

perspective to preserve hearing had to be postponed in view of repeated clinical collapses attributed to the severe brainstem compression coming from the right sided tumor. After resection of the right VS, brainstem mapping and implantation of an ABI were carried out in a single-stage procedure. She recovered well and makes continuous progress with open speech understanding and listens to music. In order to stabilize her left natural hearing (60 dB loss, 65% SDS), she is under Bevacizumab trial again and acoustic symptoms have subsided (Fig. 5.4.4).

Case presentation #3

This 43-year-old male had been deaf for a long time on the left side because of a VS for which he underwent surgery 20 years ago. He was reluctant to undergo surgery of his growing right VS with functional hearing. Due to its enlargement and cyst formation, he experienced ataxia and hearing drops. During surgery, a decompression of the IAC, cyst resection and partial tumor resection were performed. His gait and his hearing improved and were stable over

3 years. New balance and hearing problems made him decide for tumor resection and ABI placement (Fig. 5.4.5).

Discussion

Concerning auditory function, patients with NF2 are in a three-fold disadvantageous situation compared to non-NF-patients: in NF2 the danger of deafness is bilateral, it develops much earlier in life, and the chances of preservation of auditory function after treatment are reduced when compared to non-NF schwannomas²⁻⁵. NF2 schwannomas often take a multifocal origin, at various fascicles and at various sites along a fascicle; the cleavage plane is less clear and more adhesive. In view of the early onset of symptoms, often below age 20, mostly below age 30, the risk of hearing loss endangers school education as well as professional training and long-term perspectives.

Especially patients with only one hearing ear – after sudden hearing loss or treatment – are reluctant to undergo any further treatment, and tend to postpone it as long as their symptoms are not seriously life threatening.

Subsequently, the treatment options are discussed in view of the literature.

Alternatives to microsurgery

“Natural course”

The wait and scan option has been suggested mainly for non-NF patients with unilateral VS, based on the observation that some VS do not or only slowly grow over months or years and that nerve function may remain stable for a long period. Furthermore, it is agreed that radiation treatment should only be applied after proven tumor growth, and therefore, an identification of the individuals’ growth speed is important. In a literature review, Sughrue et al. could identify that tumor growth rate (below or above 2.5 mm/ year) predicted the likelihood of hearing function decline⁶.

Despite slow or moderate growth in some patients, it is also known that functions of the vestibulo-cochlear nerve suffer a continuous decline over time. After 7 to 14 years of

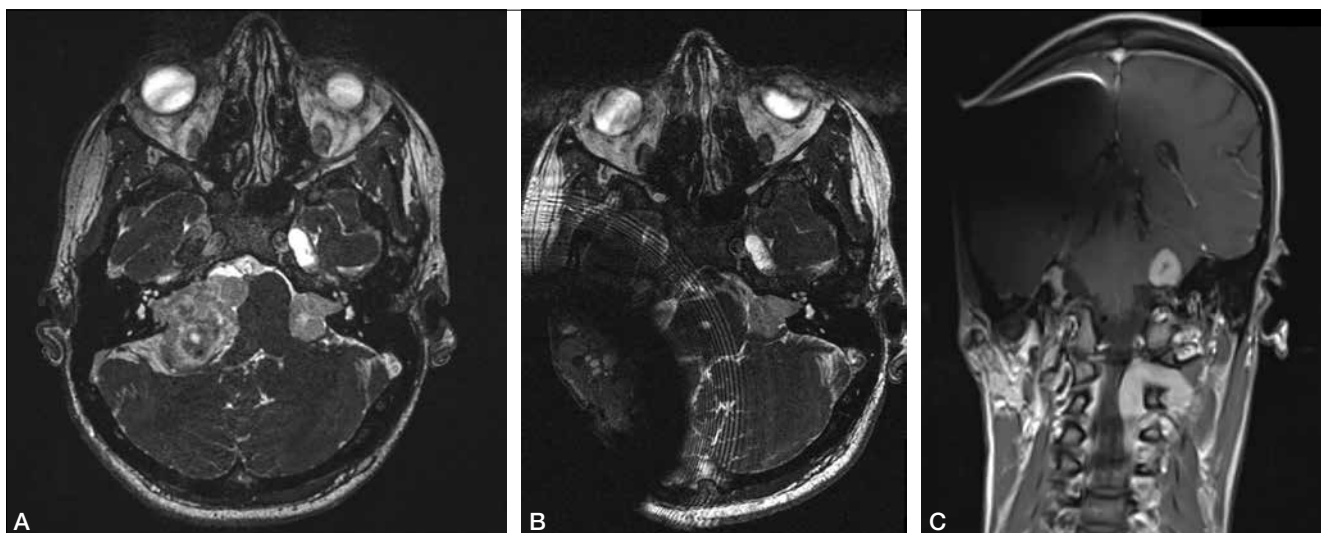


Fig. 5.4.4. Case #2: **A)** despite Bevacizumab trial with temporary response, worsening of the clinical status necessitates surgery of the large R VS and ABI implantation in view of repeated hearing drops in the L; **B), C)** under further bevacizumab trial the L VS has been stable over the last 2 years.

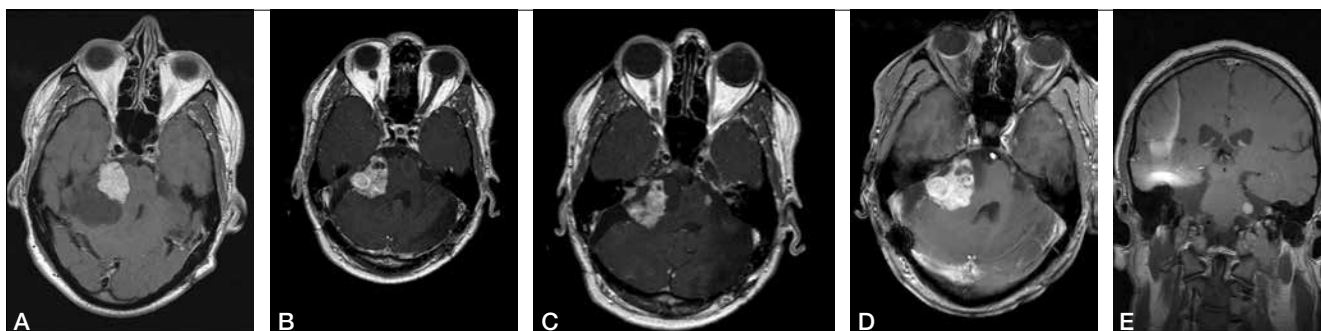


Fig. 5.4.5. Case #3: **A)** this cystic VS with severe brainstem compression is treated by partial decompression and IAC opening in 2006, with improvement of gait and hearing; **B), C)** despite growth of solid tumor, thanks to open IAC, hearing remains useful until 2008; **D)** in 2009, due to further progress of the disease, deterioration of gait and auditory function led to surgery and ABI implantation; **E)** at control in 2011, the brainstem is well decompressed and clinical function has remained stable until now.

observation, most patients are deaf⁷, while in faster growing tumors, deafness occurs after 7 years in a best case scenario. Interestingly, in some patients without a proven tumor growth, after a decade of observation, hearing also gets lost⁷. These data rely on analysis of non-NF-schwannomas. In NF-schwannomas the situation is more critical, and sudden or early hearing loss occurs more often.

Another problem in this option of observation is the dissociation between tumor size and symptoms. While in some small tumors, symptoms may be advanced with loss of vestibular and acoustic functions, patients with large – at times even brainstem compressive – tumors (case #2, Fig. 5.4.4) that still have a serviceable hearing exist. In functional hearing decline in small tumors, a harder tumor consistency and/or a more infiltrative/adhesive growth is assumed.

There is some truth in the statement by Lloyd and colleagues 2017, that “conservative management offers the best chance of hearing preservation in stable tumors”⁸; however, stable conditions are not typical in young and middle-aged NF patients.

In general, pure observation in NF will lead to acoustic decline in all young patients (< 30 years), while only patients with late manifestations have a realistic chance of natural hearing conservation.

Radiosurgery

For some patients, the concept of radio-surgical treatment is especially attractive in order to prevent multiple operations or to get a break from a series of surgeries.

The results are generally positive for unilateral sporadic VS, and functional outcome is mostly better than microsurgery: A comparative study on microsurgery versus radiosurgery

(RS) by Myrseth et al. 2009 showed no hearing preservation by surgery, but 68% by RS at 2 years⁹.

Reported rates of hearing preservation show a wide range that goes from 41%^{10,11} to 25%¹² compared to 52% obtained by microsurgery.

Even in an experienced center, tumor control was good, reported at 84% in NF2, but HP was maintained only in 3 of 12 patients at an average long term of 7.6 years¹².

According to personal experience, the decline in hearing quality after RS is more significant when compared with the tumor's natural course.

Combination of partial resection and radiosurgery

As an alternative to microsurgery or radiosurgery alone, the combination of both has been advocated by some centers^{13,14}; thereby, one avoids any dissection at the tumor-nerve-border to minimize the potential damage, but only performs some enucleation, and aims at reducing the risk of further growth by subsequent radiosurgery. The latter is performed under more difficult conditions, as the tumor borders are less even. The special risk of application of ionizing treatment to patients with a lesion in a tumor suppressor gene has to be taken into consideration. The inherent risk is significantly elevated up to the age of 40. Accordingly, the average VS patient with a unilateral sporadic tumor and the typical age of diagnosis at mid 40ties to 50ies is in a much less vulnerable phase of life than the NF-2-patient in need of treatment.

Microsurgery

The concept of auditory function preservation and the proof of its feasibility have taken a long way in unilateral sporadic tumors^{2,4,15} and the question whom to operate or not needs complex considerations¹⁶. As pointed out above, the preservation of hearing in NF is more challenging and less successful than in non-NF tumors^{3,5}. Although a recent survey states that surgical resection "invariably leads to complete loss of ipsilateral hearing"¹⁰, some centers could prove the opposite^{3,5,17}. The reported rates of HP were 41.6%¹⁷, while Zhao achieved 58% of hearing of any quality¹⁸. Samii et al. obtained 35% average preservation rate, but in well preserved pre-operative hearing function a conservation rate up to 65% was possible^{3,5}. Despite the high proportion of large tumors (75%) in our series presented here, average preservation rate was 40%, with 50% in small to medium and 35% in large tumors. Besides limited tumor extension and useful functional preoperative hearing also the quality of pre-surgical ABR is important; as it has been stated long ago: "The chances of good outcomes are best when surgery is performed early and when there is a good preoperative hearing function"⁵.

Still, the burden of suffering from a brain tumor plays an essential role even in unilateral sporadic VS patients¹⁹, a factor which is multiplied in NF2.

Antibody-immuno-therapy

Over the last 10 years, the option to influence tumor growth

by antibody immune therapy has brought some hope for NF2 patients. Treatment with Bevacizumab is effective in 60 to 70% of patients and in many of them it stops deterioration of hearing function²⁰. In conclusion, it is helpful for the goal of hearing preservation "in the short term"⁸.

Blakely investigated the radiological and hearing response to one-year intermittent bevacizumab treatment and found 43% radiological response and 36% clinical response with sustained hearing²¹. Analysis of subjective patient reporting confirmed preserved and even improved auditory function, mainly in speech discrimination, under Bevacizumab²². However, after 1 to 3 years, the effect on tumor volume and function usually subsides, and another solution must be considered. About one third to 50% of patients do not show any effect.

Auditory rehabilitation

Auditory rehabilitation by cochlear implant or auditory brainstem implant is an option, when hearing preservation is not achieved or is functionally insufficient. Again, the results are less good than in non-tumor patients needing an acoustic implant¹⁰. In few selected cases and series, good results could be reported with CI in NF2²³ with speech discrimination up to 63% in 10 of 12 patients. Lloyd et al. found better benefit from CI, if the related tumor was neither treated by surgery nor by radiosurgery⁸. Better CI outcome was also documented by Peng and colleagues²⁴, but they noted a secondary decline of auditory function in 4 of 10 patients.

Speech discrimination scores are generally reported low for ABI, as mostly there is no open speech understanding by ABI, but a word recognition of 33%²⁵, and an understanding supported by lip reading in CUNY of 38% to 94%²⁴.

An attempt for improving ABI performance by combined penetrating and surface ABI gave better results for surface electrodes²⁶, and the penetrating model was abandoned. Recent studies could show definite improvement and increasing cases with open set speech perception^{27,28}.

Conclusions

In summary, for NF2 patients one of the most important goals is to conserve at least unilateral natural functional hearing for as long as possible. Chances for this endeavor are more realistic in early microsurgical decompression: by removal of the posterior wall of the IAC and by reduction of tumor volume the acoustic nerve is decompressed and its microcirculation is recovered. Intra-operative fluid irrigation with vasodilating medication and nearfield monitoring increase the chances of good functional outcome. If complete resection is feasible, it is attempted. In some patients, auditory function remains useful for over 10 years or longer. In case of deterioration, decompressive surgery may be performed again. This option speaks rather not for an early decision for radiosurgery. Radiosurgery is recommended to be reserved

for later stages and later periods of age, primarily because of the risk of inducing further tumors in a genetic lesion of tumor control, and secondly because secondary hearing decline after RS is more pronounced when compared to the natural course of the disease.

If pre-surgical ABR and audiometry speak against any realistic chance of preservation, functional rehabilitation should be tested and discussed with the patient beforehand and ABI or CI should be implanted without long latency.

5.5. Endoscope-assisted microsurgery of trigeminal, facial and auditory nerves

J. Magnan

Cranial nerves in the Cerebellopontine Angle (CPA) share a common pathology: the neuro-vascular compression syndrome induced by an offending contact of vascular structures to the related cranial nerves which have been definitively proved by surgical decompression of the cross-compression and the resolution of the patient's symptoms¹. Dandy², Gardner³ and Jannetta⁴ were the pioneers to promote such concept and to develop microvascular decompression surgery (MVD) of cranial nerves in the cerebellopontine angle (CPA). After a period of little acceptance, the neurovascular decompression procedure has been popularized by several technological improvements: MRI preoperative assessment in T2 sequences, minimally invasive techniques⁵, endoscope-assisted microsurgery^{6,7}.

Technique

Endoscope-assisted minimally invasive retrosigmoid approach^{8,9}.

- The patient is placed in the dorsal decubitus position, with the head non-fixed, flexed and turned to the contralateral side.
- The landmarks are the posterior border of the mastoid and the Frankfurt line that corresponds to the posterior extension of the line joining the outer canthus of the eye to the superior border of the external auditory canal. The skin incision is curvilinear, 6 to 8 cm long, passing over the posterior part of the craniotomy area, about two fingerbreadth behind the pinna. The cutaneous flap is anteriorly based whereas the underlying musculo-periosteal flap is dissected in a posteriorly based fashion (Fig. 5.5.1). The mastoid emissary vein is identified and coagulated and blocked with bone wax. Burring for the craniotomy is centered on this vein using a cutting burr head. Bone dust is collected to make "bone pâte" that will be used during closure. A circular bone flap may be removed in one piece to be put back in place at the end of the procedure. The retromastoid retrosigmoid craniotomy is usually 15 to 20 mm.

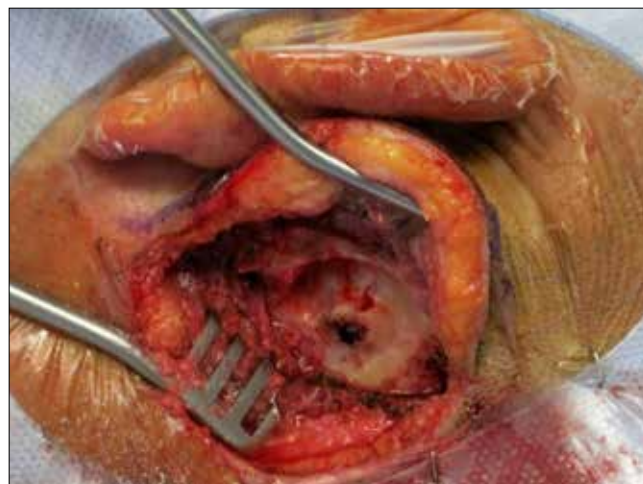

Fig. 5.5.1. Left minimally invasive retrosigmoid approach; the craniotomy is centered on the mastoid emissary vein.

- The craniotomy must reach the posterior border of the sigmoid sinus anteriorly, but it is not necessary to entirely skeletonize it. All opened mastoid air cells should be obliterated using Horsley bone wax to avoid CSF leakage through these cells to the middle ear cavities. The opening of the dura is certain when transmitted CSF pulsations are clearly seen. This is a sign of spontaneous cerebellar retraction thanks to the deep anesthesia and hyperventilation performed to reach pCO₂ of 25. The opening of the dura is a U-shaped incision to form an anteriorly based dural flap. This flap is suspended anteriorly using a stitch or fibrin glue. A fine cottonoid or synthetic dura substitute is introduced to protect the cerebellum. Following the posterior surface of the petrous bone in an anteroinferior direction to reach the lower cranial nerve area, the posterior cistern. is opened. The cerebrospinal fluid escapes and the cerebellum falls away without any pressure on it; The retrosigmoid approach provides a direct and "protected surgical corridor" to access the CPA (Fig. 5.5.2).
- After dissecting the arachnoid wrapping the cranial nerves by using the operative microscope, an endoscopic look of the CPA is made with a 4 mm, 30 degrees angled rigid endoscope. The CPA is endoscopically divided into two zones and separated by the acoustic-facial bundle. The superior zone corresponds to the trigeminal nerve which is visualized from the Meckel's cave to the pons. The most common compressing vessel of the trigeminal nerve is the Superior Cerebellar Artery (SCA). The inferior zone corresponds to the lower cranial nerve zone that is inspected in case of hemi-facial spasm. A high vertebral artery and the Posterior-Inferior Cerebellar Artery (PICA) are the most common offending vessels at the

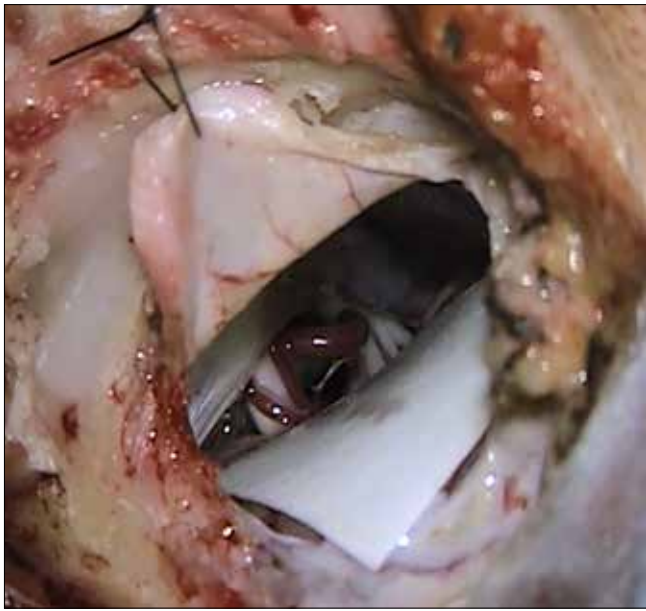

Fig. 5.5.2. Left minimally retrosigmoid approach; the "protected" surgical corridor to access the cerebellopontine angle.

Root Exit Zone (REZ) of the facial nerve. The auditory nerve is the most exposed nerve in the middle of the CPA. The Anterior-Inferior Cerebellar Artery (AICA) is commonly in contact with the acousticofacial nerve bundle. So its role as an offending vessel is less obvious and its decompression more delicate. The surgeon must be aware of potential thermal injury to the auditory nerve by the heat of the endoscope tip. Consequently, close and prolonged contact between cranial nerves and endoscope tip should be avoided. Whatever the site of the neurovascular compression, MVD aims to change the offending vessel axis in order to keep it away from the offended cranial nerve. This surgical procedure is done under the operating microscope. The offending vessel is carefully mobilized using a microelevator or a microhook. Further meticulous and careful dissections allow the artery to change its axis of direction. By inserting one or more small Teflon pads (2 to 3 mm) between the artery and the nerve and adjusting it or them with a microinstrument, the decompression is completed. Teflon is an inert material well tolerated in the CPA. The operation ends with another endoscopic look to assess the correct positioning of the Teflon pad and to check for the absence of contact between the decompressed nerve and all adjacent vascular structures that could maintain the hyperactivity of the nerve.

- Before closure, the operative field should be bloodless and is filled with physiological saline at body temperature to extrude air, which could cause postoperative headaches. The dura is sutured using

5-0 silk sutures. Due to the small size of the dural flap opening a watertight closure is not always easy to achieve. For bridging the defect, a synthetic absorbable dural substitute is useful to use. The gaps between sutures are filled by pieces of subcutaneous fat and a fibrin glue layer, the dura is then covered by another piece of dural substitute, Surgicel and fibrin glue. The craniotomy is then filled with a mixture of "bone pâté" and fibrin glue, and the bone is put back in place. The musculo-aponeurotic flap is sutured in place; finally, the subcutaneous and skin layers sutured. Duration of the intervention is usually between 1½ to 2½ hours.

Indications and results

Trigeminal nerve^{10 11}

The offending artery is: the SCA alone in 46%, associated in 30%; a venous structure alone in 11% or associated to artery in 18%, other arteries alone (AICA, dolicho-vertebral artery, basilar artery) in 4%. Multiple combinations in 34% (Figs. 5.5.3A, B, C).

The SCA is detached from the nerve and pons by dissecting the pial-arachnoidal wrapping that maintains the artery adherent to the nerve with microscissors or sharp microinstrument (Fig. 5.5.4A, B, C). The SCA with its two branches is further kept apart from the trigeminal nerve in a horizontal position toward the tentorium by fibrin glue and Teflon.

A venous structure is involved alone in 11%, or associated to an artery in 18%, other arteries alone (AICA, dolicho-vertebral artery, basilar artery) in 4%, but multiple combinations are present in 34%. The vein, usually is an aberrant trigeminal vein, is rarely mobilized but mainly coagulated with bipolar coagulation after verifying that this vein doesn't represent the predominant venous drainage.

Results

In literature, the success of the procedure varies from 73% to 97%. Since 1994 we have performed MVD on 301 patients suffering of trigeminal neuralgia resistant to medical treatment. The oldest patient was 87 years old. The complete resolution of the pain is immediate in 86 % and required revision surgery to increase the overall successful result at 91%. The recurrence after immediate postoperative relief is mentioned in all MVD series. The recurrence occurred in 14% in our patients, between 3 months to 2 years after initial surgery. Its main cause is the fibrous tissue around the trigeminal nerve inducing a new neurovascular conflict or embedding the Teflon in the nerve. Post-operative complications were limited to CSF leak in 2%. No facial paralysis or hearing loss were present in our series.

*Facial nerve*¹²⁻¹⁴

The most common offending vessel in hemifacial spasm is PICA alone in 37% (Fig. 5.5.5) or rising from a

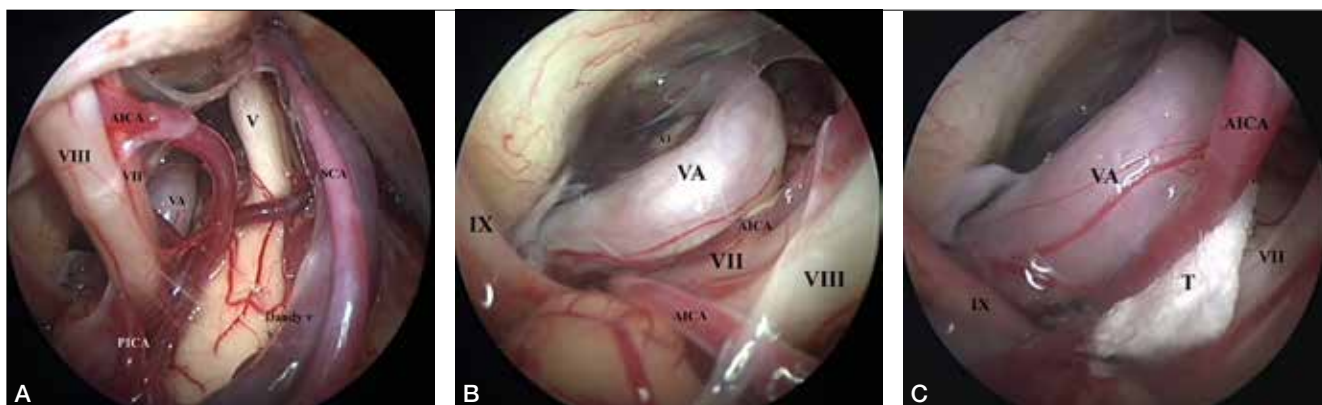


Fig. 5.5.3. Endoscopy of the left CPA. **A)** V (trigeminal nerve), SCA (superior cerebellar artery), VIII (auditory nerve), AICA (anterior-inferior cerebellar artery), VII (facial nerve), VA (vertebral artery), PICA (posterior-inferior cerebellar artery); **B)** offending vessels (AICA and VA) at the Root Exit Zone of the facial nerve (VII); **C)** decompression of the facial nerve (VII) with Teflon pad (T).

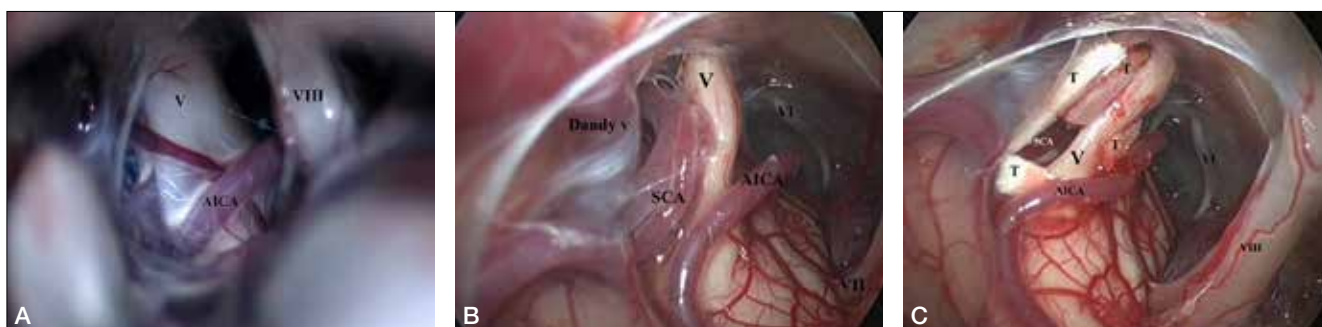


Fig. 5.5.4. Right trigeminal neuralgia. **A)** operating microscope view, V (trigeminal), VIII (auditory); **B)** endoscope view of the decompression of the SCA (superior cerebellar artery) from the trigeminal nerve (V); **C)** Teflon pads (T) insulating trigeminal nerve (V) from SCA and AICA.

dolichovertebral artery just below the REZ of the facial nerve and distorting it in 32% (Figs. 5.5.6A, B).

The endoscope-assisted procedure allows correct visualization of multiple offending vessels: a PICA with an obvious offending vertebral artery (11%) obstructing the view, a second loop of PICA at the medullo-pontine scissure, or an AICA along the brainstem underlying the other vessels (9%). The bifurcation of a dominant PICA or AICA occurs in contact with the root of the facial nerve and the vascular angle formed by this division embedding the nerve (8%). The AICA can be responsible for a facial compression in 13%, either on the cisternal course of the nerve or at the porus. If AICA is not the most common offending vessel, its pulsatile contact to a “hyperfunctioning” facial nerve can maintain hyperactivity on it and therefore lead to an abnormal muscle response.

Results

The success of the procedures varies from 83 to 97% in the literature. Since 1990, 705 patients suffering of hemifacial spasm were operated on. The complete relief of

spasm is achieved in 94% but 11% required an additional revision surgery. The complete resolution of spasm is immediate within one week of surgery in 75% of patients and delayed up to several weeks or months in 25% of patients, with 2 successful results after a long period of 12 and 18 months. The explanation for this delay is not clear and evokes the hypothesis of a residual hyperactivity of the facial nucleus. The result of MVD is stable over time, only 2 patients developed a distant recurrence, 5 and 11 years later.

The complications are low, essentially CSL leak in 3%. The incidence of hearing impairment to a level of deafness has decreased over the years from 5% to 1%. Only 1 postoperative facial paralysis occurred in a revision surgery of a patient operated previously somewhere else.

Auditory nerve^{15 16}

The relationship between the vascular compression and the symptoms is a “thorny issue” because of the lack of specificity of clinical signs and the frequency of AICA loop in contact with the acousticofacial nerve bundle.

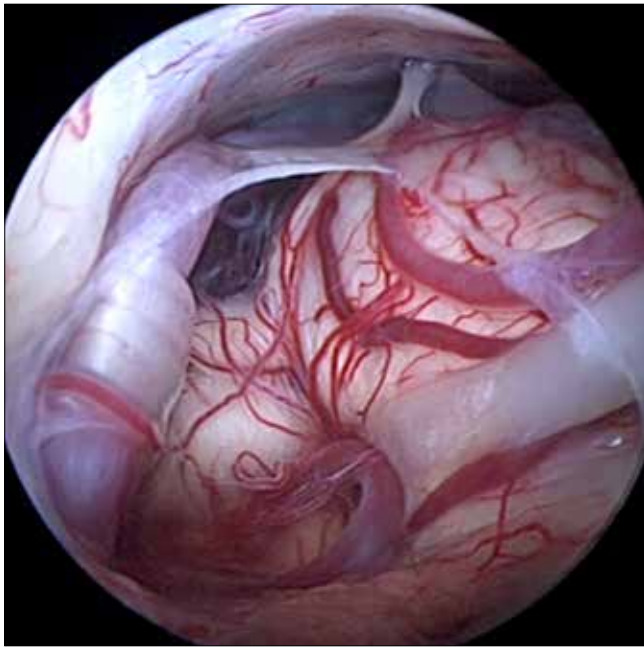

Fig. 5.5.5. Left hemifacial spasm with embedded PICA loop at the REZ of facial nerve.

1. MRI must be done with thin slices 0.4 mm to show the distortion of the nerve.
2. Complementary tests must confirm the involvement of the cochlear nerve in tinnitus with ABR abnormality (I-III inter peak prolonged latency of more 0.2 ms or I-III inter peak absolute interval superior to 2.3 ms) or of the vestibular nerve with a hyporreflexia that is relatively insensitive but at least points the affected side.

AICA, alone in 40% (Fig. 5.5.7A) or associated with PICA in 10%, is the more delicate vessel to manipulate because of the complexity of its course. This lies between the seventh and eight cranial nerves in 50% of patients, which prevents a fully efficient and complete vascular decompression. An intracanalicular loop requires drilling of the internal auditory canal (Fig. 5.5.7B). The labyrinthine artery rising from the most lateral loop limits the displacement of the vessel. Consequently peri-operative cochlear monitoring is mandatory. By placing the recording electrode in the foramen of Luschka, ABR (auditory brainstem response), CCAP (cochlear compound action potential) and DNAP (dorsal nucleus action potential) can be recorded (Fig. 5.5.8).

The other offending vessels can be the PICA in 28%, a subsarcuate artery “hugging” the auditory nerve in 20% (Fig. 5.5.8) and vein in 5%.

Results

The surgical results are not comparable to those obtained for trigeminal or facial nerves. Vascular compression-

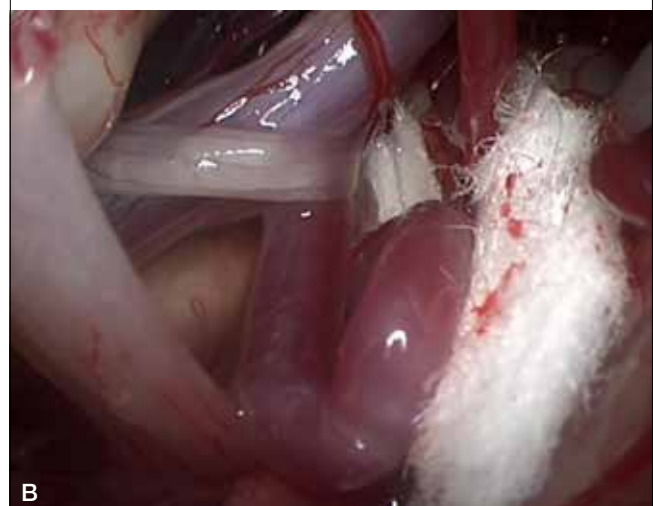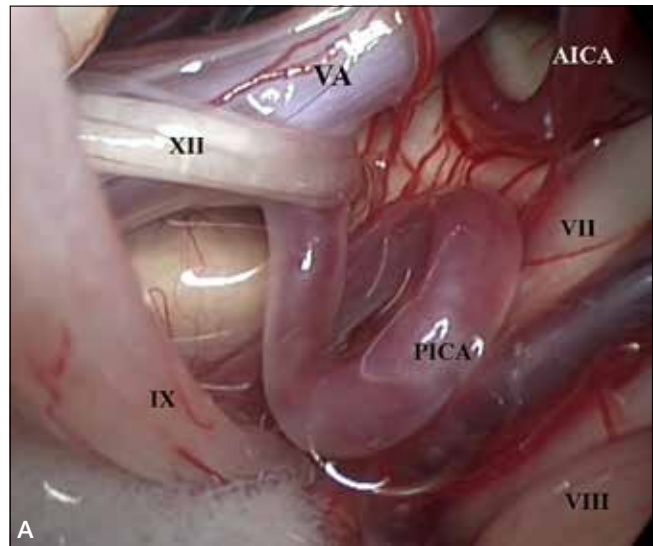


Fig. 5.5.6. Left hemifacial spasm. **A)** decompression of the REZ of the facial nerve (VII) from an offending PICA loop rising from VA (vertebral artery); **B)** Teflon (T) between the facial nerve and the offending vascular loop.

induced cochleovestibular neuropathy is still a controversial diagnosis with an uncertain vascular decompression. In the literature, the success rate varies from 33 to 77% with a large range of interpretation.

Since 1993 we performed 64 MVD of the auditory nerve in 62 cases mainly for unilateral incapacitating tinnitus alone or associated with vestibular symptoms in 40% and 2 cases of disabling vertigo without tinnitus.

At 2 year follow-up, tinnitus symptom was absent in 21%, decreased significantly for the patient in 31%, similar in 44% and worsening in 4%. The best results were obtained in cases of subsarcuate artery “hugging” the auditory nerve (7 cases), no positive result was achieved in cases of intracanalicular AICA loop. Interestingly, the hearing thresholds were slightly improved and ABR I-III < 0.2 ms relative to non-operated

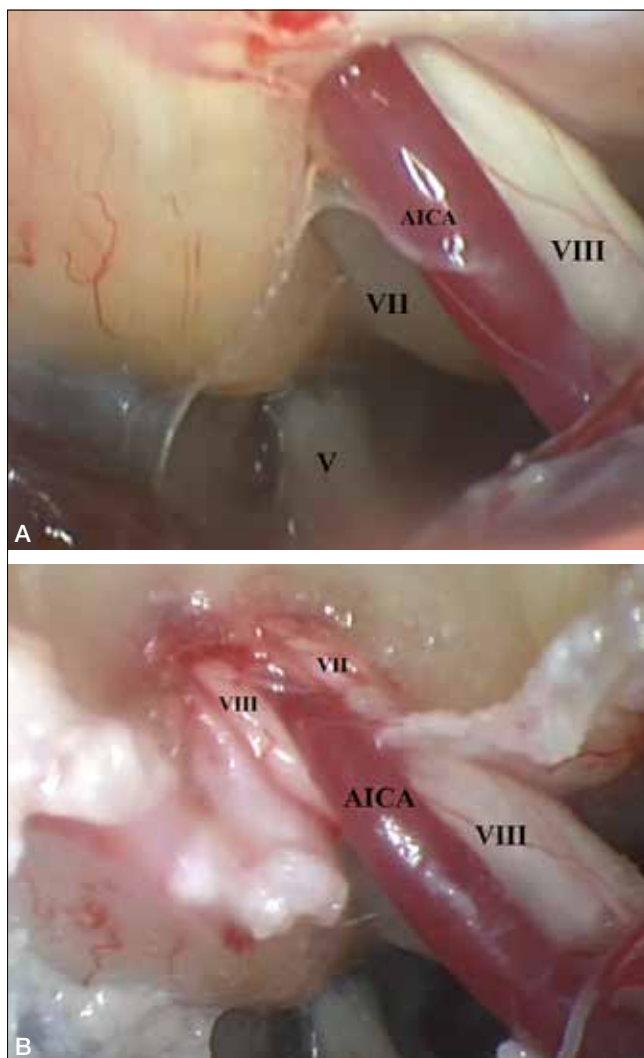


Fig. 5.5.7. Left incapacitating tinnitus. **A)** intracanalicular AICA loop VII (facial) VIII (auditory); **B)** drilling of the internal auditory canal to expose the cross-compression

side returned normal in patients with successful results. Postoperative hearing was unchanged in 37%; a 5 to 10 dB hearing loss was present in 15% and there was 1 case of hearing loss. In the follow up, one sudden and one progressive hearing loss occurred. The vestibular disorders disappeared without recurrence in 56%, and MVD was ineffective in 44%.

Conclusions

Surgery of trigeminal and facial nerves based on neurovascular decompression is the only curative treatment of patient suffering of trigeminal neuralgia and hemifacial spasm. Combining the use of both microscope and endoscope increases the efficiency of the procedure and decreases drastically the potential morbidity of the surgical procedure.

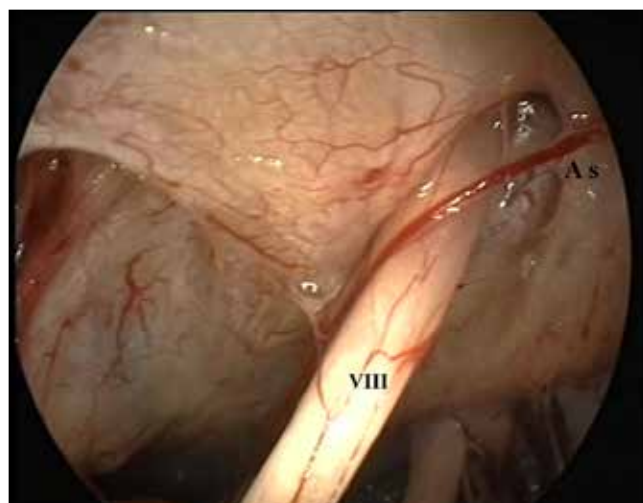


Fig. 5.5.8. Subarcuate artery (As) "hugging the auditory nerve" (VIII).

Surgery of auditory nerve is more challenging and the results are not comparable with those for trigeminal neuralgia and hemifacial spasm. Once the selection of the patients with vascular compression-induced tinnitus or vertigo will be clarified, the MVD of the auditory nerve should get a full acceptance.

Acknowledgements to Professor Carlo Zini and Pr. Mars Sindou for their teaching in this field.

5.6. Modern shifts in the clinical epidemiology of sporadic vestibular schwannoma and its implications

J.P. Marinelli, B.R. Grossardt, M.L. Carlson

Introduction

Since Eduard Sandifort's initial postmortem description of a "certain hard body" arising from the 8th Cranial Nerve in 1777, the management of sporadic vestibular schwannoma (VS) has been characterized by several distinctive eras ¹. From finger tumor enucleation in the late 1800s and Cushing's bilateral suboccipital craniectomy in the early 1900s to radiosurgery and observation with serial imaging in recent decades, the management of VS has gradually shifted towards increasingly conservative management over the last century ². Indeed, recent estimates suggest that a significant number of patients now undergo an initial period of observation alone, and the role of microsurgery continues to be reserved for fewer patients ³. Motivated by the significant sequelae of surgical intervention at the time, the origins of conservative management bear their inception to the mid-to late-1900s.

Yet, modern trends indicate that patients are increasingly being managed conservatively in the 21st century. In part, these observations are explained by a fundamental shift in the patient demographic of sporadic VS. Thought to stem from heightened use of magnetic resonance imaging (MRI), recent population-based studies suggest that VS is far more common than initially considered, with disease incidence paralleling traditionally more “common” diseases such as Parkinson’s disease and Hodgkin’s lymphoma⁴⁻⁸. In the current work, we review this evolution in the patient demographic of sporadic VS and its implications for future disease management and public health.

Background and controversies

Understanding clinical epidemiologic research

Before discussing the relevant controversies and emerging data regarding the epidemiology of VS, it is essential to first understand two key distinct definitions within the confines of clinical epidemiologic research (Fig. 5.6.1). First, the incidence of a disease is defined by the rate of new, previously undiagnosed cases in a given population over a specified time interval. With the burden of verifying patients’ first-ever lifetime diagnosis over a defined period in time, the reporting of disease incidence is almost exclusively confined to population-based studies. Next, disease prevalence represents the cross-sectional proportion (or frequency) of a given population who are living with a disease, often reported on a specific date. In a chronic disease, where people live many years without being “cured,” incident cases accumulate over time resulting in prevalence frequencies that significantly exceed incidence rates with a trend towards the highest disease prevalence in older age groups. In summary, the incidence rate of a disease provides information about the rate at which people are developing the disease of interest, and disease prevalence describes how many people are affected by the disease within a population at a specific point in time.

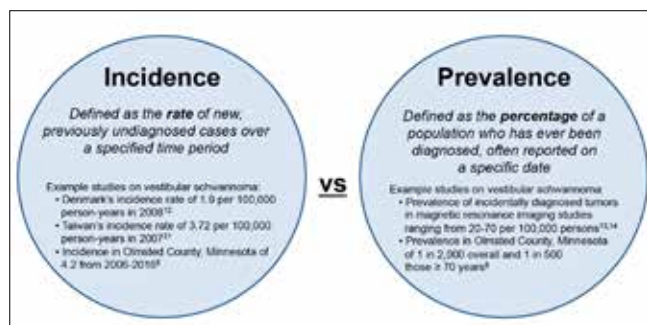


Fig. 5.6.1. Contrasting disease incidence to disease prevalence within the confines of epidemiologic research.

The controversy: how common is vestibular schwannoma, really?

Partly secondary to imprecise usage of these epidemiological definitions, the literature on the epidemiology of sporadic VS can appear inconsistent. For instance, the oft given response to the clinical question of, “How common is VS?” is, “1 in 100,000.” This response reflects population-based studies’ estimates of disease incidence, which historically have reported incidence rates within this range³⁻¹². Yet, MRI studies performed in the early 2000s show that the prevalence of incidental VS exceeds these incidence rates by at least an order of magnitude¹³⁻¹⁵. Stated another way, the prevalence of a subset of the affected VS population (i.e., those with incidental and theoretically asymptomatic tumors) far exceeded the incidence of all new patients. Of course, as alluded to in the preceding paragraph surrounding definitional distinctions within clinical epidemiologic research, it is expected that the prevalence of VS would exceed the incidence rate; however, the magnitude at which MRI studies’ prevalence exceeds the incidence rate raises the possibility that population-based studies underestimate the commonness of VS. Compounding this, temporal bone studies performed at autopsy suggested that the prevalence of incidental tumors may approximate 1 per 1,000 persons^{16,17}.

Incidence of sporadic vestibular schwannoma

Historical incidence rates

In the 1960s and 1970s, population-based studies from the Faroe Islands and Denmark estimated the incidence rate of VS to be less than 1 newly diagnosed case per 100,000 person-years; specifically, 0.54 new cases per 100,000 person-years in Denmark from 1957 to 1976. In the United States, historical population-based research has been limited by the absence of a centralized health system and accompanying population-based databases. Perhaps the only available epidemiological resource dating back to this period within the United States is the Rochester Epidemiology Project (REP), a unique medical records-linkage system that connects patient encounters from every resident of Olmsted County, Minnesota across providers within the geographic region (including Olmsted Medical Center, Mayo Clinic, and other private and smaller providers)¹⁸. Interestingly, using the REP exhaustive infrastructure, the incidence of VS from 1966 to 1975 approximated more modern estimates of disease incidence at a rate of 1.5 new cases per 100,000 person-years⁷.

Incidence using Denmark’s national database

Some of the most robust existing clinical epidemiologic research was performed using Denmark’s unique national VS database. Beginning in 1976, all patients diagnosed with VS

in Denmark are referred to Copenhagen University Hospital for management ¹¹. Since database inception, patients have been prospectively registered in this national database, enabling national population-based estimates of incidence rates over time ¹⁹. Using this database, it was determined that the incidence of VS increased from 0.78 per 100,000 person-years from 1978-1983 to 1.74 during 1996-2001, peaking at 2.28 in 2004. Four years later, Stangerup and colleagues demonstrated that the national incidence began declining to a rate of 1.94 per 100,000 person-years in 2008 ^{12 20}.

Incidence estimates in the United States

As previously stated, population-based research in the United States has been limited by the lack of longstanding national database registries. Nevertheless, after the Benign Brain Tumor Cancer Registries Amendment Act of 2004 (Public Law 107-260), the registration of VS has been nationally mandated. Since that time, studies have shown that the incidence of VS in the United States is approximately 1.1 per 100,000 person-years in 2011 ^{3 10}.

Recent developments in disease incidence

Perhaps the first recent study to show VS may affect significantly more people than the aforementioned population-based studies' suggest was a conference paper that examined the incidence of VS in Beverly Hills, California ⁶. In this study, Schwartz and Fisher identified 11 cases of VS from 1999-2004 resulting in an incidence rate of 5.4 per 100,000 person-years. Corroborated by the MRI studies on incidentally diagnosed tumors published around the same time, the unique patient demographic of Beverly Hills likely contributed to the distinctly elevated detection rate of VS in this population.

Recently, using a national database in Taiwan over the period of 2001 to 2012, the highest annual incidence rate was observed to reach 3.72 per 100,000 person-years. Interestingly, the incidence climbed to 4.86 per 100,000 person-years amongst those persons aged 60-69 years ²¹. Similarly, Maarten, et al. examined the national incidence of VS in the Netherlands and showed that incidence of VS in the Leiden region was 3.32 per 100,000 person-years from 2009-2012 ²².

Including data through 2016, the incidence of sporadic VS in Olmsted County, Minnesota was estimated using the REP. Amidst a population of approximately 160,000 persons, the incidence rate of VS was shown to be 4.2 per 100,000 person-years from 2006-2016 with an increase over the last five years to 4.5 ^{7 23}. Most notably, the incidence rate increased with older age, with an incidence rate of 11.1 per 100,000 person-years in those aged 60-69 years and 18.3 in individuals aged 70 years and older. Similar to the demographic of the population of Beverly Hills in the study by Schwartz and Fisher, the Olmsted County population possesses several unique characteristics. Namely, the economy of Olmsted

County is driven by health care, with nearly 40% of the population working in this industry, a feature nearly 4-times the national average in the United States. Moreover, this characteristic likely significantly influences overall health literacy and patients' ease-of-access to medical care and thus MRI ⁷. Substantiating this rationale surrounding patients' ease-of-access to MRI, nearly 1 in 3 individuals 70 years and older living in Olmsted County in 2017 have undergone head imaging with MRI ⁸.

Prevalence of sporadic vestibular schwannoma

Historical prevalence from temporal bone studies

The first estimates of disease prevalence stem from temporal bone studies performed at autopsy that investigated incidentally diagnosed VS ^{16 24 25}. Prevalence estimates of VS from temporal bone studies have varied widely, ranging from 2.4% to 0% ^{24 26}. Nonetheless, the ability of temporal bone studies to detect even the smallest of tumors render offers a distinctive look at the prevalence of incidental tumors. However, the implications of temporal bone findings on the clinical epidemiology and population health aspects of VS are inherently limited by study design. Beyond the current limitations of MRI that preclude clinical diagnosis of sub-millimeter tumors, autopsy data is unavoidably biased towards sicker, elderly individuals with multiple comorbidities. Moreover, the selection of temporal bones comprising these studies has been questioned ²⁶⁻²⁸. Notwithstanding these limitations, temporal bone studies provide unparalleled insight into the natural history of VS, demonstrating that over time, many people develop small VSs that often go undetected clinically.

Prevalence of incidental tumors in MRI studies

In the early 2000s, several studies reviewed thousands of historical MRI scans and reported that the clinical prevalence of incidentally diagnosed VS ranged between 20 and 70 persons per 100,000 persons (0.02% to 0.07%) ^{13 14}. Albeit biased towards older patients who required head imaging for various indications, these studies demonstrate that a surprisingly large number of people have asymptomatic VS, and these studies foreshadow a fundamental shift in the patient demographic of VS. In particular, many people are now being incidentally diagnosed with asymptomatic VS, when only 10 to 20 years prior to the advent and widespread use of MRI, such patients would have died without ever being diagnosed with VS.

Recent developments in disease prevalence

Using the REP, the prevalence of sporadic VS was examined in the population of nearly 160,000 persons residing in Olmsted County, Minnesota, on January 1, 2017 ⁸. Concomitant with the elevated incidence rates of VS observed in the same population over the past 30 years ⁷, the current prevalence of

sporadic VS amongst all ages was 42.0 per 100,000 persons (0.042%) and increased to 109.1 in those aged 60-69 (0.11%) and 212.4 (0.21%) in those 70 years and older. Moreover, the prevalence of asymptomatic, incidentally diagnosed tumors was 10.3 per 100,000 (0.010%) among adults age 20 and older and was highest amongst those age 70 years and older at 31.2 (0.031%). Substantiating these prevalence estimates, when including only those persons who had undergone head imaging with MRI, the prevalence of incidental tumors closely paralleled past MRI studies ⁸.

The changing patient demographic

An aging patient population

The recent findings surrounding disease incidence rates and prevalence frequencies suggest that the modern demographic of patients diagnosed with sporadic VS is changing. As mentioned previously, the highest incidence rate is found in elderly persons, approximating 20 per 100,000 person-years for those 70 years and older from the most recent population-based estimates ⁷. Naturally following disease incidence rates, the prevalence amongst this elderly population is over 1 in 500 persons ⁸. Correspondingly, the median age at diagnosis steadily increased over the past several decades from approximately 50 years to 60 years ^{7,12}. The analogous increase in life-expectancy over this time period alone cannot account for the increase in average age at diagnosis.

Evolving symptomatology and incidentally diagnosed tumors
Stemming from improved detection methods and disease understanding, patients are now being diagnosed with fewer attributable symptoms and at significantly shorter times after symptom onset compared to decades prior. Once commonly presenting with multiple cranial neuropathies and hydrocephalus ², patients with only audiovestibular symptoms or no symptoms characterize the modern era (Fig. 5.6.2A, B) ⁷.

The increasingly common incidental tumor typifies the current shifts in VS epidemiology. With the growing use of MRI in routine diagnostic workup, small incidental tumors are frequently found (Fig. 5.6.2C, D). To this end, nearly 25% of all tumors diagnosed over the most recent decade in Olmsted County were found incidentally after patients underwent neuroimaging for seemingly unrelated indications ⁷. In this way, the incidence rate of incidentally diagnosed tumors alone in this population was approximately 1 per 100,000 person-years over the most recent decade.

Changing tumor size and location

Inextricably connected to the rising incidence of incidentally diagnosed tumors, patients are now most often diagnosed with small intracanalicular tumors. Fifty years ago, all tumors were diagnosed only after significant extension into the cerebellopontine angle ⁷. By 2001, Danish national data

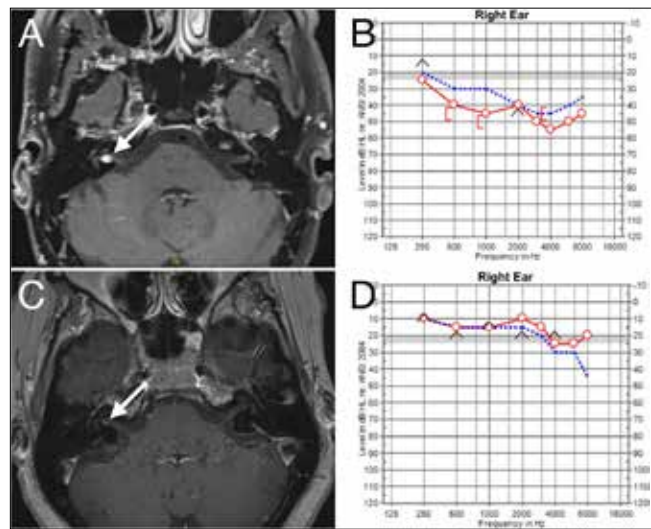


Fig. 5.6.2. A, B) 68-year-old man with minimal asymmetrical sensorineural hearing loss and a 4 mm right-sided intracanalicular vestibular schwannoma that has not grown over the course of 18 months of observation. C, D) 58-year-old woman with an incidentally diagnosed 2 mm right-sided distal intracanalicular lesion most consistent with a tiny vestibular schwannoma.

showed that nearly a third of tumors were confined to the internal auditory canal at time of diagnosis ¹². Strikingly, over the last decade in Olmsted County, nearly 75% of tumors were intracanalicular at diagnosis. Moreover, the median intracanalicular size has steadily decreased over the last 3 decades from 8 mm to 4 mm in the most recent decade ⁷.

Etiology of an increasingly common tumor

The most commonly employed rationale behind the rising incidence of VS stems from a combination of increased use of MRI and increasingly widespread implementation of screening protocols for asymmetrical sensorineural hearing loss. That is to say, the increase in disease incidence has been primarily driven by improved detection rather than a true increase in disease development. Supporting this theory, past population-based studies have shown that an inflection point in the incidence rate of VS exists around the time of the advent of MRI and widespread use of contrast enhanced thin slice MRI. For instance, in Denmark, the incidence of VS increased from roughly 0.8 per 100,000 person-years in the pre-MRI era to 1.74 from 1996-2001. In Olmsted County, the incidence rate increased from 1.4 per 100,000 person-years in the pre-CT era to 2.1 from 1986-1995 and 3.2 from 1996-2005 in the era of MRI.

Implications of a changing patient demographic

The observed shifts in the patient demographic of sporadic VS bear several important implications. First, the rising disease

prevalence fundamentally alters the way in which we think about VS as a whole. For instance, recent incidence rates for VS exceed those of historically much more publicized diseases such as Hodgkin's lymphoma and closely parallel the rates of Parkinson's disease, the second most common neurodegenerative disorder worldwide^{4,5}. What is more, most countries define a "rare disease" based on a disease prevalence that falls between 1 in 1,500 to 1 in 2,500 persons. For instance, the European Union defines rare diseases as those with a life-threatening or chronic debilitating condition with a prevalence of 50 per 100,000 persons (or, 1 in 2,000)²⁹. Similarly, the Rare Disease Act of 2002 (Public Law 107-280) defines a rare disease in the United States to be one with a prevalence less than 1 per 1,500 persons. To be considered a rare disease in Taiwan, disease prevalence must not be more than 1 per 10,000 persons. Narrower than all the aforementioned countries, China defines a rare disease as one with a prevalence less than 1 in 500,000 persons³⁰. Therefore, by recent prevalence estimates, VS would no longer be officially considered a "rare disease" in several areas of the world. Moreover, among those over age 60, the prevalence of sporadic VS exceeds rare disease thresholds by over an order of magnitude in both Europe and the United States.

Beyond reclassifying sporadic VS as a more common disease than originally considered, the shifting patient demographic towards an aging population harbors larger healthcare implications. With the highest disease incidence amongst older individuals who often carry other medical comorbidities, initial management with observation by serial imaging will likely continue to be increasingly employed. First, there is growing concern surrounding the potential deleterious long-term health implications of repeated use of intravenous contrast for MRI following gadolinium deposition³¹. Moreover, compounded by the likelihood that the incidence of VS will only increase in the coming years with increasing use of MRI, the cost of serial imaging will continue to rise. These two concerns may further drive the practice of obtaining non-contrast thinly sliced heavily-weighted T2 imaging for disease surveillance, thereby reducing gadolinium exposure and cost of imaging.

Finally, the aging, often incidentally diagnosed patient demographic characterizes an ongoing transition in the management of sporadic VS at-large. The increased ability to detect even small VSs amongst an elderly population suggests that the emerging era of VS management will be one largely comprised of "chronic disease management" compared to one of microsurgery and radiosurgery of decades past.

Conclusions

Historically considered a rare tumor that presented with multiple cranial neuropathies, hydrocephalus, and the "Syndrome of the Cerebellopontile Angle" in the Cushing era², sporadic VS in the modern era is characterized by symptomatology limited to audiovestibular symptoms alone or no symptoms (i.e., incidental cases). Disease incidence rates now approach 5 per 100,000

person-years with disease prevalence of 1 in 2,000 overall and reaching 1 in 500 in adults aged 70 years and older. These incidence rates parallel disorders such as Parkinson's disease and Hodgkin's lymphoma, and the prevalence frequencies of VS surpass the threshold of a "rare disease" by several countries' definitions. Lastly, the aging patient demographic foreshadows that the emerging era of VS management will be one largely composed of "chronic disease management" opposed to one characterized by definitive surgical treatment.

5.7. Preventing surgical morbidity in jugular paraganglioma

The two ends of aggressiveness, the partial targeted approach and the extended skull base petro-occipital approach

A. Mazzoni

The tympano-jugular paraganglioma (TJPGL) seems to present evolving concepts concerning both nature and treatment of the tumor. It is not universally defined a benign tumor, as some authors state that it is malignant¹ with a genetic dependent aggressiveness. Clinical experience, on the other hand, points out its capricious behavior and thus seems to belittle how its still obscure nature influence the principles of therapy.

Treatment morbidities, mainly surgical but not only, impact on the choice of treatment. For instance, the function of the IX, X cranial nerves decides the choice between observational and active therapy. While it is undisputed that the infratemporal approach type A allows radical removal and recovery of the tumor albeit with morbidities, a continuum of alternative procedures aims at avoiding or lowering such morbidities. There are two procedures lying at the two ends of surgical aggressiveness that have been lately proposed and may deserve to be discussed, the partial targeted surgery (PTS) on tumor submitted to observation¹, and the extended petro-occipital approach (POa)² to large intradural growth often deemed to incomplete resection or even considered inoperable.

The PTS is mainly a principle of therapy and adopts conventional approaches². It involves resection of a limited portion of a growing tumor causing an actual or potential damage and thus permitting to continue an otherwise correct observation. In other words, since it is applied to a case under observation, it extends the principle of the balance between natural and surgical morbidity in favor of observation by removing the tumor portion that can change the balance. The PTS is directed to three conditions as follow. The bleeding growth in the external auditory canal, tumor in contact with, or invading, the Fallopius canal and tumor compressing the brain stem. The procedure on the external auditory canal involves removing the tumor and suturing the canal skin. The procedure on the facial nerve involves a mastoidectomy or a lateral

petrosectomy, and removal of the local tumor with the option of grafting. The large intradural tumor compressing the brain stem is resected with a transigmoid petro-occipital approach, that is a suboccipital craniotomy combined with a transigmoid petrosectomy. The removal of the intradural tumor eliminates the brain compression and avoids a larger and riskier procedure including the dissection from the carotid artery. Indication to PTS is the same as observation of which it is a surgical appendix allowing the continuance of the same.

The PO³ approach is the second stage removal of the intradural TJPGl of which the extradural part was previously removed with the infratemporal A approach. It is a combination of a full fledge suboccipital approach with the extradural field of the IT A approach. This approach is dedicated to the > 4 cm. large intradural PGL and aims at extending the operability and safety of resection of large tumors that can be, and in the past were felt to be, hardly operable. The highlights of the approach are as follows:

- the surgical field of the previous IT A approach is reopened by removing the obliterating fat up to the internal carotid artery;
- petrous bone, posterior half of occipital condyle and low clivus are drilled off to circumferentially expose the dura all around the root of the intradural tumor;
- the dura is coagulated around the tumor root thus obtaining closure of the main blood supply and shrinking of the mass;
- suboccipital craniotomy adjoining the extradural field of the IT A approach.

The room gained combining the two approaches and the pre-hemiptic closure of blood supply are the fundamental steps for safe resection. The tumor mass can be displaced anteriorly into the field of skull base removal thus exposing the interface tumor-brain stem, and dissected.

Our experience suggested that changing the goal of surgery as in PTS as well as enlarging the access as in the PO approach can lessen the morbidity. Trial by other centers will say whether these approaches can be part of the multioptional therapies for TJPGl.

6. Conclusions

A. Mazzoni

The goal of this report was to take a sort of snapshot of the present state of affairs in the domain of skull base surgery, which has become a focus of interest in otology and neurosurgery, and made some surprising progress. The many contributors deserve our appreciation for the quality of their work, and for succeeding in condensing their topic in the limited space allowed by the setting of this report.

In order to comply with the size constraint and preserve informative power, each topic was treated following two ways. Some of the authors choose a wide exposure of their topic,

in order to make it clear and understood also by not so experienced readers. Some others adopted a synthetic overview, underlining principles and key-points where they concentrated their experience and referenced articles.

It was in the 1960s that it gradually started to become clear that skull base surgery involves making room around a targeted lesion lying within the skull base or at adjacent sites, creating a space within both the bone and the intra- and extracranial tissues. Imaging was the tool used for diagnostics and for planning the treatment, and the microscope the instrument for performing it. The same fundamentals still apply today, but it is becoming clear that microsurgery has reached its limit. The microscope and our micromanual skills are unable to further improve our precision. A breakthrough is needed in the mechanical tissue handling methods.

Leaving aside this issue for the moment, there are other points attracting our attention, such as: teaching and training in the area of skull base surgery; the opportunities for authors and centers to share details of their techniques; the lack of basic research to fill the gap, for instance, between better diagnostics (thanks to more advanced technologies) and the therapies available; and the dual nature of today's skull base surgeons. This last issue is of particular interest to us. The multidisciplinary nature of skull base surgery necessitates a joint effort by two or more specialists, otologists and neurosurgeon, or the combination in the same surgeon of techniques drawn from different specialties - in other words, procedures performed either by more than one surgeon or by one surgeon with more than one type of expertise. Is the procedure planned and performed in the same way in both cases? Probably not, but progress has come from both sources, so it is our conviction that both should be maintained.

What about the next generation of skull base surgeons, who will take responsibility for the survival and advancement of skull base surgery? Though it might seem obvious, we should always bear in mind that learning the mind-driven craftsmanship needed for one of the most difficult types of surgery demands a lasting commitment to gaining experience (both "en solitaire" and through teaching-mentoring), a clear will to share our experiences, and the awareness and acceptance of the burden of such a complex surgical field.

Acknowledgements

For Padova University, the authors thank Frances Coburn and Enrico Alexandre, MD, for the English revision of this report.

Conflict of interest statement

None declared.

References

2.2. Evidence-based therapy in diseases of the skull base

- 1 Slim K, Nini E, Forestier D, et al. *Methodological index for non-randomized studies (MINORS): development and validation of a new instrument*. ANZ Sug 2003;73:712-8.
- 2 Schmoorl C, Gall C, Stampf S, et al. *Correction of confounding bias in non-randomized studies by appropriate weighting*. Biometrical J 2011;2:369-87.

3.1. The translabyrinthine approach

- 1 Fisch U, Mattox D. *Microsurgery of the skullbase*. Thieme Publishing Group; 1988.
- 2 Friedman RA. *Lateral skull base surgery*. Thieme Publishing Group; 2012.
- 3 Jackler RK. *Atlas of skull base surgery and neurotology*. Thieme Publishing Group; 2008.
- 4 Sanna M. *Atlas of microsurgery of the lateral skull base*. Thieme Publishing Group; 2007.

3.3. The modified transcochlear approaches

- 1 House WF, Hitselberger WE. *The transcochlear approach to the skull base*. Arch Otolaryngol 1976;102:334-42.
- 2 Gantz BJ, Fisch U. *Modified transotic approach to the cerebellopontine angle*. Arch Otolaryngol 1983;109:252-6.
- 3 Sanna M, Mazzoni A, Saleh E, et al. *The system of the modified transcochlear approach: a lateral avenue to the central skull base*. Am J Otol 1998;19:88-97.
- 4 Sanna M, Saleh E, Kraiss T, et al. *The transcochlear approaches*. In: *Atlas of microsurgery of the lateral skull base*. Stuttgart, New York: Georg Thieme Verlag; 2008. pp. 80-129.
- 5 Sanna M, Mazzoni A, Gamoletti R. *The system of the modified transcochlear approaches to the petroclival area and the prepontine cistern*. Skull Base Surg 1996;6:237-48.

3.4. The middle cranial fossa approach

- 1 House WF. *Surgical exposure of the internal auditory canal and its contents through the middle, cranial fossa*. Laryngoscope 1961;71:1363-85.
- 2 House WF, Shelton C. *Middle fossa approach for acoustic tumor removal*. Neurosurg Clin N Am 2008;19:279-88.
- 3 Fisch U, Yasargil G. *Transtemporal extralabyrinthine operations on the internal auditory canal, the eighth and the seventh cranial nerves*. In: *Microsurgery applied to neurosurgery*. Stuttgart, New York: Georg Thieme Verlag; 1969. pp. 195-210.
- 4 Brackmann DE, House JR, Hitselberger WE. *Technical modifications to the middle fossa craniotomy approach in removal of acoustic neuromas*. Am J Otol 1994;15:614-9.
- 5 Wigand ME, Haid T, Berg M, et al. *The enlarged transtemporal*

approach to the cerebellopontine angle: technique and indications. Acta Otorhinolaryngol Ital 1982;2:571-82.

- 6 Kanzaki J, Kawase T, Sano K, et al. *A modified extended middle cranial fossa approach for acoustic tumors*. Arch Otorhinolaryngol 1977;217:119-21.
- 7 American Academy of Otolaryngology-Head and Neck Surgery Foundation I. *Committee on hearing and equilibrium guidelines for the evaluation of hearing preservation in acoustic neuroma (vestibular schwannoma)*. Otolaryngol Head Neck Surg 1995;113:179-80.
- 8 Scheich M, Ehrmann-Müller D, Shehata-Dieler W, et al. *Hearing results after middle fossa removal of small (T1/T2) vestibular schwannomas*. HNO 2017;65:751-7.
- 9 Wang AC, Chinn SB, Than KD, et al. *Durability of hearing preservation after microsurgical treatment of vestibular schwannoma using the middle cranial fossa approach*. J Neurosurg 2013;119:131-8.
- 10 Arts HA, Telian SA, El-Kashlan H, et al. *Hearing preservation and facial nerve outcomes in vestibular schwannoma surgery: results using the middle cranial fossa approach*. Otol Neurotol 2006;27:234-41.
- 11 House JW, Brackmann DE. *Facial nerve grading system*. Otolaryngol Head Neck Surg 1985;93:146-7.
- 12 Ginzkey C, Scheich M, Harnisch W, et al. *Outcome on hearing and facial nerve function in microsurgical treatment of small vestibular schwannoma via the middle cranial fossa approach*. Eur Arch Otorhinolaryngol 2013;270:1209-16.
- 13 Baier G, Schwager K, Helms J, et al. *Results in otosurgically treated patients with acoustic neuroma. Part 1: Facial nerve function after translabyrinthine and middle fossa resection*. Laryngorhinootologie 2008;87:565-72.
- 14 Meyer TA, Canty PA, Wilkinson EP, et al. *Small acoustic neuromas: surgical outcomes versus observation or radiation*. Otol Neurotol 2006;27:380-92.
- 15 Irving RM, Jackler RK, Pitts LH. *Hearing preservation in patients undergoing vestibular schwannoma surgery: comparison of middle fossa and retrosigmoid approaches*. J Neurosurg 1998;88:840-5.
- 16 Noudel R, Gomis P, Duntze J, et al. *Hearing preservation and facial nerve function after microsurgery for intracanalicular vestibular schwannomas: comparison of middle fossa and retrosigmoid approaches*. Acta Neurochir (Wien) 2009;151:935-44.
- 17 Ehrmann-Müller D, Mlynski R, Ginzkey C, et al. *Direct recording from cochlear nerve via a ball-electrode in transtemporal acoustic neuroma surgery*. Laryngo-Rhino-Otol 2012;91:22-7.
- 18 Yamakami I, Uchino Y, Kobayashi E, et al. *Computed tomography evaluation of air cells in the petrous bone-relationship with postoperative cerebrospinal fluid rhinorrhea*. Neurol Med Chir (Tokyo) 2003;43:334-8.
- 19 Faure A, Masse H, Gayet-Delacroix M, et al. *What is the arcuate eminence?* Surg Radiol Anat 2003;25:99-104.
- 20 Scheich M, Ginzkey C, Harnisch W, et al. *Use of flexible CO(2) laser fiber in microsurgery for vestibular schwannoma via the middle cranial fossa approach*. Eur Arch Otorhinolaryngol 2012;269:1417-23.
- 21 Falcioni M, Romano G, Aggarwal N, et al. *Cerebrospinal fluid leak after retrosigmoid excision of vestibular schwannomas*. Otol Neurotol 2008;29:384-6.
- 22 Lüdemann WO, Stieglitz LH, Gerganov V, et al. *Fat implant is superior to muscle implant in vestibular schwannoma surgery for the prevention of cerebrospinal fluid fistulae*. Neurosurgery 2008;63(Suppl 1):38-42.
- 23 Chamoun R, MacDonald J, Shelton C, et al. *Surgical approaches for resection of vestibular schwannomas: translabyrinthine, retrosigmoid, and middle fossa approaches*. Neurosurg Focus 2012;33:9.

- ²⁴ Sughrue ME, Yang I, Aranda D, et al. *Hearing preservation rates after microsurgical resection of vestibular schwannoma*. J Clin Neurosci 2010;17:1126-9.
- ²⁵ DeMonte F, Gidley PW. *Hearing preservation surgery for vestibular schwannoma: experience with the middle fossa approach*. Neurosurg Focus 2012;33:10.
- ²⁶ Arlt F, Trantakis C, Krupp W, et al. *Cerebrospinal fluid leak after microsurgical surgery in vestibular schwannomas via retrosigmoidal craniotomy*. Neurol Res 2011;33:947-52.
- ²⁷ Scheich M, Ginzkey C, Ehrmann-Müller D, et al. *Complications of the middle cranial fossa approach for acoustic neuroma removal*. J Int Adv Otol 2017;13:186-90.
- ²⁸ Ansari SF, Terry C, Cohen-Gadol AA. *Surgery for vestibular schwannomas: a systematic review of complications by approach*. Neurosurg Focus 2012;33:14.
- ²⁹ Weber PC, Gantz BJ. *Results and complications from acoustic neuroma excision via middle cranial fossa approach*. Am J Otol 1996;17:669-75.
- ³⁰ Selesnick SH, Liu JC, Jen A, et al. *The incidence of cerebrospinal fluid leak after vestibular schwannoma surgery*. Otol Neurotol 2004;25:387-93.
- ³¹ Scheich M, Ginzkey C, Ehrmann-Müller D, et al. *Management of CSF leakage after microsurgery for vestibular schwannoma via the middle cranial fossa approach*. Eur Arch Otorhinolaryngol 2016;273:2975-81.
- ³² Selesnick SH, Liu JC, Jen A, et al. *Management options for cerebrospinal fluid leak after vestibular schwannoma surgery and introduction of an innovative treatment*. Otol Neurotol 2004;25:580-6.
- ³³ Mangus BD, Rivas A, Yoo MJ, et al. *Management of cerebrospinal fluid leaks after vestibular schwannoma surgery*. Otol Neurotol 2011;32:1525-29.
- ³⁴ Minovi A, Mangold R, Kollert M, et al. *Functional results, cognitive and effective quality of life disturbances after trans-temporal resection of acoustic neuroma*. Laryngo-Rhino-Otol 2005;84:915-20.
- ³⁵ Sanna M, Taibah A, Russo A, et al. *Perioperative complications in acoustic neuroma (vestibular schwannoma) surgery*. Otol Neurotol 2004;25:379-86.
- ³⁶ Nuseir A, Sequino G, De Donato G, et al. *Surgical management of vestibular schwannoma in elderly patients*. Eur Arch Otorhinolaryngol 2012;269:17-23.
- ⁸ Kadri PA, Al-Mefty O. *The anatomical basis for surgical preservation of temporal muscle*. J Neurosurg 2004;100:517-22.
- ⁹ Spiriev T, Ebner FH, Hirt B, et al. *Fronto-temporal branch of facial nerve within the interfascial fat pad: is the interfascial dissection really safe?* Acta Neurochir (Wien) 2016;158:527-32.
- ¹⁰ Ammirati M, Spallone A, Ma J, et al. *An anatomical study of the temporal branch of the facial nerve*. J Neurosurg 1993;33:1038-43.
- ¹¹ Salas E, Ziyal IM, Bejjani GK, et al. *Anatomy of the frontotemporal branch of the facial nerve and indications for interfascial dissection*. Neurosurg 1998;43:563-8.
- ¹² Yaşargil MG, Reichman MV, Kubik S. *Preservation of the fronto-temporal branch of the facial nerve using the interfascial temporalis flap for pterional craniotomy*. J Neurosurg 1987;67:463-6.
- ¹³ Poblete T, Jiang X, Komune N, et al. *Preservation of the nerves to the frontalis muscle during pterional craniotomy*. J Neurosurg 2015;122:1274-82.
- ¹⁴ McLaughlin N, Cutler A, Martin NA. *Technical nuances of temporal muscle dissection and reconstruction for the pterional keyhole craniotomy*. J Neurosurg 2013;118:309-14.
- ¹⁵ Oikawa S, Mizuno M, Muraoka S, et al. *Retrograde dissection of the temporalis muscle preventing muscle atrophy for pterional craniotomy. Technical note*. J Neurosurg 1996;84:297-9.
- ¹⁶ Vishteh AG, Marciano FF, David CA, et al. *The pterional approach*. Oper Tech Neurosurg 1998;1:39-49.
- ¹⁷ Spetzler RF, Lee KS. *Reconstruction of the temporalis muscle for the pterional craniotomy*. J Neurosurg 1990;73:636-7.
- ¹⁸ Ezer H, Banerjee AD, Shorter C, et al. *The "agnes Fast" craniotomy: the modified pterional (osteoplastic) craniotomy*. Skull Base 2011;21:159-64.
- ¹⁹ Kim E. *Osteoplastic pterional craniotomy*. J Neurosurg 2011;68(Suppl operative 1):125-9.
- ²⁰ Park J, Hamm I-S. *Cortical osteotomy technique for mobilizing the temporal muscle in pterional craniotomies. Technical note*. J Neurosurg 2005;102:174-8.
- ²¹ Lehecka M, Laakso A, Hernesniemi J. *Specific techniques and strategies for different pathologies - aneurysms*. In: *Helsinki microneurosurgery basics and tricks*. Germany: Druckerei Hohl GmbH & Co. KG; 2011. pp. 195-206.
- ²² Chaddad-Neto F, Campos-Filho JM, Dória-Netto HL, et al. *The pterional craniotomy: tips and tricks*. Arq Neuropsiquiatr 2012;70:727-32.

3.5. The pterional approach

- ¹ Heuer GJ. *Surgical experiences with an intracranial approach to chiasmal lesions*. Arch Surg 1920;1:368-81.
- ² Yasargil MG, Fox JL. *The microsurgical approach to intracranial aneurysms*. Surg Neurol 1975;3:7-14.
- ³ Altay T, Couldwell WT. *The frontotemporal (pterional) approach: an historical perspective*. Neurosurg 2012;71:481-92.
- ⁴ Andrews RJ, Bringas JR. *A review of brain retraction and recommendations for minimizing intraoperative brain injury*. Neurosurg 1993;33:1052-63.
- ⁵ Spetzler RF, Dasplit CP, Pappas CT. *The combined supra- and infratentorial approach for lesions of the petrous and clival regions: experience with 46 cases*. J Neurosurg 1992;76:588-99.
- ⁶ Figueiredo EG, Deshmukh P, Zabramski JM, et al. *The pterional-transsylvian approach: an analytical study*. Neurosurgery 2008;62(Suppl 6):263-9.
- ⁷ Menovsky T, Sener S, Kamerling N, et al. *Preservation and microsurgical repair of the superficial temporal artery during pterional craniotomy*. World Neurosurg 2016;89:72-7.

3.7. The petro-occipital transigmoid approach (POTS)

- ¹ Mazzoni A, Sanna M. *A posterolateral approach to the skull base: the petro-occipital transigmoid approach*. Skull Base Surg 1995;5:157-67.
- ² Mazzoni A. *The petro-occipital transigmoid approach for lesions of the jugular foramen*. Skull Base Surg 2009;19:48-56.

3.8. Presigmoid retrolabyrinthine approach and variation

- ¹ Ballance C. *Some points in the surgery of the brain and its membranes*. London: Macmillan and Co, Ltd.; 1907.
- ² Krause F. *Zur Freilegung der hinteren felsenbeingfläche und des kleinhirns*. Beitrage Klin Chir 1903;37:728-64.

- 3 Dandy WE. *Removal of cerebellopontile (acoustic) tumors through a unilateral approach*. Arch Surg 1934;29:3:337.
- 4 Dandy WE. *Results of removal of acoustic tumors by the unilateral approach*. Arch Surg 1941;42:1026.
- 5 McKenzie KG, Alexander E Jr. *Acoustic neuroma*. Clin Neurosurg 1954;2:21-36.
- 6 Rand RW, Kurze T. *Micro-neurosurgical resection of acoustic tumors by a transmeatal posterior fossa approach*. Bull Los Angel Neuro Soc 1965;30:17-20.
- 7 Rand RW, Kurze T. *Preservation of vestibular, cochlear, and facial nerves during microsurgical removal of acoustic tumors*. J Neurosurg 1968;158-61.
- 8 House WF. *Surgical exposure of the internal auditory canal and its contents through the middle, cranial fossa*. Laryngoscope 1961;71:11.
- 9 Silverstein H, Norrell H. *Retrolabyrinthine surgery: a direct approach to the cerebellopontine angle*. Otolaryngol Head Neck Surg 1980;88:462-9.
- 10 Sanna M, Russo A, Falcioni M, et al. *Enlarged translabyrinthine approach for the management of large and giant acoustic neuromas: a report of 175 consecutive cases*. Ann Otol Rhinol Laryngol 2004;113:319-28.
- 11 Hakuba A, Nishimura S, Jang BJ. *A combined retroauricular and preauricular transpetrosal-transstentorial approach to clivus meningiomas*. Surg Neurol 1988;30:108-16.
- 12 Fukushima T. *Combined supra- and infra-parapetrosal approach for petroclival lesions*. In: Sekhar LN, Janecka IP (editors). *Surgery of cranial base tumors*. New York: Raven Press; 1993. pp. 661-9.
- 13 Al-Mefty O, Fox JL, Smith RR. *Petrosal approach for petroclival meningiomas*. Neurosurgery 1988;22:510-7.
- 14 Samii M, Ammirati M. *The combined supra-infratentorial pre-sigmoid sinus avenue to the petro-clival region. Surgical technique and clinical applications*. Acta Neurochir 1988;95:6-12.
- 15 Spetzler RF, Daspit CP, Pappas CTE. *The combined supra-and infratentorial approach for lesions of the petrous and clival regions; experience with 46 cases*. J Neurosurg 1992;588-99.
- 16 Couldwell WT, Fukushima T, Giannotta SL, et al. *Petroclival meningiomas: surgical experience in 109 cases*. J Neurosurg 1996;20-8.
- 17 Cho CW, Al-Mefty O. *Combined petrosal approach to petroclival meningiomas*. Neurosurgery 2002;8:708-18.
- 18 Bradley Gross, Daryoush T, Rose D, et al. *Evolution of the posterior petrosal approach*. Neurosurg Focus 2012;33:E7.
- 19 Wong R, Wong A, Stamates M, et al. *Radiographic assessment of the presigmoid retrolabyrinthine approach*. Surg Neurol Int 2017;8:129.
- 20 Erkmen K, Pravdenkova S, Al-Mefty O. *Surgical management of petroclival meningiomas: factors determining the choice of approach*. Neurosurg Focus 2005;19:E7.
- 21 Cushing H. *Tumours of the nervus acousticus and the syndrome of the cerebellopontine angle*. Philadelphia: WB Saunders; 1917. pp. 387-91.
- 22 Yasargil M. *Acoustic neuromas*. In: *Microneurosurgery*. Stuttgart, New York: Georg Thieme Verlag; 1996.
- 23 Rhoton AL. *The cerebellopontine angle and posterior fossa cranial nerves by the retrosigmoid approach*. Neurosurgery 2000;47(Suppl 3).
- 24 Morrison AW, King TT. *Experiences with a translabyrinthine-transstentorial approach to the cerebellopontine angle*. J Neurosurg 1973;382-9.
- 25 Samii M, Tatagiba M, Carvalho GA. *Retrosigmoid intradural suprameatal approach to Meckels cave and the middle fossa: surgical technique and outcome*. J Neurosurg 2000;235-41.
- 26 Cappabianca P, Cavallo LM, Esposito F, et al. *Endoscopic examination of the cerebellar pontine angle*. Clin Neurol Neurosurg 2002;104:387-91.
- 27 Divitiis OD, Cavallo LM, Fabbro MD, et al. *Freehand dynamic endoscopic resection of an epidermoid tumor of the cerebellopontine angle*. Operative Neurosurgery 2007;61.
- 28 Shahinain HK, Eby JB, Ocon M. *Fully endoscopic excision of vestibular schwannomas*. Minim Invasive Neurosurg 2004;47:329-32.
- 29 Vaz-Guimaraes F, Gardner PA, Fernandez-Miranda JC. *Fully endoscopic retrosigmoid approach for posterior petrous meningioma & trigeminal microvascular decompression*. Acta Neurochir (Wien) 2015;157:611-5.
- 30 Abolfotoh M, Bi WL, Hong CK, et al. *The combined microscopic-endoscopic technique for radical resection of cerebellopontine angle tumors*. J Neurosurg 2015;123:1301-11.

3.9. Occipital approaches, retrosigmoid approach

- 1 Mazzoni A, Zanoletti E, Denaro L, et al. *Retrolabyrinthine meotomy as part of retrosigmoid approach to expose the whole internal auditory canal: rationale, technique and outcome in hearing preservation surgery for vestibular schwannoma*. Operat Neurosurgery 2018;14:36-44.

3.10. The suprameatal approach and the transpetrosal-transapex approach

- 1 Samii M, Tatagiba M, Carvalho GA. *Retrosigmoid intradural suprameatal approach to Meckel's cave and the middle fossa: surgical technique and outcome*. J Neurosurg 2000;92:235-41.
- 2 Seoane E, Rhoton AL. *Suprameatal extension of the retrosigmoid approach: microsurgical anatomy*. Neurosurgery 1999;44:553-60.
- 3 Rhoton Jr AL. *The cerebellopontine angle and posterior fossa cranial nerves by the retrosigmoid approach*. Neurosurgery 2000;47:S93-129.
- 4 Rigante L, Herlan S, Tatagiba MS, et al. *Petrosectomy and topographical anatomy in traditional Kawase and posterior intradural petrous apicectomy (pipa) approach: an anatomical study*. World Neurosurg 2016;86:93-102.
- 5 Ebner FH, Koerbel A, Kirschniak A, et al. *Endoscope-assisted retrosigmoid intradural suprameatal approach to the middle fossa: anatomical and surgical considerations*. EJSO 2007;33:109-13.
- 6 Tatagiba M, Rigante L, Mesquita Filho P, et al. *Endoscopic-assisted posterior intradural petrous apicectomy in petroclival meningiomas: a clinical series and assessment of perioperative morbidity*. World Neurosurg 2015;84:1708-18.

3.11. The extreme lateral approach: highlights on the key steps of surgical technique

- 1 Kawashima M, Tanriover N, Rhoton AL, et al. *Comparison of the far lateral and extreme lateral variants of the atlanto-occipital transarticular approach to anterior extradural lesions of the craniovertebral junction*. Neurosurgery 2003;53:662-74.
- 2 Hadley MN, Spetzler RF, Sonntag VK. *The transoral approach to*

- the superior cervical spine. A review of 53 cases of extradural cervicomedullary compression. *J Neurosurg* 1989;71:16-23.
- 3 Samii M, Klekamp J, Carvalho G. *Surgical results for meningiomas of the craniocervical junction*. *Neurosurgery* 1996;39:1086-94.
 - 4 Sen CN, Sekhar LN. *An extreme lateral approach to intradural lesions of the cervical spine and foramen magnum*. *Neurosurgery* 1990;27:197-204.
 - 5 Babu RP, Sekhar LN, Wright DC. *Extreme lateral transcondylar approach: technical improvements and lessons learned*. *J Neurosurg* 1994;81:49-59.
 - 6 Bertalanffy H, Seeger W. *The dorsolateral, suboccipital, transcondylar approach to the lower clivus and anterior portion of the craniocervical junction*. *Neurosurgery* 1991;29:815-21.
 - 7 Bruneau M, Cornelius JF, George B. *Antero-lateral approach to the V3 segment of the vertebral artery*. *Neurosurgery* 2006;58(Suppl 1):29-35.
 - 8 Rhoton AL. *The far-lateral approach and its transcondylar, supracondylar, and paracondylar extensions*. *Neurosurgery* 2000;47(Suppl 3):195-209.
 - 9 Matsushima T, Kawashima M, Masuoka J, et al. *Transcondylar fossa (supracondylar transjugular tubercle) approach: anatomic basis for the approach, surgical procedures, and surgical experience*. *Skull Base* 2010;20:83-91.
 - 10 Wen HT, Rhoton AL, Katsuta T, et al. *Microsurgical anatomy of the transcondylar, supracondylar, and paracondylar extensions of the far-lateral approach*. *J Neurosurg* 1997;87:555-85.
 - 11 Salas E, Sekhar LN, Ziyal IM, et al. *Variations of the extreme-lateral craniocervical approach: anatomical study and clinical analysis of 69 patients*. *J Neurosurg* 1999;90(Suppl 2):206-19.
 - 12 Liu JK, Sameshima T, Gottfried ON, et al. *The combined transmastoid retro- and infralabyrinthine transjugular transcondylar trans-tubercular high cervical approach for resection of glomus jugulare tumors*. *Neurosurgery* 2006;59(Suppl 1):115-25.
 - 13 Vishteh AG, Crawford NR, Melton MS, et al. *Stability of the craniovertebral junction after unilateral occipital condyle resection: a biomechanical study*. *J Neurosurg* 1999;90(Suppl 1):91-8.
 - 14 Shibani E, Torok E, Wostrack M, et al. *The far-lateral approach: destruction of the condyle does not necessarily result in clinically evident craniovertebral junction instability*. *J Neurosurg* 2016;125:196-201.

3.12. En bloc resections of the temporal bone

- 1 Mazzoni A, Danesi G, Zanoletti E. *Primary squamous cells carcinoma of the external auditory canal: surgical treatment and long-term outcomes*. *Acta Otorhinolaryngol Ital* 2014;34:129-37.
- 2 Mazzoni A, Zanoletti E, Marioni G, et al. *En bloc temporal bone resections in squamous cell carcinoma of the ear: technique, principles and limits*. *Acta Otolaryngol* 2016;136:425-32.
- 3 Zanoletti E, Marioni G, Franchella S, et al. *Recurrent squamous cell carcinoma of the temporal bone: critical analysis of cases with a poor prognosis*. *Am J Otolaryngol* 2015;36:352-5.

3.13. Totally endoscopic and combined endo-microscopic approaches in lateral skull base surgery

Bennett M, Haynes DS. *Surgical approaches and complications in the removal of vestibular schwannomas*. *Otolaryngol Clin North Am* 2007;40:589-609.

- Koos WT, Day JD, Matula C, et al. *Neurotopographic considerations in the microsurgical treatment of small acoustic neurinomas*. *J Neurosurg* 1998;88:506-12.
- Marchioni D, Alicandri-Ciuffelli M, Rubini A, et al. *Endoscopic transcanal corridors to the lateral skull base: initial experiences*. *Laryngoscope* 2015;125:S1-13.
- Marchioni D, Bonali M, Presutti L. *Transcanal endoscopic lateral skull base surgery*. *Operative Techniques in Otolaryngology-Head and Neck Surgery* 2017;28:57-64.
- Marchioni D, Carner M, Soloperto D, et al. *Expanded transcanal transpromontorial approach: a novel surgical technique for cerebellopontine angle vestibular schwannoma removal*. *Otolaryngol Head Neck Surg* 2018;158:710-5.
- Marchioni D, Soloperto D, Masotto B, et al. *Transcanal transpromontorial acoustic neuroma surgery: results and facial nerve outcomes*. *Otol Neurotol* 2018;39:242-9.
- Presutti L, Marchioni D. *Endoscopic ear surgery*. Stuttgart, New York: Georg Thieme Verlag; 2014.
- Presutti L, Nogueira JF, Alicandri-Ciuffelli M, et al. *Beyond the middle ear. In: Cholesteatoma and ear surgery: an update*. *Otol Neurotol* 2017;215.
- Van Rompaey J, Bush C, McKinnon B, et al. *Minimally invasive access to the posterior cranial fossa: an anatomical study comparing a retrosigmoidal endoscopic approach to a microscopic approach*. *J Neurol Surg A Cent Eur Neurosurg* 2013;74:1-6.

4.1.1. Observation in vestibular schwannomas - a systematic review

- 1 xCarlson ML, Link MJ, Wanna GB, et al. *Management of sporadic vestibular schwannoma*. *Otolaryngol Clin North Am* 2015;48:407-22.
- 2 Carlson ML, Habermann EB, Wagie AE, et al. *The changing landscape of vestibular schwannoma management in the united states - a shift toward conservatism*. *Otolaryngol Head Neck Surg* 2015;153:440-6.
- 3 Stangerup S-E, Caye-Thomasen P. *Epidemiology and natural history of vestibular schwannomas*. *Otolaryngol Clin North Am* 2012;45:257-68.
- 4 Stangerup S-E, Caye-Thomasen P, Tos M, et al. *The natural history of vestibular schwannoma*. *Otol Neurotol* 2006;27:547-52.
- 5 American Academy of Otolaryngology-Head and Neck Surgery Foundation, INC. *Committee on Hearing and Equilibrium guidelines for the evaluation of hearing preservation in acoustic neuroma (vestibular schwannoma)*. *Otolaryngol Head Neck Surg* 1995;113:179-80.
- 6 Driscoll CL, Jackler RK, Pitts LH, et al. *Lesions of the internal auditory canal and cerebellopontine angle in an only hearing ear: is surgery ever advisable?* *Am J Otol* 2000;21:573-81.
- 7 Rigby PL, Shah SB, Jackler RK, et al. *Acoustic neuroma surgery: outcome analysis of patient-perceived disability*. *Am J Otol* 1997;18:427-35.
- 8 Bozorg Grayeli A, Kalamarides M, Ferrary E, et al. *Conservative management versus surgery for small vestibular schwannomas*. *Acta Otolaryngol (Stockh)* 2005;125:1063-8.
- 9 Solares A, Panizza B. *Vestibular schwannoma: an understanding of growth should influence management decisions*. *Otol Neurotol* 2008;29:829-34.
- 10 Breivik CN, Varughese JK, Wentzel-Larsen T, et al. *Conservative management of vestibular schwannoma - a prospective co-*

- hort study: treatment, symptoms, and quality of life. *Neurosurgery* 2012;70:1072-80.
- 11 Stangerup S-E, Thomsen J, Tos M, et al. *Long-term hearing preservation in vestibular schwannoma*. *Otol Neurotol* 2010;31:271-5.
 - 12 Atkins D, Best D, Briss PA, et al. *Grading quality of evidence and strength of recommendations*. *BMJ* 2004;328:1490.
 - 13 Patnaik U, Prasad SC, Tutar H, et al. *The long-term outcomes of wait-and-scan and the role of radiotherapy in the management of vestibular schwannomas*. *Otol Neurotol* 2015;36:638-46.
 - 14 Martin C, Fraysse B, Chelikh L, et al. *Croissance naturelle du neurinome de l'acoustique chez le sujet age*. *J Fr Otorhinolaryngol* 1994;43:392-7.
 - 15 Hughes M, Skilbeck C, Saeed S, et al. *Expectant management of vestibular schwannoma: a retrospective multivariate analysis of tumor growth and outcome*. *Skull Base* 2011;21:295-302.
 - 16 Raut VV, Walsh RM, Bath AP, et al. *Conservative management of vestibular schwannomas - second review of a prospective longitudinal study*. *Clin Otolaryngol Allied Sci* 2004;29:505-14.
 - 17 Kirchmann M, Karnov K, Hansen S, et al. *Ten-year follow-up on tumor growth and hearing in patients observed with an intracanalicular vestibular schwannoma*. *Neurosurgery* 2017;80:49-56.
 - 18 Hajjioff D, Raut VV, Walsh RM, et al. *Conservative management of vestibular schwannomas: third review of a 10-year prospective study*. *Clin Otolaryngol* 2008;33:255-9.
 - 19 Lin VYW, Stewart C, Grebenyuk J, et al. *Unilateral acoustic neuromas: long-term hearing results in patients managed with fractionated stereotactic radiotherapy, hearing preservation surgery, and expectantly*. *Laryngoscope* 2005;115:292-6.
 - 20 Tveiten OV, Carlson ML, Goplen F, et al. *Long-term auditory symptoms in patients with sporadic vestibular schwannoma: an international cross-sectional study*. *Neurosurgery* 2015;77:218-27.
 - 21 Caye-Thomasen P, Hansen S, Dethloff T, et al. *Sublocalization and volumetric growth pattern of intracanalicular vestibular schwannomas*. *Laryngoscope* 2006;116:1131-5.
 - 22 Caye-Thomasen P, Dethloff T, Hansen S, et al. *Hearing in patients with intracanalicular vestibular schwannomas*. *Audiol Neurootol* 2007;12:1-12.
 - 23 Stangerup S-E, Caye-Thomasen P, Tos M, et al. *Change in hearing during "wait and scan" management of patients with vestibular schwannoma*. *J Laryngol Otol* 2008;122:673-81.
 - 24 Piazza F, Frisina A, Gandolfi A, et al. *Management of acoustic neuromas in the elderly: retrospective study*. *Ear Nose Throat J* 2003;82:374-8.
 - 25 Malhotra PS, Sharma P, Fishman MA, et al. *Clinical, radiographic, and audiometric predictors in conservative management of vestibular schwannoma*. *Otol Neurotol* 2009;30:507-14.
 - 26 Timmer FCA, Artz JCJM, Beynon AJ, et al. *Prediction of vestibular schwannoma growth: a novel rule based on clinical symptomatology*. *Ann Otol Rhinol Laryngol* 2011;120:807-13.
 - 27 Roche P-H, Soumare O, Thomassin J-M, et al. *The wait and see strategy for intracanalicular vestibular schwannomas*. *Mod Manag Acoust Neuroma* 2008;21:83-8.
 - 28 Oddon PA, Montava M, Salburgo F, et al. *Conservative treatment of vestibular schwannoma: growth and penn acoustic neuroma quality of life scale in french language*. *Acta Otorhinolaryngol Ital* 2017;37:320-7.
 - 29 Maio SD, Akagami R. *Prospective comparison of quality of life before and after observation, radiation, or surgery for vestibular schwannomas: clinical article*. *J Neurosurg* 2009;111:855-62.
 - 30 Eljamel S, Hussain M, Eljamel MS. *Should initial surveillance of vestibular schwannoma be abandoned?* *Skull Base* 2011;21:59-64.
 - 31 Reddy CEE, Lewis-Jones HG, Javadpour M, et al. *Conservative management of vestibular schwannomas of 15 to 31 mm intracranial diameter*. *J Laryngol Otol* 2014;128:752-8.
 - 32 Remenyi J, Marshall A, Enticott JC, et al. *The prognostic value of speech recognition scores at diagnosis of vestibular schwannoma*. *J Clin Neurosci* 2009;16:1460-3.
 - 33 Fayad JN, Semaan MT, Lin J, et al. *Conservative management of vestibular schwannoma: expectations based on the length of the observation period*. *Otol Neurotol* 2014;35:1258-65.
 - 34 Hunter JB, Francis DO, O'Connell BP, et al. *Single institutional experience with observing 564 vestibular schwannomas: factors associated with tumor growth*. *Otol Neurotol* 2016;37:1630-6.
 - 35 Moffat DA, Kasbekar A, Axon PR, et al. *Growth characteristics of vestibular schwannomas*. *Otol Neurotol* 2012;1.
 - 36 Lees KA, Tombers NM, Link MJ, et al. *Natural history of sporadic vestibular schwannoma: a volumetric study of tumor growth*. *Otolaryngol Head Neck Surg* 2018;194599818770413.
 - 37 Bakkouri WE, Kania RE, Guichard J-P, et al. *Conservative management of 386 cases of unilateral vestibular schwannoma: tumor growth and consequences for treatment*. *J Neurosurg* 2009;110:662-9.
 - 38 Martin TPC, Senthil L, Chavda SV, et al. *A protocol for the conservative management of vestibular schwannomas*. *Otol Neurotol* 2009;30:381-5.
 - 39 Artz JCJM, Timmer FCA, Mulder JJS, et al. *Predictors of future growth of sporadic vestibular schwannomas obtained by history and radiologic assessment of the tumor*. *Eur Arch Oto-Rhino-Laryngol* 2009;266:641-6.
 - 40 Suryanarayanan R, Ramsden RT, Saeed SR, et al. *Vestibular schwannoma: role of conservative management*. *J Laryngol Otol* 2010;124:251-7.
 - 41 Al Sanosi A, Fagan PA, Biggs NDW. *Conservative management of acoustic neuroma*. *Skull Base* 2006;16:95-100.
 - 42 Agrawal Y, Clark JH, Limb CJ, et al. *Predictors of vestibular schwannoma growth and clinical implications*. *Otol Neurotol* 2010;31:807-12.
 - 43 Varughese J, Breivik C, Wentzel-Larsen T, et al. *Growth of untreated vestibular schwannoma: a prospective study - clinical article*. *J Neurosurg* 2012. Doi: 10.3171/2011.12.JNS111662.
 - 44 Ferri GG, Pirodda A, Ceroni AR, et al. *Management of growing vestibular schwannomas*. *Eur Arch Oto-Rhino-Laryngol* 2013;270:2013-9.
 - 45 Ferri GG, Modugno GC, Pirodda A, et al. *Conservative management of vestibular schwannomas: an effective strategy*. *Laryngoscope* 2008;118:951-7.
 - 46 Quaranta N, Baguley DM, Axon PR, et al. *Conservative management of vestibular schwannomas*. In: Baguley D, Ramsden R, Moffat D (eds.). *Fourth international conference on vestibular schwannoma and other CPA lesions*. Cambridge, UK; 2003. pp. 256-7.
 - 47 Fucci MJ, Buchman CA, Brackmann DE, et al. *Acoustic tumor growth: implications for treatment choices*. *Am J Otol* 1999;20:495-9.
 - 48 Roehm PC, Gantz BJ. *Management of acoustic neuromas in patients 65 years or older*. *Otol Neurotol* 2007;28:708-14.
 - 49 Battaglia A, Mastrodimos B, Cueva R. *Comparison of growth patterns of acoustic neuromas with and without radiosurgery*. *Otol Neurotol* 2006;27:705-12.
 - 50 Hoistad D, Melnik G, Mamikoglu B, et al. *Update on conservative management of acoustic neuroma*. *Otol Neurotol* 2001;22:682-5.
 - 51 Kishore A, Hadoura L, Crowther J, et al. *Outcome of 100 vestibular schwannomas managed conservatively in a 10-year study*. In: Baguley D, Ramsden R, Moffat D (editors). *Fourth international conference on vestibular schwannoma and other CPA lesions*. Cambridge, UK; 2003. p. 58.

- 52 Flint D, Fagan P, Panarese A. *Conservative management of sporadic unilateral acoustic neuromas*. J Laryngol Otol 2005;119:424-8.
- 53 Jethanamest D, Rivera AM, Ji H, et al. *Conservative management of vestibular schwannoma: predictors of growth and hearing*. Laryngoscope 2015;125:2163-8.
- 54 Whitehouse K, Foroughi M, Shone G, et al. *Vestibular schwannomas - when should conservative management be reconsidered?* Br J Neurosurg 2010;24:185-90.
- 55 Shin YJ, Fraysse B, Cognard C, et al. *Effectiveness of conservative management of acoustic neuromas*. Am J Otol 2000;21:857-62.
- 56 Kandathil CK, Cunnane ME, McKenna MJ, et al. *Correlation between aspirin intake and reduced growth of human vestibular schwannoma: volumetric analysis*. Otol Neurotol 2016;37:1428-34.
- 57 Moller P, Myrseth E, Pedersen P-H. *Small vestibular schwannoma: results with observation, surgery and gamma-knife*. In: Baguley D, Ramsden R, Moffat D (eds.). *Fourth international conference on vestibular schwannoma and other CPA lesions*. Cambridge, UK; 2003. pp. 39-40.
- 58 Rosenberg SI. *Natural history of acoustic neuromas*. Laryngoscope 2000;110:497-508.
- 59 Nutik SL, Babb MJ. *Determinants of tumor size and growth in vestibular schwannomas*. J Neurosurg 2001;94:922-6.
- 60 Tschudi D, Linder T, Fisch U. *Conservative management of unilateral acoustic neuromas*. Am J Otol 2000;21:722-8.
- 61 Álvarez-Morujó G-O, José R, Álvarez-Palacios I, et al. *Conservative management of vestibular schwannoma*. Acta Otorrinolaringol Esp 2014;275-82.
- 62 Walsh RM, Bath AP, Bance ML, et al. *The role of conservative management of vestibular schwannomas*. Clin Otolaryngol Allied Sci 2000;25:28-39.
- 63 Bederson JB, von Ammon K, Wichmann WW, et al. *Conservative treatment of patients with acoustic tumors*. Neurosurgery 1991;28:646-50.
- 64 Quaranta N, Baguley DM, Moffat DA. *Change in hearing and tinnitus in conservatively managed vestibular schwannomas*. Skull Base 2007;17:223-8.
- 65 Godefroy WP, Kaptein AA, Vogel JJ, et al. *Conservative treatment of vestibular schwannoma: a follow-up study on clinical and quality-of-life outcome*. Otol Neurotol 2009;30:968-74.
- 66 Deen HG, Ebersold MJ, Harner SG, et al. *Conservative management of acoustic neuroma: an outcome study*. Neurosurgery 1996;39:260-4.
- 67 Mirz F, Pedersen CB, Fiirgaard B, et al. *Incidence and growth pattern of vestibular schwannomas in a Danish county, 1977-98*. Acta Oto-Laryngol Suppl 2000;543:30-3.
- 68 Wiet RJ, Zappia JJ, Hecht CS, et al. *Conservative management of patients with small acoustic tumors*. Laryngoscope 1995;105:795-800.
- 69 Strasnick B, Glasscock ME, Haynes D, et al. *The natural history of untreated acoustic neuromas*. Laryngoscope 1994;104:1115-9.
- 70 Herwadkar A, Vokurka EA, Evans DGR, et al. *Size and growth rate of sporadic vestibular schwannoma: predictive value of information available at presentation*. Otol Neurotol 2005;26:86-92.
- 71 Nedzelski JM, Schessel DA, Pfeleiderer A, et al. *Conservative management of acoustic neuromas*. Neurosurg Clin N Am 2008;19:207-16.
- 72 Pennings RJE, Morris DP, Clarke L, et al. *Natural history of hearing deterioration in intracanalicular vestibular schwannoma*. Neurosurgery 2011;68:68-77.
- 73 Régis J, Carron R, Park MC, et al. *Wait-and-see strategy compared with proactive Gamma Knife surgery in patients with intracanalicular vestibular schwannomas*. J Neurosurg 2010;Suppl 113:105-11.
- 74 Modugno GC, Pirodda A, Ferri GG, et al. *Small acoustic neuromas: monitoring the growth rate by MRI*. Acta Neurochir (Wien) 1999;141:1063-7.
- 75 Stipkovits EM, Graamans K, Vasbinder GB, et al. *Assessment of vestibular schwannoma growth: application of a new measuring protocol to the results of a longitudinal study*. Ann Otol Rhinol Laryngol 2001;110:326-30.
- 76 Tomita Y, Tosaka M, Aihara M, et al. *Growth of primary and remnant vestibular schwannomas: a three-year follow-up study*. World Neurosurg 2015;83:937-44.
- 77 O'Reilly B, Murray CD, Hadley DM. *The conservative management of acoustic neuroma: a review of forty-four patients with magnetic resonance imaging*. Clin Otolaryngol Allied Sci 2000;25:93-7.
- 78 Perry BP, Gantz BJ, Rubinstein JT. *Acoustic neuromas in the elderly*. Otol Neurotol 2001;22:389-91.
- 79 Vokurka EA, Herwadkar A, Thacker NA, et al. *Using Bayesian tissue classification to improve the accuracy of vestibular schwannoma volume and growth measurement*. Am J Neuroradiol 2002;23:459-67.
- 80 van de Langenberg R, de Bondt B-J, Nelemans PJ, et al. *Predictors of volumetric growth and auditory deterioration in vestibular schwannomas followed in a wait and scan policy*. Otol Neurotol 2011;32:338-44.
- 81 Glasscock ME, Pappas DG, Manolidis S, et al. *Management of acoustic neuroma in the elderly population*. Am J Otol 1997;18:236-41.
- 82 Lee JD, Park MK, Kim JS, et al. *The factors associated with tumor stability observed with conservative management of intracanalicular vestibular schwannoma*. Otol Neurotol 2014;35:918-21.
- 83 Sakamoto T, Fukuda S, Inuyama Y. *Hearing loss and growth rate of acoustic neuromas in follow-up observation policy*. Auris Nasus Larynx 2001;Suppl 28:S23-7.
- 84 Breivik CN, Nilsen RM, Myrseth E, et al. *Conservative management or gamma knife radiosurgery for vestibular schwannoma: tumor growth, symptoms, and quality of life*. Neurosurgery 2013;73:48-56

4.1.2. Radiotherapy in acoustic neuroma

- 1 Lin D, Hegarty JL, Fischbein NJ, et al. *The prevalence of "incidental" acoustic neuroma*. Arch Otolaryngol Head Neck Surg 2005;131:241-4.
- 2 Stangerup R, Tos M, Thomsen J, et al. *True incidence of vestibular schwannoma?* Neurosurgery 2010;67:1335-40.
- 3 Kirchmann M, Karnov K, Hansen S, et al. *Ten-year follow-up on tumor growth and hearing in patients observed with an intracanalicular vestibular schwannoma*. Neurosurgery 2017;80:49-56.
- 4 Krengli M, Zanoletti E, Deantonio L. *Radiation therapy in acoustic neuroma*. In: Wenz F (editor). *Radiation oncology*. Springer International Publishing AG 2018. https://doi.org/10.1007/978-3-319-52619-5_11-1.
- 5 Berkowitz O, Han YY, Talbott EO, et al. *Gamma knife radiosurgery for vestibular schwannomas and quality of life evaluation*. Stereotact Funct Neurosurg 2017;95:166-73.
- 6 Akpinar BA, Mousavi SH, McDowell MM, et al. *Early radiosurgery improves hearing preservation in vestibular schwannoma patients with normal hearing at the time of diagnosis*. Int J Radiation Oncol Biol Phys 2016;95:729-34.
- 7 Watanabe S, Yamamoto M, Kawabe T, et al. *Stereotactic radiosurgery for vestibular schwannomas: average 10-year follow-up results focusing on long-term hearing preservation*. J Neurosurg 2016;125:64-72.
- 8 Klijn S, Verheul JB, Beute GN, et al. *Gamma Knife radiosurgery for*

- vestibular schwannomas: evaluation of tumor control and its predictors in a large patient cohort in The Netherlands. *J Neurosurg* 2016;124:1619-26.
- 9 Ellenbogen JR, Waqar M, Kinshuck AJ, et al. *Linear accelerator radiosurgery for vestibular schwannomas: results of medium-term follow-up.* *Br J Neurosurg* 2015;29:678-84.
 - 10 Mindermann T, Schlegel I. *How to distinguish tumor growth from transient expansion of vestibular schwannomas following Gamma Knife radiosurgery.* *Acta Neurochir* 2014;156:1121-3.
 - 11 Boari N, Bailo M, Gagliardi F, et al. *Gamma Knife radiosurgery for vestibular schwannoma: clinical results at long-term follow-up in a series of 379 patients.* *J Neurosurg* 2014;Suppl 121:123-42.
 - 12 Wangerid T, Bartek J Jr, Svensson M, et al. *Long-term quality of life and tumour control following gamma knife radiosurgery for vestibular schwannoma.* *Acta Neurochir (Wien)* 2014;156:389-96.
 - 13 Hasegawa T, Kida Y, Kato T, et al. *Long-term safety and efficacy of stereotactic radiosurgery for vestibular schwannomas: evaluation of 440 patients more than 10 years after treatment with Gamma Knife surgery.* *J Neurosurg* 2013;118:557-65.
 - 14 Lunsford LD, Niranjan A, Flickinger JC, et al. *Radiosurgery of vestibular schwannomas: summary of experience in 829 cases.* *J Neurosurg* 2013;Suppl 119:195-9.
 - 15 Kim YH, Kim DG, Han JH, et al. *Hearing outcomes after stereotactic radiosurgery for unilateral intracanalicular vestibular schwannomas: implication of transient volume expansion.* *Int J Radiat Oncol Biol Phys* 2013;85:61-7.
 - 16 Pollock BE, Link MJ, Foote RL. *Failure rate of contemporary low-dose radiosurgical technique for vestibular schwannoma.* *J Neurosurg* 2013;Suppl 119:840-4.
 - 17 Yomo S, Carron R, Thomassin JM, et al. *Longitudinal analysis of hearing before and after radiosurgery for vestibular schwannoma.* *J Neurosurg* 2012;117:877-85.
 - 18 Roos DE, Potter AE, Zacest AC. *Hearing preservation after low dose linac radiosurgery for acoustic neuroma depends on initial hearing and time.* *Radiother Oncol* 2011;101:420-4.
 - 19 Hsu PW, Chang C, Lee ST, et al. *Outcomes of 75 patients over 12 years treated for acoustic neuromas with linear accelerator-based radiosurgery.* *J Clin Neurosci* 2010;17:556-60.
 - 20 Fukuoka S, Takanashi M, Hojyo A, et al. *Gamma knife radiosurgery for vestibular schwannomas.* *Prog Neurol Surg* 2009;22:45-62.
 - 21 Aoyama H, Onodera S, Takeichi N, et al. *Symptomatic outcomes in relation to tumor expansion after fractionated stereotactic radiation therapy for vestibular schwannomas: single-institutional long-term experience.* *Int J Radiation Oncol Biol Phys* 2013;85:329-34.
 - 22 Woolf DK, Williams M, Goh CL, et al. *Fractionated stereotactic radiotherapy for acoustic neuromas: long-term outcomes.* *Clin Oncol* 2013;25:734-8.
 - 23 Litre F, Rousseaux P, Jovenin N, et al. *Fractionated stereotactic radiotherapy for acoustic neuromas: a prospective monocenter study of about 158 cases.* *Radiother Oncol* 2013;106:169-74.
 - 24 Tsai JT, Lin JW, Lin CM, et al. *Clinical evaluation of CyberKnife in the treatment of vestibular schwannomas.* *Biomed Res Int* 2013;2013:297093.
 - 25 Vernimmen FJ, Mohamed Z, Slabbert JP, et al. *Long-term results of stereotactic proton beam radiotherapy for acoustic neuromas.* *Radiother Oncol* 2009;90:208-12.
 - 26 Combs SE, Engelhard C, Kopp C, et al. *Long-term outcome after highly advanced single-dose or fractionated radiotherapy in patients with vestibular schwannomas - pooled results from 3 large German centers.* *Radiother Oncol* 2015;114:378-83.
 - 27 Anderson BM, Khuntia D, Bentzen SM, et al. *Single institution experience treating 104 vestibular schwannomas with fractionated stereotactic radiation therapy or stereotactic radiosurgery.* *J Neuro-Oncol* 2014;116:187-93.
 - 28 Puataweepong P, Dhanachai M, Dangprasert S, et al. *Linac-based stereotactic radiosurgery and fractionated stereotactic radiotherapy for vestibular schwannomas: comparative observations of 139 patients treated at a single institution.* *J Radiat Res* 2014;55:351-8.
 - 29 Collen C, Ampe B, Gevaert T, et al. *Single fraction versus fractionated linac-based stereotactic radiotherapy for vestibular schwannoma: a single-institution experience.* *Int J Radiat Oncol Biol Phys* 2011;81:503-9.
 - 30 Marks LB, Yorke D, Jackson AY, et al. *Use of normal tissue complication probability models in the clinic.* *J Radiation Oncology Biol Phys* 2010;76:S10-9.
 - 31 Apicella G, Paolini M, Deantonio L, et al. *Radiotherapy for vestibular schwannoma: review of recent literature results.* *Rep Pract Oncol Radiother* 2016;21:399-406.
 - 32 Breivik CN, Nilsen RM, Myrseth E, et al. *Conservative management or Gamma Knife radiosurgery for vestibular schwannoma: tumor growth symptoms, and quality of life.* *Neurosurgery* 2013;73:48-56.
 - 33 Vernimmen FJ, Slabbert JP. *Assessment of the alpha/beta ratios for arteriovenous malformations, meningiomas, acoustic neuromas, and the optic chiasma.* *Int J Radiat Biol* 2010;86:486-98.
 - 34 Kessel KA, Fischer H, Vogel MME, et al. *Fractionated vs single-fraction stereotactic radiotherapy in patients with vestibular schwannoma. Hearing preservation and patients' self-reported outcome based on an established questionnaire.* *Strahlenther Onkol* 2017;193:192-9.
 - 35 Fossati P, Vavassori A, Deantonio L, et al. *Review of photon and proton radiotherapy for skull base tumours.* *Rep Pract Oncol Radiother* 2016;21:336-55.
 - 36 Krenqli M, Apicella G, Deantonio L, et al. *Stereotactic radiation therapy for skull base recurrences: is a salvage approach still possible?* *Rep Pract Oncol Radiother* 2015;430-9.
 - 37 Bailo M, Boari N, Gagliardi F, et al. *Gamma knife radiosurgery for residual and recurrent vestibular schwannomas after previous surgery: clinical results in a series of 90 patients and review of the literature.* *World Neurosurg* 2017;98:60-72.

4.1.3. Vestibular schwannoma: surgery after radiotherapy

- 1 Stangerup SE, Caye-Thomasen P, Tos M, et al. *The natural history of vestibular schwannoma.* *Otol Neurotol* 2006;27:547-52.
- 2 Leksell L. *A note on the treatment of acoustic tumors.* *Acta Chir Scand* 1971;137:763-5.
- 3 Pollock BE. *Management of vestibular schwannomas that enlarge after stereotactic radiosurgery: treatment recommendations based on a 15-year experience.* *Neurosurgery* 2006;58:241-8.
- 4 Schulder M, Sreepada GS, Kwartler JA, et al. *Microsurgical removal of a vestibular schwannoma after stereotactic radiosurgery: surgical and pathologic findings.* *Am J Otol* 1999;20:364-7.
- 5 Patnaik U, Prasad SC, Tutar H, et al. *The long-term outcomes of wait-and-scan and the role of radiotherapy in the management of vestibular schwannomas.* *Otol Neurotol* 2015;36:638-46.
- 6 Timmer FC, Mulder JJ, Hanssens PE, et al. *Gamma knife radiosurgery for vestibular schwannomas: identification of predictors for continued tumor growth and the influence of documented tumor growth preceding radiation treatment.* *Laryngoscope* 2011;121:1834-8.

- 7 Koos WT, Bock FW, Spetzler RF (editors). *Clinical microneurosurgery*. Stuttgart, New York: Georg Thieme Verlag; 1976. pp. 91-112.
- 8 Gardner G, Robertson JH. *Hearing preservation in unilateral acoustic neuroma surgery*. *Ann Otol Rhinol Laryngol* 1988;97:55-66.
- 9 *Consensus meeting on systems for reporting results in acoustic neuroma*. November 7-9, 2001. Tokyo, Japan. Abstracts. *Keio J Med* 2001;4:13-77.
- 10 Han SJ, Oh MC, Sughrue ME, et al. *The effect of the 2003 Consensus Reporting Standards on publications describing patients with vestibular schwannoma treated with stereotactic radiosurgery*. *J Clin Neurosci* 2012;19:1144-7.
- 11 Caye-Thomasen P, Hansen S, Dethloff T, et al. *Sublocalization and volumetric growth pattern of intracanalicular vestibular schwannomas*. *Laryngoscope* 2006;116:1131-5.
- 12 Stangerup SE, Caye-Thomasen P. *Epidemiology and natural history of vestibular schwannomas*. *Otolaryngol Clin North Am* 2012;45:257-68.
- 13 Roche PH, Soumare O, Thomassin JM, et al. *The wait and see strategy for intracanalicular vestibular schwannomas*. *Prog Neurol Surg* 2008;21:83-8.
- 14 Sawamura Y, Shirato H, Sakamoto T, et al. *Management of vestibular schwannoma by fractionated stereotactic radiotherapy and associated cerebrospinal fluid malabsorption*. *J Neurosurg* 2003;99:685-92.
- 15 Kaylie DM, Horgan MJ, Delashaw JB, et al. *A meta-analysis comparing outcomes of microsurgery and gamma knife radiosurgery*. *Laryngoscope* 2000;110:1850-6.
- 16 Iwai Y, Yamanaka K, Ishiguro T. *Surgery combined with radiosurgery of large acoustic neuromas*. *Surg Neurol* 2003;59:283-9.
- 17 Kondziolka D, Lunsford LD, Flickinger JC. *Acoustic tumors: operation versus radiation-making sense of opposing viewpoints. Part II. Acoustic neuromas: sorting out management options*. *Clin Neurosurg* 2003;50:313-28.
- 18 Kondziolka D, Lunsford LD, McLaughlin MR, et al. *Long-term outcomes after radiosurgery for acoustic neuromas*. *N Engl J Med* 1998;339:1426-33.
- 19 Ramina R, Coelho Neto M, Bordignon KC, et al. *Treatment of large and giant residual and recurrent vestibular schwannomas*. *Skull Base* 2007;17:109-17.
- 20 Chihara Y, Ito K, Sugawara K, et al. *Neurological complications after acoustic neurinoma radiosurgery: revised risk factors based on long-term follow-up*. *Acta Otolaryngol Suppl* 2007;559:65-70.
- 21 Foote RL, Coffey RJ, Swanson JW, et al. *Stereotactic radiosurgery using the gamma knife for acoustic neuromas*. *Int J Radiat Oncol Biol Phys* 1995;32:1153-60.
- 22 Hasegawa T, Fujitani S, Katsumata S, et al. *Stereotactic radiosurgery for vestibular schwannomas: analysis of 317 patients followed more than 5 years*. *Neurosurgery* 2005;57:257-65.
- 23 Pollock BE, Lunsford LD, Kondziolka D, et al. *Outcome analysis of acoustic neuroma management: a comparison of microsurgery and stereotactic radiosurgery*. *Neurosurgery* 1995;36:215-24.
- 24 Benghiat H, Heyes G, Nightingale P, et al. *Linear accelerator stereotactic radiosurgery for vestibular schwannomas: a UK series*. *Clin Oncol (R Coll Radiol)* 2014;26:309-15.
- 25 Rowe JG, Radatz MW, Walton L, et al. *Gamma knife stereotactic radiosurgery for unilateral acoustic neuromas*. *J Neurol Neurosurg Psychiatry* 2003;74:1536-42.
- 26 Chopra R, Kondziolka D, Niranjan A, et al. *Long-term follow-up of acoustic schwannoma radiosurgery with marginal tumor doses of 12 to 13 Gy*. *Int J Radiat Oncol Biol Phys* 2007;68:845-51.
- 27 Murphy ES, Barnett GH, Vogelbaum MA, et al. *Long-term outcomes of Gamma Knife radiosurgery in patients with vestibular schwannomas*. *J Neurosurg* 2011;114:432-40.
- 28 Combs SE, Thilmann C, Debus J, et al. *Long-term outcome of stereotactic radiosurgery (SRS) in patients with acoustic neuromas*. *Int J Radiat Oncol Biol Phys* 2006;64:1341-7.
- 29 Hayhurst C, Monsalves E, Bernstein M, et al. *Predicting non auditory adverse radiation effects following radiosurgery for vestibular schwannoma: a volume and dosimetric analysis*. *Int J Radiat Oncol Biol Phys* 2012;82:2041-6.
- 30 Battaglia A, Mastrodimos B, Cueva R. *Comparison of growth patterns of acoustic neuromas with and without radiosurgery*. *Otol Neurotol* 2006;27:705-12.
- 31 Hussein ST, Piccirillo E, Taibah A, et al. *Salvage surgery of vestibular schwannoma after failed radiotherapy: the Gruppo Otorologico experience and review of the literature*. *Am J Otolaryngol* 2013;34:107-14.
- 32 Schulder M, Sreepada GS, Kwartler JA, et al. *Microsurgical removal of a vestibular schwannoma after stereotactic radiosurgery: surgical and pathologic findings*. *Am J Otol* 1999;20:364-7.
- 33 Flickinger JC, Lunsford LD, Coffey RJ, et al. *Radiosurgery of acoustic neurinomas*. *Cancer* 1991;67:345-53.
- 34 Lunsford LD, Linskey ME. *Stereotactic radiosurgery in the treatment of patients with acoustic tumors*. *Otolaryngol Clin North Am* 1992;25:471-91.
- 35 Tanbouzi Hussein S, Piccirillo E, Taibah A, et al. *Malignancy in vestibular schwannoma after stereotactic radiotherapy: a case report and review of the literature*. *Laryngoscope* 2011;121:923-8.
- 36 Jeon CJ, Kong DS, Nam DH, et al. *Communicating hydrocephalus associated with surgery or radiosurgery for vestibular schwannoma*. *J Clin Neurosci* 2010;17:862-4.
- 37 Baser ME, Evans DG, Jackler RK, et al. *Neurofibromatosis 2, radiosurgery and malignant nervous system tumors*. *Br J Cancer* 2000;82:998.
- 38 Pollock BE, Lunsford LD, Norén G. *Vestibular schwannoma management in the next century: a radiosurgical perspective*. *Neurosurgery* 1998;43:475-81.
- 39 Ogunrinde OK, Lunsford LD, Flickinger JC, et al. *Cranial nerve preservation after stereotactic radiosurgery for small acoustic tumors*. *Arch Neurol* 1995;52:73-9.
- 40 Yamamoto M, Jimbo M, Ide M, et al. *Is unchanged tumor volume after radiosurgery a measure of outcome? Stereotact Funct Neurosurg* 1996;66(Suppl 1):231-9.
- 41 Friedman RA, Brackmann DE, Hitselberger WE, et al. *Surgical salvage after failed irradiation for vestibular schwannoma*. *Laryngoscope* 2005;115:1827-32.
- 42 Breen P, Flickinger JC, Kondziolka D, et al. *Radiotherapy for non-functional pituitary adenoma: analysis of long-term tumor control*. *J Neurosurg* 1998;89:933-8.
- 43 Iwai Y, Yamanaka K, Yamagata K, et al. *Surgery after radiosurgery for acoustic neuromas: surgical strategy and histological findings*. *Neurosurgery* 2007;60:75-82.
- 44 Piccirillo E, Wiet MR, Flanagan S, et al. *Cystic vestibular schwannoma: classification, management, and facial nerve outcomes*. *Otol Neurotol* 2009;30:826-34.

4.1.4. Complications in acoustic neuroma surgery

- 1 Waldman EH, Lustig LR. *Sir Charles Alfred Ballance: contributions to otology and neurotology*. *Otol Neurotol* 2005;26:1073-82.
- 2 Thomsen J, Tos M, Harmsen A, et al. *Surgery of acoustic neuromas. Preliminary experience with a translabyrinthine approach*. *Acta Neurol Scand* 1977;56:277-90.

- 3 Samii M, Matthies C. *Management of 1,000 vestibular schwannomas (acoustic neuromas): surgical management and results with an emphasis on complications and how to avoid them.* Neurosurg 1997;40:11-23.
- 4 Huang X, Xu M, Xu J, et al. *Complications and management of large intracranial vestibular schwannomas via the retrosigmoid approach.* World Neurosurg 2017;99:326-35.
- 5 Huang X, Xu J, Xu M, et al. *Functional outcome and complications after the microsurgical removal of giant vestibular schwannomas via the retrosigmoid approach: a retrospective review of 16-year experience in a single hospital.* BMC Neurol 2017;17:1-9.
- 6 Kunert P, Dziedzic T, Czernicki T, et al. *Surgery for sporadic vestibular schwannoma. Part II. Complications (not related to facial and auditory nerves).* Neurol Neurochir Pol 2016;50:90-7.
- 7 Mahboubi H, Ahmed OH, Yau AY, et al. *Complications of surgery for sporadic vestibular schwannoma.* Otolaryngol Head Neck Surg 2014;150:275-81.
- 8 Sanna M, Taibah A, Russo A, et al. *Perioperative complications in acoustic neuroma (vestibular schwannoma) surgery.* Otol Neurotol 2004;25:379-86.
- 9 Slattery WH 3rd, Francis S HK. *Perioperative morbidity of acoustic neuroma surgery.* Otol Neurotol 2001;22:895-902.
- 10 Ölander C, Gudjonsson O, Kinnefors A, et al. *Complications in translabyrinthine surgery of vestibular schwannoma.* Acta Otolaryngol 2018;138:639-45.
- 11 Ansari SF, Terry C, Cohen-Gadol AA. *Surgery for vestibular schwannomas: a systematic review of complications by approach.* Neurosurg Focus 2012;33:E14.
- 12 Nonaka Y, Fukushima T, Watanabe K, et al. *Contemporary surgical management of vestibular schwannomas: analysis of complications and lessons learned over the past decade.* Neurosurg 2013;72(Suppl Operative 2):103-15.
- 13 Sughrue ME, Yang I, Aranda D, et al. *Beyond audiotfacial morbidity after vestibular schwannoma surgery.* J Neurosurg 2011;114:367-74.
- 14 Selesnick SH, Liu JC, Jen A, et al. *The incidence of cerebrospinal fluid leak after vestibular schwannoma surgery.* Otol Neurotol 2004;25:387-93.
- 15 Brennan JW, Rowed DW, Nedzelski JM, et al. *Cerebrospinal fluid leak after acoustic neuroma surgery: influence of tumor size and surgical approach on incidence and response to treatment.* J Neurosurg 2001;94:217-23.
- 16 Lebowitz RA, Hoffman RA, Roland JT Jr, et al. *Autologous fibrin glue in the prevention of cerebrospinal fluid leak following acoustic neuroma surgery.* Am J Otol 1995;16:172-4.
- 17 Sade B, Mohr G, Dufour JJ. *Vascular complications of vestibular schwannoma surgery: a comparison of the suboccipital retrosigmoid and translabyrinthine approaches.* J Neurosurg 2006;105:200-4.
- 18 Baro V, Denaro L, d'Avella D. *Securing hemostasis in pediatric low-grade posterior cerebral fossa tumors: the value of thrombin-gelatin hemostatic matrix.* Pediatr Neurosurg 2018;53:330-6.
- 19 Dubey A, Sung WS, Shaya M, et al. *Complications of posterior cranial fossa surgery-an institutional experience of 500 patients.* Surg Neurol 2009;72:369-75.
- 20 Sabab A, Sandhu J, Bacchi S, et al. *Postoperative headache following treatment of vestibular schwannoma: a literature review.* J Clin Neurosci 2018;52:26-31.

4.1.5. Hearing Preservation Surgery (HPS) with the retrosigmoid approach

- 1 Elliot FA, McKissock W. *Acoustic neuroma. Early diagnosis.* Lancet 1954;2:1189-91.
- 2 Pertuiset B. *La conservation des fonctions auditives et faciales au cours de l'exérèse totale des neurinomes de l'acoustique par voie sousoccipitale.* Presse Med 1966;74:2327-30.
- 3 Smith MFW, Miller RN, Cox DJ. *Suboccipital microsurgical removal of acoustic neuromas of all sizes.* Ann Otol Rhinol Laryngol 1973;82:407-11.
- 4 Bremond G, Garcin M, Magnan J. *Preservation of hearing in the removal of acoustic neuroma ("minima" posterior approach by retrosigmoid route).* J Laryngol Otol 1980;94:1199-204.
- 5 Sterkers JM, Corlieu P, Hamancl KF, et al. *Chirurgie des tumeurs de l'acoustique par voie retrosigmoïde.* Ann Otolaryng Ch Cervicofac 1980;97:519-32.
- 6 Jannetta PJ, Moeller AR, Moeller MB. *Technique of hearing preservation in small acoustic neuromas.* Ann Surg 1984;4:513-23.
- 7 House WF. *Surgical exposure of the internal auditory canal and its content through the middle cranial fossa.* Laryngoscope 1961;71:1363-85.
- 8 House WF, Lutje CM. *Acoustic tumors.* Baltimore: University Park Press; 1979. pp. 207-11.
- 9 Glasscock ME, Hays JW, Miller GW, et al. *Preservation of hearing in tumors of the internal auditory canal and cerebellopontine angle.* Laryngoscope 1978;88:43-55.
- 10 Glasscock ME, Hays JW, Minor LB, et al. *Preservation of hearing in surgery for acoustic neuroma.* J Neurosurg 1993;78:864-70.
- 11 Mazzoni A, Calabrese V, Danesi G. *A modified retrosigmoid approach for direct exposure of the fundus of the internal auditory canal for hearing preservation in acoustic neuroma surgery.* Am J Otol 2000;21:98-109.
- 12 Mazzoni A, Biroli F, Foresti C, et al. *Hearing preservation surgery in acoustic neuroma. Slow progress and new strategies.* Acta Otolaryngol Ital 2011;31:76-84.
- 13 Mazzoni A, Zanoletti E, Denaro L, et al. *Retrolabyrinthine meatotomy as part of retrosigmoid approach to expose the whole internal auditory canal: rationale, technique and outcome in hearing preservation surgery for vestibular schwannoma.* Operat Neurosurg 2018;14:36-44.
- 14 Carlson ML, Jakob ST, Pollock BE, et al. *Long-term hearing outcomes following stereotactic radiosurgery for vestibular schwannoma: patterns of hearing loss and variables influencing audiometric decline.* J Neurosurgery 2013;118:579-87.
- 15 Kirchmann M, Karnov K, Hansen S, et al. *Ten-year follow-up of tumor growth and hearing in patients observed with intracanalicular schwannoma.* Neurosurgery 2017;80:49-56.
- 16 Zanoletti E, Cazzador D, Faccioli C, et al. *Multi-option therapy vs observation for small acoustic neuroma: hearing-focused management.* Acta Otorhinolaryngol Ital 2018;38:384-92.

4.1.6. Assessing hearing to orient the choice of treatment for acoustic neuroma

- 1 Samii M, Matthies C. *Management of 1000 vestibular schwannomas (acoustic neuromas): hearing function in 1000 tumor resections.* Neurosurgery 1997;40:248-60.
- 2 Soares VY, Atai NA, Fujita T, et al. *Extracellular vesicles derived*

- from human vestibular schwannomas associated with poor hearing damage cochlear cells. *Neuro Oncol* 2016;18:1498-507.
- 3 Dilwali S, Landegger LD, Soares VY, et al. *Secreted factors from human vestibular schwannomas can cause cochlear damage*. *Sci Rep* 2015;5:18599.
 - 4 Humes LE, Kewley-Port D, Fogerty D, et al. *Measures of hearing threshold and temporal processing across the adult lifespan*. *Hear Res* 2010;264:30-40.
 - 5 Zanoletti E, Cazzador D, Faccioli C, et al. *Multi-option therapy vs observation for small acoustic neuroma: hearing-focused management*. *Acta Otorhinolaryngol Ital* 2018;38:384-92.
 - 6 Berger EH, Kieper RW, Gauger D. *Hearing protection: surpassing the limits to attenuation imposed by the bone-conduction pathways*. *J Acoust Soc Am* 2003;114:1955-67.
 - 7 Van de Heyning P, Távora-Vieira D, Mertens G, et al. *Towards a unified testing framework for single-sided deafness studies: a consensus paper*. *Audiol Neurotol* 2017;21:291-300.
 - 8 Rodgers B, Stucken E, Metrailler A, et al. *Factors influencing cochlear patency after translabyrinthine surgery*. *Otolaryngol Head Neck Surg* 2017;157:269-72.
 - 9 Beutner C, Mathys C, Turowski B, et al. *Cochlear obliteration after translabyrinthine vestibular schwannoma surgery*. *Eur Arch Otorhinolaryngol* 2015;272:829-33.
 - 10 Delgado-Vargas B, Medina M, Polo R, et al. *Cochlear obliteration following a translabyrinthine approach and its implications in cochlear implantation*. *Acta Otorhinolaryngol Ital* 2018;38:56-60.
 - 11 Gardner G, Robertson JH. *Hearing preservation in unilateral acoustic neuroma surgery*. *Ann Otol Rhinol Laryngol* 1988;97:5-66.
 - 12 American Academy of Otolaryngology Head and Neck Surgery Foundation, INC. *Committee on Hearing and Equilibrium guidelines for the evaluation of hearing preservation in acoustic neuroma (vestibular schwannoma)*. *Otolaryngol Head Neck Surg* 1995;113:179-80.
 - 13 Kanzaki J, Tos M, Sanna M, et al. *New and modified reporting systems from the consensus meeting on systems for reporting results in vestibular schwannoma*. *Otol Neurotol* 2003;24:642-8.
 - 14 Meyer TA, Canty PA, Wilkinson EP, et al. *Small acoustic neuromas: surgical outcomes versus observation or radiation*. *Otol Neurotol* 2006;27:380-92.
 - 15 Kollmeier B. *The multilingual matrix test. Principles, applications, and comparison across languages: a review*. *Int J Audiol* 2015;54(Suppl 2):3-16.
 - 5 Hoffman RA, Kohan D, Cohen NL. *Cochlear implants in the management of bilateral acoustic neuromas*. *Am J Otol* 1992;13:525-8.
 - 6 Carlson ML, Breen JT, Driscoll CL, et al. *Cochlear implantation in patients with neurofibromatosis type 2: variables affecting auditory performance*. *Otol Neurotol* 2012;33:853-62.
 - 7 Mukherjee P, Ramsden JD, Donnelly N, et al. *Cochlear implants to treat deafness caused by vestibular schwannomas*. *Otol Neurotol* 2013;34:1291-8.
 - 8 Di Lella F, Merkus P, Di Trapani G, et al. *Vestibular schwannoma in the only hearing ear: role of cochlear implants*. *Ann Otol Rhinol Laryngol* 2013;122:91-9.
 - 9 Sanna M, Medina MD, Macak A, et al. *Vestibular schwannoma resection with ipsilateral simultaneous cochlear implantation in patients with normal contralateral hearing*. *Audiol Neurootol* 2016;21:286-95.
 - 10 Lustig LR, Yeagle J, Driscoll CL, et al. *Cochlear implantation in patients with neurofibromatosis type 2 and bilateral vestibular schwannoma*. *Otol Neurotol* 2006;27:512-8.
 - 11 Vincenti V, Pasanisi E, Guida M, et al. *Hearing rehabilitation in neurofibromatosis type 2 patients: cochlear versus auditory brainstem implantation*. *Audiol Neurootol* 2008;13:273-80.

4.1.8. The hearing-focused therapy in acoustic neuroma: hearing preservation surgery, hearing rehabilitation with CI, observation

- 1 Zanoletti E, Cazzador D, Faccioli C, et al. *Multi-option therapy vs observation for small acoustic neuroma: hearing-focused management*. *Acta Otorhinolaryngol Ital* 2018;38:384-92.
- 2 Kanzaki J, Tos M, Sanna M, et al. *New and modified reporting systems from the consensus meeting on systems for reporting results in vestibular schwannoma*. *Otol Neurotol* 2003;24:642-8.
- 3 Kirchmann M, Karnov K, Hansen S, et al. *Ten-year follow-up on tumor growth and hearing in patients observed with an intracanalicular vestibular schwannoma*. *Neurosurgery* 2017;80:49-56.
- 4 Carlson ML, Jacob JT, Pollock BE, et al. *Long-term hearing outcomes following stereotactic radiosurgery for vestibular schwannoma: patterns of hearing loss and variables influencing audiometric decline*. *J Neurosurg* 2013;118:579-87.
- 5 Carlson ML, Link MJ, Wanna GB, et al. *Management of sporadic vestibular schwannoma*. *Otolaryngol Clin North Am* 2015;48:407-22.
- 6 Mazzoni A, Zanoletti E, Denaro L, et al. *Retrolabyrinthine meatotomy as part of retrosigmoid approach to expose the whole internal auditory canal: rationale, technique, and outcome in hearing preservation surgery for vestibular schwannoma*. *Oper Neurosurg (Hagerstown, Md)* 2018;14:36-44.
- 7 Golfinos JG, Hill TC, Rokosh R, et al. *A matched cohort comparison of clinical outcomes following microsurgical resection or stereotactic radiosurgery for patients with small- and medium-sized vestibular schwannomas*. *J Neurosurg* 2016;125:1472-82.
- 8 Hasegawa T, Fujitani S, Katsumata S, et al. *Stereotactic radiosurgery for vestibular schwannomas: analysis of 317 patients followed more than 5 years*. *Neurosurgery* 2005;57:257-65.
- 9 Lau T, Olivera R, Miller T, et al. *Paradoxical trends in the management of vestibular schwannoma in the United States*. *J Neurosurg* 2012;117:514-9.
- 10 Miller T, Lau T, Vasan R, et al. *Reporting success rates in the treatment of vestibular schwannomas: are we accounting for the natural history?* *J Clin Neurosci* 2014;21:914-8.

- 11 Watanabe S, Yamamoto M, Kawabe T, et al. *Stereotactic radiosurgery for vestibular schwannomas: average 10-year follow-up results focusing on long-term hearing preservation*. J Neurosurg 2016;125(Suppl 1):64-72.
- 12 Kari E, Friedman RA. *Hearing preservation: microsurgery*. Curr Opin Otolaryngol Head Neck Surg 2012;20:358-66.
- 13 Khrais T, Sanna M. *Hearing preservation surgery in vestibular schwannoma*. J Laryngol Otol 2006;120:366-70.
- 14 Mazzoni A, Calabrese V, Danesi G. *A modified retrosigmoid approach for direct exposure of the fundus of the internal auditory canal for hearing preservation in acoustic neuroma surgery*. Am J Otol 2000;21:98-109.
- 15 Meyer TA, Canty PA, Wilkinson EP, et al. *Small acoustic neuromas: surgical outcomes versus observation or radiation*. Otol Neurotol 2006;27:380-92.
- 16 Beutner C, Mathys C, Turowski B, et al. *Cochlear obliteration after translabyrinthine vestibular schwannoma surgery*. Eur Arch Otorhinolaryngol 2015;272:829-33.
- 17 Lloyd SKW, King AT, Rutherford SA, et al. *Hearing optimisation in neurofibromatosis type 2: a systematic review*. Clin Otolaryngol 2017;42:1329-37.
- 18 Lassaletta L, Aristegui M, Medina M, et al. *Ipsilateral cochlear implantation in patients with sporadic vestibular schwannoma in the only or best hearing ear and in patients with NF2*. Eur Arch Otorhinolaryngol 2016;273:27-35.
- 19 Benatti A, Castiglione A, Trevisi P, et al. *Endocochlear inflammation in cochlear implant users: case report and literature review*. Int J Pediatr Otorhinolaryngol 2013;77:885-93.
- 20 Martini A, Marioni G, Zanoletti E, et al. *Yap, Taz and Areg Expression in Eighth Cranial Nerve Schwannoma*. Int J Biol Markers 2017;32:319-24.
- 9 Sass H, Cayé-Thomasen P. *Contemporary molecular biology of sporadic vestibular schwannomas: a systematic review and clinical implications*. J Int Adv Otol 2018;14:322-9.
- 10 Welling DB, Guida M, Goll F, et al. *Mutational spectrum in the neurofibromatosis type 2 gene in sporadic and familial schwannomas*. Hum Genet 1996;98:189-93.
- 11 Chen H, Xue L, Wang H, et al. *Differential NF2 gene status in sporadic vestibular schwannomas and its prognostic impact on tumour growth patterns*. Sci Rep 2017;7:5470.
- 12 Chen H, Xue L, Huang H, et al. *Synergistic effect of Nutlin-3 combined with MG-132 on schwannoma cells through restoration of merlin and p53 tumour suppressors*. EBioMedicine 2018;36:252-65.
- 13 Chen Y, Wang ZY, Wu H. *PI4ARF deficiency and its correlation with overexpression of p53/MDM2 in sporadic vestibular schwannomas*. Eur Arch Otorhinolaryngol 2015;272:2227-34.
- 14 Wu H, Chen Y, Wang ZY, et al. *Involvement of p21 (waf1) in merlin deficient sporadic vestibular schwannomas*. Neuroscience 2010;170:149-55.
- 15 Carlson ML, Smadbeck JB, Link MJ, et al. *Next-generation sequencing of sporadic vestibular schwannoma: necessity of biallelic NF2 inactivation and implications of accessory non-NF2 variants*. Otol Neurotol 2018;39:e860-71.
- 16 Cayé-Thomasen P, Borup R, Stangerup SE, et al. *Deregulated genes in sporadic vestibular schwannomas*. Otol Neurotol 2010;31:256-66.
- 17 Sass HC, Borup R, Alanin M, et al. *Gene expression, signal transduction pathways and functional networks associated with growth of sporadic vestibular schwannomas*. J Neurooncol 2017;131:283-92.
- 18 Agnihotri S, Gugel I, Remke M, et al. *Gene-expression profiling elucidates molecular signaling networks that can be therapeutically targeted in vestibular schwannoma*. J Neurosurg 2014;121:1434-45.
- 19 de Vries M, van der Mey AG, Hogendoorn PC. *Tumor biology of vestibular schwannoma: a review of experimental data on the determinants of tumor genesis and growth characteristics*. Otol Neurotol 2015;36:1128-36.
- 20 Zhang N, Chen J, Ferraro GB, et al. *Anti-VEGF treatment improves neurological function in tumors of the nervous system*. Exp Neurol 2018;299:326-33.
- 21 Fong B, Barkhoudarian G, Pezeshkian P, et al. *The molecular biology and novel treatments of vestibular schwannomas*. J Neurosurg 2011;115:906-14.

4.1.9. Current molecular knowledge on sporadic VIII cranial nerve schwannoma

- 1 Waterval J, Kania R, Somers T. *EAONO position statement on vestibular schwannoma: imaging assessment. What are the indications for performing a screening MRI scan for a potential vestibular schwannoma?* J Int Adv Otol 2018;14:95-9.
- 2 Lees KA, Tombers NM, Link MJ, et al. *Natural history of sporadic vestibular schwannoma: a volumetric study of tumor growth*. Otolaryngol Head Neck Surg 2018;159:535-42.
- 3 Marinelli JP, Lohse CM, Carlson ML. *Incidence of vestibular schwannoma over the past half-century: a population-based study of Olmsted County, Minnesota*. Otolaryngol Head Neck Surg 2018;159:717-23.
- 4 Zanoletti E, Cazzador D, Faccioli C, et al. *Multi-option therapy vs observation for small acoustic neuroma: hearing-focused management*. Acta Otorhinolaryngol Ital 2018;38:384-92.
- 5 Martini A, Marioni G, Zanoletti E, et al. *YAP, TAZ and AREG expression in eighth cranial nerve schwannoma*. Int J Biol Markers 2017;32:e319-24.
- 6 Sughrue ME, Yeung AH, Rutkowski MJ, et al. *Molecular biology of familial and sporadic vestibular schwannomas: implications for novel therapeutics*. J Neurosurg 2011;114:359-66.
- 7 Kim S, Jho EH. *Merlin, a regulator of Hippo signaling, regulates Wnt β -catenin signaling*. BMB Rep 2016;49:357-8.
- 8 Pan D. *The hippo signaling pathway in development and cancer*. Dev Cell 2010;19:491-505.

4.2.1. Treatment options for sporadic tympano-jugular paraganglioma (TJPG)

- 1 Pareschi R, Righini S, Destito D, et al. *Surgery of glomus jugulare tumors*. Skull Base 2003;13:149-58.
- 2 Sanna M, Jain Y, De Donato G, et al. *Management of jugular paraganglioma: the Gruppo Otologico experience*. Otol Neurotol 2004;25:797-804.
- 3 Gilbo P, Morris CG, Werning JW, et al. *Radiotherapy for benign head and neck paraganglioma. A 45 years experience*. Cancer 2014;20:3738-43.
- 4 Willem SN, Einstein DB, Maciunas RJ, et al. *Treatment of glomus jugulare tumors in patients with advanced age. Planned limited resection followed by gamma knife radiosurgery*. Otol Neurotol 2005;26:1229-34.
- 5 Harrison LB, Session RB, Hong WK. *Head and neck cancer. a multidisciplinary approach*. Philadelphia: Lippincot Williams & Wilkins; 2009. pp. 655-989.

- 6 Larner GM, Seung SH, Spaulding CA, et al. *Glomus jugulare tumors. Long-term control by radiation therapy*. Cancer 1992;69:1813-7.
- 7 Gjuric M, Gleeson M. *Consensus statement and guidelines on the management of paragangliomas of the head and neck*. Skull Base 2009;19:109-16.
- 8 Mazzoni A, Zanoletti E. *Observation and partial targeted surgery in the management of tympano-jugular paraganglioma: a contribution to the multioptional treatment*. Eur Arch Otorhinolaryngol 2016;273:635-42.
- 9 Mazzoni A, Cazzador D, d'Avella D, et al. *Large intradural tympano-jugular paragangliomas. a contribution on surgery and management*. World Neurosurg 2019;122:e1482-90.

4.2.2. Radical surgery in jugular foramen paragangliomas: indications and results

- 1 Fisch U, Mattox D. *Microsurgery of the Skull Base*. Stuttgart, New York: Georg Thieme Verlag; 1988.
- 2 Jansen JC, van den Berg R, Kuiper A, et al. *Estimation of growth rate in patients with head and neck paragangliomas influences the treatment proposal*. Cancer 2000;88:2811-6.
- 3 Prasad SC, Mimoune HA, D'Orazio F, et al. *The role of wait-and-scan and the efficacy of radiotherapy in the treatment of temporal bone paragangliomas*. Otol Neurotol 2014;35:922-31.
- 4 Carlson ML, Sweeney AD, Wanna GB, et al. *Natural history of glomus jugulare: a review of 16 tumors managed with primary observation*. Otolaryngol Head Neck Surg 2015;152:98-105.
- 5 Lope Ahmad RA, Sivalingam S, Konishi M, et al. *Oncologic outcome in surgical management of jugular paraganglioma and factors influencing outcomes*. Head Neck 2013;35:527-34.
- 6 Jansen TTG, Timmers H, Marres HAM, et al. *Results of a systematic literature review of treatment modalities for jugulotympanic paraganglioma, stratified per Fisch class*. Clin Otolaryngol 2018;43:652-61.
- 7 Odat H, Shin SH, Odat MA, et al. *Facial nerve management in jugular paraganglioma surgery: a literature review*. J Laryngol Otol 2016;130:219-24.
- 8 Bacciu A, Medina M, Ait Mimoune H, et al. *Lower cranial nerves function after surgical treatment of Fisch class C and D tympano-jugular paragangliomas*. Eur Arch Otorhinolaryngol 2015;272:311-9.
- 9 Mazzoni A, Zanoletti E. *Observation and partial targeted surgery in the management of tympano-jugular paraganglioma: a contribution to the multioptional treatment*. Eur Arch Otorhinolaryngol 2016;273:635-42.
- 10 Moore O, Baker HW. *Carotid-artery ligation in surgery of the head and neck*. Cancer 1955;8:712-26.
- 11 Matas RI. *Testing the efficiency of the collateral circulation as a preliminary to the occlusion of the great surgical arteries*. Ann Surg 1911;53:1-43.
- 12 Erickson KM, Cole DJ. *Carotid artery disease: stenting vs endarterectomy*. Br J Anaesth 2010;105(Suppl 1):34-49.
- 13 cer data base report on malignant paragangliomas of the head and neck. Cancer 2002;94:730-7.
- 2 Lee JA, Duh QY. *Sporadic paraganglioma*. World J Surg 2008;32:683.
- 3 Milia ME, Turri L, Beldi D, et al. *Multidisciplinary approach in the treatment of malignant paraganglioma of the glomus vagale: a case report*. Tumori 2011;97:225-8.
- 4 Pęcak M, Pluta E, Hetnał M, et al. *Role of irradiation in combined treatment of head and neck paragangliomas at the Centre of Oncology in Krakow between 1970-2005*. Contemp Oncol (Pozn) 2014;18:182-6.
- 5 Trombetta M. *The role of radiotherapy in the management of paraganglioma*. Otorhinolaryngology Clinic: an International Journal 2011;3:25-9.
- 6 Cao KI, Feuvret L, Herman P, et al. *Protontherapy of head and neck paragangliomas: a monocentric study*. Cancer Radiother 2018;22:31-7.
- 7 Patel NS, Link MJ, Driscoll CLW, et al. *Hearing outcomes after stereotactic radiosurgery for jugular paraganglioma*. Otol Neurotol 2018;39:99-105.
- 8 Tosun İ, Atalar B, Şahin B, et al. *Robotic radiosurgery of head and neck paragangliomas: a single institution experience*. Asia Pac J Clin Oncol 2018;14:e3-7.
- 9 Marchetti M, Pinzi V, Tramacere I, et al. *Radiosurgery for paragangliomas of the head and neck: another step for the validation of a treatment paradigm*. World Neurosurg 2017;98:281-7.
- 10 Dobberpuhl MR, Maxwell S, Feddock J, et al. *Treatment outcomes for single modality management of glomus jugulare tumors with stereotactic radiosurgery*. Otol Neurotol 2016;37:1406-10.
- 11 Schuster D, Sweeney AD, Stavas MJ, et al. *Initial radiographic tumor control is similar following single or multi-fractionated stereotactic radiosurgery for jugular paragangliomas*. Am J Otolaryngol 2016;37:255-8.
- 12 Smee RI, Jayasekara J, Williams JR, et al. *Paragangliomas: presentation and management by radiotherapy at the Prince of Wales Hospital*. J Med Imaging Radiat Oncol 2015;59:229-35.
- 13 Gilbo P, Morris CG, Amdur RJ, et al. *Radiotherapy for benign head and neck paragangliomas: a 45-year experience*. Cancer 2014;120:3738-43.
- 14 Galland-Girodet S, Maire JP, De-Mones E, et al. *The role of radiation therapy in the management of head and neck paragangliomas: impact of quality of life versus treatment response*. Radiother Oncol 2014;111:463-7.
- 15 Chun SG, Nedzi LA, Choe KS, et al. *A retrospective analysis of tumor volumetric responses to five-fraction stereotactic radiotherapy for paragangliomas of the head and neck (glomus tumors)*. Stereotact Funct Neurosurg 2014;92:153-9.
- 16 Dupin C, Lang P, Dessard-Diana B, et al. *Treatment of head and neck paragangliomas with external beam radiation therapy*. Int J Radiation Oncol Biol Phys 2014;89:353-9.
- 17 Chen PG, Nguyen JH, Payne SC, et al. *Treatment of glomus jugulare tumors with Gamma Knife radiosurgery*. Laryngoscope 2010;120:1856-62.
- 18 Ganz J.C, Abdelkarim K. *Glomus jugulare tumours: certain clinical and radiological aspects observed following Gamma Knife radiosurgery*. Acta Neurochir 2009;151:423-6.
- 19 Krengli M, Apicella G, Deantonio L, et al. *Stereotactic radiation therapy for skull base recurrences: is a salvage approach still possible?* Rep Pract Oncol Radiother 2015;430-9.
- 20 Hinerman RW, Amdur RJ, Morris CG, et al. *Definitive radiotherapy in the management of paragangliomas arising in the head and neck: a 35-year experience*. Head Neck 2008;30:1431-8.

4.2.3. Primary radiotherapy in paraganglioma: indications and results

- 1 Lee JH, Barich F, Karnell LH, et al.; American College of Surgeons Commission on Cancer; American Cancer Society. *National can-*

- ²¹ Lim M, Bower R, Nangiana JS, et al. *Radiosurgery for glomus jugulare tumors*. *Technol Cancer Res Treat* 2007;6:419-23.
- ²² Vernimmen FJ, Slabbert JP. *Assessment of the alpha/beta ratios for arteriovenous malformations, meningiomas, acoustic neuromas, and the optic chiasma*. *Int J Radiat Biol* 2010;86:486-98.
- ²³ Lassen-Ramshad Y, Ozyar E, Alanyal S, et al. *Paraganglioma of the head and neck region, treated with radiation therapy, a Rare Cancer Network study*. *Head Neck* 2019.Epub 2019 Jan 11.
- ¹⁸ Miller JP, Semaan MT, Maciunas RJ, et al. *Radiosurgery for glomus jugular tumors*. *Otolaryngol Clin North Am* 2009;42:689-706.
- ¹⁹ Fayad JN, Keles B, Brackmann DE. *Jugular foramen tumors: clinical characteristics and treatment outcomes*. *Otol Neurotol* 2010;31:299-305.
- ²⁰ Gjuric M, Wigand ME, Weidenbecher M, et al. *Function preserving surgery of glomus jugular tumors. An achievable goal?* *HNO* 1997;45:983-9.
- ²¹ Kemeny AA. *Contemporary management of jugular paragangliomas (glomus tumours): microsurgery and radiosurgery*. *Acta Neurochir (Wien)* 2009;151:419-21.

4.2.4. Partial surgery in paraganglioma: indications and results

- ¹ Sanna M, Jain Y, De Donato G, et al. *Management of jugular paragangliomas: the Gruppo Otologico experience*. *Otol Neurotol* 2004;25:797-804.
- ² Oldring D, Fisch U. *Glomus tumors of the temporal region: surgical therapy*. *Am J Otol* 1979;1:7-18.
- ³ Pensak ML, Jackler RK. *Removal of jugular foramen tumors: the fallopian bridge technique*. *Otolaryngol Head Neck Surgery* 1997;117:586-91.
- ⁴ Sanna M, Shin SH, Piazza P, et al. *Infratemporal fossa approach type a with transcondylar-transstercular extension for Fisch type C2 to C4 tympanojugular paragangliomas*. *Head Neck* 2014;36:1581-8.
- ⁵ Oker N, Tran Ba Huy P. *Authors' response to the letter on the article: "Malignant head/neck paragangliomas. Comparative study"*. *Eur Ann Otorhinolaryngol Head Neck Dis* 2015;132:111.
- ⁶ Makiese O, Chibbaro S, Marsella M, et al. *Jugular foramen paragangliomas: management, outcome and avoidance of complications in a series of 75 cases*. *Neurosurgery Rev* 2012;35:185-94.
- ⁷ Tran Ba, Huy P. *Radiotherapy for glomus jugular paraganglioma*. *Eur Ann Otorhinolaryngol Head Neck Dis* 2014;131:223-6.
- ⁸ Hendel SF, Miller MH, Miller LS, et al. *Angiographic changes of head and neck chemodectomas following radiotherapy*. *Arch Otolaryngol* 1977;103:87-9.
- ⁹ Chweya CM, Patel NS, Young WF Jr, et al. *Salvage radiosurgery after subtotal resection for catecholamine-secreting jugular paragangliomas: report of two cases and review of the literature*. *Otol Neurotol* 2019;40:103-7.
- ¹⁰ Sahyouni R, Mahboubi H, Moshtaghi O, et al. *Radiosurgery of glomus tumors of temporal bone: a meta-analysis*. *Otol Neurotol* 2018;39:488-93.
- ¹¹ Scheick SM, Morris CG, Amdur RJ, et al. *Long-term outcomes after radiosurgery for temporal bone paragangliomas*. *Am J Clin Oncol* 2018;41:223-6.
- ¹² Guss ZD, Batra S, Limb CJ, et al. *Radiosurgery of glomus jugular tumors: a meta-analysis*. *Oncol Biol Phys* 2011;81:e497-502.
- ¹³ Fisch U, Mattox D. *Microsurgery of the skull base*. Stuttgart, New York: Georg Thieme Verlag; 1988.
- ¹⁴ A. Mazzoni. *The petro-occipital trans-sigmoid approach for lesions of the jugular foramen*. *Skull Base* 2009;19:48-56.
- ¹⁵ Sanna M, Khrais T, Menozi R, et al. *Surgical removal of jugular paragangliomas after stenting of the intratemporal internal carotid artery: a preliminary report*. *Laryngoscope* 2006;116:742-6.
- ¹⁶ Tran ba Huy P, Chao PZ, Benmansour F, et al. *Long-term oncological results in 47 cases of jugular paragangliomas surgery with special emphasis on the facial nerve issue*. *J Laryngol Otol* 2001;115:981-7.
- ¹⁷ Marchetti M, Pinzi V, Tramacere I, et al. *Radiosurgery for paragangliomas of the head and neck: another step for the validation of a treatment paradigm*. *World Neurosurg* 2017;98:281-7.

4.2.5. Management of internal carotid artery in skull base paraganglioma surgery

- ¹ Fisch U, Mattox D. *Paragangliomas of the temporal bone*. In: *Micro-surgery of the skull base*. Stuttgart, New York: Georg Thieme Verlag; 1988. pp. 148-281.
- ² Sanna M, Piazza P, Shin SH, et al. *Microsurgery of skull base paragangliomas*. Stuttgart, New York: Georg Thieme Verlag; 2013.
- ³ Sanna M, Khrais T, Menozi R, et al. *Surgical removal of jugular paragangliomas after stenting of the intratemporal internal carotid artery: a preliminary report*. *Laryngoscope* 2006;116:742-6.
- ⁴ Piazza P, Di Lella F, Bacciu A, et al. *Preoperative protective stenting of the internal carotid artery in the management of complex head and neck paragangliomas: long-term results*. *Audiol Neurotol* 2013;18:345-52.
- ⁵ Sanna M, Piazza P, Ditrapani G, et al. *Management of the internal carotid artery in tumors of the lateral skull base: preoperative permanent balloon occlusion without reconstruction*. *Otol Neurotol* 2004;25:998-1005.
- ⁶ Sanna M, De Donato G, Piazza P, et al. *Revision glomus tumor surgery*. *Otolaryngol Clin N Am* 2006;39:763-82.
- ⁷ Piazza P, Di Lella F, Menozzi R, et al. *Absence of the contralateral internal carotid artery: a challenge for management of ipsilateral glomus jugulare and glomus vagale tumors*. *Laryngoscope* 2007;117:1333-7.
- ⁸ Sanna M, Piazza P, De Donato G, et al. *Combined endovascular-surgical management of the internal carotid artery in complex tympanojugular paragangliomas*. *Skull Base* 2009;19:26-42.
- ⁹ Piazza P, Di Lella F, Bacciu A, et al. *Preoperative protective stenting of the internal carotid artery in the management of complex head and neck paragangliomas: long-term results*. *Audiol Neurotol* 2013;18:345-52.
- ¹⁰ Konishi M, Piazza P, Shin SH, et al. *The use of internal carotid artery stenting in management of bilateral carotid body tumors*. *Eur Arch Otorhinolaryngol* 2011;268:1535-9.
- ¹¹ Sanna M, Shin SH, De DG. *Management of complex tympanojugular paragangliomas including endovascular intervention*. *Laryngoscope* 2011;121:1372-82.

4.3.1 Chordoma and chondrosarcoma

- ¹ Borba LAB, Al-Mefty O, Mrak RE, et al. *Cranial chordomas in children and adolescents*. *J Neurosurg* 1996;84:584-91.
- ² McMaster ML, Goldstein AM, Bromley CM, et al. *Chordoma: incidence and survival patterns in the United States, 1973-1995*. *Cancer Causes Control* 2001;12:1-11.
- ³ Sebro R, DeLaney T, Hornicek F, et al. *Differences in sex distribu-*

- tion, anatomic location and MR imaging appearance of pediatric compared to adult chordomas. *BMC Med Imaging* 2016;16:53.
- 4 Horten BC, Montague SR. *In vitro characteristics of a sacrococcygeal chordoma maintained in tissue and organ culture systems.* *Acta Neuropathol* 1976;35:13-25.
 - 5 Jahangiri A, Jian B, Miller L, et al. *Skull base chordomas. Clinical features, prognostic factors, and therapeutics.* *Neurosurg Clin N Am* 2013;24:79-88.
 - 6 Mitchell A, Scheithauer BW, Krishnan Unni K, et al. *Chordoma and chondroid neoplasms of the sphenoid-occiput: an immunohistochemical study of 41 cases with prognostic and nosologic implications.* *Cancer* 1993;72:2943-9.
 - 7 Catton C, O'Sullivan B, Bell R, et al. *Chordoma: long-term follow-up after radical photon irradiation.* *Radiother Oncol* 1996;41:67-70.
 - 8 Chambers PW, Schwinn CP. *Chordoma. A clinicopathologic study of metastasis.* *Am J Clin Pathol* 1979;72:765-76.
 - 9 Higinbotham NL, Phillips RF, Farr HW, et al. *Chordoma. Thirty-five-year study at Memorial Hospital.* *Cancer* 1967;20:1841-50.
 - 10 Amichetti M, Cianchetti M, Amelio D, et al. *Proton therapy in chordoma of the base of the skull: a systematic review.* *Neurosurg Rev* 2009;32:403-16.
 - 11 George B, Bresson D, Bouazza S, et al. *Chordoma.* *Neurochirurgie* 2014;60:63-140.
 - 12 Labidi M, Watanabe K, Bouazza S, et al. *Clivus chordomas: a systematic review and meta-analysis of contemporary surgical management.* *J Neurosurg Sci* 2016;60:476-84.
 - 13 Mendenhall WM, Mendenhall CM, Lewis SB, et al. *Skull base chordoma.* *Head Neck* 2005;27:159-65.
 - 14 Campbell RG, Prevedello DM, Filho LD, et al. *Contemporary management of clival chordomas.* *Curr Opin Otolaryngol Head Neck Surg* 2015;23:153-61.
 - 15 Koutourousiou M, Snyderman CH, Fernandez-Miranda J, et al. *Skull base chordomas.* *Otolaryngol Clin North Am* 2011;44:1155-71.
 - 16 Fatemi N, Dusick JR, Gorgulho AA, et al. *Endonasal microscopic removal of clival chordomas.* *Surg Neurol* 2008;69:331-8.
 - 17 Holzmann D, Reisch R, Krayenbühl N, et al. *The transnasal transclival approach for clival chordoma.* *Minim Invasive Neurosurg* 2010;53:211-7.
 - 18 Hong Jiang W, Ping Zhao S, Hai Xie Z, et al. *Endoscopic resection of chordomas in different clival regions.* *Acta Otolaryngol* 2009;129:71-83.
 - 19 Rahme RJ, Arnaout OM, Sanusi OR, et al. *Endoscopic approach to clival chordomas: the northwestern experience.* *World Neurosurg* 2018;110:e231-8.
 - 20 Stippler M, Gardner PA, Snyderman CH, et al. *Endoscopic endonasal approach for clival chordomas.* *Neurosurgery* 2009;64:268-77.
 - 21 Tan NC, Naidoo Y, Oue S, et al. *Endoscopic surgery of skull base chordomas.* *J Neurol Surg* 2012;73:379-86.
 - 22 Wang K, Wang L, Tian K, et al. *Surgical resection of upper-middle clivus chordomas via a modified anterior transpetrous approach.* *Clin Neurol Neurosurg* 2015;130:20-5.
 - 23 Zoli M, Milanese L, Bonfatti R, et al. *Clival chordomas: considerations after 16 years of endoscopic endonasal surgery.* *J Neurosurg* 2018;128:329-38.
 - 24 Fisch U, Pilsbury HC. *Infratemporal fossa approach to lesions in the temporal bone and base of the skull.* *Arch Otolaryngol* 1979;105:99-107.
 - 25 Fisch U. *The infratemporal fossa approach for nasopharyngeal tumors.* *Laryngoscope* 1983;93:36-44.
 - 26 Fisch U, Fagan P, Valvanavis A. *The infratemporal fossa approach for the lateral skull base.* *Otolaryngol Clin North Am* 1984;17:513-52.
 - 27 Mazzoni A, Sanna M. *A posterolateral approach to the skull base: the petro-occipital transsigmoid approach.* *Skull Base Surg* 1995;5:157-67.
 - 28 Richardson MS. *Pathology of skull base tumors.* *Otolaryngol Clin North Am* 2001;34:1025-42.
 - 29 Bloch O, Parsa AT. *Skull base chondrosarcoma. Evidence-based treatment paradigms.* *Neurosurg Clin N Am* 2013;24:89-96.
 - 30 Rosenberg AE, Nielsen GP, Keel SB, et al. *Chondrosarcoma of the base of the skull: a clinicopathologic study of 200 cases with emphasis on its distinction from chordoma.* *Am J Surg Pathol* 1999;23:1370-8.
 - 31 Van Gompel JJ, Janus JR. *Chordoma and chondrosarcoma.* *Otolaryngol Clin North Am* 2015;48:501-14.
 - 32 Noel G, Feuvret L, Calugaru V, et al. *Chondrosarcomas of the base of the skull in Ollier's disease or Maffucci's syndrome - three case reports and review of the literature.* *Acta Oncol* 2004;43:705-10.
 - 33 Rosenberg AE. *Pathology of chordoma and chondrosarcoma of the axial skeleton.* In: Harsh GR (ed.). *Chordomas and chondrosarcomas of the skull base and spine.* New York: Thieme; 2003. pp. 8-15.
 - 34 Koch BB, Karnell LH, Hoffman HT, et al. *National Cancer Database report on chondrosarcoma of the head and neck.* *Head Neck* 2000;22:408-25.
 - 35 Colli BO, Al-Mefty O. *Chordomas of the skull base: follow-up review and prognostic factors.* *Neurosurg Focus* 2001;10:E1.
 - 36 Feigl GC, Bundschuh O, Gharabaghi A, et al. *Evaluation of a new concept for the management of skull base chordomas and chondrosarcomas.* *J Neurosurg* 2005;102:165-70.
 - 37 Gay E, Sekhar LN, Rubinstein E, et al. *Chordomas and chondrosarcomas of the cranial base: results and follow-up of 60 patients.* *Neurosurgery* 1995;36:887-97.
 - 38 Sekhar LN, Pranarthiharan R, Chanda A, et al. *Chordomas and chondrosarcomas of the skull base: results and complications of surgical management.* *Neurosurg Focus* 2001;10:E2.
 - 39 Sekhar LN, Chanda A, Chandrasekar K, et al. *Chordoma and chondrosarcomas.* In: Winn HR (editor). *Youmans neurological surgery.* Philadelphia: Saunders; 2004. pp. 1283-94.
 - 40 Harnsberger R, Patricia A, Hudgins MD, et al. *Diagnostic imaging: head and neck.* Salt Lake City, UT: Amirsys; 2004. 1st edition.
 - 41 Yeom KW, Lober RM, Mobley BC, et al. *Diffusion-weighted MRI: distinction of skull base chordoma from chondrosarcoma.* *AJNR* 2013;34:1056-61.
 - 42 Fisch U. *Infratemporal fossa approach to tumours of the temporal bone and base of the skull.* *J Laryngol Otol* 1978;92:949-67.
 - 43 Mazzoni A. *The petro-occipital trans-sigmoid approach for lesions of the jugular foramen.* *Skull Base* 2009;19:48-56.
 - 44 Zanoletti E, Martini A, Emanuelli E, et al. *Lateral approaches to the skull base.* *Acta Otorhinolaryngol Ital* 2012;32:281-7.
 - 45 Mazzoni A, Sanna M. *A posterolateral approach to the skull base: the petro-occipital transsigmoid approach.* *Skull Base Surg* 1995;5:157-67.
 - 46 Prado FO, Nishimoto IN, Perez DE, et al. *Head and neck chondrosarcoma: analysis of 16 cases.* *Br J Oral Maxillofac Surg* 2009;47:555-7.
 - 47 Burkey BB, Hoffman HT, Baker SR, et al. *Chondrosarcoma of the head and neck.* *Laryngoscope* 1990;100:1301-5.
 - 48 Harwood AR, Krajchich JI, Fornasier VL. *Radiotherapy of chondrosarcoma of bone.* *Cancer* 1980;45:2769-77.
 - 49 Hug EB, Slater JD. *Proton radiation therapy for chordomas and chondrosarcomas of the skull base.* *Neurosurg Clin N Am* 2000;11:627-38.
 - 50 Fuji H, Nakasu Y, Ishida Y, et al. *Feasibility of proton beam therapy*

for chordoma and chondrosarcoma of the skull base. *Skull Base* 2011;21:201-6.

- ⁵¹ Lustig LR, Sciubba J, Holliday MJ. *Chondrosarcomas of the skull base and temporal bone*. *J Laryngol Otol* 2007;121:725-35.
- ⁵² Zanation AM, Snyderman CH, Carrau RL, et al. *Endoscopic endonasal surgery for petrous apex lesions*. *Laryngoscope* 2009;119:19-25.

4.3.2. Endolymphatic sac tumours

- ¹ Hassard AD, Boudreau SF, Cron CC. *Adenoma of the endolymphatic sac*. *J Otolaryngol* 1984;13:213-6.
- ² Heffner DK. *Low-grade adenocarcinoma of probable endolymphatic sac origin. A clinicopathologic study of 20 cases*. *Cancer* 1989;64:2292-302.
- ³ Li JC, Brackmann DE, Lo WW, et al. *Reclassification of aggressive adenomatous mastoid neoplasms as endolymphatic sac tumors*. *Laryngoscope* 1993;103:1342-8.
- ⁴ Zanoletti E, Girasoli L, Borsetto D, et al. *Endolymphatic sac tumour in von hippel-lindau disease: management strategies*. *Acta Otorhinolaryngol Ital* 2017;37:423-9.
- ⁵ Dornbos D, Kim HJ, Butman JA, et al. *Review of the neurological implications of von Hippel-Lindau disease*. *JAMA Neurol* 2018;75:620-7.
- ⁶ Megerian CA, Haynes DS, Poe DS, et al. *Hearing preservation surgery for small endolymphatic sac tumors in patients with von Hippel-Lindau syndrome*. *Otol Neurotol* 2002;23:378-87.
- ⁷ Tay KY, Yu E, Kassel E. *Spinal metastasis from endolymphatic sac tumor*. *AJNR Am J Neuroradiol* 2007;28:613-4.
- ⁸ Lonser RR, Glenn GM, Walther M, et al. *von Hippel-Lindau disease*. *Lancet* 2003;361:2059-67.
- ⁹ Mazzoni A. *The petro-occipital trans-sigmoid approach for lesions of the jugular foramen*. *Skull Base* 2009;19:48-56.
- ¹⁰ Sinclair G, Al-Saffar Y, Brigui M, et al. *Gamma knife radiosurgery in the management of endolymphatic sac tumors*. *Surg Neurol Int* 2018;9:18.

4.3.3. Posterior fossa meningiomas: the neuro-otologist perspective

- ¹ Castellano F, Ruggiero G. *Meningiomas of the posterior fossa*. *Acta Radiol Suppl* 1953;104:1-177.
- ² Martinez R, Vaquero J, Areitio E, et al. *Meningiomas of the posterior fossa*. *Surg Neurol* 1983;19:237-43.
- ³ He X, Liu W, Wang Y, et al. *Surgical management and outcome experience of 53 cerebellopontine angle meningiomas*. *Cureus* 2017;9:e1538.
- ⁴ Thomas NW, King TT. *Meningiomas of the cerebellopontine angle. A report of 41 cases*. *Br J Neurosurg* 1996;10:59-68.
- ⁵ A. Mazzoni. *The petro-occipital trans-sigmoid approach for lesions of the jugular foramen*. *Skull Base* 2009;19:48-56.
- ⁶ Tummala RP, Coscarella E, Morco JJ. *Transpetrosal approaches to the posterior fossa*. *Neurosurg Focus* 2005;19:E6.
- ⁷ House JW, Brackmann DE. *Facial nerve grading system*. *Otolaryngol Head Neck Surg* 1985;93:146-7.
- ⁸ Simpson D. *The recurrence of intracranial meningiomas after surgical treatment*. *J Neurol Neurosurg Psychiatry* 1957;20:22-39.

4.3.4. Lateral skull base meningiomas: the neurosurgeon's perspective

- ¹ Philippon J, Cornu P. *The recurrence of meningiomas*. In: Al Mefty O (editor). *Meningiomas*. New York, NY: Raven Press; 1991. pp. 87-106.
- ² Roser F, Nakamura M, Jacobs C, et al. *Sphenoid wing meningiomas with osseous involvement*. *Surg Neurol* 2005;64:37-43.
- ³ Russel SM, Benjamin V. *Medial sphenoid ridge meningiomas: classification, microsurgical anatomy, operative nuances and long-term surgical outcome in 35 consecutive patients*. *Neurosurgery* 2008;62(Suppl 1):38-50.
- ⁴ Bassiouni H, Asgari S, Sandalcioğlu IE, et al. *Anterior clinoidal meningiomas: functional outcome after microsurgical resection in a consecutive series of 106 patients: clinical article*. *J Neurosurg* 2009;111:1078-90.
- ⁵ Pamir MN, Belirgen M, Ozduman K, et al. *Anterior clinoidal meningiomas: analysis of 43 consecutive surgically treated cases*. *Acta Neurochir (Wien)* 2008;150:625-35.
- ⁶ Nakamura M, Roser F, Jacobs C, et al. *Medial sphenoid wing meningiomas: clinical outcome and recurrence rate*. *Neurosurgery* 2006;58:626-39.
- ⁷ Nakamura M, Roser F, Dormiani M, et al. *Facial and cochlear nerve function after surgery of cerebello pontine angle meningiomas*. *Neurosurgery* 2005;57:77-90.
- ⁸ Samii M, Gerganov VM. *Cerebellopontine angle meningiomas*. In: DeMonte F, McDermott MW (eds.). *Al Mefty's meningiomas*. New York: Thieme Medical Publishers; 2011. p. 262.
- ⁹ Bassiouni H, Hunold A, Asgari S, et al. *Meningiomas of the posterior petrous bone: functional outcome after microsurgery*. *J Neurosurg* 2004;100:1014-24.
- ¹⁰ Wu ZB, Yu CJ, Guan SS. *Posterior petrous meningiomas: 82 cases*. *J Neurosurg* 2005;102:284-9.
- ¹¹ Bricolo AP, Turazzi S, Talacchi A, et al. *Microsurgical removal of petroclival meningiomas: a report of 33 patients*. *Neurosurgery* 1992;31:813-28.
- ¹² Coppens JR, Couldwell WT. *Clival and petroclival meningiomas*. In: DeMonte F, McDermott MW (editors). *Al Mefty's meningiomas*. New York: Thieme Medical Publishers; 2011. pp. 272-7.
- ¹³ Muto J, Prevedello DM, Ditzel Filho LF, et al. *Comparative analysis of the anterior transpetrosal approach with the endoscopic endonasal approach to the petroclival region*. *J Neurosurg* 2016;125:1171-86.
- ¹⁴ Azar M, Kazemi F, Jahanbakhshi A, et al. *Gamma knife radiosurgery for cavernous sinus meningiomas: analysis of outcome in 166 patients*. *Stereotact Funct Neurosurg* 2017;95:259-67.
- ¹⁵ Kano H, Park KJ, Kondziolka D, et al. *Does prior microsurgery improve or worsen the outcomes of stereotactic radiosurgery for cavernous sinus meningiomas?* *Neurosurgery* 2013;73:401-10.
- ¹⁶ Calbucci F. *Treatment strategy for sphenopetroclival meningiomas*. *World Neurosurg* 2011;75:419-20.
- ¹⁷ Samii M, Tatagiba M, Carvalho GA. *Retrosigmoid intradural suprameatal approach to Meckel's cave and the middle fossa: surgical technique and outcome*. *J Neurosurg* 2000;92:235-41.
- ¹⁸ Bambakidis NC, Kakarla UK, Kim LJ, et al. *Evolution of surgical approaches in the treatment of petroclival meningiomas: a retrospective review*. *Neurosurgery* 2008;62(Suppl 3):1182-91.
- ¹⁹ House WF, Hitselberger WE. *The transcochlear approach to the skull base*. *Arch Otolaryngol* 1976;102:334-42.
- ²⁰ De la Cruz A, Teufert KB. *Transcochlear approach to cerebellopontine angle and clivus lesions: indications, results, and complications*. *Otol Neurotol* 2009;30:373-80.

- 21 Al-Mefty O, Sekhar LN, Sen C, et al. *Petroclival meningioma: case history and responses*. Skull Base 2001;11:143-8.
- 22 Cho CW, Al-Mefty O. *Combined petrosal approach to petroclival meningiomas*. Neurosurgery 2002;51:708-16.

4.3.5. Primary squamous cell carcinoma of the temporal bone

- 1 Lionello M, Stritoni P, Facciolo MC, et al. *Temporal bone carcinoma. Current diagnostic, therapeutic, and prognostic concepts*. J Surg Oncol 2014;110:383-92.
- 2 Gidley PW, DeMonte F. *Temporal bone malignancies*. Neurosurg Clin N Am 2013;24:97-110.
- 3 Homer JJ, Lesser T, Moffat D, et al. *Management of lateral skull base cancer: United Kingdom National Multidisciplinary Guidelines*. J Laryngol Otol 2016;130:S119-24.
- 4 Sasaki CT. *Distant metastases from ear and temporal bone cancer*. ORL J Otorhinolaryngol Relat Spec 2001;63:250-1.
- 5 Zanoletti E, Lovato A, Stritoni P, et al. *A critical look at persistent problems in the diagnosis, staging and treatment of temporal bone carcinoma*. Cancer Treat Rev 2015;41:821-6.
- 6 Gillespie MB, Francis HW, Chee N, et al. *Squamous cell carcinoma of the temporal bone: a radiographic-pathologic correlation*. Arch Otolaryngol Head Neck Surg 2001;127:803-7.
- 7 Zanoletti E, Marioni G, Franchella S, et al. *Recurrent squamous cell carcinoma of the temporal bone: critical analysis of cases with a poor prognosis*. Am J Otolaryngol 2015;36:352-5.
- 8 Moody SA, Hirsch BE, Myers EN. *Squamous cell carcinoma of the external auditory canal: an evaluation of a staging system*. Am J Otol 2000;21:582-8.
- 9 Mazzoni A, Zanoletti E, Marioni G, et al. *En bloc temporal bone resections in squamous cell carcinoma of the ear: technique, principles and limits*. Acta Otolaryngol 2016;136:425-32.
- 10 Zanoletti E, Marioni G, Stritoni P, et al. *Temporal bone squamous cell carcinoma: analyzing prognosis with univariate and multivariate models*. Laryngoscope 2014;124:1192-8.
- 11 Prasad SC, D'Orazio F, Medina M, et al. *State of the art in temporal bone malignancies*. Curr Opin Otolaryngol Head Neck Surg 2014;22:154-65.
- 12 Hashi N, Shirato H, Omatsu T, et al. *The role of radiotherapy in treating squamous cell carcinoma of the external auditory canal, especially in early stages of disease*. Radiother Oncol 2000;56:221-5.
- 13 Marioni G, Zanoletti E, Giacomelli L, et al. *Clinical and pathological parameters prognostic for increased risk of recurrence after postoperative radiotherapy for temporal bone carcinoma*. Head Neck 2016;38:894-8.
- 14 Bacciu A, Clemente IA, Piccirillo E, et al. *Guidelines for treating temporal bone carcinoma based on long-term outcomes*. Otol Neurotol 2013;34:898-907.
- 15 Nakagawa T, Kumamoto Y, Natori Y, et al. *Squamous cell carcinoma of the external auditory canal and middle ear: an operation combined with preoperative chemoradiotherapy and a free surgical margin*. Otol Neurotol 2006;27:242-8.
- 16 Takenaka Y, Cho H, Nakahara S, et al. *Chemoradiation therapy for squamous cell carcinoma of the external auditory canal: a meta-analysis*. Head Neck 2015;37:1073-80.
- 17 Shiga K, Ogawa T, Maki A, et al. *Concomitant chemoradiotherapy as a standard treatment for squamous cell carcinoma of the temporal bone*. Skull Base 2011;21:153-8.
- 18 Morita S, Homma A, Nakamaru Y, et al. *The outcomes of surgery and chemoradiotherapy for temporal bone cancer*. Otol Neurotol 2016;37:1174-82.
- 19 Higgins TS, Antonio SA. *The role of facial palsy in staging squamous cell carcinoma of the temporal bone and external auditory canal: a comparative survival analysis*. Otol Neurotol 2010;31:1473-9.
- 20 Marioni G, Martini A, Favaretto N, et al. *Temporal bone carcinoma: a first glance beyond the conventional clinical and pathological prognostic factors*. Eur Arch Otorhinolaryngol 2016;273:2903-10.
- 21 Marioni G, Nucci R, Marino F, et al. *Neoangiogenesis in temporal bone carcinoma: the prognostic role of CD105*. Otol Neurotol 2012;33:843-8.
- 22 Marioni G, Zanoletti E, Stritoni P, et al. *Expression of the tumour-suppressor MASPIN in temporal bone carcinoma*. Histopathology 2013;63:242-9.
- 23 Morita S, Nakamaru Y, Homma A, et al. *Expression of p53, p16, cyclin D1, epidermal growth factor receptor and Notch1 in patients with temporal bone squamous cell carcinoma*. Int J Clin Oncol 2017;22:181-9.
- 24 Ebisumoto K, Okami K, Hamada M, et al. *Cetuximab with radiotherapy as an alternative treatment for advanced squamous cell carcinoma of the temporal bone*. Auris Nasus Larynx 2018;45:637-9.

4.3.6. Petrous bone cholesteatoma

- 1 Moffat D, Jones S, Smith W. *Petrous temporal bone cholesteatoma: a new classification and long-term surgical outcomes*. Skull Base 2008;18:107-15.
- 2 Vashishth A, Singh Nagar TR, Mandal S, et al. *Extensive intratemporal cholesteatomas: presentation, complications and surgical outcomes*. Eur Arch Otorhinolaryngol 2015;272:289-95.
- 3 Tutar H, Goksu N, Aydil U, et al. *An analysis of petrous bone cholesteatomas treated with translabyrinthine transotic petrosectomy*. Acta Otolaryngol 2013;133:1053-7.
- 4 Sanna M, Pandya Y, Mancini F, et al. *Petrous bone cholesteatoma: classification, management and review of the literature*. Audiol Neurootol 2011;16:124-36.
- 5 Danesi G, Cooper T, Panciera DT, et al. *Sanna classification and prognosis of cholesteatoma of the petrous part of the temporal bone: a retrospective series of 81 patients*. Otol Neurotol 2016;37:787-92.
- 6 Álvarez FL, Gómez JR, Bernardo MJ, et al. *Management of petrous bone cholesteatoma: open versus obliterative techniques*. Eur Arch Otorhinolaryngol 2011;268:67-72.
- 7 MacKeith SA, Soledad-Juarez M, Tiberti L, et al. *Recurrent aseptic meningitis as a rare but important presentation of congenital petrous apex cholesteatoma: the value of appropriate imaging*. BMJ Case Rep 2014.
- 8 Sheahan P, Walsh RM. *Supralabyrinthine approach to petrosal cholesteatoma*. J Laryngol Otol 2003;117:558-60.
- 9 Conte G, Scola E, Calloni S, et al. *Flat panel angiography in the cross-sectional imaging of the temporal bone: assessment of image quality and radiation dose compared with a 64-section multisection CT scanner*. AJNR Am J Neuroradiol 2017;38:1998-2002.
- 10 Piergallini L, Scola E, Tuscano B, et al. *Flat-panel CT versus 128-slice CT in temporal bone imaging: assessment of image quality and radiation dose*. Eur J Radiol 2018;106:106-13.
- 11 Baráth K, Huber AM, Stämpfli P, et al. *Neuroradiology of cholesteatomas*. AJNR Am J Neuroradiol 2011;32:221-9.
- 12 Vercruyssen JP, De Foer B, Pouillon M, et al. *The value of diffusion-weighted MR imaging in the diagnosis of primary acquired and residual cholesteatoma: a surgical verified study of 100 patients*. Eur Radiol 2006;16:1461-7.

- 13 Vaid S, Kamble Y, Vaid N, et al. *Role of magnetic resonance imaging in cholesteatoma: the Indian experience*. Indian J Otolaryngol Head Neck Surg 2013;65(Suppl 3):485-92.
- 14 Williams MT, Ayache D, Alberti C, et al. *Detection of postoperative residual cholesteatoma with delayed contrast-enhanced MR imaging: initial findings*. Eur Radiol 2003;13:169-74.
- 15 Sugimoto H, Hatano M, Noda M, et al. *Endoscopic management of petrous apex cholesteatoma*. Eur Arch Otorhinolaryngol 2017;274:4127-30.
- 16 Song JJ, An YH, Ahn SH, et al. *Surgical management options and postoperative functional outcomes of petrous apex cholesteatoma*. Acta Otolaryngol 2011;131:9.
- 17 Pandya Y, Piccirillo E, Mancini MF, et al. *Management of complex cases of petrous bone cholesteatoma*. Ann Otol Rhinol Laryngol 2010;119:514-25.
- 18 van Dinther JJ, Verduynde JP, De Foer B, et al. *Subarcuate supralabyrinthine approach for supralabyrinthine petrous cholesteatoma*. Ann Otol Rhinol Laryngol 2010;119:42-6.
- 19 Kojima H, Tanaka Y, Yaguchi Y, et al. *Endoscope-assisted surgery via the middle cranial fossa approach for a petrous cholesteatoma*. Auris Nasus Larynx 2008;35:469-74.
- 20 Oyama K, Ikezono T, Tahara S, et al. *Petrous apex cholesterol granuloma treated via the endoscopic transsphenoidal approach*. Acta Neurochir (Wien) 2007;149:299-302.
- 21 Aubry K, Kovac L, Sauvaget E, et al. *Our experience in the management of petrous bone cholesteatoma*. Skull Base 2010;20:163-7.
- 22 Senn P, Haeusler R, Panosetti E, et al. *Petrous bone cholesteatoma with hearing preservation*. Otol Neurotol 2011;32:236-41.
- 23 Hong SJ, Lee JH, Jung SH, et al. *Can cochlear function be preserved after a modified translabyrinthine approach to eradicate a huge cholesteatoma extending to the petrous apex?* Eur Arch Otorhinolaryngol 2009;266:1191-7.
- 24 Magliulo G. *Petrous bone cholesteatoma: clinical longitudinal study*. Eur Arch Otorhinolaryngol 2007;264:115-20.
- 25 Vashishth A, Fulcheri A, Chandra Prasad S, et al. *Cochlear implantation in chronic otitis media with cholesteatoma and open cavities: long-term surgical outcomes*. Otol Neurotol 2018;39:45-53.
- 26 Iannella G, Savastano E, Pasquariello B, et al. *Giant petrous bone cholesteatoma: combined microscopic surgery and an adjuvant endoscopic approach*. J Neurol Surg Rep 2016;77:e46-9.
- 27 Patron V, Hitier M. *Combined microscopic/endoscopic management of petrous apex lesions*. Eur Arch Otorhinolaryngol 2018;275:319-21.
- 28 Kanzara T, Virk JS, Chawda S, et al. *Wholly endoscopic permeatal removal of a petrous apex cholesteatoma*. Case Rep Otolaryngol 2014;2014:184230.
- 6 Hoa M, House JW, Linthicum FH. *Petrous apex cholesterol granuloma: maintenance of drainage pathway, the histopathology of surgical management and histopathologic evidence for the exposed marrow theory*. Otol Neurotol 2012;33:1059-65.
- 7 Sanna M, Dispenza F, Mathur N, et al. *Otoneurological management of petrous apex cholesterol granuloma*. Am J Otolaryngol 2009;30:407-14.
- 8 Sanna M, Pandya Y, Mancini F, et al. *Petrous bone cholesteatoma: classification, management and review of the literature*. Audiol Neurootol 2011;16:124-36.
- 9 Prasad SC, Piras G, Piccirillo E, et al. *Surgical strategy and facial nerve outcomes in petrous bone cholesteatoma*. Audiol Neurootol 2016;21:275-85.
- 10 House WF, Hitselberger WE, Horn KL. *The middle fossa transpetrous approach to the anterior-superior cerebellopontine angle*. Am J Otol 1986;7:1-4.
- 11 Sanna M, Piazza P, Shin SH, et al. *Microsurgery of skull base paragangliomas*. Stuttgart, New York: Georg Thieme Verlag; 2013.
- 12 Sanna M, Khrais T, Menozzi R, et al. *Surgical removal of jugular paragangliomas after stenting of the intratemporal internal carotid artery: a preliminary report*. Laryngoscope 2006;116:742-6.
- 13 Bacciu A, Nusier A, Lauda L, et al. *Are the current treatment strategies for facial nerve schwannoma appropriate also for complex cases?* Audiol Neurootol 2013;18:184-91.
- 14 Sanna M, Khrais T, Mancini F, et al. *The facial nerve in temporal bone and lateral skull base microsurgery*. Stuttgart, New York: Georg Thieme Verlag; 2006.

5.2. The evolving evidence based algorithm in vestibular schwannoma management

5.1. Petrous apex and surrounding areas lesions: clinical and surgical management

- 1 Sanna M, Saleh E, Khrais T, et al. *Atlas of microsurgery of the lateral skull base*. Stuttgart, New York: Georg Thieme Verlag; 2008.
- 2 Sanna M, Russo A, Taibah A, et al. *The temporal bone: anatomical dissection and surgical approaches*. Stuttgart, New York: Georg Thieme Verlag; 2018.
- 3 Connor SE, Leung R, Natas S. *Imaging of the petrous apex: a pictorial review*. Br J Radiol 2008;81:427-35.
- 4 Razek AA, Huang BY. *Lesions of the petrous apex: classification and findings at CT and MR imaging*. Radiographics 2012;32:151-73.
- 5 Jackler RK, Cho M. *A new theory to explain the genesis of petrous apex cholesterol granuloma*. Otol Neurotol 2003;24:96-106.
- 1 Pirsig W, Ziermann-Becker B, Teschler-Nicola M. *Acoustic neurofibromatosis in a child from the early bronze age*. In: Tos M, Thomsen J (editors). *Proceedings of the first international conference on acoustic neuroma*. Amsterdam, New York: Kugler Publications; 1992. pp. 7-12.
- 2 Sandiford E. *De duram quodam corpusculo, nervo auditorio adherente*. In: Van de Eyk P, Vygh D (eds). *Observationes anatomicae-pathologicae*. 1777;116-20.
- 3 Bell C. *The nervous system of the human body; embracing the papers delivered to the Royal Society on the subject of nerves. Appendix of cases*. Washington DC: Duff Green; 1833. pp. 112-4.
- 4 Ramsden RT. *"A brilliant surgical result, the first recorded": Anandale's case, 3rd May 1895*. J Laryngol Otol 1995;109:369-73.
- 5 Jerger J. *Hearing tests in otologic diagnosis*. Am Speech Hearing Assoc 1962;4:139-45.
- 6 Canty P. *Speech audiometry in acoustic neuroma*. J Laryngol Otol 1978;92:843-51.
- 7 Fowler EP. *Loudness recruitment: definition and clarification*. Arch Otolaryngol 1963;78:748-53.
- 8 Jerger J. *Bekesy audiometry in analysis of auditory disorders*. J Speech Hearing Res 1960;3:275-87.
- 9 Johnson EW. *Auditory test results in 500 cases of acoustic neuroma*. Arch Otolaryngol 1977;103:152-8.
- 10 Kiang NY-S, Peake WT. *Components of electrical responses recorded from the cochlea*. Ann Rhinol Laryngol 1960;69:448-58.
- 11 Selters WA, Brackmann DE. *Acoustic tumor detection with brainstem electric response audiometry*. Arch Otolaryngol 1977;103:181-7.
- 12 Dandy WE. *Rontgenography of the brain after the injection of air into the spinal canal*. Ann Surg 1919;70:397-403.

- ¹³ Hounsfield GN. *Computerised transverse axial scanning (tomography) I. Description of system*. Br J Radiol 1973;46:1016-22.
- ¹⁴ Ballance CA. *Some points in the surgery of the brain and its membranes*. London: Macmillan; 1907.
- ¹⁵ Cushing HW. *Tumors of the nervus acusticus and the syndrome of the cerebello-pontine angle*. Philadelphia and London: WB Saunders Company; 1917.
- ¹⁶ Dandy WE. *An operation for the total extirpation of tumors in the cerebello-pontine angle. A preliminary report*. Bull Johns Hopkins Hosp 1922;33:344-5.
- ¹⁷ House WF. *Middle cranial fossa approach to the petrous pyramid. Report of 50 cases*. Arch Otolaryngol 1963;78:460-9.
- ¹⁸ Panse R. *Ein gliom des akustikus*. Arch Ohren-Heilk 1904;61:1.
- ¹⁹ Thomsen J, Tos M. *Acoustic neuromas. Diagnostic delay, growth rate and possible non-surgical treatment*. Acta Otolaryngol Suppl 1988; 452:26-33.
- ²⁰ Leksell L. *The stereotaxic method and radiosurgery of the brain*. Acta Chir Scand 1951;102:316-9.
- ²¹ Moffat DA, Kasbekar AV, Baguley DM, et al. *Growth characteristics of vestibular schwannomas*. Otol Neurotol 2012;33:1053-8.
- ²² Moffat DA, Parker RA, Hardy DG, et al. *Factors affecting final facial nerve outcome following vestibular schwannoma surgery*. J Laryngol Otol 2014;128:406-15.
- ²³ Humphriss RL, Baguley DM, Moffat DA. *Change in hearing handicap after translabyrinthine vestibular schwannoma excision*. Otol Neurotol 2004;25:371-8.
- ²⁴ Baguley DM, Axon PR, Moffat DA, et al. *Change in tinnitus handicap after translabyrinthine vestibular schwannoma excision*. Otol Neurotol 2005;26:1061-3.
- ²⁵ Humphriss RL, Baguley DM, Moffat DA. *Change in dizziness handicap after vestibular schwannoma excision*. Otol Neurotol 2003;24:661-5.
- ²⁶ Lloyd SK, Baguley DM, Moffat DA, et al. *Audiovestibular factors influencing quality of life in patients with conservatively managed sporadic vestibular schwannoma*. Otol Neurotol 2010;31:968-76.
- ²⁷ Sackett D. *Evidence-based medicine*. Lancet 1995;346:1171.
- ²⁸ Bednarska E, Bryant D, Devereaux PJ; Expertise-Based Working Group. *Orthopaedic surgeons prefer to participate in expertise-based randomized trials*. Clin Orthop Relat Res 2008;466:1734-44.
- ²⁹ Irving RM, Hardy DG, Moffat DA, et al. *The patient's perspective after vestibular schwannoma removal: quality of life and implications for management*. Am J Otol 1995;16:331-7.
- ³⁰ da Cruz MJ, Moffat DA, Hardy DG. *Postoperative quality of life in vestibular schwannoma patients measured by the SF36 health questionnaire*. Laryngoscope 2000;110:151-5.
- ³¹ Myrseth E, Moller P, Pedersen PH, et al. *Vestibular schwannomas: clinical results and quality of life after microsurgery or gamma knife radiosurgery*. Neurosurgery 2005;56:927-35.
- ³² Persson O, Bartek J Jr, Shalom NB, et al. *Stereotactic radiosurgery vs. fractionated radiotherapy for tumor control in vestibular schwannoma patients: a systematic review*. Acta Neurochir (Wein) 2017;159:1013-21.
- ² Lloyd SK, Evans DG. *Neurofibromatosis type 2 service delivery in England*. Neurochirurgie 2018;64:375-80.
- ³ Peyre M, Goutagny S, Bah A, et al. *Conservative management of bilateral vestibular schwannomas in neurofibromatosis type 2 patients, hearing and tumor growth results*. Neurosurgery 2013;72:907-13.
- ⁴ Peyre M, Goutagny S, Imbeaud S, et al. *Increased growth rate of vestibular schwannoma after resection of contralateral tumor in neurofibromatosis type 2*. Neuro Oncol 2011;13:1125-32.
- ⁵ Fisher LM, Doherty JK, Lev MH, et al. *Concordance of bilateral vestibular schwannoma growth and hearing changes in neurofibromatosis 2, neurofibromatosis 2 natural history consortium*. Otol Neurotol 2009;30:835-41.
- ⁶ Mallory GW, Pollock BE, Foote RL, et al. *Stereotactic radiosurgery for neurofibromatosis 2-associated vestibular schwannomas, toward dose optimization for tumor control and functional outcomes*. Neurosurgery 2014;74:292-300.
- ⁷ Lloyd SKW, King AT, Rutherford SA, et al. *Hearing optimisation in neurofibromatosis type 2: a systematic review*. Clin Otolaryngol 2017;42:1329-37.
- ⁸ Evans DG, Birch JM, Ramsden RT, et al. *Malignant transformation and new primary tumours after therapeutic radiation for benign disease, substantial risks in certain tumour prone syndromes*. J Med Genet 2006;43:289-94.
- ⁹ Torres R, Nguyen Y, Vanier A, et al. *Multivariate analysis of factors influencing facial nerve outcome following microsurgical resection of vestibular schwannoma*. Otolaryngol Head Neck Surg 2017;156:525-33.
- ¹⁰ Friedman RA, Goddard JC, Wilkinson EP, et al. *Hearing preservation with the middle cranial fossa approach for neurofibromatosis type 2*. Otol Neurotol 2011;32:1530-7.
- ¹¹ Bernardeschi D, Peyre M, Collin M, et al. *Internal auditory canal decompression for hearing maintenance in neurofibromatosis type 2 patients*. Neurosurgery 2016;79:370-7.
- ¹² Blakeley JO, Ye X, Duda DG, et al. *Efficacy and biomarker study of bevacizumab for hearing loss resulting from neurofibromatosis type 2-associated vestibular schwannomas*. J Clin Oncol 2016;34:1669-75.
- ¹³ Goutagny S, Giovannini M, Kalamarides M. *A 4-year phase II study of everolimus in NF2 patients with growing vestibular schwannomas*. J Neurooncol 2017;133:443-5.
- ¹⁴ Sanna M, Di Lella F, Guida M, et al. *Auditory brainstem implants in NF2 patients, results and review of the literature*. Otol Neurotol 2012;33:154-64.
- ¹⁵ Carlson ML, Breen JT, Driscoll CL, et al. *Cochlear implantation in patients with neurofibromatosis type 2, variables affecting auditory performance*. Otol Neurotol 2012;33:853-62.
- ¹⁶ Tan H, Jia H, Li Y, et al. *Impact of cochlear implantation on the management strategy of patients with neurofibromatosis type 2*. Eur Arch Otorhinolaryngol 2018;275:2667-74.
- ¹⁷ Ramsden RT, Freeman SR, Lloyd SK, et al. *Auditory brainstem implantation in neurofibromatosis type 2, experience from the manchester programme*. Otol Neurotol 2016;37:1267-74.
- ¹⁸ Grayeli AB, Kalamarides M, Bouccara D, et al. *Auditory brainstem implant in neurofibromatosis type 2 and non-neurofibromatosis type 2 patients*. Otol Neurotol 2008;29:1140-6.
- ¹⁹ Coez A, Zilbovicius M, Ferrary E, et al. *Processing of voices in deafness rehabilitation by auditory brainstem implant*. Neuroimage 2009;47:1792-6.

5.4. When preservation of auditory function is a must: technique and outcome in a series of neurofibromatosis type II

- 1 Mazzone A, Zanoletti E, Denaro L, et al. *Retrolabyrinthine meatotomy as part of retrosigmoid approach to expose the whole internal auditory canal: rationale, technique, and outcome in hearing preservation surgery for vestibular schwannoma*. Oper Neurosurg (Hagerstown) 2018;14:36-44.
- 2 Samii M, Matthies C. *Management of 1,000 vestibular schwannomas (acoustic neuromas): hearing function in 1,000 tumor resections*. Neurosurgery 1997;40:248-60.
- 3 Samii M, Matthies C, Tatagiba M. *Management of vestibular schwannomas (acoustic neuromas): auditory and facial nerve function after resection of 120 vestibular schwannomas in patients with neurofibromatosis 2*. Neurosurgery 1997;40:696-705.
- 4 Samii M, Gerganov V, Samii A. *Improved preservation of hearing and facial nerve function in vestibular schwannoma surgery via the retrosigmoid approach in a series of 200 patients*. JNS 2006;105:527-35.
- 5 Samii M, Gerganov VM, Samii A. *Microsurgery management of vestibular schwannomas in neurofibromatosis type 2: indications and results*. Prog Neurol Surg 2008;21:169-75.
- 6 Sughrue ME, Yang I, Aranda D, et al. *The natural history of untreated sporadic vestibular schwannomas: a comprehensive review of hearing outcomes*. J Neurosurg 2010;112:163-7.
- 7 Sughrue ME, Kane AJ, Kaur R, et al. *A prospective study of hearing preservation in untreated vestibular schwannomas*. J Neurosurg 2011;114:381-5.
- 8 Lloyd SKW, King AT, Rutherford SA, et al. *Hearing optimisation in neurofibromatosis type 2: a systematic review*. Clin Otolaryngol 2017;42:1329-37.
- 9 Myrseth E, Møller P, Pedersen PH, et al. *Vestibular schwannoma: surgery or gamma knife radiosurgery? A prospective, nonrandomized study*. Neurosurgery 2009;64:654-61.
- 10 North HJD, Lloyd SKW. *Hearing rehabilitation in neurofibromatosis type 2*. Adv Otorhinolaryngol 2018;81:93-104.
- 11 Chung LK, Nguyen TP, Sheppard JP, et al. *A systematic review of radiosurgery versus surgery for neurofibromatosis type 2 vestibular schwannomas*. World Neurosurg 2018;109:47-58.
- 12 Mallory GW, Pollock BE, Foote RL, et al. *Stereotactic radiosurgery for neurofibromatosis 2-associated vestibular schwannomas: toward dose optimization for tumor control and functional outcomes*. Neurosurgery 2014;74:292-300.
- 13 Tonn JC. *Microneurosurgery and radiosurgery - an attractive combination*. Acta Neurochir Suppl 2004;91:103-8.
- 14 Brokinkel B, Sauerland C, Holling M, et al. *Gamma knife radiosurgery following subtotal resection of vestibular schwannoma*. J Clin Neurosci 2014;21:2077-82.
- 15 Tatagiba M, Roser F, Schuhmann MU, et al. *Vestibular schwannoma surgery via the retrosigmoid transmeatal approach*. Acta Neurochir 2014;156:421-5.
- 16 Zanoletti E, Cazzador D, Faccioli C, et al. *Multi-option therapy vs observation for small acoustic neuroma: hearing-focused management*. Acta Otorhinolaryngol Ital 2018;38:384-92.
- 17 Chen LH, Zhang HT, Xu RX, et al. *Microsurgery for patients diagnosed with neurofibromatosis type 2 complicated by vestibular schwannomas: clinical experience and strategy for treatments*. Medicine (Baltimore) 2018;97:e0270.
- 18 Zhao F, Wang B, Yang Z, et al. *Surgical treatment of large vestibular schwannomas in patients with neurofibromatosis type 2: outcomes on facial nerve function and hearing preservation*. J Neurooncol 2018;138:417-24.
- 19 Carlson ML, Tveiten OV, Driscoll CL, et al. *Long-term quality of life in patients with vestibular schwannoma: an international multicenter cross-sectional study comparing microsurgery, stereotactic radiosurgery, observation, and nontumor controls*. J Neurosurg 2015;122:833-42.
- 20 Plotkin SR, Stemmer-Rachamimov AO, Barker FG 2nd, et al. *Hearing improvement after bevacizumab in patients with neurofibromatosis type 2*. N Engl J Med 2009;361:358-67.
- 21 Blakeley JO, Ye X, Duda DG, et al. *Efficacy and biomarker study of bevacizumab for hearing loss resulting from neurofibromatosis type 2-associated vestibular schwannomas*. J Clin Oncol 2016;34:1669-75.
- 22 Huang V, Bergner AL, Halpin C, et al. *Improvement in patient-reported hearing after treatment with bevacizumab in people with neurofibromatosis type 2*. Otol Neurotol 2018;39:632-8.
- 23 Tan H, Jia H, Li Y, et al. *Impact of cochlear implantation on the management strategy of patients with neurofibromatosis type 2*. Eur Arch Otorhinolaryngol 2018;275:2667-74.
- 24 Peng KA, Lorenz MB, Otto SR, et al. *Cochlear implantation and auditory brainstem implantation in neurofibromatosis type 2*. Laryngoscope 2018;128:2163-9.
- 25 Grayeli AB, Kalamarides M, Bouccara D, et al. *Auditory brainstem implant in neurofibromatosis type 2 and non-neurofibromatosis type 2 patients*. Otol Neurotol 2008;29:1140-6.
- 26 Otto SR, Shannon RV, Wilkinson EP, et al. *Audiologic outcomes with the penetrating electrode auditory brainstem implant*. Otol Neurotol 2008;29:1147-54.
- 27 Behr R, Colletti V, Matthies C, et al. *New outcomes with auditory brainstem implants in NF2 patients*. Otol Neurotol 2014;35:1844-51.
- 28 Matthies C, Brill S, Varallyay C, et al. *Auditory brainstem implants in neurofibromatosis type 2: is open speech perception feasible?* J Neurosurg 2014;120:546-58.

5.5. Endoscope-assisted microsurgery of trigeminal, facial and auditory nerves

- 1 Barrow D. *Surgery of the cranial nerves of the posterior fossa*. AANS Publications;1993.
- 2 Dandy W. *Concerning the cause of trigeminal neuralgia*. Am J Surg 1934;24:447-55.
- 3 Gardner J. *Concerning the mechanism of trigeminal neuralgia and hemifacial spasm*. J Neurosurg 1962;19:947-58.
- 4 Jannetta P. *Trigeminal neuralgia and hemifacial spasm-etiology and definitive treatment*. Trans Am Neurol Assoc 1975;100:89-91.
- 5 Bremond G, Garcin M, Magnan J, et al. *L'abord "a minima" de l'espace pontocerebelleux*. Cah ORL 1974;9:443-60.
- 6 Magnan J, Chays A, Caces F, et al. *Apport de l'endoscopie de l'angle pontocerebelleux par voie retrosigmoïde: neurinomes et conflits vasculo-nerveux*. Ann Otolaryngol Chir Cervicofac (Paris) 1993;110:239-65.
- 7 Magnan J, Sanna M. *Endoscopy*. In: *Neuro-Otology*. Stuttgart, New York: Georg Thieme Verlag; 1999.
- 8 Miyazaki H, Deveze A, Magnan J. *Neuro-otologic surgery through minimally invasive retrosigmoid approach. Endoscope-assisted microvascular decompression, vestibular neurectomy and tumor removal*. Laryngoscope 2005;115:1612-7.
- 9 Magnan J, Parikh B, Miyazaki H. *Functional surgery of CPA by minimally invasive retrosigmoid approach*. Jaypee Brothers; 2013.
- 10 El-Garem H, Badr-El-Dine M, Talat AM, et al. *Endoscopy as a tool in minimally invasive trigeminal neuralgia surgery*. Otol Neurotol 2002;23:132-5.

- 11 Balansard C, Meller R, Bruzzo M, et al. *Trigeminal neuralgia: results of microsurgical and endoscope-assisted vascular decompression*. *Ann Otolaryngol Chir Cervicofac* 2003;120:330-7.
- 12 Magnan J, Caces F, Locatelli P, et al. *Hemifacial spasm: endoscopic vascular decompression*. *Otolaryngol Head Neck Surg* 1997;117:308-14.
- 13 Magnan J, Curto CL. *Hemifacial spasm*. In: Slattery W, Azzizaadeh B (editors). *The Facial nerve*. Stuttgart, New York: Georg Thieme Verlag; 2014. pp.137-45.
- 14 Badr-el-Dine M, Elgarem H, Talaat AM, et al. *Endoscopically assisted minimally invasive microvascular decompression of hemifacial spasm*. *Otol Neurotol* 2002;23:123-8.
- 15 Moller M, Moller A, Jannetta P, et al. *Vascular decompression surgery for severe tinnitus: selection criteria and results*. *Laryngoscope* 1993;103:421-7.
- 16 Magnan J, Lafont B, Rameh C. *Long term follow-up of MVD for tinnitus*. In: Moller AR, Langguth B, DeRidder D, et al. (editors). *Textbook of Tinnitus*. Springer; 2011. pp. 669-79.
- 15 Vernooij MW, Ikram MA, Tanghe HL, et al. *Incidental findings on brain MRI in the general population*. *N Engl J Med* 2007;357:1821-8.
- 16 Leonard JR, Talbot ML. *Asymptomatic acoustic neurilemoma*. *Arch Otolaryngol* 1970;91:117-24.
- 17 Stewart TJ, Liland J, Schuknecht HF. *Occult schwannomas of the vestibular nerve*. *Arch Otolaryngol* 1975;101:91-5.
- 18 Rocca WA, Yawn BP, St Sauver JL, et al. *History of the Rochester epidemiology project: half a century of medical records linkage in a US population*. *Mayo Clin Proc* 2012;87:1202-13.
- 19 Tos M, Charabi S, Thomsen J. *Incidence of vestibular schwannomas*. *Laryngoscope* 1999;109:736-40.
- 20 Stangerup SE, Caye-Thomasen P. *Epidemiology and natural history of vestibular schwannomas*. *Otolaryngol Clin North Am* 2012;45:257-68.
- 21 Koo M, Lai JT, Yang EY, et al. *Incidence of vestibular schwannoma in Taiwan from 2001 to 2012: a population-based national health insurance study*. *Ann Otol Rhinol Laryngol* 2018;127:694-7.
- 22 Kleijwegt M, Ho V, Visser O, et al. *Real incidence of vestibular schwannoma? Estimations from a national registry*. *Otol Neurotol* 2016;37:1411-7.
- 23 Marinelli JP, Lohse CM, Carlson ML. *Incidence of Intralabyrinthine schwannoma: a population-based study within the United States*. *Otol Neurotol* 2018;39:1191-4.
- 24 Hardy M, Crowe SJ. *Early asymptomatic acoustic tumor*. *Arch Surg* 1936;32:292-301.
- 25 Schuknecht TJ. *Occult schwannomas of the vestibular nerve*. *Arch Otolaryngol* 1975;101:5.
- 26 Karjalainen S, Nuutinen J, Neittaanmaki H, et al. *The incidence of acoustic neuroma in autopsy material*. *Arch Otorhinolaryngol* 1984;240:91-3.
- 27 Schmidt RF, Boghani Z, Choudhry OJ, et al. *Incidental vestibular schwannomas: a review of prevalence, growth rate, and management challenges*. *Neurosurg Focus* 2012;33:E4.
- 28 Tos M, Stangerup SE, Caye-Thomasen P, et al. *What is the real incidence of vestibular schwannoma?* *Arch Otolaryngol Head Neck Surg* 2004;130:216-20.
- 29 Baldovino S, Moliner AM, Taruscio D, et al. *Rare diseases in europe: from a wide to a local perspective*. *Isr Med Assoc J* 2016;18:359-63.
- 30 Song P, Gao J, Inagaki Y, et al. *Rare diseases, orphan drugs, and their regulation in Asia: current status and future perspectives*. *Intractable Rare Dis Res* 2012;1:3-9.
- 31 Costa AF, van der Pol CB, Maralani PJ, et al. *Gadolinium deposition in the brain: a systematic review of existing guidelines and policy statement issued by the Canadian association of radiologists*. *Can Assoc Radiol J* 2018;69:373-82.

5.6. Modern shifts in the clinical epidemiology of sporadic vestibular schwannoma and its implications

- 1 Ramsden RT. *The bloody angle: 100 years of acoustic neuroma surgery*. *J R Soc Med* 1995;88:464P-8P.
- 2 Cushing H. *Tumors of the nervus acusticus and the syndrome of the cerebellopontile ange*. Philadelphia and London: WB Saunders Company; 1917. p. 291.
- 3 Carlson ML, Habermann EB, Wagie AE, et al. *The changing landscape of vestibular schwannoma management in the United States. A shift toward conservatism*. *Otolaryngol Head Neck Surg* 2015;153:440-6.
- 4 Savica R, Grossardt BR, Bower JH, et al. *Incidence of dementia with Lewy bodies and Parkinson disease dementia*. *JAMA Neurol* 2013;70:1396-402.
- 5 Shenoy P, Maggioncalda A, Malik N, et al. *Incidence patterns and outcomes for Hodgkin lymphoma patients in the United States*. *Adv Hematol* 2011;2011:725219.
- 6 Schwartz M, Fisher L. *Incidence and clinical characteristics of acoustic neuroma in Beverly Hills*. *Skull Base* 2006;16:A040.
- 7 Marinelli JP, Lohse CM, Carlson ML. *Incidence of vestibular schwannoma over the past half-century: a population-based study of Olmsted County, Minnesota*. *Otolaryngol Head Neck Surg* 2018;159:717-23.
- 8 Marinelli JP, Grossardt BR, Lohse CM, et al. *Prevalence of sporadic vestibular schwannoma: reconciling temporal, radiologic, and population-based studies*. *Otol Neurotol* 2019;40:384-90.
- 9 Evans DG, Moran A, King A, et al. *Incidence of vestibular schwannoma and neurofibromatosis 2 in the North West of England over a 10-year period: higher incidence than previously thought*. *Otol Neurotol* 2005;26:93-7.
- 10 Kshetry VR, Hsieh JK, Ostrom QT, et al. *Incidence of vestibular schwannomas in the United States*. *J Neurooncol* 2015;124:223-8.
- 11 Stangerup SE, Tos M, Caye-Thomasen P, et al. *Increasing annual incidence of vestibular schwannoma and age at diagnosis*. *J Laryngol Otol* 2004;118:622-7.
- 12 Stangerup SE, Tos M, Thomsen J, et al. *True incidence of vestibular schwannoma?* *Neurosurgery* 2010;67:1335-40.
- 13 Anderson TD, Loevner LA, Bigelow DC, et al. *Prevalence of unsuspected acoustic neuroma found by magnetic resonance imaging*. *Otolaryngol Head Neck Surg* 2000;122:643-6.
- 14 Lin D, Hegarty JL, Fischbein NJ, et al. *The prevalence of "incidental" acoustic neuroma*. *Arch Otolaryngol Head Neck Surg* 2005;131:241-4.
- 15 Williams MD. *Paraganglioma of the head and neck: an overview from diagnosis to genetics*. *Head Neck Pathol* 2017;11:278-87.
- 16 Mazzoni A, Zanoletti E. *Observation and partial targeted surgery in the management of tympano-jugular paraganglioma: a contribution to the multioptional treatment*. *Eur Arch Otorhinolaryngol* 2016;273:635-42.
- 17 Mazzoni A, Cazzador D, d'Avella D, et al. *Large intradural growth of tympano-jugular paraganglioma: a contribution to surgery and management*. *World Neurosurg* 2019;122:e1482-90.

5.7. Preventing surgical morbidity in jugular paraganglioma

- 1 Williams MD. *Paraganglioma of the head and neck: an overview from diagnosis to genetics*. *Head Neck Pathol* 2017;11:278-87.
- 2 Mazzoni A, Zanoletti E. *Observation and partial targeted surgery in the management of tympano-jugular paraganglioma: a contribution to the multioptional treatment*. *Eur Arch Otorhinolaryngol* 2016;273:635-42.
- 3 Mazzoni A, Cazzador D, d'Avella D, et al. *Large intradural growth of tympano-jugular paraganglioma: a contribution to surgery and management*. *World Neurosurg* 2019;122:e1482-90.

