


Accepted Manuscript

Sinonasal non-intestinal type adenocarcinoma: a retrospective review of 22 patients.

Maurizio Bignami, MD, Davide Lepera, MD, Luca Volpi, MD, Alessia Lambertoni, MD, Alberto Arosio, MD, Andrea Pistochini, MD, Piero Nicolai, MD, Paolo Castelnuovo, MD



PII: S1878-8750(18)31987-9

DOI: [10.1016/j.wneu.2018.08.201](https://doi.org/10.1016/j.wneu.2018.08.201)

Reference: WNEU 9059

To appear in: *World Neurosurgery*

Received Date: 16 July 2018

Revised Date: 25 August 2018

Accepted Date: 28 August 2018

Please cite this article as: Bignami M, Lepera D, Volpi L, Lambertoni A, Arosio A, Pistochini A, Nicolai P, Castelnuovo P, Sinonasal non-intestinal type adenocarcinoma: a retrospective review of 22 patients., *World Neurosurgery* (2018), doi: 10.1016/j.wneu.2018.08.201.

This is a PDF file of an unedited manuscript that has been accepted for publication. As a service to our customers we are providing this early version of the manuscript. The manuscript will undergo copyediting, typesetting, and review of the resulting proof before it is published in its final form. Please note that during the production process errors may be discovered which could affect the content, and all legal disclaimers that apply to the journal pertain.

**Sinonasal non-intestinal type adenocarcinoma: a retrospective review
of 22 patients.**

Authors

Maurizio Bignami, MD¹; Davide Lepera, MD¹; Luca Volpi, MD¹; Alessia
Lambertoni, MD¹; Alberto Arosio, MD¹; Andrea Pistochini, MD; Piero Nicolai, MD²;
Paolo Castelnuovo, MD¹

¹ Department of Otorhinolaryngology, Ospedale di Circolo e Fondazione Macchi,
University of Insubria, Varese, Italy

² Department of Otorhinolaryngology, Spedali Civili, University of Brescia, Brescia,
Italy

Corresponding author:

Davide Lepera, M.D. Department of Otorhinolaryngology, University of Insubria,
Varese, Via Guicciardini,9 - Varese, Italy.

Phone: (+39) 0332.393278

Fax: (+39) 0332.393279

e-mail: davide.lepera86@gmail.com

KEYWORDS: sinonasal adenocarcinoma; non-intestinal type adenocarcinoma;
sinonasal malignancies; endoscopic surgery; skull base.

INTRODUCTION

Cancers of the nasal cavity and the paranasal sinuses are uncommon pathologies, accounting for 1% of the whole body cancers and only 3% of those arising in the head and neck region. Primary adenocarcinomas of the sinonasal tract are a heterogeneous group of malignancies, representing 10 to 20% of all primary malignant neoplasms of the nasal cavity and paranasal sinuses¹ and are classified as salivary (5-10%) and non-salivary type². The World Health Organization (WHO) classification of the non-salivary type considers two categories: intestinal-type adenocarcinoma (ITAC) and non-intestinal type adenocarcinoma (n-ITAC)³. The latter is further subdivided into high- and low-grade. Most of the published series focus on ITACs, including homogeneous and relatively large series, describing treatments, outcomes and prognostic factors⁴. ITAC is a professional tumor related with the exposure to wood and leather dust with a peculiar epidemiologic and histopathologic profile and biological behaviour, completely different from the n-ITAC and consequently the two subgroups should be analysed independently. On the contrary, literature focusing on n-ITAC is inadequate and insufficient since most of the studies include all the subtypes of adenocarcinoma⁵ and/or focuses on low-grade tumors⁶ or on the histological profile⁷.

This retrospective study aims to analyse a series of 22 consecutive patients treated with curative intent for sinonasal n-ITAC in two tertiary care referral centres. To our best knowledge this is the first series published and the aim of this study is to report the oncological outcomes and prognostic factors of this particular group of patients.

MATERIALS AND METHODS

Patients

After approval by the respective ethics committees, a retrospective review of all patients affected by non-intestinal non-salivary gland tumors (n-ITAC) of the sinonasal tract treated at the Department of Otorhinolaryngology of the University Hospitals of Insubria–Varese and Brescia (Italy) between

April 1997 and October 2016, was carried out. Epidemiological and clinical data, surgical and histological reports, pre- and post-operative radiological images, complications, data on adjuvant therapy and follow-up information were reviewed.

The extension of the neoplasm was assessed pre-operatively by clinical, endoscopic and radiological examinations, in particular with a multiplanar computer tomography (CT) and contrast enhanced magnetic resonance (MR). After imaging evaluation, multiple biopsies under endoscopic control were performed in local anaesthesia. In cases of histological analysis performed elsewhere, a revision of the pathological slides was performed at our institutions. The presence of local or distant metastases was assessed with a total body contrast enhanced CT scan and a neck ultrasound. Treatment planning was discussed by the local multidisciplinary team of the 2 centres, based on a common management strategy. Only patients treated with radical intent were included in our survey. All patients in the series were retrospectively staged, using clinical, radiologic, and histopathological evaluations, according to the 2016 Union for International Cancer Control (UICC) TNM classification (eight edition)⁸.

Treatment

Surgical planning was tailored according to the tumour extension, patient comorbidity and performance status. Surgical options included: exclusive endoscopic resection (ER), endoscopic resection with transnasal craniectomy (ERTC), and an endoscopic endonasal procedure combined with an external approach (frontal osteoplastic flap approach, OPF; or cranoendoscopic resection CER). Tumors limited to the paranasal sinuses without any involvement of the orbit and/or anterior skull base were treated with ER, tumors in contact with or involving limited infiltration of the anterior skull base, focal infiltration of the dura, with or without limited intradural extension, were considered indications for ERTC, which included the resection of the anterior skull base extending between the two *laminae papyraceae* and from the posterior wall of the frontal sinus to the *planum sphenoidalis*, the overlying dura, and olfactory bulbs and tracts. In cases of unilateral lesions in

focal contact with the anterior skull base, the ERTC procedure was limited to the affected side. When the medial wall of the maxillary sinus was involved, an endoscopic medial maxillectomy was performed, with or without the resection of the nasolacrimal duct, according to the extension of the neoplasm. CER was indicated in cases of infiltration of the dura far over the orbital roof, or extensive infiltration in the brain. The contraindications to the endoscopic approach were the extension to the nasal floor or nasal bones, to the anterior or lateral wall of the maxillary sinus, the extensive involvement of the lacrimal pathway (except the nasolacrimal duct), and invasion of the orbital fat. In all cases, surgical margins were carefully examined intra-operatively with frozen sections and the surgical procedure was continued until histological clear margins were achieved or until further resection was impossible regardless of the surgical approach. The specific surgical techniques of the different approaches are detailed elsewhere⁹⁻¹².

All patients scheduled for a purely endoscopic endonasal approach were informed about the possibility of intra-operative switching to a cranio-endoscopic resection. After surgery, a brain CT scan was performed on the first post-operative day for all patients who had undergone skull base reconstruction, in order to rule out intracranial complications and to evaluate the extent of pneumocephalus. Nasal packing was removed within 48 hours. Intravenous third-generation cephalosporin was started the day before surgery and continued for at least 5 days.

Postoperative treatments included adjuvant radiotherapy (RT) in case of close or positive surgical margins, high grade tumors or even when the tumor was radically removed but involved critical regions, such as frontal sinus, sphenoid sinus, anterior skull base (with or without dural infiltration), lamina papyracea or periorbit, and nasopharynx.

The postoperative RT was delivered using the 3D conformal RT or intensity-modulated RT. The clinical target volume usually consisted in the whole resection cavity and involved subsites.

Follow-up

Postoperative follow-up was performed with nasal endoscopy every 15 days until the complete healing of the surgical cavity, then every 2 months during the first year, every 4 months during the second year, and every 6 months thereafter. Postoperative MR with gadolinium was performed after 4 months from surgery and thereafter every 6 months. A systemic staging consisting of total body positron emission tomography-CT scan and neck ultrasound were performed once a year. No patient was lost during the follow-up. The study met the approval of the local board of medical ethics.

Statistical analysis

All data were collected and processed with a commercially available computer software package (SPSS for Windows, version 19, 2010; SPSS, Chicago, IL). The estimated distribution of the overall survival (OS), disease-specific survival (DSS), and recurrence-free survival (RFS) were calculated using the Kaplan–Meier method. Multivariate analysis of survival was carried out using an explorative Cox proportional hazard model (p values < 0.05 were considered significant).

RESULTS

A total of 22 patients fulfilled the inclusion criteria of this study. A slight female predominance was found since 9 patients were men (40.9%) and 13 women (59.1%) with a male/female ratio of 0.69. The mean age was 63.5 years (range: 33-82). No clear evidence of occupational predisposing factors was found, and the patients included were housewives in 5 cases, office workers in 9 cases, artisans in 3 cases (1 case working with aluminium, 1 with glass and the last one with wood), hairdressers in 2 cases, bricklayer in 1 case and farmers in 2. Four patients (18.1%) had been treated previously: 2 patients with endoscopic transnasal debulking, 1 patient with radiotherapy and the last

one with chemo-radiotherapy.

There were no asymptomatic patients. Unilateral nasal obstruction was the most frequently represented symptom, reported in 15 of the 22 patients (68.2%), whereas epistaxis, rhinorrhoea and anosmia were observed in 12 (54.5%), 7 (31.8%) and 9 (40.9%) of the 22 patients, respectively. Headache or facial pain was reported in 4 of the 22 patients. No patients reported facial swelling or signs of orbital involvement, such as diplopia, epiphora or visual loss.

The origin of the tumor was the ethmoid in 17 of the 22 cases (77.3%), the nasal fossa in 3 (13.6%), the nasal septum in 1 (4.5%) and the sphenoidal sinus in 1 (4.5%). Half of the lesions were on the left side and half on the right. The tumors were staged according to the 2016 UICC TNM classification (eighth edition)⁸ as follows: 5 patients with pT1 (22.7%), 4 patients with pT2 (18.2%), 6 patients with pT3 (27.3%), 3 patients with pT4a (13.6%), and 4 patients with pT4b (18.2%). Concerning the grade of differentiation, 13 tumours were low-grade (59.1%), and 9 high-grade (40.9%). None of the patients in this series had regional or distant metastases at the time of diagnosis.

All 22 patients were treated surgically: 12 patients (54.6%) were managed with ER (4 T1, 3 T2, 2 T3, 2 T4a for sphenoid sinus involvement and 1 T4b for nasopharynx involvement), 7 patients (31.8%) underwent ERTC (1 T1, 1 T2, 3 T3, 1 T4a and 1 T4b) and 3 patients (13.6%) were treated with CER (1 T3 and 1 T4b). In all cases, a free-margin resection (R0) was achieved, except in 2 patients (9.1%) in whom the definitive histology highlighted a microscopic invasion of the margins (R1) in sites not amenable for further surgical resection (brain parenchyma, orbital apex, or cavernous sinus). None of the patients received elective neck dissection. Mean hospitalization time was 7 days (range: 1–16 days). Major post-operative complications occurred only in 1 patient (4.5%) who had been submitted to ERTC and who presented a cerebrospinal fluid leak, which was solved by maintaining lumbar drainage for 5 days. Minor post-operative complications occurred in 2 patients (9.1%) who presented a frontal mucocele and a seroma of the thigh (fascia donor site)

after ER and CER, respectively.

Adjuvant treatment was delivered in 13 patients (59.0%). Eleven patients (50.0%) were treated with adjuvant RT: 7 tumours were high-grade: 1 T1, 2 T2, 2 T3 and 2 T4 and the remaining 4 tumours were low-grade (3 staged T4 and 1 T3). One of the two patients with positive margins was treated with adjuvant chemoradiotherapy and the other with palliative chemotherapy since no further radiotherapy was indicated due to the previous treatment. Stage, treatment and follow-up are summarized in **Table 1**.

Follow-up ranged between 7 and 189 months (mean: 77 months) and no patient was lost. The 2 patients (9.1%) with positive surgical margins (R1) were both staged T4b G3 and died of disease after 70 and 10 months, respectively. During the follow-up, 2 of the 22 patients (9.1%) experienced recurrence of disease; one case was a pT3 G1 of the right ethmoid sinus treated with a radical surgical resection without adjuvant radiotherapy, because of previous radiotherapy treatment. In this case, the relapse occurred in the ipsilateral maxillary sinus at 25 months; this patient was treated with an endoscopic transnasal revision surgery and is NED after 48 months. The second case was a pT4b G3 of the right ethmoid treated with a cranoendoscopic resection with positive surgical margins (R1) and post-operative chemioradiation; after 38 months, this patient had a neck recurrence treated with neck dissection and radiotherapy, but died from distant metastases 70 months after the first treatment. One patient had a persistent intracranial malignancy that was treated with palliative intent. At the time of the analysis, 18 of the 22 patients (81.8%) were alive with no evidence of disease (NED), 2 of the 22 patients (9.1%) died of disease (DOD), whereas another 2 (9.1%) died of other causes (DOC) unrelated to the tumor. The details on treatment and follow-up of patients who experienced persistent or recurrent disease are summarized in **Table 2**.

Adjuvant radiotherapy was administered for stage T4 or grade G3 and selected T3. Six patients were staged as T3 tumors, all treated with microscopic free-margin resection; 3 cases were treated with adjuvant radiotherapy (1 case G1 and 2 cases G3), 2 of whom are NED after 93 and 55 months and the third died of other causes unrelated with the tumour after 127 months without local,

regional or distant recurrences. Three cases, all with G1 grade, did not receive adjuvant radiotherapy and are NED after 53, 48 and 27 months (average 42.7 months), respectively; one case, which was pre-operatively irradiated, after 25 months reported a local relapse that was surgically resected with R0 margins and then he was NED after 48 months from the primary tumour.

In this present series, the 5-year OS and DSS were $95.2 \pm 4.65\%$, and the 5-year RFS was $90.4 \pm 6.45\%$ (see Figure 1). When pT1, pT2 and pT3 versus pT4a/pT4b tumors were compared, the 5-year OS and DSS were 100% for pT1-2-3 and $83.3 \pm 1.52\%$ for pT4a/pT4b ($p=0.037$ and 0.407 , respectively). The 5-year RFS was $92.9 \pm 0.68\%$ for pT1-2-3 and $85.7 \pm 1.32\%$ for pT4a/pT4b ($p=0.51$). The low and high grade were compared and the 5-year OS and DSS were 100% for G1 and 87.5 ± 1.17 for G3 ($p=0.041$), and the 5-year RFS was $91.7 \pm 7.98\%$ for G1 and 88.9 ± 1.05 for G3 ($p=0.746$). The group with negative surgical margins was compared with the group with positive surgical margins and the 5-years OS and DSS were 100% for the negative and 50 ± 3.54 for the positive surgical margins ($p<0.001$) and the 5-year RFS was $94.4 \pm 0.54\%$ for G1 and 50 ± 3.54 for G3 ($p=0.019$). The survival rates are detailed in Table 3.

A multivariate analysis was performed comparing the OS between sexes (men vs women), pT classification (pT1–pT2–pT3 vs pT4a/b), surgical approach (exclusive endoscopic resection with or without transnasal craniectomy vs cranioendoscopic resection), surgical margins (negative vs positive), and grading (G1 vs G3). Results of the Cox proportional hazards analysis are reported in **Table 4**.

DISCUSSION

This retrospective study reports the treatment and outcomes of a uniform cohort of 22 patients affected by sinonasal non-salivary non-intestinal type adenocarcinoma (n-ITAC) and treated with endoscopic transnasal surgical resection. To the best of our knowledge there are no

reports in the literature specifically focusing on n-ITAC. Our study includes a relatively large sample of patients from two Italian tertiary centres with the same policy in terms of diagnostic and therapeutic management of sinonasal cancers. The uniformity of the sample is the strength of this study although it is a retrospective analysis.

N-ITACs is a diagnosis for exclusions since they are defined as adenocarcinoma without the histopathologic features of either sinonasal intestinal type adenocarcinoma or salivary type adenocarcinoma¹³. Low-grade exhibit varied architectural forms with exophytic papillae and tubular or glandular pattern with a low grade cytology, round and uniform nuclei and very rare mitotic figures. They are positive for CK7 and S-100 and negative for CK20, MUC2 (Mucin 2), and CDX2; differently, ITAC subtype will be positive for CK20 and negative for CK7¹⁴. A low-grade subtype arises more frequently in the ethmoidal complex¹⁵, that was the most frequently site of origin of the lesion in our study. It has a more indolent course and has an excellent prognosis with a 5-year survival up to 85%¹⁶. High-grade subtypes have been reported to display a diversity of morphologic patterns such as blastomatous, apocrine, oncocytic/mucinous, poorly differentiated/undifferentiated and others⁶. Even if is reported in literature to develop mainly into the maxillary sinus, in our review the most represented site of origin was the ethmoid for the high and low grade tumors. High-grade tumors have an aggressive course and are associated classically with a poor prognosis with a 3-year survival up to 20%^{6, 15, 16}. This data is coherent with our results since high grade tumors shown a worst prognosis when compared with low grade n-ITACs ($p=0.041$) but the result of the current paper are better then the published literature with a 5-years OS and DSS of 100% for low grade and 87.5 ± 1.17 for high grade. The grade was also an independent predictor factor for the OS (Fig.3). The differential diagnosis for low grade n-ITAC should take into account intestinal-type adenocarcinoma, acinic cells carcinoma, oncocytic Schneiderian papilloma and, most rarely, metastatic thyroid papillary carcinoma, whereas for high grade forms include salivary type adenocarcinoma and non-otherwise specified adenocarcinomas (NOS)². A second opinion by an expert pathologist is mandatory before the beginning of any treatment.

While the aetiology of ITAC is known to be related with wood and leather dust¹⁷, no occupational or environmental factors have been shown to have any aetiological correlation with the development of n-ITAC. Furthermore, our series has not shown any correlation with work factors, since none of the patients' history showed clear evidence of exposure to a specific known cancerogenic factor. A different histogenesis of ITAC and n-ITAC have been hypothesized by Choi et al⁷. The authors reported that non-enteric type tumors exclusively manifest CK7 expression, emphasising a direct origin from submucosal seromucous glands or from surface epithelium. N-ITAC is assumed to evolve through neoplastic transformation of the budding ductal formation, even if validation and evidence of such transformation remains unpublished. ITAC, contrariwise, evolves from a metaplasia, as suggested by the histological features and the conversion of CK7 to CK20 in the nasal respiratory-type mucosa¹⁸. These data support the hypothesis that ITAC and n-ITAC are different diseases that should be analysed independently.

According to the literature, the median age of presentation is about V decades and there is prevalence of the male gender, in particular for high-grade group. In our study the median age was about VI decades and there was predominance of the female gender.

To the best of our knowledge, only large studies including both ITAC and n-ITAC are present in the literature: Choussy et al.¹⁹ considered 418 patients and reported a 5-year OS of 64%; Bhayani et al.²⁰ considered 66 patients, 31 of whom affected by n-ITAC, and reported a 5-year OS of 65.9%; Orvidas et al.²¹ considered 24 patients, of whom 58% had n-ITAC, and reported a 5-year OS of 58%. The paper by Chen et al⁵ is the only one analysing n-ITAC independently. It reports a DS survival rate of 71.2% in 300 cases of n-ITAC with no differences in terms of survival when compared with 25 cases of ITAC. However, all the other data concerning treatment and follow-up were analysed including the total 325 cases. In our paper we report a 5-year OS and DSS of 95.2% higher than the reported survival concerning both ITAC and n-ITAC. This issue supports the hypothesis that ITAC and n-ITAC should be addressed as completely different diseases also in terms of prognosis, but further studies are needed to compare these two groups.

According to the literature, the mainstay of the treatment is the radical surgical resection of the tumor with or without adjuvant radiotherapy^{5, 19, 20, 22-24}. Craniofacial resection²⁵ has represented for a long time the gold standard procedure for the surgical treatment of sinonasal and skull base cancers^{26, 27} even though it is associated with non negligible mortality (4.7%) and morbidity (36.3%) rates²⁸. For selected tumors, the endoscopic transnasal resection has been proposed as a valid alternative technique, with encouraging outcomes and the advantage of reduced morbidity, and it has been advocated recently as the surgical treatment of choice for ITAC when correctly planned and indicated²⁹. The importance of radical resection, regardless of the surgical approach, cannot be over-emphasized since the presence of positive post-operative margins is the most important prognostic factor. Consequently, open and endoscopic approaches are not in contrast each-others but they should be used to reach the free-margins resection in accordance with the different indications. In our data, the 5-year OS and DSS are 100% in cases of free margins and drops down to 50% \pm 3.54 in cases of positive margins ($p < 0.0001$), regardless of the type of surgery, grade of differentiation or the staging. This is confirmed by the multivariate analysis, where surgical margins emerge as an independent prognostic factor for the OS ($p < 0.0001$, HR 13.2). Conversely, the extent of surgery is not related with the prognosis in multivariate analysis (ER and ERTC versus CER, $p > 0.05$).

Different studies in the literature have suggested the effectiveness of single modality treatment in cases of low-stage lesions^{9, 20, 23, 30}. On the other hand, other studies have advocated post-operative radiotherapy in all cases, regardless of the stage or grade, therefore also for T1 and T2 stages³¹. Our treatment policy is not completely in alignment with these statements and, considering sinonasal n-ITACs, the indication for adjuvant radiotherapy is still questioned in cases of low-stage lesions (pT1-pT2) when surgical clear wide margins are obtained. In these selected patients, we consider radiotherapy only in case of high grade lesions (G3), regardless staging T1 or T2, while we consider radiotherapy as an overtreatment without outcomes improving in case of low stage and low grade lesions (T1-T2 G1). Some authors confirm this statement, reporting no statistical differences in

patients affected by low grade lesions treated with surgery alone or with adjuvant radiotherapy³² In our report a single modality treatment, with surgery alone, was performed in case of radical surgical resection only for low stage and low grade diagnosis. None of them developed recurrence during follow-up and RT in these selected patients could be addressed as an overtreatment.

Bhayani et al. recently demonstrated, in a single-centre study of 66 patients affected by sinonasal adenocarcinoma, how high-staged tumors and cases with sphenoid sinus involvement have worse prognosis ($p < 0.05$ and $p < 0.013$, respectively)²⁰. A large multi-centre series of 418 patients affected by sinonasal adenocarcinoma presented by Choussy et al.¹⁹ showed a poor prognosis for T4 staged lesions, including disease with extension to the sphenoid, orbit, brain and dura ($p < 0.0001$). In alignment with these studies, the adjuvant radiotherapy was administered to all those in our group of patients who were affected by high-staged lesions (T4a and T4b) at the time of the diagnosis. Despite the multimodality treatment, these patients presented worse outcomes; in our study, lesions staged T4a-T4b have a 5-year OS and DSS of $83.3\% \pm 1.52$ whereas T1-2-3 reported 100% ($p = 0.041$)

According to our data, 4 patients with a T3 G1 R0 were included and one of them was treated with adjuvant radiotherapy. A recurrence of disease occurred after 15 months in one patient treated exclusively with radical surgical resection because of previous radiotherapy. Even though our data do not reach any statistical significance due to the small sample of patients, a multimodality treatment seems to be the best option for T3 lesions.

Concerning the histological grade of the tumour, Orvidas et al. reported that patients with high-grade tumors are 5.4 times more likely to die of any cause than patients with low-grade tumours ($p = 0.04$)²¹. In contrast, Choussy et al.¹⁹ report no statistical difference in terms of survival between low grade and high grade lesions, this series evaluated 418 cases and made a comparison between a high grade group, that includes patients affected by ITAC and poorly differentiated adenocarcinoma (248 pt), and a low grade group, that includes well differentiated adenocarcinoma (107 pt). According to the current study, high grade tumors were treated with adjuvant radiotherapy and,

notwithstanding the multimodal treatment, presented a poorer 5-years OS and DSS when compared with low grade tumors (87.5 ± 1.17 and 100% for high grade and low grade respectively, $p = 0.041$)

At present, there are no absolute guidelines establishing the indication for chemotherapy in non-metastatic n-ITAC treatment because of the lack of relevant studies³³.

CONCLUSION

N-ITAC is a rare group of tumor and there are no papers in literature focusing on it. However several papers includes n-ITAC with ITAC but these are different pathologies with different etiopathogenesis, histogenesis, biological behaviour and prognosis. According to the current literature, there is no standardized treatment algorithm for sinonasal n-ITAC, however surgery followed by radiation has remained a mainstay in the management of these tumors. The free margin resection is of utmost importance and the surgical approach must be tailored according to the local extension of the lesion. The endoscopic transnasal approach, when correctly planned and indicated, is the surgery of choice given the low morbidity and mortality. Although comparative studies between the single modality and the multimodality treatments would be desirable, there are limitations in the assessment of this issue due to the rarity of this pathology. Anyway, the indications for post-operative radiotherapy on the tumour bed remain a subject of controversy, it is suggest in case of high staged (T3-T4) and high grade (G3) lesions. N-ITAC presents a favourable outcomes with a 5-year OS of $95.2 \pm 4.65\%$ and the high grade, pT4 stage and positive surgical margins were independent negative prognostic factors.

1. Barnes L. Intestinal-type adenocarcinoma of the nasal cavity and paranasal sinuses. *The American journal of surgical pathology*. Mar 1986;10(3):192-202.
2. Leivo I. Sinonasal Adenocarcinoma: Update on Classification, Immunophenotype and Molecular Features. *Head Neck Pathol*. Mar 2016;10(1):68-74.

3. El-Naggar AK, Chan JKC, Grandis JR, Takata T, Slootweg PJ. *WHO Classification of Head and Neck Tumours*: International Agency for Research on Cancer; 2017.
4. Fiaux-Camous D, Chevret S, Oker N, et al. Prognostic value of the seventh AJCC/UICC TNM classification of intestinal-type ethmoid adenocarcinoma: Systematic review and risk prediction model. *Head & neck*. Jan 09 2017.
5. Chen MM, Roman SA, Sosa JA, Judson BL. Predictors of Survival in Sinonasal Adenocarcinoma. *Journal of neurological surgery. Part B, Skull base*. Jun 2015;76(3):208-213.
6. Stelow EB, Jo VY, Mills SE, Carlson DL. A histologic and immunohistochemical study describing the diversity of tumors classified as sinonasal high-grade nonintestinal adenocarcinomas. *The American journal of surgical pathology*. Jul 2011;35(7):971-980.
7. Choi HR, Sturgis EM, Rashid A, et al. Sinonasal adenocarcinoma: evidence for histogenetic divergence of the enteric and nonenteric phenotypes. *Human pathology*. Nov 2003;34(11):1101-1107.
8. Brierley JD, Gospodarowicz MK, Wittekind C. *TNM Classification of Malignant Tumours*: Wiley; 2016.
9. Nicolai P, Castelnuovo P, Lombardi D, et al. Role of endoscopic surgery in the management of selected malignant epithelial neoplasms of the naso-ethmoidal complex. *Head & neck*. Dec 2007;29(12):1075-1082.
10. Nicolai P, Battaglia P, Bignami M, et al. Endoscopic surgery for malignant tumors of the sinonasal tract and adjacent skull base: a 10-year experience. *American journal of rhinology*. May-Jun 2008;22(3):308-316.
11. Villaret AB, Yakirevitch A, Bizzoni A, et al. Endoscopic transnasal craniectomy in the management of selected sinonasal malignancies. *American journal of rhinology & allergy*. Jan-Feb 2010;24(1):60-65.
12. Castelnuovo P, Battaglia P, Locatelli D, Delu G, Sberze F, Bignami M. Endonasal micro-endoscopic treatment of malignant tumors of the paranasal sinuses and anterior skull base. *Operative Techniques in Otolaryngology-Head and Neck Surgery*. 2006;17(3):152-167.
13. Barnes L, Organization WH, Cancer IAfRo. *Pathology and Genetics of Head and Neck Tumours*: IARC Press; 2005.
14. Bhajee F, Carron J, Bell D. Low-grade nonintestinal sinonasal adenocarcinoma: a diagnosis of exclusion. *Ann Diagn Pathol*. Jun 2011;15(3):181-184.
15. Heffner DK, Hyams VJ, Hauck KW, Lingeman C. Low-grade adenocarcinoma of the nasal cavity and paranasal sinuses. *Cancer*. Jul 15 1982;50(2):312-322.
16. Knecht PP, Ah-See KW, vd Velden LA, Kerrebijn J. Adenocarcinoma of the ethmoidal sinus complex: surgical debulking and topical fluorouracil may be the optimal treatment. *Archives of otolaryngology--head & neck surgery*. Feb 2001;127(2):141-146.
17. Bonzini M, Battaglia P, Parassoni D, et al. Prevalence of occupational hazards in patients with different types of epithelial sinonasal cancers. *Rhinology*. Mar 2013;51(1):31-36.
18. Slack JM, Tosh D. Transdifferentiation and metaplasia--switching cell types. *Curr Opin Genet Dev*. Oct 2001;11(5):581-586.
19. Choussy O, Ferron C, Vedrine PO, et al. Adenocarcinoma of Ethmoid: a GETTEC retrospective multicenter study of 418 cases. *The Laryngoscope*. Mar 2008;118(3):437-443.
20. Bhayani MK, Yilmaz T, Sweeney A, et al. Sinonasal adenocarcinoma: a 16-year experience at a single institution. *Head & neck*. Oct 2014;36(10):1490-1496.
21. Orvidas LJ, Lewis JE, Weaver AL, Bagniewski SM, Olsen KD. Adenocarcinoma of the nose and paranasal sinuses: a retrospective study of diagnosis, histologic characteristics, and outcomes in 24 patients. *Head & neck*. May 2005;27(5):370-375.
22. Turner JH, Reh DD. Incidence and survival in patients with sinonasal cancer: a historical analysis of population-based data. *Head & neck*. Jun 2012;34(6):877-885.

23. Lund VJ, Chisholm EJ, Takes RP, et al. Evidence for treatment strategies in sinonasal adenocarcinoma. *Head & neck*. Aug 2012;34(8):1168-1178.
24. Vergez S, du Mayne MD, Coste A, et al. Multicenter study to assess endoscopic resection of 159 sinonasal adenocarcinomas. *Ann Surg Oncol*. Apr 2014;21(4):1384-1390.
25. Ketcham AS, Wilkins RH, Vanburen JM, Smith RR. A Combined Intracranial Facial Approach to the Paranasal Sinuses. *American journal of surgery*. Nov 1963;106:698-703.
26. Ganly I, Patel SG, Singh B, et al. Craniofacial resection for malignant paranasal sinus tumors: Report of an International Collaborative Study. *Head & neck*. Jul 2005;27(7):575-584.
27. Patel SG, Singh B, Stambuk HE, et al. Craniofacial surgery for esthesioneuroblastoma: report of an international collaborative study. *Journal of neurological surgery. Part B, Skull base*. Jun 2012;73(3):208-220.
28. Ganly I, Patel SG, Singh B, et al. Complications of craniofacial resection for malignant tumors of the skull base: report of an International Collaborative Study. *Head & neck*. Jun 2005;27(6):445-451.
29. Nicolai P, Schreiber A, Bolzoni Villaret A, et al. Intestinal type adenocarcinoma of the ethmoid: Outcomes of a treatment regimen based on endoscopic surgery with or without radiotherapy. *Head & neck*. Apr 2016;38 Suppl 1:E996-E1003.
30. de Gabory L, Maunoury A, Maurice-Tison S, et al. Long-term single-center results of management of ethmoid adenocarcinoma: 95 patients over 28 years. *Ann Surg Oncol*. Apr 2010;17(4):1127-1134.
31. Bogaerts S, Vander Poorten V, Nuyts S, Van den Bogaert W, Jorissen M. Results of endoscopic resection followed by radiotherapy for primarily diagnosed adenocarcinomas of the paranasal sinuses. *Head & neck*. Jun 2008;30(6):728-736.
32. Turri-Zanoni M, Battaglia P, Lambertoni A, et al. Treatment strategies for primary early-stage sinonasal adenocarcinoma: A retrospective bi-institutional case-control study. *J Surg Oncol*. Oct 2015;112(5):561-567.
33. Lund V, Howard DJ, Wei WI. Endoscopic resection of malignant tumors of the nose and sinuses. *American journal of rhinology*. Jan-Feb 2007;21(1):89-94.

Table 1. pT classification (2016 Union for International Cancer Control (UICC) TNM classification

- eight edition), primary site of origin, grading, and surgical margins in the patients enrolled.. ER: endoscopic resection; ERTC: endoscopic resection with transnasal craniectomy; CER: combined transcranial-transnasal resection; NER: nasopharyngeal endoscopic resection; RT: radiotherapy; NED: no evidence of disease; DOC died for other cause; DOD: died for disease.

Table 2. Pattern of failure. pT, T classification according to the 2016 Union for International

Cancer Control (UICC) TNM classification (eight edition);P: persistence, DM: distant metastases, LR: local recurrence; CHT: chemotherapy; RT radiotherapy; ER: endoscopic resection; ERTC: endoscopic resection with transnasal craniectomy; CER: combined transcranial-transnasal

resection; NER: nasopharyngeal endoscopic resection; RT: radiotherapy; NED: no evidence of disease; DOC died for other cause; DOD: died for disease.

Table 3. Survival rates of the cohort and according to pT classification, margins and grading of the tumor. Abbreviations: OS, overall survival; DSS, disease-specific survival; RFS, recurrence-free survival; pT, T classification according to the 2016 Union for International Cancer Control (UICC) TNM classification (eight edition); N/A, not applicable.

Table 4. Mutivariate analysis. (overall survival). EER: endoscopic endonasal resection with or without craniectomy; CER combined transcranial-transnasal resection

FIG.1 Overall (A), disease specific (B) and recurrence free (C) survival of the enrolled population

FIG.2 Overall (A), disease specific (B) and recurrence free (C) survival of the enrolled population depending on pT stage

FIG.3 Overall (A), disease specific (B) and recurrence free (C) survival of the enrolled population depending on grading

FIG.4 Overall (A), disease specific (B) and recurrence free (C) survival of the enrolled population depending on surgical margins

A - Low Grade 13/22								
pT	N°	Origin	Type of Surgery	Adjuvant Treatment	Margins	Status	Follow Up (median, months)	Recurrences/relapses
T1	4	3 Ethmoid 1 Nasal Fossa	4 ER	NO	4 R0	4 NED	69.25	0
T2	2	1 Ethmoid 1 Nasal Fossa	2 ER	NO	2 R0	2 NED	179.50	0
T3	4	3 Ethmoid 1 Nasal Fossa	2 ER 1 ERTC 1 CER	1 RT	4 R0	3 NED 1 DOC	63.75	1 on T
T4a	2	1 Ethmoid 1 Nasal Fossa	2 ER	2 RT	2 R0	1 NED 1 DOC	99.50	0
T4b	1	1 Ethmoid	1 CER	1 RT	1 R0	1 NED	136	0
B - High Grade 9/22								
pT	N°	Origin	Type of Surgery	Adjuvant Treatment	Margins	Status	Follow Up (median, months)	Recurrences/relapses
T1	1	1 Ethmoid	1 ERTC	1 RT	1 R0	1 NED	77.31	0
T2	2	2 Ethmoid	1 ER 1 ERTC	2 RT	2 R0	2 NED	35.3	0
T3	2	2 Ethmoid	2 ERTC	2 RT	2 R0	2 NED	73.96	0
T4a	1	1 Olfactory Fissure	1 ERTC	1 RT	1 R0	1 NED	7.16	0
T4b	3	2 Ethmoid 1 Olfactory Fissure	1 ER+NER 1 ERTC 1 CER	2 RT	2 R1 1 R0	2 DOD 1 NED	39.07	1 on T 1 on T and N

Table 1 – pT classification (2016 Union for International Cancer Control (UICC) TNM classification - eight edition), primary site of origin, grading, and surgical margins in the patients enrolled.. ER: endoscopic resection; ERTC: endoscopic resection with transnasal craniectomy; CER: combined transcranial-transnasal resection; NER: nasopharyngeal endoscopic resection; RT: radiotherapy; NED: no evidence of disease; DOC died for other cause; DOD: died for disease.

ID	Type of recurrence	Previous Treatments	pT/Grading	Type of Surgery	Adjuvant Treatment	Time to relapse (months)	Site of Recurrence/Persistence	Treatment of recurrence	Follow up after recurrence	
									Months	Status
1	P - DM	Endoscopic Debulking	pT4b/G3	ERTC	RT	38	Neck/ Intracranial- Intraorbital	Neck dissection + RT	32	DOD
2	P	CHT-RT	pT4b/G3	CER	-	0	Intracranial- Intraorbital	-	10	DOD
3	LR	RT	pT3/G1	ER	-	25	Maxillary sinus	ER	23	NED

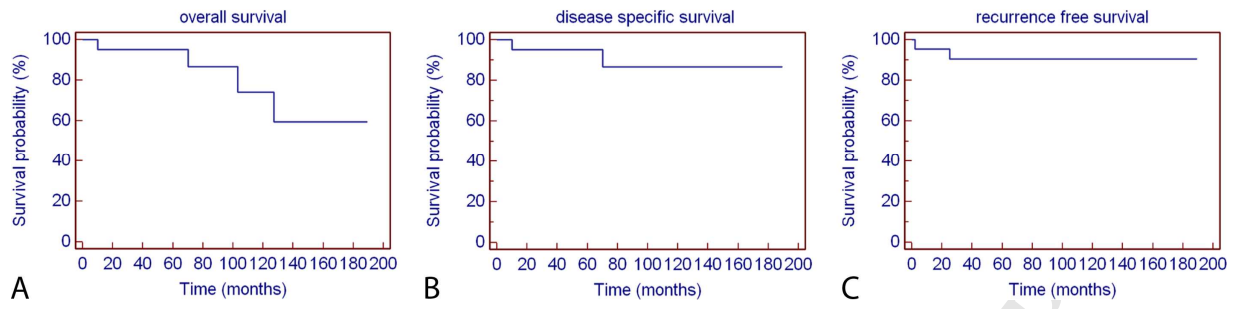
Table 2: Pattern of failure. pT, T classification according to the 2016 Union for International Cancer Control (UICC) TNM classification (eight edition); P: persistence, DM: distant metastases, LR: local recurrence; CHT: chemotherapy; RT radiotherapy; ER: endoscopic resection; ERTC: endoscopic resection with transnasal craniectomy; CER: combined transcranial-transnasal resection; NER: nasopharyngeal endoscopic resection; RT: radiotherapy; NED: no evidence of disease; DOD died for other cause; DOD: died for disease.

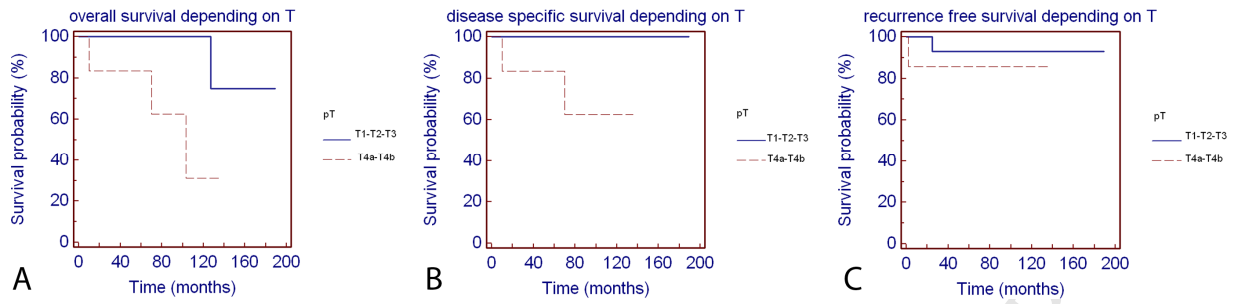
	5-y OS	p value OS	5-y DSS	p value DSS	5-y RFS	p value RFS
All Patients	95.2 ± 4.65	N/A	95.2 ± 4.65	N/A	90.4 ± 6.45	N/A
pT						
T1/2/3	100	0.041	100	0.041	92.9 ± 0.68	0.510
T4a/b	83.3 ± 1.52		83.3 ± 1.52		85.7 ± 1.32	
Grading						
Low grade	100	0.041	100	0.041	91.7 ± 7.98	0.746
High grade	87.5 ± 1.17		87.5 ± 1.17		88.9 ± 1.05	
Margins						
Positive	50.0 ± 3.54	<0.001	50.0 ± 3.54	<0.001	50.0 ± 3.54	0.018
Negative	100		100		94.4 ± 0.54	

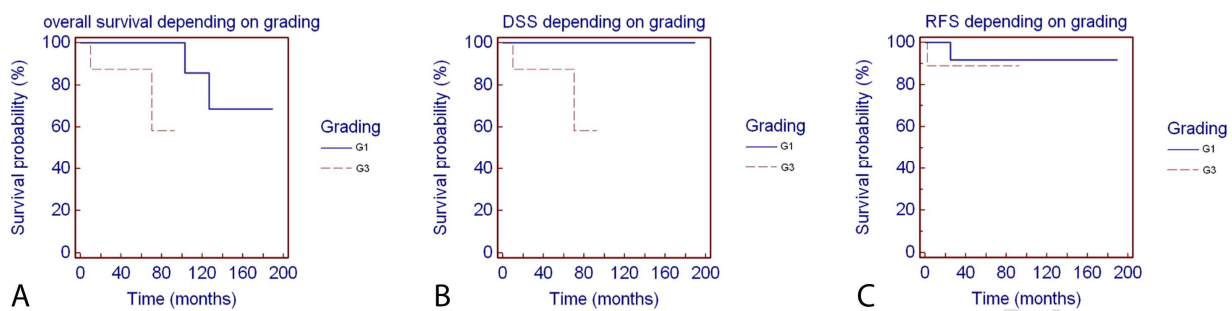
Table 3 Survival rates of the cohort and according to pT classification, margins and grading of the tumor. Abbreviations: OS, overall survival; DSS, disease-specific survival; RFS, recurrence-free survival; pT, T classification according to the 2016 Union for International Cancer Control (UICC) TNM classification (eight edition); N/A, not applicable.

	HR	P-value
Gender (M vs F)	0,21	0,10
pT1-T2-T3 vs pT4a-T4b	2,45	0,045 *
Surgical margins	13,2	0,0001 *
Grading	2,61	0,04 *
EER vs CER	0,35	0,24

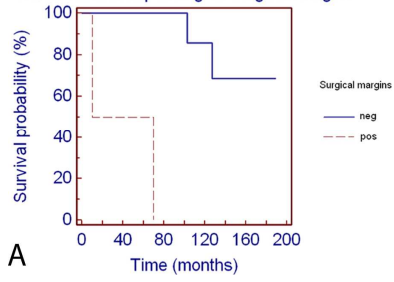
Table 4 Mutivariate analysis. (overall survival). EER: endoscopic endonasal resection with or without craniectomy; CER combined transcranial-transnasal resection





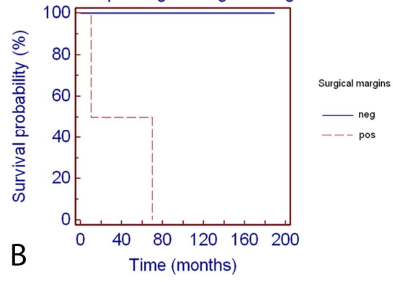


overall survival depending on surgical margins



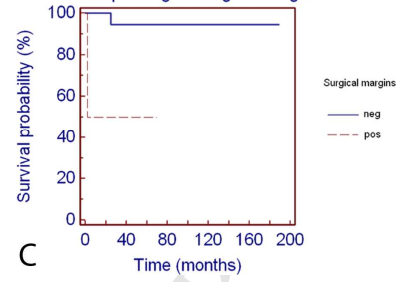
A

DSS depending on surgical margins



B

RFS depending on surgical margins



C

ACCEPTED MANUSCRIPT

HIGHLIGHTS:

- Intestinal-type and non-intestinal-type adenocarcinomas are different diseases that should be analysed independently.
- Surgery followed by radiation has remained a mainstay in the management of non-intestinal-type adenocarcinomas.
- The free-margins resection is of utmost importance regardless the surgical approach.
- The endoscopic transnasal approach, when correctly planned and indicated, is the surgery of choice given the low morbidity and mortality.

ABBREVIATIONS LIST:

CER: crano-endoscopic resection

CT: computer tomography

DOC: died of other causes

DOD: died of disease

DSS: disease specific survival

ER: endoscopic resection

ERTC: endoscopic resection with transnasal craniectomy

ITAC: intestinal type adenocarcinomas

MR: magnetic resonance

NED: not evidence of disease

n-ITAC: non-salivary non-intestinal type adenocarcinomas

OPF: frontal osteoplastic flap

OS: overall survival

RFS: recurrence free survival

RT: radiotherapy

UICC: Union for International Cancer Control