

Effect of genotype, gender and feed restriction on growth, meat quality and the occurrence of white striping and wooden breast in broiler chickens

A. Trocino,^{*,1} A. Piccirillo,^{*} M. Birolo,[†] G. Radaelli,^{*} D. Bertotto,^{*} E. Filiou,[†] M. Petracci,[‡]
and G. Xiccato[†]

^{*}Department of Comparative Biomedicine and Food Science (BCA), University of Padova, Viale dell'Università 16, I-35020 Legnaro, Padova, Italy; [†]Department of Agronomy Food Natural Resources Animal and Environment (DAFNAE), University of Padova, Viale dell'Università 16, I-35020 Legnaro, Padova, Italy; and [‡]Department of Agricultural and Food Sciences, Alma Mater Studiorum, University of Bologna, I-47521 Cesena, Forlì Cesena, Italy

ABSTRACT Due to their importance for the control of meat quality in broiler chickens, the present study aimed at identifying the factors associated with the occurrence of myopathies and characterizing the meat properties when affected by myopathies. To this aim, a total of 768 broiler chickens were reared until slaughter (46 d) to evaluate the effect of genotype, gender, and feeding regime (ad libitum vs. restricted rate, 80% from 13 to 21 d of age) on performance and meat quality. Standard broilers were heavier (3,270 vs. 3,139 g; $P < 0.001$) and showed lower feed conversion (1.56 vs. 1.61; $P < 0.001$) than the high-yield broilers. Males showed higher final live weight (3,492 vs. 2,845 g) and lower feed conversion (1.54 vs. 1.63) than females ($P < 0.001$). Feed restriction decreased final live weight (3,194 vs. 3,142 g; $P < 0.01$) and feed conversion (1.60 vs. 1.57; $P < 0.01$) compared to ad libitum feeding.

At gross examination, feed restriction tended to increase white-striped breasts (69.5 vs. 79.5%; $P < 0.10$), whereas females showed less wooden breasts than males (8.0 vs. 16.3%; $P < 0.05$). White-striped fillets had higher pHu (5.87 vs. 5.83), and lower a* (−0.81 vs. −0.59) and b* color indexes (13.7 vs. 14.5) ($P < 0.05$), whereas wooden breast fillets exhibited higher cooking losses (25.6 vs. 22.1%) and AK-shear force (4.23 vs. 2.84 kg/g) compared with normal fillets ($P < 0.001$). At histological examination, 3.1% of pectoralis major were normal, 26.6% mildly degenerated, 45.3% moderately degenerated, and 25.0% severely degenerated. In conclusion, genotype had a moderate effect on growth without modifying myopathy occurrence. In contrast, gender and feed restriction affected performance, meat quality, and breast abnormalities.

Key words: growth, meat quality, myopathies, histology

2015 Poultry Science 94:2996–3004
<http://dx.doi.org/10.3382/ps/pev296>

INTRODUCTION

Poultry production is based on intensive farming systems using fast-growing genetic lines with high breast muscle yield, which provide products of constant quality (Petracci et al., 2014). Consumers value the satisfying sensory and nutritional properties of poultry meat, but they are increasingly concerned about the intensive production systems (Cavani et al., 2009; Petracci et al., 2014). In fact, animal welfare is considered at risk because intensive rearing conditions and behavioral constraints may induce stress and challenge the health of broilers, which show skeletal abnormalities causing lameness, contact dermatitis, ascites and metabolic disorders (De Jong et al., 2012). These conditions are

dependent on management conditions and may vary by genotype.

The general negative position towards a too high selective trend is made even more severe by the latest findings about the correlation between high growth rate and high breast yield and the occurrence of myopathies affecting pectoralis major and other muscles, i.e., white striping and wooden breast (Kuttappan et al., 2012a, 2013a; Lorenzi et al., 2014; Sihvo et al., 2014). Histologically, white striping has been defined as a degenerative myopathy of breast muscles (Kuttappan et al., 2013b), inducing alterations in nutritional and technological properties of meat (Mazzoni et al., 2015; Mudalal et al., 2015), and affecting negatively the consumer preference and choice (Kuttappan et al., 2012b). In addition, wooden breast has been associated with polyphasic myodegeneration with regeneration and accumulation of interstitial connective tissue or fibrosis (Sihvo et al., 2014), causing negative changes in technological properties of breast fillets (Mudalal et al., 2015).

© 2015 Poultry Science Association Inc.

Received February 19, 2015.

Accepted August 27, 2015.

¹Corresponding author: angela.trocino@unipd.it

Feeding strategies may be used to control the occurrence of myopathies in broiler chickens: low-energy diets reduce both growth rate and the occurrence of white striping (Kuttappan et al., 2012a). Similarly, feed restriction may reduce the incidence of myopathy by controlling the early growth and the occurrence of metabolic diseases (De Jong et al., 2012; Sahraei, 2012; Butzen et al., 2013).

Confirming the correlations between growth rate and myopathies (e.g., white striping and/or wooden breast), identifying the factors associated with their occurrence, and characterizing the meat properties of affected muscle are essential in controlling meat quality.

Therefore, the present study aimed at evaluating whether feeding birds ad libitum or at a restricted rate during the first growth period (from 13 to 21 d of age) may affect performance, meat quality, and the occurrence of white striping and wooden breast in broilers belonging to two genetic lines, selected for standard or high breast yield, and to both genders. Furthermore, meat quality of normal broilers and broilers affected by white striping and wooden breast were compared.

MATERIALS AND METHODS

Experimental Facilities

The trial was performed at the poultry house of the Experimental Farm “Toniolo” of the University of Padova (Legnaro, Padova, Italy) during the period June to July 2014, after a long period of downtime (6 months). The poultry house was equipped with a cooling system, forced ventilation, radiant heating and controlled light systems. Thirty-two wire-net pens (125 cm wide × 177 cm length × 120 cm height; 2.2 m²) were available, each equipped with an automatic circular drinker (diameter: 39 cm) and a circular feeder (diameter: 37 cm) for manual distribution of feed. The pens had a concrete floor bedded by wood shavings litter (height 5 cm, 2.5 kg/m²).

Twenty-four hours of light were provided during the first 2 d after chicks arrival; afterward, hours of lights were progressively reduced to reach and maintain a 18L:6D light program from the d 12 onward.

Animals, Experimental Groups, and In Vivo Recordings

A total of 768 broilers were used for the specific aims of the present study, delivered by authorized transport means at the experimental facilities of the University on the hatching day. Half of the chicks (384) belonged to a high-breast-yield hybrid; the other half were from a standard-breast-yield genotype, and both were sexed. All chicks had been vaccinated against Marek's disease, Infectious Bronchitis, and Newcastle disease at the hatchery. At their arrival, 24 chicks per pen were

housed, randomly allocated to 8 experimental groups, i.e. 2 genotypes × 2 genders × 2 feeding plans (ad libitum vs. restricted), and controlled from the day after their arrival until slaughtering at 46 d of age. Chicks were individually weighed the day after their arrival, identified by a leg mark, and controlled for live weight once a week until slaughtering. Pen feed consumption was measured daily during the trial. A total of 5.2% losses were recorded during the trial, of which 3.5% were due to mortality and 1.7% were due to birds culled before slaughtering because of lameness.

Diets and Feeding Plans

Four commercial diets were administered during the trial, i.e., diet P1 (crude protein 22.2%, ether extract 7.90%; crude fiber 2.60%, calcium 1.00%, and phosphorus 0.70%) from 0 to 12 d, diet P2 (crude protein 20.8%, ether extract 8.50%; crude fiber 2.50%, calcium 1.00%, and phosphorus 0.65%) from 13 to 21 d, diet P3 (crude protein 19.0%, ether extract 8.10%; crude fiber 2.50%, calcium 0.95%, and phosphorus 0.60%) from 22 to 35 d and diet P4 (crude protein 17.4%, ether extract 8.80%; crude fiber 2.40%, calcium 0.80%, and phosphorus 0.60%) from 35 d until slaughtering. Diets were produced by a commercial feed mill (Mangimificio Settecolli, Montegalda, Vicenza, Italy). Half of the pens were fed ad libitum during the experimental trial, the remaining half were restricted in the period 13 to 21 d of age. The restricted birds received the 80% of the quantity consumed by the broilers fed ad libitum on the previous day. The restriction program was calculated separately on the four groups obtained by the combination of 2 genotypes × 2 genders.

Commercial Slaughtering and Meat Quality Recordings

At 46 d of age, all birds were slaughtered in a commercial slaughterhouse, after about 7 h of feed withdrawal and about 4 h of water withdrawal. Birds were individually weighed before crating. All birds of a pen (i.e. 20 to 24) were loaded in a transport cage (62.6 cm wide × 160 cm long × 25.0 cm high; 1 m²). Loading took about one hour; transport from the experimental facilities to the commercial slaughterhouse about 15 min; lairage before slaughtering about 3 h. Birds were slaughtered according to the standard practice of the commercial slaughterhouse. Ready-to-cook carcasses were recovered after 2 h of refrigeration at 2°C.

A total of 256 carcasses (8 per pen), that had been previously selected on the basis of the slaughter live weight to be representative within a pen, were submitted to gross examination to evaluate the occurrence (presence or absence) and the degree (normal, moderate, severe) of white striping on pectoralis major muscle (Kuttappan et al., 2012b), and the occurrence

(presence or absence) of wooden breast (Sihvo et al., 2014). Macroscopically, pectoralis major muscles affected by wooden breast appeared pale, outbulging, and hardened; the affected areas were covered with petechiae or slightly larger hemorrhagic foci and with a clear viscous fluid; lesions mainly affected the cranial end of breast muscles. Afterwards, out of the 256 carcasses, 128 (4 per pen) were further selected, as representative of the average live weight and variability of each pen, and transported to the Department laboratories to be stored at 2°C before meat quality analyses. Forty-eight hours after slaughter, pectoralis major muscles were separated from the breasts to be submitted to meat quality analyses (Petracci and Baéza, 2011). The pH of the pectoralis major muscles were measured in triplicate on their ventral side with a pH meter (Basic 20, Crison Instruments Sa, Carpi, Italy) equipped with a specific electrode (cat. 5232, Crison Instruments Sa, Carpi, Italy). The L*a*b* color indexes were measured in triplicate in the ventral side of the same muscles covered by a transparent plastic film, using a Minolta CM-508 C spectrophotometer (Minolta Corp., Ramsey, NJ, USA) (Petracci and Baéza, 2011).

Thereafter, one meat portion (8 cm × 4 cm × 3 cm) was separated from the cranial side of pectoralis major, parallel to muscle fiber directions, and stored under vacuum in plastic bags at -18°C until the meat analyses. Thawing and cooking losses were measured in this cut (Petracci and Baéza, 2011). After thawing, the meat portion was put in plastic bags and cooked in a water bath for 45 minutes, until an internal temperature of 80°C was achieved. After a 40-min cooling, a further meat portion (4 cm × 2 cm × 1 cm) was separated to assess the maximum shear force with LS5 dynamometer (Lloyd Instruments Ltd, Bognor Regis, UK) using the Allo-Kramer (10 blades) probe (load cell: 500 kg; distance between the blades: 5 mm; thickness: 2 mm; cutting speed: 250 mm/min) (Mudalal et al., 2015).

Histological Analysis

At the Department laboratories, 64 of the 128 broilers used for meat quality analyses, representative of the average live weight and variability of each pen, were immediately used to sample pectoralis major and pectoralis minor muscles for histological analysis. Samples were fixed in 10% buffered neutral formalin at 4°C overnight, washed in phosphate-buffered saline (PBS, 0.1 M, pH 7.4), dehydrated through a graded series of ethanol and embedded in paraffin. Consecutive sections were cut at a thickness of 4 μm using a microtome and stained with hematoxylin and eosin (H&E) and Masson's Trichrome. H&E staining was employed to evaluate the general morphology of the tissues, whereas Masson's Trichrome (Bancroft and Stevens, 1975) was used to identify the presence of collagen. Following visual examination of the sections with the aid of a light microscope (Olympus Vanox photomicroscope, Japan), an as-

essment of myopathic lesions, lipidosis and fibrosis was made using a score based on a scale ranging from 0 to 3 (0, normal; 1, mild; 2, moderate; 3, severe). In details the score (0) was attributed when samples presented no necrotic fibers, no infiltration of connective tissues, normal or central nuclei; the score (1) was used when samples showed central nuclei, some fibers with hyaline cytoplasm, scarce necrotic fibers, absence of connective tissue infiltration; the score (2) was given when samples diffusely presented necrotic fibers, thickening of interstitial connective tissue, presence of inflammatory cells, and appearance of adipose tissue aggregates; finally, the highest score (3) was attributed to samples that exhibited a great amount of interstitial connective tissue and inflammatory cells, as well as of necrotic fibers and lobules of adipose tissue.

Statistical Analysis

Individual data of initial and final weights and daily growth were analyzed by ANOVA with feeding system, genotype, gender, and their interaction as main factors of variability and with pen as a random effect, by the PROC MIXED of SAS software (SAS Institute, 2009). Cage data for feed intake and feed conversion were analyzed by ANOVA with feeding system, genotype, gender, and their interactions as main factors of variability, and by the PROC GLM (SAS Institute, 2009). Individual data of meat traits were also analyzed by PROC MIXED with myopathies (presence vs. absence of white striping or wooden breast) as main factor of variability and pen as a random effect. The frequency of myopathies was analyzed with the CATMOD PROC (SAS Institute, 2009) according to feeding system, genotype, gender, and their interactions.

RESULTS

Growth Performance

Live weight of the standard strain broilers was lower on d 1 of the trial ($P < 0.001$), similar on d 22 and higher on d 46 compared to the high-breast yield broilers, due to the higher daily weight gain (+3.6%; $P < 0.001$) measured during the second period of growth in the former birds. Feed conversion was significantly lower in the standard strain compared to the high-breast-yield genotype both in the first period (mostly due to the significantly lower feed intake, -2.4%; $P < 0.01$) and in the second period (mostly due to the significantly higher daily weight gain), resulting thus in a 3% improvement on the whole trial ($P < 0.001$) (Table 1).

Males and females performance also soon differed ($P < 0.001$) with males having heavier weights than females at both 22 and 46 d of age which showed higher daily weight gain (+23%) and feed intake (+17%) and lower feed conversion (-6%) during the whole trial (Table 1).

Table 1. Productive performance¹ (LS means) of broilers until slaughtering.

Item	Breast yield (B)		Gender (G)		Feeding system (F)		P-value							MSE
	Standard	High	Females	Males	Ad libitum	Restricted	B	G	F	B × F ²	G × F	B × G ³	B × G × F	
Broilers (n)	364	364	363	365	362	366								
Live weight (g)														
On d 1	50	53	51	52	51	51	<0.001	0.32	0.57	0.37	0.97	0.79	0.95	4
On d 22	952	949	887	1,014	1,023	878	0.73	<0.001	<0.001	0.61	0.15	0.61	0.61	94
On d 46	3,207	3,130	2,845	3,492	3,194	3,142	<0.001	<0.001	<0.01	0.13	0.24	<0.001	0.76	234
First period (1 to 22 d)														
Weight gain (g/d)	43.0	42.7	39.8	45.9	46.3	39.4	0.43	<0.001	<0.001	0.57	0.15	0.61	0.61	4.4
Feed intake (g/d)	56.3	57.7	54.2	59.8	61.5	52.5	<0.01	<0.001	<0.001	0.91	0.09	0.62	0.63	1.4
Feed conversion	1.31	1.34	1.35	1.30	1.33	1.33	0.03	<0.001	0.90	0.62	0.55	0.83	0.92	0.04
Second period (23 to 46 d)														
Weight gain (g/d)	95.1	91.8	82.4	104.5	91.5	95.4	<0.001	<0.001	<0.001	0.04	0.50	<0.001	0.88	8.2
Feed intake (g/d)	166	168	153	181	166	168	0.81	<0.001	0.14	0.73	0.37	0.02	0.94	3.6
Feed conversion	1.76	1.83	1.85	1.74	1.82	1.76	<0.001	<0.001	<0.001	0.02	0.52	<0.01	0.74	0.04
Whole trial (1 to 46 d)														
Weight gain (g/d)	71.0	69.2	62.8	77.3	70.7	69.5	<0.001	<0.001	<0.01	0.13	0.24	<0.001	0.76	5.2
Feed intake (g/d)	110	111	102	119	113	109	0.29	<0.001	<0.001	0.65	0.17	0.02	0.86	2.2
Feed conversion	1.56	1.61	1.63	1.54	1.60	1.57	<0.001	<0.001	<0.01	0.06	0.99	0.06	0.98	0.03

MSE, root mean square error; SEM is equal to MSE/√n.

¹Individual data: live weight and daily growth rate. Pen data: feed intake and feed conversion.

²Interaction of breast yield × feeding system. Weight gain during the second period: 93.7, 96.4, 79.3 and 104.3 g/d, *P* < 0.05; feed conversion during the second period, 1.77, 1.75, 1.87, and 1.78, *P* < 0.05, in standard yield broilers fed ad libitum, standard yield broilers submitted to restriction, high yield broilers fed ad libitum and high yield broilers submitted to restriction.

³Interaction of breast yield × gender. Live weight on d 46: 2,916, 3,497, 2,774 and 3,487 g, *P* < 0.001; weight gain during the second period: 85.5, 104.5, 79.3 and 104.3 g/d, *P* < 0.001; feed intake during the second period: 154, 179, 151 and 182 g/d, *P* < 0.05; feed conversion during the second period: 1.79, 1.72, 1.90 and 1.75, *P* < 0.01; weight gain in the whole trial: 64.4, 77.5, 61.2 and 77.2 g/d, *P* < 0.001; feed intake: 103, 117, 102 and 120 g/d in standard yield females, standard yield males, high yield females and high yield males; *P* < 0.05.

The feeding regime affected performance of broilers: restricting broilers from 13 to 21 d of age impaired live weight at 22 d of age (−15%; *P* < 0.001) because of the lower feed intake (−16%; *P* < 0.001) and daily weight gain (−15%; *P* < 0.001) during the first period compared to broilers fed ad libitum (Table 1). At the end of the trial, the restricted broilers still weighed less (−2%; *P* < 0.01) despite the compensatory growth (+4%; *P* < 0.001) measured during the second period. Accordingly, feed restriction improved feed conversion during the second period (3%; *P* < 0.001) and the whole trial (2%; *P* < 0.01).

Some significant interactions were observed between the genotype and the gender of the birds (Table 1). A major difference in the final live weight was measured between males and females of the high-breast-yield genotype (+26%) than those of the standard genotype (+20%) (*P* < 0.001) because of corresponding differences among groups in daily weight gain (*P* < 0.001) and feed intake (*P* < 0.05) during the second period of growth (Table 1).

Further significant interactions were measured between the feeding system and the genotype of birds during the second period: the lowest daily gain was measured in the high-breast-yield broilers always fed ad libitum, the highest daily weight gain was recorded in birds of the standard genotype previously submitted to feed restriction, whereas intermediate values were measured in the other two experimental groups (*P* < 0.05). Feed intake changed with a similar trend (Table 1).

Occurrence of Myopathies in Pectoralis Major and Meat Quality

At gross examination, the occurrence of white striping was similar in the broilers of the two genotypes, even if the occurrence of severe white striping resulted lower in standard broilers than in high-breast genotype (−10 percentage units; *P* < 0.05) (Figure 1). Besides, the occurrence of white striping (moderate and severe) was lower in broilers always fed ad libitum compared to those submitted to feed restriction (−10 percentage units) at a level approaching significance (*P* = 0.07) (Figure 1). The occurrence of wooden breast was affected only by gender and doubled from females to males (8.0% vs. 16.3%; *P* < 0.05) (Figure 2).

The presence of white striping increased the pH of pectoralis major (+0.7%; *P* < 0.05), and decreased its *a** (−37%; *P* < 0.05) and *b** indexes (−6%; *P* = 0.05) (Table 2). Cooking losses (+16%; *P* < 0.001) and shear force (+49%; *P* < 0.001) measured on pectoralis major were higher in broilers showing wooden breast compared to those without the myopathy (Table 2).

Macroscopic Observations and Histology

At gross examination, out of the 64 specimens used for histopathological analysis, 18.7% showed normal pectoralis major (score 0), 67.2% moderate white striping (score 1), and 14.1% severe white striping (score 2). Indeed, at histological examination of muscle fibers, 3.1% of pectoralis major were normal

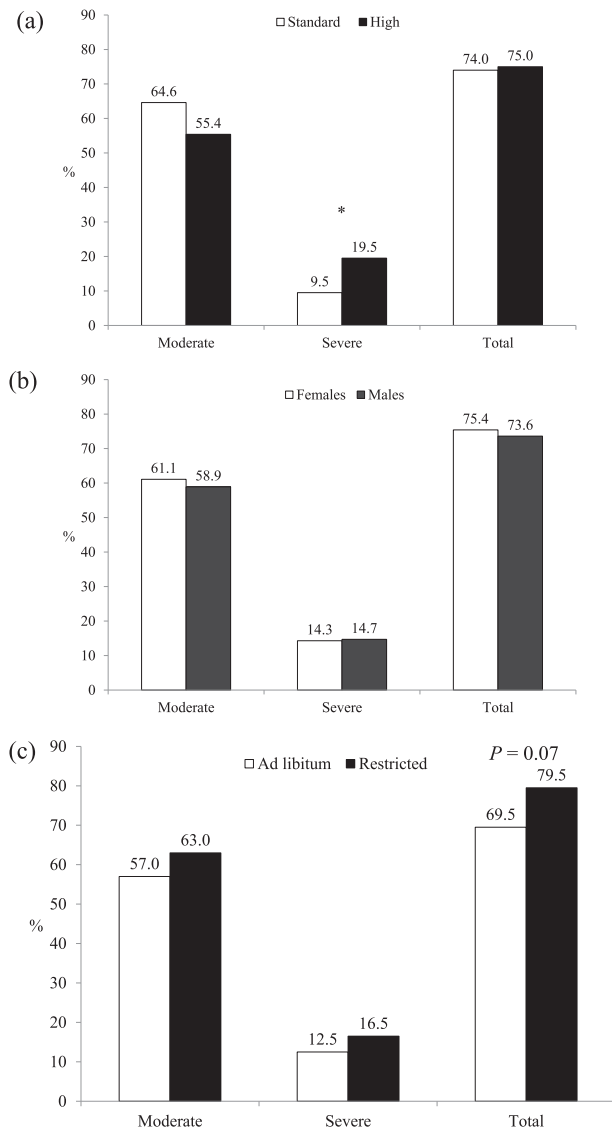


Figure 1. Percentage of broilers showing white striping (moderate, severe, total) of pectoralis major at gross observation performed at commercial slaughter (46 d of age): effect of genotype (standard vs. high-breast yield) (a); gender (females vs. males) (b); and feeding regime (ad libitum vs. restricted) (c). *, $P < 0.05$.

(score 0); 26.6% showed mild degeneration (score 1); 45.3% moderate degeneration (score 2); and 25.0% severe degeneration (score 3) (Figure 3). A significant but low correlation was found between the white striping score at gross examination and the score at histological examination of the pectoralis major ($r = 0.30$; $P < 0.05$) (data not shown).

A lower degeneration of the pectoralis minor muscle fibers was also observed: at histology, 54.7% of samples were normal, 20.3% were scored as mildly degenerated, 18.7% as moderately degenerated, and 6.3% as severely degenerated (data not shown). A significant but moderate correlation was found between the scores attributed to pectoralis major and minor at histological examination ($r = 0.48$; $P < 0.001$) (data not shown).

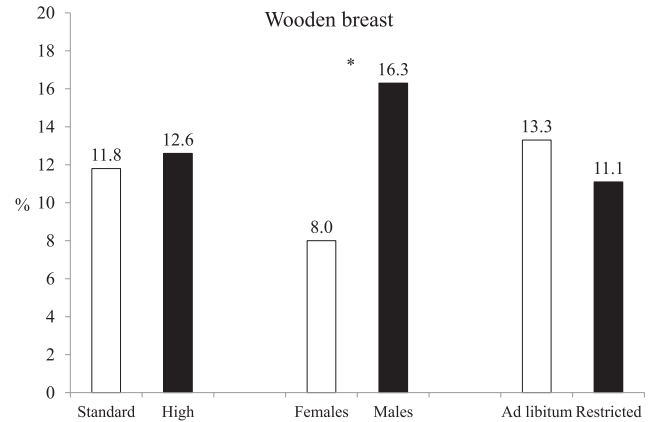


Figure 2. Percentage of broilers showing wooden breast of pectoralis major at gross observation performed at commercial slaughter (46 d of age): effect of genotype (standard vs. high-breast yield); gender (females vs. males); and feeding regime (ad libitum vs. restricted). *, $P < 0.05$.

The histomorphology of muscle tissues from birds showing white striping as well as wooden breast at gross examination revealed a range of myodegenerative lesions (Figure 4, A-F) from 1 (mild) to 3 (severe). In normal tissues, muscle fibers exhibited a regular diameter and were filled with longitudinally arrayed myofibrils (Figure 4A); in each fiber nuclei were located peripherally, immediately under the plasma membrane (Figure 4A). Individual muscle fibers were surrounded by a delicate layer of reticular fibers, the endomysium. The entire muscle exhibited cross-striations, although few hyper-eosinophilic fibers with loss of cross striations and internalization of nuclei were detectable (insert of Figure 4A). In samples affected by white striping as well as wooden breast, the major histopathological changes consisted of internalization of nuclei, loss of cross striations, vacuolar degeneration, and necrosis of fibers (Figure 4B), lymphocytes, and macrophage infiltration (Figure 4C), high variability in fiber size (degenerating and regenerating fibers) (Figure 4D), lipidosis, and fibrosis (Figure 4D-F). The results of histomorphology were in accordance with those of macroscopic observations.

DISCUSSION

Controlling the occurrence and the degree of breast myopathies would be of great interest for the poultry industry in view of maintaining consumer acceptance (Kuttappan et al., 2012b) and meat technological properties (Mazzoni et al., 2015; Mudalal et al., 2015). Moderately white-striped breasts are usually marketed as such to consumers, while severely white-striped and wooden breasts are downgraded and used in the manufacturing of further-processed products. In general, as observed in the present study, white-striped breasts exhibit some minor differences in final pH and color indexes (lightness, red, and yellow), not always consistent among studies (Petracchi et al., 2013a; Mazzoni et al.,

Table 2. Pectoralis major traits (LS means) of broilers affected by white striping or wooden breast.

Items	White striping (WS)		Wooden breast (WB)		P-value		MSE
	Without	With ¹	Without	With	WS	WB	
Broilers (n)	29	99	111	17			
Pectoralis major							
pH	5.83	5.87	5.84	5.85	0.04	0.67	0.10
L*	46.1	45.8	45.7	46.2	0.49	0.44	2.3
a*	-0.59	-0.81	-0.62	-0.77	0.05	0.27	0.51
b*	14.5	13.7	14.4	13.8	0.04	0.17	1.9
Thawing losses (%)	11.2	10.2	10.3	11.1	0.12	0.31	2.9
Cooking losses (%)	24.0	23.8	22.1	25.6	0.79	<0.001	3.5
Shear force (kg/g)	3.57	3.50	2.84	4.23	0.79	<0.001	1.27

MSE, root mean square error; SEM is equal to MSE/\sqrt{n} .

¹Moderately and severely white-striped breasts are considered together.

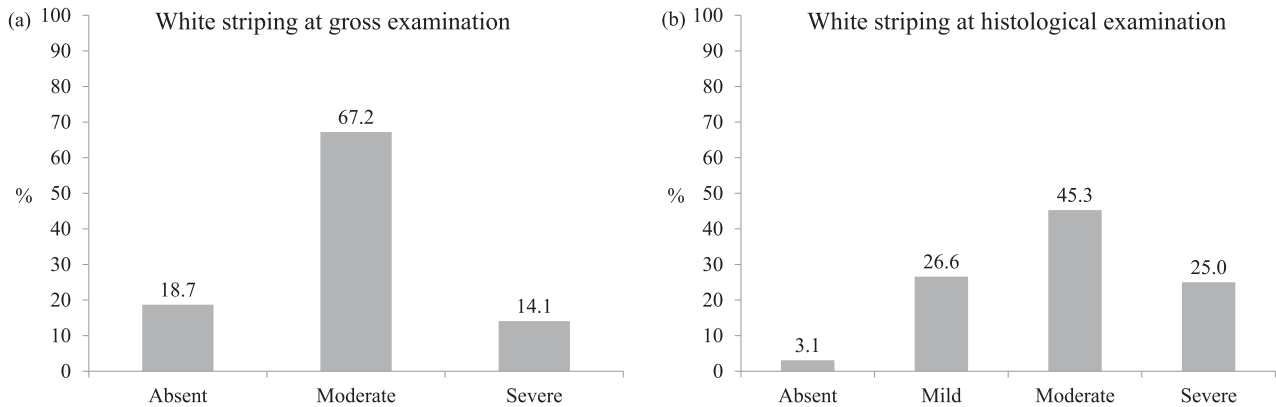


Figure 3. Percentage of broilers showing white striping of pectoralis major (a) at gross observation (absent, moderate, severe,) and (b) at histological evaluation (absent, mild, moderate, severe): broilers slaughtered at 46 d of age and submitted to histological analysis (n = 64).

2015; Mudalal et al., 2015). Other authors also reported higher cooking losses of white-striped breasts (Petracci et al., 2013a; Mazzoni et al., 2015; Mudalal et al., 2015). In the present study, wooden breasts showed similar final pH and color indexes, but lose more water during cooking and exhibited higher shear force as compared to normal or white-striped breasts as previously described by Petracci et al. (2013a) and Mudalal et al. (2015).

The occurrence rate of myopathies justifies the large interest in the topic: under commercial conditions, Lorenzi et al. (2014) measured an average prevalence of 43.1% of white-striped breasts on 70 flocks of birds (about 35,000) examined at slaughter, which reached 60.3% in the heaviest animals (males with live weight from 3.8 to 4.2 kg). Under experimental conditions and using four different commercial strains, Kuttappan et al. (2013a) found 55.8% of breasts showing moderate and severe white striping (47.5% and 8.3%, respectively) in broilers (59 to 63 d). In contrast, with lighter birds slaughtered from 45 to 54 d of age (average live weight: 2.75 kg), Petracci et al. (2013a) found 12.0% of white-striped breast fillets (8.9% with moderate white striping and 3.1% with severe white striping). In our trial, at gross examination 74.5% of the fillets examined were white-striped and 12.2% exhibited wooden breasts (regardless from the experimental group); on

the other side, 97% of breasts submitted to histological examination showed damaged muscle fibers. Differences in live weight of birds may partially explain the different rates of myopathy occurrence among studies (Kuttappan et al., 2012a, 2013a).

In fact, the occurrence of myopathies in broilers has been associated with high growth rate and breast yield, i.e., the objectives of the genetic selection during the last decades (Petracci et al., 2014). Increased hypertrophy and, thus, increased fiber size in muscles of fast-growing broilers together with a reduced capillarization are considered to cause negative effects on fiber metabolism and consequently lead to pathological changes in white-striped and wooden breasts (Kuttappan et al., 2013b; Petracci et al., 2014; Sihvo et al., 2014). In fact, some authors (Hoving-Bolink et al., 2000; Joiner et al., 2014) suggested that myopathic changes could be a consequence of reduced oxygen supply to muscle as a result of lower capillarity density in fast-growing genotypes and that the diminished relative vascular support may contribute to an increased incidence of pectoral myopathy in high-yield broilers.

In our study, a range of macroscopic (i.e., white striations of various size and number parallel to myofibers, paleness and hardness of muscles, presence of a clear fluid and petechiae on the muscles surface) and

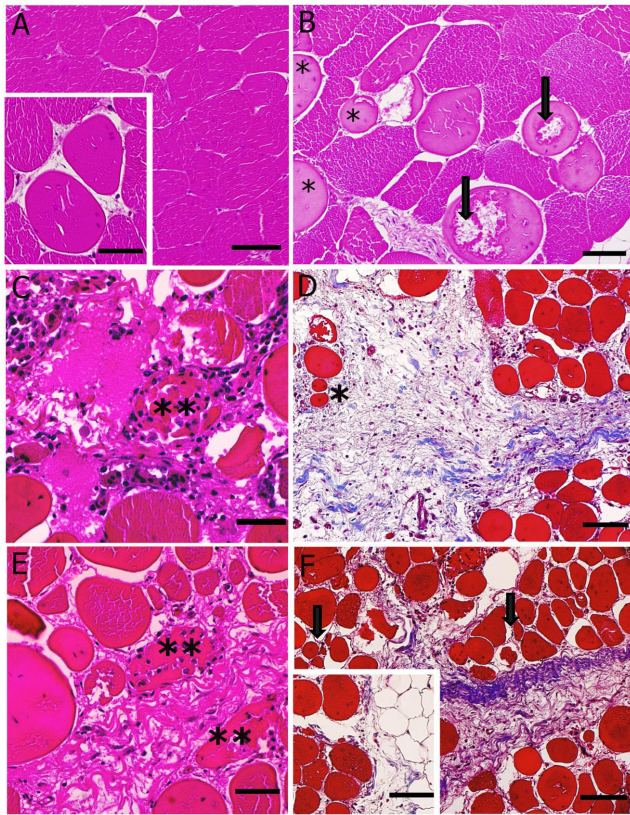


Figure 4. Histological evaluation of muscle fibers in normal sample (A); sample with moderate white striping (B); sample with severe white striping (C); sample with both white striping and wooden breast (D); samples with severe wooden breast (E, F). Panels (A-C) and (E) are stained with hematoxylin and eosin, whereas panels (D) and (F) are stained with Masson's Trichrome staining. A) In normal samples, each muscle fiber consists of a multi-nucleate cell with a striated pattern, reflecting the regular arrangement of sarcomeres within each cell. Nuclei are arranged peripherally. Occasionally, some muscle fibers exhibit hyper-eosinophilic aspect with loss of cross striations and internalization of nuclei (insert in A). B) Hyper-eosinophilic fibers (*asterisks*) as well as fibers with vacuolar degeneration (*arrows*) are detectable scattered among normal fibers. C) Fragmented muscle fiber, which undergoes to phagocytosis (*asterisks*). The interstitium is infiltrated by lymphocytes and macrophages. D) Severe degenerative myopathic lesions in which muscle fibers are replaced with fibrosis. The collagen fibers are stained in blue. Numerous inflammatory cells are detectable. The variability in fiber size indicates the presence of a regeneration process (*asterisk*). E) Necrotic fibers (*asterisks*) immersed in an abundant connective tissue. F) Degenerative process characterized by an abundant fibrosis and fibers with variable size (*arrows*). Insert in F shows the replacement of muscle tissue with fatty tissue. Scale bars: A, insert in A, B, C, E, 20 μm ; D, F, insert in F, 40 μm . Color version available in the online PDF.

microscopic lesions (i.e., internalization of nuclei, loss of cross striation, vacuolar degeneration and necrosis of fibers, lymphocytes and macrophages infiltration, degenerating and regenerating fibers of variable size, lipidosis and fibrosis) were observed in white-striped and wooden breasts. Pectoralis major muscles exhibited the highest levels of myodegeneration compared to pectoralis minor muscles and the severity of gross and histological lesions increased as the degree of white striping increased from normal to severe, reaching the worst feature in muscles affected by wooden breast. Indeed, the highest amount of fibrosis was usually detectable

in samples affected by wooden breast compared with those affected by white striping. Similar observations have been made by Kuttappan et al. (2013b) and Mazzoni et al. (2015) about white striping and by Sihvo et al. (2014) about wooden breast. Indeed, Kuttappan et al. (2013b) found that the severity of myopathic lesions increased as the degree of white striping increased from 0 to 3, and that the tissue changes were less apparent in pectoralis minor compared with pectoralis major. Gross and histological similarities in pectoralis major affected by wooden breasts between our findings and those described by Sihvo et al. (2014) are remarkable as well.

Kuttappan et al. (2013a) demonstrated that heavier birds and birds with thicker breasts are most likely to show white striping compared to lighter birds. The occurrence of white striping may be affected by final slaughter weights as affected by genotype, gender and feeding regime. In our study, however, the direct correlation between white striping and bird weight was not proved to be significant. Less information is available on the factors involved in the occurrence of wooden breast, even if high growth rate and high breast yield have been considered (Sihvo et al., 2014).

Both genotypes tested in our trial were commercial fast-growing strains, which fully expressed their performance by reaching final live weights (on average 3,168 g at 46 d of age, corresponding to 70.1 g/d daily growth) and feed conversion rates (1.59) during the trial consistent with their standard. Indeed, performance resulted higher than that achievable under field commercial conditions: Lorenzi et al. (2014) reported that females and males belonging to standard and high-breast yield genotypes reached 2,676 g and 2,684 g live weight at 47.7 and 48.0 d of age, accounting for a daily growth rate of 56.1 g/d and 56.4 g/d, respectively for the two genders (average values of the two hybrids).

Under our conditions, the standard hybrid always showed a lower feed intake and was somewhat advantaged, especially during the second period of growth in which it maintained a higher growth rate, compared to the high-breast-yield genotype. Also Petracci et al. (2013b) found that broilers of the standard genotype reached the slaughter weight (4.2 kg) two days before the high-breast-yield broilers (53 d vs. 55 d of age).

Significant differences have been previously found in the occurrence of white striping according to the genotype with standard genotype being less affected than high-breast-yield genotype (Petracci et al., 2013a; Lorenzi et al., 2014), but this was not the case in our trial, as mentioned above. We might hypothesize that the growth rate was so high in both genotypes to induce a similar white striping occurrence or we might argue that differences in live weight between the two genotypes were not sufficiently wide.

On the other hand, despite significant differences in live weight, the occurrence or the degree of white striping did not differ between females and males, whereas the occurrence of wooden breasts was

significantly higher in males than in females. Kuttappan et al. (2013a) reported no significant effect of gender on white striping occurrence, but they observed that females had a higher rate of normal breasts whereas males showed a higher rate of severely white-striped breasts. These effects were attributed to differences in bird weight. On the other hand, comparing birds with similar live weight (2.7 kg, medium-size broilers), Lorenzi et al. (2014) found a significantly higher rate of moderately white-striped breasts in males than in females (31.3% vs. 21.7%; $P < 0.05$), even if the rate of severely white-striped breasts did not differ between genders (2.7% on average). To our knowledge, no published data are available on the occurrence rate of wooden breast according to gender, whereas in our trial wooden breasts occurred more in males than in females.

As expected, the feeding regime impaired growth rate of broilers during the restriction period (i.e. from 13 to 21 d of age), as previously found by several authors adopting different feed restriction plans and systems (Urdaneta-Rincon and Leeson, 2002; Zhan et al., 2007; Butzen et al., 2013). During the re-alimentation period, however, previously restricted birds showed a compensatory growth, which allowed birds to reduce differences in final live weight and improved feed conversion rate. In our study, the early feed restriction increased the occurrence of white striped breasts by 10 percentage units. In contrast, Kuttappan et al. (2012a) succeeded in reducing growth rate, final live weight, and breast weight as well as the occurrence of white striping in broilers slaughtered at 54 d of age by lowering the energy value of diets. In this study, in spite of the fact that birds restricted from 13 to 21 d of age showed lower final live weight, the faster growth rate related to their compensatory growth during the refeeding period, likely even increased the rate of breast muscle growth and the damage at the fiber level in comparison with birds always fed ad libitum which showed a more constant growth rate during the trial. When feed restriction was applied during the first two weeks post-hatching, Velleman et al. (2010) found negative effects on pectoralis major structure, which showed poor organization, increased necrosis, and fat deposition. The same Authors identified the immediate post-hatch period as critical to maintain muscle growth and structure, but we found negative effects also when restriction was applied later (13 to 21 d post-hatching). Accordingly, further investigation is necessary to clarify whether and how the development stage of the muscle fiber or the rate of compensatory growth or their interaction could induce the damage at the fiber level and, thus, affect the occurrence of myopathies.

In conclusion, growth performance may significantly change with genotype, but the extent of differences is quite limited within the tested modern hybrids and not really relevant from an economic point of view. On the other hand, both gender and early feed restriction may largely affect live performance as well as myopathy occurrence, which is worth of further investigation. In

fact, myopathies affect meat quality, even if to a different extent depending on the type (white striping or wooden breast). Broilers are found to be affected by myopathies to a large extent, and the histological observations correspond to the gross examination of the muscles. Obtaining more information about the time and the mechanisms of myopathies occurrence would permit to modulate the production factors in view of reducing the presence and the degree of abnormalities.

ACKNOWLEDGMENTS

This study was funded by the University of Padova (Year 2013; Research Project CUP: C24G14000090001). The Authors wish to thank Dr. Silvia Mella and Dr. Marco Sandonà (Agricola Berica Soc. Coop.), and Mr. Mirco Ghirelli (Euroagricola) for their kind assistance in providing materials to be used in the trial.

REFERENCES

- Bancroft, J. D., and A. Stevens. 1975. *Histopathological stains and their diagnostic uses*. 4th ed. Churchill & Livingstone Press, Edinburgh, London, New York.
- Butzen, F. M., A. M. L. Ribeiro, M. M. Vieira, A. M. Kessler, J. C. Dadalt, and M. P. Della. 2013. Early feed restriction in broilers. I-Performance, body fraction weights, and meat quality. *J. Appl. Poult. Res.* 22:251–259.
- Cavani, C., M. Petracci, A. Trocino, and G. Xiccato. 2009. Advances in research on poultry and rabbit meat quality. *Ital. J. Anim. Sci.* 8:741–750.
- De Jong, I., C. Berg, A. Butterworth, and I. Estevéz. 2012. Scientific report updating the EFSA opinions on the welfare of broilers and broiler breeders. Support. Publ. 2012EN-295:1–116.
- Hoving-Bolink, A. H., R. W. Kranen, R. E. Klont, C. L. M. Gerritsen, and K. H. de Greef. 2000. Fibre area and capillary supply in broiler breast muscle in relation to productivity and ascites. *Meat Sci.* 56:397–402.
- Joiner, K. S., A. C. G. A. Hamlin, A. R. J. Lien, and S. F. B. Bilgili. 2014. Evaluation of Capillary and Myofiber Density in the Pectoralis Major Muscles of Rapidly Growing, High-Yield Broiler Chickens During Increased Heat Stress. *Avian Dis.* 58:377–382.
- Kuttappan, V. A., V. B. Brewer, J. K. Apple, P. W. Waldroup, and C. M. Owens. 2012a. Influence of growth rate on the occurrence of white striping in broiler breast fillets. *Poult. Sci.* 91:2677–2685.
- Kuttappan, V. A., V. B. Brewer, A. Mauromoustakos, S. R. McKee, J. L. Emmert, J. F. Meullenet, and C. M. Owens. 2013a. Estimation of factors associated with the occurrence of white striping in broiler breast fillets. *Poult. Sci.* 92:811–819.
- Kuttappan, V. A., Y. S. Lee, G. F. Erf, J. C. Meullenet, S. R. McKee, and C. M. Owens. 2012b. Consumer acceptance of visual appearance of broiler breast meat with varying degrees of white striping. *Poult. Sci.* 91:1240–1247.
- Kuttappan, V. A., H. Shivaprasad, D. P. Shaw, B. A. Valentine, B. M. Hargis, F. D. Clark, S. R. McKee, and C. M. Owens. 2013b. Pathological changes associated with white striping in broiler breast muscles. *Poult. Sci.* 92:331–338.
- Lorenzi, M., S. Mudalal, C. Cavani, and M. Petracci. 2014. Incidence of white striping under commercial conditions in medium and heavy broiler chickens in Italy. *J. Appl. Poult. Res.* 23:754–758.
- Mazzoni, M., M. Petracci, A. Meluzzi, C. Cavani, P. Clavanzani, and F. Sirri. 2015. Relationship between pectoralis major muscle histology and quality traits of chicken meat. *Poult. Sci.* 94:123–130.
- Mudalal, S., M. Lorenzi, F. Soglia, C. Cavani, and M. Petracci. 2015. Implications of white striping and wooden breast abnormalities

- on quality traits of raw and marinated chicken meat. *Animal* 9:728–734.
- Petracci, M., and E. Baéza. 2011. Harmonization of methodologies for the assessment of poultry meat quality features. *Worlds Poultry Sci. J.* 67:137–151.
- Petracci, M., S. Mudalal, A. Bonfiglio, and C. Cavani. 2013a. Occurrence of white striping under commercial conditions and its impact on breast meat quality in broiler chickens. *Poult. Sci.* 92:1670–1675.
- Petracci, M., S. Mudalal, and C. Cavani. 2014. Meat quality in fast-growing broiler chickens. *Proc. XIVth European Poultry Conference, Stavanger, Norway*, 221–233.
- Petracci, M., F. Sirri, M. Mazzoni, and A. Meluzzi. 2013b. Comparison of breast muscle traits and meat quality characteristics in 2 commercial chicken hybrids. *Poult. Sci.* 92:2438–2447.
- Sahraei, M. 2012. Feed restriction in broiler chickens production: a review. *Glob. Vet.* 8:449–458.
- SAS Institute. 2009. *The SAS/STAT 9.2 User's Guide*. SAS Inst. Inc., Cary, NC.
- Sihvo, H. K., K. Immonen, and E. Puolanne. 2014. Myodegeneration with fibrosis and regeneration in the pectoralis major muscle of broilers. *Vet. Pathol.* 51:619–623.
- Urdaneta-Rincon, M., and S. Leeson. 2002. Quantitative and qualitative feed restriction on growth characteristics of male broiler chickens. *Poult. Sci.* 81:679–688.
- Velleman, S. G., K. E. Nestor, C. S. Coy, I. Harford, and N. B. Anthony. 2010. Effect of posthatch feed restriction on broiler breast muscle development and muscle transcriptional regulatory factor gene and heparan sulfate proteoglycan expression. *Int. J. Poultry Sci.* 9:417–425.
- Zhan, X. A., M. Wang, H. Ren, R. Q. Zhao, J. X. Li, and Z. L. Tan. 2007. Effect of early feed restriction on metabolic programming and compensatory growth in broiler chickens. *Poult. Sci.* 86:654–660.