

Technical notes & surgical techniques

A case of resorbable mesh cranioplasty in infant, technical considerations, outcome and literature review



Valentina Baro^{a,*}, Andrea Landi^a, Stefano Fusetti^b, Mariagiulia Anglani^c, Domenico d'Avella^a, Luca Denaro^a

^a Academic Neurosurgery, Department of Neurosciences, University of Padova Medical School, via Giustiniani 5, 35100 Padova, Italy

^b Unit of Maxillofacial Surgery, Department of Neurosciences, University of Padova Medical School, via Giustiniani 5, 35100 Padova, Italy

^c Unit of Neuroradiology, Department of Neurosciences, University of Padova Medical School, via Giustiniani 5, 35100 Padova, Italy

ARTICLE INFO

Keywords:

Craniectomy
Cranioplasty
Infant
Resorbable mesh

ABSTRACT

Calvaria defects in children present a reconstructive challenge. When autogenous bone is not available, synthetic materials can be used; however, they present many drawbacks limiting their use in infants. Children, especially under the age of two, represent an incomparable limitation and they are infrequently reported in literature. The reconstructive strategies presented in the last decades are different without a clear consensus about the best procedure and material for a specific range of age. We report our experience with resorbable mesh cranioplasty using a polylactic acid / polyglycolic acid resorbable mesh plate with bone matrix in a 3-month old child who previously underwent decompressive craniectomy. This reconstructive strategy failed, and the patient was scheduled for a second procedure. After the case presentation, the literature is reviewed and discussed focusing on infants and young children.

1. Introduction

Dealing with cranial repair in paediatric population, especially after brain injury, is still a challenge. Cranioplasty in children is blamed for several unsolved problems and complications associated with the underlying pathologies, age-related factors and specific materials used for bony reconstruction [1–7]. Beyond cosmetic and protective purposes, cranioplasty is recommended also for physiological reasons [8]. Despite recent studies have shown an increased risk of resorption requiring surgical revision in 21.7% to 54.4% of the cases, the use of autologous bone flap is still universally accepted as the first choice in children [1,3,5,7,9], restraining the use of synthetic implants in cranioplasty revision [3]. Bone flap resorption occurs more frequently in post-traumatic cranial repair and it is correlated with the size of the defect [1,5], the extent of dural opening/duraplasty [5], in patients under the age of 7, in the presence of impaired CSF circulation [3,5,7], in case of comminute skull fractures, underlying brain contusions [3] and delayed cranioplasty [9]. All the risks are summarized in Table 1. In fact, the growth of the skull is very rapid in the first year of age and the growing brain reaches the 80% of its volume during the first 2 years, creating a tensile strain in the overlying dural layer and bone. This closed

interaction between growing brain, dura mater and neurocranium, together with osteogenic factors produced by the dural layer itself, are the main responsables for cranial osteogenesis [10,11]. A perturbation in this mechanism, such as after a decompressive craniectomy, could hinder autologous bone cranioplasty integration, promoting its resorption [2,12].

When autologous bone flap is not available, or in case of cranioplasty revision, synthetic materials can be used; however, they present many drawbacks limiting their use in infants. Before the age of 3, the diploic space is not reliably present and the skull is thin, prohibiting the use of split calvaria and limiting the implantations of custom prosthesis. Moreover, the majority of the materials is rigid and non-growing and most of them lack of osteointegration leading to various long-term complications (e.g. fracture, extrusion, infection, dislocation) [6,13,14].

Children under the age of one, who underwent cranioplasty after decompressive craniectomy, are infrequent in literature and few cases are reported so far [1,2,5], making the choice among materials and reconstructive techniques even more difficult.

We report the case of our youngest patient, a 3 months-old boy, who underwent cranioplasty after decompressive craniectomy. The

Abbreviations: CSF, cerebrospinal fluid; CT, Computed Tomography; EVD, external ventricular drain; GCS, Glasgow Coma Scale; HA, hydroxyapatite; IFU, instruction for use; LD, lumbar drain; MRI, Magnetic Resonance Imaging; PMMA, polymethyl methacrylate

* Corresponding author at: Academic Neurosurgery, Department of Neurosciences, University of Padova Medical School, Via Giustiniani 2, 35128 Padova, Italy.

E-mail address: valentina.bar@unipd.it (V. Baro).

<https://doi.org/10.1016/j.inat.2019.100635>

Received 21 November 2019; Accepted 24 November 2019

2214-7519/© 2019 The Authors. Published by Elsevier B.V. This is an open access article under the CC BY-NC-ND license (<http://creativecommons.org/licenses/by-nc-nd/4.0/>).

Table 1
Risk factors identified for autologous bone flap resorption after decompressive craniectomy.

Author, year	No. of pts	Age range	Size of defect	% Resorption	Risk factors
Grant et al., 2004	40	4 m-19 y	14–147 cm ² , mean 99.4 cm ²	50%	Skull defect > 75 cm ²
Frassanito et al., 2012	3	1 m-11 m	NR	100%	Specific age-related factor advocated: Minor bony reserve Pushing force of the growing brain Loss of dural layer Impaired CSF dynamics
Piedra et al., 2012	61	< 18 y	NR	42% in delayed cranioplasty group 12% in early cranioplasty group	Late cranioplasty (> 6 weeks)
Bowers et al., 2013	54	Mean 6.2 y	NR	50%	Underlying contusion Comminuted skull fracture Permanent VP shunt
Martin et al., 2014	27	1 m-17 y	NR	54.4%	Age < 2.5 y Young age (< 7 y) Size of skull defect Permanent shunt placement
Rocque et al., 2018	240	< 18 y	NR	21.7%	Extent of dural opening/duraplasty Young age External ventricular drain, lumbar shunt

m: months; y: years; NR: not reported; CSF: cerebrospinal fluid.

reconstruction technique is described and afterwards we discuss its outcome and the current literature.

2. Materials and methods

2.1. Clinical history

This 42 days-old boy was admitted to the Paediatric Emergency Department for a traumatic brain injury. He fell from his mother's arms while on the stairs. Four hours after the trauma he was GCS 13. The CT scan showed an acute left fronto-parietal subdural hematoma associated with a parietal fracture and a diastasis of the coronal suture. The patient underwent urgent craniectomy and evacuation of the subdural hematoma. During surgery, because of the brain swelling, we performed a wide decompressive craniectomy and duraplasty (October 2017). Post-operatively he presented a right leg myoclonus, a mild right upper limb paresis and a subgaleal fluid collection on the craniectomy site. He was discharged ten days after surgery. A follow-up MRI, performed 3 weeks later, showed the resolution of the brain herniation and disclosed a persistent pseudomeningocele on the site of craniectomy (Fig. 1). We planned accordingly an early surgical intervention for dural repair and cranioplasty, which was postponed by 2 weeks due to a respiratory tract infection (December 2017).

2.2. Surgical technique

The patient was positioned in supine position with the head turned to the right side, underpinned by a smooth head-holder. After opening

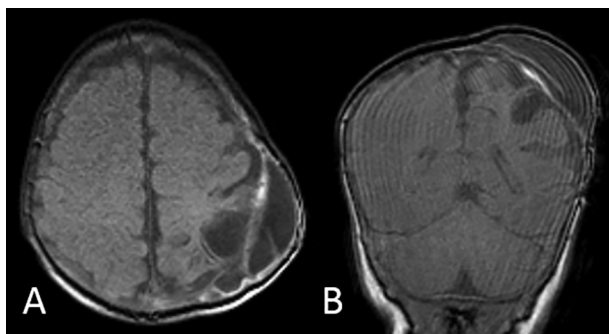


Fig. 1. Axial (A) and coronal (B) T1-weighted MR images depict the persistence of a pseudomeningocele at 1 month after surgery. Movement artefacts partially affected the images quality.

the skin flap, we exposed the pseudomeningocele composed of scar tissue and dural patch, we drained it therefore, we resected its walls displaying the underlying gliotic cerebral cortex.

2.2.1. Dural reconstruction

The cerebral cortex was carefully dissected from the bony edges and we broadened the craniectomy exposing healthy dural tissue all around. After that, a collagen matrix duraplasty (DuraGen- Integra® Integra LifeSciences) was placed meticulously under it. Moreover, we strengthened the dural layer reconstruction using a vascularized patch of autologous pericranial tissue, placed above the collagen matrix duraplasty, sutured and glued with fibrin glue.

2.2.2. Cranioplasty

In order to neutralize the pulsatile effect of the dura, preventing the recurrence of the pseudomeningocele and CSF collection and to restore the cranial vault, we supplemented the dura reconstruction with a rigid cranioplasty. Considering the age of the patient (3 months old at the time of surgery) the size of the defect (25 cm²) and the thickness of his bone (3.35 mm), we opted for an amorphous copolymer resorbable mesh plate (85:15 L-Lactide-co-glycolide, RapidSorb® Mesh Plate-DePuy Synthes, 100 × 100 mm, 0.5 mm thick) tailored and moulded in situ, fixed with resorbable screws (Fig. 2). The scalp was then closed with resorbable sutures without placing a drain and the patient was treated with a preoperative and 3-days postoperative course of cephalosporin antibiotics.

3. Results

Postoperative MRI performed 48-hours after surgery disclosed the presence of subcutaneous serous fluid collection, which was subsequently aspirated without further recurrences. Therefore, the patient had a regular postoperative course without other complications and the clinical examination demonstrated a good overall shape at discharge (Fig. 3A and B).

Follow-up MRI performed 3 months after the cranioplasty showed the resolution of the pseudomeningocele and the absence of delayed intracranial complications (Fig. 3C and D). At six months follow-up, the patient presented an almost complete resolution of the distal paresis, a better axial tone and he was free from seizures without antiepileptic drugs. As far as the cranioplasty is concerned, he presented signs of mesh resorption and peripheral ossification. At last follow-up, 18 months after surgery, he was still free from seizures and he did not show any deficit. Unfortunately, the clinical examination revealed the

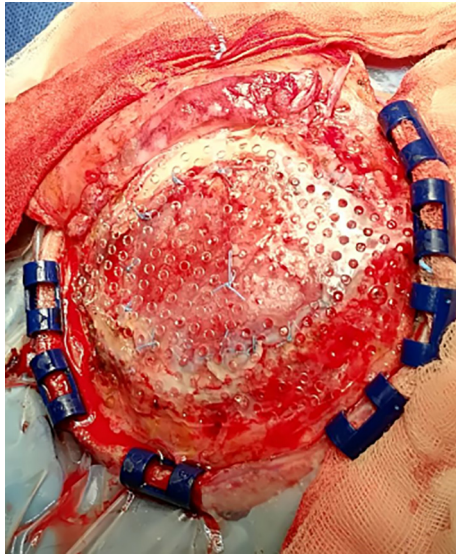


Fig. 2. Intraoperative picture shows the duraplasty with pericranium sutured to the dura mater reinforced by the resorbable mesh cut and moulded in situ and fixated by means of resorbable screws.

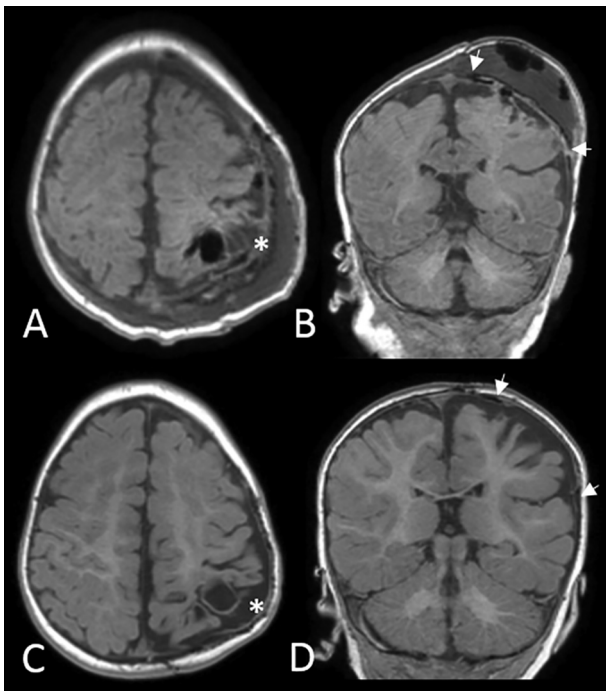


Fig. 3. Postoperative axial (A) and coronal (B) T1-weighted MR images show the absence of complications and the correct placement of the mesh (the white star is placed in the contour of the implant in axial plane A and C, white arrows indicate the limits of the implant in the coronal plane B and D). Follow-up axial (C) and coronal (D) T1-weighted MR images performed 3 months after cranioplasty disclose a thinning of the prosthesis and an overall good cosmetic result.

persistence of the bony defect warranting a second surgery. We decided to plan a customized hydroxyapatite (HA) implant after the age of 2 year, according to the product IFU.

4. Discussion

Cranial repair after traumatic brain injury in young children seems to be a minefield riddled of pitfalls and fallacies. It is as a matter of fact

still a challenge for surgeons and the protagonist of a fierce controversy in literature without clear guidelines to select a proper material for cranioplasty at this age [6,13,14]. For these reasons, this issue deserves a systematic and thorough discussion.

4.1. The unique feature of children: the cranial growth

The most rapid skull expansion occurs during the first year of age and the cranial indexes of children older than 3 years of age are similar to those of the adults [15–17]. Moreover, the two sexes show clear regional variations in the pattern of skull base growth during the first 5 years of life [18]. This process of cranial bone development is determined and directed by a complex signalling pathway, together with mechanical forces. The rapid development of the brain during the first two years of age generates a tensile strain in the overlying dura and bone, inducing the dura mater to proliferate and to release osteogenic growth factor promoting the differentiations of the osteoblasts. The interactions between brain, dura mater and neurocranium and especially the role of dura mater seem to be essential for the osteogenesis [10,11]. The calvarial healing is consequently most robust in this first period and Hou et al. concluded that children under the age of one should not receive any cranial repair, identifying the best age for cranioplasty with the age of 3 and older [17]. A disruption of this mechanism, as in the case of decompressive craniectomy, could promote bony resorption and an ineffective osteointegration of synthetic materials [2,12]. In fact, children have specific physiological and anatomical features making them different from adult population, requiring peculiar consideration when planning cranial repair.

4.2. Reconstructive cranioplasty: techniques and materials

4.2.1. Autologous bone

As mentioned above, autologous bone flap is historically the gold standard in the first attempt at repairing skull defect in children. It has undoubtedly many advantages, including the use of an autologous material, which permits to maintain and restore the proper contour and shape of the skull avoiding foreign non-growing materials and the possibility to be reintegrated in the growing native bone. Despite these attractive aspects, the autologous bone flap cranioplasty conceals an important drawback, such as a high rate of bony resorption warranting surgical revision. Several single centres and one multicentre studies analysed the rate of failed osteointegration and the related risk factors [1–3,5,7,9] (Table 1). Nowadays the rate of autologous bone resorption requiring second surgery stands between 21.7% and 54.4% of the cases. These findings polarise the debate about whether a heterologous material should be used as a first choice in younger age [5] or only in case of autologous flap failure [3]. Young age (under 7 years-old) is in fact among the various risk factors identified for bone resorption. The highest turnover of bone tissue and the thinness of the calvaria could probably represent some of the crucial factors promoting bony resorption (together with the dura mater, cf. previous paragraph) [1]. The use of autologous bone from donor site (i.e. ribs, iliac crest, split-thickness calvaria) is burden of site morbidity and, in the case of split-thickness calvaria, this solution is not feasible in children under the age of 3 [6,14]. Moreover, even if this technique was advocated as the method of choice in the past decades [19], it seems to have currently been overtaken by synthetic custom made cranioplasties, which have shown a higher rate of success in revision surgery [3].

4.2.2. Hydroxyapatite

Hydroxyapatite is a peculiar material reproducing the mineral component of the bone with a 3D structure, which favours the osteoconduction and osteoinduction reducing rejection.

Before the development and the diffusion of the use of customized HA implants in children, several authors had already used HA cement alone [20–26] or associated with resorbable [24,27–33] or tantalum

Table 2

Cases treated with hydroxyapatite cement or paste under the age of two Pts: patients; m: months; NR: not reported.

Author, year	No of pts	Age (m)	Sex	Indication for cranioplasty	Area of bony defect	Follow-up (months)	Complications
Matic et al., 2002	1	17	F	Previous corrective surgery for craniosynostosis	NR	NR	NR
Durham et al., 2003	1	18	M	Trauma	168 cm ²	7	None
Eppeley et al., 2003	1	16	NR	NR	NR	NR	NR
Cohen et al., 2004	1	11	NR	NR	NR	NR	None
Zins et al., 2007	2	12	NR	NR	> 25 cm ²	NR	No major complications
		22	NR	NR	< 25 cm ²	NR	No major complications

Pts: patients; m: months; NR: not reported.

mesh [34]. Despite good aesthetic results, this material revealed important drawbacks limiting its use. An unacceptably high rate of infections was described in patients who underwent HA cranioplasty near sinuses or nasal mucosa, and in case of large defect (> 25 cm²), which were also found to be more prone to fracture and fragmentation in long-term follow-up [13,20–22,24,25,35]. These findings indicate the major contraindications of the use of HA cements and paste. Moreover, the implant achieves its final strength hours/days after surgery, exposing it to the risk of fracture by trauma or it can be cracked by the CSF pulsation directly transmitted to the dura mater [36]. Furthermore, most of the series included paediatric and adult patients, with few patients under 2 years of age, reported without specific considerations, as shown in Table 2 [20,28,29,34,35].

During the past decade, technical advancement creates a new generation of HA prosthesis, the custom-made HA implants, with the purpose of overcoming the above-mentioned limits and of increasing the osteoconductive and inductive proprieties by providing structural modifications. This technique has been adopted in paediatric cranioplasty with good outcome [37–42]. An optimal osteointegration of 98–100% with excellent cosmetic result has been reported by Zaccaria et coll. in 83% of the patients [41]. Beuriat et coll. treated 19 patients successfully and without any complications and among them we found the youngest patients treated by customized implant, an 8 month old child [39]. Furthermore, Frassanito et al confirmed the effectiveness and safety of this group of implants in children older than 2.5 years of age. Apart from the time needed for 3D Cranial CT acquisition, images reconstruction and implant fabrication, which forecloses the use in emergency surgery, the prosthesis are susceptible to fracture following head trauma in the first period. Furthermore, younger children show a higher rate of complications compared to the older ones (20.8% to 3.8%) and age-related factors have been advocating to explain this negative effect [38].

4.2.3. Polymethyl methacrylate

This material has been widely used in children and the common complications reported in long term studies are infection, extrusion, migration, fracture, lack of integration and a disagreeable thermal sensitivity [6,13,19,43–45]. Its use in large defect (> 25 cm²) especially placed near the sinuses and in presence of irradiated skin carries a risk of complications over the 80%, requiring a careful patients selection [43,44]. Moreover, non-customized PMMA cranioplasty should be avoided in case of large defects and in patients under 5 years of age because of the increased risk of failure [1,6,44]. Most of these disadvantages have been managed and reduced with the introduction of porous PMMA and custom-made prosthesis. Indeed, PMMA can be moulded freehand directly during surgery (especially for small sized bony defects) or it can be customized, reducing surgical time, the risk of diathermal damage and giving an optimal aesthetic result. As far as the most expensive custom-made prosthesis is concerned, the overall treatment cost seems not be increased by the price of a customized implant [25]. The recent study from the Gaslini Hospital group reported encouraging results, as they found a rate long term complications of 16.6% with satisfactory osteointegration and cosmetic results with customized prosthesis, promoting its use also in cranioplasty post-

decompressive craniectomy and in younger patients [45].

4.2.4. Titanium

This material is widely used in adult cranioplasties and, the use in children is limited to the older ones. In fact, it is a rigid, inert material which could have deleterious effects in younger children, affecting the normal growth of the skull [6,13,14]. Williams et coll. reported recently a series of titanium custom-made cranioplasty in children. His patients population was older than 6 year-old and only 3 patients were younger than 8 years, concluding that this material could be used in selected paediatric patients greater than 5 years of age, as a consequence of the cranial growth [46].

4.3. Analysis of our case

In our case, the autologous bone was not conserved at the time of first surgery because of the existing fracture and the subsequent enlargement of the craniectomy. Brain herniation resolved after 3 weeks and the cranioplasty was planned 54 days after decompressive craniectomy, just above the limit of 4 weeks defined for early cranioplasty, postponed by 2 weeks due to a respiratory tract infection.

At that time, the patient was 96 day-old and we discussed in our multidisciplinary team about the best way to treat the pseudomeningocele and to perform the cranioplasty. We decided to avoid the use of bone paste/cement (both HA or PMMA) because of the area of the defect (25 cm²), fearing about the aesthetic results and complications due to possible fragmentations and migration. Our centre has an excellent experience with customized HA cranioplasty, but this prosthesis was not considered because of the thinness of the bone (3.35 mm), in fact the minimum thickness of the implant (4 mm) represents a significant limitation in (very young children) infants [39] and the specific product IFU recommend the implant after the age of 2 years. We finally decided to adopt a resorbable mesh moulded in situ after broadening the bony edges to expose intact dura mater (both for the duraplasty and for promoting osteogenesis). We did not supplement the reconstruction with bone powder or cement because of the thickness of the duraplasty, worrying about overcoming the bony edges, making it ineffective and prone to inadequate integration and subcutaneous migration.

After the failure of our first attempt to cranial vault repair, we decided to plan custom-made HA cranioplasty after the age of two according to the IFU and the current practice.

4.4. Take home messages

Ex-post reflections appear always easy and obvious, but this case led us to up-date the various techniques with their respective pros and cons, indications and contraindications, highlighting the lack of consensus regarding the materials of choice for cranioplasty in children, especially in younger group, which remains a burning field for paediatric neurosurgeon.

5. Conclusions

Cranial vault repair in younger children remains a challenge

without a clear guideline, especially after decompressive craniectomy. A tailored patient-based approach, according to the single centre experience, is still the choice in growing-skull age. A multicentric study could help the paediatric neurosurgical community to better understand the issue, developing recommendations preventing complications and failures.

Declaration of Competing Interest

The authors declare that they have no known competing financial interests or personal relationships that could have appeared to influence the work reported in this paper.

Acknowledgement

None.

Funding

None.

Appendix A. Supplementary data

Supplementary data to this article can be found online at <https://doi.org/10.1016/j.inat.2019.100635>.

References

- [1] G.A. Grant, M. Jolley, R.G. Ellenbogen, T.S. Roberts, J.R. Gruss, J.D. Loeser, Failure of autologous bone-assisted cranioplasty following decompressive craniectomy in children and adolescents, *J. Neurosurg. Pediatr.* 100 (2004) 163–168, <https://doi.org/10.3171/ped.2004.100.2.0163>.
- [2] P. Frassanito, L. Massimi, M. Caldarelli, G. Tamburrini, C. Di Rocco, Complications of delayed cranial repair after decompressive craniectomy in children less than 1 year old, *Acta Neurochir. (Wien)* 154 (2012) 927–933, <https://doi.org/10.1007/s00701-011-1253-5>.
- [3] C.A. Bowers, J. Riva-Cambrin, D.A. Hertzler, M.L. Walker, Risk factors and rates of bone flap resorption in pediatric patients after decompressive craniectomy for traumatic brain injury, *J. Neurosurg. Pediatr.* 11 (2013) 526–532, <https://doi.org/10.3171/2013.1.PEDS12483>.
- [4] B.G. Rocque, K. Amancherla, S.M. Lew, S. Lam, Outcomes of cranioplasty following decompressive craniectomy in the pediatric population, *J. Neurosurg. Pediatr.* 12 (2013) 120–125, <https://doi.org/10.3171/2013.4.PEDS12605>.
- [5] K.D. Martin, B. Franz, M. Kirsch, M. Von Der Hagen, W. Polanski, S.B. Sobottka, Autologous bone flap cranioplasty following decompressive craniectomy is combined with a high complication rate in pediatric traumatic brain injury patients, *Acta Neurochir. (Wien)* 156 (2014) 813–824, <https://doi.org/10.1007/s00701-014-2021-0>.
- [6] A.H. Feroze, G.G. Walmsley, O. Choudhri, H.P. Lorenz, G.A. Grant, M.S. Edwards, Evolution of cranioplasty techniques in neurosurgery: historical review, pediatric considerations, and current trends, *J. Neurosurg.* 123 (2015) 1098–1107, <https://doi.org/10.3171/2014.11.JNS14622>.
- [7] B.G. Rocque, B.S. Agee, E.M. Thompson, M. Piedra, L.C. Baird, N.R. Selden, S. Greene, et al., Complications following pediatric cranioplasty after decompressive craniectomy: a multicenter retrospective study, *J. Neurosurg. Pediatr.* 22 (3) (2018) 225–232, <https://doi.org/10.3171/2018.3.PEDS17234>.
- [8] S.H. Halani, J.K. Chu, J.G. Malcolm, R.S. Rindler, J.W. Allen, J.A. Grossberg, G. Pradilla, F.U. Ahmad, Effects of cranioplasty on cerebral blood flow following decompressive craniectomy: a systematic review of the literature, *Neurosurg.* 81 (2017) 204–216, <https://doi.org/10.1093/neuros/nyx054>.
- [9] M.P. Piedra, E.M. Thompson, N.R. Selden, B.T. Ragel, D.J. Guillaume, Optimal timing of autologous cranioplasty after decompressive craniectomy in children, *J. Neurosurg. Pediatr.* 10 (2012) 268–272, <https://doi.org/10.3171/2012.6.PEDS1268>.
- [10] K.D. Fong, S.M. Warren, E.G. Lobo, J.H. Henderson, T.D. Fang, C.M. Cowan, D.R. Carter, M.T. Longaker, Mechanical strain affects dura mater biological processes: implications for immature calvarial healing, *Plast Reconstr. Surg.* 112 (2003) 1312–1327, <https://doi.org/10.1097/01.PRS.0000079860.14734.D6>.
- [11] J.R. Gagan, S.S. Tholpady, R.C. Ogle, Cellular dynamics and tissue interactions of the dura mater during head development, *Birth Defects Res Part C - Embryo Today Rev.* 81 (2007) 297–304, <https://doi.org/10.1002/bdrc.20104>.
- [12] P. Frassanito, L. Massimi, M. Caldarelli, G. Tamburrini, C. Di Rocco, Bone flap resorption in infants, *J. Neurosurg. Pediatr.* 13 (2014) 243–244, <https://doi.org/10.3171/jns.1994.80.5.0947>.
- [13] J.T. Goodrich, A.L. Sandler, O. Tepper, A review of reconstructive materials for use in craniofacial surgery bone fixation materials, bone substitutes, and distractors, *Child's Nerv. Syst.* 28 (2012) 1577–1588, <https://doi.org/10.1007/s00381-012-1776-y>.
- [14] P. Frassanito, G. Tamburrini, L. Massimi, S. Peraio, M. Caldarelli, C. Di Rocco, Problems of reconstructive cranioplasty after traumatic brain injury in children, *Child's Nerv. Syst.* 33 (2017) 1759–1768, <https://doi.org/10.1007/s00381-017-3541-8>.
- [15] C.K.B.C. Westropp, Growth of the skull in young children standards of head circumference, *J. Neurol. Neurosurg. Psychiatr.* 19 (1956) 52–54.
- [16] A.F. Roche, D. Mukherjee, S.M. Guo, W.M. Moore, Head circumference reference data: birth to 18 years, *Pediatrics* 79 (1987) 706–712.
- [17] H.D. Hou, M. Liu, K.R. Gong, G. Shao, C.Y. Zhang, Growth of the skull in young children in Baotou, China, *Child's Nerv. Syst.* 30 (2014) 1511–1515, <https://doi.org/10.1007/s00381-014-2468-6>.
- [18] S. Sgouros, K. Natarajan, A.D. Hockley, J.H. Goldin, M. Wake, Skull base growth in childhood, *Pediatr. Neurosurg.* 31 (1999) 259–268.
- [19] A. Kaiser, O.E. Illi, H.F. Sailer, U.G. Stauffer, Cranioplasties for congenital and acquired skull defects in children - comparison of new concepts with conventional methods, *Eur. J. Pediatr. Surg.* 3 (1993) 236–240, <https://doi.org/10.1055/s-2008-1063551>.
- [20] D. Matic, J.H. Phillips, A contradiction for the use of hydroxyapatite cement in the pediatric population, *Plast. Reconstr. Surg.* 110 (2002) 1–5.
- [21] W.P. Magee, N. Ajkay, N. Freda, R.S. Rosenblum, Use of fast-setting hydroxyapatite cement for secondary craniofacial contouring, *Plast. Reconstr. Surg.* 114 (2004) 289–297, <https://doi.org/10.1097/01.PRS.0000131868.67896.83>.
- [22] E. Gómez, M. Martín, J. Arias, F. Carceller, Clinical applications of Norian SRS (calcium phosphate cement) in craniofacial reconstruction in children: our experience at Hospital la Paz since 2001, *J. Oral. Maxillofac. Surg.* 63 (2005) 8–14, <https://doi.org/10.1016/j.joms.2004.09.008>.
- [23] F.D. Burstein, J.K. Williams, R. Hudgins, W. Boydston, A. Reisner, K. Stevenson, S. Cohen, Hydroxyapatite cement in craniofacial reconstruction: experience in 150 patients, *Plast. Reconstr. Surg.* 118 (2006) 484–489, <https://doi.org/10.1097/01.prs.0000234811.48147.64>.
- [24] J.E. Zins, A. Moreira-Gonzalez, F.A. Papay, Use of calcium-based bone cements in the repair of large, full-thickness cranial defects: a caution, *Plast. Reconstr. Surg.* 120 (2007) 1332–1342, <https://doi.org/10.1097/01.prs.0000279557.29134.cd>.
- [25] M.S. Gilardino, D.S. Cabiling, S.P. Bartlett, Long-term follow-up experience with carbonated calcium phosphate cement (norian) for cranioplasty in children and adults, *Plast. Reconstr. Surg.* 123 (2009) 983–994, <https://doi.org/10.1097/PRS.0b013e318199f6ad>.
- [26] A.K. Gosain, H. Chim, J.S. Arneja, Application-specific selection of biomaterials for pediatric craniofacial reconstruction: developing a rational approach to guide clinical use, *Plast. Reconstr. Surg.* 123 (2009) 319–330, <https://doi.org/10.1097/PRS.0b013e318193478c>.
- [27] S.B. Baker, J. Weinzwieg, R.E. Kirschner, S.P. Bartlett, Applications of a new carbonated calcium phosphate bone cement: early experience in pediatric and adult craniofacial reconstruction, *Plast. Reconstr. Surg.* 109 (2002) 1789–1796, <https://doi.org/10.1097/00006534-200205000-00003>.
- [28] B.L. Eppley, L. Hollier, S. Stal, Hydroxyapatite cranioplasty: 2. clinical experience with a new quick-setting material, *J. Craniofac. Surg.* 14 (2003) 209–214, <https://doi.org/10.1097/00001665-200303000-00014>.
- [29] A.J. Cohen, R.D. Dickerman, S.J. Schneider, New method of pediatric cranioplasty for skull defect utilizing polylactic acid absorbable plates and carbonated apatite bone cement, *J. Craniofac. Surg.* 15 (2004) 469–472, <https://doi.org/10.1097/00001665-200405000-00025>.
- [30] L. David, L. Argenta, D. Fisher, Hydroxyapatite cement in pediatric craniofacial reconstruction, *J. Craniofac. Surg.* 16 (2005) 129–133.
- [31] B.M. Greenberg, S.J. Schneider, Alloplastic reconstruction of large cranio-orbital defects, *Ann. Plast. Surg.* 55 (2005) 43–51, <https://doi.org/10.1097/01.sap.0000168157.10664.9c>.
- [32] D. Pang, H.H. Tse, M. Zwienenberg-Lee, M. Smith, J. Zovickian, The combined use of hydroxyapatite and bioresorbable plates to repair cranial defects in children, *J. Neurosurg. Pediatr.* 102 (2005) 36–43, <https://doi.org/10.3171/ped.2005.102.1.0036>.
- [33] M.T. Chao, S. Jiang, D. Smith, G.E. Decesare, G.M. Cooper, I.F. Pollack, J. Giroto, J.E. Losee, Demineralized bone matrix and resorbable mesh bilaminate cranioplasty: a novel method for reconstruction of large-scale defects in the pediatric calvaria, *Plast. Reconstr. Surg.* 123 (2009) 976–982, <https://doi.org/10.1097/PRS.0b013e31819ba46f>.
- [34] S.R. Durham, J.G. McComb, M.L. Levy, A.R. Cohen, A.H. Menezes, L.N. Sutton, Correction of large (> 25 cm²) cranial defects with “reinforced” hydroxyapatite cement: technique and complications, *Neurosurg.* 52 (2003) 842–845, <https://doi.org/10.1227/01.NEU.0000054220.01290.8E>.
- [35] A.M. Affifi, C.R. Gordon, L.S. Pryor, W. Sweeney, F.A. Papay, J.E. Zins, Calcium phosphate cements in skull reconstruction: a meta-analysis, *Plast. Reconstr. Surg.* 126 (2010) 1300–1309, <https://doi.org/10.1097/PRS.0b013e3181ead057>.
- [36] A. Maniker, S. Cantrell, C. Vaicys, Failure of hydroxyapatite cement to set in repair of a cranial defect: case report, *Neurosurg.* 43 (1998) 953–954, <https://doi.org/10.1097/00006123-199810000-00134>.
- [37] R.S. de Oliveira, R. Brigato, J.F. Madureira, A.A. Cruz, F.V. de Mello Filho, N. Alonso, H.R. Machado, Reconstruction of a large complex skull defect in a child: a case report and literature review, *Child's Nerv. Syst.* 23 (2007) 1097–1102, <https://doi.org/10.1007/s00381-007-0413-7>.
- [38] P. Frassanito, G. Tamburrini, L. Massimi, C. Di Rocco, A. Nataloni, G. Fabbri, M. Caldarelli, Post-marketing surveillance of custombone service implanted in children under 7 years old, *Acta Neurochir. (Wien)* 157 (2015) 115–121, <https://doi.org/10.1007/s00701-014-2254-y>.
- [39] P.A. Beuriat, A. Szathmari, B. Grassiot, F. Di Rocco, C. Mottolese, Pourquoi peut-on

- utiliser une plastie en hydroxyapatite pour réparer une perte de substance osseuse de la boîte crânienne chez les enfants : expérience à propos de 19 cas, *Neurochirurg.* 62 (2016) 251–257, <https://doi.org/10.1016/j.neuchi.2016.04.003>.
- [40] R. Maduri, E. Viaroli, M. Levivier, R.T. Daniel, M. Messerer, Use of a 3D skull model to improve accuracy in cranioplasty for autologous flap resorption in a 3-year-old child, *Pediatr. Neurosurg.* 52 (2017) 351–355, <https://doi.org/10.1159/000479329>.
- [41] L. Zaccaria, S.J. Tharakan, S. Altermatt, Hydroxyapatite ceramic implants for cranioplasty in children: a single-center experience, *Child's Nerv. Syst.* 33 (2017) 343–348, <https://doi.org/10.1007/s00381-016-3327-4>.
- [42] P. Frassanito, L. Massimi, G. Tamburrini, F. Bianchi, A. Nataloni, V. Canella, M. Caldarelli, Custom-made hydroxyapatite for cranial repair in a specific pediatric age group (7–13 years old): a multicenter post-marketing surveillance study, *Child's Nerv. Syst.* 34 (2018) 2283–2289, <https://doi.org/10.1007/s00381-018-3905-8>.
- [43] J.P. Pochon, J. Klöti, Cranioplasty for acquired skull defects in children – a comparison between autologous material and methylmethacrylate 1974–1990, *Eur. J. Pediatr. Surg.* 1 (1991) 199–201, <https://doi.org/10.1055/s-2008-1042487>.
- [44] K.S. Blum, S.J. Schneider, A.D. Rosenthal, Methyl methacrylate cranioplasty in children: long-term results, *Pediatr. Neurosurg.* 26 (1997) 33–35.
- [45] P. Fiaschi, M. Pavanello, A. Imperato, V. Dallolio, A. Accogli, V. Capra, A. Consales, A. Cama, G. Piatelli, Surgical results of cranioplasty with a polymethylmethacrylate customized cranial implant in pediatric patients: a single-center experience, *J. Neurosurg. Pediatr.* 17 (2016) 705–710, <https://doi.org/10.3171/2015.10.PEDS15489>.
- [46] L. Williams, K. Fan, R. Bentley, Titanium cranioplasty in children and adolescents, *J. Cranio-Maxillofacial. Surg.* 44 (2016) 789–794, <https://doi.org/10.1016/j.jcms.2016.03.010>.