



Contrast-enhanced ultrasound features of hepatocellular carcinoma in dogs

Tommaso Banzato ¹, Giuseppe Rubini,² Riccardo Orlandi ³, Paolo Bargellini,³ Federico Bonsembiante,⁴ Alessandro Zotti¹

Abstract

Background This study aimed to describe the contrast-enhanced ultrasound (CEUS) features of canine hepatocellular carcinoma (HCC) in relation to cellular differentiation and lesion size.

Methods Sixty dogs with a cytological diagnosis of HCC and that underwent a CEUS examination were retrospectively selected. The wash-in and wash-out patterns of contrast enhancement, along with the time to wash-in and the time to wash-out, of each lesion were recorded. A dimensional cut-off value of 3 cm was adopted for classification.

Results Cellular differentiation had a significant influence on both wash-in (chi-squared=16.99; $P<0.001$) and wash-out (chi-squared=10.9; $P=0.004$) patterns of contrast enhancement. Lesion size had a lower, but still significant, influence on both wash-in (chi-squared=12.7; $P=0.005$) and wash-out (chi-squared=7.42; $P=0.024$) patterns. A homogeneous hyperenhancement in the arterial phase followed by homogeneous wash-out were suggestive of a well-differentiated HCC. The cellular differentiation of lesions with inhomogeneous hyperenhancement or hypoenhancement/no enhancement as well as an inhomogeneous wash-out or no wash-out could not be inferred.

Conclusions No significant difference in the time to wash-in and the time to wash-out in relation to cellular differentiation or lesion size was evident. CEUS has the potential to improve efficiency in the diagnosis of HCCs in dogs.

Introduction

Contrast-enhanced ultrasound (CEUS) is a specialised application of B-mode ultrasonography using an intravascular contrast agent to increase the backscattering of blood, thus allowing a real-time evaluation of the vascularisation of different organs or lesions.¹ In human medicine, detailed guidelines on the use of CEUS both for hepatic² and extrahepatic³ diseases have been proposed and are constantly updated following new advances in the literature.⁴ CEUS is reported to have a high sensitivity

and specificity in the distinction between benign and malignant liver masses.^{5–8} Moreover, CEUS showed promise in the distinction between inflammatory and non-inflammatory liver disease,⁹ and in the diagnosis of gall bladder disease.¹⁰ The possible applications of CEUS in the diagnosis of extrahepatic^{11–13} pathologies have also been studied in veterinary clinical settings. However, to date, no detailed guidelines on the use of this diagnostic tool in dogs have become available.

Primary hepatic neoplasia is uncommon in dogs and accounts for 1.5 per cent of all the neoplasms in the canine species¹⁴ and hepatocellular carcinoma (HCC) is the most common form of liver neoplasia in dogs.¹⁵ HCCs are classified on the basis of their gross morphology as massive, nodular and diffused,¹⁵ as well as on the basis of cellular differentiation as: poorly, moderately or well differentiated. The prognosis and treatment options for HCC are related to morphology and histology.¹⁴ Furthermore, poorly differentiated HCCs are reported to have a higher metastatic rate compared with more differentiated HCCs.¹⁶

Veterinary Record (2019) doi:10.1136/vetrec-2018-105282

¹Department of Animal Medicine, Productions, and Health, Università degli Studi di Padova, Legnaro, Italy

²ULTRAVET, Bologna, Italy

³Tyrus Veterinary Clinic, Terni, Italy

⁴Department of Comparative Biomedicine and Food Science, University of Padua, Legnaro, Italy

E-mail for correspondence: Dr Tommaso Banzato; tommaso.banzato@unipd.it

Provenance and peer review Not commissioned; externally peer reviewed.

Received November 22, 2018

Revised September 25, 2019

Accepted October 5, 2019

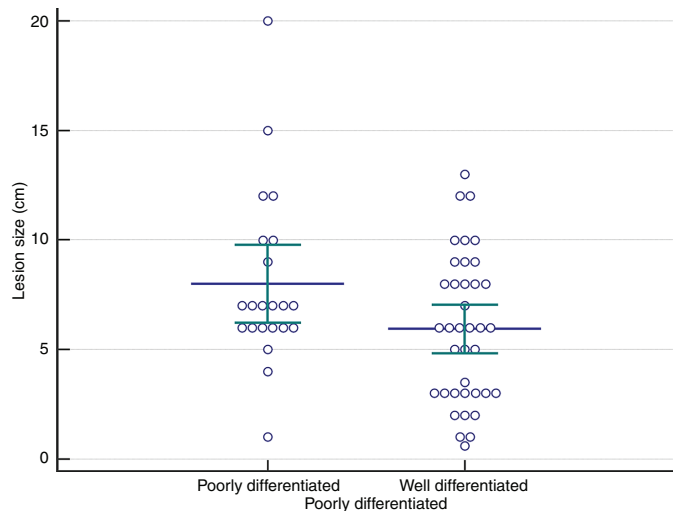


Figure 1 Multiple comparison graph of the lesion size of well-differentiated and moderately/poorly differentiated hepatocellular carcinomas (HCCs). No statistically significant differences were evident (chi-squared=3.38, P=0.063). Blue line is the mean, green lines are the quartiles.

In human medicine, the use of CEUS in the diagnostic workflow of HCCs is still debated, mostly due to factors such as lesion size and cellular differentiation, which are reported to influence the patterns of contrast medium distribution within the lesion.^{17–19} To the best of the authors’ knowledge, the effects of lesion size and cellular differentiation on the HCC patterns of contrast enhancement have not yet been elucidated in dogs. The possibility to accurately predict the cellular differentiation of HCCs in dogs could help the clinician in the choice of the optimal treatment for each patient. In particular, radiofrequency or thermal ablation^{20–22} alone, or in combination with surgical resection, could be used for the treatment of less aggressive forms of HCC. The treatment options for HCC in human beings depend on the size, the number of tumours, the stage and the cause of cirrhosis.²³

The aims of the present study were therefore:

1. To describe the influence of cellular differentiation, as evaluated by cytology, on the perfusion characteristics of HCCs.
2. To evaluate the effect of lesion size, regardless of cellular differentiation, on the patterns of HCC contrast medium distribution.

Methods

Patients

Dogs referred for specialty CEUS examination, between January 2010 and June 2018, with a cytological

diagnosis of HCC were retrospectively included in the study. Complete signalment was recorded for each patient.

The inclusion criteria were:

1. Cytological diagnosis of HCC and cellular differentiation of the lesion reported clearly by the pathologist.
2. Cytological diagnosis performed within one month of the CEUS examination.

The exclusion criteria were:

1. Multiple lesions in the liver evident in B-mode ultrasound.
2. Cytological diagnosis other than HCC.
3. HCC included only within differential diagnoses without any evidence of cellular differentiation.
4. Patients receiving chemotherapy for HCC or other malignancies.
5. Thrombosis of the hepatic vein, congenital or acquired vascular abnormalities, due to possible haemodynamic interference.

CEUS image acquisition

All patients were fasted for at least eight hours before the CEUS examination. All the examinations were performed by two veterinarians (GR and PB) each with more than 20 years’ experience in veterinary ultrasonography. Ultrasonographic examinations were performed using a GE Logiq E9 (GE Medical Systems, Milwaukee, Wisconsin, USA), an Esaote MyLab70 Gold (Esaote Italia, Milan, Italy) or an Esaote Twice (Esaote Italia, Milan, Italy) ultrasound machine on unsedated dogs positioned in dorsal recumbency. The mechanical index was set to a very low value (0.2) to prevent bubble disruption. The contrast medium (Sonovue, Bracco Imaging BV, Geneva, Switzerland) was manually administered intravenously through an 18/20G catheter inserted in the cephalic vein at the dose of 0.05 ml/kg and all the examinations were stored digitally. Each patient was scanned continuously for at least two minutes.

Cytological procedures

Ultrasound-guided fine needle aspiration using a 21 g needle attached to a 2.5 g syringe for cytology was performed in all cases after the completion of the CEUS to avoid bleeding artefacts. Cytology was always performed, using a fine needle aspiration technique, after the CEUS examination to avoid artefacts caused by bleeding. The cellular differentiation of HCC was determined according to the available literature.^{24–25} Lesions were

	Total	Hyperechogenicity	Hypoechoogenicity	Isoechoogenicity	Mixed echogenicity
Cellular differentiation					
Well differentiated	38 (63.3)	7 (18.4)	10 (26.6)	5 (13.1)	16 (42.1)
Moderately/poorly differentiated	22 (36.7)	4 (18.1)	3 (16.6)	1 (4.5)	16 (72.7)
P value		0.950	0.224	0.354	0.231
Lesion size					
Up to 3 cm	14 (25)	5 (35.7)	3 (21.4)	1 (7.1)	5 (35.7)
Above 3 cm	46 (75)	6 (13.0)	10 (21.7)	5 (10.8)	25 (54.4)
P value		0.126	0.998	0.984	0.236

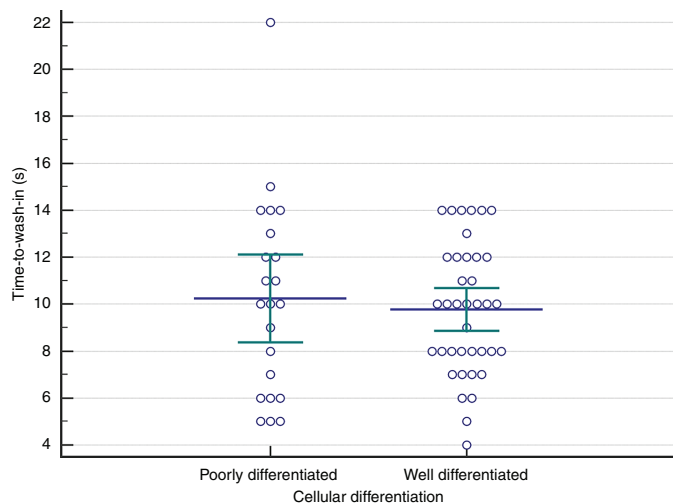


Figure 2 Multiple comparison graph of the time to wash-in of well-differentiated and moderately/poorly differentiated hepatocellular carcinomas (HCCs). No significant differences were evident (chi-squared=0.02; P=0.865). Blue line is the mean, green lines are the quartiles.

classified as poorly or moderately differentiated based on the presence of marked or moderate malignancy features in the hepatocytes, such as: anisokaryosis, anisocytosis, anisonucleoliosis, macrokaryosis, macronucleoliosis.²⁵ HCCs were classified as being well differentiated if the following cytological features were present: dissociation of hepatocytes, acinar of palisading cytoarchitectures of the neoplastic hepatocytes, presence of naked nuclei and capillaries, mild anisokaryosis and anisocytosis, multinucleated cells, and increased nucleus to cytoplasm ratio.²⁴

B-mode ultrasound and contrast-enhanced image analysis

All the ultrasonographic examinations were reviewed separately by the same two operators (TB and GR); the final features were determined after a consensus discussion. The lesions were classified as: hypoechoic, isoechoic, hyperechoic or as having mixed echogenicity, according to their echogenicity in comparison to the surrounding liver parenchyma.

The CEUS examinations were reviewed separately the two operators. Final features were determined after a consensus discussion. The entire procedure was divided into: (1) an arterial phase (0–15 seconds from contrast medium injection), (2) a portal phase (15–60 seconds

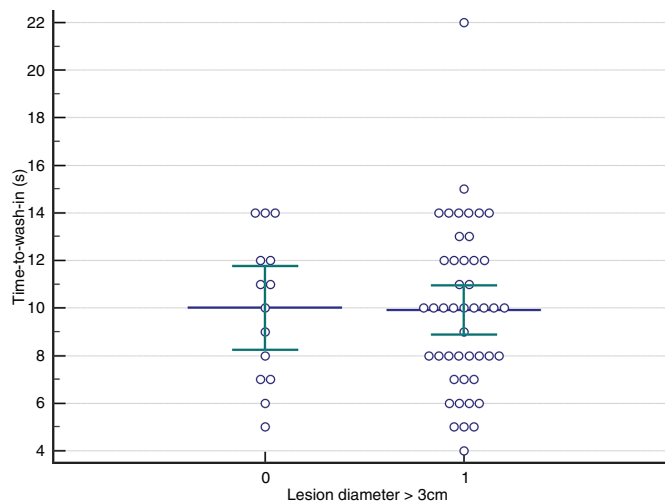


Figure 3 Multiple comparison graph of the time to wash-in of hepatocellular carcinomas (HCCs) in relation to lesion size. No significant differences were evident (chi-squared=0.08; P=0.933). 0 refers to lesions with a diameter <3 cm, 1 to lesions with a diameter >3 cm. Blue line is the mean, green lines are the quartiles.

from contrast medium injection) and (3) a late phase (60–120 seconds from contrast medium injection), in accordance with the available literature.⁵

The time to wash-in and the time to wash-out were calculated using purpose-developed MATLAB script generating time-intensity curves from the .avi examination files.

Using purpose-developed MATLAB script generating time-intensity curves from the .avi examination files the time-intensity curves of two regions of interest (ROI) were calculated. One ROI was placed on the lesion and the other one was placed on an ultrasonographically normal portion of the liver parenchyma.

The wash-in was considered as the enhancement pattern of each lesion immediately after contrast medium injection. The echogenicity of the lesion during the wash-in was compared with that of the surrounding liver tissue. The wash-in enhancement patterns were defined as follows: (1) hyperenhancement if the lesion was more enhancing than the remainder of the liver parenchyma; (2) hypoenhancement if the lesion was less enhancing than the remainder of the liver parenchyma; (3) iso-enhancement, if the lesion was as enhancing as the remainder of the liver parenchyma.

Table 2 Number of cases (along with percentage of total) divided according to lesion size and cellular differentiation, showing hyperenhancement and hypoenhancement during wash-in						
	Total	Hyperenhancement*	Homogeneous enhancement	Inhomogeneous enhancement	Peripheral enhancement	Hypoenhancement
Cellular differentiation						
Well differentiated	38 (63.3)	34 (89.5)	22 (64.7)	7 (20.6)	5 (14.7)	4 (10.5)
Moderately/poorly differentiated	22 (36.7)	18 (81.8)	1 (5.5%)	11 (61.1)	6 (33.3)	4 (18.2)
P value		0.434	0.001†	0.015†	0.201	0.402
Lesion size						
Up to 3 cm	14 (25)	13 (86)	11 (84.6)	1 (7.6)	1 (7.6)	1 (6)
Above 3 cm	46 (75)	39 (84.7)	12 (30.8)	18 (46.2)	9 (23.1)	7 (15.3)
P value		0.953	0.020†	0.015†	0.21	0.734

*Includes homogeneous enhancement, inhomogeneous enhancement and peripheral enhancement.
†Statistically significant differences.

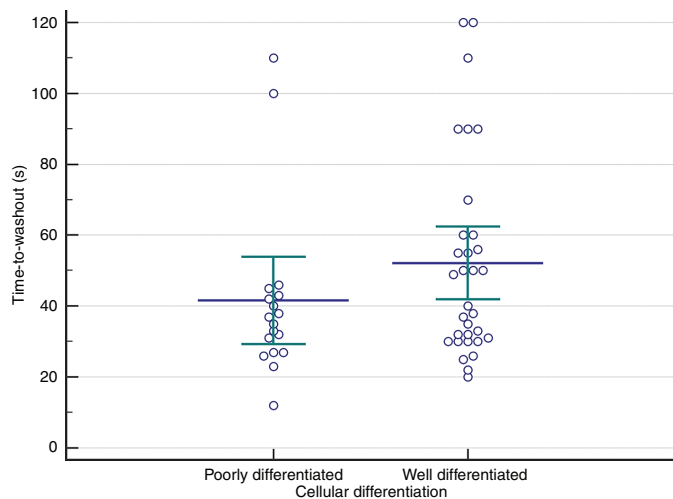


Figure 4 Multiple comparison graph of the time to wash-out of well-differentiated and moderately/poorly differentiated hepatocellular carcinomas (HCCs). No significant differences were evident (chi-squared=1.778; P=0.181). Blue line is the mean, green lines are the quartiles.

Hyperenhancing wash-in was further classified as: (a) homogeneous, (b) inhomogeneous or (c) peripheral, depending on the intralesional distribution of contrast medium. In hyperenhancing/isoenhancing lesions, the time to wash-in, defined as the first time contrast became visible within the lesion after injection, was recorded.

Only lesions with a hyperenhancing wash-in were considered as having a wash-out. Wash-out was defined as the lesion becoming less enhancing than the remainder liver parenchyma during the examination. If the lesion was still isoenhancing to the liver parenchyma at the end of the examination (two minutes), it was classified as having no wash-out. In inhomogeneous hyperenhancing lesions, observation of the wash-out was focused on the area showing hyperenhancement. A progressive and synchronous wash-out in the entire lesion was defined as homogeneous and anything other than this was defined as heterogeneous. The time to wash-out, considered as the time for the lesion to become less enhancing than the surrounding liver parenchyma, was also recorded.

Statistics and data analysis

The lesions were divided into two groups, based on their maximum diameter, using a cut-off value of 3 cm to evaluate the effect of the tumour size on the CEUS features of HCC. This procedure was adapted from similar publications evaluating HCC contrast-enhancement patterns in human patients.¹⁸ The effects of cellular differentiation and tumour size both on the echogenicity of the B-mode, along with the wash-in (homogeneous hyperenhancement, inhomogeneous hyperenhancement, peripheral hyperenhancement and hypoenhancement) and wash-out (homogeneous wash-out, inhomogeneous wash-out and no wash-out) patterns were tested with the chi-squared test or Fisher's exact method.²⁶ The effect of cellular differentiation and tumour size on the time to wash-in and time to

wash-out were analysed using the Kruskal-Wallis test for non-normally distributed data or one-way analysis of variance for normally distributed data. The statistical evaluation was performed using the MedCalc software package (SPSS, Chicago, USA). A P value less than 0.05 was considered statistically significant for each test.

Results

Patients

Sixty dogs of varying breeds including: 32 mixed breed, 5 golden retriever, 4 boxer, 4 labrador retriever, 3 beagle, 12 other breeds; 9 entire females (15 per cent), 20 neutered females (33.3 per cent), 23 entire males (38.3 per cent), 8 neutered males (13.3 per cent); median age was 13 years, range 7–16, matched the inclusion criteria. Most of the dogs included in this study were referred for specialty CEUS characterisation of previously ultrasonographically identified liver masses and, therefore, complete clinical records for most of the patients were not available.

Hepatocellular carcinoma

Sixteen dogs were diagnosed with poorly differentiated HCC (9 males – median age 14 years, range 12–16; 7 female – median age 14 years, range 13–16), 6 with moderately differentiated HCC (1 male – age 13 years; 5 females – median age 11 years, range 11–13) and 38 with well-differentiated HCC (20 males – median age 12 years, range 7–16; 18 females – median age 14 years, range 13–16). Due to the relatively low number of moderately differentiated HCCs in the database, poorly differentiated HCCs and moderately differentiated HCCs were considered as a single category, subsequently named as 'moderately/poorly differentiated', in the analysis. All data (lesion size, time to wash-in and time to wash-out) were non-normally distributed and therefore differences between groups were always tested with the Kruskal-Wallis test. Mean±SD lesion size was 6.7±3.7 cm (range 0.6–20 cm) and no statistically

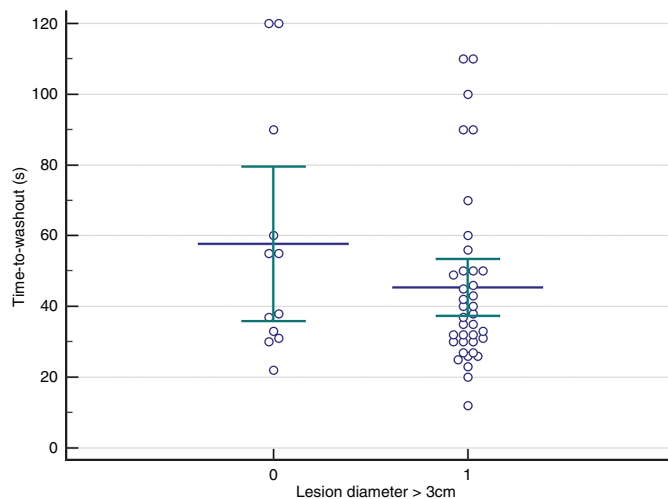


Figure 5 Multiple comparison graph of the time to wash-out of hepatocellular carcinoma (HCCs) in relation to lesion size. No significant differences were evident (chi-squared=1.29; P=0.255). 0 refers to lesions with a diameter <3 cm, 1 to lesions with a diameter >3 cm. Blue line is the mean, green lines are the quartiles.

	Total	Homogeneous wash-out	Inhomogeneous wash-out	No wash-out
Cellular differentiation				
Well differentiated	38 (63.3)	17 (44.7)	15 (44.7)	6 (10.5)
Moderately/poorly differentiated	22 (36.7)	0	18 (81.8)	4 (18.2)
P value		0.004*	0.09	0.862
Lesion size				
Up to 3 cm	14 (33.3)	7 (50)	5 (35.7)	2 (14.3)
Above 3 cm	46 (66.7)	7 (15.2)	31 (67.4)	8 (17.4)
P value		0.017*	0.098	0.734

*Statistically significant differences.

significant differences in the dimensions of moderately/poorly differentiated and well-differentiated HCCs were evident (chi-squared=3.38, P=0.063). A multiple comparison graph with the dimensions of well-differentiated and moderately/poorly differentiated lesions is shown in [figure 1](#).

B-mode ultrasonographic image analysis

There were no clear differences in the B-mode features either in relation to cellular differentiation or lesion size. The results of the chi-squared test showed distribution of the B-mode features as not significantly different (chi-squared=3.360; P=0.339) between well-differentiated and moderately/poorly differentiated HCCs. There was also no significantly different distribution of the B-mode features in relation to lesion size (chi-squared=3.904; P=0.272). Differences in the proportion of cases showing individual B-mode features based on lesion size and cellular differentiation have also been calculated and are reported in [table 1](#).

Wash-in enhancement patterns and time to wash-in

Hyperenhancement in the arterial phase was the most common feature of HCC (regardless of cellular differentiation and lesion size) and was evident in 86.6 per cent (52/60) of the cases included in this study. Nonetheless, four well-differentiated and four moderately/poorly differentiated HCC cases (13.4 per cent of the total) were hypoenhancing with no significant differences in relation to cellular differentiation or lesion size. Interestingly, none of

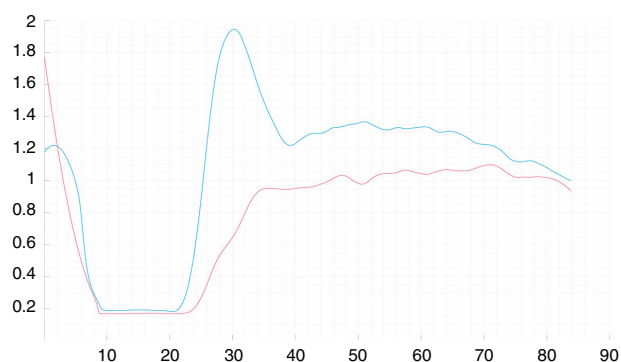


Figure 6 Time-intensity curve of a well-differentiated hepatocellular carcinoma (HCC) showing hyperenhancing wash-in and early wash-out. The red line represents the hepatic parenchyma and the blue line represents the lesion.

the lesions was isoenhancing to the liver parenchyma during wash-in. The number of HCC cases showing each wash-in enhancement pattern as classified by cellular differentiation and lesion size is reported in [table 2](#). Multiple comparison graphs with the time to wash-in in relation to cellular differentiation and lesion size are reported in [figures 2 and 3](#), respectively. The results of the chi-squared test showed distribution of the contrast enhancement patterns as significantly different (chi-squared=16.99; P<0.001) between well-differentiated and moderately/poorly differentiated HCCs. There was also a significantly different distribution of the contrast enhancement patterns in relation to lesion size (chi-squared=12.7; P=0.005). No significant differences in the time to wash-in in relation to cellular differentiation (chi-squared=0.02; P=0.865) or lesion size (chi-squared=0.08; P=0.933) were evident.

Wash-out patterns and time to wash-out

The number of HCC cases showing wash-out in the arterial, portal or late phase, or without wash-out, classified by cellular differentiation and lesion size, is reported in [table 3](#). The results of the chi-squared test showed no differences in the phase in which wash-out started based on cellular differentiation (chi-squared=0.251; P=0.882) or lesion size (chi-squared=0.170; P=0.917). There were no statistically significant differences between well-differentiated and moderately/poorly differentiated HCCs neither

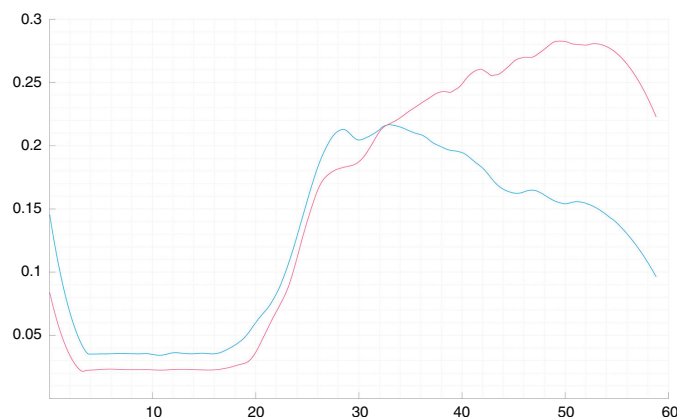


Figure 7 Time-intensity curve of a poorly differentiated hepatocellular carcinoma (HCC) showing isoenhancing wash-in and hypoenhancing wash-out. The red line represents the hepatic parenchyma and the blue line represents the lesion.

in the individual contrast phase in which wash-out was evident (arterial, portal or late phase, or no wash-out) (table 3), nor in the time to wash-out (chi-squared=1.778; P=0.181). The lesion size resulted as influential (chi-squared=1.29; P=0.255). Multiple comparison graphs with the time to wash-out in relation to cellular differentiation and lesion size, respectively, are depicted in figures 4 and 5.

There was a statistically significant difference in the number of HCC cases showing different wash-out enhancement patterns (homogeneous, inhomogeneous, no wash-out) both based on cellular differentiation (chi-squared=10.9; P=0.004) and lesion size (chi-squared=7.42; P=0.024); indeed, homogeneous hyperenhancement was more frequently associated with well-differentiated HCCs while inhomogeneous hyperenhancement was more frequently associated with moderately/poorly differentiated HCCs. No differences were evident for lesions showing peripheral enhancement and hypoenhancement. Moreover, smaller lesions showed more frequently homogeneous hyperenhancement while larger lesions showed more frequently inhomogeneous hyperenhancement. Differences in the proportion of cases showing individual wash-out patterns (homogeneous, inhomogeneous and no wash-out) based on lesion size and cellular differentiation have also been calculated and are reported in table 4. Although significant, the influence of lesion size on wash-out pattern was lower than that of cellular differentiation, and only lesions with a homogeneous hyperenhancement showed significant differences related to lesion size. Interestingly, five well-differentiated HCCs with homogeneous wash-in had an inhomogeneous wash-out (n=3) or no-wash-out (n=2).

Examples of the time-intensity curves generated using the MATLAB script in lesions demonstrating different wash-in and wash-out patterns are presented in figures 6–9. The CEUS images of: (1) a lesion showing homogeneous hyperenhancing wash-in and homogeneous hypoenhancing wash-out, (2) a lesion showing inhomogeneous hyperenhancing wash-in and homogeneous iso-enhancement in the late phase (no

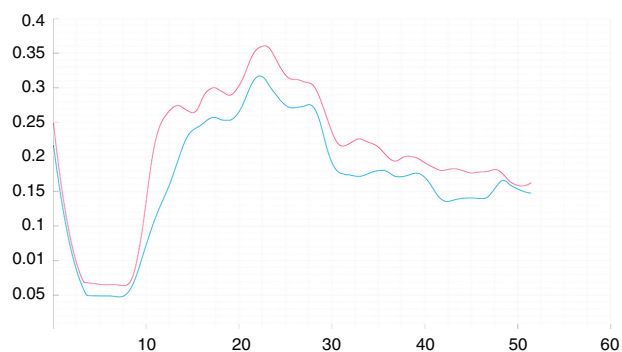


Figure 8 Time-intensity curve of a well-differentiated hepatocellular carcinoma (HCC) showing iso-enhancing wash-in and wash-out until the late phase (no wash-out). The red line represents the hepatic parenchyma and the blue line represents the lesion.

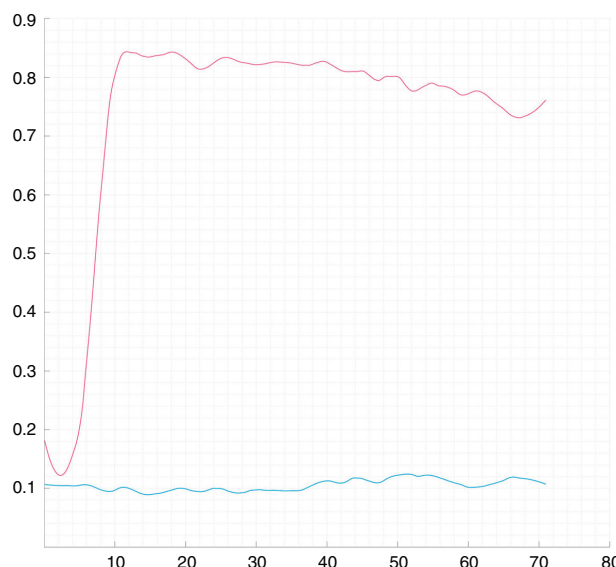


Figure 9 Time-intensity curve of a well-differentiated hepatocellular carcinoma (HCC) showing a non-enhancing lesion. The red line represents the hepatic parenchyma and the blue line represents the lesion.

-wash-out) and (3) a lesion showing hyperenhancement during wash-in and iso-enhancement during wash-out (no wash-out) are reported in figures 10–12, respectively.

Discussion

In human patients hyperenhancement in the arterial phase is recorded in 97 per cent of HCCs regardless of cellular differentiation or lesion size.¹⁸ The authors believe that the relatively higher proportion of hypoenhancing lesions (13.4 per cent) evaluated in this study might be due both to the higher dimensional variability of the collected lesions (larger lesions more likely have necrotic areas) that induce an unpredictable influence on the patterns of contrast enhancement¹⁸ or, possibly, to an inherent higher proportion of hypovascular HCCs in the canine species. In human medicine, CEUS is often performed as part of the diagnostic process for patients undergoing liver transplantation but, following the Milan criteria, patients with lesions larger than 5 cm are usually excluded from the above surgical procedure.²⁷

As a result of the statistical analyses, homogeneous hyperenhancement is suggestive of a well-differentiated HCC (table 1) (odds ratio (OR) 31.16 per cent, 95 per cent CI 3.68 per cent to 263.83 per cent). The significantly higher prevalence of inhomogeneous enhancement in moderately/poorly differentiated HCCs (50.5 per cent; 11/18) than in well-differentiated ones (18.4 per cent; 7/38) suggests that such a feature is more frequently associated with aggressive lesions (OR: 6.06 per cent, 95 per cent CI 1.17 per cent to 21.38 per cent). The number of well-differentiated and moderately/poorly differentiated lesions having peripheral enhancement was not significantly different, indicating central necrosis as not clearly associated with lesion aggressiveness. It is the authors' belief that, in such cases, the use of CEUS can still provide

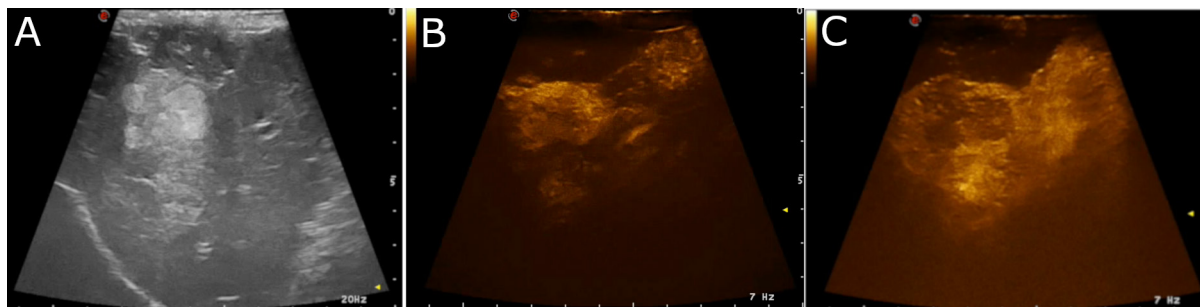


Figure 10 Contrast-enhanced ultrasonographic (CEUS) images of a well-differentiated hepatocellular carcinoma (HCC) showing hypoenhancement in wash-in and wash-out. (A) B-mode ultrasonographic image of the lesion. (B, C) CEUS images of the lesion 15 seconds and 45 seconds after contrast medium injection, respectively.

valuable information regarding lesion morphology and might help the ultrasonographer in selecting the most appropriate regions to be sampled. Interestingly similar patterns of contrast enhancement in relation to cellular differentiation and lesion type are reported in human patients¹⁸ in which identification of cellular differentiation of HCCs is important for the choice of the best treatment option.²⁸

Moderately/poorly differentiated HCCs only had inhomogeneous wash-out or no wash-out whereas well-differentiated HCCs displayed all the possible wash-out patterns. Prospectively lesions displaying homogeneous wash-out are very likely to be well-differentiated HCCs while the cellular differentiation of HCCs displaying inhomogeneous or no wash-out cannot be predicted through CEUS alone.

The proportion of lesions showing inhomogeneous wash-out or no wash-out displayed no differences based on lesion size. In human patients, the time to wash-out is reported to be significantly influenced both by cellular differentiation and lesion size,¹⁸ with moderately/poorly differentiated and larger HCCs having the shortest time to wash-out. Interestingly, no differences in time to wash-out in relation to cellular differentiation or lesion size were evident in the present study (figure 5). It is the authors' opinion that such a difference could be inherent to the study populations considered in the two studies (60 v 276 patients). The inclusion of a larger and more homogeneous caseload could provide more detailed information regarding the HCC wash-out time in dogs.

As a result of the present study most of the well-differentiated HCCs showed a homogeneous hyperenhancement in the arterial phase followed

by homogeneous wash-out. Indeed, only one moderately/poorly differentiated HCC showed homogeneous hyperenhancement and no moderately/poorly differentiated HCCs showed homogeneous wash-out. On the other hand, the cellular differentiation of lesions with inhomogeneous hyperenhancement or hypoenhancement/no enhancement as well as an inhomogeneous wash-out could not be inferred. These results are only partially in agreement with previous reports⁵ that describe hypoenhancement in the portal or the late phase as a distinctive characteristic of malignant nodules. A straightforward comparison of the results of the present study with the reported CEUS features of liver nodules in dogs^{5,7} is, at this moment in time, very difficult. Indeed, in the study by O'Brien *et al.*,⁵ the number of HCCs included (n=1) is insufficient for making a reliable comparison, while in the study by Nakamura *et al.*,⁷ a contrast medium called Sonazoid was used. This is taken up by macrophages and Kupffer cells and therefore has a very different diffusion kinetic from Sonovue, which is purely intravascular. Kutara *et al.*,²⁹ described the perfusion characteristics, using a contrast agent called Leviovist (that has a diffusion kinetic similar to Sonazoid), in eight canine HCCs. In that study all the HCCs displayed hyperenhancement in the arterial phase. On the other hand, in the portal phase, four HCCs displayed hypoenhancement, and four displayed hyperenhancement to the liver parenchyma, thus, at least partially, highlighting the variable CEUS features of HCCs, also in the dog described in the this study.

There is a remarkable overlapping of the CEUS features of HCCs described in the present study with the CEUS features of other neoplasms described in other

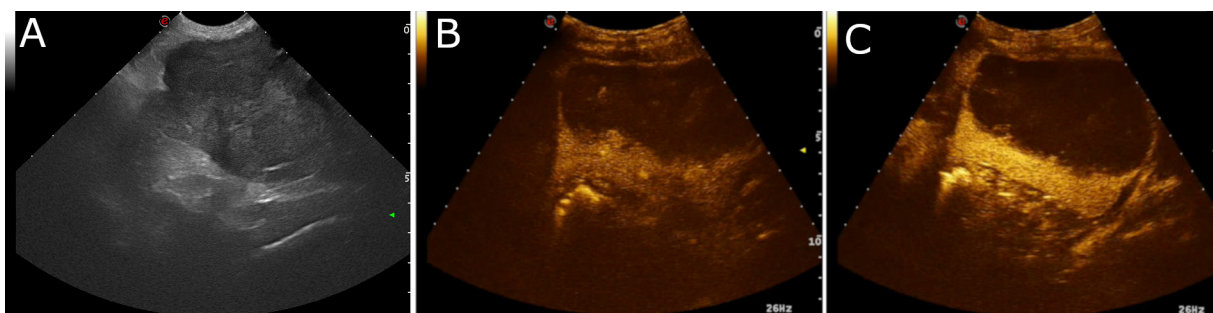


Figure 11 Contrast-enhanced ultrasonographic (CEUS) images of a well-differentiated hepatocellular carcinoma (HCC) showing inhomogeneous hyperenhancing wash-in and no wash-out. (A) B-mode ultrasonographic image of the lesion. (B, C) CEUS images of the lesion 15 seconds and 45 seconds after contrast medium injection, respectively.

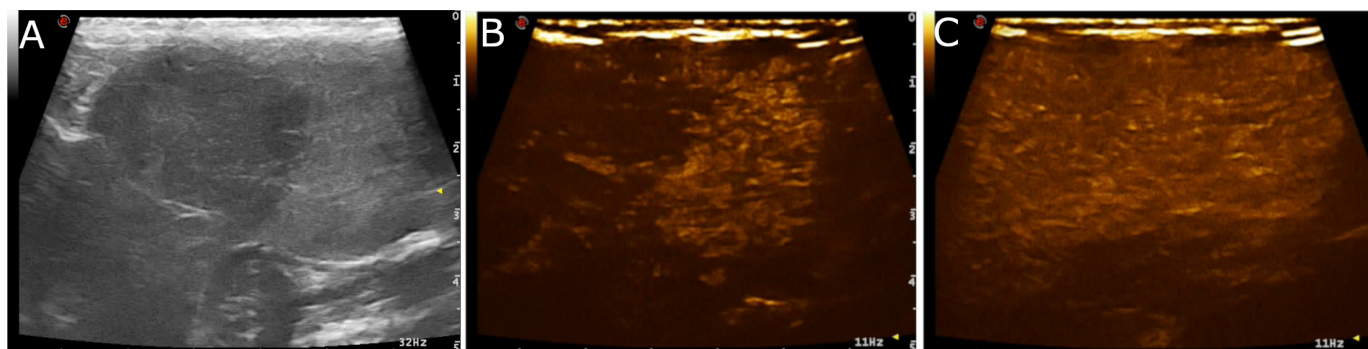


Figure 12 Contrast-enhanced ultrasonographic (CEUS) images of a well-differentiated hepatocellular carcinoma (HCC) showing homogeneous hyperenhancing wash-in and iso-enhancement in the late phase (no-wash-out). (A) B-mode ultrasonographic image of the lesion. (B, C) CEUS images of the lesion 15 seconds and 45 seconds after contrast medium injection, respectively.

papers.⁵⁻⁸ For example, Ivancic *et al*⁸, described that most of the haemangiosarcomas reported in their study were hypoenhancing in all the phases, a feature that was also found in eight HCCs of the present study cases. Further studies, possibly including a large number of cases, are required to determine the characteristic CEUS features of each tumour type.

One of the main limitations of this work is that most of the lesions were diagnosed only through cytology, which is reported to have a lower accuracy than histopathology in the evaluation of liver masses.³⁰ Cytology is reported to have a low sensitivity (34.8 per cent) but an extremely high positive predictive value (100 per cent) for HCC.³⁰ It should be stressed that all the cases in which cytopathological results were not unequivocal (ie, when HCC was included only within differential diagnoses) were excluded from the present study. Nevertheless, hyperplastic nodules or adenomas cannot be completely ruled out if the lesion has the cytological characteristics of a well-differentiated HCC.²⁴ Benign liver nodules⁵ (such as adenomas or hyperplastic nodules) are reported to be mostly isoechoic to the liver parenchyma in all phases (15/16 cases included in the study by O'Brien *et al* and 5/6 in the study by Nakamura *et al*). None of the cases included in this study showed such CEUS features. The characteristic CEUS features of the liver are due to the peculiar vascularisation of this organ. Therefore, lesions that retain the normal hepatic vasculature (such as adenomas and hyperplastic nodules) are more likely to show the same CEUS features of the normal liver. On

the contrary, more aggressive and disruptive lesions, such as HCCs, are significantly related to different CEUS features.

A possible limitation is that the cytological specimens were evaluated by the different pathologists working in the two institutions included in the study but were not reviewed by a single pathologist for this study. In this way some interobserver variability in the classification of the samples might have occurred.

Another important limitation is that the conditions of the liver parenchyma were not evaluated in any study subject. The World Federation for Ultrasound in Medicine and Biology clinical practice recommendations for the application of CEUS to the diagnosis of liver diseases in human medicine make a clear distinction between the CEUS features of HCCs in the non-cirrhotic and the cirrhotic liver.³ Nevertheless, more recent studies^{18 19} showed no significant influence of the hepatic background on the CEUS characteristics of HCCs.

The influence of both cellular differentiation and lesion size on the wash-in and the wash-out patterns suggests that other diagnostic tools, such as cytology or histopathology, should be used along with CEUS in the diagnosis or follow-up of HCC. To conclude, CEUS might be useful as an ancillary imaging technique in the diagnosis of liver masses or as an alternative tool when cytology cannot be performed safely (eg, when the lesion is near a main vessel, or when the patient has clotting problems). Another possible application of CEUS is in the non-invasive follow-up of already

	Total	Wash-out in arterial phase	Wash-out in portal phase	Wash-out in late phase	No wash-out
Cellular differentiation					
Well differentiated	38 (63.3)	0	25 (65.8)	7 (23.7)	6 (10.5)
Moderately/poorly differentiated	22 (36.7)	0	16 (72.7)	2 (9.1)	4 (18.2)
P value			0.790	0.288	0.652
Lesion size					
Up to 3 cm	14 (33.3)	0	9 (64.3)	4 (28.6)	1 (7.1)
Above 3 cm	46 (66.7)	0	32 (69.6)	7 (15.2)	7 (15.2)
P value			0.963	0.459	0.739

diagnosed lesions. Indeed, a variation in the CEUS features of an HCC in time, for example changing from homogeneous to inhomogeneous hyperenhancement, might suggest a transition from a well-differentiated to a moderately/poorly differentiated HCC.

Funding The present paper is part of a project funded by a Research Grant from the Department of Animal Medicine, production and Health – MAPS, University of Padua, Italy: SID- Zotti 2018 (€ 32.000; Application of deep-learning algorithms in pet animals diagnostic imaging).

Competing interests None declared.

Patient consent for publication Not required.

Data availability statement All data relevant to the study are included in the article.

Open access This is an open access article distributed in accordance with the Creative Commons Attribution Non Commercial (CC BY-NC 4.0) license, which permits others to distribute, remix, adapt, build upon this work non-commercially, and license their derivative works on different terms, provided the original work is properly cited, an indication of whether changes were made, and the use is non-commercial. See: <http://creativecommons.org/licenses/by-nc/4.0/>.

© British Veterinary Association 2019. Re-use permitted under CC BY-NC. No commercial re-use. Published by BMJ.

ORCID iDs

Tommaso Banzato <http://orcid.org/0000-0002-1261-9033>
Riccardo Orlandi <http://orcid.org/0000-0002-6544-0256>

References

- Haers H, Saunders JH. Review of clinical characteristics and applications of contrast-enhanced ultrasonography in dogs. *J Am Vet Med Assoc* 2009;234:460–70.
- Claudon M, Dietrich CF, Choi BI, et al. Guidelines and good clinical practice recommendations for Contrast Enhanced Ultrasound (CEUS) in the liver - update 2012: A WFUMB-EFSUMB initiative in cooperation with representatives of AFSUMB, AIUM, ASUM, FLAUS and ICUS. *Ultrasound Med Biol* 2013;39:187–210.
- Piscaglia F, Nolsøe C, Dietrich C, et al. The EFSUMB guidelines and recommendations on the clinical practice of contrast enhanced ultrasound (CEUS): update 2011 on non-hepatic applications. *Ultraschall in Med* 2012;33:33–59.
- Heimbach JK, Kulik LM, Finn RS, et al. AASLD guidelines for the treatment of hepatocellular carcinoma. *Hepatology* 2018;67:358–80.
- O'Brien RT, Iani M, Matheson J, et al. Contrast harmonic ultrasound of spontaneous liver nodules in 32 dogs. *Vet Radiol Ultrasound* 2004;45:547–53.
- Kanemoto H, Ohno K, Nakashima K, et al. Characterization of canine focal liver lesions with contrast-enhanced ultrasound using a novel contrast agent-sonazoid. *Vet Radiol Ultrasound* 2009;50:188–94.
- Nakamura K, Takagi S, Sasaki N, et al. Contrast-Enhanced ultrasonography for characterization of canine focal liver lesions. *Vet Radiol Ultrasound* 2010;51:79–85.
- Ivančić M, Long F, Seiler GS. Contrast harmonic ultrasonography of splenic masses and associated liver nodules in dogs. *J Am Vet Med Assoc* 2009;234:88–94.
- Morishita K, Hiramoto A, Michishita A, et al. Washout ratio in the hepatic vein measured by contrast-enhanced ultrasonography to distinguish between inflammatory and noninflammatory hepatic disorders in dogs. *J Vet Intern Med* 2017;31:770–7.
- Bargellini P, Orlandi R, Paloni C, et al. Contrast-Enhanced ultrasound complements two-dimensional ultrasonography in diagnosing gallbladder diseases in dogs. *Vet Radiol Ultrasound* 2018;59:345–56.
- Macrì F, Di Pietro S, Mangano C, et al. Quantitative evaluation of canine urinary bladder transitional cell carcinoma using contrast-enhanced ultrasonography. *BMC Vet Res* 2018;14:84.
- Feliciano MAR, Ramirez RAU, Maronezi MC, et al. Accuracy of four ultrasonography techniques in predicting histopathological classification of canine mammary carcinomas. *Vet Radiol Ultrasound* 2018;59:444–52.
- Bargellini P, Orlandi R, Dentini A, et al. Use of contrast-enhanced ultrasound in the differential diagnosis of adrenal tumors in dogs. *J Am Anim Hosp Assoc* 2016;52:132–43.
- Withrow SJ, Page R, Vail D. Withrow and MacEwen's Small Animal Clinical Oncology. Elsevier, 2013. <https://linkinghub.elsevier.com/retrieve/pii/C20090531352>
- Liptak JM, Dernell WS, Monnet E, et al. Massive hepatocellular carcinoma in dogs: 48 cases (1992–2002). *J Am Vet Med Assoc* 2004;225:1225–30.
- Cullen JM. Tumors of the liver and gallbladder. *tumors Domestic Anim*, 2016: 602–31.
- Jang H-J, Kim TK, Burns PN, et al. Enhancement patterns of hepatocellular carcinoma at contrast-enhanced us: comparison with histologic differentiation. *Radiology* 2007;244:898–906.
- Yang D, Li R, Zhang X-H, et al. Perfusion characteristics of hepatocellular carcinoma at contrast-enhanced ultrasound: influence of the cellular differentiation, the tumor size and the underlying hepatic condition. *Sci Rep* 2018;8:1–10.
- Jin C, Zhang X-Y, Li J-W, et al. Impact of tumor size and cirrhotic background for differentiating HCC and ICC with CEUS: does it matter for patients undergoing hepatectomy? *Oncotarget* 2017;8.
- Lee DH, Lee JM, Kang TW, et al. Clinical outcomes of radiofrequency ablation for early hypovascular HCC: a multicenter retrospective study. *Radiology* 2018;286:338–49.
- Ryu M-O, Lee S-H, Ahn J-O, et al. Treatment of solid tumors in dogs using veterinary high-intensity focused ultrasound: a retrospective clinical study. *Vet J* 2018;234:126–9.
- Chevallier P, Baudin G, Anty R, et al. Treatment of hepatocellular carcinomas by thermal ablation and hepatic transarterial chemoembolization. *Diagn Interv Imaging* 2015;96:637–46.
- Livraghi T, Mäkitalo H, Line P-D. Treatment options in hepatocellular carcinoma today. *Scand J Surg* 2011;100:22–9.
- Masserdotti C, Drigo M. Retrospective study of cytologic features of well-differentiated hepatocellular carcinoma in dogs. *Vet Clin Pathol* 2012;41:382–90.
- Meyer DJ. The Liver. In: Ruskin RE, Meyer DJ, Louis S, eds. *Canine and feline cytology. A color atlas and interpretation guide*. 2nd ed. Saunders Elsevier, 2010: 242–3.
- Campbell I, Chi-squared CI. Chi-squared and Fisher-Irwin tests of two-by-two tables with small sample recommendations. *Stat Med* 2007;26:3661–75.
- Mazzaferro V, Bhoori S, Sposito C, et al. Milan criteria in liver transplantation for hepatocellular carcinoma: an evidence-based analysis of 15 years of experience. *Liver Transpl* 2011;17 Suppl 2:S44–57.
- Galle PR, Forner A, Llovet JM. EASL clinical practice guidelines: management of hepatocellular carcinoma. *J Hepatol* 2018;69:182–236.
- Kutara K, Asano K, Kito A, et al. Contrast harmonic imaging of canine hepatic tumors. *J Vet Med Sci* 2006;68:433–8.
- Bahr KL, Sharkey LC, Murakami T, et al. Accuracy of US-guided fna of focal liver lesions in dogs: 140 cases (2005–2008). *J Am Anim Hosp Assoc* 2013;49:190–6.

