

# World Journal of *Gastroenterology*

*World J Gastroenterol* 2020 April 14; 26(14): 1546-1682



**FIELD OF VISION**

- 1546 SARS-COV-2 infection (coronavirus disease 2019) for the gastrointestinal consultant  
*Hajifathalian K, Mahadev S, Schwartz RE, Shah S, Sampath K, Schnoll-Sussman F, Brown Jr RS, Carr-Locke D, Cohen DE, Sharaiha RZ*

**OPINION REVIEW**

- 1554 Optimized timing of using infliximab in perianal fistulizing Crohn's disease  
*Sun XL, Chen SY, Tao SS, Qiao LC, Chen HJ, Yang BL*

**REVIEW**

- 1564 Intestinal epithelial barrier and neuromuscular compartment in health and disease  
*D'Antongiovanni V, Pellegrini C, Fornai M, Colucci R, Blandizzi C, Antonioli L, Bernardini N*
- 1580 Gastrointestinal cancer stem cells as targets for innovative immunotherapy  
*Chivu-Economescu M, Necula LG, Matei L, Dragu DL, Neagu AI, Alexiu I, Bleotu C, Diaconu CC*

**MINIREVIEWS**

- 1594 Is the measurement of drain amylase content useful for predicting pancreas-related complications after gastrectomy with systematic lymphadenectomy?  
*Nakanishi K, Kanda M, Sakamoto J, Kodera Y*

**ORIGINAL ARTICLE****Basic Study**

- 1601 Silymarin, boswellic acid and curcumin enriched dietetic formulation reduces the growth of inherited intestinal polyps in an animal model  
*Girardi B, Pricci M, Giorgio F, Piazzolla M, Iannone A, Losurdo G, Principi M, Barone M, Ierardi E, Di Leo A*

**Retrospective Cohort Study**

- 1613 Lifestyle factors and long-term survival of gastric cancer patients: A large bidirectional cohort study from China  
*Zhao LL, Huang H, Wang Y, Wang TB, Zhou H, Ma FH, Ren H, Niu PH, Zhao DB, Chen YT*

**Retrospective Study**

- 1628 Optimal treatment strategies for hepatic portal venous gas: A retrospective assessment  
*Gonda M, Osuga T, Ikura Y, Hasegawa K, Kawasaki K, Nakashima T*
- 1638 Clinical and microbiological characteristics of patients with biliary disease  
*Gu XX, Zhang MP, Zhao YF, Huang GM*

- 1647** Development and validation of a prediction model for microvascular invasion in hepatocellular carcinoma  
*Wang L, Jin YXZ, Ji YZ, Mu Y, Zhang SC, Pan SY*

**Prospective Study**

- 1660** Macrophage inhibitory cytokine-1/growth differentiation factor-15 in premalignant and neoplastic tumours in a high-risk pancreatic cancer cohort  
*O'Neill RS, Emmanuel S, Williams D, Stoita A*

**CASE REPORT**

- 1674** Small bowel racemose hemangioma complicated with obstruction and chronic anemia: A case report and review of literature  
*Fu JX, Zou YN, Han ZH, Yu H, Wang XJ*

**ABOUT COVER**

Associate Editor of *World Journal of Gastroenterology*, Yung-Jue Bang, MD, PhD, Professor, Department of Internal Medicine, Seoul National University College of Medicine, Seoul 110-744, South Korea

**AIMS AND SCOPE**

The primary aim of *World Journal of Gastroenterology* (*WJG*, *World J Gastroenterol*) is to provide scholars and readers from various fields of gastroenterology and hepatology with a platform to publish high-quality basic and clinical research articles and communicate their research findings online.

*WJG* mainly publishes articles reporting research results and findings obtained in the field of gastroenterology and hepatology and covering a wide range of topics including gastroenterology, hepatology, gastrointestinal endoscopy, gastrointestinal surgery, gastrointestinal oncology, and pediatric gastroenterology.

**INDEXING/ABSTRACTING**

The *WJG* is now indexed in Current Contents®/Clinical Medicine, Science Citation Index Expanded (also known as SciSearch®), Journal Citation Reports®, Index Medicus, MEDLINE, PubMed, PubMed Central, and Scopus. The 2019 edition of Journal Citation Report® cites the 2018 impact factor for *WJG* as 3.411 (5-year impact factor: 3.579), ranking *WJG* as 35<sup>th</sup> among 84 journals in gastroenterology and hepatology (quartile in category Q2). CiteScore (2018): 3.43.

**RESPONSIBLE EDITORS FOR THIS ISSUE**

Responsible Electronic Editor: *Yan-Liang Zhang*  
 Proofing Production Department Director: *Yun-Xiaojuan Wu*  
 Responsible Editorial Office Director: *Ze-Mao Gong*

**NAME OF JOURNAL**

*World Journal of Gastroenterology*

**ISSN**

ISSN 1007-9327 (print) ISSN 2219-2840 (online)

**LAUNCH DATE**

October 1, 1995

**FREQUENCY**

Weekly

**EDITORS-IN-CHIEF**

Subrata Ghosh, Andrzej S Tarnawski

**EDITORIAL BOARD MEMBERS**

<http://www.wjgnet.com/1007-9327/editorialboard.htm>

**PUBLICATION DATE**

April 14, 2020

**COPYRIGHT**

© 2020 Baishideng Publishing Group Inc

**INSTRUCTIONS TO AUTHORS**

<https://www.wjgnet.com/bpg/gerinfo/204>

**GUIDELINES FOR ETHICS DOCUMENTS**

<https://www.wjgnet.com/bpg/GerInfo/287>

**GUIDELINES FOR NON-NATIVE SPEAKERS OF ENGLISH**

<https://www.wjgnet.com/bpg/gerinfo/240>

**PUBLICATION ETHICS**

<https://www.wjgnet.com/bpg/GerInfo/288>

**PUBLICATION MISCONDUCT**

<https://www.wjgnet.com/bpg/gerinfo/208>

**ARTICLE PROCESSING CHARGE**

<https://www.wjgnet.com/bpg/gerinfo/242>

**STEPS FOR SUBMITTING MANUSCRIPTS**

<https://www.wjgnet.com/bpg/GerInfo/239>

**ONLINE SUBMISSION**

<https://www.f6publishing.com>

## Intestinal epithelial barrier and neuromuscular compartment in health and disease

Vanessa D'Antongiovanni, Carolina Pellegrini, Matteo Fornai, Rocchina Colucci, Corrado Blandizzi, Luca Antonioli, Nunzia Bernardini

**ORCID number:** Vanessa D'Antongiovanni (0000-0002-3303-0674); Carolina Pellegrini (0000-0003-2644-5430); Matteo Fornai (0000-0002-0812-3959); Rocchina Colucci (0000-0002-2593-5457); Corrado Blandizzi (0000-0001-9927-5386); Luca Antonioli (0000-0002-0246-4242); Nunzia Bernardini (0000-0001-9061-9402).

### Author contributions:

D'Antongiovanni V and Pellegrini C equally contribute to the manuscript; D'Antongiovanni V, Pellegrini C, Antonioli L, Blandizzi C and Bernardini N conceived the manuscript and contributed to drafting; D'Antongiovanni V, Pellegrini C, Colucci R, Fornai M, Antonioli L, Blandizzi C and Bernardini N contributed to search and selection of abstracts, review of the full length articles and writing the final version of the manuscript. D'Antongiovanni V, Pellegrini C, Colucci R, Fornai M, Antonioli L, Blandizzi C and Bernardini N read and approved the final manuscript.

### Conflict-of-interest statement:

Authors declare no conflict of interests for this article.

### Open-Access:

This article is an open-access article that was selected by an in-house editor and fully peer-reviewed by external reviewers. It is distributed in accordance with the Creative Commons Attribution NonCommercial (CC BY-NC 4.0) license, which permits others to

**Vanessa D'Antongiovanni, Matteo Fornai, Corrado Blandizzi, Luca Antonioli, Nunzia Bernardini,** Department of Clinical and Experimental Medicine, University of Pisa, Pisa 56126, Italy

**Carolina Pellegrini,** Department of Pharmacy, University of Pisa, Pisa 56126, Italy

**Rocchina Colucci,** Department of Pharmaceutical and Pharmacological Sciences, University of Padova, Padova 35131, Italy

**Corresponding author:** Matteo Fornai, PharmD, PhD, Assistant Professor, Unit of Pharmacology and Pharmacovigilance, Department of Clinical and Experimental Medicine, University of Pisa, Via Roma 55, Pisa 56126, Italy. [matteo.fornai@unipi.it](mailto:matteo.fornai@unipi.it)

### Abstract

A number of digestive and extra-digestive disorders, including inflammatory bowel diseases, irritable bowel syndrome, intestinal infections, metabolic syndrome and neuropsychiatric disorders, share a set of clinical features at gastrointestinal level, such as infrequent bowel movements, abdominal distension, constipation and secretory dysfunctions. Several lines of evidence indicate that morphological and molecular changes in intestinal epithelial barrier and enteric neuromuscular compartment contribute to alterations of both bowel motor and secretory functions in digestive and extra-digestive diseases. The present review has been conceived to provide a comprehensive and critical overview of the available knowledge on the morphological and molecular changes occurring in intestinal epithelial barrier and enteric neuromuscular compartment in both digestive and extra-digestive diseases. In addition, our intent was to highlight whether these morphological and molecular alterations could represent a common path (or share some common features) driving the pathophysiology of bowel motor dysfunctions and related symptoms associated with digestive and extra-digestive disorders. This assessment might help to identify novel targets of potential usefulness to develop original pharmacological approaches for the therapeutic management of such disturbances.

**Key words:** Digestive disease; Enteric nervous system; Intestinal epithelial barrier; Intestinal motility; Metabolic disorders; Neuropsychiatric disorders

©The Author(s) 2020. Published by Baishideng Publishing Group Inc. All rights reserved.

**Core tip:** Current evidence suggests that impairments of intestinal epithelial barrier and

distribute, remix, adapt, build upon this work non-commercially, and license their derivative works on different terms, provided the original work is properly cited and the use is non-commercial. See: <http://creativecommons.org/licenses/by-nc/4.0/>

**Manuscript source:** Unsolicited manuscript

**Received:** December 17, 2019

**Peer-review started:** December 17, 2019

**First decision:** January 16, 2020

**Revised:** March 4, 2020

**Accepted:** March 9, 2020

**Article in press:** March 9, 2020

**Published online:** April 14, 2020

**P-Reviewer:** Tang ST

**S-Editor:** Wang J

**L-Editor:** A

**E-Editor:** Zhang YL



enteric neuromuscular compartment might represent a common condition underlying the onset/progression of bowel functional disturbances in both digestive and extra-digestive diseases. In this review, we summarize the impact of morphological and molecular alterations occurring in intestinal epithelial barrier and enteric neuromuscular compartment on bowel motor and secretory functions in digestive and extra-digestive diseases. This assessment, beyond to provide insight on the pathophysiology of bowel motor dysfunctions, could pave the way to the identification of novel therapeutic targets for the management of bowel dysfunctions associated with digestive and extra-digestive disorders.

**Citation:** D'Antongiovanni V, Pellegrini C, Fornai M, Colucci R, Blandizzi C, Antonioli L, Bernardini N. Intestinal epithelial barrier and neuromuscular compartment in health and disease. *World J Gastroenterol* 2020; 26(14): 1564-1579

**URL:** <https://www.wjgnet.com/1007-9327/full/v26/i14/1564.htm>

**DOI:** <https://dx.doi.org/10.3748/wjg.v26.i14.1564>

## INTRODUCTION

A number of digestive and extra-digestive disorders, such as inflammatory bowel diseases (IBDs), irritable bowel syndrome (IBS), intestinal infections, metabolic syndrome and neuropsychiatric disorders, share a set of clinical features at gastrointestinal (GI) level. Digestive functional disturbances, such as infrequent bowel movements, abdominal distension, constipation and secretory dysfunctions, are often complained by patients affected by the above diseases, undermining their quality of life and contributing relevantly to morbidity<sup>[1-4]</sup>.

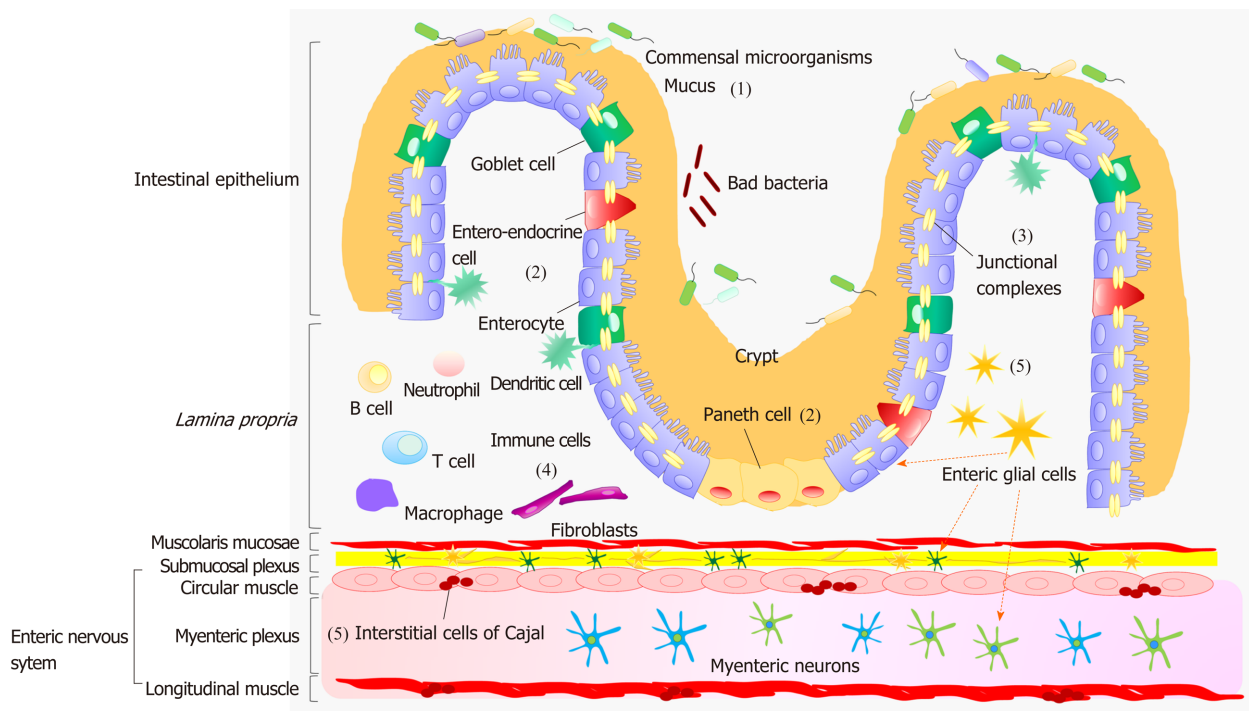
Several lines of evidence indicate that morphological and molecular changes in intestinal epithelial barrier (IEB) and enteric neuromuscular compartment can be associated with both digestive and extra-digestive diseases. For instance, both IBD and obese patients are characterized by an impairment of IEB and remodeling of enteric neuromuscular compartment, which appear to contribute to alterations of both intestinal motor and secretory functions<sup>[5,6]</sup>. In parallel, the same or similar morphofunctional GI alterations characterize different neuropsychiatric disorders, such as Parkinson's disease (PD), Alzheimer's disease (AD), multiple sclerosis (MS), amyotrophic lateral sclerosis (ALS), autism spectrum disorder (ASD) and depression<sup>[7-9]</sup>.

Based on this background, the present review has been conceived to provide a comprehensive and critical overview of available knowledge on the morphological and molecular changes occurring in IEB and enteric neuromuscular compartment in both digestive and extra-digestive diseases. In addition, our intent was to highlight whether these alterations could represent a common path (or share some common features) driving the pathophysiology of bowel motor dysfunctions and related symptoms associated with digestive and extra-digestive disorders. This assessment might help to identify novel targets of potential usefulness to develop novel pharmacological approaches for the therapeutic management of such disturbances.

## MORPHOLOGY AND FUNCTION OF IEB AND NEUROMUSCULAR COMPARTMENT UNDER PHYSIOLOGICAL CONDITIONS

A dynamic interplay, occurring between IEB, enteric immune system and neuromuscular compartment, contributes relevantly to the maintenance of gut homeostasis<sup>[10]</sup>. The IEB represents the main physical barrier between the lumen and tissue compartments<sup>[11]</sup>. The luminal surface of intestinal mucosa is covered by a hydrated gel, consisting mainly of mucins secreted by goblet cells<sup>[11]</sup>. The outer mucus layer provides a habitat for commensal microorganisms, while the inner mucus layer acts as a physical barrier preventing the penetration of microorganisms and other noxious agents into bowel tissues<sup>[11]</sup> (Figure 1). Under physiological conditions, there is an equilibrium between the mucus secretion rate and its erosion, due to the movement of luminal contents, ensuring a stable thicknesses of the mucus layer.

Below the mucus layer, the IEB, an epithelial cell monolayer arranged into finger-



**Figure 1** Diagram showing the morphology of intestinal epithelial barrier and neuromuscular compartment. (1) The intestinal mucosa is covered by a hydrated gel, consisting mainly of mucins secreted by goblet cells. The outer mucus layer provides a habitat for commensal microorganisms, while the inner mucus layer acts as a physical barrier preventing the penetration of microorganisms and other noxious agents into bowel tissues; (2) The epithelium includes: enterocytes that act as a selective physical barrier and regulate nutrient absorption, goblet cells, entero-endocrine cells that release intestinal hormones or peptides, and Paneth cells that regulate microbial populations and protect neighboring stem cells; (3) Junctional complexes confer mechanical strength to the intestinal epithelial barrier and regulate paracellular permeability; (4) The *lamina propria*, besides containing a number of innate and adaptive immune cells that respond to the insults with the secretion of inflammatory mediators, such as prostaglandins, histamine, and cytokines, is characterized by an intricate network of fibroblasts playing a key role in the proliferation of intestinal epithelium; and (5) Enteric glial cells, a cellular component of the enteric nervous system, are associated with both submucosal and myenteric neurons and are located also in proximity of epithelial cells. They coordinate signal propagation from and to myenteric neurons and epithelial cells, thus regulating bowel motility as well as the secretory and absorptive functions of enteric epithelium; interstitial cells of Cajal are the source of the electrical slow waves responsible for the transmission of excitation to the neighboring smooth muscle cells.

like protrusions (villi) and invaginations (crypts), forms a selective physical barrier<sup>[1]</sup>. The villi provide an efficient surface for nutrient absorption, while stem cells, located at the basis of crypts, give rise to several types of epithelial cells: Enterocytes, goblet cells, entero-endocrine cells and Paneth cells<sup>[1]</sup> (Figure 1). Enterocytes are the major cell type in intestinal epithelium. Beyond their critical role as selective physical barrier, they tightly regulate the nutrient absorption (e.g., ions, water, sugar, peptides, and lipids) as well as the secretion of immunoglobulins. In parallel, the entero-endocrine cells release intestinal hormones or peptides into bloodstream upon stimulation, to activate nervous responses. Finally, Paneth cells, located at the base of small intestinal crypts, regulate microbial populations and protect neighboring stem cells, through the secretion of antimicrobial peptides<sup>[1]</sup>.

The IEB holds three fundamental functions: (1) It acts as a physical barrier, preventing the passage of harmful intraluminal entities; (2) It operates as a selective filter, allowing the passage of nutrients and water; and (3) It has secretory functions, such as the release of mucus and immunoglobulins<sup>[1]</sup>.

The efficiency of IEB depends on the maintenance of its integrity, ensured by three junctional complexes that join adjacent epithelial cells and include tight junctions (TJs), adherent junctions and desmosomes<sup>[1]</sup> (Figure 1). TJs, the most apical intercellular junctions, consist of trans-membrane proteins, such as claudins, occludin and tri-cellulin, which are anchored to the actin cytoskeleton *via* a cytoplasmic plaque including the zona occludens (ZO-1, ZO-2 and ZO-3)<sup>[1]</sup>. Adherent junctions, located just beneath TJs, share a common structural organization with the junctional complex mentioned above. Desmosomes are located along the lateral membranes beneath adherent junctions. The main tasks of such junctional complexes are to confer mechanical strength to the IEB and regulate paracellular permeability<sup>[1]</sup>.

With regard for the enteric immune system, several review articles have provided a thorough overview about the intricate networks occurring among the immune cells, resident both in the *lamina propria* and Peyer's patches, and the mucosal and neuromuscular compartment<sup>[10]</sup> (Figure 1).

The enteric nervous system (ENS) holds a pivotal role in shaping the majority of GI functions<sup>[12]</sup>. This nervous network is arranged into two plexuses: The submucosal plexus (or Meissner's plexus), located in the submucosa, and the myenteric plexus (or Auerbach's plexus), located between the circular and longitudinal muscle layer<sup>[12]</sup> (Figure 1). The neurons of submucosal plexus, besides contributing to the motor control of smooth muscles, regulate secretive and absorptive functions, whereas those of the myenteric plexus are involved mainly in the initiation and control of gut motor activity<sup>[12]</sup>. The ENS, beyond the regulation of GI motor functions, contributes to the control of key functions involved in the maintenance of IEB homeostasis, including paracellular or transcellular permeability, epithelial cell proliferation and TJ expression; it regulates also several mucosal functions, independently of cerebral inputs<sup>[13]</sup>.

Among the cellular components of ENS, there is increasing evidence highlighting a pivotal involvement of enteric glial cells (EGCs), interstitial cells of Cajal (ICC) and smooth muscle cells in the regulation of gut homeostasis. EGCs are associated with both submucosal and myenteric neurons and are located also in proximity to epithelial cells<sup>[12]</sup>. They coordinate signal propagation from and to myenteric neurons and epithelial cells, thus taking a significant part to the control of bowel motility as well as the secretory and absorptive functions of the enteric epithelium<sup>[14,15]</sup> (Figure 1). A crucial role in the control of the motor functions of enteric smooth myocytes is played by the ICC, located in the tunica muscularis<sup>[12]</sup>. These cells generate spontaneous and rhythmic electrical activity, on the basis of which they are considered as pacemakers for gut motility<sup>[12]</sup> (Figure 1). The muscular compartment consists of two layers of smooth muscle cells: The circular one, where fibers are oriented along the transversal axis and generate forward transit with relatively little mixing, and the longitudinal muscle layer, equipped with fibers oriented along the longitudinal axis, that, beyond the maintenance of intestinal muscle tone, contributes to shorten the lumen and support the propulsion<sup>[12]</sup> (Figure 1). The outer surface of the muscular layer is covered by the adventitia, which secretes lubricating fluids to reduce friction generated by muscle movements<sup>[12]</sup>.

Overall, the structural and functional integrity of IEB and neuromuscular compartment are essential to ensure an adequate implementation of digestive motor and secretory functions. In particular, a proper interplay between IEB and ENS gives rise to a dynamic network aimed at coordinating the GI physiology and preserving the integrity of gut microenvironment.

---

## MORPHOLOGICAL FEATURES OF IEB AND NEUROMUSCULAR COMPARTMENT IN DIGESTIVE DISEASES

---

### IBDs

IBDs, comprising mainly ulcerative colitis (UC) and Crohn's disease (CD), are chronic intestinal inflammatory disorders, characterized clinically by abdominal pain, diarrhea or constipation, and weight loss<sup>[1]</sup>. Anatomically, UC is restricted to the rectum, colon and caecum, while CD can affect the entire GI tract, although it commonly affects the terminal ileum and colon<sup>[1]</sup>. Currently, the etiology of IBDs has not been completely elucidated. Intensive research efforts have been focused on the characterization of the role of IEB and enteric neuromuscular compartment in the onset of IBDs and related digestive disturbances.

Several studies have documented a defective mucus layer in IBD patients. In particular, the histological analysis of UC colonic biopsies has shown a depletion of goblet cells, a reduced mucin glycosylation, and a decrease in mucin (MUC)-2 biosynthesis and secretion<sup>[16-19]</sup>. By contrast, CD patients display an abnormal glycosylation and mucin hyperproduction accompanied by goblet cell hyperplasia<sup>[17]</sup> (Table 1). Such alterations can increase the epithelial permeability to luminal bacteria and microbial products, which, upon interaction with immune cells, trigger and maintain the inflammatory response<sup>[18-20]</sup>.

A common feature of IBD patients is the increase in paracellular permeability due to TJ abnormalities that, besides altering the transport of solutes and water and causing leak flux diarrhea, allow the tissue penetration of large molecules and luminal pathogens, triggering innate immune responses<sup>[5,21,22]</sup>. In this regard, IBD patients have been found to display an increased expression of claudin-2 and claudin-18 as well as a decreased expression and tissue redistribution of occludin, along with an increased serum ZO-1 concentration<sup>[5,23-26]</sup> (Table 1).

IBD patients are commonly affected by GI motility disorders<sup>[27,28]</sup>. Indeed, changes in small bowel transit have been reported in both UC and CD patients<sup>[27]</sup>. Consistent



**Table 1 Summary of current human and experimental data on molecular, morphological and functional changes in intestinal epithelial barrier and neuromuscular compartment in digestive disorders**

Digestive disorder	Morphofunctional changes in intestinal epithelial barrier	Morphofunctional changes in enteric neuromuscular compartment	Notes	Ref.
<b>Human investigations</b>				
IBD	Altered composition of mucus layer	↓ Myenteric neurons (b)	(a) UC ↓ claudin-1 and -4; CD ↓ claudin-3, -5 and -8	[5,16-19,23-26,29-36]
	Abnormal glycosylation of mucins	↑ SP release (c)	(b) Another study reported an increment of the enteric neuron number	
	↑ Paracellular and transcellular permeability	↑ NK-1 and NK-2 receptors		
	↑ Claudin-2 and claudin-18 (a)	Altered morphology of ICC	(c) Other authors reported a significant reduction of both AChE activity and ACh release in IBD patients suffering from moderate-severe disease, as compared with healthy controls or IBD patients with low disease severity	
	↓ Occludin and ZO-1	Functional alterations of EGCs		
IBS	↑ Mucus secretion	↓ Thickness of muscle layer	(d) Positive correlation between increased intestinal permeability and visceral pain	[51,54-63]
	↑ Paracellular permeability (d)	↑ Entero-endocrine cell activity		
	↓ Occludin and ZO-1	↑ SP release (f)		
	Altered expression of claudins (e)	Altered circulating levels of 5-HT	(e) IBS-D: ↓ claudin-1 and claudin-4, resulting in diarrhea; IBS-C: ↑ claudin-1, claudin-3 and claudin-4, resulting in constipation	
		Altered number and morphology of ICC ↑ EGC density	(f) Positive correlation between increased SP release and pain scores	
Intestinal infections	Altered composition of mucus layer	↓ Circulating levels of 5-HT		[72,74,75,76,78,79]
	↓ Goblet cell number	↑ SP release		
	↑ Paracellular permeability altered TJs			
	↑ Epithelial apoptosis			
Diverticulosis and diverticulitis	↑ Mucosal folds	Altered smooth muscle cells	(g) A more recent study did not observe alterations of ENS	[77,80-83]
	Mucosal ulcerations	Altered serotonergic system		
	Crypt distortion	↑ Tachykinergic contractile activity		
		↓ Cholinergic pathway activity		
		↓ ICC number ↓ EGC density (g)		
<b>Experimental models</b>				
IBD	Altered composition of mucus layer	↓ Myenteric neurons		[37-50]
	↓ Goblet cell number	Altered morphology of ICC		
	↑ Paracellular and transcellular permeability	↓ EGC density		
	↑ Claudin-1 and claudin-2			
	↓ Occludin and ZO-1			
IBS	↑ Mucus secretion	↓ Thickness of muscle layer	(h) Positive correlation between increased intestinal permeability and visceral pain	[63,65-68,70]
	↑ Paracellular permeability (h)	Altered number of ICC		
	↓ Occludin and ZO-1	↑ SP release		

Intestinal infections		↓ Circulating levels of 5-HT	
		↑ EGC density	
	↑ MUC1 expression	↑ SP release	[84-87]
	↓ MUC2 expression		
	↑ Paracellular permeability		
	Altered TJs		

↑: Increase; ↓: Decrease; 5-HT: Serotonin; Ach: Acetylcholine; AChE: Acetylcholinesterase; CD: Crohn's disease; EGCs: Enteric glial cells; ENS: Enteric nervous system; IBD: Inflammatory bowel disease; IBS: Irritable bowel syndrome; IBS-C: IBS with constipation; IBS-D: IBS with diarrhea; ICC: Interstitial cells of Cajal; MUC: Mucin; NK: Neurokinin; SP: Substance P; TJ: Tight junction; UC: Ulcerative colitis; ZO-1: Zonulin-1.

with these clinical findings, several lines of evidence indicate the occurrence of neuroplastic changes in the neuromuscular compartment and suggest that these are critical steps in contributing to the alterations of digestive motility in the presence of IBDs. In particular, several studies have described a reduction of myenteric neurons<sup>[29]</sup>, mainly in UC than CD tissues<sup>[30]</sup>, likely resulting from increased apoptotic processes, not restricted to specific neural populations<sup>[31]</sup>. IBD patients display also subtle changes in the expression of enteric neurotransmitters or their receptors. For instance, high levels of substance P (SP) and upregulation of NK-1 and NK-2 receptors have been observed in the colon and rectum of IBD patients<sup>[32-34]</sup>. Other human studies reported morphological abnormalities of ICC and EGCs, that could participate to the initiation/maintenance of IBDs and their associated symptoms<sup>[28,29,35]</sup>. In support of this view, histological examinations of UC and CD bowel biopsies pointed out an increase in glial fibrillary acidic protein (GFAP), S100 calcium-binding protein B (S100B), and glial cell line-derived neurotrophic factor (GDNF) in the inflamed area, suggesting that EGCs were activated during the inflammatory processes<sup>[36]</sup> (Table 1).

The mechanisms underlying pathological interplays among immune/inflammatory processes, IEB, neuromuscular compartment and bowel motor dysfunctions in IBDs remain to be elucidated. In this respect, interesting evidence comes from studies on IBD animal models. *Il10*<sup>-/-</sup> mice (lacking the expression of IL-10 and developing colitis spontaneously), as well as colitis induced by dextran sodium sulfate (DSS) or dinitrobenzene sulfonic acid (DNBS) display a significant loss of goblet cells and alterations of mucus layer composition, implying a dysfunction in the mucus barrier permeability<sup>[18,37-39]</sup>. In addition, mouse with DSS colitis showed a reduced expression of occludin and ZO-1 as well as an increase of claudin-1 and claudin-2, along with a marked increase in apoptotic death of epithelial cells<sup>[40,41]</sup> (Table 1). Of note, the reduction of ZO-1 expression was found to precede the onset of intestinal inflammation, suggesting that the ZO-1 alteration was not a consequence of the inflammatory process, but rather an early event, prodromal to the onset of colitis<sup>[40]</sup>. In support to this view, studies conducted in *Il10*<sup>-/-</sup> mice, beyond showing alterations of villus and crypt architecture, displayed an increment of intestinal permeability, that occurred as a primary defect, before the onset of mucosal inflammation, suggesting a disruption of IEB<sup>[42,43]</sup>.

The occurrence of ENS abnormalities, including axonal hypertrophy, a decrease in the number of enteric neurons and morphological alterations of ICC, has been described also in animal models of IBD<sup>[44-48]</sup>. Brown *et al*<sup>[49]</sup> reported that the activation of EGCs in the context of neuroinflammation induce enteric neuronal death in DNBS-treated mice, suggesting that glial response to inflammatory mediators might contribute to the development of bowel motor abnormalities. Currently, only one pre-clinical study, conducted in rats with 2,4,6-trinitrobenzene sulfonic acid (TNBS) colitis, reported a loss of EGCs following bowel inflammation, demonstrating that colitis can affect differently the EGCs in the submucosal and myenteric plexus<sup>[50]</sup> (Table 1). Of note, at present studies on histological alterations of EGC markers such as GFAP, S100B and GDNF in animal tissues of IBDs are lacking. Therefore, further investigations should be implemented to help better clarifying putative correlations among the morphofunctional alterations of EGCs, bowel inflammation and motor dysfunctions in IBDs.

### IBS

IBS is a frequent disorder affecting up to 15%-25% of the adult population<sup>[2]</sup>. IBS patients are classified into subtypes by predominant stool pattern: IBS with diarrhea (IBS-D); constipation (IBS-C); mixed (IBS-M); and untyped IBS (IBS-U)<sup>[2]</sup>. Among the patients complaining of constipation, 11% have functional slow transit constipation (STC); such patients differ from IBS-C due to the absence of abdominal pain. Emerging evidence suggests that, beyond psychosocial factors and low-grade

intestinal inflammation, alterations of IEB and enteric neuromuscular compartment could contribute to IBS onset, development and related symptoms.

Human studies have reported a status of exuberant mucin secretion by goblet cells along with an increased paracellular permeability due to TJ abnormalities in IBS patients<sup>[51]</sup>. The increment of IEB permeability is thought to represent an important step in the sequence of events leading to the onset of low-grade intestinal inflammation and disturbed bowel functions<sup>[52,53]</sup>. The integrity of IEB in IBS patients has been investigated by evaluating the urinary excretion of oral probes, such as <sup>13</sup>C mannitol<sup>[54]</sup>. This approach has allowed to document an increase in the intestinal permeability of IBS patients, likely reflecting alterations of TJs occurring during the acute phase of the disorder<sup>[54]</sup>. Histological examinations of colonic biopsies showed an abnormal cellular distribution of claudins as well as a reduced expression of ZO-1 and occludin in all IBS subtypes as compared to healthy controls<sup>[51,55,56]</sup> (Table 1). Currently there is no evidence regarding changes in IEB in STC patients.

As far as the neuromuscular compartment is concerned, several alterations have been described in patients, suggesting their contribution to the pathophysiology of IBS symptoms, such as bowel dysmotility. However, no predominant patterns of motor activity have emerged as markers for IBS. In this context, translational evidence highlighted a hypertrophy of the muscle layer, mainly in IBS-D patients, and alterations of the number and size of ICC both in IBS and STC patients<sup>[57-60]</sup>. Cheng *et al.*<sup>[51]</sup> reported an abnormal density of entero-endocrine cells in rectal biopsies of IBS patients, along with a strong secretory status, suggesting that the endocrine system may play an important role in the pathophysiology of IBS. Other studies observed an increase in circulating serotonin levels in IBS-D patients, contrary to IBS-C, characterized by reduced levels of circulating serotonin<sup>[61,62]</sup>. These findings suggest that serotonin, beyond regulating gut motility, plays an important role in immune activation and inflammation, thus contributing to the pathophysiology of IBS. Currently, only few studies have taken into consideration the morphology of EGCs in IBS. For instance, Wang *et al.*<sup>[63]</sup> observed an increment of EGCs in the colonic mucosa of IBS patients (Table 1). By contrast, STC patients displayed a significant decrease in EGCs in both the myenteric and submucosal plexus<sup>[64]</sup>. At present, there is no evidence to explain the relationship between the altered number of EGCs and bowel motor dysfunctions in IBS and STC patients. Therefore further studies are needed.

Consistently with human findings, an increment of mucus secretion and hyperplasia of goblet cells has been observed in IBS animal models<sup>[65]</sup>. In addition, in an IBS-D rat model induced by acetic acid, a significant reduction of ZO-1 and occludin expression has been shown<sup>[66]</sup>. These findings suggest that morphological alterations of mucus layer and TJ proteins could contribute to the increased sensitivity to visceral pain and other aspects of IBS symptoms<sup>[65,67]</sup> (Table 1).

The occurrence of ENS abnormalities has been described also in IBS animal models. Indeed, similarly to patients, murine models of IBS showed a significant reduction of the total thickness of muscle layer and alterations of ICC<sup>[65,68]</sup>. Likewise, Wang *et al.*<sup>[69]</sup> showed a significant reduction of ICC number in a rat model of STC. Thus, current data from human and pre-clinical studies indicate that changes in ICC numbers are closely associated with alterations of intestinal motor patterns in both IBS and STC<sup>[57,68,70]</sup>. Of interest, similarly to IBS patients, Wang *et al.*<sup>[63]</sup> reported an increase in the number of EGCs, observing a positive correlation between changes in EGCs and abdominal pain (Table 1).

### Other digestive disorders

For a variety of digestive disorders, such as intestinal infections and diverticular disease (including diverticulosis and diverticulitis), the pathogenesis remains unclear and several hypotheses have been formulated. Nevertheless, alterations of IEB and enteric neuromuscular compartment have been described as common features likely involved in the pathogenesis and progression of these diseases.

In intestinal infections, the presence of pathogens in the intestine can induce pathological alterations of the mucus layer and IEB, resulting in the onset of inflammatory responses within the gut wall<sup>[71]</sup>. Indeed, infectious agents may damage the intestinal mucosa by a direct interaction with mucins or the release of toxins<sup>[72,73]</sup>. In this regard, human studies have documented a depletion of goblet cells and an altered composition of mucus, resulting in an enhanced interaction between harmful intraluminal entities and enteric epithelium, exacerbating intestinal inflammation<sup>[72,74]</sup>. On the other hand, infectious agents have developed mechanisms that target the host's TJs. Clinical data from norovirus-infected patients showed a flattening of epithelium and a severe loss of villi as well as a reduction of TJ expression and an increment of epithelial apoptosis<sup>[75,76]</sup> (Table 1).

When considering the morphofunctional alterations of the mucus layer and IEB occurring in diverticular disease, a limited number of clinical data are currently

available. For instance, a recent study showed a prominent mucosal folding with crypt distortion, mucosal ulcerations and infiltration of inflammatory cells in patients with diverticulitis<sup>[77]</sup> (Table 1).

With regard for the neuromuscular compartment, structural and functional abnormalities have been observed, either in patients with intestinal infections and subjects affected by diverticular disease. A common feature in such disorders is the alteration of enteric neurotransmitters. Clinical evidence in *Giardia duodenalis*-infected patients showed a reduction of circulating serotonin and a decreased number of serotonin-containing enterochromaffin cells in the duodenal mucosa<sup>[78]</sup>. Other authors reported an increment of SP levels in the gut of patients infected with *Cryptosporidium*<sup>[79]</sup> (Table 1). Similarly to intestinal infections, patients with diverticular disease displayed alterations of the serotonergic system<sup>[80]</sup> and an increment of tachykinergic motor activity as well as a reduction of cholinergic motility<sup>[81]</sup>. Other authors reported an altered expression patterns of important molecular factors involved in the regulation of smooth muscle cells contractility at level of the *tunica muscularis*<sup>[82]</sup>. In addition, Wedel *et al.*<sup>[83]</sup> observed a thickening of muscle layers, along with a reduced number of EGCs and ICC (Table 1).

Consistently with human findings, pre-clinical studies in mice infected with *Citrobacter rodentium* or *Campylobacter jejuni*, beyond showing a depletion of MUC2, displayed an increment of MUC1 secretion<sup>[84]</sup>. Such an increase, observed both in human and pre-clinical studies, highlights a mechanism of host defense aimed at trapping parasites in the mucus, thereby favoring their expulsion. On the other hand, Elmi *et al.*<sup>[85]</sup> reported an increment of IEB permeability due to TJ alterations in mice infected with *Campylobacter jejuni*, *Escherichia coli* and *Citrobacter rodentium*, that contributed to promote bacterial invasion into host cells and the development of inflammatory process (Table 1).

When considering the morphofunctional alterations of neuromuscular compartment in animal models of intestinal infections, some authors reported a significant increase in SP levels in *Cryptosporidium*-infected macaque or rats infected with *Trichinella spiralis*, suggesting a relationship between the SP content and inflammation associated with pathogen invasion as well as a positive correlation between SP levels and the severity of diarrhea<sup>[86,87]</sup> (Table 1). Current animal models of diverticular disease, based on low-fiber diets, have generated very inconsistent results and/or a significant impairment of the systemic health status<sup>[88]</sup>. Thus, at present, pre-clinical studies on the histological alterations of IEB and ENS in models of diverticular disease are strongly needed.

---

## MORPHOLOGICAL FEATURES OF IEB AND NEUROMUSCULAR COMPARTMENT IN EXTRA-DIGESTIVE DISEASES

---

### ***Metabolic disorders (obesity and diabetes)***

Patients with metabolic disorders, including obesity and type 2 diabetes mellitus, often experience GI dysfunctions, such as impaired gastric emptying, infrequent bowel movements and constipation<sup>[3]</sup>. In this setting, several lines of evidence support the contention that a chronic low-grade systemic inflammatory condition, besides interfering with the metabolic processes, could contribute to alterations of IEB and enteric neuromuscular compartment, which, in turn, could lead to the onset of bowel motor abnormalities.

A recent study showed that obese patients display an increase in IEB permeability, along with a decreased expression of occludin and tri-cellulin as well as an increase in circulating lipopolysaccharide (LPS), an indirect index of intestinal permeability, and ZO-1 levels<sup>[6]</sup> (Table 2). However, despite these interesting observations, human studies, showing a correlation between altered IEB, changes in the enteric neuromuscular compartment and intestinal motor dysfunctions, are currently lacking. In this respect, pioneering evidence, supporting the relevance of IEB alterations in the pathophysiology of bowel dysmotility in metabolic disorders, comes from pre-clinical studies. For instance, mice with high fat diet (HFD)-induced obesity displayed a decrease in ZO-1, occludin and claudin expression, as well as an increase in circulating LPS levels<sup>[89-91]</sup>. Likewise, leptin-deficient mice (genetic model of obesity) showed an increased IEB permeability along with morphological changes in villi/crypt length and decreased expression of TJ- and mucus-related genes, that could contribute to the alterations of intestinal motility<sup>[92]</sup> (Table 2).

Of note, pre-clinical studies have shown that obese mice are characterized by a remarkable morphofunctional rearrangement of the ENS, such as a decrease in the density of nitrergic and VIPergic neurons and an altered intestinal smooth muscle cell

**Table 2 Summary of current human and experimental data on molecular, morphological and functional changes in intestinal epithelial barrier and neuromuscular compartment in metabolic disorders**

Metabolic disorder	Morphofunctional changes in intestinal epithelial barrier	Morphofunctional changes in enteric neuromuscular compartment	Ref.
<b>Human investigations</b>			
Obesity	↑ Circulating LPS ↓ Occludin and tri-cellulin immunopositivity ↑ ZO-1	NA	[6]
Diabetes	↑ Intestinal permeability (urinary excretion of lactulose)	NA	[6]
<b>Experimental models</b>			
HFD-induced obese mice	↓ ZO-1, occludin and claudins ↑ Circulating LPS	↓ Nitroergic and VIPergic neurons Altered smooth muscle cell excitability ↓ Enteric inhibitory neurotransmission ↑ Enteric excitatory tachykinergic neurotransmission ↑ SP immunopositivity ↑ A <sub>2B</sub> adenosine receptor expression	[89-91,93,94,96,97]
Lep ob/ob mice	↑ Intestinal permeability Alterations of villi/crypt length ↓ TJs and mucus-related genes	NA	[92]
Ob/ob mice	↑ Paracellular permeability Altered TJs	↓ Intestinal motor activity ↓ ACh receptors Delayed intestinal transit rate	[95]

↑: Increase; ↓: Decrease; A<sub>2B</sub>: Adenosine 2B receptor; Ach: Acetylcholine; HFD: High-fat diet; Lep: Leptin; LPS: Lipopolysaccharide; NA: Not available; Ob/ob: Obese mice; SP: Substance P; TJ: Tight junction; ZO-1: Zonulin-1.

excitability, with consequent impairment of enteric inhibitory neurotransmission<sup>[93,94]</sup>. In addition, Schacht *et al*<sup>[95]</sup> showed that ob/ob mice (a genetic model of diabetes) displayed a decrease in the intestinal transit rate, likely resulting from a loss of acetylcholine receptors in muscle layers and an impaired intestinal motor activity (Table 2). These findings support the view that alterations of the enteric neuromuscular compartment could contribute to bowel dysmotility in metabolic disorders. Consistently with this hypothesis, a recent study showed that HFD mice displayed a marked enhancement of enteric excitatory tachykinergic neurotransmission along with an increase in SP immunoreactivity that contributes to colonic dysmotility<sup>[96]</sup>. In addition, these authors demonstrated that an increase in colonic adenosine A<sub>2B</sub> receptor expression modulated the activity of excitatory tachykinergic nerves, participating to the enteric dysmotility associated with obesity<sup>[97]</sup> (Table 2).

### Neuropsychiatric disorders

Patients with neuropsychiatric diseases, including PD, AD, ALS, MS, ASD and depression, are often characterized by functional digestive disturbances, including infrequent bowel movements, abdominal distension and constipation<sup>[4]</sup>. Several lines of evidence suggest that changes in gut microbiota composition, impairments of IEB, intestinal inflammation and rearrangements of the enteric neuromuscular compartment contribute to these bowel motor dysfunctions<sup>[4]</sup>. In this section, we summarize the most prominent data about the morphofunctional changes in IEB and neuromuscular compartment in the most common central nervous system (CNS) disorders.

Patients with early PD display an increase in IEB permeability, which correlates with staining of intestinal mucosa for *Escherichia coli*, tissue oxidative stress and enteric  $\alpha$ -synuclein accumulation<sup>[98]</sup>. Clairembault *et al*<sup>[99]</sup> reported an alteration of occludin expression in colonic biopsies from PD patients, although the paracellular and transcellular permeability did not differ among PD patients and controls. Others observed an increase in IEB permeability and decreased colonic ZO-1 expression in

PD patients with severe intestinal symptoms, thus supporting the view that morphofunctional alterations of IEB could contribute to bowel motor dysfunctions in PD<sup>[7]</sup>. Of note, changes in intestinal permeability have been documented also in patients with MS and ASD, and in all these settings the respective patterns appear to correlate with the disability status<sup>[8,9]</sup> (Table 3). Nevertheless, current evidence doesn't allow to establish a clear casual link between IEB alterations and bowel motor dysfunctions in CNS disorders.

Besides IEB alterations, several evidence suggest that patients with CNS diseases display alterations of enteric neuromuscular compartment, that could contribute to bowel dysmotility. A recent study has reported an increment of EGCs in colonic biopsies from PD patients<sup>[100]</sup>. Wunsch *et al*<sup>[101]</sup> described the presence of ENS nerve fiber disintegration and EGC activation in MS patients. Others reported an increased  $\alpha$ -synuclein as well as  $\beta$ -amyloid (A $\beta$ ) protein,  $\beta$ -amyloid protein precursor (A $\beta$ PP) and phosphorylated Tau (p-Tau) immunoreactivity in colonic myenteric and submucosal neurons from PD and AD patients, respectively, suggesting that morphological changes in ENS and protein accumulation in enteric neurons could contribute to bowel motor dysfunctions in CNS diseases<sup>[98,102]</sup> (Table 3).

However, current human studies don't allow to establish a clear casual link among changes in IEB, alterations of neuromuscular compartment and bowel motor dysfunctions in CNS disorders. In this regard, research efforts have been made in pre-clinical models of neurological disorders. Wu *et al*<sup>[103]</sup> showed an increase in circulating LPS levels, a decrease in ZO-1 and E-cadherin expression, and an abnormal increase in the number of Paneth cells in ALS mice. Other studies observed the concomitance of abnormal intestinal permeability, enteric  $\alpha$ -synuclein accumulation and delayed bowel transit in mice with PD induced by LPS and rotenone<sup>[7,104]</sup>. Recent pioneering studies in different animal models of PD highlighted relevant rearrangements in the chemical coding of both enteric inhibitory and excitatory neurons, along with impairments of ileum and colonic motor activity, which likely contribute to the decrease in small intestinal and colonic transit rate as well as the efficiency of peristaltic reflex<sup>[105-107]</sup>. Of note, alterations of enteric neurochemical coding, characterized by a decrease in neuronal nitric oxide synthase (nNOS) and choline acetyltransferase (ChAT), age-related loss of myenteric neurons, EGC activation, intestinal smooth muscle cell atrophy and altered bowel motility have been observed in several animal models of CNS diseases, including AD, MS and ALS<sup>[4]</sup> (Table 3).

---

## CONCLUSION

---

Current data from human and pre-clinical studies suggest that impairments of IEB and enteric neuromuscular compartment might represent a common condition underlying the onset/progression of bowel functional disturbances in both digestive and extra-digestive diseases. Indeed, even though each disease displays different clinical and neuropathological features, patients with IBD, IBS, intestinal infections, diverticular disease as well as metabolic and CNS disorders are characterized by significant molecular and morphofunctional alterations of IEB, ENS and intestinal muscular layers. In particular, changes in TJ protein expression and distribution as well as morphofunctional alterations of EGCs represent a common feature of such disorders, that could contribute to the pathophysiology of bowel motor disturbances. However, the molecular mechanisms underlying the interplays between IEB and enteric neuromuscular compartment as well as their role in the pathophysiology of bowel dysmotility in digestive and extra-digestive disorders remain to be elucidated.

Another important aspect of the current evidence from the literature is that changes in gut microbiota composition could also promote the development of functional bowel disorders<sup>[108,109]</sup>. Indeed, a number of exhaustive review articles have widely described changes of intestinal microbiota in patients with digestive and neuropsychiatric disorders<sup>[110-113]</sup>. However, human studies do not allow to establish a causal role between gut dysbiosis and bowel functional disturbances in digestive and extra-digestive diseases. Therefore, an integrated overview about the relationship between alterations in gut microbiota composition and bowel functional disturbances associated with digestive and extra-digestive diseases is missing and requires investigations.

In conclusion, based on current knowledge, some important issues remain to be addressed: (1) What is the role of IEB in bowel motor dysfunctions associated with digestive and extra-digestive diseases? (2) What are the molecular mechanisms underlying the interplay between IEB and enteric neuromuscular compartment in the onset of bowel motor abnormalities associated with digestive and extra-digestive

**Table 3 Summary of current human and experimental data on molecular, morphological and functional changes in intestinal epithelial barrier and neuromuscular compartment in central nervous system disorders**

Central nervous system disorder	Morphofunctional changes in intestinal epithelial barrier	Morphofunctional changes in enteric neuromuscular compartment	Ref.
<b>Human investigations</b>			
PD	↑ Intestinal permeability ↓ Occludin and ZO-1 expression	↑ EGC density α-syn accumulation in myenteric neurons	[7,98-100]
AD	NA	↑ Aβ, AβPP and p-Tau immunoreactivity in colonic myenteric and submucosal neurons	[102]
MS	↑ Intestinal permeability (urinary mannitol concentration)	ENS fiber disgregation EGC activation	[8,101]
ASD	Altered intestinal permeability	NA	[9]
<b>Experimental models</b>			
Rotenone-induced central dopaminergic neurodegeneration	↑ Intestinal permeability	α-syn accumulation in myenteric neurons Delayed bowel transit	[7,104]
LPS-induced central dopaminergic neurodegeneration	↑ intestinal permeability (lactulose/mannitol ratio and sucralose levels)	α-syn accumulation in myenteric neurons Delayed bowel transit	[7,104]
6-OHDA-induced nigrostriatal neurodegeneration	NA	Impairment of colonic cholinergic and tachykinergic motor activity	[105-106]
Tg A53T mice (genetic model of PD)	NA	Impairment of colonic cholinergic motor activity α-syn accumulation in myenteric and submucosal neurons	[107]
APP/PS1 mouse (genetic model of AD)	NA	↑ Aβ protein precursor, Aβ Protein and p-Tau ↓ nNOS and ChAT EGC activation	[4]
Tg CRND8 mice (genetic models of AD)	NA	↑ Aβ protein precursor in myenteric neurons Enteric glial activation (GFAP, nestin) Enteric neuronal loss Smooth muscle cell atrophy	[4]
EAE (animal model of MS)	Abnormal intestinal permeability (plasma Na-F and FITC levels) ↓ ZO-1 expression	Crypt depth and thickness of submucosal and muscular layers Enteric glial activation Neuronal loss Abnormal GI motility	[4]
G93A mice (genetic model of ALS)	↑ Circulating LPS ↓ ZO-1 and E-cadherin expression ↑ Paneth cells number	NA	[4,103]

↑: Increase; ↓: Decrease; 6-OHDA: 6-hydroxydopamine; α-syn: α-synuclein; Aβ: Amyloid β; AβPP: β-amyloid protein precursor; AD: Alzheimer's disease; ALS: Amyotrophic lateral sclerosis; ASD: Autism spectrum disorder; ChAT: Choline acetyltransferase; EGC: Enteric glial cell; ENS: Enteric nervous system; FITC: Fluorescein isothiocyanate; GFAP: Glial fibrillary acidic protein; GI: Gastrointestinal; LPS: Lipopolysaccharide; nNOS: Neuronal nitric oxide synthase; MS: Multiple sclerosis; NA: Not available; PD: Parkinson's disease; p-Tau: Phosphorylated Tau; ZO-1: Zonulin.

diseases? (3) Can diet influence the alterations of IEB and enteric neuromuscular compartment in digestive and extra-digestive diseases? And (4) What is the impact of gut dysbiosis in bowel motor dysfunctions associated with digestive and extra-digestive diseases?

To address these points, research efforts should be made to characterize simultaneously the alterations of IEB and neuromuscular compartment, regarded as an integrated network, in animal models and patients. Understanding these aspects could pave the way to the identification of novel therapeutic targets and the development of novel pharmacological entities for the management of bowel

dysfunctions associated with digestive and extra-digestive disorders. Indeed, at present, there is a lack of therapeutic interventions able to restore IEB integrity and dysfunctions of the enteric neuromuscular compartment. A limited number of clinical studies have reported some benefits in terms of improvement of IEB integrity and restoration of ENS functions, following the administration of probiotics and prebiotics. However, clinical results remain patchy due to heterogeneity of study protocols, related mainly to the selection of study population, sample size, dosage, formulation and bacterial strains used, as well as the duration of therapy and outcome measures. Therefore, intensive research efforts are needed to deepen the beneficial effects of probiotics and prebiotics observed in clinical studies. Moreover, further research in this area is necessary to identify novel therapeutic targets suitable for strengthening IEB and to treat or prevent GI disorders.

## REFERENCES

- 1 **Sairenji T**, Collins KL, Evans DV. An Update on Inflammatory Bowel Disease. *Prim Care* 2017; **44**: 673-692 [PMID: 29132528 DOI: 10.1016/j.pop.2017.07.010]
- 2 **Drossman DA**. Functional Gastrointestinal Disorders: History, Pathophysiology, Clinical Features and Rome IV. *Gastroenterology* 2016 [PMID: 27144617 DOI: 10.1053/j.gastro.2016.02.032]
- 3 **Le Pluart D**, Sabaté JM, Bouchoucha M, Hercberg S, Benamouzig R, Julia C. Functional gastrointestinal disorders in 35,447 adults and their association with body mass index. *Aliment Pharmacol Ther* 2015; **41**: 758-767 [PMID: 25728697 DOI: 10.1111/apt.13143]
- 4 **Pellegrini C**, Antonioli L, Colucci R, Blandizzi C, Fornai M. Interplay among gut microbiota, intestinal mucosal barrier and enteric neuro-immune system: a common path to neurodegenerative diseases? *Acta Neuropathol* 2018; **136**: 345-361 [PMID: 29797112 DOI: 10.1007/s00401-018-1856-5]
- 5 **Vivinus-Nébot M**, Frin-Mathy G, Bziouche H, Dainese R, Bernard G, Anty R, Filippi J, Saint-Paul MC, Tulic MK, Verhasselt V, Hébuterne X, Piche T. Functional bowel symptoms in quiescent inflammatory bowel diseases: role of epithelial barrier disruption and low-grade inflammation. *Gut* 2014; **63**: 744-752 [PMID: 23878165 DOI: 10.1136/gutjnl-2012-304066]
- 6 **Genser L**, Aguanno D, Soula HA, Dong L, Trystram L, Assmann K, Salem JE, Vaillant JC, Oppert JM, Laugerette F, Michalski MC, Wind P, Rousset M, Brot-Laroche E, Leturque A, Clément K, Thenet S, Poitou C. Increased jejunal permeability in human obesity is revealed by a lipid challenge and is linked to inflammation and type 2 diabetes. *J Pathol* 2018; **246**: 217-230 [PMID: 29984492 DOI: 10.1002/path.5134]
- 7 **Perez-Pardo P**, Dodiya HB, Engen PA, Forsyth CB, Huschens AM, Shaikh M, Voigt RM, Naqib A, Green SJ, Kordower JH, Shannon KM, Garssen J, Kraneveld AD, Keshavarzian A. Role of TLR4 in the gut-brain axis in Parkinson's disease: a translational study from men to mice. *Gut* 2019; **68**: 829-843 [PMID: 30554160 DOI: 10.1136/gutjnl-2018-316844]
- 8 **Buscarinu MC**, Cerasoli B, Annibali V, Policano C, Lionetto L, Capi M, Mechelli R, Romano S, Fornasiero A, Mattei G, Piras E, Angelini DF, Battistini L, Simmaco M, Umeton R, Salvetti M, Ristori G. Altered intestinal permeability in patients with relapsing-remitting multiple sclerosis: A pilot study. *Mult Scler* 2017; **23**: 442-446 [PMID: 27270497 DOI: 10.1177/1352458516652498]
- 9 **Fiorentino M**, Sapone A, Senger S, Camhi SS, Kadzielski SM, Buie TM, Kelly DL, Cascella N, Fasano A. Blood-brain barrier and intestinal epithelial barrier alterations in autism spectrum disorders. *Mol Autism* 2016; **7**: 49 [PMID: 27957319 DOI: 10.1186/s13229-016-0110-z]
- 10 **Veiga-Fernandes H**, Mucida D. Neuro-Immune Interactions at Barrier Surfaces. *Cell* 2016; **165**: 801-811 [PMID: 27153494 DOI: 10.1016/j.cell.2016.04.041]
- 11 **Salvo Romero E**, Alonso Cotoner C, Pardo Camacho C, Casado Bedmar M, Vicario M. The intestinal barrier function and its involvement in digestive disease. *Rev Esp Enferm Dig* 2015; **107**: 686-696 [PMID: 26541659 DOI: 10.17235/reed.2015.3846/2015]
- 12 **Furness JB**, Callaghan BP, Rivera LR, Cho HJ. The enteric nervous system and gastrointestinal innervation: integrated local and central control. *Adv Exp Med Biol* 2014; **817**: 39-71 [PMID: 24997029 DOI: 10.1007/978-1-4939-0897-4\_3]
- 13 **Puzan M**, Hasic S, Ghio C, Koppes A. Enteric Nervous System Regulation of Intestinal Stem Cell Differentiation and Epithelial Monolayer Function. *Sci Rep* 2018; **8**: 6313 [PMID: 29679034 DOI: 10.1038/s41598-018-24768-3]
- 14 **Savidge TC**, Newman P, Pothoulakis C, Ruhl A, Neunlist M, Bourreille A, Hurst R, Sofroniew MV. Enteric glia regulate intestinal barrier function and inflammation via release of S-nitrosoglutathione. *Gastroenterology* 2007; **132**: 1344-1358 [PMID: 17408650 DOI: 10.1053/j.gastro.2007.01.051]
- 15 **Delvalle NM**, Fried DE, Rivera-Lopez G, Gaudette L, Gulbransen BD. Cholinergic activation of enteric glia is a physiological mechanism that contributes to the regulation of gastrointestinal motility. *Am J Physiol Gastrointest Liver Physiol* 2018; **315**: G473-G483 [PMID: 29927320 DOI: 10.1152/ajpgi.00155.2018]
- 16 **Gersemann M**, Becker S, Kübler I, Koslowski M, Wang G, Herrlinger KR, Griger J, Fritz P, Fellermann K, Schwab M, Wehkamp J, Stange EF. Differences in goblet cell differentiation between Crohn's disease and ulcerative colitis. *Differentiation* 2009; **77**: 84-94 [PMID: 19281767 DOI: 10.1016/j.diff.2008.09.008]
- 17 **Dorofeyev AE**, Vasilenko IV, Rassokhina OA, Kondratiuk RB. Mucosal barrier in ulcerative colitis and Crohn's disease. *Gastroenterol Res Pract* 2013; **2013**: 431231 [PMID: 23737764 DOI: 10.1155/2013/431231]
- 18 **Johansson ME**, Gustafsson JK, Holmén-Larsson J, Jabbar KS, Xia L, Xu H, Ghishan FK, Carvalho FA, Gewirtz AT, Sjövall H, Hansson GC. Bacteria penetrate the normally impenetrable inner colon mucus layer in both murine colitis models and patients with ulcerative colitis. *Gut* 2014; **63**: 281-291 [PMID: 23426893 DOI: 10.1136/gutjnl-2012-303207]
- 19 **van der Post S**, Jabbar KS, Birchenough G, Arike L, Akhtar N, Sjövall H, Johansson MEV, Hansson GC. Structural weakening of the colonic mucus barrier is an early event in ulcerative colitis pathogenesis. *Gut* 2019; **68**: 2142-2151 [PMID: 30914450 DOI: 10.1136/gutjnl-2018-317571]



- 20 **Swidsinski A**, Loening-Baucke V, Theissig F, Engelhardt H, Bengmark S, Koch S, Lochs H, Dörffel Y. Comparative study of the intestinal mucus barrier in normal and inflamed colon. *Gut* 2007; **56**: 343-350 [PMID: 16908512 DOI: 10.1136/gut.2006.098160]
- 21 **Xu CM**, Li XM, Qin BZ, Liu B. Effect of tight junction protein of intestinal epithelium and permeability of colonic mucosa in pathogenesis of injured colonic barrier during chronic recovery stage of rats with inflammatory bowel disease. *Asian Pac J Trop Med* 2016; **9**: 148-152 [PMID: 26919945 DOI: 10.1016/j.apjtm.2016.01.001]
- 22 **Michielan A**, D'Inca R. Intestinal Permeability in Inflammatory Bowel Disease: Pathogenesis, Clinical Evaluation, and Therapy of Leaky Gut. *Mediators Inflamm* 2015; **2015**: 628157 [PMID: 26582965 DOI: 10.1155/2015/628157]
- 23 **Zeissig S**, Bürgel N, Günzel D, Richter J, Mankertz J, Wahnschaffe U, Kroesen AJ, Zeitz M, Fromm M, Schulzke JD. Changes in expression and distribution of claudin 2, 5 and 8 lead to discontinuous tight junctions and barrier dysfunction in active Crohn's disease. *Gut* 2007; **56**: 61-72 [PMID: 16822808 DOI: 10.1136/gut.2006.094375]
- 24 **Zwiers A**, Fuss IJ, Leijen S, Mulder CJ, Kraal G, Bouma G. Increased expression of the tight junction molecule claudin-18 A1 in both experimental colitis and ulcerative colitis. *Inflamm Bowel Dis* 2008; **14**: 1652-1659 [PMID: 18831034 DOI: 10.1002/ibd.20695]
- 25 **Yamamoto-Furusho JK**, Mendivil EJ, Fonseca-Camarillo G. Differential expression of occludin in patients with ulcerative colitis and healthy controls. *Inflamm Bowel Dis* 2012; **18**: E1999 [PMID: 22134947 DOI: 10.1002/ibd.22835]
- 26 **Caviglia GP**, Dughera F, Ribaldone DG, Rosso C, Abate ML, Pellicano R, Bresso F, Smedile A, Saracco GM, Astegiano M. Serum zonulin in patients with inflammatory bowel disease: a pilot study. *Minerva Med* 2019; **110**: 95-100 [PMID: 30160088 DOI: 10.23736/S0026-4806.18.05787-7]
- 27 **Fischer M**, Siva S, Wo JM, Fadda HM. Assessment of Small Intestinal Transit Times in Ulcerative Colitis and Crohn's Disease Patients with Different Disease Activity Using Video Capsule Endoscopy. *AAPS PharmSciTech* 2017; **18**: 404-409 [PMID: 27032935 DOI: 10.1208/s12249-016-0521-3]
- 28 **Bassotti G**, Villanacci V, Cathomas G, Maurer CA, Fisogni S, Cadei M, Baron L, Morelli A, Valloncini E, Salerni B. Enteric neuropathology of the terminal ileum in patients with intractable slow-transit constipation. *Hum Pathol* 2006; **37**: 1252-1258 [PMID: 16949932 DOI: 10.1016/j.humpath.2006.04.027]
- 29 **Bernardini N**, Segnani C, Ippolito C, De Giorgio R, Colucci R, Faussone-Pellegrini MS, Chiarugi M, Campani D, Castagna M, Mattii L, Blandizzi C, Dolfi A. Immunohistochemical analysis of myenteric ganglia and interstitial cells of Cajal in ulcerative colitis. *J Cell Mol Med* 2012; **16**: 318-327 [PMID: 21426484 DOI: 10.1111/j.1582-4934.2011.01298.x]
- 30 **Ganguli SC**, Kamath MV, Redmond K, Chen Y, Irvine EJ, Collins SM, Tougas G. A comparison of autonomic function in patients with inflammatory bowel disease and in healthy controls. *Neurogastroenterol Motil* 2007; **19**: 961-967 [PMID: 17931336 DOI: 10.1111/j.1365-2982.2007.00987.x]
- 31 **Bassotti G**, Villanacci V, Nascimbeni R, Cadei M, Fisogni S, Antonelli E, Corazzi N, Salerni B. Enteric neuroglial apoptosis in inflammatory bowel diseases. *J Crohns Colitis* 2009; **3**: 264-270 [PMID: 21172285 DOI: 10.1016/j.crohns.2009.06.004]
- 32 **Mazumdar S**, Das KM. Immunocytochemical localization of vasoactive intestinal peptide and substance P in the colon from normal subjects and patients with inflammatory bowel disease. *Am J Gastroenterol* 1992; **87**: 176-181 [PMID: 1370872]
- 33 **Goode T**, O'Connell J, Anton P, Wong H, Reeve J, O'Sullivan GC, Collins JK, Shanahan F. Neurokinin-1 receptor expression in inflammatory bowel disease: molecular quantitation and localisation. *Gut* 2000; **47**: 387-396 [PMID: 10940277 DOI: 10.1136/gut.47.3.387]
- 34 **Menzies JR**, McKee R, Corbett AD. Differential alterations in tachykinin NK2 receptors in isolated colonic circular smooth muscle in inflammatory bowel disease and idiopathic chronic constipation. *Regul Pept* 2001; **99**: 151-156 [PMID: 11384776 DOI: 10.1016/s0167-0115(01)00244-0]
- 35 **Rumessen JJ**, Vanderwinden JM, Horn T. Ulcerative colitis: ultrastructure of interstitial cells in myenteric plexus. *Ultrastruct Pathol* 2010; **34**: 279-287 [PMID: 20568987 DOI: 10.3109/01913121003770701]
- 36 **von Boyen GB**, Schulte N, Pflüger C, Spaniol U, Hartmann C, Steinkamp M. Distribution of enteric glia and GDNF during gut inflammation. *BMC Gastroenterol* 2011; **11**: 3 [PMID: 21235736 DOI: 10.1186/1471-230X-11-3]
- 37 **Morampudi V**, Bhinder G, Wu X, Dai C, Sham HP, Vallance BA, Jacobson K. DNBS/TNBS colitis models: providing insights into inflammatory bowel disease and effects of dietary fat. *J Vis Exp* 2014; e51297 [PMID: 24637969 DOI: 10.3791/51297]
- 38 **Schwerbrock NM**, Makkink MK, van der Sluis M, Büller HA, Einerhand AW, Sartor RB, Dekker J. Interleukin 10-deficient mice exhibit defective colonic Muc2 synthesis before and after induction of colitis by commensal bacteria. *Inflamm Bowel Dis* 2004; **10**: 811-823 [PMID: 15626900 DOI: 10.1097/00054725-200411000-00016]
- 39 **Dharmani P**, Leung P, Chadee K. Tumor necrosis factor- $\alpha$  and Muc2 mucin play major roles in disease onset and progression in dextran sodium sulphate-induced colitis. *PLoS One* 2011; **6**: e25058 [PMID: 21949848 DOI: 10.1371/journal.pone.0025058]
- 40 **Poritz LS**, Garver KI, Green C, Fitzpatrick L, Ruggiero F, Koltun WA. Loss of the tight junction protein ZO-1 in dextran sulfate sodium induced colitis. *J Surg Res* 2007; **140**: 12-19 [PMID: 17418867 DOI: 10.1016/j.jss.2006.07.050]
- 41 **Yuan B**, Zhou S, Lu Y, Liu J, Jin X, Wan H, Wang F. Changes in the Expression and Distribution of Claudins, Increased Epithelial Apoptosis, and a Mannan-Binding Lectin-Associated Immune Response Lead to Barrier Dysfunction in Dextran Sodium Sulfate-Induced Rat Colitis. *Gut Liver* 2015; **9**: 734-740 [PMID: 25717051 DOI: 10.5009/gnl14155]
- 42 **Gomes-Santos AC**, Moreira TG, Castro-Junior AB, Horta BC, Lemos L, Cruz DN, Guimarães MA, Cara DC, McCafferty DM, Faria AM. New insights into the immunological changes in IL-10-deficient mice during the course of spontaneous inflammation in the gut mucosa. *Clin Dev Immunol* 2012; **2012**: 560817 [PMID: 22400037 DOI: 10.1155/2012/560817]
- 43 **Madsen KL**, Malfair D, Gray D, Doyle JS, Jewell LD, Fedorak RN. Interleukin-10 gene-deficient mice develop a primary intestinal permeability defect in response to enteric microflora. *Inflamm Bowel Dis* 1999; **5**: 262-270 [PMID: 10579119 DOI: 10.1097/00054725-199911000-00004]
- 44 **Linden DR**, Couvrette JM, Ciolino A, McQuoid C, Blaszyk H, Sharkey KA, Mawe GM. Indiscriminate loss of myenteric neurones in the TNBS-inflamed guinea-pig distal colon. *Neurogastroenterol Motil* 2005; **17**: 751-760 [PMID: 16185315 DOI: 10.1111/j.1365-2982.2005.00703.x]
- 45 **Park JH**, Kwon JG, Kim SJ, Song DK, Lee SG, Kim ES, Cho KB, Jang BI, Kim DH, Sin JI, Kim TW,

- Song IH, Park KS. Alterations of colonic contractility in an interleukin-10 knockout mouse model of inflammatory bowel disease. *J Neurogastroenterol Motil* 2015; **21**: 51-61 [PMID: 25537671 DOI: 10.5056/jnm14008]
- 46 **Kiriukhin SO**, Makarova OV. [Morphological changes in the colonic muscular layer and interstitial cells of Cajal in experimental acute ulcerative colitis]. *Arkh Patol* 2016; **78**: 27-32 [PMID: 27804943 DOI: 10.17116/patol201678527-32]
- 47 **Dai YC**, Zheng L, Zhang YL, Chen X, Chen DL, Wang LJ, Tang ZP. Jianpi Qingchang decoction regulates intestinal motility of dextran sulfate sodium-induced colitis through reducing autophagy of interstitial cells of Cajal. *World J Gastroenterol* 2017; **23**: 4724-4734 [PMID: 28765693 DOI: 10.3748/wjg.v23.i26.4724]
- 48 **Ippolito C**, Segnani C, Errede M, Virgintino D, Colucci R, Fornai M, Antonioli L, Blandizzi C, Dolfi A, Bernardini N. An integrated assessment of histopathological changes of the enteric neuromuscular compartment in experimental colitis. *J Cell Mol Med* 2015; **19**: 485-500 [PMID: 25521239 DOI: 10.1111/jcmm.12428]
- 49 **Brown IA**, McClain JL, Watson RE, Patel BA, Gulbransen BD. Enteric glia mediate neuron death in colitis through purinergic pathways that require connexin-43 and nitric oxide. *Cell Mol Gastroenterol Hepatol* 2016; **2**: 77-91 [PMID: 26771001 DOI: 10.1016/j.jcmgh.2015.08.007]
- 50 **da Silva MV**, Marosti AR, Mendes CE, Palombit K, Castelucci P. Submucosal neurons and enteric glial cells expressing the P2X7 receptor in rat experimental colitis. *Acta Histochem* 2017; **119**: 481-494 [PMID: 28501138 DOI: 10.1016/j.acthis.2017.05.001]
- 51 **Cheng P**, Yao J, Wang C, Zhang L, Kong W. Molecular and cellular mechanisms of tight junction dysfunction in the irritable bowel syndrome. *Mol Med Rep* 2015; **12**: 3257-3264 [PMID: 25998845 DOI: 10.3892/mmr.2015.3808]
- 52 **Dunlop SP**, Hebden J, Campbell E, Naesdal J, Olbe L, Perkins AC, Spiller RC. Abnormal intestinal permeability in subgroups of diarrhea-predominant irritable bowel syndromes. *Am J Gastroenterol* 2006; **101**: 1288-1294 [PMID: 16771951 DOI: 10.1111/j.1572-0241.2006.00672.x]
- 53 **Martínez C**, Lobo B, Pigrau M, Ramos L, González-Castro AM, Alonso C, Guilarte M, Guilá M, de Torres I, Azpiroz F, Santos J, Vicario M. Diarrhoea-predominant irritable bowel syndrome: an organic disorder with structural abnormalities in the jejunal epithelial barrier. *Gut* 2013; **62**: 1160-1168 [PMID: 22637702 DOI: 10.1136/gutjnl-2012-302093]
- 54 **Grover M**, Camilleri M, Hines J, Burton D, Ryks M, Wadhwa A, Sundt W, Dyer R, Singh RJ. (13) C mannitol as a novel biomarker for measurement of intestinal permeability. *Neurogastroenterol Motil* 2016; **28**: 1114-1119 [PMID: 26914765 DOI: 10.1111/nmo.12802]
- 55 **Bertiaux-Vandaële N**, Youmba SB, Belmonte L, Lecleire S, Antonietti M, Gourcerol G, Leroi AM, Déchelotte P, Ménard JF, Ducrotté P, Coëffier M. The expression and the cellular distribution of the tight junction proteins are altered in irritable bowel syndrome patients with differences according to the disease subtype. *Am J Gastroenterol* 2011; **106**: 2165-2173 [PMID: 22008894 DOI: 10.1038/ajg.2011.257]
- 56 **Kong WM**, Gong J, Dong L, Xu JR. [Changes of tight junction claudin-1, -3, -4 protein expression in the intestinal mucosa in patients with irritable bowel syndrome]. *Nan Fang Yi Ke Da Xue Xue Bao* 2007; **27**: 1345-1347 [PMID: 17884774]
- 57 **Ohgo H**, Imaeda H, Yamaoka M, Yoneno K, Hosoe N, Mizukami T, Nakamoto H. Irritable bowel syndrome evaluation using computed tomography colonography. *World J Gastroenterol* 2016; **22**: 9394-9399 [PMID: 27895427 DOI: 10.3748/wjg.v22.i42.9394]
- 58 **Törnblom H**, Lindberg G, Nyberg B, Veress B. Full-thickness biopsy of the jejunum reveals inflammation and enteric neuropathy in irritable bowel syndrome. *Gastroenterology* 2002; **123**: 1972-1979 [PMID: 12454854 DOI: 10.1053/gast.2002.37059]
- 59 **Tong WD**, Liu BH, Zhang LY, Zhang SB, Lei Y. Decreased interstitial cells of Cajal in the sigmoid colon of patients with slow transit constipation. *Int J Colorectal Dis* 2004; **19**: 467-473 [PMID: 15045515 DOI: 10.1007/s00384-003-0577-x]
- 60 **Ohlsson B**, Gustafsson R, Swahn F, Toth E, Veress B, Thorlacius H. Endoscopic full-thickness biopsy, a novel method in the work up of complicated abdominal symptoms. *Therap Adv Gastroenterol* 2018; **11**: 1756283X17730747 [PMID: 29383022 DOI: 10.1177/1756283X17730747]
- 61 **Atkinson W**, Lockhart S, Whorwell PJ, Keevil B, Houghton LA. Altered 5-hydroxytryptamine signaling in patients with constipation- and diarrhea-predominant irritable bowel syndrome. *Gastroenterology* 2006; **130**: 34-43 [PMID: 16401466 DOI: 10.1053/j.gastro.2005.09.031]
- 62 **Fu R**, Chen M, Chen Y, Mao G, Liu S. Expression and clinical significance of 5-HT and 5-HT<sub>2R</sub> in the intestinal mucosa of patient with diarrhea-type irritable bowel syndrome. *Exp Ther Med* 2019; **17**: 3077-3082 [PMID: 30936979 DOI: 10.3892/etm.2019.7297]
- 63 **Wang P**, Du C, Chen FX, Li CQ, Yu YB, Han T, Akhtar S, Zuo XL, Tan XD, Li YQ. BDNF contributes to IBS-like colonic hypersensitivity via activating the enteroglia-nerve unit. *Sci Rep* 2016; **6**: 20320 [PMID: 26837784 DOI: 10.1038/srep20320]
- 64 **Bassotti G**, Villanacci V, Maurer CA, Fisogni S, Di Fabio F, Cadei M, Morelli A, Panagiotis T, Cathomas G, Salerni B. The role of glial cells and apoptosis of enteric neurones in the neuropathology of intractable slow transit constipation. *Gut* 2006; **55**: 41-46 [PMID: 16041063 DOI: 10.1136/gut.2005.073197]
- 65 **O'Malley D**, Julio-Pieper M, Gibney SM, Dinan TG, Cryan JF. Distinct alterations in colonic morphology and physiology in two rat models of enhanced stress-induced anxiety and depression-like behaviour. *Stress* 2010; **13**: 114-122 [PMID: 20214436 DOI: 10.3109/10253890903067418]
- 66 **Hou Q**, Huang Y, Zhu S, Li P, Chen X, Hou Z, Liu F. MiR-144 Increases Intestinal Permeability in IBS-D Rats by Targeting OCLN and ZO1. *Cell Physiol Biochem* 2017; **44**: 2256-2268 [PMID: 29258088 DOI: 10.1159/000486059]
- 67 **Da Silva S**, Robbe-Masselot C, Ait-Belgnaoui A, Mancuso A, Mercade-Loubière M, Salvador-Cartier C, Gillet M, Ferrier L, Loubière P, Dague E, Theodorou V, Mercier-Bonin M. Stress disrupts intestinal mucus barrier in rats via mucin O-glycosylation shift: prevention by a probiotic treatment. *Am J Physiol Gastrointest Liver Physiol* 2014; **307**: G420-G429 [PMID: 24970779 DOI: 10.1152/ajpgi.00290.2013]
- 68 **Yang B**, Zhou XC, Lan C. Impact of the alterations in the interstitial cells of Cajal on intestinal motility in post-infection irritable bowel syndrome. *Mol Med Rep* 2015; **11**: 2735-2740 [PMID: 25484117 DOI: 10.3892/mmr.2014.3039]
- 69 **Wang YB**, Ling J, Zhang WZ, Li G, Qiu W, Zheng JH, Zhao XH. Effect of bisacodyl on rats with slow transit constipation. *Braz J Med Biol Res* 2018; **51**: e7372 [PMID: 29846410 DOI: 10.1590/1414-431x20187372]
- 70 **Lin MJ**, Yu BP. Colonic Hypermotility in a Rat Model of Irritable Bowel Syndrome Is Associated with

- Upregulation of TMEM16A in Myenteric Plexus. *Dig Dis Sci* 2018; **63**: 3329-3338 [PMID: 30155840 DOI: 10.1007/s10620-018-5261-7]
- 71 **Khan WI**, Collins SM. Immune-mediated alteration in gut physiology and its role in host defence in nematode infection. *Parasite Immunol* 2004; **26**: 319-326 [PMID: 15679628 DOI: 10.1111/j.0141-9838.2004.00715.x]
- 72 **Engevik MA**, Yacyshyn MB, Engevik KA, Wang J, Darien B, Hassett DJ, Yacyshyn BR, Worrell RT. Human *Clostridium difficile* infection: altered mucus production and composition. *Am J Physiol Gastrointest Liver Physiol* 2015; **308**: G510-G524 [PMID: 2552581 DOI: 10.1152/ajpgi.00091.2014]
- 73 **Vesterlund S**, Karp M, Salminen S, Ouwehand AC. *Staphylococcus aureus* adheres to human intestinal mucus but can be displaced by certain lactic acid bacteria. *Microbiology* 2006; **152**: 1819-1826 [PMID: 16735744 DOI: 10.1099/mic.0.28522-0]
- 74 **Bergstrom KS**, Guttman JA, Rumi M, Ma C, Bouzari S, Khan MA, Gibson DL, Vogl AW, Vallance BA. Modulation of intestinal goblet cell function during infection by an attaching and effacing bacterial pathogen. *Infect Immun* 2008; **76**: 796-811 [PMID: 17984203 DOI: 10.1128/IAI.00093-07]
- 75 **Troeger H**, Loddenkemper C, Schneider T, Schreier E, Epple HJ, Zeitz M, Fromm M, Schulzke JD. Structural and functional changes of the duodenum in human norovirus infection. *Gut* 2009; **58**: 1070-1077 [PMID: 19036950 DOI: 10.1136/gut.2008.160150]
- 76 **Karandikar UC**, Crawford SE, Ajami NJ, Murakami K, Kou B, Ettayebi K, Papanicolaou GA, Jongwutiwes U, Perales MA, Shia J, Mercer D, Finegold MJ, Vinjé J, Atmar RL, Estes MK. Detection of human norovirus in intestinal biopsies from immunocompromised transplant patients. *J Gen Virol* 2016; **97**: 2291-2300 [PMID: 27412790 DOI: 10.1099/jgv.0.000545]
- 77 **Ambrosio MR**, Rocca BJ, Ginori A, Barone A, Onorati M, Lazzi S. Long pedunculated colonic polyp with diverticulosis: case report and review of the literature. *Pathologica* 2011; **103**: 8-10 [PMID: 21837918]
- 78 **Dizdar V**, Spiller R, Singh G, Hanevik K, Gilja OH, El-Salhy M, Hausken T. Relative importance of abnormalities of CCK and 5-HT (serotonin) in Giardia-induced post-infectious irritable bowel syndrome and functional dyspepsia. *Aliment Pharmacol Ther* 2010; **31**: 883-891 [PMID: 20132151 DOI: 10.1111/j.1365-2036.2010.04251.x]
- 79 **Robinson P**, Okhuysen PC, Chappell CL, Weinstock JV, Lewis DE, Actor JK, White AC. Substance P expression correlates with severity of diarrhea in cryptosporidiosis. *J Infect Dis* 2003; **188**: 290-296 [PMID: 12854086 DOI: 10.1086/376836]
- 80 **Böttner M**, Barrenschee M, Hellwig I, Harde J, Egberts JH, Becker T, Zorenkov D, Wedel T. The enteric serotonergic system is altered in patients with diverticular disease. *Gut* 2013; **62**: 1753-1762 [PMID: 23144076 DOI: 10.1136/gutjnl-2012-302660]
- 81 **Guagnini F**, Valenti M, Mukenge S, Matias I, Bianchetti A, Di Palo S, Ferla G, Di Marzo V, Croci T. Neural contractions in colonic strips from patients with diverticular disease: role of endocannabinoids and substance P. *Gut* 2006; **55**: 946-953 [PMID: 16423891 DOI: 10.1136/gut.2005.076372]
- 82 **Mattii L**, Ippolito C, Segnani C, Battolla B, Colucci R, Dolfi A, Bassotti G, Blandizzi C, Bernardini N. Altered expression pattern of molecular factors involved in colonic smooth muscle functions: an immunohistochemical study in patients with diverticular disease. *PLoS One* 2013; **8**: e7023 [PMID: 23437299 DOI: 10.1371/journal.pone.0057023]
- 83 **Wedel T**, Büsing V, Heinrichs G, Nohroudi K, Bruch HP, Roblick UJ, Böttner M. Diverticular disease is associated with an enteric neuropathy as revealed by morphometric analysis. *Neurogastroenterol Motil* 2010; **22**: 407-414, e93-e94 [PMID: 20040058 DOI: 10.1111/j.1365-2982.2009.01445.x]
- 84 **Lindén SK**, Florin TH, McGuckin MA. Mucin dynamics in intestinal bacterial infection. *PLoS One* 2008; **3**: e3952 [PMID: 19088856 DOI: 10.1371/journal.pone.0003952]
- 85 **Elmi A**, Nasher F, Jagatia H, Gundogdu O, Bajaj-Elliott M, Wren B, Dorrell N. *Campylobacter jejuni* outer membrane vesicle-associated proteolytic activity promotes bacterial invasion by mediating cleavage of intestinal epithelial cell E-cadherin and occludin. *Cell Microbiol* 2016; **18**: 561-572 [PMID: 26451973 DOI: 10.1111/cmi.12534]
- 86 **Swain MG**, Agro A, Blennerhassett P, Stanisz A, Collins SM. Increased levels of substance P in the myenteric plexus of *Trichinella*-infected rats. *Gastroenterology* 1992; **102**: 1913-1919 [PMID: 1375178 DOI: 10.1016/0016-5085(92)90313-n]
- 87 **Hernandez J**, Lackner A, Aye P, Mukherjee K, Twardy DJ, Mastrangelo MA, Weinstock J, Griffiths J, D'Souza M, Dixit S, Robinson P. Substance P is responsible for physiological alterations such as increased chloride ion secretion and glucose malabsorption in cryptosporidiosis. *Infect Immun* 2007; **75**: 1137-1143 [PMID: 17158891 DOI: 10.1128/IAI.01738-05]
- 88 **Patel B**, Guo X, Noblet J, Chambers S, Kassab GS. Animal Models of Diverticulosis: Review and Recommendations. *Dig Dis Sci* 2018; **63**: 1409-1418 [PMID: 29679297 DOI: 10.1007/s10620-018-5071-y]
- 89 **Nakadate K**, Hirakawa T, Tanaka-Nakadate S. Small intestine barrier function failure induces systemic inflammation in monosodium glutamate-induced chronically obese mice. *Appl Physiol Nutr Metab* 2019; **44**: 587-594 [PMID: 30345803 DOI: 10.1139/apnm-2018-0560]
- 90 **Ahmad R**, Rah B, Bastola D, Dhawan P, Singh AB. Obesity-induces Organ and Tissue Specific Tight Junction Restructuring and Barrier Deregulation by Claudin Switching. *Sci Rep* 2017; **7**: 5125 [PMID: 28698546 DOI: 10.1038/s41598-017-04989-8]
- 91 **Antonoli L**, D'Antongiovanni V, Pellegrini C, Fornai M, Benvenuti L, di Carlo A, van den Wijngaard R, Caputi V, Cerantola S, Giron MC, Németh ZH, Haskó G, Blandizzi C, Colucci R. Colonic dysmotility associated with high-fat diet-induced obesity: Role of enteric glia. *FASEB J* 2020 [PMID: 32086846 DOI: 10.1096/fj.201901844R]
- 92 **Nagpal R**, Newman TM, Wang S, Jain S, Lovato JF, Yadav H. Obesity-Linked Gut Microbiome Dysbiosis Associated with Derangements in Gut Permeability and Intestinal Cellular Homeostasis Independent of Diet. *J Diabetes Res* 2018; **2018**: 3462092 [PMID: 30250849 DOI: 10.1155/2018/3462092]
- 93 **Soares A**, Beraldi EJ, Ferreira PE, Bazotte RB, Buttow NC. Intestinal and neuronal myenteric adaptations in the small intestine induced by a high-fat diet in mice. *BMC Gastroenterol* 2015; **15**: 3 [PMID: 25609418 DOI: 10.1186/s12876-015-0228-z]
- 94 **Bhattarai Y**, Fried D, Gulbransen B, Kadrofske M, Fernandes R, Xu H, Galligan J. High-fat diet-induced obesity alters nitric oxide-mediated neuromuscular transmission and smooth muscle excitability in the mouse distal colon. *Am J Physiol Gastrointest Liver Physiol* 2016; **311**: G210-G220 [PMID: 27288421 DOI: 10.1152/ajpgi.00085.2016]

- 95 **Schacht S**, Masood F, Catmull S, Dolan R, Altatabaee R, Grow W, Al-Nakkash L. Dietary Genistein Influences Number of Acetylcholine Receptors in Female Diabetic Jejunum. *J Diabetes Res* 2017; **2017**: 3568146 [PMID: 28835900 DOI: 10.1155/2017/3568146]
- 96 **Antonioli L**, Caputi V, Fornai M, Pellegrini C, Gentile D, Giron MC, Orso G, Bernardini N, Segnani C, Ippolito C, Csóka B, Haskó G, Németh ZH, Scarpignato C, Blandizzi C, Colucci R. Interplay between colonic inflammation and tachykinergic pathways in the onset of colonic dysmotility in a mouse model of diet-induced obesity. *Int J Obes (Lond)* 2019; **43**: 331-343 [PMID: 30082748 DOI: 10.1038/s41366-018-0166-2]
- 97 **Antonioli L**, Pellegrini C, Fornai M, Tirota E, Gentile D, Benvenuti L, Giron MC, Caputi V, Marsilio I, Orso G, Bernardini N, Segnani C, Ippolito C, Csóka B, Németh ZH, Scarpignato C, Blandizzi C, Colucci R. Colonic motor dysfunctions in a mouse model of high-fat diet-induced obesity: an involvement of A<sub>2B</sub> adenosine receptors. *Purinergic Signal* 2017; **13**: 497-510 [PMID: 28808842 DOI: 10.1007/s11302-017-9577-0]
- 98 **Forsyth CB**, Shannon KM, Kordower JH, Voigt RM, Shaikh M, Jaglin JA, Estes JD, Dodiya HB, Keshavarzian A. Increased intestinal permeability correlates with sigmoid mucosa alpha-synuclein staining and endotoxin exposure markers in early Parkinson's disease. *PLoS One* 2011; **6**: e28032 [PMID: 22145021 DOI: 10.1371/journal.pone.0028032]
- 99 **Clairembault T**, Leclair-Visonneau L, Coron E, Bourreille A, Le Dily S, Vavasour F, Heymann MF, Neunlist M, Derkinderen P. Structural alterations of the intestinal epithelial barrier in Parkinson's disease. *Acta Neuropathol Commun* 2015; **3**: 12 [PMID: 25775153 DOI: 10.1186/s40478-015-0196-0]
- 100 **Clairembault T**, Kamphuis W, Leclair-Visonneau L, Rolli-Derkinderen M, Coron E, Neunlist M, Hol EM, Derkinderen P. Enteric GFAP expression and phosphorylation in Parkinson's disease. *J Neurochem* 2014; **130**: 805-815 [PMID: 24749759 DOI: 10.1111/jnc.12742]
- 101 **Wunsch M**, Jabari S, Voussen B, Enders M, Srinivasan S, Cossais F, Wedel T, Boettner M, Schwarz A, Weyer L, Göcer O, Schroeter M, Maeurer M, Woencckhaus M, Pollok K, Radbruch H, Klotz L, Scholz CJ, Nickel J, Friebe A, Addicks K, Ergün S, Lehmann PV, Kuerten S. The enteric nervous system is a potential autoimmune target in multiple sclerosis. *Acta Neuropathol* 2017; **134**: 281-295 [PMID: 28620692 DOI: 10.1007/s00401-017-1742-6]
- 102 **Puig KL**, Lutz BM, Urquhart SA, Rebel AA, Zhou X, Manocha GD, Sens M, Tuteja AK, Foster NL, Combs CK. Overexpression of mutant amyloid- $\beta$  protein precursor and presenilin 1 modulates enteric nervous system. *J Alzheimers Dis* 2015; **44**: 1263-1278 [PMID: 25408221 DOI: 10.3233/JAD-142259]
- 103 **Wu S**, Yi J, Zhang YG, Zhou J, Sun J. Leaky intestine and impaired microbiome in an amyotrophic lateral sclerosis mouse model. *Physiol Rep* 2015; **3** [PMID: 25847918 DOI: 10.14814/phy2.12356]
- 104 **Kelly LP**, Carvey PM, Keshavarzian A, Shannon KM, Shaikh M, Bakay RA, Kordower JH. Progression of intestinal permeability changes and alpha-synuclein expression in a mouse model of Parkinson's disease. *Mov Disord* 2014; **29**: 999-1009 [PMID: 24898698 DOI: 10.1002/mds.25736]
- 105 **Fornai M**, Pellegrini C, Antonioli L, Segnani C, Ippolito C, Barocelli E, Ballabeni V, Vegezzi G, Al Harraq Z, Blandini F, Levandis G, Cerri S, Blandizzi C, Bernardini N, Colucci R. Enteric Dysfunctions in Experimental Parkinson's Disease: Alterations of Excitatory Cholinergic Neurotransmission Regulating Colonic Motility in Rats. *J Pharmacol Exp Ther* 2016; **356**: 434-444 [PMID: 26582732 DOI: 10.1124/jpet.115.228510]
- 106 **Pellegrini C**, Fornai M, Colucci R, Tirota E, Blandini F, Levandis G, Cerri S, Segnani C, Ippolito C, Bernardini N, Cseri K, Blandizzi C, Haskó G, Antonioli L. Alteration of colonic excitatory tachykinergic motility and enteric inflammation following dopaminergic nigrostriatal neurodegeneration. *J Neuroinflammation* 2016; **13**: 146 [PMID: 27295950 DOI: 10.1186/s12974-016-0608-5]
- 107 **Rota L**, Pellegrini C, Benvenuti L, Antonioli L, Fornai M, Blandizzi C, Cattaneo A, Colla E. Constipation, deficit in colon contractions and alpha-synuclein inclusions within the colon precede motor abnormalities and neurodegeneration in the central nervous system in a mouse model of alpha-synucleinopathy. *Transl Neurodegener* 2019; **8**: 5 [PMID: 30774946 DOI: 10.1186/s40035-019-0146-z]
- 108 **Enck P**, Mazurak N. Dysbiosis in Functional Bowel Disorders. *Ann Nutr Metab* 2018; **72**: 296-306 [PMID: 29694952 DOI: 10.1159/000488773]
- 109 **Nagao-Kitamoto H**, Kitamoto S, Kuffa P, Kamada N. Pathogenic role of the gut microbiota in gastrointestinal diseases. *Intest Res* 2016; **14**: 127-138 [PMID: 27175113 DOI: 10.5217/ir.2016.14.2.127]
- 110 **Cryan JF**, O'Riordan KJ, Sandhu K, Peterson V, Dinan TG. The gut microbiome in neurological disorders. *Lancet Neurol* 2020; **19**: 179-194 [PMID: 31753762 DOI: 10.1016/S1474-4422(19)30356-4]
- 111 **Nouvenne A**, Ticinesi A, Tana C, Prati B, Catania P, Miraglia C, De' Angelis GL, Di Mario F, Meschi T. Digestive disorders and Intestinal microbiota. *Acta Biomed* 2018; **89**: 47-51 [PMID: 30561395 DOI: 10.23750/abm.v89i9-S.7912]
- 112 **Grochowska M**, Laskus T, Radkowski M. Gut Microbiota in Neurological Disorders. *Arch Immunol Ther Exp (Warsz)* 2019; **67**: 375-383 [PMID: 31578596 DOI: 10.1007/s00005-019-00561-6]
- 113 **Passos MDCF**, Moraes-Filho JP. INTESTINAL MICROBIOTA IN DIGESTIVE DISEASES. *Arq Gastroenterol* 2017; **54**: 255-262 [PMID: 28723981 DOI: 10.1590/S0004-2803.201700000-31]



Published By Baishideng Publishing Group Inc  
7041 Koll Center Parkway, Suite 160, Pleasanton, CA 94566, USA  
Telephone: +1-925-3991568  
E-mail: [bpgoffice@wjgnet.com](mailto:bpgoffice@wjgnet.com)  
Help Desk: <http://www.f6publishing.com/helpdesk>  
<http://www.wjgnet.com>

