


Preliminary Outcomes of Viabahn Balloon-Expandable Endoprosthesis as Bridging Stent in Renal Arteries During Fenestrated Endovascular Aortic Repair

Journal of Endovascular Therapy
 1–10
 © The Author(s) 2021
 Article reuse guidelines:
sagepub.com/journals-permissions
 DOI: 10.1177/15266028211012403
www.jevt.org


Luca Mezzetto, MD¹ , Davide Mastrorilli, MD¹ , Nicola Leone² ,
 Stefano Gennai, MD², Roberto Silingardi, MD², Gian Franco Veraldi, MD¹,
 Michele Piazza, MD³, Francesco Squizzato, MD³,
 and Michele Antonello, MD³

Abstract

Purpose: To report preliminary outcomes of Viabahn Balloon-Expandable Endoprosthesis (VBX) stent-graft as bridging stent for renal arteries in fenestrated endovascular aneurysm repair (FEVAR). **Materials and Methods:** Between 2018 and 2019, patients undergoing FEVAR at 3 referral Italian university hospitals were prospectively collected. During the study period, VBX was the first-line choice as bridging stent for renal arteries. Procedural and anatomical data were analyzed, including renal artery (RA) configuration. A dedicated software (3Mensio, Vascular Imaging, Bilthoven, The Netherlands) was used and RA anatomy classified as follow: upward-oriented in case of any angle $>30^\circ$ above the horizontal or transverse axis perpendicular to the aortic axis, downward-oriented if there was an angle $>30^\circ$ measured below the transverse axis and downward + upward in case of an angle $<30^\circ$ associated with a renal artery angulation $>90^\circ$. Primary endpoints were technical success, defined as complete deployment of the fenestrated endograft without target vessel (TV) loss, limb stenosis or occlusion and type I or III endoleak, and freedom from target artery instability (TAI), defined by target vessel-related death, occlusion, rupture or reintervention for stenosis, endoleak or disconnection. Secondary endpoints were target artery patency rate and freedom from reinterventions. **Results:** A total of 26 elective FEVAR for juxta/pararenal aneurysm (20), thoracoabdominal type II (3) and type IV (3) were included. Fifty-one RA were planned for revascularization. Of these, 32 were downward, 10 horizontal, 6 upward, 4 were downward + upward. Technical success was achieved in 88.5% (23/26) of patients and 94.2% (48/51) of the TVs. One occlusion (2.1%) occurred within 30 days in a patient with previous endovascular aortic repair and suprarenal fixation. During follow-up (median 10 months), there was 1 type IC endoleak after 6 months (2.1%) in a patient with upward plus downward arterial orientation. Freedom from TAI was 96.1% (CI = 0.89 to 1.04) at first month and 92.3% (CI = 0.82 to 1.03) at 6 months. No aneurysm-related mortality and renal insufficiency occurred during follow-up. **Conclusion:** The use of VBX as bridging stent of RA in FEVAR is safe and feasible. Previous EVAR and tortuosity of RA may be a challenging on target vessel fate.

Keywords

thoracoabdominal aortic aneurysm, fenestrated repair, balloon-expandable stent, renal artery

Introduction

Thoracoabdominal aortic aneurysms (TAAAs) and para/juxtarenal aneurysms (PRAs/JRAAs) are complex pathologies that impose a continuous challenge to the vascular surgeon. Fenestrated and branched endovascular aneurysm repair (F/B-EVAR) has shown favourable outcomes, especially in several recent experiences.^{1–3} Nowadays, the choice of right stent-graft for bridging the visceral vessels seems to be important for postoperative success. Even if BEVAR allows the use of both self-expandable stent graft

¹Vascular Surgery, University Hospital of Verona, University of Verona School of Medicine, Verona, Italy

²Vascular Surgery, NOCSAE Nuovo Ospedale Civile di Baggiovara Sant'Agostino Estense, Baggiovara, Modena, Italy

³Vascular and Endovascular Surgery, Department of Cardiac, Thoracic, Vascular Sciences and Public Health, University of Padua, Padua, Italy

Corresponding Author:

Luca Mezzetto, Department of Vascular Surgery, University Hospital of Verona, University of Verona School of Medicine, Piazzale Aristide Stefani, 1, Verona, 37126, Italy.

Email: luca.mezzetto@aovr.veneto.it

(SESG) and balloon expandable stent graft (BESG), the use of BESG is mandatory in FEVAR. Although overall target vessel (TV) patency rate is satisfactory,^{2,4} complications related to renal TV remains a challenge.⁵ Different anatomical configuration of renal arteries as been described and showed to affect bridging stent graft patency.⁶ Moreover, the positional changes of the kidneys during respiration can produce bending and modifications of renal artery orientation. This dynamic bending seems to affect the 3-dimensional shape at the level of the ostia.⁷ In the setting of renal artery stenting, this motion may injure the artery and/or the stent, contributing to restenosis and disconnection of the bridging stent.⁸ In this specific scenario, a dedicated stent graft that is able to conform itself to the renal artery anatomy, should be mandatory. In the recent years, the Viabahn Balloon Expandable (VBX) Endoprosthesis (W. L. Gore & Associates, Flagstaff, AZ, USA) was introduced in the market and was mostly used for aortoiliac occlusive lesions. Its unusual design with unconnected longitudinal stents and the polytetrafluoroethylene layer provides high degree of longitudinal stability and flexibility, encouraging its use other clinical fields such as bridging stent in thoracoabdominal aortic repair.⁹ The aim of this study is to evaluate preliminary results of VBX as bridging stent in renal arteries during FEVAR.

Materials and Methods

Patient Selection

Data were collected prospectively from a dedicated database on consecutive patients who underwent FEVAR at 3 referral Italian university hospitals from May 2018 to October 2019. Directional branches were excluded from the current study. The VBX was systematically used as the bridging stent for the renal arteries in all patients. Demographics, anatomical characteristics, indications to treatment, procedural and postoperative data were analyzed. An informed consent for the surgical procedure and the scientific purpose was obtained in all cases of this study.

Device Design and Procedure Details

VBX has been introduced by W. L. Gore in 2018 and it represents the latest generation stent graft. It is a balloon expandable stent graft, which consists of a stainless-steel balloon-expandable stent, and a fluoropolymer graft. The stent is coated with the BioActive heparin surface and is encapsulated in the fluoropolymer. The main difference with other devices lies in its structure. The stent rows are not connected to each other longitudinally, leaving this task to the expanded polytetrafluoroethylene (PTFE) only. The result of this design is a high-grade flexibility and resistance to fracture. The endoprosthesis is preloaded on a delivery

system equipped with a ultrathin semi-compliant balloon compatible with 0.035 guide-wire, which improves stent attachment and deliverability.

All patients in this study underwent computed tomography angiography (CTA) of the thoraco-abdominal aorta for the preoperative planning. Cook Medical (Bloomington, IN) aortic endograft was used in all procedures. Using dedicated software for vessels analysis (3Mensio; Vascular Imaging, Bilthoven, The Netherlands), a custom made fenestrated endograft was planned by the same surgical team that performed the procedure and its feasibility was confirmed by the Cook Zenith Planning Centre. TVs diameters and lengths were determined according to the preoperative CTA. The renal artery origin angle was measured at the preoperative CTA measured between a longitudinal aortic axis and a transverse axis placed at the level of the origin of each of the renal arteries.¹⁰ The orientation of the renal artery was classified according to Gallitto et al.⁶ In particular, the renal artery was classified as upward-oriented in case of any angle $>30^\circ$ above the horizontal or transverse axis perpendicular to the aortic axis. The renal artery was classified as downward-oriented if there was an angle $>30^\circ$ measured below the transverse axis.

The VBX was the unique balloon-expandable stent graft used for mating target vessels. In case of ineffective bridging, a second VBX or bare metal stent (BMS) was used for relining.

The procedural features and details of FEVAR have been previously described.¹ As to renal stent deployment, a protrusion into the aortic lumen of 2 diamond shape of VBX is normally suggested then flared with a noncompliant 9- to 10-mm balloon at the level of fenestration (Figure 1). In case of narrow aorta, in order to avoid stent graft competition, a protrusion of only 1 diamond shape (5 mm) was allowed. Preoperative antiplatelet or anticoagulant therapy was confirmed at all patients' discharge.

Follow-up Protocol

Follow-up protocol consisted of clinical examination and radiological evaluation at 1, 6, and 12 months and annually thereafter. Radiological evaluation included CTA or CT without contrast enhancement plus duplex ultrasound (DUS) in patients with stage III-IV-V chronic kidney disease according to National Kidney Foundation/Kidney Disease Quality Initiative (NKF/KDQOQI)¹¹ and/or in case of intolerance to contrast medium. Data regarding the living status of patients was obtained from electronic registry office, using a personal identification code for each patient.

Definitions and Study Outcomes

Primary endpoints were technical success and target artery instability. Technical success was defined as a complete

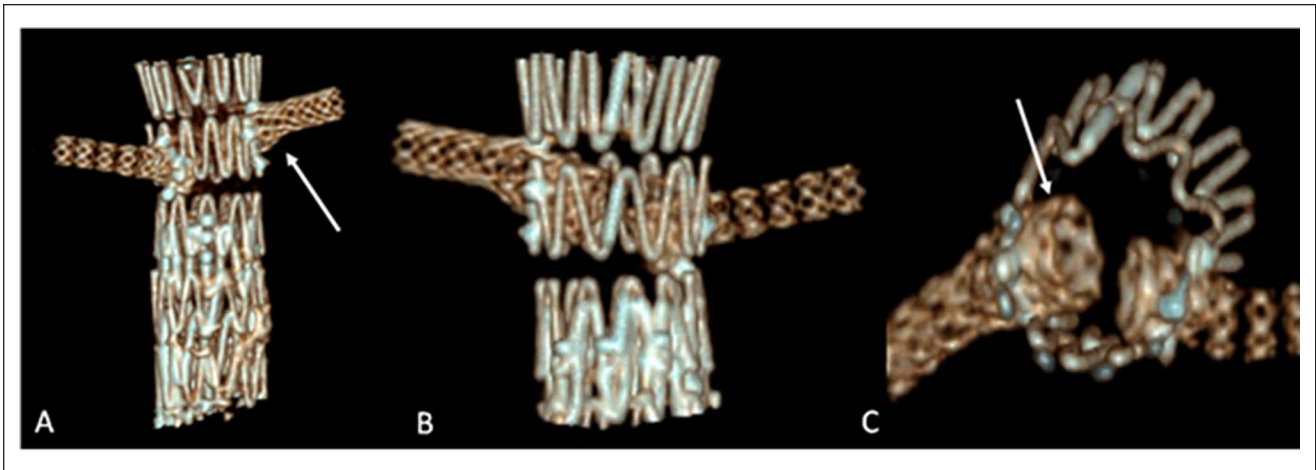


Figure 1. Volume rendering reconstruction of VBX as bridging stent in renal arteries from front (A) and posterior (B) plan. Inside point of view of fenestrated aortic stent graft (C), which show the correct flaring of the stent graft (white arrows).

deployment of the fenestrated endograft without TV loss, limb stenosis or occlusion, and type I or III endoleak, further defined by the absence of surgical conversion and survival >24 hours. Target artery instability (TAI) was defined as a composite outcome, including any TV-related death, occlusion, rupture or reintervention for stenosis, endoleak, or disconnection.¹ Secondary endpoints were specific rates of primary and secondary patency, freedom from endoleak, freedom from reintervention and renal function. Type IC and type IIIC endoleaks were defined as leaks from the distal target vessel sealing zone or from bridging stent disruption, respectively. Reinterventions related to target renal vessel were defined as any procedure performed to correct a defect of the renal bridging.

Clinical outcomes were reported with data on perioperative adverse events such as spinal cord ischemia, transient ischemic attack or stroke, myocardial infarct or arrhythmias and renal impairment requiring dialysis. Freedom from any reintervention and 30-day mortality were reported.

Chronic kidney disease (CKD) was defined as estimated glomerular filtration rate (eGFR) <60 mL/min/1.73 m² based on the NFK/KDOQI.¹¹ The RIFLE classification¹² was used for the postoperative evaluation of acute renal failure, defined as an increase in eGFR of at least 25%. Renal outcome was defined as a decline in GFR of < 60 ml/min/1.73 m² (ie, progression to CKD stage ≥3) or a GFR decline > 20% or progression in CKD stage (ie, from stage 3 to 4) signaled clinically significant worsening of renal function.

Statistical Analysis

Data were analyzed using IBM SPSS Statistics 24 (IBM Corp, Armonk, NY). The continuous variables were reported as median and interquartile ranges (IQRs). The

categorical variables were reported as percentages. Values from each observation, both intra- and interobserver, for maximum aortic diameter, left and right renal diameters and orientations were compared. Weighted k-Cohen test and intraclass correlation coefficient (ICC) was performed in order to evaluate the observations' degree of agreement. A $p < .05$ was considered statistically significant. Time-dependent freedom from TAI was reported using Kaplan-Meier estimates \pm standard error.

Results

Patient Cohort

Between May 2018 and October 2019, 26 consecutive patients (median age 73 years; 84.6% male) underwent FEVAR for complex aortic aneurysm: 20 (76.9%) PRAs/JRAAs and 6 (23.1%) TAAAs. All patients were classified unfit for open surgery as 23 had an American Society of Anesthesiologists (ASA) score of III and 3 (11.5%) had an ASA score of IV. Demographics and preoperative data are summarized in Table 1.

The median aneurysm diameter was 59.5 mm (53–67.2 mm) with median renal artery diameter of 6 mm (5.7–7 mm) from both sides. According to classification reported by Gallito et al,⁶ 32 RA were downward [17 right RA (65.4%); 15 left RA (57.7%)], 10 horizontal [5 right RA (19.2%); 5 left RA (19.2%)], 6 upward [2 right RA (7.7%); 4 left RA (15.4%)], 4 were downward + upward [2 right RA (7.7%); 2 left RA (7.7%)].

Procedure Details

All procedures were performed in operating rooms equipped with C-arm or in a dedicated hybrid operating rooms, under

Table 1. Demographic Data, Preoperative Clinical and Anatomical Characteristics of 26 Included Patients.

Characteristic	n	%
Demographics		
Age, y, median (IQR)		73 (71–77)
Age >80 y	3	11.5
Male sex	22	84.6
Cardiovascular risk factors		
Cigarette smoking	11	42.3
Hypertension	23	88.5
Hypercholesterolemia	17	65.4
Coronary artery disease	11	42.3
COPD	7	26.9
Diabetes mellitus	2	7.7
CKD stage 4–5	2	7.7
Stroke/TIA	0	0.0
ASA class >3	3	11.5
Prior aortic repair		
Endovascular	7	26.9
Open repair	1	3.8
Anatomic characteristics		
Juxta-/pararenal aneurysm	20	76.9
TAAA (Crawford II)	3	11.5
TAAA (Crawford IV)	3	11.5
Indications		
Atherosclerotic aneurysm	19	73.1
EL Ia post standard EVAR	5	19.2
Thoracoabdominal aneurysm	2	7.7
Maximum aortic diameter, mm		59.5 (IQR 53–67.2)
Right renal artery diameter, mm, median (IQR)		6 (IQR 6–7)
Left renal artery diameter, mm, median (IQR)		6 (IQR 5.7–7)
Right renal artery angulation		
0. Horizontal	5	19.2
1. Upward	2	7.7
2. Downward	17	65.4
3. 1+2	2	7.7
Left renal artery angulation		
0. Horizontal	5	19.2
1. Upward	4	15.4
2. Downward	15	57.7
3. 1+2	2	7.7

Abbreviations: ASA, American Society of Anesthesiologists; CKD, chronic kidney disease; COPD, chronic obstructive pulmonary disease; EL, endoleak; EVAR, endovascular aneurysm repair; TAAA, thoraco-abdominal aortic aneurysm; TIA, transient ischemic attack.

general anesthesia. Bilateral percutaneous femoral access was used in 17 of 26 cases and surgical left brachial access was necessary in 76.9% (20 of 26 cases), as described in Table 2. All 26 fenestrated endografts were successfully deployed, with a cumulative median procedure and fluoroscopy time of 305 minutes (IQR 297–314 minutes) and 78 minutes (IQR 67–82 minutes), respectively. Two procedures (a type II TAAA and a type IV TAAA with left hypogastric occluded) were completed in 2 steps, 4 weeks apart, to reduce the risk of spinal cord ischemia.

Of the 51 RA originally planned for revascularization, technical success was achieved in 94.2% (48/51) of the

vessels and 88.5% (23/26) of patients. Among patients with technical failures, 3 right renal arteries were not catheterized due to technical challenges, consisting of severe ostial stenosis in 2 cases and the presence of the proximal BMS of a previous EVAR in 1 case. Renal blood flow was guaranteed by the alignment of the fenestration to the renal vessels and subsequent follow up was uneventful in all 3 cases.

Median length and diameter of the renal bridging stents were 29 mm (range 29–39) and 7 mm (range 6–7) on both sides with an oversize of 0.8 mm on the right and 0.9 on the left side (Table 2).

Table 2. Procedural Details and Device Design of 26 Patients Treated by Fenestrated Endovascular Aneurysm Repair (FEVAR) Using Viabahn Balloon-Expandable (VBX) Stent-Graft.

Procedure/Device Design	n	%
Brachial access	20	76.9
Bilateral percutaneous access	17	65.4
<i>Device design</i>		
Diameter of aortic graft at level of renal fenestration, mm, median (IQR)	24.5 (22–30)	
Number of fenestrations		
4	23	88.4
3	2	11.5
2	1	3.8
Right renal artery		
Stent length, mm, median (IQR)	29 (29–39)	
Stent diameter, mm, median (IQR)	7 (6–7)	
Oversizing, mm, median (IQR)	0.8 (0.7–1)	
Reline with self-expandable BMS	3	11.5
Left renal artery		
Stent length, mm, median (IQR)	29 (IQR 29–39)	
Stent diameter, mm, median (IQR)	7 (IQR 5–7)	
Oversizing, mm, median (IQR)	0.9 (IQR 0.8–1.2)	
Reline with self-expandable BMS	4	15.4
Hospital stay, d, median (IQR)	4.5 (IQR 4–9.75)	
Postoperative antiplatelet therapy:		
SAPT	5	19.2
DAPT	17	65.4
OAC only	2	7.7
OAC + SAPT	2	7.7

Abbreviations: BMS, bare metal stent; DAPT, dual antiplatelet therapy; OAC, oral anticoagulant; SAPT, single antiplatelet therapy.

Intra- and Interobserver Variability

The intra- and interobserver variabilities of the aortic and renal arteries diameter and renal arteries orientations were assessed. The measurements of renal arteries orientation showed no statistically significant difference between intraobserver analysis ($k=0.78$, $p<0.001$ for left renal artery; $k=0.71$, $p<0.001$ for right renal artery).

Similar results were obtained for the interobserver analysis ($k=0.83$, $p<0.001$ for left renal artery; $k=0.75$, $p<0.001$ for right renal artery). Finally, both aortic and renal arteries diameter showed a good reproducibility with an almost perfect agreement for aortic measurement ($ICC=0.98$, $p<0.001$) and substantial agreement for renal arteries diameter ($ICC=0.73$, $p=0.003$ for right renal artery; $ICC=0.88$, $p<0.001$ for left renal artery).

Clinical and Target Artery Outcomes

Median hospital stay was 4.5 days (IQR 4–9.75) and no patient died during the postoperative period. Two patients (7.7%) had a myocardial infarction after the procedure and underwent urgent percutaneous coronary revascularization. One patient (3.8%) had an atrial fibrillation on second postoperative day, completely resolved after pharmacological

cardioversion. Immediate paraplegia occurred in 1 male patient (3.8%) with JRAA. The same patient had a transient ischemic attack about 6 hours after the procedure. The proximal endograft landing zone was placed 5 cm above the celiac trunk and both hypogastric arteries were patent. Cerebrospinal fluid drainage was promptly placed at the onset of neurological symptoms, without any clinical improvement. Postoperative acute kidney injury was observed in 5 patients (19.2%), requiring temporary hemodialysis in 2 (7.6%). One of these patients had unilateral renal branch occlusion, with an eGFR decrease from >60 mL/min to eGFR of 33 mL/min; the other patient had preoperative chronic kidney disease. At discharge, no patients needed permanent dialysis or became dialysis dependent during available follow-up. Using the CKD staging criteria, 92% of patients ($n=24$) did not experience a change in CKD stage (Table 3).

After a median follow-up of 10 months (IQR 9–11), 2 patients (4.1%) developed TAI (Table 4). Primary patency rate was $92.3\pm 5.2\%$ and secondary patency rate was $96\pm 3.9\%$. One occlusion occurred within 30 days after index procedure, in a patient who had previous endovascular aortic repair with suprarenal fixation and on single antiplatelet therapy. An immediate attempt of recanalization by relining or by local fibrinolysis resulted ineffective and a

Table 3. Outcomes of Acute and Chronic Renal Dysfunction After Fenestrated Endovascular Aneurysm Repair (FEVAR) (N=26).

Variable	n	%
Acute kidney injury	5	19
Postoperative GFR decline >20% CKD	8	31
Stable	24	92
Decline	2	8
Last available GFR decline >20%	2	8
Renal function decline	2	8

Abbreviations: CKD, chronic kidney disease; GFR, glomerular filtration rate.

Table 4. Rates of Target Artery Instability (TAI) in 48 Renal Arteries Stented Using Viabahn Balloon-Expandable (VBX) Stent-Graft in Fenestrated Endovascular Aneurysm Repair (FEVAR) at Median Follow-up of 10 Months.

Overall renal stent	48	
Target artery instability	2	4.1%
Branch-related occlusion or stenosis		
Occlusion	1	2.1%
Stenosis/kinking	0	/
Branch-related disconnection	0	/
Branch-related endoleak IC and IIIC:		
IC endoleak	1	2.1%
IIIC endoleak	0	/
Branch-related reintervention	2	4.1%

definitive worsening of renal function not requiring hemodialysis was observed. A type IC endoleak was revealed at 6 months of follow-up in a patient with upward plus downward renal arteries orientation; this was treated by means of relining with another VBX stent. Further follow-up was uneventful (Table 5).

Freedom from TAI was 96.1% (95% CI = 0.89 to 1.04) at 1 month and 92.3% (95% CI = 0.82 to 1.03) at 6 months (Figure 2). Freedom from reintervention was 96.1% (95% CI = 0.89 to 1.04) at 1 month and 92.3% (95% CI = 0.82 to 1.03) at 6 months. There were no aneurysm ruptures or aneurysm-related deaths during the study.

Discussion

The latest European Society of Vascular Surgery guidelines recommend FEVAR for the treatment of complex aortic aneurysms, whenever anatomically feasible,¹³ due to its reduced perioperative morbidity and mortality compared to open repair.¹⁴ Despite of the advantages of such less invasive technique, a recent meta-analysis states that FEVAR is burdened by a greater number of reoperations related to loss

of TV patency, especially when considering renal arteries.⁵ Mechanical movements during respiratory circle, small diameter and anatomical configuration of renal artery have been suggested as causes of potential failure.⁸

The adequate sealing between the aortic graft fenestration and the target vessel can be achieved by flaring the proximal edge of the stent-graft using - BESG during FEVAR.^{15,16} BEGS of different manufactures have been tested in FEVAR, but the right choice for bridging the renal arteries still remains largely debated.^{5,17-25}

Since April 2018, the VBX stent was initially used for aortoiliac reconstructions, where it revealed a high grade of flexibility and trackability even in complex anatomies.^{26,27} These encouraging results, supported by the availability of many lengths (15–79 mm) and diameters (up to 16 mm), broadened the indications also to FEVAR and BEVAR. Even if preliminary experiences in several hospital have been recently described,^{25,28} to the best of our knowledge none of these were focused on renal arteries.

In the present study, we reported the preliminary results of VBX on 48 targeted renal arteries, classified on the basis of their anatomical configurations. This resulted in a 94% of technical success in our experience, which is in line with available reports, ranging from 83% to 100%.^{5,17-25} Technical failure occurred in three cases, and none of these was due to unsuitable bridging stent. Only two patients had a renal complication with a TAI rate of 4.1%. These results are comparable with TAI for renal arteries in FEVAR extracted from the literature (Table 6).

A stent occlusion occurred after 1 month of follow-up in a patient previously undergoing EVAR. The probable explanation was an extrinsic compression of the stent by the free flow of the aortic endograft (Figure 3). Several endovascular attempts of recanalization were performed and finally the vessel was left occluded. Technically, the strong attachment to balloon of the stent^{29,30} allows an off-label approach to track the stent through high-grade stenosis even without the need of a sheath. On the other hand, one of the main criticisms made to VBX derives from the absence of connecting bars which would make the space between the rows, occupied by only PTFE, more prone to constraining and crushing inside the graft fenestration. Potentially, this limit could be overcome by reinforcing the VBX with a BMS. However, the systematic use of BMS to reinforce balloon expandable stent graft (BESG) does not seem a definitive solution, especially in long-term outcomes.³¹ Independently by the stent-graft used for TV, we consider the suprarenal fixation of previous EVAR a challenge and an independent risk factor for TAI.

Orientation and angulations of the renal arteries were supposed to affect the outcomes of F/B-EVAR²⁴; in particular, downward + upward configuration seems to have lower patency rate.

Table 5. Details of Target Artery Instability (TAI) for Renal Arteries in Fenestrated Endovascular Aortic Repair (FEVAR) in 2 of 48 Viabahn Balloon-Expandable (VBX) Stent-Graft Implanted.

	Patient 1	Patient 2
Indication	Endoleak type IA	Juxtarenal aneurysm
TAI	Occlusion	Endoleak type IC
Months to TAI	1	6
Side	Left	Left
Renal arteries diameter (mm)	5.5	5.6
Renal arteries orientation	Downward	Downward + upward
Previous aortic repair	Yes	No
Stent diameter (mm)	6	7
Stent length (mm)	29	29
Graft diameter at renal level (mm)	25	28
Relining with bare metal stent	No	No
Oversizing (mm)	0.5	1.4
Number of fenestrations	2	4
eGFR preoperative	>60	>60
eGFR at last follow-up	33	58
MACE at follow-up	No	No
Paraplegia	No	No
Reintervention type	Attempt of recanalization	Relining
Reintervention success	No	Yes

Abbreviations: eGFR, estimated glomerular filtration rate; MACE, major adverse cardiovascular event.

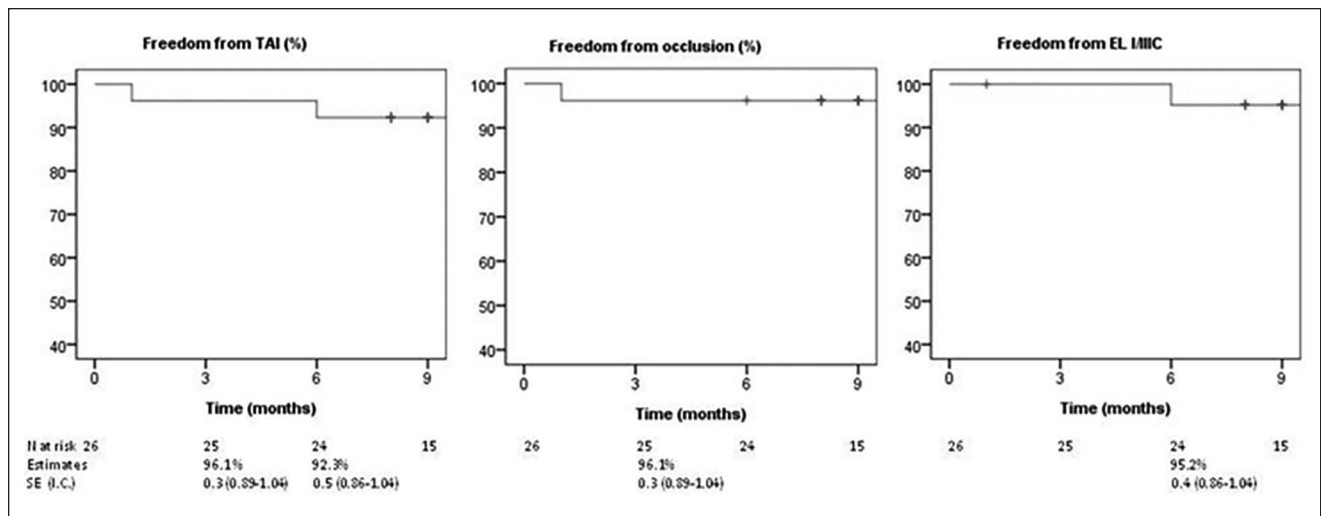


Figure 2. Kaplan-Meier estimates of target artery instability (TAI), occlusion, and endoleak type I/IIIC in 26 patients who underwent fenestrated endovascular aneurysm repair (FEVAR) using Viabahn Balloon-Expandable (VBX) stent-graft.

In our case series, 4 patients (14%) had such configuration but only 1 of these developed a type III endoleak about 6 months after the procedure. VBX 7×29 mm without relining with BMS was used and it was probably too short for an adequate distal sealing in such complex anatomy. A distal extension with VBX 7×39 mm was enough to obtain

the complete sealing to the target vessel. Longer stent-graft or primary relining with longer BMS should be planned in this anatomical configuration. It remains to clarify the role of respiratory motions on the evaluation of renal arteries orientation and prospective imaging studies are probably necessary to define this aspect.

Table 6. Summary of Results on Reports for Target Artery Instability (TAI) in Renal Arteries in Fenestrated Endovascular Aneurysm Repair (FEVAR).

Study, Year of Publication	Procedure Considered	Patients Included	Technical Success (%)	TAI (Only Renal Arteries), n (%)	Median/Mean Follow-up (mo)
Verhoeven et al (2010) ¹⁷	FEVAR	JRAA	87	7/169 (4.1)	24
Mastracci et al (2013) ¹⁸	B/FEVAR	TAAA ⁴ /JRAA ³	—	69/1111 (6.2)	36
Panuccio et al (2015) ¹⁹	B/FEVAR	TAAA/PRAA	99	19/272 (6.9)	15
Martin-Gonzalez et al (2015) ²⁰	FEVAR	TAAA/JRAA	97	16/374 (4.2)	36
Martin-Gonzalez et al (2016) ⁵	FEVAR	TAAA I/II/III	99	13/411 (3.1)	22
Sylvan et al (2016) ²¹	B/FEVAR	TAAA II/III	—	23/314 (7.3)	20
Budtz-Lilly et al (2017) ²²	B/FEVAR	TAAA/JRAA	95	6/127 (4.7)	25
Spear et al (2018) ²³	FEVAR	TAAA/JRAA	100	2/46 (4.3)	13
Bertoglio et al (2018) ²⁴	B/FEVAR	TAAA	83	5/24 (20)	14
Gallito et al (2019) ²⁵	B/FEVAR	TAAA/JRAA	100	0/30 (0)	6
Torsello et al (2020) ⁹	B/FEVAR	TAAA/JRAA	97.5	Not applicable	6
Present study	FEVAR	TAAA/JRAA	94	2/48 (4.1)	10

Abbreviations: B/FEVAR, branched/fenestrated endovascular aneurysm repair; JRAA, juxtarenal aortic aneurysm; PRAA, pararenal aortic aneurysm; TAAA, thoracoabdominal aortic aneurysm.

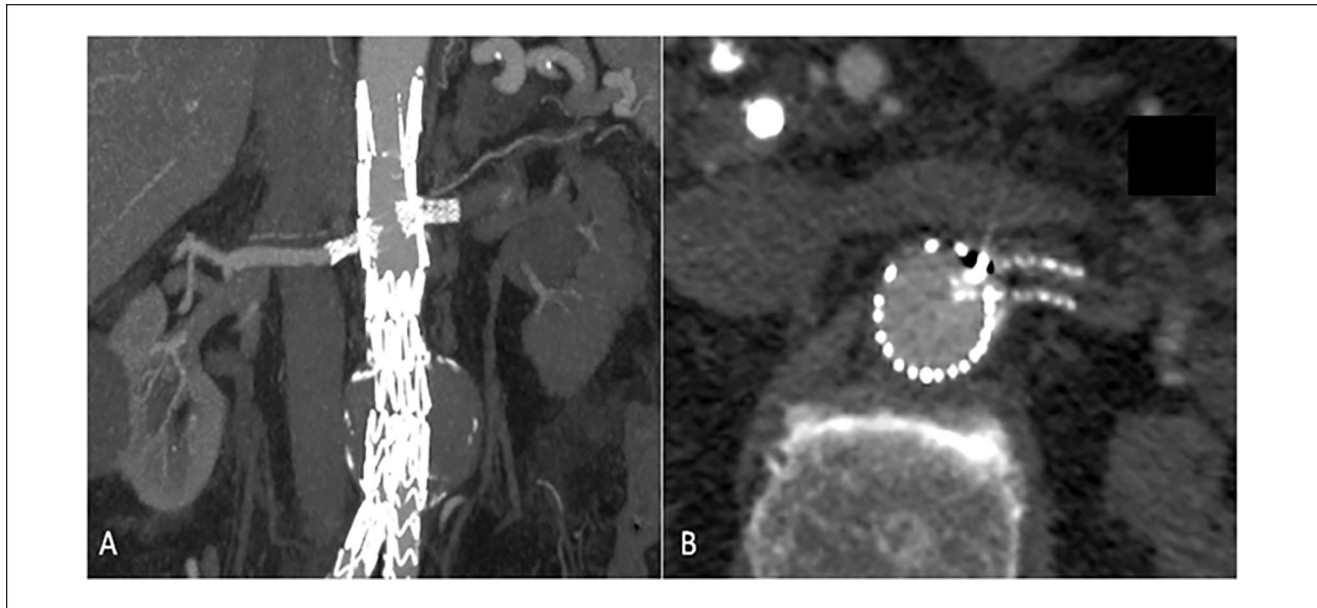


Figure 3. Occlusion of the left renal artery 1 month after the index procedure. (A) Multiplanar reconstruction showing Viabahn Balloon-Expandable (VBX) stent-graft that passes through the free flow of the previous infrarenal endovascular aortic repair. (B) Axial section. In this case, the angulation of the left renal artery is downward, but the stent is crushed by the graft and probably inducing the occlusion.

Study Limitations

The present study has several limitations. This study lacked a comparison group and had a limited number of patients with a relatively short follow-up, and further data are needed to evaluate the exact incidence of TV complications and to define the impact of anatomical configurations of renal artery on TAI. However, there is a lack of evidence in this field, and only sparse data merging different types of

stents are available specifically for renal TV outcomes after FEVAR. None of these is focused on VBX.

Conclusion

Our preliminary experience showed that the use of the VBX stent as bridging stent in FEVAR for renal arteries is safe and feasible, even in complex anatomies. Of note, this last generation stent graft has several advantages such as

resistance to thrombosis, high grade of flexibility, and trackability. Particular attention should be posed in selected cases at risk for failure, such as previous EVAR and downward + upward renal configuration. Although these preliminary outcomes are encouraging, the study is limited by a short follow-up and small number of patients. Comparison with other types of stents is necessary to further assess the role of the VBX stent in FEVAR.

Declaration of Conflicting Interests

The author(s) declared no potential conflicts of interest with respect to the research, authorship, and/or publication of this article.

Funding

The author(s) received no financial support for the research, authorship, and/or publication of this article.

ORCID iDs

Luca Mezzetto  <https://orcid.org/0000-0002-6284-1740>

Davide Mastrorilli  <https://orcid.org/0000-0001-9531-1503>

Nicola Leone  <https://orcid.org/0000-0001-6424-212X>

References

1. Mastracci TM, Eagleton MJ, Kuramochi Y, et al. Twelve-year results of fenestrated endografts for juxtarenal and group IV thoracoabdominal aneurysms. *J Vasc Surg.* 2015;61:355–364.
2. Verhoeven EL, Katsargyris A, Bekkema F, et al. Editor's Choice. Ten-year experience with endovascular repair of thoracoabdominal aortic aneurysms: results from 166 consecutive patients. *Eur J Vasc Endovasc Surg.* 2015;49:524–531.
3. Silingardi R, Gennai S, Leone N, et al. Standard “off-the-shelf” multibranch thoracoabdominal endograft in urgent and elective patients with single and staged procedures in multicenter experience. *J Vasc Surg.* 2018;67:1005–1016.
4. Oderich GS, Ribeiro M, Reis de Souza L, et al. Endovascular repair of thoracoabdominal aortic aneurysms using fenestrated and branched endografts. *J Thorac Cardiovasc Surg.* 2017;153:S32–S41.e7.
5. Martin-Gonzalez T, Mastracci T, Carrell T, et al. Mid-term outcomes of renal branches versus renal fenestrations for thoraco-abdominal aneurysm repair. *Eur J Vasc Endovasc Surg.* 2016;52:141–148.
6. Gallitto E, Faggioli G, Pini R, et al. Renal artery orientation influences the renal outcome in endovascular thoracoabdominal aortic aneurysm repair. *Eur J Vasc Endovasc Surg.* 2018;56:382–390.
7. Conway BD, Greenberg RK, Mastracci TM, et al. Renal artery implantation angles in thoracoabdominal aneurysms and their implications in the era of branched endografts. *J Endovasc Ther.* 2010;17:380–387.
8. Draney MT, Zarins CK, Taylor CA. Three-dimensional analysis of renal artery bending motion during respiration. *J Endovasc Ther.* 2005;12:380–386.
9. Torsello GF, Beropoulos E, Munaò R, et al. Outcomes of bridging stent grafts in fenestrated and branched endovascular aortic repair. *J Vasc Surg.* 2020;72:859–865.
10. Oderich GS, Forbes TL, Chaer R, et al. Reporting standards for endovascular aortic repair of aneurysms involving the renal-mesenteric arteries. *J Vasc Surg.* 2021;73(1S):4S–52S.
11. National Kidney Foundation. K/DOQI clinical practice guidelines for chronic kidney disease: evaluation, classification, and stratification. *Am J Kidney Dis.* 2002;39(2 suppl 1):S1–S266.
12. Bellomo R, Kellum JA, Ronco C. Defining and classifying acute renal failure: from advocacy to consensus and validation of the RIFLE criteria. *Intensive Care Med.* 2007;33:409–413.
13. Wanhainen A, Verzini F, Van Herzele I, et al. Editor's Choice. European Society for Vascular Surgery (ESVS) 2019 Clinical Practice Guidelines on the Management of Abdominal Aorto-iliac Artery Aneurysms. *Eur J Vasc Endovasc Surg.* 2019;57:8–93. [published correction appears in *Eur J Vasc Endovasc Surg.* 2020;59(3):494]
14. Jones AD, Waduud MA, Walker P, et al. Meta-analysis of fenestrated endovascular aneurysm repair versus open surgical repair of juxtarenal abdominal aortic aneurysms over the last 10 years. *BJS Open.* 2019;3:572–584.
15. Mohabbat W, Greenberg RK, Mastracci TM, et al. Revised duplex criteria and outcomes for renal stents and stent grafts following endovascular repair of juxtarenal and thoracoabdominal aneurysms. *J Vasc Surg.* 2009;49:827–837.
16. Grimme FA, Zeebregts CJ, Verhoeven EL, et al. Visceral stent patency in fenestrated stent grafting for abdominal aortic aneurysm repair. *J Vasc Surg.* 2014;59:298–306.
17. Verhoeven EL, Vourliotakis G, Bos WT, et al. Fenestrated stent grafting for short-necked and juxtarenal abdominal aortic aneurysm: an 8-year single-centre experience. *Eur J Vasc Endovasc Surg.* 2010;39:529–536.
18. Mastracci TM, Greenberg RK, Eagleton MJ, et al. Durability of branches in branched and fenestrated endografts. *J Vasc Surg.* 2013;57:926–933.
19. Panuccio G, Bisdas T, Berekoven B, et al. Performance of bridging stent grafts in fenestrated and branched aortic endografting. *Eur J Vasc Endovasc Surg.* 2015;50:60–70.
20. Martin-Gonzalez T, Pinçon C, Maurel B, et al. Renal outcomes following fenestrated and branched endografting. *Eur J Vasc Endovasc Surg.* 2015;50:420–430.
21. Sylvan J, Brier C, Wolski K, et al. Impact of alterations in target vessel curvature on branch durability after endovascular repair of thoracoabdominal aortic aneurysms. *J Vasc Surg.* 2016;63:634–641.
22. Budtz-Lilly J, Wanhainen A, Eriksson J, et al. Adapting to a total endovascular approach for complex aortic aneurysm repair: outcomes after fenestrated and branched endovascular aortic repair. *J Vasc Surg.* 2017;66:1349–1356.
23. Spear R, Sobocinski J, Hertault A, et al. One year outcomes of 101 BeGraft stent grafts used as bridging stents in fenestrated endovascular repairs. *Eur J Vasc Endovasc Surg.* 2018;55:504–510.
24. Bertoglio L, Loschi D, Cambiagli T, et al. Preliminary outcomes of the LifeStream balloon-expandable covered stent

- in fenestrated and branched thoracoabdominal endovascular repairs. *J Endovasc Ther.* 2018;25:230–236.
25. Gallitto E, Faggioli G, Pini R, et al. First/preliminary experience of Gore Viabahn Balloon-Expandable Endoprosthesis as bridging stent in fenestrated and branched endovascular aortic repair. *Ann Vasc Surg.* 2019;61:299–309.
 26. Bismuth J, Gray B, Holden A, et al. Pivotal study of a next-generation balloon-expandable stent-graft for treatment of iliac occlusive disease. *J Endovasc Ther.* 2017;24:629–637.
 27. Piazza M, Antonello M. The first balloon-expandable stent graft approved for treatment of iliac occlusive disease. *J Endovasc Ther.* 2017;24:638–639.
 28. Motta F, Parodi FE, Knowles M, et al. Performance of Viabahn Balloon Expandable Stent (VBX) compared to self-expandable covered (SES) stents for branched endovascular aortic repair. *J Vasc Surg.* 2021;73:410–416.e2.
 29. Torsello GF, Herten M, Müller M, et al. In vitro evaluation of the Gore Viabahn Balloon-Expandable Stent-Graft for fenestrated endovascular aortic repair. *J Endovasc Ther.* 2019;26:361–368.
 30. Torsello GB, Austermann M. Comparison of the biomechanical properties of the Advanta V12/iCast and Viabahn Stent-Grafts as bridging devices in fenestrated endografts: an in vitro study. *J Endovasc Ther.* 2020;27:258–265.
 31. Khoury MK, Timaran DE, Knowles M, et al. Visceral stent patency after fenestrated endovascular aneurysm repair using bare-metal stent extensions versus covered stents only. *J Vasc Surg.* 2020;71:23–29.