

A registry-based study of thyroid paraganglioma: histological and genetic characteristics

Ernst von Dobschuetz, Helena Leijon¹, Camilla Schalin-Jääntti^{2,3}, Francesca Schiavi³, Michael Brauckhoff^{4,†}, Mariola Peczkowska⁵, Giovanna Spiazzi⁶, Serena Demattè⁷, Maria Enrica Cecchini⁷, Paola Sartorato⁸, Jolanta Krajewska⁹, Kornelia Hasse-Lazar⁹, Katarzyna Roszkowska-Purska¹⁰, Elisa Taschin³, Angelica Malinoc¹¹, Lars A Akslen¹², Johanna Arola¹, Dariusz Lange¹³, Ambrogio Fassina¹⁴, Gianmaria Pennelli¹⁴, Mattia Barbareschi¹⁵, Jutta Luetgtes¹⁶, Aleksander Prejbisz⁵, Andrzej Januszewicz⁵, Tim Strate, Birke Bausch¹⁷, Frederic Castinetti¹⁸, Barbara Jarzab⁹, Giuseppe Opocher³, Charis Eng¹⁹ and Hartmut P H Neumann¹¹

Section of Endocrine Surgery, Department of General, Visceral and Thoracic Surgery, Krankenhaus Reinbek, St. Adolf Stift, Academic Teaching Hospital University of Hamburg, Reinbek, Germany

¹Department of Pathology, Helsinki University Central Hospital and University of Helsinki, Helsinki, Finland

²Division of Endocrinology, Department of Medicine, Helsinki University Central Hospital and University of Helsinki, Helsinki, Finland

³Familial Cancer Clinic and Onco-Endocrinology, Veneto Institute of Oncology, IRCCS, Padova, Italy

⁴Department of Endocrine Surgery, University of Bergen, Bergen, Norway

⁵Department of Hypertension, Institute of Cardiology, Warsaw, Poland

⁶Endocrinology, Diabetes and Metabolism, University of Verona and Azienda Ospedaliera Universitaria Integrata Verona, Verona, Italy

⁷Units of Internal Medicine, Santa Chiara General Hospital, Trento, Italy

⁸Department of Internal Medicine, General Hospital, Montebelluna, Treviso, Italy

⁹Department of Nuclear Medicine and Endocrine Oncology, Maria Skłodowska-Curie Memorial Cancer Center and Institute of Oncology, Gliwice Branch, Gliwice, Poland

¹⁰Department of Pathology and Laboratory Diagnostics, Skłodowska-Curie Memorial Institute of Oncology, Warsaw, Poland

¹¹Section for Preventive Medicine, Department of Nephrology and General Medicine, Albert-Ludwigs-University of Freiburg, Hugstetter Straße 55, 79106 Freiburg, Germany

¹²Section for Pathology, Department of Clinical Medicine, Centre for Cancer Biomarkers CCBIO, University of Bergen, Bergen, Norway

¹³Department of Tumor Pathology, M.Skłodowska-Curie Memorial Cancer Center and Institute of Oncology, Gliwice Branch, Gliwice, Poland

¹⁴Surgical Pathology and Cytopathology Unit, Department of Medicine, DIMED, University of Padova, Padova, Italy

¹⁵Department of Pathology, Santa Chiara Regional Hospital, Trento, Italy

¹⁶Department of Pathology, Marienkrankenhaus, Hamburg, Germany

¹⁷Department of Gastroenterology, Albert-Ludwigs-University of Freiburg, Freiburg, Germany

¹⁸Department of Endocrinology, La Timone Hospital, Hopitaux de Marseille and Centre de Recherche en Neurobiologie et Neurophysiologie de Marseille, Aix-Marseille University, Marseille, France

¹⁹Genomic Medicine Institute, Lerner Research Institute and Taussig Cancer Institute, Cleveland Clinic, Cleveland, Ohio, USA

[†]M Brauckhoff died on September 10, 2014. We dedicate this manuscript to his memory.

Correspondence should be addressed to H P H Neumann
Email
 hartmut.neumann@uniklinik-freiburg.de

Abstract

The precise diagnosis of thyroid neoplasias will guide surgical management. Primary thyroid paraganglioma has been rarely reported. Data on prevalence, immunohistochemistry (IHC), and molecular genetics in a systematic series of such patients are pending. We performed a multinational population-based study on thyroid paraganglioma and analyzed prevalence,

Key Words

- ▶ neuroendocrinology
- ▶ thyroid
- ▶ molecular genetics

IHC, and molecular genetics. Patients with thyroid paraganglioma were recruited from the European-American-Head-and-Neck-Paraganglioma-Registry. Demographic and clinical data were registered. Histopathology and IHC were re-investigated. All patients with thyroid paraganglioma underwent molecular genetic analyses of the *SDHA*, *SDHB*, *SDHC*, *SDHD*, *SDHAF2*, *VHL*, *RET*, *TMEM127*, and *MAX* genes. Analyses included Sanger sequencing and multiplex ligation-dependent probe amplification (MLPA) for detection of large rearrangements. Of 947 registrants, eight candidates were initially identified. After immunohistochemical analyses of these eight subjects, 5 (0.5%) were confirmed to have thyroid paraganglioma. IHC was positive for chromogranin, synaptophysin, and S-100 and negative for calcitonin in all five thyroid paragangliomas, whereas the three excluded candidate tumors stained positive for pan-cytokeratin, a marker excluding endocrine tumors. Germline variants, probably representing mutations, were found in four of the five confirmed thyroid paraganglioma cases, two each in *SDHA* and *SDHB*, whereas the excluded cases had no mutations in the tested genes. Thyroid paraganglioma is a finite entity, which must be differentiated from medullary thyroid carcinoma, because medical, surgical, and genetic management for each is different. Notably, approximately 80% of thyroid paragangliomas are associated with germline variants, with implications for additional tumors and a potential risk for the family. As opposed to sporadic tumors, surgical management and extent of resection are different for heritable tumors, each guided by the precise gene involved.

Endocrine-Related Cancer
(2015) 22, 191–204

Introduction

Neuroendocrine tumors of the thyroid gland are rare, and virtually all are medullary thyroid carcinoma (Ferri *et al.* 2009). Paragangliomas of the head and neck are neuroendocrine neoplasms developing from parasympathetic paraganglia, which occur at skull base and cervical sites, mostly the carotid body and the tympanic, vagal, and jugular paraganglia. The inferior laryngeal paraganglia can be located within the thyroid capsule explaining why this tumor might occur in the thyroid gland.

Head and neck paragangliomas can occur as sporadic tumors or as a manifestation of familial paraganglioma syndromes type 1–5 (PGL 1 to PGL 5). PGL 1 to PGL 5 are associated with germline mutations of the genes encoding succinate dehydrogenase subunit D, *SDHD* (PGL 1), succinate dehydrogenase complex assembly factor 2, *SDHAF2* (PGL 2), succinate dehydrogenase subunit C, *SDHC* (PGL 3), succinate dehydrogenase subunit B, *SDHB* (PGL 4), and succinate dehydrogenase subunit A, *SDHA* (PGL 5), the *SDHx* genes (Zantour *et al.* 2004, Boedeker *et al.* 2009). Heritable non-*SDHx* paraganglioma can also occur in tumor syndromes mainly associated with pheochromocytomas such as von Hippel–Lindau disease (associated with mutations of the *VHL* gene), multiple endocrine neoplasia type 2 (*RET* gene), and neurofibromatosis type 1 (*NF1* gene) (Boedeker *et al.* 2009, Neumann

et al. 2009, Burnichon *et al.* 2010, Castro-Vega *et al.* 2014, Yang *et al.* 2015). In patients carrying germline mutations of the new susceptibility genes *FH*, *PHD1* (*EGLN2*), and *PHD2* (*EGLN1*), head and neck paragangliomas have not been reported (Castro-Vega *et al.* 2014, Yang *et al.* 2015). Somatic mutations of the *HIF2A* (*EPAS1*) gene have been reported in abdominal paraganglial tumors but not in head and neck paragangliomas (Toledo *et al.* 2013). We therefore sought to determine the frequency and characteristics of thyroid paragangliomas in our population-based European-American-Head-and-Neck-Paraganglioma-Registry based in Freiburg, Germany.

Methods

Patients and data collection

We utilized the population-based European-American-Head-and-Neck-Paraganglioma-Registry (European-American-HNPGL-Registry), which is based in Freiburg/Germany and currently has 947 registrants. Registration policy has been described in detail previously (Neumann *et al.* 2004, 2009, Schiavi *et al.* 2005). Of these 947 registrants with head and neck paragangliomas, only eight carried the initial (working) diagnosis of thyroid paraganglioma. For these eight, we re-reviewed registered

data for their putative thyroid paraganglioma including demographic information such as age, sex, symptoms, location and size of the tumor, radiological imaging, and results from fine-needle aspiration cytology and histopathology of the surgical specimens. Tumors were diagnosed as malignant, only if patients showed metastases (Lloyd *et al.* 2004).

Histology and immunohistochemistry

Tumor materials from eight patients who had a working (initial) diagnosis of thyroid paraganglioma were collected and new slides from the paraffin blocks were centrally sectioned and re-analyzed by our internal reference center in the Department of Pathology of the University of Helsinki Central Hospital using conventional H&E histology and immunohistochemistry (IHC). The panel of IHC included staining against chromogranin A, synaptophysin, S-100, pan-cytokeratin (CK-PAN), calcitonin, thyroid transcription factor 1 (TTF1), MIB1, and p53. Slides were processed through deparaffinization in xylene followed by rehydration with graded alcohol series. Endogenous peroxidase was blocked with 0.3% Dako REAL Peroxidase-Blocking Solution. Detection was performed using a Dako REAL EnVision/HRP detection system in Autostainer (Labvision Autostainer 480S). Slides were counterstained with Meyer's hematoxylin and mounted in mounting medium (Fluka, Eukitt Quick-hardening mounting medium). In each immunohistochemical staining run, a positive and a negative control were used. Each of the different IHC procedures was performed on the same day for all eight cases and blindly scored by J A and H L with 100% concordance.

These results were compared with those primarily obtained in the participating centers. The diagnosis paraganglioma was newly established according to the criteria of the WHO (DeLellis 2004). All patients provided written informed consent.

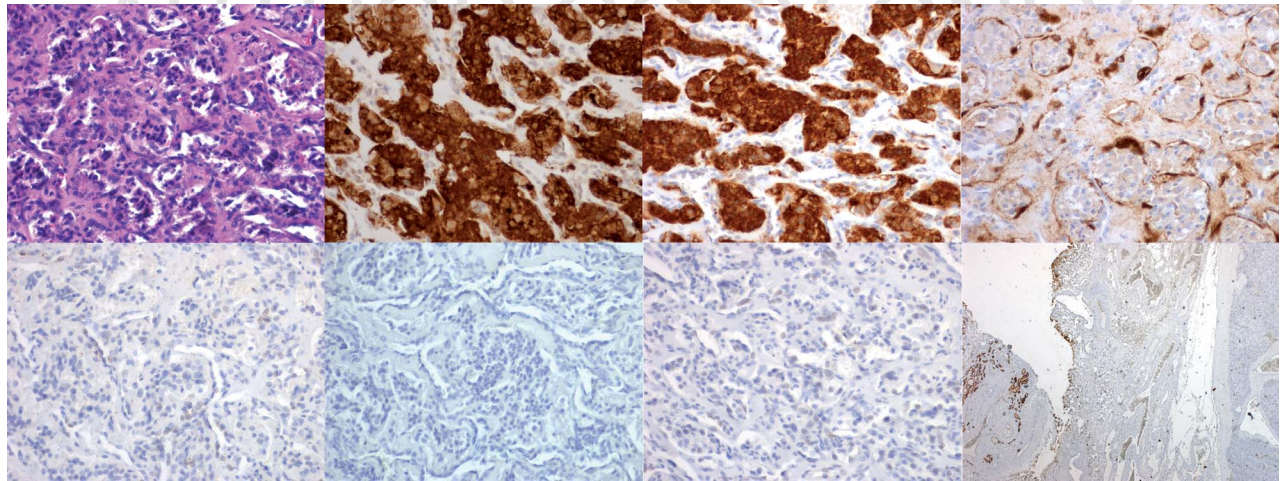
Genetic mutation analyses

All patients were offered molecular testing for germline mutations of the genes, which have been reported to cause head and neck paragangliomas: *SDHA*, *SDHAF2*, *SDHB*, *SDHC*, *SDHD*, *VHL*, *RET*, *MAX*, and *TMEM127* (Neumann *et al.* 2004, Schiavi *et al.* 2005, Burnichon *et al.* 2010). In these genes we looked for mutations in all exons except for *RET*, for which exons 8, 10, 11, and 13–16 only were analyzed. Mutation screening was not performed for the new candidate genes *FH*, *EGLN2*, *EGLN1*, and *EPAS1*

Table 1 Clinical findings in eight patients who entered the registry with the diagnosis of thyroid paraganglioma

Case	Age	Sex	Paraganglioma confirmed	Benign/malignant	Symptoms	Hyper-tension	Preoperative ultrasonography	Fine needle biopsy before first operation	Initial diagnosis	Treatment based on first diagnosis	Diagnosis paraganglioma made
1	27	Male	Yes	Ben	Relative tested as SDHB-positive Node in the neck	No	No	Not done	PGL	Hormone substitution	After 1st operation
2	32	Male	Yes	Ben	Node in the neck	No	Yes	Adenoma	PGL	Hormone substitution	After 1st operation
3	36	Female	Yes	Ben	Node in the neck	No	No	Not done	Hemangiopericytoma	Hormone substitution	After 3 years
4	37	Female	Yes	Ben	Lump in the neck	No	Yes	Follicular neoplasia	Follicular thyroid cancer	Radioactive iodine	After 12 years
5	71	Female	Yes	Ben	Swallowing difficulties	Yes	Yes	Follicular neoplasia	PGL	Hormone substitution	After 1st operation
A	42	Female	No	Mal	No	No	Yes	Not done	PGL	Hormone substitution	After 1st operation
B	67	Female	No	Ben	Incidental finding	No	Yes	Follicular neoplasia	PGL	Hormone substitution	After 1st operation
C	69	Male	No	Ben	Swallowing difficulties	No	Yes	Suspicious for a tumor	Neuroendocrine tumor, PGL	Radioactive iodine	After some weeks

The diagnosis of paraganglioma was confirmed in five patients (1, 2, 3, 4, and 5) and excluded in three patients (A, B, and C) by this study. 'Initial diagnosis' was revised after some weeks to 12 years (last column), but always before entry into the registry.

**Figure 1**

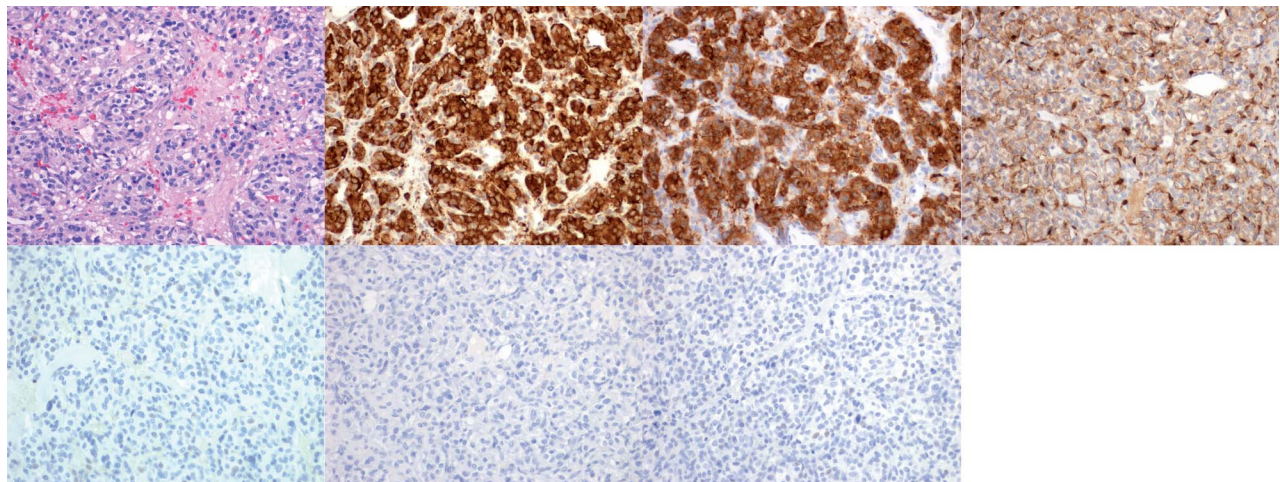
Immunohistochemistry of case 1: H&E, chromogranin, synaptophysin, S-100, CK-PAN, calcitonin, TTF1, and internal control for CK-PAN.

Note that there is positive staining of the tumor for chromogranin and

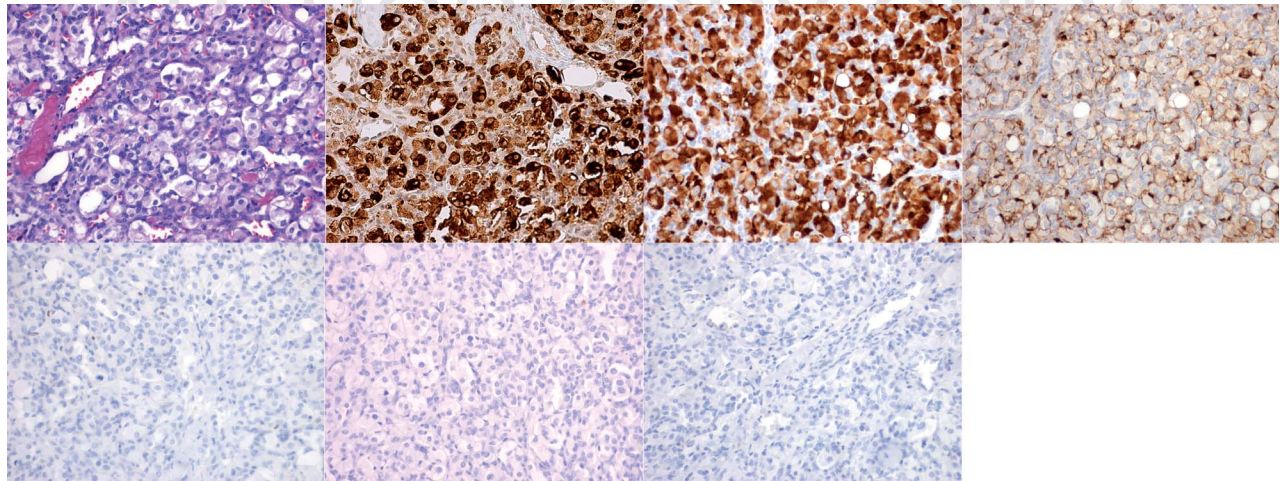
(Toledo *et al.* 2013, Castro-Vega *et al.* 2014, Yang *et al.* 2015), because such patients seem to have only extremely rare head and neck paragangliomas: in addition, *EPAS1* mutations are typically associated with polycythemia, which was not seen in any of our registrants. Genomic DNA was obtained from EDTA-anticoagulated whole blood. We performed bidirectional Sanger sequencing of the coding regions and splice sites of all genes. In order to find a deletion or duplication of the listed genes, we performed multiplex ligation-dependent probe amplification (MLPA) analyses for *VHL*, *SDHB*, *SDHC*, *SDHD*, *SDHAF2*, *MAX*, and *SDHA* and semi-quantitative multiplex PCR for *TMEM127*. We did

not scan *RET* for large rearrangements. The sequences of the primers used for these analyses and PCR conditions are available upon request. To elucidate the extent of large deletions, breakpoints were located through quantitative real-time PCR gene-dosage determination, and then characterized by long-range PCR and nucleotide sequencing. The results were subjected to *in silico* analyses using the programs SIFT, MutationTaster, and PolyPhen-2 in order to predict pathogenicity of the DNA variants. They are considered to be probably pathogenic if at least two of the three software packages predicted them to be damaging/pathogenic.

not scan *RET* for large rearrangements. The sequences of the primers used for these analyses and PCR conditions are available upon request. To elucidate the extent of large deletions, breakpoints were located through quantitative real-time PCR gene-dosage determination, and then characterized by long-range PCR and nucleotide sequencing. The results were subjected to *in silico* analyses using the programs SIFT, MutationTaster, and PolyPhen-2 in order to predict pathogenicity of the DNA variants. They are considered to be probably pathogenic if at least two of the three software packages predicted them to be damaging/pathogenic.

**Figure 2**

Immunohistochemistry of case 2: H&E, chromogranin, synaptophysin, S-100, CK-PAN, calcitonin, and TTF1. Note that there is positive staining of the tumor for chromogranin and synaptophysin, and of sustentacular cells for S-100. Negative staining is shown for CK-PAN, calcitonin, and TTF1.

**Figure 3**

Immunohistochemistry of case 3: H&E, chromogranin, synaptophysin, S-100, CK-PAN, calcitonin, and TTF1. Note that there is positive staining of the tumor for chromogranin and synaptophysin, and of sustentacular cells for S-100. Negative staining is shown for CK-PAN, calcitonin, and TTF1.

Results

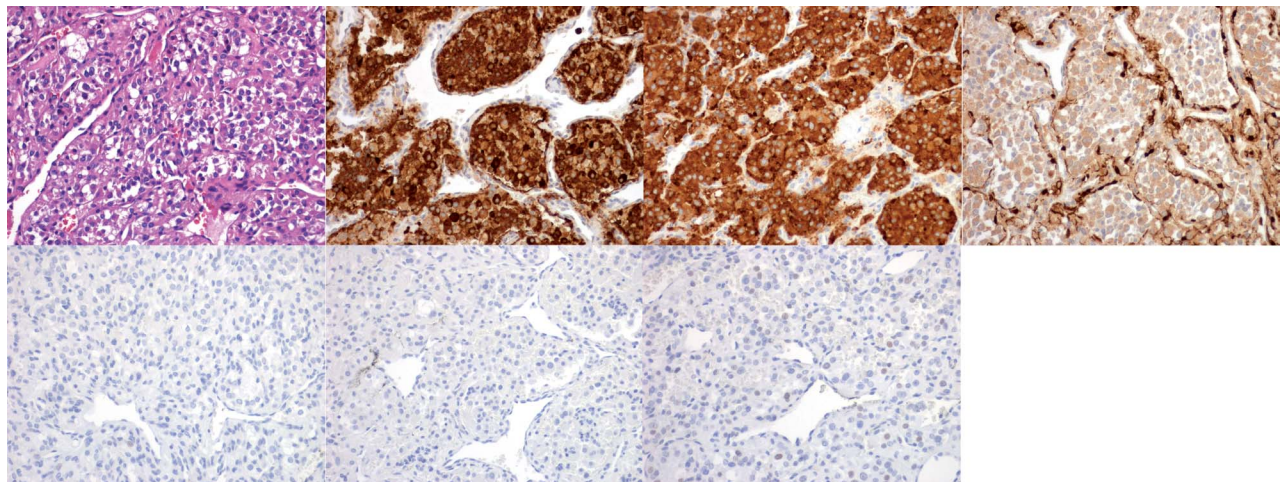
Prevalence of thyroid paraganglioma

As of May 1, 2014, the European-American-HNPGL-Registry based in Freiburg, Germany, comprises 947 registrants. Among these 947 patients, 939 carried the diagnosis of head and neck paragangliomas (HNPs): 55% had tympanojugular HNPs, 45% had carotid body tumors, 5% had vagal HNPs, and 2% had HNPs with other locations; bilateral HNPs and HNPs at several locations were present. Of the 947 patients, eight carried the putative diagnosis of thyroid

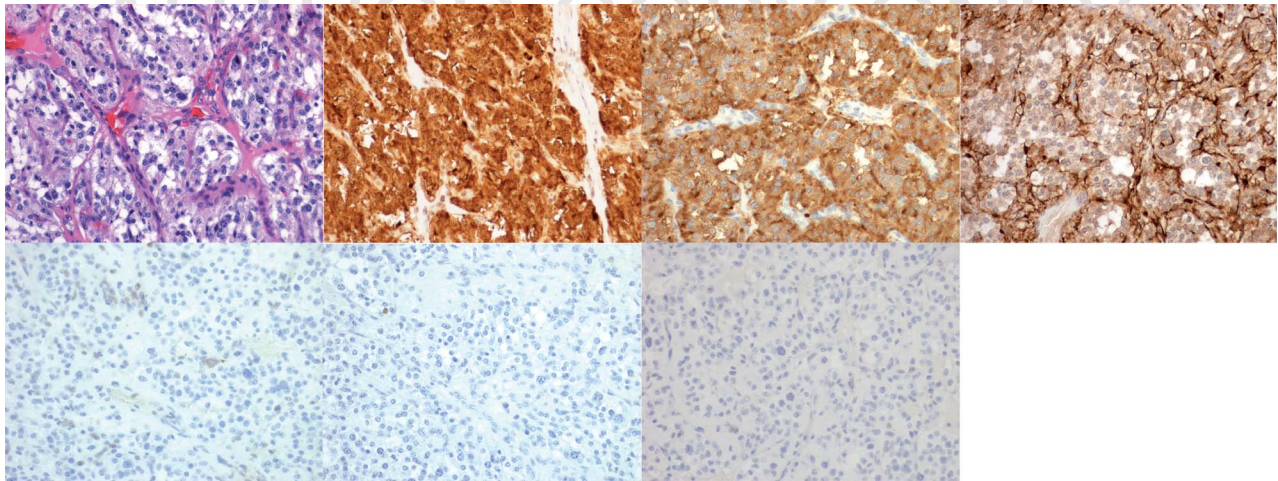
paraganglioma. After comprehensive re-analysis (described below), three tumors did not meet the WHO criteria of thyroid paraganglioma (see below); thus, in the European-American-HNPGL-Registry, the prevalence of documented thyroid paraganglioma was estimated to be 0.5% (5/944).

Patients

The eight patients with the initial working diagnosis of thyroid paraganglioma comprised five females and three males with ages at diagnosis of 27–71 (median 40) years.

**Figure 4**

Immunohistochemistry of case 4: H&E, chromogranin, synaptophysin, S-100, CK-PAN, calcitonin, and TTF1. Note that there is positive staining of the tumor for chromogranin and synaptophysin, and of sustentacular cells for S-100. Negative staining is shown for CK-PAN, calcitonin, and TTF1.

**Figure 5**

Immunohistochemistry of case 5: H&E, chromogranin, synaptophysin, S-100, CK-PAN, calcitonin, and TTF1. Note that there is positive staining of the tumor for chromogranin and synaptophysin, and of sustentacular cells for S-100. Negative staining is shown for CK-PAN, calcitonin, and TTF1.

All patients had focal enlargement of the thyroid gland. One had dysphagia. Thyroid ultrasonography revealed tumors with a largest diameter of 22–60 (median 44) mm. None of the patients had either additional neuroendocrine tumors or metastases. Clinical findings are given in Table 1. Family history for paraganglial tumors was positive only in one patient (case 1).

Fine-needle aspiration cytology

Fine-needle aspiration cytology was performed in five of the eight patients. Cytology revealed findings suggesting a ‘tumor’ in one, an adenoma in one, and a follicular neoplasia in three patients (Table 1).

Treatment

All patients underwent surgery for removal of the thyroid tumor. This was performed in two patients by hemithyroidectomy and in six patients by total thyroidectomy.

Histology and IHC

Histology was studied using hematoxylin and eosin (H&E) stains and IHC was systematically performed and re-investigated at one of the participating centers (Helsinki). Histology together with IHC revealed that five of the eight tumors had the characteristics of paragangliomas (Figs 1, 2, 3, 4, and 5). On the basis of conventional histology,

Table 2 Results of immunohistochemistry performed in this study

Case	Chromogranin A	Synaptophysin	S-100	Calcitonin	TTF1	CytokeratinPAN	Diagnosis
1	Positive	Positive	Positive	Negative	Negative	Negative	Thyroid paraganglioma
2	Positive	Positive	Positive	Negative	Negative	Negative	Thyroid paraganglioma
3	Positive	Positive	Positive	Negative	Negative	Negative	Thyroid paraganglioma
4	Positive	Positive	Positive	Negative	Negative	Negative	Thyroid paraganglioma
5	Positive	Positive	Positive	Negative	Negative	Negative	Thyroid paraganglioma
A	Negative	Negative	Negative	Negative	Negative	Positive	No paraganglioma
B	Positive	Positive	Negative	A few positive cells	Positive	Positive	No paraganglioma
C	Positive	Positive	Negative (a few positive cells)	Negative	Negative	Positive	No paraganglioma

Table 3 Results of mutation screening. Four patients had blood DNA variants in the *SDHA* or *SDHB* genes

Case	Gene RefSeq	Nucleotide variation and predicted effect on protein	Protein domain	Public databases			Pathogenicity clues (<i>in silico</i> analysis)
				dbSNP	ESP	HGMD	
Case 1	<i>SDHB</i> NM_003000.2	c.530G>A p.Arg177His	4Fe-4S ferredoxin-type	rs150437793 (MAF: T=0.000/0)	Eur. Am.: T=0.00% Afr. Am.: T=0.02%	CM130559 pathogenic phenotype: pheochromocytoma	Alamut software Highly conserved nucleotide (phyloP: 0.84 (-5.2; 1.1)) Highly conserved amino acid, up to Baker's yeast (considering 14 species) Small physicochemical difference between Arg and His (Grantham dist.: 29 (0-215)) Align GVD: C25 (GV: 0.00-GD: 28.82) SIFT: deleterious (score: 0, median: 4.07) MutationTaster: disease causing (P value: 1) Polyphen-2 HumDiv: possibly damaging - score 0.611 (sensitivity: 0.87; specificity: 0.91) Polyphen-2 HumVar: benign - score 0.380 (sensitivity: 0.85; specificity: 0.79)
Case 2	<i>SDHB</i> NM_003000.2	c.201-1339_239delinsAluYb8 p.?				Not reported in the literature	
Case 3	<i>SDHA</i> NM_004168.2	c.394T>C p.Trp132Arg	FAD-binding domain			Not reported in the literature	Highly conserved nucleotide (phyloP: 0.96 (-5.2; 1.1)) Highly conserved amino acid, up to Baker's yeast (considering 13 species) Moderate physicochemical difference between Trp and Arg (Grantham dist.: 101 (0-215)) Align GVD: C65 (GV: 0.00-GD: 101.29) SIFT: deleterious (score: 0, median: 3.74) MutationTaster: disease causing (P value: 1) Polyphen-2 HumDiv: probably damaging - score 1.000 (sensitivity: 0.00; specificity: 1.00) Polyphen-2 HumVar: probably damaging - score 0.998 (sensitivity: 0.18; specificity: 0.98)

Table 3 Continued

Case	Gene RefSeq	Nucleotide variation and predicted effect on protein	Protein domain	Public databases			Pathogenicity clues (in silico analysis)
				dbSNP	ESP	HGMD	
Case 4	SDHA NM_004168.2	c.1799G>A p.Arg600Gln	Fumarate reductase/succinate dehydrogenase flavo-protein-like C-terminal	rs112656 (MAF: A=0.014/31)	Eur. Am.: T=0.00% Afr. Am.: T=0.00%	HGMD Not reported in the literature	Alamut software Highly conserved nucleotide (phyloP: 0.91 (-5.2; 1.1)) Highly conserved amino acid, up to Baker's yeast (considering 13 species) Small physicochemical difference between Arg and Gln (Grantham dist.: 43 (0–215)) Align GVGD: C35 (GV: 0.00–GD: 42.81) SIFT: deleterious (score: 0, median: 3.74) MutationTaster: disease causing (P value: 1) Polyphen-2 HumDiv: probably damaging – score 1.000 (sensitivity: 0.00; specificity: 1.00) Polyphen-2 HumVar: probably damaging – score 0.999 (sensitivity: 0.09; specificity: 0.99)

NA, not applicable. Further explanations of abbreviation will be provided on request.

there were cells with diffuse sheet-like patterns of growth or nests (the classic *Zellballen*). These cells had mostly a clear or basophilic abundant cytoplasm according to H&E staining and some variations in the nuclei. These cells represented chief cells. The mitotic rate was low. Around the sheets or nests of chief cells, there were cells that represented sustentacular cells. Between tumor cells, there were highly vascularized fibrous septa. IHC of all these five tumors revealed chief cells positive for the neuroendocrine markers chromogranin A and synaptophysin. Sustentacular cells were positive for S-100. CK-PAN, TTF1, and calcitonin were also investigated and were negative in all primary thyroid paragangliomas. Both the histology and immunohistochemical profile were consistent with the WHO classification of tumors (DeLellis 2004).

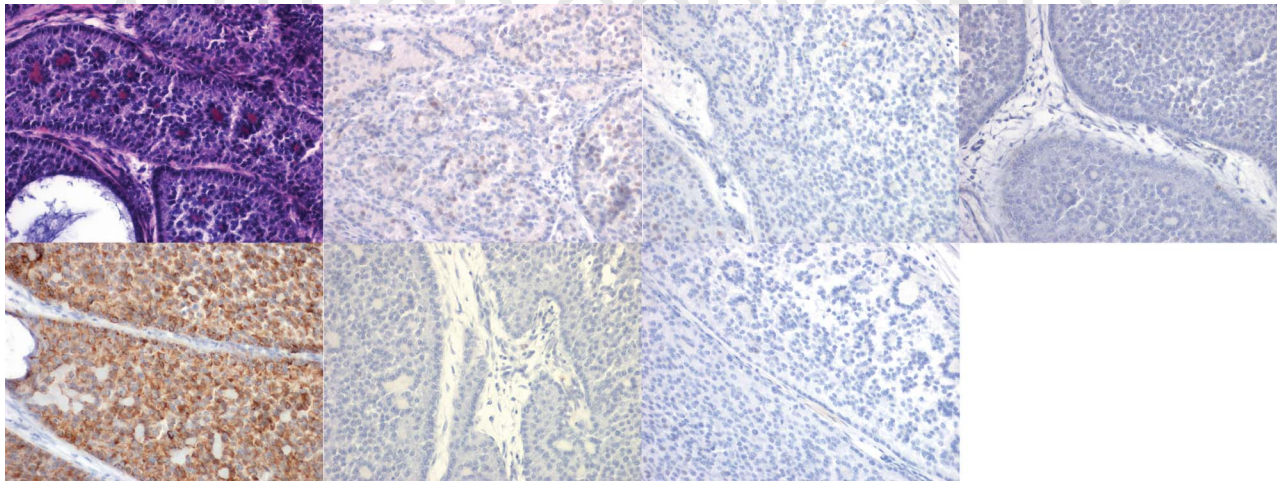
The levels of the proliferation marker MIB1 were low, between 3 and 5% in all five thyroid paragangliomas, and p53 was negative, which did not indicate a mutation in this tumor-suppressor gene.

Three cases (cases A, B, and C in Tables 1, 2, and 3) that were initially included in the study as thyroid paragangliomas were excluded because of their immunohistochemical profiles (Figs 6, 7, and 8). All these cases stained positive with CK-PAN, a marker which would exclude paraganglioma. The tumor of patient A is only positive for CK-PAN, which resulted in an immunohistochemical diagnosis of an epithelial neoplasia. The tumor of patient B is a medullary thyroid carcinoma or a metastasis of a neuroendocrine tumor. The tumor of patient C is a metastasis of a neuroendocrine tumor or a calcitonin-negative medullary thyroid carcinoma. A summary of the IHC results is given in Table 2.

Molecular genetics and family history

All eight patients were analyzed for nine known paraganglioma predisposition genes as part of this study. The three cases that were excluded as thyroid paragangliomas were found not to carry any germline mutations in the nine genes. Of the five patients with confirmed thyroid paragangliomas, four were found to have germline DNA variants, which probably represent mutations (Table 3).

In the first confirmed thyroid paraganglioma case, the youngest of our series who was 27 years old at the time of diagnosis, the mutation was known from a relative carrying the germline DNA variant *SDHB* c.664G>A p.Arg177His. This family consisted of ten members and one unrelated wife (1st generation). Of the ten relatives, there were eight mutation carriers and two members in whom the mutation is not present (Fig. 9). Six mutation

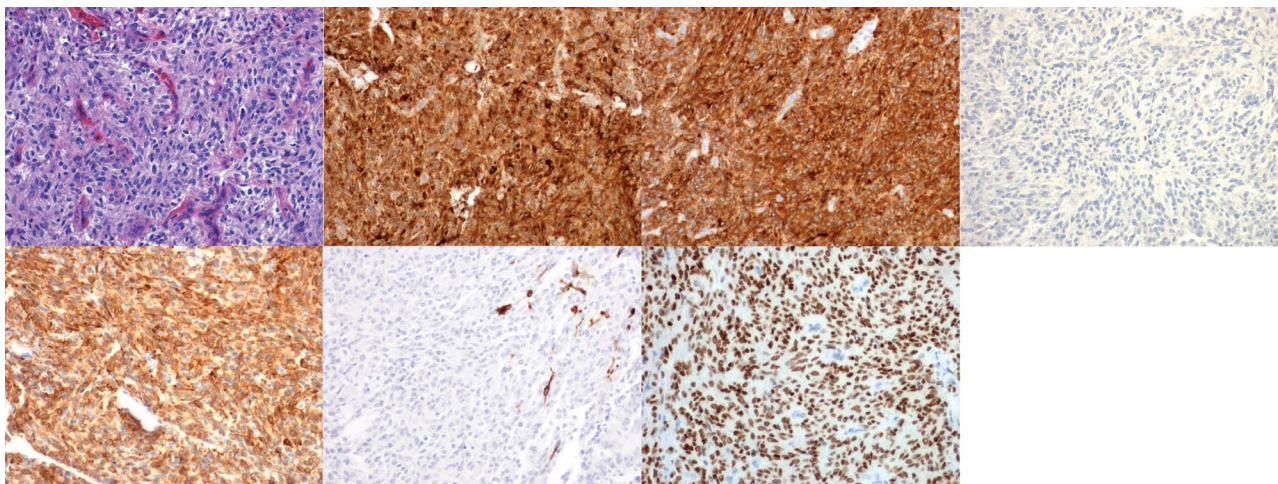
**Figure 6**

Immunohistochemistry of case A: H&E, chromogranin, synaptophysin, S-100, CK-PAN, calcitonin, and TTF1. Note that there is positive staining for CK-PAN and negative staining for chromogranin, synaptophysin, S-100, calcitonin, and TTF1.

carriers had paragangliomas or pheochromocytomas. Among these six patients is the 27-year-old patient with thyroid paraganglioma (III.1), the first symptomatic patient of this family (II.1) who presented with meta-chronic bilateral pheochromocytoma. One 80-year-old mutation carrier underwent computerized tomography of the neck, chest, and abdomen with normal results. One 14-year-old mutation carrier was not investigated thus far. The two relatives without mutations had not undergone surgery for any tumor. *In silico* analyses of the variant associated with disease indicated this variant to be deleterious according to the SIFT program, to be disease

causing according to the MutationTaster program, and to be possibly damaging according to the PolyPhen-2 program. Together, the results of the *in silico* analyses and the segregation of mutation and phenotype in the pedigree make the germline variant most probably pathogenic. The phenotypic data are in accordance with the well-known reduced penetrance of tumors in subjects carrying mutations of the *SDHB* gene.

The second case (case 2) was a 32-year-old male who was found to have a complex rearrangement, consisting of a partial deletion of intron 2 and exon 3 of the *SDHB* gene and an Alu insertion (Alu family Yb8) (Fig. 10). The latter

**Figure 7**

Immunohistochemistry of case B: H&E, chromogranin, synaptophysin, S-100, CK-PAN, calcitonin, and TTF1. Note that there is positive staining not only for CK-PAN, but also for chromogranin, synaptophysin, and TTF1. Staining for S-100 is negative, and staining for calcitonin shows only very few positive cells.

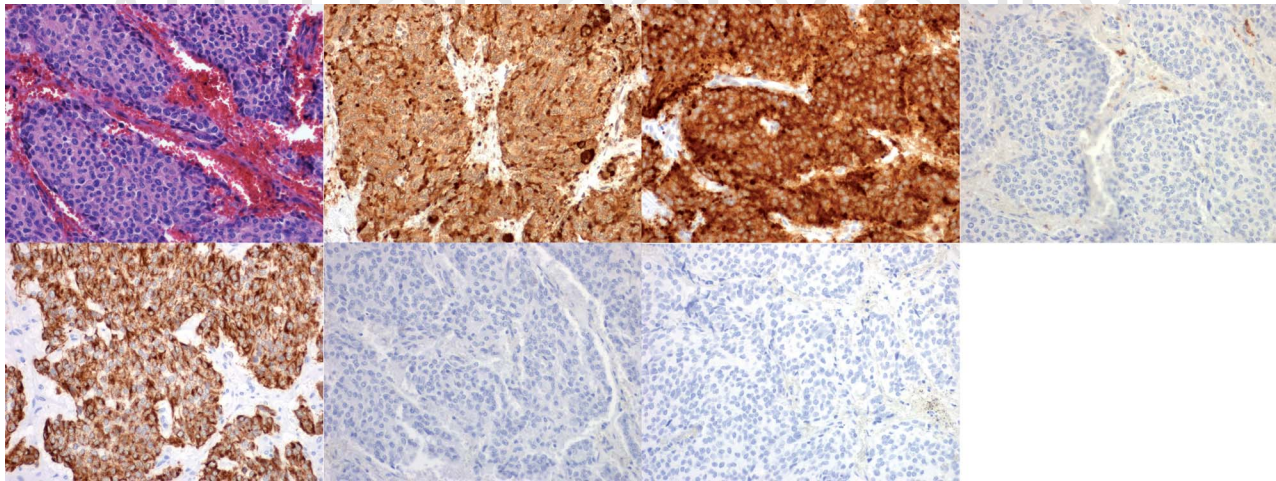


Figure 8

Immunohistochemistry of case C: H&E, chromogranin, synaptophysin, S-100, CK-PAN, calcitonin, and TTF1. Note that there is positive staining not only for CK-PAN, but also for chromogranin and synaptophysin. Staining for S-100, calcitonin, and TTF1 are negative.

mutation has not been reported thus far. There is no additional patient in the family of this case with known paraganglial tumors.

Two more patients, 36 and 37 years old at diagnosis, had germline DNA variants of the *SDHA* gene. *In silico* analyses results indicated both variants to be deleterious according to SIFT, disease causing according to Mutation-Taster, and probably damaging according to PolyPhen-2. Thus, these two DNA variants are most probably mutations rather than polymorphisms (Table 3). Family history was negative for paraganglial tumors in these two patients.

The blood DNA variants detected in cases 1, 3, and 4 are shown in Fig. 11. The four patients who probably are carriers of germline mutations were the four youngest of this series.

Postoperative and long-term follow-up

Plasma and 24-h urine catecholamines or metanephrines were measured in all five patients with confirmed thyroid paraganglioma, preoperatively in one and postoperatively in four, and all measurements revealed normal results. In addition, results obtained from whole-body nuclear medicinal investigation using ^{131}I -metaiodobenzylguanidine scintigraphy (in three cases), ^{111}In somatostatin receptor scintigraphy (in two cases), ^{18}F -fluoro-dihydroxyphenylalanine positron emission tomography (PET) (in one case), and ^{68}Ga -1,4,7,10-tetraazacyclododecane-1,4,7,10-tetraacetic acid-octreotate (DOTATATE) PET/CT (in one case) were postoperatively normal. After a median 5 years

of follow-up of the patients with confirmed thyroid paraganglioma, none had been shown to have developed metastases. It is noteworthy that case 4 is a 37-year-old female patient with *SDHA* c.1799G>A p.Arg600Gln who was diagnosed with a recurrent/relapsed tumor in the thyroid bed 12 years after thyroidectomy for thyroid paraganglioma. The recurrent tumor was histologically proven to be a paraganglioma again.

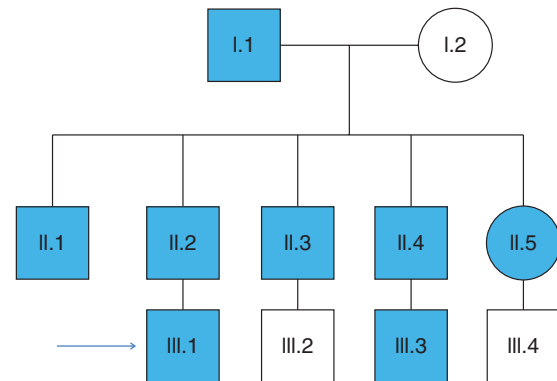
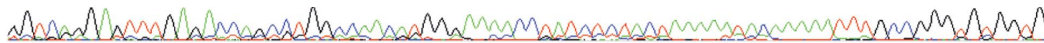


Figure 9

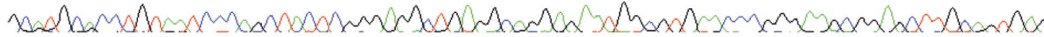Pedigree of the family with the mutation *SDHc.530G>A* (p.Arg177His) (family of case 1): family members highlighted in blue are mutation carriers, whereas those in white have been demonstrated not to carry the mutation. Patient III.1 is the patient with thyroid paraganglioma. Patient II.1 was diagnosed with bilateral pheochromocytoma at the age of 18 and 35 years. Patients II.2 and II.3 had bilateral carotid body tumors at ages of 45 and 42 respectively. Patient II.4 had thoracic paraganglioma at the age of 40. Patient II.5 had an extra-abdominal paraganglioma at the age of 33. Patient I.1 had CT of the neck, thorax, and abdomen at the age of 80 with normal results. Patient III.3 is a 14-year-old boy awaiting clinical investigations.

NM_003000.2: c.201-1339_239delinsAluYb8
 Chr1 (GRCh38): g.17033107_17034484delinsAluYb8

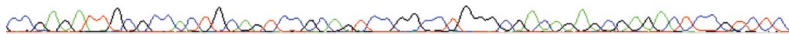
tagcaagggtttttaagcttccaattcccagtgtagcagaggtccagcagaaggacgtctacatagtgctgatacaa
 atacagataatggccagacgcagtcgctcacacctgtaatcccagcatttgggaaggctgaggcaggtggatcacttga
 ggtcaggagtttgagaccagcctggccaacatgggaaaacctatctctactaaaaatacaaaaatttgcgggtgtggtg
 |||||
 GGTCAAGGAGTTTGGACACGCTGGCCAACATGGGAAAACCTATCTCTACTAAAAATACAAAAATTTGCCGGGTGTGGT



gcatgcacctgtaatcccagctactcgggaggtgagcaggagaatcgcttgaaccgggaagtagaggttgcagtgag
 |||||
 GCATGCACCTGTAATCCAGCTACTCGGGAGGCTGAGGCAGGAGAATGGCGTGAACCCGGGAAGCGGAGCTTGCAGTGAG



ccgagatcgcaccattgctcaccaccataatcccaacactttgagaatccaaggcaggaggatcacttgagtccaggag
 |||||
 CCGAGATTGCCCACTGCAGTCCGAGTCCGGCTGGGGCAGAGGAGACTCCGCTCAAAAAAAAAAAAAAAAAAAAAA



ccgagatcgcaccattgctcaccaccataatcccaacactttgagaatccaaggcaggaggatcacttgagtccaggag
 tttagagaccagcctggcaacatggcgaatcccacctctacaaaaatacaaaaattaagctggatgtggtggcacat
 acctgtagtccagctactgggggctgagcaggaggatctctgaggctgggatgcggaggttacagatctgagatcg
 tggcactgcactccagcctgggtaacagagcaagaccocgtctcaagaaaaaagaaaaaaatgaaatacagatagta
 ctaaaggaaatgacgtatTTTTAAGTATTTTTAATCTCATAGAAAAATAGTgagtggaatggggcaggggtggc
 aaccagaaaaatgatttgtggagcacttactgtatgccaggtactatgaaaaattacataTTTTTatgtaatttccacag
 taacctgtggtgtaaatattaactctacagataaaactgaggttcagagagtaatttccgtagaatcacagttctgcat
 gatgattattatagttaaactatgatttatatgtcagatgctgctgtaaaagatctcgtgtgattaaactcacctccagca
 atcctgtgggatgcaggtgctgctctcgcactcagtgattaaatgcctaggcagaaataaatcatttgcctgcaagc
 tggtaagtggtcagccatggtgcagaccagtctcttggctgccaggccggcactccaggtcccacgccagggatgctc
 cgcttagtaccatgtcactgccttgtatggtctaggaggctcacagtgatttgactgggggactgtgagtgattgggtg
 tcttttattctctgactatgtcttcttattggttatgtatttaattactatTTAAactattgtctacatcctaaa
 aatcaaaactaaaatttgaaataaaattttggaaaaaactttgcagggagcttcagaagtaaaaaaactcggccac
 tgtatggaagttgtgtcacttctactactactttagctttccatttccctagaaatgtggttgactgtgatcatca
 aatagaactgtgcagtaacttaaaatgtaagaatctgcaaaaacaaactacagaacaattccgaagtgacctgagaa
 gaccaaatggataagctaatacatccaggtgtctccgattatattatgataaagtgtagggaggtgaaactgtacataaa
 taccactggatTTTTtctttagATGTGGCCCCATGGTATGGATGCTTTAATCAAGATTAAGAATGAAGTTGACTC

TACTTTGACCTTCCGAAGATCATGCAGAGAAGgtgagcatttcattcctggtgggctccagatacttgggtcttccaaa



gaggcttgggctggccaaagctgatagagacatctgaaaacagctgcagctctctgctgggtgaacttgcctgtgcaacc
 taattccttttcttgggtaaatgcattccaaaattcctaaccatgggtgcaagttctggttctgagtttacttctcctcagg
 agcattctatcctgtggttactgcatctggcggctccctgtgagctgctccacgctcaaggcctagctaggacctgctg

deleted region
 inserted region (AluYb8)
 (bold) sdhb exon 3

Endocrine-Related Cancer

Figure 10

Genomic sequence and electropherogram of the *SDHB* genomic rearrangement of case 2: the genomic sequences of intron 2 and exon 3 (in bold) are shown in the figure, and the intronic repeat markers are shown in italics (AluSz and AluJb). The deleted region is highlighted in red and the inserted segment (AluYb8 sequence) with its polyA tail in green. Long-range PCR was used to amplify the deleted region and produced an

approximately 1.1 kb mutant product compared with the approximately 2.5 kb WT genomic sequence, predicting a deletion of approximately 1.4 kb; bidirectional sequencing of the mutant PCR product confirmed the partial deletion of intron 2 and exon 3 and showed the insertion of approximately 150 bp corresponding to an AluYb8 sequence (shown in the figure).

AUTHOR COPY ONLY

Discussion

In the European-American-HNPGL-Registry, the prevalence of confirmed thyroid paragangliomas was 0.5%, of which all but one are very likely to carry germline mutations in *SDHx* genes. Despite the expertise and experience of our registry and the associated investigators, only five of the eight initially identified putative thyroid paragangliomas turned out to be confirmed thyroid paragangliomas, based on immunohistochemical re-analyses and re-review.

The diagnosis of a paraganglioma in the thyroid gland is a challenge. In our series, preoperative reports of results of fine-needle cytology, which was performed in three cases, were not suspicious in any case for paraganglioma, but showed atypical cells as observed in follicular neoplasias or adenomas (Table 1). Other thyroid neoplasias easily mistaken for thyroid paraganglioma include follicular and papillary carcinoma as well as non-paraganglial neuroendocrine neoplasias, chief of which is medullary thyroid carcinoma (Skiadas *et al.* 2001, Zantour *et al.* 2004, Yano *et al.* 2007, Yu *et al.* 2013). As illustrated by our study, the most important clinical technique for differentiating thyroid paraganglioma from other histologies is IHC. We reviewed the literature finding 48 available case reports (Basu & Viswanathan 2011, Phitayakorn *et al.* 2011, Armstrong *et al.* 2012, Capel 2012, Castelblanco *et al.* 2012, Costinean *et al.* 2012, Evankovich *et al.* 2012, Kieu *et al.* 2012, Mohyuddin *et al.* 2013, Yu *et al.* 2013). Similar to our cases, true thyroid paragangliomas are characterized by immunohistochemical positive staining for chromogranin A (30 of 30 investigated tumors/case), synaptophysin (21/21), S-100 (27/28), and neuron-specific enolase (18/18). Of equal importance, thyroid paragangliomas stain negative for calcitonin (38/38), carcinoembryonic antigen (CEA, 20/20), thyroglobulin (22/22), TTF1 (15/16) and cytokeratin (17/17). Indeed, these results form the basis for the WHO classification of endocrine tumors for paragangliomas in general: paragangliomas stain positive for antibodies against chromogranin A (the marker for neuroendocrine tumors) in all cases and S-100 (the marker for sustentacular cells of paragangliomas) as well as synaptophysin in nearly all cases, but negative for calcitonin (the marker for medullary thyroid carcinoma), thyroglobulin, and cytokeratin in all cases (DeLellis 2004). Interestingly, two of our paraganglioma patients are males, which is in contrast to the results in the reviewed literature (Basu & Viswanathan 2011, Phitayakorn *et al.* 2011, Armstrong *et al.* 2012, Capel 2012, Castelblanco *et al.* 2012, Costinean *et al.* 2012,

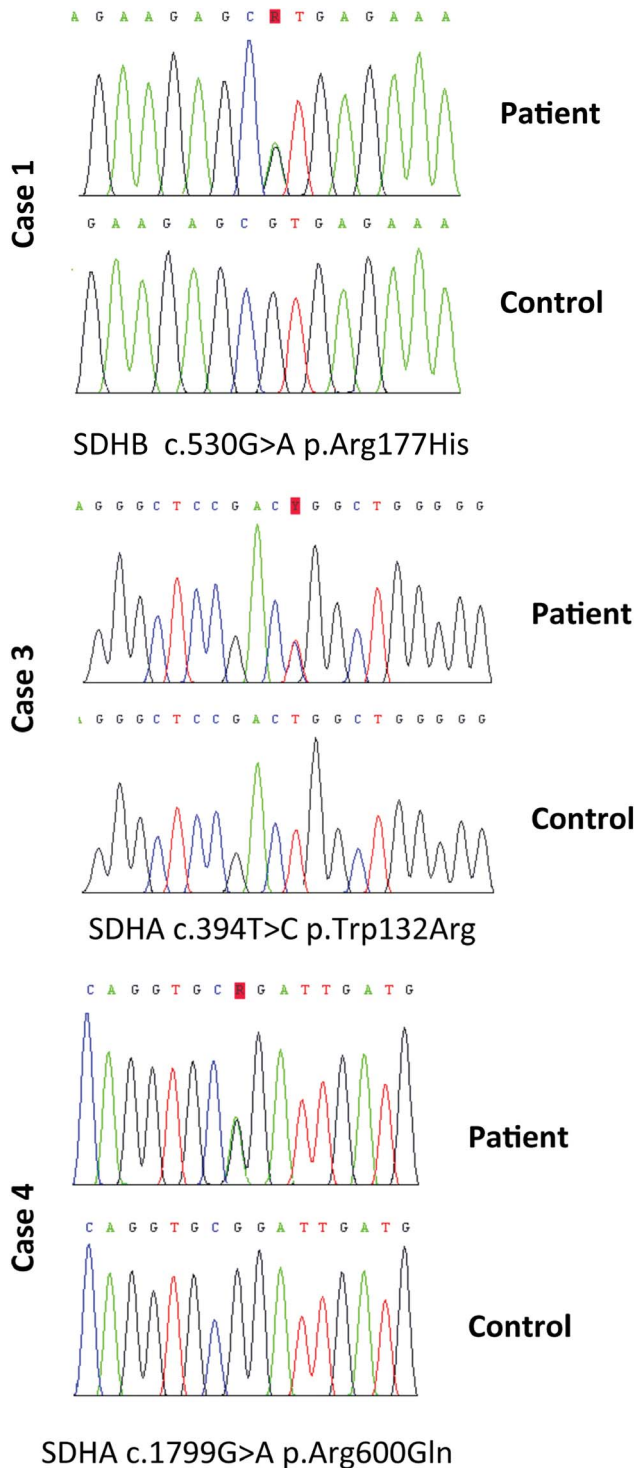


Figure 11
Electropherograms of *SDHB* and *SDHA* sequence variants identified in cases 1, 3, and 4.

Evankovich *et al.* 2012, Kieu *et al.* 2012, Mohyuddin *et al.* 2013, Yu *et al.* 2013).

Of our five confirmed thyroid paraganglioma patients, four were found very likely to carry germline mutations in *SDHx*. In contrast, none of the three patients who eventually turned out to have non-paraganglioma thyroid tumors (cases A, B, and C, Table 1, Figs 6, 7, and 8) were found to have germline mutations in the nine known pheochromocytoma–paraganglioma-related genes. Therefore, in addition to IHC, germline genetic analysis could be helpful in differentiating thyroid paraganglioma from other types of thyroid neoplasms that mimic this histology.

Thyroid paraganglioma is a rare entity with approximately 60 cases that are reported, including our series (LaGuettes *et al.* 1997, Yano *et al.* 2007, Ferri *et al.* 2009, González Poggioli *et al.* 2009, Basu & Viswanathan 2011, Phitayakorn *et al.* 2011, Varsavsky *et al.* 2011, Armstrong *et al.* 2012, Capel 2012, Castelblanco *et al.* 2012, Costinean *et al.* 2012, Evankovich *et al.* 2012, Kieu *et al.* 2012, Mohyuddin *et al.* 2013, Yu *et al.* 2013). A major question is whether the rare entity of thyroid paraganglioma is of practical clinical relevance. Our series demonstrates that this diagnosis dictates specific treatment and hence the consequences regarding correct treatment are obvious: one female patient was primarily diagnosed with a papillary thyroid carcinoma. Consequently, the patient was subjected to radioactive iodine radiation. Only the relapse of her tumor 12 years later led to the identification of a paraganglioma, resulting in the retrospective diagnosis of a primary thyroid paraganglioma and not papillary thyroid carcinoma. From an outcome point of view, it is important to know that thyroid paraganglioma may show local invasive growth but confirmed metastases are extremely rare (Massaioli *et al.* 1979, Mohyuddin *et al.* 2013).

Finally, it has to be emphasized that we found in most patients with thyroid paraganglioma germline DNA variants, which most probably represent germline mutations. This opens avenues for genetic family screening and preventive medicine. Patients with germline mutations of the *SDHB* gene, as found in two of our patients, may display adrenal, retroperitoneal, pelvic, or thoracic paragangliomas or metachronous head and neck paragangliomas such as carotid glomus tumors (Haegert *et al.* 1974, Hughes *et al.* 1997), which may become malignant and therefore have to undergo lifelong high-risk clinical surveillance (Neumann *et al.* 2004). Similar risk profiles will be identified once a statistically significant number of patients with mutations of the *SDHA* gene are available.

In summary, our systematic, population-based series of thyroid paragangliomas indicates that thyroid paraganglioma is an important entity to be differentiated from other thyroid tumors, mainly medullary thyroid carcinoma, despite its prevalence of approximately 0.5% in HNPs, because clinical management is vastly different. The fact that the genetic load of thyroid paraganglioma is seemingly 80% is also significant, with implications for both patient management and family members.

Declaration of interest

The authors declare that there is no conflict of interest that could be perceived as prejudicing the impartiality of the research reported.

Funding

This work was supported by: grants from the Deutsche Krebshilfe (grant number 107995 to H P H Neumann), the Sondra J and Stephen R Hardis Endowment (to C Eng), and the Arthur Blank Foundation, Atlanta, GA, USA (to C Eng). B Jarzab and J Krajewska were supported by Polish National Science Center grant number NN401410639. Mariola Pęczkowska, Aleksander Prejbisz and Andrzej Januszewicz were supported by a grant from the Polish Ministry of Science and Higher Education (N N402 386038).

Author contribution statement

B Jarzab, G Opocher, C Eng and H P H Neumann shared senior authorship.

References

- Armstrong MJ, Chiosea SI, Carty SE, Hodak SP & Yip L 2012 Thyroid paragangliomas are locally aggressive. *Thyroid* **22** 88–93. (doi:10.1089/thy.2011.0110)
- Basu S & Viswanathan S 2011 Primary paraganglioma of thyroid presenting as solitary thyroid mass. *Journal of Cancer Research and Therapeutics* **7** 385–387. (doi:10.4103/0973-1482.87028)
- Boedeker CC, Erlic Z, Richard S, Kontny U, Gimenez-Roqueplo A-P, Cascon A, Robledo M, de Campos JM, van Nederveen FH, de Krijger RR *et al.* 2009 Head and neck paragangliomas in von Hippel–Lindau disease and multiple endocrine neoplasia type 2. *Journal of Clinical Endocrinology and Metabolism* **94** 1938–1944. (doi:10.1210/jc.2009-0354)
- Burnichon N, Briere JJ, Libe R, Vescovo L, Riviere J, Tissier F, Jouanno E, Jeunemaitre X, Benit P, Tzagoloff A *et al.* 2010 *SDHA* is a tumor suppressor gene causing paraganglioma. *Human Molecular Genetics* **19** 3011–3020. (doi:10.1093/hmg/ddq206)
- Capel I, Gil MP, Marqués G, Barcons S & Rigla M 2012 Paraganglioma cervical simulando nódulo tiroideo con afectación del nervio recurrente. *Endocrinología y Nutrición* **59** 274–275. (doi:10.1016/j.endonu.2011.09.011)
- Castelblanco E, Gallel P, Ros S, Gatiús S, Valls J, De-Cubas AA, Maliszewska A, Yebra-Pimentel MT, Menarguez J, Gamallo C *et al.* 2012 Thyroid paraganglioma. Report of 3 cases and description of an immunohistochemical profile useful in the differential diagnosis with medullary thyroid carcinoma, based on complementary DNA array results. *Human Pathology* **43** 1103–1112. (doi:10.1016/j.humpath.2011.08.022)

- Castro-Vega LJ, Buffet A, De Cubas AA, Cascon A, Menara M, Khalifa E, Amar L, Azriel S, Bourdeau I, Chabre O *et al.* 2014 Germline mutations in *FH* confer predisposition to malignant pheochromocytomas and paragangliomas. *Human Molecular Genetics* **23** 2440–2446. (doi:10.1093/hmg/ddt639)
- Costinean S, Balatti V, Bottoni A, Old M, Croce C & Wakely PE Jr 2012 Primary intrathyroidal paraganglioma: histopathology and novel molecular alterations. *Human Pathology* **43** 2371–2375. (doi:10.1016/j.humpath.2012.06.021)
- DeLellis RA 2004 Paraganglioma. In *Pathology and Genetics of Tumours of the Endocrine Organs. World Health Organization Classification of Tumours Pathology and Genetics of Tumours of Endocrine Organs*, p 117. Eds RA DeLellis, RV Lloyd, PU Heitz & C Eng. Lyon: IARC Press.
- Evankovich J, Dedhia RC, Bastaki JM, Tublin M & Johnson JT 2012 Primary sclerosing paraganglioma of the thyroid gland: a case report. *Annals of Otolaryngology, Rhinology, and Laryngology* **121** 510–515.
- Ferri E, Manconi R, Armato E & Ianniello F 2009 Primary paraganglioma of thyroid gland: a clinicopathologic and immunohistochemical study with review of the literature. *Acta Otorhinolaryngologica Italica* **29** 97–102.
- González Poggioli N, López Amado M & Yebra Pimentel M 2009 Paraganglioma of the thyroid gland: a rare entity. *Endocrine Pathology* **20** 62–65. (doi:10.1007/s12022-009-9066-2)
- Haegert DG, Wang NS, Farrer PA, Seemayer TA & Thelmo W 1974 Non-chromaffin paragangliomatosis manifesting as a cold thyroid nodule. *American Journal of Clinical Pathology* **61** 561–570.
- Hughes JH, El-Mofty S, Sessions D & Liapis H 1997 Primary intrathyroidal paraganglioma with metachronous carotid body tumor: report of a case and review of the literature. *Pathology, Research and Practice* **193** 791–796 discussion 797–799. (doi:10.1016/S0344-0338(97)80059-3)
- Kieu V, Yuen A, Tassone P & Hobbs CG 2012 Cervical paraganglioma presenting as thyroid neoplasia. *Otolaryngology and Head and Neck Surgery* **146** 516–518. (doi:10.1177/0194599811419229)
- LaGuetta J, Matias-Guiu X & Rosai J 1997 Thyroid paraganglioma: a clinicopathologic and immunohistochemical study of three cases. *American Journal of Surgical Pathology* **21** 748–753. (doi:10.1097/0000478-199707000-00002)
- Lloyd RV, Tischler AS, Kimura N, McNicol AM & Young WF 2004 Adrenal tumors. In *Pathology and Genetics of Tumours of the Endocrine Organs World Health Organization Classification of Tumours*, pp 137–138. Eds RA DeLellis, RV Lloyd, PU Heitz & C Eng. Lyon: IARC Press.
- Massaioli N, Balbo G, Fausone G & Negro D 1979 Paraganglioma branchiomero endotiroideo (non cromaffine). Descrizione di un caso clinico. *Minerva Chirurgica* **34** 867–874.
- Mohyuddin N, Ferrer K & Patel U 2013 Malignant paraganglioma of the thyroid gland with synchronous bilateral carotid body tumors. *Ear, Nose, & Throat Journal* **92** E20–E23.
- Neumann HP, Pawlu C, Peczkowska M, Bausch B, McWhinney SR, Muresan M, Buchta M, Franke G, Klisch J, Bley TA *et al.* 2004 Distinct clinical features of paraganglioma syndromes associated with *SDHB* and *SDHD* gene mutations. *Journal of the American Medical Association* **292** 943–951. (doi:10.1001/jama.292.8.943)
- Neumann HP, Erlic Z, Boedeker CC, Rybicki LA, Robledo M, Hermsen M, Schiavi F, Falcioni M, Kwok P, Bauters C *et al.* 2009 Clinical predictors for germline mutations in head and neck paraganglioma patients: cost reduction strategy in genetic diagnostic process as fall-out. *Cancer Research* **69** 3650–3656. (doi:10.1158/0008-5472.CAN-08-4057)
- Phitayakorn R, Faquin W, Wei N, Barbesino G & Stephen AE 2011 Thyroid-associated paragangliomas. *Thyroid* **21** 725–733. (doi:10.1089/thy.2010.0362)
- Schiavi F, Boedeker CC, Bausch B, Peczkowska M, Gomez CF, Strassburg T, Pawlu C, Buchta M, Salzmann M, Hoffmann MM *et al.* 2005 Predictors and prevalence of paraganglioma syndrome associated with mutations of the *SDHC* gene. *Journal of the American Medical Association* **294** 2057–2063. (doi:10.1001/jama.294.16.2057)
- Skiadas PK, Kakavoulis TN & Gikonti IJ 2001 Normalisation of blood pressure and heart rate after excision of a thyroid paraganglioma. *European Journal of Surgery* **167** 392–394. (doi:10.1080/110241501750215320)
- Toledo RA, Qin Y, Srikantan S, Morales NP, Li Q, Deng Y, Kim SW, Pereira MA, Toledo SP, Su X *et al.* 2013 *In vivo* and *in vitro* oncogenic effects of *HIF2A* mutations in pheochromocytomas and paragangliomas. *Endocrine-Related Cancer* **20** 349–359. (doi:10.1530/ERC-13-0101)
- Varsavsky M, Cortes Berdonces M, Alonso G, Garcia Martin A & Munoz Torres M 2011 Adenopatía metastásica de un microcarcinoma tiroideo, diagnóstico final de un supuesto paraganglioma. *Endocrinología y Nutrición* **58** 143–144. (doi:10.1016/j.endonu.2010.10.0090)
- Yang C, Zhuang Z, Flidner SM, Shankavaram U, Sun MG, Bullova P, Zhu R, Elkahlon AG, Kourlas PJ, Merino M *et al.* 2015 Germ-line *PHD1* and *PHD2* mutations detected in patients with pheochromocytoma/paraganglioma-polycythemia. *Journal of Molecular Medicine* **93** 93–104. (doi:10.1007/s00109-014-1205-7)
- Yano Y, Nagahama M, Sugino K, Ito K & Kameyama K 2007 Paraganglioma of the thyroid: report of a male case with ultrasonographic imagings, cytologic, histologic, and immunohistochemical features. *Thyroid* **17** 575–578. (doi:10.1089/thy.2006.0284)
- Yu BH, Sheng WQ & Wang J 2013 Primary paraganglioma of thyroid gland: a clinicopathologic and immunohistochemical analysis of three cases with a review of the literature. *Head and Neck Pathology* **7** 373–380. (doi:10.1007/s12105-013-0467-7)
- Zantour B, Guilhaume B, Tissier F, Louvel A, Jeunemaitre X, Gimenez-Roqueplo AP & Bertagna X 2004 A thyroid nodule revealing a paraganglioma in a patient with a new germline mutation in the *succinate dehydrogenase B* gene. *European Journal of Endocrinology* **151** 433–438. (doi:10.1530/eje.0.1510433)

Received in final form 7 January 2015

Accepted 16 January 2015

Made available online as an Accepted Preprint

16 January 2015