

Sensitivity and specificity of antibodies against HPV16 E6 and other early proteins for the detection of HPV16-driven oropharyngeal squamous cell carcinoma

Dana Holzinger¹, Gunnar Wichmann², Lorena Baboci^{1,3}, Angelika Michel¹, Daniela Höfler¹, Manuel Wiesenfarth⁴, Lea Schroeder¹, Paolo Boscolo-Rizzo⁵, Christel Herold-Mende^{6,7}, Gerhard Dyckhoff⁶, Andreas Boehm², Annarosa Del Mistro⁸, Franz X. Bosch⁶, Andreas Dietz², Michael Pawlita¹ and Tim Waterboer¹

¹ Division of Molecular Diagnostics of Oncogenic Infections, Infection, Inflammation and Cancer Program, German Cancer Research Center (DKFZ), Heidelberg, Germany

² Department of Otorhinolaryngology, University Hospital Leipzig, Leipzig, Germany

³ Department of Oncology and Surgical Sciences, University of Padua, Padua, Italy

⁴ Division of Biostatistics, German Cancer Research Center, Heidelberg, Germany

⁵ Department of Neurosciences, ENT Clinic and Regional Center for Head and Neck Cancer, University of Padua, Treviso, Italy

⁶ Department of Otorhinolaryngology, Head and Neck Surgery, Heidelberg University, Heidelberg, Germany

⁷ Department of Neurosurgery, Division of Experimental Neurosurgery, Heidelberg University, Heidelberg, Germany

⁸ Department of Immunology and Molecular Oncology, IRCCS Veneto Institute of Oncology (IOV), Padua, Italy

To determine the sensitivity and specificity of HPV16 serology as diagnostic marker for HPV16-driven oropharyngeal squamous cell carcinoma (OPSCC), 214 HNSCC patients from Germany and Italy with fresh-frozen tumor tissues and sera collected before treatment were included in this study. Hundred and twenty cancer cases were from the oropharynx and 94 were from head and neck cancer regions outside the oropharynx (45 oral cavity, 12 hypopharynx and 35 larynx). Serum antibodies to early (E1, E2, E6 and E7) and late (L1) HPV16 proteins were analyzed by multiplex serology and were compared to tumor HPV RNA status as the gold standard. A tumor was defined as HPV-driven in the presence of HPV16 DNA and HPV16 transformation-specific RNA transcript patterns (E6*1, E1⁺E4 and E1C). Of 120 OPSCC, 66 (55%) were HPV16-driven. HPV16 E6 seropositivity was the best predictor of HPV16-driven OPSCC (diagnostic accuracy 97% [95%CI 92–99%], Cohen's kappa 0.93 [95%CI 0.8–1.0]). Of the 66 HPV-driven OPSCC, 63 were HPV16 E6 seropositive, compared to only one (1.8%) among the 54 non-HPV-driven OPSCC, resulting in a sensitivity of 96% (95%CI 88–98) and a specificity of 98% (95%CI 90–100). Of 94 HNSCC outside the oropharynx, six (6%) were HPV16-driven. In these patients, HPV16 E6 seropositivity had lower sensitivity (50%, 95%CI 19–81), but was highly specific (100%, 95%CI 96–100). In conclusion, HPV16 E6 seropositivity appears to be a highly reliable diagnostic marker for HPV16-driven OPSCC with very high sensitivity and specificity, but might be less sensitive for HPV16-driven HNSCC outside the oropharynx.

Key words: head and neck squamous cell carcinoma, oropharynx, human papillomavirus, early proteins, diagnosis, biomarker, serology
Additional Supporting Information may be found in the online version of this article.

Grant sponsor: European Commission, grant HPV-AHEAD; **Grant number:** FP7-HEALTH-2011-282562; **Grant sponsor:** Leipzig Research Center for Civilization Diseases (LIFE), University of Leipzig, European Union, European Regional Development Fund (ERFD) and Free State of Saxony within the framework of the Excellence Initiative (LIFE)

DOI: 10.1002/ijc.30697

History: Received 13 Jan 2017; Accepted 27 Feb 2017; Online 18 Mar 2017

Correspondence to: Dana Holzinger, PhD, Division of Molecular Diagnostics of Oncogenic Infections (F020), Infection, Inflammation and Cancer Program, German Cancer Research Center (DKFZ), Im Neuenheimer Feld 280, D-69120 Heidelberg, Germany, Tel.: +49 6221 42 4603, Fax: +49 6221 42 4932, E-mail: d.holzinger@dkfz.de

Introduction

Human papillomavirus (HPV) infection is associated with a subset of oropharyngeal squamous cell carcinomas (OPSCC),^{1–3} and a small proportion of head and neck squamous cell carcinomas (HNSCC) outside the oropharynx.^{4,5} HPV-driven OPSCC are regarded as distinct tumor entity and are characterized by (i) at least one HPV genome copy per tumor cell,^{6–8} (ii) active viral oncogene expression^{6,7,9–13} affecting the levels of cellular proteins regulating cell cycle (e.g., high levels of p16^{INK4a} and low levels of pRb) as well as apoptosis (low levels of p53) and (iii) better patient survival.^{9,11,14} In contrast, HPV DNA-positive but non-HPV-driven OPSCC harbor HPV DNA only in low copy numbers with absent or low-level viral transcription, have no apparent effect on cellular surrogate markers (low levels of p16^{INK4a} and high levels of pRb) and patient survival is similar to that of patients with HPV-negative tumors.^{1,6,11} Therefore, documenting biologically active HPV infections rather than mere

What's new?

Human papillomavirus (HPV) infection is associated with a subset of oropharyngeal squamous cell carcinomas (OPSCC). HPV-driven OPSCC patients have an improved survival, but a reliable marker that is applicable in clinical operations is still needed. Here, the authors analyzed HPV16 antibody levels to the oncoproteins E6 and E7 and to the regulatory proteins E1 and E2 in the serum of patients with molecularly-defined tumor HPV status. HPV16 serology could identify HPV-driven OPSCC patients with very high sensitivity [96% (95%CI 88–98)] and specificity [98% (95%CI 90–100)]. HPV16 serology may thus represent a powerful and accurate diagnostic marker for HPV-driven OPSCC.

HPV DNA detection is necessary to determine accurate HPV-attributable fractions in all HNSCC. In research studies, detection of active viral oncogene expression (*i.e.*, HPV mRNA transcripts encoding the viral oncoproteins) is currently considered the gold-standard for defining HPV-driven head and neck cancers.^{4,5,8,11} Particularly in studies where only formalin-fixed paraffin-embedded tissue is available, immunohistochemical detection of overexpressed cellular surrogate marker p16^{INK4a}, or the detection of viral DNA are commonly used to define HPV-positive tumors, yet none of these markers alone has sufficient sensitivity and specificity.^{8,11,15} Thus, a combination of these markers has been suggested⁸ and can be regarded as accepted marker combination for diagnosing HPV-driven HNSCC, but in some studies a lower sensitivity and specificity have also been reported.¹⁵ A reliable marker for the identification of HPV-driven HNSCC that is applicable in routine clinical operations is, therefore, still needed.

Serum antibodies to the HPV oncoproteins E6 and E7 are strongly associated with HPV-driven OPSCC.^{16–19} A recent study showed that high levels of HPV16 E6 antibodies were already present in 35% of European OPSCC patients up to 10+ years prior to diagnosis.²⁰ Besides the strong associations of E6 and/or E7 seropositivity with OPSCC, seropositivity to HPV regulatory proteins E1 and E2 is also strongly associated with OPSCC,^{20–23} while the association of seropositivity to HPV E4 protein with OPSCC is weaker.^{20,24} The seroprevalence of any of the HPV early proteins (E proteins) in patients with HPV-unrelated tumors and in healthy individuals is low.^{20,25–31} A small number of studies have investigated serological and molecular HPV markers in combination and have reported HPV16 E6 and/or E7 seropositivity in 60–100% of HPV-positive OPSCC using HPV16 DNA and/or p16^{INK4a} as molecular markers for HPV-positivity;^{8,17,22,24,28,29,31–33} only two smaller studies analyzed HPV RNA transcription in the tumors and E6 and E7 serum markers.^{8,30} Sensitivity and specificity of HPV serology as a marker for HPV-driven tumors using HPV RNA as gold-standard have so far not yet been determined.

The aim of this study was to determine the prediction accuracy of HPV serology for (i) HPV16-driven OPSCC and (ii) HPV16-driven HNSCC outside the oropharynx. In patients from three HNSCC study centers,^{11,34,35} we analyzed HPV16 antibody levels to the oncoproteins E6 and E7 and to

the regulatory proteins E1 and E2 in serum of the patients with molecularly defined tumor HPV status. We calculated sensitivity and specificity of seropositivity to HPV16 E proteins individually and in combination for the detection of HPV16-driven OPSCC as well as cancers of the oral cavity, hypopharynx and larynx.

Methods**Study population and patient samples**

Patients diagnosed with primary HNSCC from three study centers, Padua (Italy), Heidelberg and Leipzig (Germany) were included if (i) a fresh-frozen tumor biopsy with $\geq 25\%$ tumor-cell content, (ii) serum samples at time of diagnosis, (iii) valid HPV DNA status of the tumor tissues and (iv) valid viral RNA pattern analyses on HPV16 DNA-positive tumors were available.^{11,34,35} The original study designs allowed covering a broad range of tumors. In Heidelberg only OPSCC and in Leipzig primarily HPV DNA-positive HNSCC were collected; we, therefore, expected a high HPV seroprevalence in these patients. In contrast, squamous cell carcinomas from all head and neck regions (except nasopharynx) were collected in Padua. As the HPV-attributable fraction in HNSCC in this geographical region is relatively low,³⁵ we expected a low HPV seroprevalence in these patients. Patients with HPV DNA-positive tumors from other types than HPV16 ($n = 4$) were excluded from this study. In total, 214 patients (40 from Heidelberg, 76 from Leipzig, and 98 from Padua) fulfilled the inclusion criteria. The study was approved by the Ethics Committees of (i) the Medical Faculty of the University of Heidelberg, study codes 70/99 and 176/2002, (ii) the Medical Faculty of the University of Leipzig, study codes 201–10-12072010 and 202–10-12072010 and (iii) the Clinical Experimentation (CEP) of Treviso, ethic votes 345/AULSS9 and 421/AULSS9. Biopsies were snap-frozen in precooled isopentane/liquid nitrogen (Heidelberg and Padua) or in TRIzol® (Leipzig) and stored at -80°C until isolation of nucleic acids. Serum samples were stored at -80°C . Patient and tumor characteristics were obtained locally from clinical records and combined in a central data base.

Nucleic acid isolation and HPV16 detection in tumor tissues

Nucleic acids of the tumor tissues were prepared as previously described.^{11,34,35} In brief, cryosections were homogenized

in liquid nitrogen (Heidelberg and Padua) or tissues were mechanically disintegrated for 80 sec at 4000 rpm in a Peqlab MiniLys (Peqlab, Germany) (Leipzig). Tumor cell content was determined in adjacent hematoxylin-eosin-stained sections (Heidelberg and Padua). DNA was isolated using QIAamp DNA Mini Kit (Qiagen, Germany) (Heidelberg), the standard TRIzol® protocol (Invitrogen) (Leipzig) or MagNA Pure 96 DNA and viral NA Large Volume Kit (Roche, Germany) (Padua). RNA was isolated using RNeasy Mini Kit (Qiagen) (Heidelberg and Padua) or Ambion Pure Link™ RNA Mini Kit (Life Technologies) (Leipzig), always with on-column DNase I digestion (Qiagen).

Molecular HPV markers were analyzed centrally at the German Cancer Research Center (Heidelberg). HPV DNA was determined by BSGP5+/6+ PCR/Multiplex Papillomavirus Genotyping^{11,34–37} capable of homogeneous amplification of 51 mucosal HPV types and amplicon detection by type-specific hybridization to probes on xMAP Luminex beads. Cellular β -globin sequences were co-amplified as internal DNA quality control.

HPV16 RNA patterns were analyzed in all HPV16 DNA-positive tumors ($n = 94$) by reverse-transcription quantitative PCR (RT-qPCR)³⁸ ($n = 82$) or by nucleic acid sequence-based amplification (NASBA) and hybridization to splice-specific probes on Luminex beads^{11,39} ($n = 12$). Briefly, two RT-qPCR reactions quantified the HPV16 transcripts E6*I (226^526), E1^E4 (880^3358) and E1C (880^2582) as well as ubiquitin C (ubC) as internal RNA quality control. Viral RNA patterns were defined as positive when E6*I was up-regulated relative to E1^E4 and/or E1C was present. In NASBA, HPV16 E6*I and/or E6*II, E1^E4, E1C and L1 (3632^5639) transcripts were quantified. Transcript ratios were calculated for E6*II or E6*I over E1^E4, and for E1C over L1. The cutoffs for viral RNA patterns positivity in both assays were previously defined on HPV DNA-positive cervical cell samples.^{38,39} Presence of viral RNA patterns has been demonstrated¹¹ to be the best molecular marker among HPV DNA, viral load and p16^{INK4a} to define HPV-driven OPSCC and to predict best improved survival. We, therefore, used viral RNA patterns as gold-standard, that is, HPV DNA-positive and viral RNA patterns-positive tumors were defined as HPV-driven. HPV DNA-negative or DNA-positive but viral RNA patterns-negative tumors had similar clinical characteristics, similarly low HPV16 antibody prevalence (Supporting Information Table S1) and seroreactivity (Supporting Information Figure S1) and were, therefore, combined to the non-HPV-driven group ($n = 142$).

HPV16 serology

HPV antibodies were analyzed by bead-based multiplex serology, as described previously.⁴⁰ Briefly, bacterially expressed affinity-purified HPV16 proteins E1, E2, E6, E7 and L1 fused to N-terminal Glutathione S-transferase and bound to fluorescence-labelled polystyrene beads (Luminex) were exposed to 1:100 diluted human sera. Bound antibodies were stained

by anti-human immunoglobulin and fluorescent reporter conjugate, and median fluorescence intensity (MFI) was determined. MFI values were dichotomized as antibody positive or negative^{33,40–42} using predefined cutoff values,^{20,27} that is, 1000 MFI (E6), 548 MFI (E7), 200 MFI (E1), 679 MFI (E2) and 422 MFI (L1). For quality control, 76/214 serum samples were randomly selected and re-analyzed independently. Agreement of dichotomized E6 and E2 seropositivity was 100% each, and for E7, E1 and L1 seropositivity, it was 97%, 80% and 96%, respectively.

Donor identity of tumor tissues and serum samples

DNA samples of patients with discordant results between molecular HPV status in the tumor tissues and HPV16 serology in their serum were included in a SNP typing assay⁴³ to proof the donor identity of these samples. DNA was extracted from 50 μ l serum samples using MagNA Pure 96 DNA and viral NA Large Volume Kit (Roche, Germany).

P16^{INK4a} immunostaining

P16^{INK4a} expression was determined and evaluated as described previously.⁴⁴ Due to limited access to FFPE material, immunostaining was primarily done on HPV-driven HNSCC. P16^{INK4a} immunostaining data were available for 122/214 cases, that is, 65 HPV-driven and 57 non-HPV-driven HNSCC patients.

Statistical evaluation

Patient and tumor characteristics were analyzed in relation to the HPV RNA status of the tumors (non-HPV-driven and HPV-driven). MFI values were plotted for all HPV16 antibodies by HPV RNA status of the tumor tissues, medians were calculated and compared using Mann-Whitney non-parametric analysis (GraphPad Prism, version 5.03).

Sensitivity, specificity, diagnostic accuracy and Cohen's kappa values of HPV16 seropositivity and the respective 95% confidence intervals (95% CI) were calculated to estimate prediction accuracy of HPV serology (all individual markers and all possible marker combinations) for HPV-driven HNSCC and by head and neck regions (OPSCC and HNSCC outside the oropharynx). Diagnostic accuracy was calculated as a proportion of correctly classified subjects among all subjects.

All statistical tests were performed using SAS software version 9.4 with a level of significance of 0.05. Cluster analysis (heat map) of HPV serum markers was done using Multi Experiment Viewer Software (MeV, Version 4.9.0).

Results

Molecular HPV16 status of HNSCC and patient characteristics

The majority of HPV-driven HNSCC patients came from Heidelberg and Leipzig, while non-HPV-driven HNSCC patients were mainly from Padua (Table 1). There were no gender, age and tumor size differences by HPV RNA status.

Table 1. Patient and tumor characteristics by HPV RNA status of the HNSCC tumor tissues studied from three study centers, Heidelberg (D), Leipzig (D) and Padua (I)

	Total (<i>n</i> = 214)	HPV– (<i>n</i> = 142)	HPV+ (<i>n</i> = 72)	<i>p</i> -value
Characteristics	<i>n</i> (%)	<i>n</i> (%)	<i>n</i> (%)	
Study center				
Heidelberg (D)	40 (19)	25 (18)	15 (21)	<0.001 ¹
Leipzig (D)	76 (36)	23 (16)	53 (74)	
Padua (I)	98 (45)	94 (66)	4 (5)	
Gender				
Male	159 (74)	107 (75)	52 (72)	0.6 ¹
Female	55 (26)	35 (25)	20 (28)	
Age, years				
Median (range)	63 (39–95)	63 (40–95)	62 (39–85)	0.5 ²
Head and neck region				
Oral cavity	45 (21)	44 (31)	1 (1)	<0.001 ¹
Oropharynx	120 (56)	54 (38)	66 (92)	
Hypopharynx	12 (6)	11 (8)	1 (1)	
Larynx	37 (17)	33 (23)	4 (6)	
Oropharynx subsite (<i>n</i> = 120)				
Tonsil	70 (58)	25 (46)	45 (68)	0.02 ¹
Base of tongue	20 (17)	9 (17)	11 (17)	
Other	30 (25)	20 (37)	10 (15)	
Tumor size				
T1-T2	114 (53)	74 (52)	40 (56)	0.6 ¹
T3-T4	100 (47)	68 (48)	32 (44)	
Lymph node involvement				
N0	71 (33)	61 (43)	10 (14)	<0.001 ¹
N+	143 (67)	81 (57)	62 (86)	
Clinical stage				
I–III	80 (37)	68 (48)	12 (17)	<0.001 ¹
IV	134 (63)	74 (52)	60 (83)	
Tobacco				
Never	73 (35)	42 (31)	31 (44)	0.02 ¹
Former	27 (13)	14 (10)	13 (18)	
Current	106 (52)	79 (59)	27 (38)	
Missing	8	7	1	
Alcohol				
Never	56 (28)	42 (32)	14 (20)	0.04 ¹
Former	19 (9)	15 (11)	4 (5)	
Current	128 (63)	75 (57)	53 (75)	
Missing	11	10	1	
p16 immunostaining ³				
High	79 (65)	16 (28)	63 (97)	<0.001 ¹
Low	43 (35)	41 (72)	2 (3)	
Missing	92	85	7	

Abbreviations: HPV–: non-HPV-driven; HPV+: HPV-driven.

¹χ² test.²Mann–Whitney test.³p16 data were available for 122/214 cases.

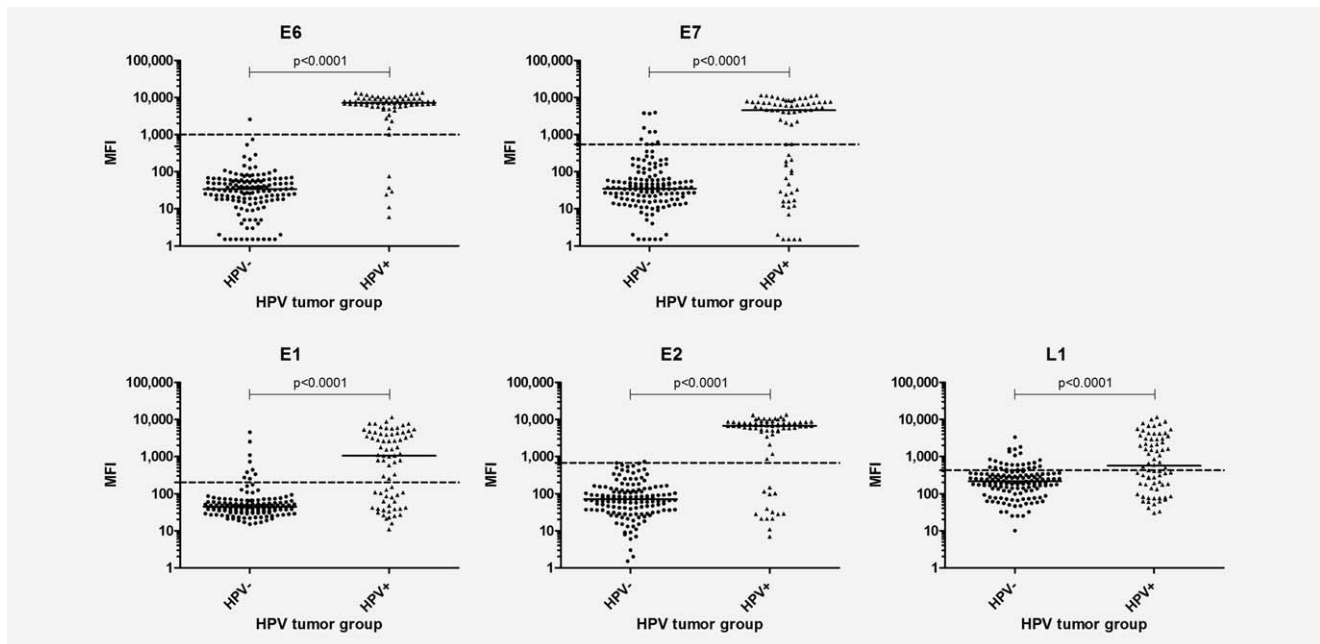


Figure 1. Median fluorescence intensities (MFI values) of HPV16 antibodies (E6, E7, E1, E2 and L1) in patients with HPV- and HPV+ HNSCCs. HPV-, HPV DNA-negative or HPV16 DNA-positive but HPV16 RNA patterns-negative (non-HPV-driven); HPV+, HPV16 DNA-positive and HPV16 RNA patterns-positive (HPV-driven); dashed lines, cutoffs for the respective antibodies; black bars, median MFI. *P*-values were calculated using Mann-Whitney test.

HPV-driven tumors originated mainly from the oropharynx (92%), in particular from the tonsils (68%) and the base of tongue (17%), while non-HPV-driven tumors originated mainly from non-oropharyngeal sites, for example, oral cavity (31%), larynx (23%) and hypopharynx (8%). Compared to non-HPV-driven HNSCC patients, HPV-driven HNSCC patients had more lymph node involvement and advanced clinical stage, were more frequently non-smokers and current alcohol consumers and had high p16^{INK4a} expression (Table 1). Of the 120 OPSCC, 66 (55%) were HPV-driven and of 94 HNSCC outside the oropharynx only 6 (6%) were HPV-driven (Table 1).

HPV16 seropositivity in HNSCC patients by HPV status of the tumor tissues

High antibody levels to all four E proteins and to L1 were found frequently in HPV-driven HNSCC patients and rarely in non-HPV-driven HNSCC patients (Fig. 1).

Of the 72 HPV-driven HNSCC patients, 66 (92%) were E6 seropositive. In detail, 33 (49%; 32 oropharynx and 1 hypopharynx) were seropositive for all E antibodies, and another 17 (25%; 16 oropharynx and 1 larynx) were seropositive for E6 and two other E antibodies (Fig. 2). Four HPV-driven HNSCC patients (6%; all oropharynx) were E6 seropositive only, without antibodies to the other E antigens. One HPV-driven OPSCC patient was E6 seronegative, but was strongly seropositive for the other E antibodies, that is, E7 (9768 MFI), E1 (7646 MFI) and E2 (5263 MFI) and we, therefore, defined an algorithm termed 'HPV sero-pattern' that combined E6 seropositivity (>1000 MFI) and/or

seropositivity to at least three E proteins. Five HPV-driven HNSCC patients (7%; 2 oropharynx, 1 oral cavity and 2 larynx carcinomas) were HPV E6 seronegative, with three being negative for all E antibodies and two being E7 seropositive only (MFI values 549 and 1879). One non-HPV-driven OPSCC patient was E6 seropositive with strong reactivity to E6 (2571 MFI) as well as to E1 (4527 MFI) (Figs. 1 and 2). Serological and molecular HPV results were independently reproduced for the five HPV sero-pattern negative HPV-driven HNSCC patients, and donor identity of serum and tumor sample pairs was confirmed by SNP analysis of extracted DNA.⁴³ Donor identity for serum and tumor sample of the HPV E6 seropositive but non-HPV-driven HNSCC could not be verified by SNP typing due to insufficient sample volume.

Sensitivity and specificity of HPV16 serology for HPV-driven HNSCC

For each individual antigen, antibody sensitivity for HPV-driven tumors in OPSCC cases ranged from 97% for any E to 53% for L1, and specificity ranged from 98% for both E6 and E1 to 57% for L1 (Table 2). The best prediction accuracy was found for E6 seropositivity (diagnostic accuracy 97% [95% CI 92–99], Cohen's kappa 0.93 [0.8–1.0]). The HPV sero-pattern algorithm had similar predictive values as E6 seropositivity: sensitivity 97% (95%CI 90–99), specificity 98% (95%CI 90–100), diagnostic accuracy 98% (95%CI 93–99) and Cohen's kappa 0.95 (0.8–1.0). Sensitivity in HNSCC cases outside the oropharynx ranged from 83% for any E to 17% for E1, and specificity ranged from 100% for E6 to 74%

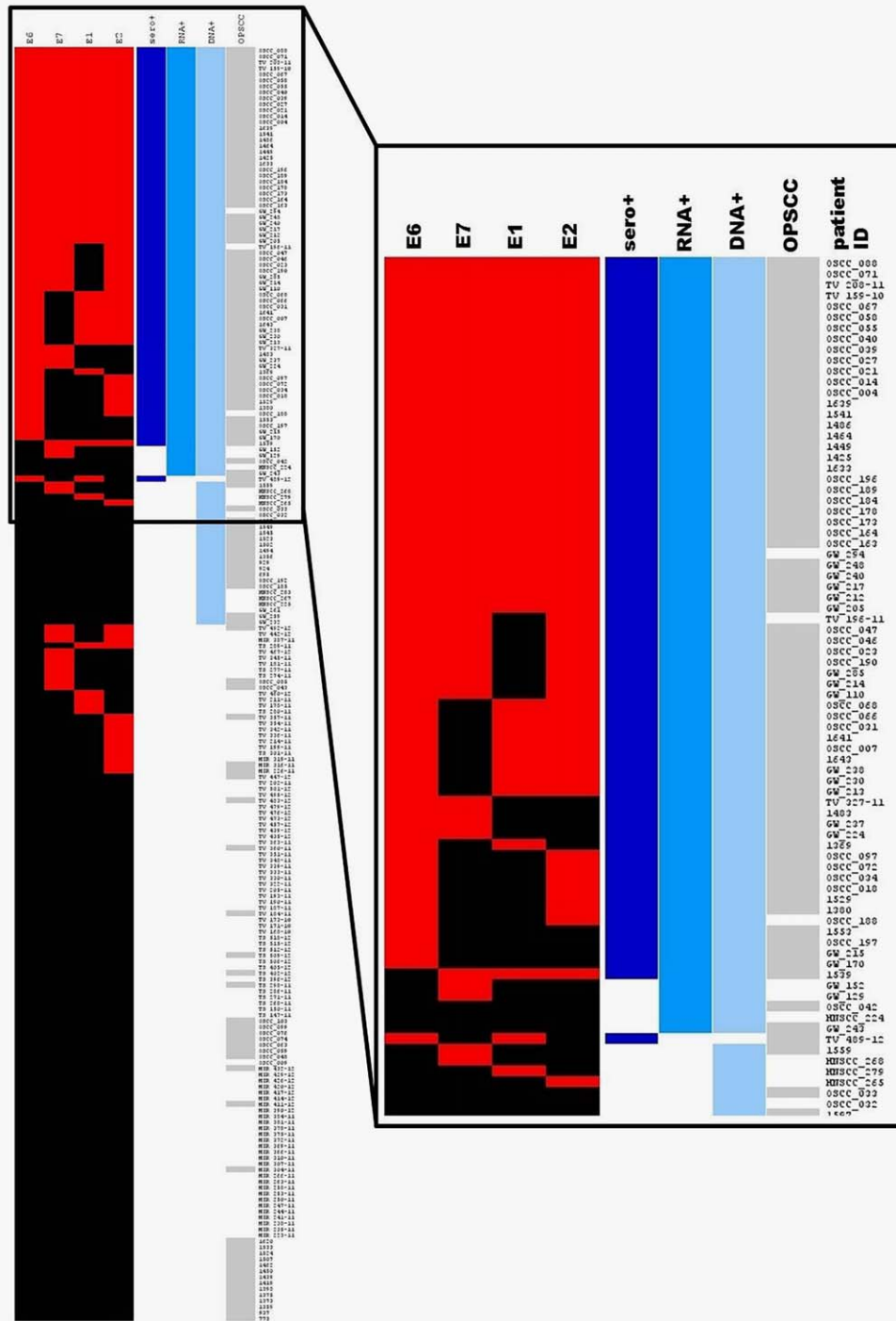


Figure 2. Heat-map of HPV16 E antibodies, as well as DNA and RNA status in HNSCC patients. Patients were clustered by seropositivity (red) to early antigens (E6, E7, E1 and E2) and grouped according to their molecular HPV status (RNA+ and DNA+) in the tumor tissues. The HPV sero-pattern algorithm (*i.e.*, E6 > 1000MFI or seropositive for three of four early proteins) is displayed as sero+. Seronegativity is displayed in black. Clustering of HPV16 E6 seropositive and/or HPV RNA+ patients is depicted in higher magnification. [Color figure can be viewed at wileyonlinelibrary.com]

for any E. Compared to OPSCC cases, the sensitivity of E6 seropositivity and the HPV sero-pattern was much lower in HNSCC cases outside the oropharynx (50% vs. ≥96%), while specificity was high in all head and neck regions (98% in

OPSCC cases and 100% in HNSCC cases outside the oropharynx, Table 2).

Antibody seropositivity of all possible E combinations were highly specific (≥97%), but sensitivity (46–88%) and

Table 2. Sensitivity, specificity, diagnostic accuracy and kappa value for HPV16 antibodies by HPV RNA status and HNSCC region

	HPV	Serology	HPV-	HPV+	Sensitivity %	Specificity %	Diagnostic accuracy %	Cohen's kappa
	Antibody	Status	<i>n</i>	<i>n</i>	(95%CI)	(95%CI)	(95%CI)	(95%CI)
OPSCC	E6	-	53	3				
		+	1	63	96 (88-98)	98 (90-100)	97 (92-99)	0.93 (0.8-1.0)
	E7	-	50	22				
		+	4	44	67 (55-77)	93 (83-97)	78 (70-85)	0.58 (0.4-0.8)
	E1	-	53	21				
		+	1	43	65 (53-76)	98 (90-100)	80 (72-86)	0.61 (0.4-0.8)
	E2	-	50	11				
		+	4	55	83 (73-90)	93 (83-97)	88 (80-92)	0.80 (0.6-0.9)
	L1	-	48	31				
		+	6	35	53 (41-65)	57 (33-79)	54 (43-64)	0.06 (0.0-0.2)
	any E	-	45	2				
		+	9	64	97 (90-99)	83 (71-91)	91 (84-95)	0.81 (0.6-1.0)
sero-pattern	-	53	2					
	+	1	64	97 (90-99)	98 (90-100)	98 (93-99)	0.95 (0.8-1.0)	
HNSCC outside the oropharynx								
E6	-	88	3 ¹					
	+	0	3 ²	50 (19-81)	100 (96-100)	97 (91-99)	0.65 (0.5-0.8)	
E7	-	80	2					
	+	8	4	67 (30-90)	91 (83-95)	89 (82-94)	0.39 (0.2-0.6)	
E1	-	82	5					
	+	6	1	17 (3-56)	93 (86-97)	88 (80-93)	0.09 (0.0-0.3)	
E2	-	77	3					
	+	11	3	50 (19-81)	88 (79-93)	85 (77-91)	0.23 (0.1-0.4)	
L1	-	72	2					
	+	16	4	67 (30-90)	82 (73-89)	81 (72-88)	0.23 (0.1-0.4)	
any E	-	65	1					
	+	23	5	83 (44-97)	74 (64-82)	75 (65-82)	0.21 (0.1-0.4)	
sero-pattern	-	88	3 ¹					
	+	0	3 ²	50 (19-81)	100 (96-100)	97 (91-99)	0.65 (0.5-0.8)	

Abbreviations: HPV-: non-HPV-driven; HPV+: HPV-driven.

HPV sero-pattern, E6 >1000 MFI or seropositive for three of four early proteins. OPSCC, oropharynx tumors including tonsils and base of tongue; HNSCC, head and neck squamous cell carcinoma outside the oropharynx including oral cavity, hypopharynx, larynx. +, seropositive; -, seronegative.

¹1/3 with extension to the Waldeyer's ring (extended pathology report).

²3/3 with extension to the Waldeyer's ring (extended pathology report).

diagnostic accuracy (82-94%) were strongly decreased (Supporting Information Table S2).

HPV16 serology in comparison to molecular and cellular HPV markers

To compare the predictive values of HPV16 serology (E6 seropositivity and HPV sero-pattern positivity) with p16 immunostaining or the combination of p16 immunostaining

and HPV DNA in OPSCC cases and HNSCC cases outside the oropharynx, assay performance characteristics were calculated based on a subset of the cohort ($n = 122$) where p16 immunostaining was available. To diagnose HPV-driven OPSCC cases, sensitivity of E6 seropositivity was 95%, while it was 97% for high p16, p16/HPV DNA positivity and HPV sero-pattern positivity, respectively. Specificity was only 65% for high p16 and 83% for p16/HPV DNA positivity, but

Table 3. Sensitivity, specificity, diagnostic accuracy and kappa value for HPV16 serology in comparison to p16^{INK4a} expression, by HPV RNA status and HNSCC region.

	HPV marker		HPV-	HPV+	Sensitivity %	Specificity %	Diagnostic accuracy %	Cohen's kappa
			<i>n</i>	<i>n</i>	(95%CI)	(95%CI)	(95%CI)	(95%CI)
OPSCC	p16 ^{INK4a}	low	26	2				
		high	14	60	97 (89–99)	65 (50–78)	84 (76–90)	0.65 (0.5–0.8)
	p16 ^{INK4a} /DNA	other ¹	33	2				
		high/DNA+	7	60	97 (89–99)	83 (68–91)	91 (84–95)	0.80 (0.6–1.0)
	E6	–	40	3				
		+	0	59	95 (87–98)	100 (91–100)	97 (92–99)	0.94 (0.8–1.0)
	sero-pattern	–	40	2				
		+	0	60	97 (89–99)	100 (91–100)	98 (93–100)	0.96 (0.8–1.0)
HNSCC outside the oropharynx								
p16 ^{INK4a}	low	15	0					
	high	2	3	100 (44–100)	88 (62–97)	90 (70–97)	0.69 (0.3–1.0)	
p16 ^{INK4a} /DNA	other ¹	16	0					
	high/DNA+	1	3	100 (44–100)	94 (73–99)	95 (76–99)	0.83 (0.4–1.0)	
E6	–	17	0					
	+	0	3	100 (44–100)	100 (82–100)	100 (84–100)	1.0 (0.6–1.0)	
sero-pattern	–	17	0					
	+	0	3	100 (44–100)	100 (82–100)	100 (84–100)	1.0 (0.6–1.0)	

Abbreviation: HPV–: non-HPV-driven; HPV+: HPV-driven.

HPV sero-pattern, E6 >1000 MFI or seropositive for three of four early proteins. P16 high, p16 staining in >25% of tumor cells; p16 low, p16 staining in <25%. P16^{INK4a}/DNA, p16 staining combined with HPV DNA positivity. +, seropositive; –, seronegative.

¹Other includes p16 high and HPV DNA-negative, p16 low and HPV DNA-positive, p16 low and HPV DNA-negative; high/DNA+ includes cases with high p16 (>25%) and with HPV16 DNA-positivity.

100% for HPV16 E6 and HPV sero-pattern positivity, respectively (Table 3). Sensitivity for HPV-driven HNSCC cases outside the oropharynx was high for any marker (each 100%), but specificity ranged from 88% for high p16 to 100% for E6 and sero-pattern positivity, respectively (Table 3).

Discussion

In this study, we determined the predictive accuracy of HPV16 antibodies to the oncoproteins E6 and E7, the regulatory proteins E1 and E2 and the major capsid protein L1 in serum of HNSCC patients as diagnostic markers for HPV16-driven OPSCC and HNSCC outside the oropharynx. To our knowledge, this is the first study that has comprehensively analyzed the potential of antibodies to HPV16 E proteins as a diagnostic marker for HNSCC with molecularly defined HPV status including RNA analyses as gold-standard. To diagnose HPV-driven OPSCC by HPV seropositivity, HPV16 E6 and the HPV sero-pattern had both very high sensitivity (both ≥96%) and specificity (both 98%) as well as high diagnostic accuracy (both ≥97%) and kappa values (both ≥0.93). In contrast, the sensitivity to diagnose HNSCC outside the oropharynx was much lower (both 50%), despite high specificity (both 100%). In comparison to the cellular surrogate

marker p16^{INK4a} or its combination with HPV DNA positivity, E6 seropositivity and HPV sero-pattern had higher specificity (100% vs. ≤83%).

HPV16 antibody patterns in HPV-driven and non-HPV-driven HNSCC differed strongly. Almost all HPV-driven HNSCC patients had high HPV antibody levels to many E proteins, while in non-HPV-driven HNSCC patients positive antibody reactions were rare, at low level and only to single E proteins (Figs. 1 and 2). In OPSCC patients, E6 antibodies were most prevalent, followed by E2, E7 and E1 (Table 2). The antibody patterns observed in high frequency among the HPV-driven OPSCC patients in this study have also been seen in our previous studies in OPSCC patients with undefined HPV status, albeit with lower prevalence.^{20,21,24,41} Strongest associations were previously reported for HPV16 E6 seropositivity with OPSCC relative to non-tumor controls, or HNSCC cases outside the oropharynx. Associations for E7, E1 and E2 were still high, but lower than for E6, and associations for L1 were much weaker.^{20,21,24,41} Although seropositivity to many of the E proteins is very common among the HPV-driven HNSCC patients, their antibody patterns are not homogeneous (Fig. 2). At present, it remains unclear why some seropositive patients react to less than all

of the four E proteins. It remains to be determined by detailed HPV transcriptome and HPV sequence analysis whether in individual tumors mutational changes might modify major epitopes and whether specific E proteins are expressed.

HPV-driven tumors originate mainly in the oropharynx, while HPV-driven HNSCCs outside the oropharynx are much less frequent.^{4,5,45} Of the six HPV-driven HNSCCs outside the oropharynx (Table 1), three (one oral cavity and two larynx carcinomas, two of them small tumors) were E6 seronegative and HPV sero-pattern negative, indicating that seroconversion in HPV-driven HNSCC outside the oropharynx may occur less frequently than in HPV-driven OPSCC and may reduce the sensitivity of HPV serology as marker for HPV-driven HNSCC cases outside the oropharynx. Intriguingly, the three E6 seropositive HPV-driven HNSCC outside the oropharynx (one hypopharynx and two larynx carcinomas) were all large tumors extending to parts of Waldeyer's ring in the oropharynx (Table 2) suggesting that seroconversion might be associated with close proximity to the lymphoepithelial structures in the oropharynx. Of the 142 non-HPV-driven HNSCC patients, 141 were E6 seronegative and only one was E6 seropositive leading to an excellent specificity (98% for OPSCC and 100% for HNSCC outside the oropharynx) of HPV serology as diagnostic marker for HPV-driven HNSCC. The single discordant patient showed high antibody levels to E6 (2571 MFI) and E1 (4527 MFI) but not to E7 and E2. The low HPV seroprevalence in non-HPV-driven HNSCC patients in this study is in line with large studies using the same methodology in control populations, which found an HPV16 E6 antibody prevalence of 0.7%.²⁷ HPV16 seropositivity in the absence of HPV-driven HNSCC could be due to the presence of an undetected HPV-driven tumor at other anatomical sites, as HPV16 E seropositivity has also been described for cervical, anal, vulvar and penile cancers.^{26,46–50}

Among the limitations of our study is the small number of HPV-driven HNSCC cases outside the oropharynx that—due to their low prevalence—hindered to accurately estimate the sensitivity of HPV16 serology for these tumors and therefore results remained inconclusive. Moreover, the HPV sero-pattern algorithm suggested here for the first time needs validation in larger cohorts to investigate whether it adds

significant benefits to HPV-driven OPSCC diagnosis, as the inclusion of the non-E6 proteins is based on a single case. It is known that OPSCC driven by other HPV-types (non-HPV16) can induce antibody responses⁵¹ to E proteins of these types. However, due to the very small fraction of non-HPV16-driven HNSCC, we did not attempt to determine whether non-HPV16-driven OPSCC have seropositivity frequencies as high as HPV16-driven OPSCC and whether HPV serology for these other types could also represent a reliable marker.

In conclusion, we demonstrated here that HPV serology can identify individuals with HPV-driven OPSCC with very high sensitivity and specificity and thus represents a powerful diagnostic marker. However, this study does not allow speculating about the use of HPV16 E6 antibodies for secondary prevention of HPV-driven OPSCC, although we have shown that these antibodies can be detected >10 years prior to OPSCC diagnosis.²⁰ In this study, we focused on determining the sensitivity and specificity of HPV serology as a diagnostic marker for HPV-driven OPSCC, and we found that HPV serology is highly accurate. Moreover, determining the HPV status on an OPSCC patient by serology might be an attractive option in clinical settings, for example, where OPSCC patients are stratified by HPV status into different therapeutic regimes. Currently, de-intensification of radiotherapy is discussed for HPV-driven OPSCC patients and corresponding clinical trials are ongoing. Nevertheless, further research is needed to determine whether HPV serology as a diagnostic marker has utility for early detection of HPV-driven OPSCC.

ACKNOWLEDGEMENT

We thank Monika Oppenländer, Ute Koch, Tanya Pfeiffer, Antje Schuhmann, Ines Kaden, Nataly Henfling, Anett Reiche and Ulrike Scharrer for excellent technical assistance.

Conflict of Interest

The authors D. Holzinger, G. Wichmann, L. Baboci, A. Michel, D. Höfler, M. Wiesenfarth, Lea Schroeder, P. Boscolo-Rizzo, C. Herold-Mende, G. Dyckhoff, A. Boehm, A. Kreimer, A. Del Mistro, FX Bosch, A. Dietz and T. Waterboer disclosed no potential conflicts of interest. M. Pawlita received research funding through cooperation contracts of DKFZ with Qiagen and Roche.

References

- Andl T, Kahn T, Pfuhl A, et al. Etiological involvement of oncogenic human papillomavirus in tonsillar squamous cell carcinomas lacking retinoblastoma cell cycle control. *Cancer Res* 1998; 58:5–13.
- Gillison ML, Koch WM, Capone RB, et al. Evidence for a causal association between human papillomavirus and a subset of head and neck cancers. *J Natl Cancer Inst* 2000;92:709–20.
- Snijders PJ, Cromme FV, van den Brule AJ, et al. Prevalence and expression of human papillomavirus in tonsillar carcinomas, indicating a possible viral etiology. *Int J Cancer* 1992;51: 845–50.
- Castellsague X, Alemany L, Quer M, et al. HPV involvement in head and neck cancers: comprehensive assessment of biomarkers in 3680 patients. *J Natl Cancer Inst* 2016;108:djv403.
- Halec G, Holzinger D, Schmitt M, et al. Biological evidence for a causal role of HPV16 in a small fraction of laryngeal squamous cell carcinoma. *Br J Cancer* 2013;109:172–83.
- Jung AC, Briolat J, Millon R, et al. Biological and clinical relevance of transcriptionally active human papillomavirus (HPV) infection in oropharynx squamous cell carcinoma. *Int J Cancer* 2010;126:1882–94.
- Klussmann JP, Weissenborn SJ, Wieland U, et al. Prevalence, distribution, and viral load of human papillomavirus 16 DNA in tonsillar carcinomas. *Cancer* 2001;92:2875–84.
- Smeets SJ, Hesselink AT, Speel EJ, et al. A novel algorithm for reliable detection of human

- papillomavirus in paraffin embedded head and neck cancer specimen. *Int J Cancer* 2007;121:2465–72.
9. Ang KK, Harris J, Wheeler R, et al. Human papillomavirus and survival of patients with oropharyngeal cancer. *N Engl J Med* 2010;363:24–35.
 10. Braakhuis BJ, Snijders PJ, Keune WJ, et al. Genetic patterns in head and neck cancers that contain or lack transcriptionally active human papillomavirus. *J Natl Cancer Inst* 2004;96:998–1006.
 11. Holzinger D, Schmitt M, Dyckhoff G, et al. Viral RNA patterns and high viral load reliably define oropharynx carcinomas with active HPV16 involvement. *Cancer Res* 2012;72:4993–5003.
 12. van Houten VM, Snijders PJ, van den Brekel MW, et al. Biological evidence that human papillomaviruses are etiologically involved in a subgroup of head and neck squamous cell carcinomas. *Int J Cancer* 2001;93:232–5. Cross-Ref[10.1002/ijc.1313]
 13. Wiest T, Schwarz E, Enders C, et al. Involvement of intact HPV16 E6/E7 gene expression in head and neck cancers with unaltered p53 status and perturbed pRb cell cycle control. *Oncogene* 2002;21:1510–7.
 14. Weinberger PM, Yu Z, Haffty BG, et al. Molecular classification identifies a subset of human papillomavirus-associated oropharyngeal cancers with favorable prognosis. *J Clin Oncol* 2006;24:736–47.
 15. Prigge ES, Arbyn M, von Knebel Doeberitz M, et al. Diagnostic accuracy of p16INK4a immunohistochemistry in oropharyngeal squamous cell carcinomas: a systematic review and meta-analysis. *Int J Cancer* 2017;140:1186–1198.
 16. Dahlstrom KR, Adler-Storhiz K, Etzel CJ, et al. Human papillomavirus type 16 infection and squamous cell carcinoma of the head and neck in never-smokers: a matched pair analysis. *Clin Cancer Res* 2003;9:2620–6.
 17. D'Souza G, Kreimer AR, Viscidi R, et al. Case-control study of human papillomavirus and oropharyngeal cancer. *N Engl J Med* 2007;356:1944–56.
 18. Herrero R, Castellsague X, Pawlita M, et al. Human papillomavirus and oral cancer: the International Agency for Research on Cancer multicenter study. *J Natl Cancer Inst* 2003;95:1772–83.
 19. Zumbach K, Hoffmann M, Kahn T, et al. Antibodies against oncoproteins E6 and E7 of human papillomavirus types 16 and 18 in patients with head-and-neck squamous-cell carcinoma. *Int J Cancer* 2000;85:815–8.
 20. Kreimer AR, Johansson M, Waterboer T, et al. Evaluation of human papillomavirus antibodies and risk of subsequent head and neck cancer. *J Clin Oncol* 2013;31:2708–15.
 21. Anantharaman D, Gheit T, Waterboer T, et al. Human papillomavirus infections and upper aero-digestive tract cancers: the ARCAGE study. *J Natl Cancer Inst* 2013;105:536–45.
 22. Anderson KS, Dahlstrom KR, Cheng JN, et al. HPV16 antibodies as risk factors for oropharyngeal cancer and their association with tumor HPV and smoking status. *Oral Oncol* 2015;51:662–7.
 23. Anderson KS, Wong J, D'Souza G, et al. Serum antibodies to the HPV16 proteome as biomarkers for head and neck cancer. *Br J Cancer* 2011;104:1896–905.
 24. Lang Kuhs KA, Pawlita M, Gibson SP, et al. Characterization of human papillomavirus antibodies in individuals with head and neck cancer. *Cancer Epidemiol* 2016;42:46–52.
 25. Kelsey KT, Nelson HH, Kim S, et al. Human papillomavirus serology and tobacco smoking in a community control group. *BMC Infect Dis* 2015;15:8.
 26. Kreimer AR, Brennan P, Lang Kuhs KA, et al. Human papillomavirus antibodies and future risk of anogenital cancer: a nested case-control study in the European prospective investigation into cancer and nutrition study. *J Clin Oncol* 2015;33:877–84.
 27. Lang Kuhs KA, Anantharaman D, Waterboer T, et al. Human papillomavirus 16 E6 antibodies in individuals without diagnosed cancer: a pooled analysis. *Cancer Epidemiol Biomarkers Prev* 2015;24:683–9.
 28. Tachezy R, Klozar J, Rubenstein L, et al. Demographic and risk factors in patients with head and neck tumors. *J Med Virol* 2009;81:878–87.
 29. Koslabova E, Hamsikova E, Salakova M, et al. Markers of HPV infection and survival in patients with head and neck tumors. *Int J Cancer* 2013;133:1832–9.
 30. Rotnaglova E, Tachezy R, Salakova M, et al. HPV involvement in tonsillar cancer: prognostic significance and clinically relevant markers. *Int J Cancer* 2011;129:101–10.
 31. Smith EM, Ritchie JM, Pawlita M, et al. Human papillomavirus seropositivity and risks of head and neck cancer. *Int J Cancer* 2007;120:825–32.
 32. Smith EM, Pawlita M, Rubenstein LM, et al. Risk factors and survival by HPV-16 E6 and E7 antibody status in human papillomavirus positive head and neck cancer. *Int J Cancer* 2010;127:111–7.
 33. Smith EM, Rubenstein LM, Haugen TH, et al. Complex etiology underlies risk and survival in head and neck cancer human papillomavirus, tobacco, and alcohol: a case for multifactor disease. *J Oncol* 2012;2012:571862.
 34. Wichmann G, Rosolowski M, Krohn K, et al. The role of HPV RNA transcription, immune response-related gene expression and disruptive TP53 mutations in diagnostic and prognostic profiling of head and neck cancer. *Int J Cancer* 2015;137:2846–57.
 35. Baboci L, Holzinger D, Boscolo-Rizzo P, et al. Low prevalence of HPV-driven head and neck squamous cell carcinoma in North-East Italy. *Papillomavirus Res* 2016;2:133–40. Cross-Ref[10.1016/j.pvr.2016.07.002]
 36. Schmitt M, Bravo IG, Snijders PJ, et al. Bead-based multiplex genotyping of human papillomaviruses. *J Clin Microbiol* 2006;44:504–12.
 37. Schmitt M, Dondog B, Waterboer T, et al. Homogeneous amplification of genital human alpha papillomaviruses by PCR using novel broad-spectrum GP5+ and GP6+ primers. *J Clin Microbiol* 2008;46:1050–9.
 38. Hofler D, Bohmer G, von Wasielewski R, et al. HPV16 RNA patterns defined by novel high-throughput RT-qPCR as triage marker in HPV-based cervical cancer precursor screening. *Gynecol Oncol* 2015;138:676–82.
 39. Schmitt M, Dalstein V, Waterboer T, et al. Diagnosing cervical cancer and high-grade precursors by HPV16 transcription patterns. *Cancer Res* 2010;70:249–56.
 40. Waterboer T, Sehr P, Michael KM, et al. Multiplex human papillomavirus serology based on in situ-purified glutathione s-transferase fusion proteins. *Clin Chem* 2005;51:1845–53.
 41. Ribeiro KB, Levi JE, Pawlita M, et al. Low human papillomavirus prevalence in head and neck cancer: results from two large case-control studies in high-incidence regions. *Int J Epidemiol* 2011;40:489–502.
 42. Sitas F, Egger S, Urban MI, et al. InterSCOPE study: Associations between esophageal squamous cell carcinoma and human papillomavirus serological markers. *J Natl Cancer Inst* 2012;104:147–58.
 43. Castro F, Dirks WG, Fahrnich S, et al. High-throughput SNP-based authentication of human cell lines. *Int J Cancer* 2013;132:308–14.
 44. Holzinger D, Flechtenmacher C, Henfling N, et al. Identification of oropharyngeal squamous cell carcinomas with active HPV16 involvement by immunohistochemical analysis of the retinoblastoma protein pathway. *Int J Cancer* 2013;133:1389–99.
 45. Ndiaye C, Mena M, Alemany L, et al. HPV DNA, E6/E7 mRNA, and p16INK4a detection in head and neck cancers: a systematic review and meta-analysis. *Lancet Oncol* 2014;15:1319–31.
 46. Bertisch B, Franceschi S, Lise M, et al. Risk factors for anal cancer in persons infected with HIV: a nested case-control study in the Swiss HIV Cohort Study. *Am J Epidemiol* 2013;178:877–84.
 47. Dillner J. The serological response to papillomaviruses. *Semin Cancer Biol* 1999;9:423–30.
 48. Heideman DA, Waterboer T, Pawlita M, et al. Human papillomavirus-16 is the predominant type etiologically involved in penile squamous cell carcinoma. *J Clin Oncol* 2007;25:4550–6.
 49. Meschede W, Zumbach K, Braspenning J, et al. Antibodies against early proteins of human papillomaviruses as diagnostic markers for invasive cervical cancer. *J Clin Microbiol* 1998;36:475–80.
 50. Zumbach K, Kisseljev F, Sacharova O, et al. Antibodies against oncoproteins E6 and E7 of human papillomavirus types 16 and 18 in cervical-carcinoma patients from Russia. *Int J Cancer* 2000;85:313–8.
 51. Baboci L, Boscolo-Rizzo P, Holzinger D, et al. Evidence of the causal role of human papillomavirus type 58 in an oropharyngeal carcinoma. *Virol J* 2013;10:334. CrossRef[10.1186/1743-422X-10-334]