



UNIVERSITÀ  
DEGLI STUDI  
DI PADOVA

Sede Amministrativa: Università degli Studi di Padova

Dipartimento di Scienze Cardiologiche, Toraciche e Vascolari

---

SCUOLA DI DOTTORATO DI RICERCA IN SCIENZE MEDICHE, CLINICHE E  
SPERIMENTALI

INDIRIZZO: SCIENZE CARDIOVASCOLARI

CICLO: 25°

**TITOLO TESI**

*Arrhythmogenic Right Ventricular Cardiomyopathy:  
Prognostic Value of Electroanatomic Voltage Mapping*

**Direttore della Scuola:** Ch.mo Prof. Gaetano Thiene

**Coordinatore d'indirizzo:** Ch.mo Prof. Gaetano Thiene

**Supervisore:** Ch.mo Prof. Domenico Corrado

**Dottorando:** Dott. Federico Migliore

## **Contents**

<b>Abstract.....</b>	<b>3</b>
<b>General Aspects of Arrhythmogenic Right Ventricular Cardiomyopathy (ARVC)</b>	
<b>History.....</b>	<b>7</b>
<b>Pathogenesis and Pathophysiology.....</b>	<b>15</b>
<i>Pathology</i>	
<i>Genetic Background: A Disease of the Desmosome</i>	
<i>Etiopathogenetic Theories</i>	
<b>Clinical Presentation and Diagnosis.....</b>	<b>26</b>
<i>Clinical Presentation</i>	
<i>Twelve-lead Electrocardiogram</i>	
<i>Cardiovascular Imaging</i>	
<i>Diagnostic Criteria</i>	
<b>Risk Stratification and Prevention of Sudden Cardiac Death.....</b>	<b>38</b>
<i>Natural History</i>	
<i>Risk Stratification</i>	
<i>Implantable Cardioverter Defibrillator</i>	
<i>Catheter Ablation of Ventricular Tachycardia</i>	
<i>Pharmacological Therapy</i>	
<i>Preparticipation Athletic Screening</i>	
<b>Introduction: Electroanatomic Voltage Mapping.....</b>	<b>80</b>
<i>Methods and Equipment</i>	
<i>Clinical Results in ARVC</i>	
<i>Pathophysiologic and Clinical Implications</i>	
<i>Differential Diagnosis between ARVC and Idiopathic Ventricular Tachycardia</i>	
<i>Electroanatomic Voltage Mapping-guided Catheter Ablation</i>	
<i>Electroanatomic Voltage Mapping Versus Contrast-Enhanced Cardiac</i>	
<i>Magnetic Resonance</i>	

**Study: Arrhythmogenic Right Ventricular Cardiomyopathy:  
Prognostic Value of Electroanatomic Voltage Mapping**

*Aim of the Study*.....100

*Methods*.....101

*Results*.....106

*Discussion*.....110

*Conclusions*.....116

*References*.....125

**Publications by Dr. Federico Migliore** .....144

## ABSTRACT

**Background:** Endocardial voltage mapping (EVM) identifies low-voltage right ventricular (RV) areas, which may represent the electroanatomic scar substrate of life-threatening tachyarrhythmias. We prospectively assessed the prognostic value of EVM in a consecutive series of patients with arrhythmogenic right ventricular cardiomyopathy/dysplasia (ARVC).

**Methods:** We studied 69 consecutive ARVC patients [47 males; median age 35 years(28-45)] who underwent electrophysiological study and both bipolar and unipolar EVM. The extent of confluent bipolar (<1.5mV) and unipolar (<6.0mV) low-voltage electrograms was estimated using the CARTO-incorporated area calculation software.

**Results:** Fifty-three patients (77%) showed  $\geq 1$  RV electroanatomic scars with an estimated burden of bipolar vs unipolar low-voltage areas of 24.8% (7.2-31.5) and 64.8% (39.8-95.3), respectively (P=0.009). In the remaining patients with normal bipolar-EVM (n=16;23%), the use of unipolar EVM unmasked  $\geq 1$  region of low-voltage electrogram affecting 26.2% (11.6-38.2) of RV wall. During a median follow-up of 41 (28-56) months, 19(27.5%) patients experienced arrhythmic events, such as sudden death (n=1), appropriate ICD interventions (n=7), or sustained ventricular tachycardia (n=11). Univariate predictors of arrhythmic outcome included previous cardiac arrest or syncope (HR=3.4; 95%CI:1.4-8.8; P=0.03) and extent of bipolar low-voltage areas (HR=1.7 per 5%; 95%CI=1.5-2; P<0.001), while the only independent predictor was the bipolar low-voltage electrogram burden (HR=1.6 per 5%; 95% CI:1.2-1.9; P<0.001). Patients with normal bipolar-EVM had an uneventful clinical course.

**Conclusions:** The extent of bipolar RV endocardial low-voltage area was a powerful predictor of arrhythmic outcome in ARVC, independently of history and RV dilatation/dysfunction. A normal bipolar-EVM characterized a low-risk subgroup of ARVC patients.

## RIASSUNTO

**Introduzione:** Il mappaggio elettroanatomico mediante sistema CARTO permette di identificare e quantificare aree di basso voltaggio del ventricolo destro che corrispondono a cicatrici elettroanatomiche, substrato di aritmie ventricolari pericolose per la vita.

Lo scopo dello studio era di valutare, in modo prospettico, il valore prognostico del mappaggio elettroanatomico in una coorte di pazienti affetti da Cardiomiopatia Aritmogena del Ventricolo Destro.

**Materiali e Metodi:** La popolazione di studio includeva 69 pazienti (47maschi; età mediana 35 anni; 28-35) affetti da Cardiomiopatia Aritmogena del Ventricolo Destro. Tutti i pazienti sono stati sottoposti ad un completo *work up* clinico che includeva: elettrocardiogramma, ecocardiografia, cateterismo cardiaco, studio elettrofisiologico e mappaggio elettroanatomico del ventricolo destro, utilizzando sia mappe bipolari sia unipolari. L'estensione degli elettrogrammi confluenti di basso voltaggio bipolari (<1.5 mV) e unipolari (<6.0 mV) è stata stimata usando un software incorporato nel sistema CARTO.

**Risultati:** In cinquantatre pazienti (77%) è stata riscontrata  $\geq 1$  regione cicatriziale a carico del ventricolo destro con una percentuale stimata di aree di basso voltaggio bipolari e unipolari rispettivamente di 24.8% (7.2-31.5) e 64.8 (39.8-95.3), rispettivamente (P=0.009). In tutti pazienti con una normale mappa bipolare (n= 16; 23%) l'utilizzo del mappaggio unipolare ha identificato  $\geq 1$  regione con elettrogrammi di basso voltaggio che interessava il 26.2% (11.6-38.2) del ventricolo destro. Durante un follow-up di 41 (28-56) mesi 19 (27.5%) pazienti subirono eventi aritmici maggiori, quali morte improvvisa (n=1), intervento appropriato dell'ICD (n=7), o tachicardia ventricolare sostenuta (n=11). All'analisi univariata i predittori dell'outcome aritmico includevano:

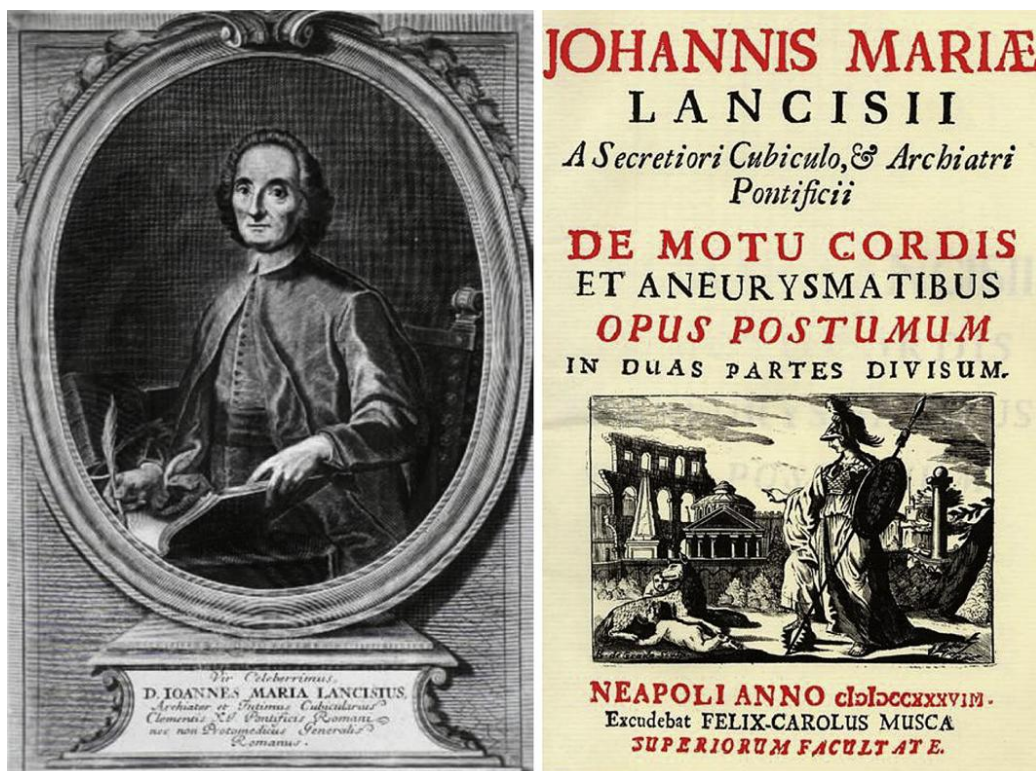sincope (HR=3.4; 95%CI: 1.4-8.8; P=0.03), e l'estensione delle aree di basso voltaggio bipolare (HR=1.7 per 5%; 95%CI: 1.5-2; P<0.001). All'analisi multivariata, l'unico predittore indipendente risultava l'estensione delle aree di basso voltaggio al mappaggio bipolare (HR=1.6 per 5%;95% CI:1.2-1.9; P<0.001). Tutti i pazienti con un mappaggio bipolare normale presentavano un decorso clinico privo di eventi aritmici.

**Conclusioni:** l'estensione delle aree endocardiche di basso voltaggio nel ventricolo destro risulta essere un potente predittore di eventi aritmici maligni nella Cardiomiopatia Aritmogena del Ventricolo Destro indipendentemente dalla storia clinica e dalla dilatazione/disfunzione del ventricolo destro. La presenza di un normale mappaggio elettroanatomico bipolare rappresenta un sottogruppo di pazienti affetti da Cardiomiopatia Aritmogena del Ventricolo Destro a basso rischio aritmico.

## General Aspects of Arrhythmogenic Right Ventricular Cardiomyopathy (ARVC)

### History

In 1736 Giovanni Maria Lancisi published in Naples the book *De Motu Cordis et Aneurysmatibus* (1). In Chapter V of the book entitled *De Hereditaria ad Cordis Aneurysmata Constitutione: De Cordis Prolapsu* (On the Hereditary Predisposition to Cardiac Aneurysms: Cardiac Prolapse), he reported some examples of such morbid entities and described the history of a family with disease recurrence in four generations, all featuring signs and symptoms that were in keeping with what nowadays we call Arrhythmogenic Right Ventricular Cardiomyopathy (ARVC) including: palpitations, dilatation and aneurysms of the right ventricle (RV), heart failure, and sudden death (Figure 1).



**Figure 1.** The book by Giovanni Maria Lancisi published in Naples in 1736. (From Thiene G. Arrhythmogenic Cardiomyopathy. Cardiac Electrophysiology clinics 2011 p. 180)



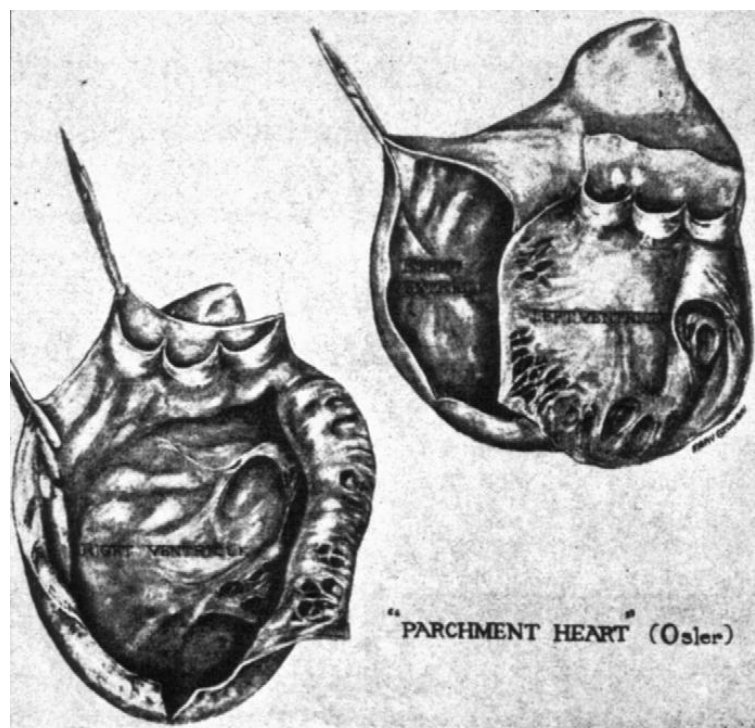
The first recent pathologic description was made by Laennec, as reported in his bibliography by Saintignon in 1904. (2) In *Middlemarch*, published in 1871 by George Eliot, the protagonist Dr Lydgate, talking to his patient, says “*you are suffering from what is called fatty degeneration of the heart, a disease which was first described by Laennec... it is my duty to tell you that death from the disease is often sudden..*” (3). In 1905 Sir William Osler reported a case of a nearly 40-year-old man who died suddenly while climbing a hill. (4) Postmortem disclosed a biventricular myocardial atrophy, with a thinning and translucency of the ventricular free walls, which Osler immortalized with the name “parchment heart.”

In 1950 Segall reviewed the specimen and republished the case with unequivocal drawings showing paper-thin walls (Figure 2) (5).

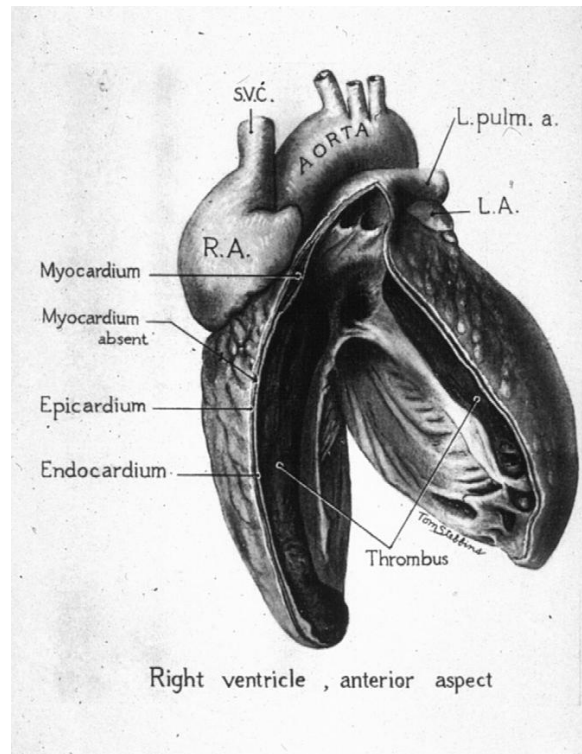
In 1952 Uhl at the Johns Hopkins Hospital in Baltimore published a case of congenital malformation of the heart characterized by total absence of myocardium of the RV in an 8-month-old female infant who died of congestive heart failure and with no arrhythmias at electrocardiography (ECG) (6). The description of the heart at autopsy reads (Figure 3): “*Externally the heart appears greatly enlarged. almost the entire dilated chamber (RV) was occupied by a large laminated mural thrombosis which adhered firmly to the endocardium along the anterior wall of the ventricle. Examination of the cut edge of the ventricle wall revealed it to be paper-thin with no myocardium visible...In the RV wall epicardium and endocardium lie adjacent to each other with no intervening cardiac muscle...no fibro-fatty tissue in the RV free wall was observed*”.

In 1961 and 1965 Sergio Dalla Volta first published cases under the name of “auricularization of the RV pressure” to emphasize the behavior of the RV chamber without an effective systolic contraction, with the blood being pushed to the pulmonary artery mainly due to the right atrial systole. (7,8) Although the patients presented also with ventricular arrhythmias, Dalla Volta pointed more to the hemodynamic features rather than to the arrhythmogenicity of the RV. One of the original patients reported by Dalla Volta underwent cardiac transplantation 30 years later in 1995 at the age of 65 because of congestive RV failure. The left ventricle (LV) was normal,

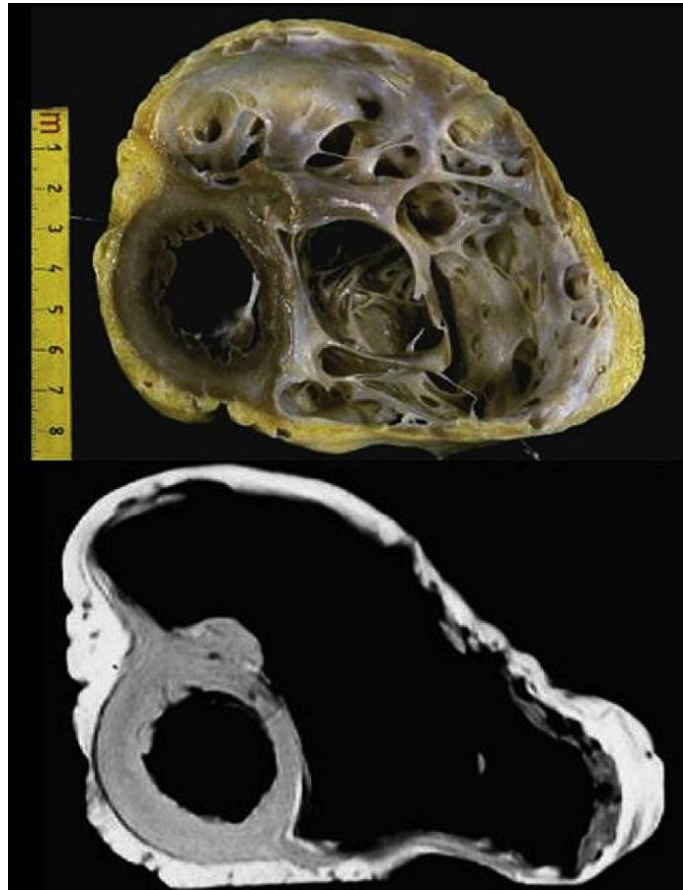whereas the RV was hugely dilated with diffuse paper-thin free wall and complete disappearance of the myocardium (Figure 4). (9) At the same University of Padua in 1972, the pathologist Vito Terribile performed the autopsy of a woman with a history of palpitations and congestive heart failure, who died of pulmonary embolism. The heart showed an extreme dilatation, mural thrombosis, and “adipositas cordis” of the RV, and the LV myocardium exhibited areas of “myocardiosclerosis,” all structural findings in keeping with ARVC.(10) Interest on the arrhythmic aspects of the disease was attracted by Guy Fontaine from Paris in the 1970s with the report of nonischemic ventricular tachyarrhythmias with left bundle branch block (LBBB) morphology originating from the RV.(11) In 1982, Frank Marcus from the University of Arizona, named the manifestation of primary RV disease as “RV dysplasia” because the histology of the myocardial specimens, resected at surgery for removal of arrhythmic foci, showed anomalous histologic features of the RV myocardium consisting of fibro-fatty tissue, which were believed to be the consequence of an embryonic maldevelopment (12).



**Figure 2.** The drawings of the “parchment heart” of Osler, with paper-thin walls of both ventricles. (From Thiene G. Arrhythmogenic Cardiomyopathy. Cardiac Electrophysiology clinics 2011 p. 180)



**Figure 3.** The original picture of the Uhl's anomaly. (From Thiene G. Arrhythmogenic Cardiomyopathy. Cardiac Electrophysiology clinics 2011 p. 180)



**Figure 4.** The heart at cardiac transplantation of one of the patients published by Dalla Volta in 1964. Note the huge dilatation of the right ventricle, both at gross and in vitro magnetic resonance, with paper-thin RV free wall. (From Thiene G. Arrhythmogenic Cardiomyopathy. Cardiac Electrophysiology clinics 2011 p. 182)

By observing the presence of aneurysms in the inflow, apex, and outflow of RV, the investigators coined the term “*triangle of dysplasia*,” a pathognomonic landmark of the disease.

Andrea Nava in Padua, by analyzing the study of families with sudden death and autopsy evidence of ARVC from Piazzola sul Brenta (a small village close to Padua in the Veneto Region), discovered the hereditary nature of the disease, a monogenic disorder with a Mendelian autosomal dominant transmission.(13,14)

Gaetano Thiene proved the risk of sudden cardiac death (SCD) as first manifestation of the disease by the postmortem study of a series of young victims, in the setting of a project supported by the Veneto Region. (15,16) The first observation concerned a young doctor, formerly cycle

champion, who died suddenly on a tennis court during a hot afternoon of May 1979. Fifteen minutes after the starting of the game he stopped, took his pulse, walked back to the border of the tennis court, and suddenly fainted. In his diary, written on October 4, 1978, during preparation of the Internal Medicine examination, the phrase “ventricular tachycardia of left bundle branch block morphology” was found, which retrospectively can refer to his own ECG. His girlfriend related that on that day he had suffered palpitations and did an ECG. It took years to understand that the explanation of cardiac arrest and ventricular fibrillation (VF) was the fibro-fatty tissue that had been observed at autopsy in the RV free wall and at apex of the LV, and not conduction system abnormalities as first hypothesized.

In 1988 a group of Greek doctors, observed a cardiac malignant disease in Naxos in the setting of cardiocutaneous syndrome, consisting of ARVC, palmoplantar keratosis, and woolly hair, called “Naxos disease”. (17) The Greek group postulated that those patients might belong to families descended from Venetians, who had landed in Naxos in 1207.

Domenico Corrado demonstrated that ARVC was the leading cause of SCD among athletes, differing from the United States where hypertrophic cardiomyopathy ranked first. (18)

In 1994 an international task force headed by Bill McKenna put forward the diagnostic criteria, based on family history of ARVC and/or sudden death, ECG depolarization/conduction/repolarisation abnormalities, arrhythmias of RV origin, global and/or regional dysfunction and structural alterations of the RV, and fibro-fatty replacement of the RV myocardium at pathologic analysis.(19) In the absence of a single gold standard, the diagnosis was achieved by major or minor criteria (2 major, or 1 major and 3 minor, or 4 minor). A revision of the diagnostic criteria was recently accomplished by introducing quantitative other than qualitative diagnostic parameters, including cardiac magnetic resonance and genetic testing. (20)

Regarding the treatment, the prevention of SCD is now feasible with the introduction of implantable cardioverterdefibrillator (ICD) devices. Implantable defibrillator is the most logical therapeutic strategy for patients with ARVC, whose natural history is primarily characterized by the

risk of arrhythmic cardiac arrest. Several studies on either secondary or primary prevention have provided significant insights for therapy-based risk stratification of ARVC patients, leading to identification of clinical and electrophysiologic markers that may predict the appropriate shock against life-threatening ventricular arrhythmias. (21,22).

Other fascinating contributions came from pathobiology and genetics. Cristina Basso, on studying a large series of heart specimens, disclosed that ARVC/ is not a congenital heart disorder, rather, it is a genetically determined myocardial dystrophy with acquired cell death occurring with time, mostly during adolescence. (23)

Based on genetic observations, ARVC is a genetically determined cardiomyopathies, caused by mutations in desmosomal genes. (24-27) Genotype-phenotype correlations, performed by Barbara Bauce, disclosed that the desmoplakin variant of the disease featured extensive LV ventricular involvement so as to suggest that the disease, being biventricular, should be better called Arrhythmogenic cardiomyopathy (AC). (28) Predominant LV and biventricular involvement was confirmed by contrast-enhanced cardiac magnetic resonance in genotyped ARVC patients. (29)

Electron microscopy studies, performed by Cristina Basso in genotyped patients with ARVC, revealed abnormalities of the desmosomes. Desmosomes appeared less numerous, short, pale, and fragmented, suggesting that disruption of intercalated discs was the final common pathway of a genetically determined, progressive cell death.(30) The discovery of the defective genes, although limited to 50% of affected families, opened new avenues. Genetic screening, for early diagnosis and detection of healthy carriers as well as reassurance of noncarriers, entails a tremendous impact on primary prevention of arrhythmic complications and lifestyle, by including disqualification of sport activity and genetic counseling for disease recurrence in siblings and offspring, alongside the dilemma of procreation. (31)

European and American teams continue to be committed in the study of the disease. At the turn of the last millennium, following a series of meetings of experts from both sides of the Atlantic, it became evident that the expertise of scientists and clinicians should merge into an “army” for the

fight against the calamity of sudden death due to ARVC. An International Registry was considered mandatory to collect study material and concentrate efforts on this rare disorder. (32,33) Two teams were created, one in Europe coordinated by Gaetano Thiene and one in North America coordinated by Frank Marcus. The two projects started by using a similar database and sharing some Core Labs. The method was somewhat different: the European Registry enrolled patients who were previously diagnosed as well as new entries, (33) whereas the North American Registry enrolled only newly diagnosed patients. (34)

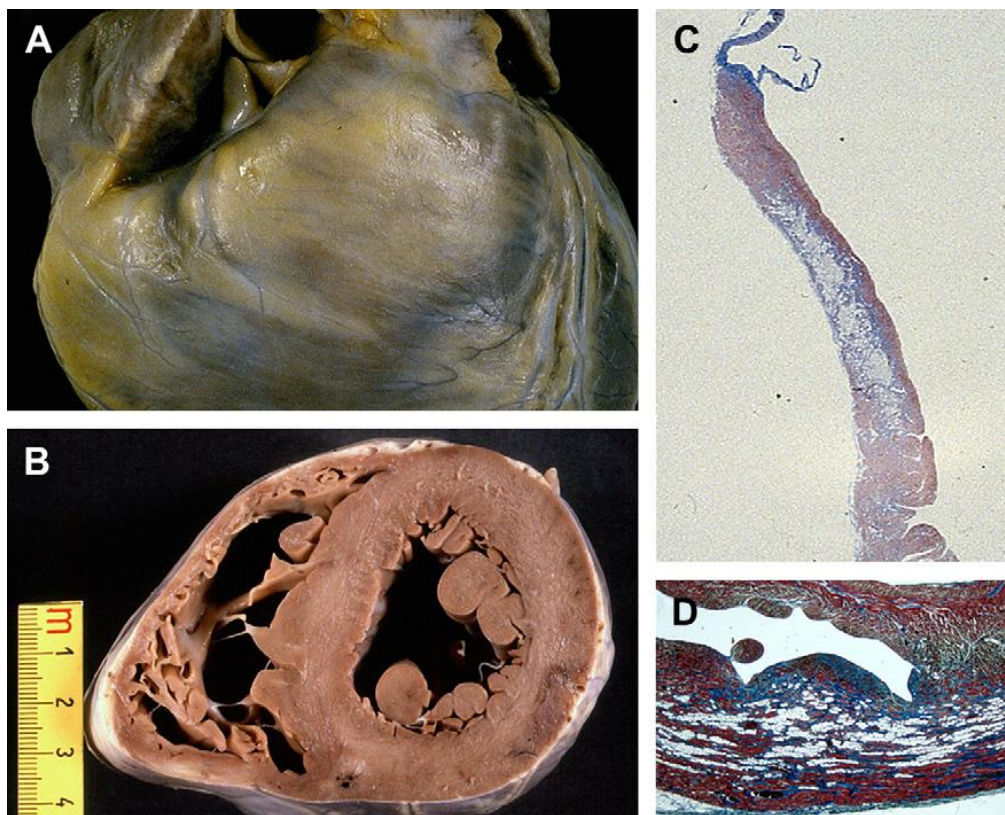
## ***Pathogenesis and Pathophysiology***

### ***Pathology***

The original systematic description of morphologic abnormalities of ARVC dates back to 1988, when Thiene and colleagues (15) investigated a series of juvenile sudden deaths that occurred in the northeast of Italy, thus recognizing that the disease is a major cause of cardiac arrest in the young. Since then, the pathologic diagnosis of ARVC has been traditionally based on gross and histologic evidence of transmural myocardial loss with fibrofatty replacement of the RV free wall, extending from the epicardium toward the endocardium. RV aneurysms, whether single or multiple, located in the so-called triangle of dysplasia (ie, inflow, apex, and outflow tract) are considered a pathognomonic feature of ARVC, although not necessarily present in all cases. (23) Hearts with end-stage disease and congestive heart failure consistently showed a higher prevalence of biventricular involvement, usually with multiple aneurysms and a parchmentlike appearance of the free wall. (23, 35) However, all the morphologic features mentioned earlier refer to the classic ARVC picture. Recently, it has been shown that the disease can have a phenotypic spectrum much wider than previously believed, with grossly normal hearts at one end, in whom only a careful histopathology investigation can reveal ARVC features in 1 or both ventricles, and hearts with massive RV, with or without LV involvement, at the opposite end (Figure 1). The wide variability in reported pathologic features mostly depends on the selection bias (ie, whether the cases come from referral centers for arrhythmias/sudden death or for heart failure/cardiac transplantation). Transmural fibrofatty myocardial replacement of the RV free wall has always been considered the *conditio sine qua non* for pathologic diagnosis of ARVC, which might explain why several cases with early segmental RV involvement (ie, not yet full thickness deepening from epicardium to endocardium) or those with predominant or isolated LV disease, usually without wall thinning and aneurysm formation, escape the diagnosis. (36) The existence of cases with biventricular



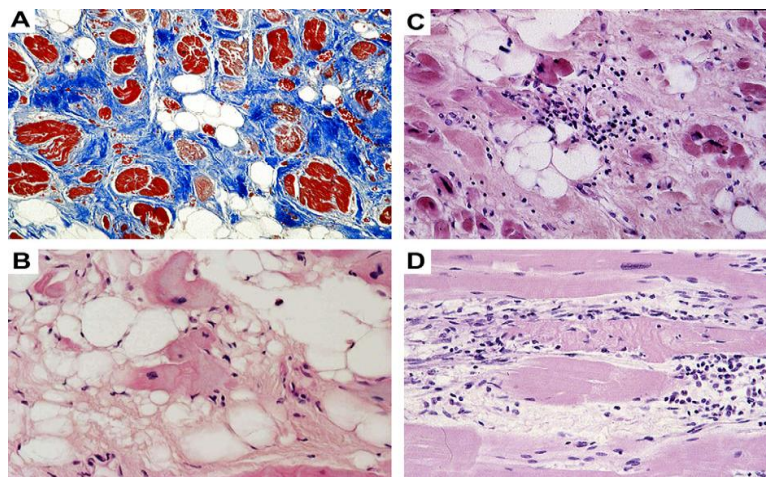
involvement or predominantly either LV or RV should suggest the use of the more comprehensive term Arrhythmogenic cardiomyopathy. Histologic examination reveals islands of surviving myocytes interspersed with fibrous and fatty tissue. (23,35,36) Clusters of myocytes may be seen dying at histology, providing evidence of the acquired nature of myocardial atrophy, and are frequently associated with inflammatory infiltrates, which probably plays a major role in triggering lifethreatening arrhythmias (Figure 2). (37)



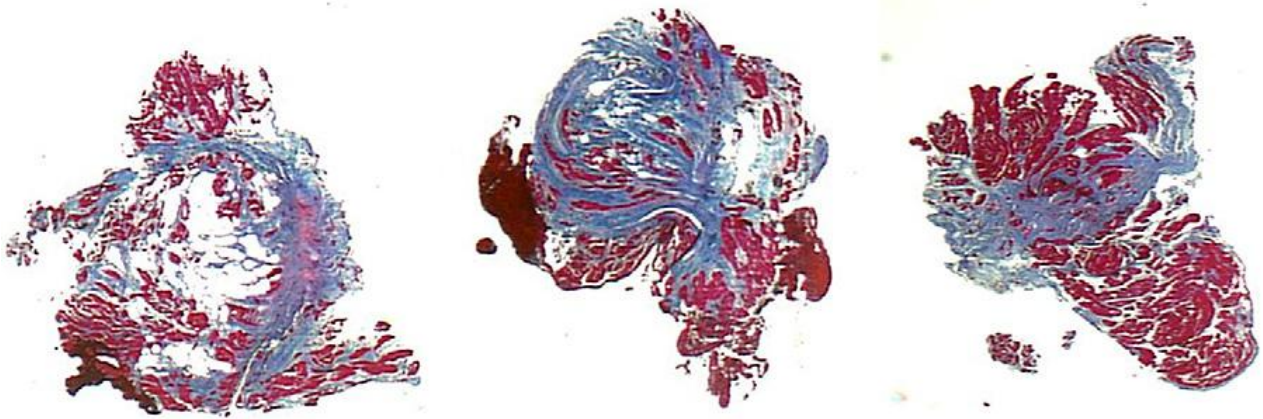
**Figure 1.** ARVC in a 26-year-old athlete who died suddenly. (A) Anterior view of the RV outflow tract, which appears mildly dilated. (B) Cross section of the heart showing the absence of RV free wall aneurysms: note the spotty involvement of the posterior right ventricular free wall. (C) Histology of the RV outflow tract; note the regional loss of myocardium with fibrofatty replacement. (D) Histology of the posterior RV free wall; note the fibrofatty replacement of the myocardium in the absence of wall thinning. (Modified from Basso C, Thiene G, Corrado D, et al. Arrhythmogenic right ventricular cardiomyopathy: dysplasia, dystrophy or myocarditis? *Circulation* 1996;94:983–91)

Rather than being a continuous process, disease progression may occur during periodic bursts of an otherwise stable disease that can be clinically silent in most patients but sometimes may be characterized by life-threatening arrhythmic exacerbation. Environmental factors, such as exercise or inflammation, may facilitate disease onset and progression. Fatty infiltration of the RV per se is

not a sufficient morphologic hallmark of ARVC. (38) A certain amount of intramyocardial fat is present in the RV anterolateral and apical region even in the normal heart, and increases with age and body size. Moreover, ARVC is distinct from adipositas cordis. (39) Presence of replacement-type fibrosis and myocyte degenerative changes are essential to provide a clear-cut diagnosis, besides remarkable fat replacement. Transvenous endomyocardial biopsy may be of help in the diagnostic work-up for an in vivo tissue characterization through histologic evidence of fibrofatty myocardial replacement. (19,40,41) Samples should be retrieved from the RV free wall, because the fibrofatty replacement is herein usually transmural and thus detectable from the endocardial approach, whereas the ventricular septum is usually spared. A residual amount of myocardium (<60%), caused by fibrous or fibrofatty replacement, has been proved to have a high diagnostic accuracy and is now considered a major criterion for ARVC diagnosis (Figure 3). (19,20,41) Moreover, endomyocardial biopsy is essential to rule out the so-called ARVC phenocopies, such as myocarditis, sarcoidosis, or idiopathic RV outflow tract tachycardia, particularly when dealing with probands with a sporadic ARVC form.



**Figure 2.** Histologic features of ARVC. (A) Residual myocytes entrapped within fibrous and fatty tissue. (B) Adipogenesis in areas of myocyte injury. (C) Inflammatory infiltrates within fibrofatty areas. (D) Myocyte contraction band necrosis.



**Figure 3.** Diagnostic endomyocardial biopsy in ARVC (major criterion); each of the 3 biopsy samples shows a significant amount Q10 of myocardial atrophy, with less than 60% of the surface area having fibrous and fibrofatty replacement. (From Marcus FI, McKenna WJ, Sherrill D, et al. Diagnosis of arrhythmogenic right ventricular cardiomyopathy/ dysplasia: proposed modification of the task force criteria. *Circulation* 2010;121:1533–41)

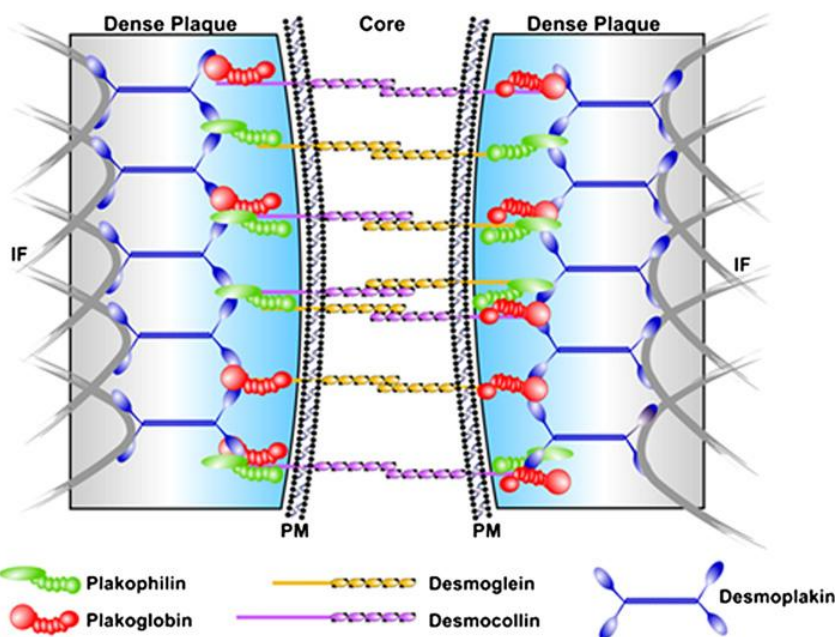
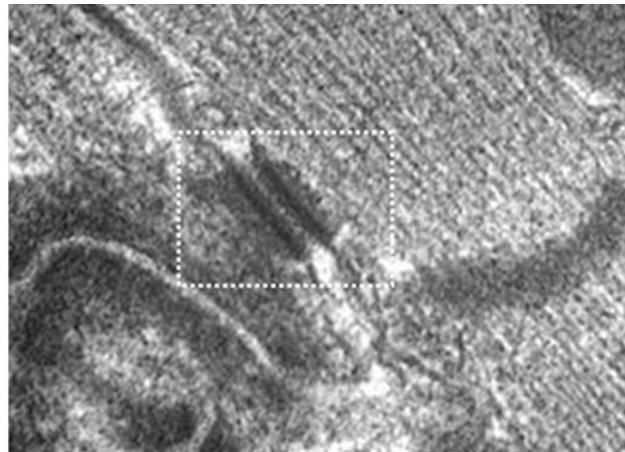
### ***Genetic Background: A disease of the Desmosome***

Despite the early recognition in the 1980s of the hereditary character of the disease in at least 50% of cases, (14, 42,43) the first ARVC-causing gene (plakoglobin) was identified only in 2000, (43) in the recessive cardiocutaneous syndrome called Naxos disease. Soon after, a recessive mutation of desmoplakin was found to cause another cardiocutaneous syndrome (Carvajal disease), characterized by biventricular involvement. (44,45) Desmoplakin was the first defective gene to be associated with autosomal dominant ARVC by Rampazzo and colleagues (46) in 2002. Subsequently, a variety of mutations in plakophilin-2, desmoglein-2, and desmocollin-2 genes have been found, (47-49) and plakoglobin has been reported even in dominant forms. (50) More recently, the gene coding for desmin has been identified as a novel ARVC gene, (51) and should be included in the molecular genetic screening of patients with ARVC. Thus, with the exception of a few other genes unrelated to cell adhesion complex, such as ryanodine 2 receptor, the transforming growth factor  $\beta$ 3, and the transmembrane protein encoding genes, (52-54) the most common disease genes encode for desmosomal proteins, and double or compound heterozygosity is commonly reported. (55-57) This consistent type of protein alteration supports the concept of a final common pathway of genetically determined cardiomyopathies, ARVC being deemed to be a desmosomal disease, hypertrophic cardiomyopathy a sarcomeric disease, and dilated cardiomyopathy a

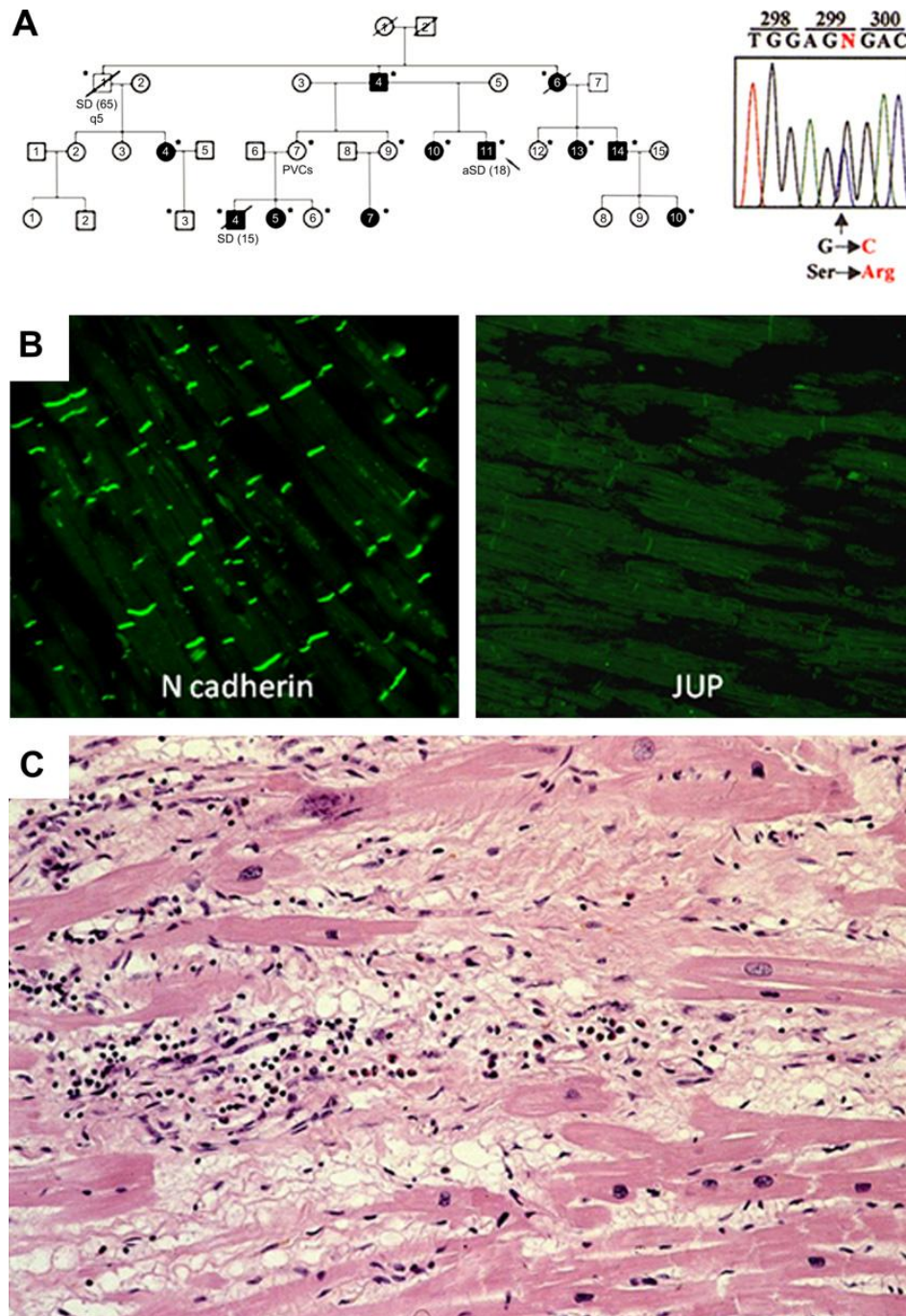
cytoskeletal disease (Figure 4). (24) For these reasons, morphologic and molecular studies of intercellular junctions became a major issue both in humans and experimental pathology. Ultrastructural investigation of endomyocardial biopsies in gene-positive patients with ARVC revealed intercalated disk remodeling with desmosomal abnormalities. In particular, the number of desmosomes was significantly lower, the desmosomal gap widened, and desmosomal length higher in ARVC than in controls. Moreover, abnormally located desmosomes were identified in most cases, often with pale internal plaques. Later, immunohistochemical and molecular studies of intercellular junction proteins showed plakoglobin redistribution from intercellular junctions to other locations within the cell in Naxos disease and Carvajal syndrome. (58,59) These data provided the first evidence that a mutation in a single desmosomal protein may disrupt the subcellular distribution of another intercellular junction protein that is not genetically altered. More recently, Asimaki and colleagues (60) found that, in nearly every case of ARVC, the signal for the intracellular linker protein, plakoglobin, is diminished at intercalated disks and seems to be specific for ARVC (Figure 5). From these findings, the investigators suggested that the evaluation of abnormal localization of desmosomal proteins by immunohistochemistry analysis on endomyocardial biopsy samples represents a promising test for ARVC diagnosis. Redistribution of plakoglobin from junctions to intracellular pools could be part of a final common pathway in disease pathogenesis and impaired mechanical coupling might account for abnormal electrical coupling by gap junction remodeling. Immunohistochemical and electron microscopy studies in Naxos disease revealed reduced localization of mutant plakoglobin to cell-cell junctions, diminished expression of the gap junction protein connexin-43 (Cx43), and a decreased number and size of gap junctions. In Carvajal syndrome, immunoreactive signals for both desmoplakin and plakoglobin were markedly diminished at intercalated disks, as were signals for desmin and connexin-43. (58,59) More recently, similar changes in the various intercalated disk proteins were observed in the classic form of ARVC without cardiocutaneous manifestations caused by plakophilin-2 mutations. 46 These preliminary findings suggest that gap junction remodeling might provide an alternative mechanism for



conduction delay and RV electrical instability, which may result in potentially fatal arrhythmias before fibrofatty myocardial replacement occurs at histology. However, largescale clinicopathologic series, including patients without ARVC, are needed before using this test in the routine diagnostic work-up.



**Figure 4.** Transmission electron microscopy of the desmosome at intercalated disc (boxed area) and schematic representation of the intracellular and intercellular components of the desmosomal plaque. Three separate families of proteins assemble to form desmosome: desmosomal cadherins (desmoglein and desmocollin), armadillo proteins (plakoglobin and plakophilin) and plakins (desmoplakin). The desmosomal cadherins present with extracellular domains that play a pivotal role in cell adhesion, whereas the intracellular domains interact with the armadillo proteins. Among the latter, plakophilin binds to the N-terminal domain of desmoplakin and the C terminal of desmoplakin anchors desmin intermediate filaments. IF, intermediate filaments; PM, cytoplasmic membrane. (From Basso C, Corrado D, Marcus FI, et al. Arrhythmogenic right ventricular cardiomyopathy. *Lancet* 2009;373:1289–300)



**Figure 5.** Immunoreactive plakoglobin signal and histologic features in a sudden death victim from familial ARVC caused by a mutant desmoplakin gene. (A) Family pedigree of the ARVC family and identified mutation (S299R) in exon 7 of desmoplakin gene. (B) Immunohistochemical analysis of human myocardial samples of the proband from patients who died suddenly at the age of 15 years shows a marked reduction in immunoreactive signal levels for plakoglobin but normal signal levels for the nondesmosomal adhesion molecule N-cadherin. (C) Histology of the ventricular myocardium showing ongoing myocardial atrophy with early fibrofatty replacement. (From Corrado D, Basso C, Pilichou K, et al. Molecular biology and the clinical management of arrhythmogenic right ventricular cardiomyopathy/dysplasia. *Heart* 2011;97:530-9).

### ***Etiopathogenetic Theories***

To explain the loss of the ventricular myocardium being substituted by fibrous and fatty tissue, several etiopathogenetic theories have been put forward.(23,26) The original concept was that of a congenital abnormality (dysplasia, aplasia, or hypoplasia) characterized by maldevelopment of the RV myocardium. Confusion in the literature about ARVC has been created by the misuse of the term Uhl anomaly, which was described as an almost total absence of the myocardium of the RV in a 7-month-old infant, with the epicardium applied directly to endocardium in the absence of intervening fat. (6) In contrast, in ARVC there is always fat and fibrous tissue with residual myocytes between the epicardial and endocardial layers. Additional features in differential diagnosis include the lack of family history, heart failure as clinical picture, infrequency of arrhythmias, and a significantly earlier age of presentation, usually in childhood, for Uhl anomaly. In ARVC, myocardial atrophy is the consequence of cell death occurring after birth, usually during childhood, and is progressive with time, as distinct from Uhl disease, a congenital heart defect in which the RV myocardium fails to develop at the embryonic stage. As for the inflammatory theory, it has been a matter of debate whether the inflammatory cells are a reaction to cell death or the consequence of infective or immune mechanisms. (23,26) Cardiotropic viruses, such as adenovirus, hepatitis C virus, and parvovirus B19, have been reported in the myocardium of some patients with ARVC, and they have been proposed as possible causal agents, thus supporting an infective pathogenesis. (61,62) However, the viral agent might be just an innocent bystander or play a secondary, but still important, role. According to the latter hypothesis, the genetically dystrophic myocardium could favor viral settlement (superimposed myocarditis), leading to progression or the precipitation of the disease phenotype. Similar pathologic features of inflammation have been described in spontaneous animal models of ARVC, with a clinical picture dominated by right heart failure and ventricular arrhythmias at risk of sudden death. Moreover, recent evidence of massive inflammatory cell infiltrates following acute myocyte necrosis in the early stages of the disease onset in ARVC transgenic animal models supports the reactive nature of

myocarditis. (63) To explain the fibrofatty phenomenon, a transdifferentiation theory has been put forward, according to which cardiomyocytes transform into fibrocytes and/or adipocytes.<sup>52</sup> However, this theory is questionable because of the limited dedifferentiation capabilities of adult cardiomyocytes. The most likely etiopathogenetic theory remains the dystrophic theory (myocardial dystrophy), which was postulated before the discovery of the disease-causing genes. (23,26) The idea came from the observation of the similarities of histopathologic features of ARVC and of skeletal muscle dystrophies (such as Duchenne or Becker), that is, a progressive and acquired muscular atrophy with replacement by exuberant fatty and fibrous tissue. Thus, in ARVC, cardiomyocyte death, either by apoptosis or necrosis, could account for a genetically determined progressive loss of the ventricular myocardium.<sup>(64,65)</sup> The discovery of the first disease gene (plakoglobin) made it possible to identify additional genes in the autosomal dominant variants of ARVC (ie, desmoplakin, plakophilin-2, desmoglein-2, and desmocollin-2). (23,26) According to the widely accepted defective desmosome hypothesis, genetically determined disruption of desmosomal integrity is the key factor leading to the development of ARVC. Although desmosomes are traditionally considered specialized structures that provide mechanical attachment between cells, they are emerging as mediators of intracellular and intercellular signal transduction pathways. (66-68) Some desmosomal proteins fulfill roles both as structural proteins in cell-cell adhesion junctions and as signaling molecules in pathways mediated by Wnt ligands. Evidence is increasing that mutations in desmosomal proteins can perturb the normal balance of critical proteins in junctions and the cytosol, which, in turn, could alter gene expression by circumventing normal Wnt signaling pathways. Moreover, there is increasing evidence that components of the desmosome are essential for the proper function and distribution of the gap junction protein Cx43, supporting the notion of a molecular crosstalk between desmosomal and gap junction proteins. (69,70)

Transgenic animal models recapitulating the ARVC phenotype have recently been developed. A transgenic mouse with cardiac-restricted overexpression of the C-terminal mutant (R2834H) desmoplakin has been shown to develop increased cardiomyocyte apoptosis, myocardial



fibrosis, and lipid accumulation as well as biventricular dilatation/dysfunction. (71) The mutant mice displayed aberrant intermediate (desmin) filament localization at intercalated discs. Interruption of desmoplakindesmin interactions might lead to desmosome instability, with reduced resistance to mechanical stress, as supported by the ultrastructural evidence of intercalated disc remodeling with widened gaps. This reduced resistance in turn leads to abnormal localization of other cell-cell adhesion molecules and changes in gap junction components. Data from Garcia-Gras and colleagues (72) on cardiac desmoplakin-deficient mice suggest an alternative molecular mechanism of disease that implicates inhibition of the canonical Wnt/bcatenin signaling through Tcf/Lef transcription factors in the pathogenesis of ARVC. In this study, cardiac-specific loss of the desmosomal protein desmoplakin was sufficient to cause nuclear translocation of plakoglobin, increased expression of adipogenic and fibrogenic genes, and the development of an ARVC-like phenotype consisting of myocardial fibrofatty infiltration, cavity enlargement, and ventricular arrhythmias. This evidence for potential Wnt/b-catenin signaling defects implicates a role of cell adhesion proteins not only as passive players in providing mechanical attachment between cells, but as regulators in cardiac development, in myocyte differentiation, and in the maintenance of the myocardial architecture. Another study on heterozygous plakoglobin-deficient mice showed that mutant animals had increased RV volume, reduced RV function, and more frequent and severe ventricular tachycardia of RV origin. In this animal model, endurance training accelerated the development of RV dysfunction and arrhythmias. However, the clinical phenotype of this heterozygous plakoglobin-deficient mutant mouse showed only limited similarity to the human forms of ARVC, because none of the mutant mice were found to have myocardial fibrofatty replacement, and only inconsistent RV dilation was noted. Further insights into the pathobiologic mechanisms involved in ARVC (onset and progression) are provided by the study of a transgenic mouse model (Tg-NS) with cardiac overexpression of desmoglein-2 gene mutation N271S.51 Transgenic mice reproduced the clinical features of ARVC, including spontaneous ventricular

arrhythmias, cardiac dysfunction, biventricular dilatation with aneurysms, and sudden death at young age. Investigation of transgenic lines with different levels of transgene expression attested to a dose-dependent dominant-negative effect of the mutation. The study showed for the first time that myocyte necrosis is the key initiator of myocardial injury. Myocyte necrosis was the first manifestation of disease in all Tg-NS hearts studied. Electron microscopic evaluation in Tg-NS/H mice between 2 and 3 weeks old showed disruption of the sarcolemma, disgregation of myofilaments and other cytoplasmic elements, and mitochondrial swelling, all ultrastructural features consistent with cardiomyocyte necrosis. Myocardial cell death subsequently triggers an inflammatory response and massive calcification within the myocardium, followed later by injury repair with fibrous tissue replacement and aneurysm formation.

## ***Clinical Presentation and Diagnosis***

### ***Clinical Presentation***

Arrhythmogenic RV cardiomyopathy/Dysplasia is a heart muscle disorder characterized by progressive myocyte degeneration with fibrous or fibrofatty replacement, resulting in intraventricular conduction abnormalities and reentrant ventricular arrhythmias occasionally leading to sudden death. (23,26) The incidence of disease in the general population ranges from 1:5000 up to 1:2000. (23,26)

During disease evolution 3 phases of clinical expression have been observed: the early subclinical phase with concealed structural abnormalities (“concealed disease”), the clinical phase in which the established structural criteria are fulfilled (“overt disease”), and the advanced disease phase with severe structural progression (“end-stage disease”).

### ***Concealed Disease***

Individuals with concealed disease are often asymptomatic but may nonetheless be at risk of sudden cardiac death. Functional/structural alterations are subtle or absent on conventional imaging. However, 12-lead resting electrocardiography (ECG) and signal-averaged ECG may reveal minor abnormalities. Asymptomatic ventricular extrasystoles in excess of 200 may be recorded on 24-h ambulatory ECG. Delayed-enhancement imaging in cardiac magnetic resonance might be informative, particularly in early LV involvement. (73) The clinician usually is confronted with the concealed type of disease while evaluating members of affected families. (14,42) The disease onset and expression at early concealed phase have been studied in children homozygous for recessive JUP mutation (Naxos disease). In these individuals, woolly hair and palmoplantar keratoderma appear from infancy, with the cardiomyopathy presenting full penetrance by adolescence. (74) These cutaneous manifestations enable identification of children who are going on to develop ARVC. It was observed that frequent ventricular extrasystoles and depolarization abnormalities preceded any

structural alteration. In a 7-year-old child with Naxos disease presenting this early electrical/arrhythmic phenotype, detailed postmortem evaluation by experts, following a noncardiac death, failed to reveal any macroscopic or histologic cardiac abnormality. (58) However, immunohistology of the heart revealed that mutant plakoglobin failed to localize at intercellular junctions. Connexin-43 was significantly reduced in both right and left ventricles with reduced number and size of gap junctions, leading to the hypothesis that abnormalities in the mechanical junctions may modify the function of electrical coupling and cause intraventricular conduction defects and reentrant ventricular arrhythmias before the development of pathologic myocardial changes. (58) In another 15-year-old boy from Italy, a carrier of dominant DSP mutation who died suddenly, resting ECG shortly before death showed minor nondiagnostic abnormalities.(28) Post mortem, a subepicardial band of acute-subacute myocyte necrosis with granulation tissue and fibrous and fatty tissue repair was revealed on the posterolateral wall of the left ventricle. It has been suggested that myocardial destruction with fibrofatty replacement may be episodic rather than gradual and continuous. (28) Delayed-enhancement imaging in cardiac magnetic resonance might be informative in this case. (73) Therefore, it is of practical significance that individuals with signs suggesting concealed ARVC are followed up serially by 12-lead, signal-averaged, and 24-h ambulatory ECG and, potentially, cardiac magnetic resonance with late-enhancement imaging. This follow-up is most important for familial disease in which family members, particularly the carriers of pathogenic mutations, are at risk of disease development. In the concealed phase of ARVC, differential diagnosis from benign ventricular extrasystoles and acute/subacute myocarditis is important and should be based on characteristics of arrhythmia, ECG abnormalities, cardiac magnetic resonance with late enhancement, family history, and molecular genetic results.

### Overt Disease

Individuals with overt disease present with symptomatic arrhythmias, and RV morphologic/functional abnormalities are readily discernible by conventional imaging. (35,75,76) The disease usually presents between the second and fifth decade of life. The initial event is usually

syncope or sustained palpitation, while sudden death may be the first manifestation of the disease. Chest pain with elevated myocardial enzymes has been reported in some cases. At the time of event, 12-lead ECG may reveal sustained ventricular tachycardia of LBBB morphology. All symptomatic patients exhibit diagnostic findings on 12-lead ECG and 2-dimensional echocardiography applying the established criteria.<sup>43,45</sup> Event-free survival is almost 60% at the beginning of the fifth decade of life.

### End-Stage Disease

Heart disease progresses over time, involving the right or mostly both ventricles. Structural progression detected by serial echocardiography is usually associated with severe potentially lethal ventricular arrhythmias. Close follow-up of patients with recessive ARVC revealed that disease evolution follows a stepwise progression. (77) In each step an arrhythmic storm precedes morphologic/functional deterioration of the right and LV. In cases with grossly diffuse RV ventricular involvement and right atrial dilatation, atrial fibrillation and paroxysmal atrial tachycardia have been observed. (77) Symptoms of heart failure, with fatigue, gastrointestinal disorders, hepatomegaly, and ascites, appear in the final stages when the right or both ventricles are severely affected. (78) ARVC is one of the rare heart disorders causing heart failure without pulmonary hypertension. Arrhythmic activity is almost totally suppressed at the end stages of evolution. Cardiac sarcoidosis mimics clinical presentation of ARVC with respect to arrhythmic, electrocardiographic, and structural findings. It should be considered in cases with biventricular involvement in the absence of family history, and differential diagnosis is based mainly on histologic findings. When ARVC involves both ventricles severely or there is predominantly left ventricular involvement, it is difficult to differentiate clinically from dilated cardiomyopathy. Arrhythmogenicity exceeding the degree of structural profile and family history of right-dominant disease support ARVC diagnosis. Endomyocardial biopsy and molecular genetic investigation further assist in establishing disease diagnosis.

## ***Twelve-lead Electrocardiogram***

### *Activation Delay (Depolarization) Findings*

Activation delay due to cellular uncoupling and altered tissue architecture by fibrofatty alteration is often visible on the ECG. In the original descriptions and 1994 TFC, typical manifestations are epsilon waves and widening of the QRS complex (>110 ms) in leads V1 to V3. (19) Epsilon waves and localized QRS prolongation are major criteria of the 1994 TFC. Epsilon wave was defined as a distinct deflection after the end of the QRS complex, that is, after the QRS complex had returned to the isoelectric line. (79) In the new TFC the epsilon wave remained as a major criterion, but the widening of the QRS complex was deleted. This widening may give rise to confusion, because discrimination from right bundle branch block (RBBB) may be difficult. Although the epsilon wave is highly specific for ARVC, sensitivity is low. Peters and Trummel (80) determined increased precordial QRS ratio by  $(V1+V2+V3)/(V4+V5+V6) > 1.2$  to solve the problem of discrimination with RBBB. However, this criterion was found in only 35% of patients with proven ARVC. Nasir and colleagues (80) reported the delayed S-wave upstroke, defined from the nadir of the S wave up to the isoelectric line in V1–3, of 55 milliseconds or more to be a sensitive criterion representing activation delay. The authors' group (81) introduced prolonged terminal activation duration (TAD). TAD is defined as the longest value in V1–3, from the nadir of the S wave to the end of all depolarization deflections, thereby including not only the S-wave upstroke but also late fractionated signals and epsilon waves. Thus, total activation delay was conveyed by this new parameter. The difference between S-wave upstroke and TAD is clearly visible. TAD was considered prolonged if 55 milliseconds or more, and only applicable in the absence of complete RBBB. The authors applied the same value as determined for prolonged S-wave upstroke by Nasir and colleagues (80) because it proved to be a cutoff point with high specificity in the authors' study as well. Prolonged TAD appeared to be the most sensitive activation delay criterion. It was recorded in 30 of 42 ARVC patients (71%), whereas the criterion

of only prolonged S wave was identified in only 52% of these patients. Prolonged TAD was not identified in 26 of 27 patients with idiopathic VT.

### Repolarization Findings

Abnormalities in repolarization in patients with ARVC are visible as inverted T-waves. In the 1994 TFC, inverted (negative) T-waves in V1–3 or beyond were considered as a minor criterion for ARVC diagnosis in the absence of RBBB, and only if the patient was older than 12 years. Because of the high specificity for ARVC, this criterion was upgraded to a major criterion in the new TFC, for individuals older than 14 years and in the absence of complete RBBB. In the authors' series of 42 ARVC patients, this criterion was observed in 28 patients (67%) and in none of the patients with idiopathic VT. (81) Thus, sensitivity and specificity are similar to prolonged TAD. In the new TFC, two additional criteria were included as minor criteria: 1. Inverted T-waves only in leads V1 and V2 in individuals older than 14 years and in the absence of complete RBBB.<sup>34</sup> This criterion was identified in 4 of the authors' 42 patients (10%). Inverted T-waves in leads 1–4 in individuals older than 14 years in the presence of RBBB. (20) This criterion was added because RBBB may be attributable to local activation delay, and a negative T-wave in V4 and beyond is very unlikely in classic RBBB.

### Twelve-lead Electrocardiogram during Ventricular Tachycardia

Type and number of VT morphologies reflect location and extension of the disease process. In the absence of severe LV and septal structural disease, a VT with LBBB morphology (dominant negativity in V1) means a site of origin in the RV. This is the reason why ARVC is associated with monomorphic VT with LBBB morphology. Idiopathic VT originating from the RV outflow tract typically shows LBBB morphology with an inferior (vertical) axis. By contrast, in ARVC, affected areas are also found in other parts of the RV including the so-called triangle of dysplasia.<sup>1</sup> Consequently, VTs originating from these areas can show LBBB morphology with a nonvertical

axis as well. The authors evaluated the occurrence of LBBB VT with a superior axis, arbitrarily defined from  $-30^{\circ}$  to  $-150^{\circ}$  (81) This morphology was recorded in 27 of 42 patients (64%) with ARVC/D diagnosed according to the 1994 TFC. None of the 27 patients with idiopathic VT had this morphology. Thus, this criterion had a similar specificity and sensitivity to that of prolonged TAD. In accordance with the authors' definition, recording of a VT with LBBB morphology and superior axis, defined as negative or indeterminate QRS in leads II, III, and aVF, and positive in lead aVL, became a major criterion in the new TFC. A VT with LBBB morphology and inferior axis remained a minor criterion. The number of premature ventricular complexes on Holter recording required for counting as a minor criterion decreased to 500 per 24 hours. Because of the variable extension of the disease process in ARVC, the number of different VT morphologies may vary as well. Thus, multiple VT morphologies may be recorded in a single patient. The number of different VTs in ARVC patients was quantified and compared with data from a control group after 8 years of follow-up. (80) Multiple VT morphologies were recorded in 27 of 42 ARVC/D patients (64%), whereas the control group with idiopathic VT had only a single morphology. This study confirmed that occurrence of multiple VT morphologies is the rule rather than the exception in ARVC patients. In the case of only a single VT morphology occurring spontaneously, programmed electrical stimulation (PES) contributed significantly to yield multiple morphologies. In total, 10 additional ARVC patients or in total 88% fulfilled the multiple VT morphology criterion. (80) Because of significant overlap with the superior axis criterion, the number of VT morphologies was not used in the new TFC.

### ***Cardiovascular Imaging***

At early stages, the disease involves subepicardial/mediomural layers of myocardium in certain regions of RV free wall as the outflow tract, apex, and posterodiaphragmatic wall, called the "triangle of dysplasia." At this stage structural/functional alterations may not be detectable by



conventional imaging. Therefore, the disease cannot be excluded in the absence of structural/functional abnormalities on imaging in young individuals with characteristics for ARVC ventricular arrhythmias or positive family history. Alternatively, late enhancement in cardiac magnetic resonance might reveal subepicardial/mid-myocardial distribution, suggesting fibrous substitution in these areas. Late enhancement has proved to be informative for early LV involvement, whereas analogous characterization of RV myocardium has proved difficult because of the thin wall of the RV and possible confusion with fat. (82,83) All patients with overt disease present these regional wall motion abnormalities at the “triangle of dysplasia” on 2-dimensional echocardiography, cardiac magnetic resonance, or angiography. Regional hypokinesia may be prone to overinterpretation, leading to falsepositive results, and were excluded from the revised diagnostic criteria. Morphologic abnormalities consisting of trabecular derangement, hyperreflective moderator band, and sacculations have been also observed. With disease progression, the RV becomes globally dilated. RV outflow tract dilatation on 2-dimensional echocardiography (end-diastolic diameter  $\geq 32$  mm on parasternal long-axis view) showed sensitivity of 75% and specificity of 95% in large series of ARVC probands. (20) On cardiac magnetic resonance it shows RV end-diastolic volume of 110 mL/m<sup>2</sup> or more for males and 100 mL/m<sup>2</sup> or more for females, and ejection fraction of 40% or greater. (20) Since the initial descriptions of the disease, LV involvement has been increasingly reported and related to adverse prognosis. (84)

### ***Diagnostic Criteria***

Multiple criteria are needed to diagnose ARVC/D because there is no single criterion that is sufficiently specific to reliably establish the diagnosis. Thus, there is no “gold standard.”<sup>1</sup> In about 50% of patients, a desmosomal genetic abnormality can be identified. However, even if a desmosomal abnormality is present, it does not indicate that the individual is or will be affected

because the penetrance is so variable. In the early stages the disease may be difficult to differentiate from normal, and in the advanced stage the diagnosis may be obvious. Even so, several diseases such as cardiac sarcoidosis can mimic the clinical presentation of ARVC. (85) Usually the patient will come to medical attention for evaluation of palpitations, due to premature ventricular beats (PVBs) or nonsustained ventricular tachycardia. (26) Other clinical presentations are sustained ventricular tachycardia, syncope, or resuscitated sudden death. Evaluation may be requested because of ARVC in a family member. Uncommonly, the patient can present with right heart failure with or without ventricular arrhythmias. Then the differential diagnosis includes congenital or acquired heart disease that primarily affects the right heart such as atrial septal defect, Ebstein anomaly and congenital or acquired tricuspid regurgitation, primary pulmonary hypertension, or pulmonary hypertension secondary to pulmonary emboli. Recognition of the disease has now been extended to patients with desmosomal abnormalities who present with primarily left or biventricular involvement associated with ventricular arrhythmias. This possibility raises the question of whether the disease should be called “arrhythmogenic cardiomyopathy” rather than “arrhythmogenic RV cardiomyopathy.” The original description of the clinical profile of 24 patients with this disease was based on experience with patients in the more advanced stage of the disease, generally unresponsive to antiarrhythmic drugs, who were referred to a tertiary care electrophysiology center for treatment of recurrent ventricular tachycardia. Twenty-one of the 24 patients had electrocardiograms (ECGs) with T-wave inversion in V1 to V4. Nine patients had incomplete right bundle branch block (RBBB) and one patient had complete RBBB. Postexcitation or epsilon waves were present in 7 patients. By echocardiogram, the right ventricle/left ventricle ratio was increased in all patients. The LV size and contractility was normal in all but one patient. As is common with many newly diagnosed diseases, the index cases with severe disease are followed by those with lesser severity of the disease as well as variations from the original description. In a recent study of 108 newly diagnosed patients with ARVC, only 30 of 95 (32%) patients had T-wave inversion beyond V3. Epsilon waves were present in 1 of 95 ECGs, severe wall motion abnormalities by 2-dimensional (2-D) echocardiogram in 44 of

93 (47%), and markedly reduced global RV function in 24 of 85 (28%). (86) The observation that there were patients with ARVC who had fewer and less severe clinical features of the disease was soon recognized after the first clinical profile was published in 1982. It became evident that the disease can be exceedingly difficult to diagnose, particularly in those with minimal structural and/or functional alterations of the RV. This corollary led to the formation of a Task Force that in 1994 proposed major and minor criteria to aid in the diagnosis. (19) This report achieved the goal of standardizing diagnostic criteria. With time and experience, it became evident that these criteria lack diagnostic sensitivity. Therefore, a second Task Force was assembled in 2007 to modify these criteria, and the revised criteria have recently been published. Several modifications, particularly those relating to the ECG, deserve emphasis because the 12-lead ECG can alert the physician to strongly suspect this diagnosis. For example, in the 1994 guidelines, ventricular tachycardia with LBBB configuration was considered a minor criterion. It has become evident that patients who have ventricular arrhythmias arising from the RV can be further categorized as those who have LBBB with an inferior axis versus LBBB with a superior axis. In those with LBBB and inferior axis (QRS positive in leads 2, 3, and aVF, and negative in lead aVL), the differential diagnosis is that of RV outflow tract tachycardia (RVOT), a relatively benign condition, and ARVC, which may have a serious prognosis. Patients with this configuration of ventricular arrhythmia who have T-wave inversion in leads V1 to V3 on the standard 12-lead ECG are more likely to have ARVC than benign idiopathic RVOT. Morin and colleagues<sup>11</sup> recently reported that in patients with ventricular tachycardia of LBBB and inferior QRS axis, there were 35 of 94 (37%) patients with AC who had T-wave inversion in V1 to V3, but only 5 of 121 (4%) patients with idiopathic RVOT tachycardia had this ECG finding. Patients who have ventricular ectopy not originating from the RVOT, characterized by LBBB configuration with a superior QRS axis (negative QRS in leads 2, 3, and aVF, and positive in lead aVL) are more likely to have RV cardiomyopathy. This information is reflected in the revised criteria that categorize ventricular arrhythmias of LBBB configuration with an inferior QRS as a minor criterion while grading those with superior superior axis as a major

criterion. Also, T-wave inversion in leads V1, V2, V3 or beyond is now listed as a major ECG criterion rather than minor. In addition, T-wave inversion beyond V3 in the presence of RBBB is listed as a new minor criterion, because this finding is uncommon in patients with RBBB who do not have ARVC.<sup>12</sup> A new ECG finding considered to be a minor criterion is slurring and delay of the upslope of the QRS complex in V1, V2, or V3 caused by prolonged depolarization in the RV. This criterion is defined as “terminal activation duration of QRS  $\geq 55$  msec measured from the nadir of the S wave to the end of the QRS, including R prime in V1, V2, or V3 in the absence of complete RBBB.” The definition of an abnormal signal-averaged ECG has been changed in the modified criteria. In the previous criteria, the standard interpretation of an abnormal ECG was 2 of the 3 abnormal measurements of late potentials. It has been found that there is similar sensitivity and specificity with any one of the three measurements; the filtered QRS duration (fQRS  $\geq 114$  milliseconds), duration of terminal QRS less than 40 mV (low-amplitude signal  $\geq 38$  milliseconds), or the root mean squared voltage of the terminal 40 milliseconds (root mean square  $\leq 20$  mV). The presence of only one abnormal parameter in the absence of QRS duration of 110 milliseconds or more on the standard ECG is now a minor criterion for late potentials in the modified Task Force criteria. There were no criteria for the diagnosis of ARVC by magnetic resonance imaging (MRI) in the 1994 guidelines because there was little diagnostic experience with this imaging modality at that time. Quantitative parameters are also provided for abnormal criteria by echocardiography, and methods to analyze RV angiograms for volume and wall motion abnormalities are now available. In the 1994 Task Force criteria patients with moderate to severe decrease in LV function were excluded. This restriction has been eliminated in the modified criteria because it is clear that patients with desmosomal abnormalities can present with predominant left or biventricular involvement. Documentation of familial involvement has been clarified. There is also recognition of the relatively newly discovered genetic abnormalities. The presence of a pathogenic mutation probably associated with ARVC in the proband or family members under evaluation is now recognized as a major criterion. The new criteria include modified diagnostic terminology. Patients

formerly were classified as affected or not affected, based on meeting Task Force criteria. It is now realized that this sharp division should be changed because there are patients who almost meet the criteria and are thought to be affected. Some of these patients have a desmosomal abnormality. The new terminology for diagnosis consists of definite: 2 major criteria, or 1 major and 2 minor criteria, or 4 minor criteria from different categories; borderline: 1 major and 1 minor, or 3 minor criteria from different categories; possible: 1 major or 2 minor criteria from different categories. The revised criteria were applied post hoc to 108 newly diagnosed probands enrolled in the Multidisciplinary Study of Right Ventricular Dysplasia, a study supported by the National Institutes of Health. Not including genetic results, of the 28 probands classified as borderline (met some but not all of the original Task Force criteria—ie, 1 major and 1 minor or 3 minor), 16 were reclassified by the new criteria as affected, 5 remained borderline, and 7 were classified as “possible ARVC.” Of 7 probands previously classified as unaffected, 4 became “possible,” 1 became affected, and 2 became borderline. Therefore, the major effect of the revised criteria is to increase the sensitivity of the classification, primarily in probands previously classified as borderline. The sensitivity of the revised criteria is not perfect. For example, 9 of 28 probands classified as borderline by original criteria have gene variants consistent with ARVC. When genetic abnormalities were not included, the proposed criteria classified 4 as affected, 3 as borderline, and 2 as possible. Including the proposed genetic criteria resulted in all 9 being classified as affected, by including genetic abnormalities. It has been observed that family members of probands may have the disease but with reduced penetrance. Family members may have some clinical manifestations of ARVC and/or the genetic abnormality, but do not meet the new Task Force criteria for probands. Therefore, guidelines have been proposed for family members and have been adopted as part of the modified Task Force criteria. (20) According to these recommendations, in the context of proven ARVC in a first-degree relative, the diagnosis of familial ARVC is based on the documentation of one of the following in a family member: 1) T-wave inversion in right precordial leads, V1, V2, and V3 in individuals older than 14 years; 2) Late potentials by signal-averaged ECG; 3) Ventricular

tachycardia of LBBB morphology on ECG, Holter monitor, or during exercise testing, or >200 premature ventricular contractions (PVCs) in 24 hours; 4) Mild global dilatation and/or reduction in RV ejection fraction with normal left ventricle or mild segmental dilatation of the RV; 5) Regional RV hypokinesis.

## ***Risk Stratification and Prevention of Sudden Cardiac Death***

### ***Natural History***

Based on clinicopathologic and follow-up studies, 4 clinical phases of the disease have been identified: (1) the concealed form is the subclinical and asymptomatic phase, which is characterized by subtle structural abnormalities. In this disease stage, SCD might occur as the first disease manifestation in previously asymptomatic young people, mostly during physical exercise or competitive sports activity. (15,87) Early/minor disease expression is usually observed in family members who are identified during family screening. The electrocardiograph (ECG) may either be normal or show right precordial repolarization abnormalities with no, or only regional, RV wall motion abnormalities. Differential diagnosis with idiopathic RV outflow tract tachycardia is often not achieved by means of conventional clinical testing and may depend on demonstration of underlying fibrofatty replacement of RV myocardium by endomyocardial biopsy, (41) RV delayed enhancement by contrast-enhanced cardiac magnetic resonance (CMR),(82) The overt arrhythmic form is the classic clinical presentation. Ventricular arrhythmias dominate the clinical scenario in the form of frequent premature ventricular beats, short runs of VT, or sustained monomorphic VT, with a LBBB morphology. Such arrhythmias may provoke syncope, especially during physical exercise, and may degenerate into VF leading to cardiac arrest. Common ECG abnormalities consist of T-wave inversion and prolongation of QRS interval (>110 milliseconds) in the precordial leads that explore the RV (ie, V1–V2/V3). The spectrum of RV morphofunctional alterations ranges from global dilatation/dysfunction to regional wall motion abnormalities and diastolic bulging typically localized in the triangle of dysplasia. The LV and the septum are usually involved to a lesser extent, whereas biventricular or left-dominant variants of disease have been reported. (29) Ventricular structural abnormalities are clearly detected by current imaging techniques such as echocardiography, angiography, and CMR.

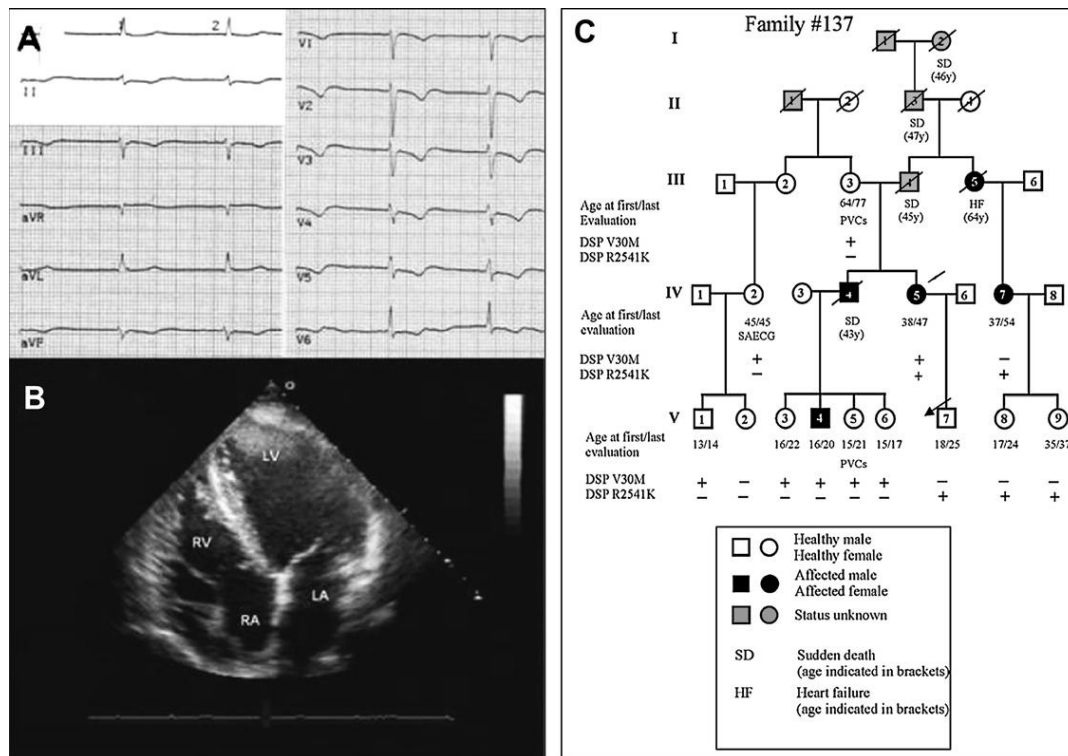
In patients experiencing severe arrhythmic symptoms/events, implantable cardioverter defibrillator (ICD) has proved to represent a life-saving therapy. RV failure caused by progressive loss of myocardium with severe RV dilatation and systolic dysfunction, in the presence of preserved LV function (or mild dysfunction). Biventricular heart failure with significant LV involvement, which mimics dilated cardiomyopathy of other causes with progressive heart failure and related complications, such as atrial fibrillation, thromboembolic events, and malignant tachyarrhythmias, (35) requiring anticoagulation therapy, ICD, and, in the most severe cases, cardiac transplantation. (35) More recent studies on genotype-phenotype correlations have shown common and early LV involvement in carriers of desmoplakin mutations (Figure 1). (55) In contrast with the original idea of an almost exclusive RV involvement, 3 distinct ARVC/D phenotypes are currently recognized: the RV phenotype, either isolated or associated with mild LV involvement; the left dominant phenotype, with early and prominent LV manifestations; and the biventricular phenotype, characterized by equal involvement of both ventricles. Therefore, the old view that LV involvement occurs secondarily in advanced disease has evolved into the current perspective that ARVC is a genetically determined myocardial disease affecting the whole heart.

### *Incidence of SCD and Heart Failure*

The mortality of patients with ARVC is currently estimated to be around 1% per year. Most deaths are related to life-threatening ventricular arrhythmias that may occur at any time during the disease course. Progressive ventricular dysfunction leading to heart failure and embolic stroke may cause death in a smaller proportion of patients.<sup>1</sup> The overall incidence of SCD caused by VF varies between 0.1% and 3% per year in adults with diagnosed and treated ARVC, although it is unknown and expected to be higher in adolescents and young adults, in whom the disease is clinically silent until sudden and unexpected arrhythmic cardiac arrest occurs. (78) Nava and colleagues (42) observed a lower mortality among family members during a mean follow-up of 8.5 years (0.08% per year) compared with ARVC probands. Hulot and colleagues (78) reported the long-term



natural history of 130 patients with ARVC who were referred to a tertiary center and followed for 8.1 ( $\pm 7.8$ ) years. There were 21 deaths, which accounted for an annual mortality of 3% caused by either progressive heart failure in approximately two-thirds of patients or SCD in one-third of patients.



**Figure 1.** Clinical findings of index case (IV,5) and pedigree of family #137 with DSP-related ARVC. (A) Twelve-lead ECG with low QRS voltages in frontal leads and T wave inversion in inferior and precordial leads. (B) Two-dimensional echocardiogram showing a biventricular involvement. (C) Family's pedigree: arrow indicates the index case; + and - denote the presence or absence of a desmosomal gene mutation. (Modified from Baucé B, Nava A, Boffagna G, et al. Multiple mutations in desmosomal proteins encoding genes in arrhythmogenic right ventricular cardiomyopathy/dysplasia. *Heart Rhythm* 2010;7:25, 26).

### Risk Stratification

SCD in patients with ARVC is often an unpredictable event that occurs without alarming symptoms. This explains why there has been a trend toward indiscriminate ICD implantation once the disease was diagnosed, without an appropriate risk stratification. In recent years, several studies have tried to identify the clinical variable associated with an unfavorable arrhythmic course. The available data based on autopsy series or observational clinical investigations suggest that the most

powerful predictors of SCD and worse outcome in ARVC include prior cardiac arrest caused by VF, unexplained syncope, VT (either sustained or nonsustained), exposure to intense physical exercise, severe RV/LV dysfunction, and young age at the time of diagnosis (Box 1). (21,22,88)

### Cardiac Arrest and Malignant Tachyarrhythmias

In patients with ARVC, VF, and monomorphic VT are arrhythmic manifestations caused by different pathobiologic mechanisms that occur in different disease phases. Corrado and colleagues (21) reported that prior cardiac arrest caused by VF and hemodynamically unstable VT are independent risk factors for life-saving ICD interventions in a large series of patients with ARVC. However, patients implanted because of VT without hemodynamic compromise had a statistically significant better outcome, with a negligible incidence of VF episodes during follow-up. These findings are in agreement with the current perspective that VF occurs in younger affected patients with progressive disease during active phases of myocyte death, whereas hemodynamically well-tolerated monomorphic VT is caused by a reentry mechanism around a stable myocardial scar as the result of a healing process that occurs in a later stage of the disease course. Resuscitated VF is a poor prognostic factor. In the series reported by of Canu and colleagues, (89) a prior history of aborted SCD from VF was documented in 2 of the 3 patients who died suddenly.

### Syncope

The importance of syncope as a risk factor for SCD in ARVC was first reported by Marcus and colleagues (90) and was later confirmed by other groups. Turrini and colleagues (91) reported that syncope was an independent predictor of SCD with a sensitivity of 40% and a specificity of 90%. Syncope has been proved to be the strongest predictor of appropriate and life-saving device interventions in patients with ARVC who received an ICD for primary prevention (DARVIN II). (21) The 9% annual incidence of appropriate device discharges among patients with prior syncope is comparable with that observed in patients who underwent device implantation because of a

history of cardiac arrest or sustained VT. Young individuals with genetic cardiomyopathies and/or ion channel disorders may suffer from vasovagal or, more widely, nonarrhythmic syncope, which makes differential diagnosis difficult and its prognostic value elusive. For instance, in patients with hypertrophic cardiomyopathy, several nonarrhythmic mechanisms, such as reflex-mediated change in vascular tone or heart rate, LV outflow tract obstruction, and supraventricular tachyarrhythmia, may cause syncope. In patients with ARVC, most episodes of syncope are secondary to ventricular tachyarrhythmias and associated with a poor prognosis similarly to sustained VT or VF. (21)

### Sport Activity

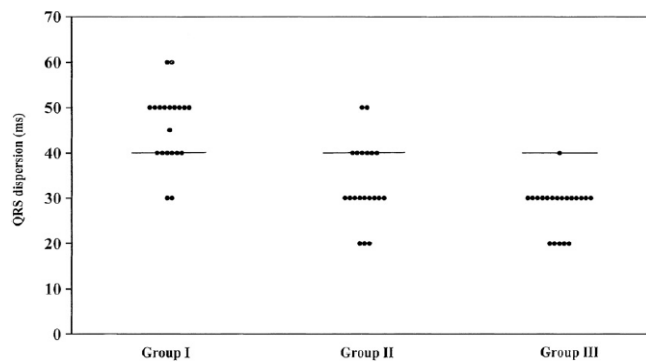
ARVC shows a propensity for life-threatening ventricular arrhythmias during physical exercise, and participation in competitive athletics has been associated with an increased risk for SCD. (15,87,92) Identification of affected athletes by preparticipation screening has proved to result in a substantial reduction of mortality of young competitive athletes. In addition, physical sport activity has been implicated as a factor promoting acceleration of the disease progression. There is experimental evidence that in heterozygous plakoglobin deficient mice, endurance training accelerated the development of RV dysfunction and arrhythmias. (93) It has been suggested that impairment of myocyte cell-to-cell adhesion may lead to tissue and organ fragility that is sufficient to promote myocyte death, especially in conditions of mechanical stress, such as those occurring during competitive sports activity. As a corollary, asymptomatic and healthy gene carriers should be advised to refrain from practicing significant physical exercise, not only for reducing the risk of ventricular arrhythmias but also to prevent disease worsening. Whether prophylactic b-blocker therapy further lowers the rate of arrhythmic complications and slows down disease progression remains to be proved.

## Clinical Findings

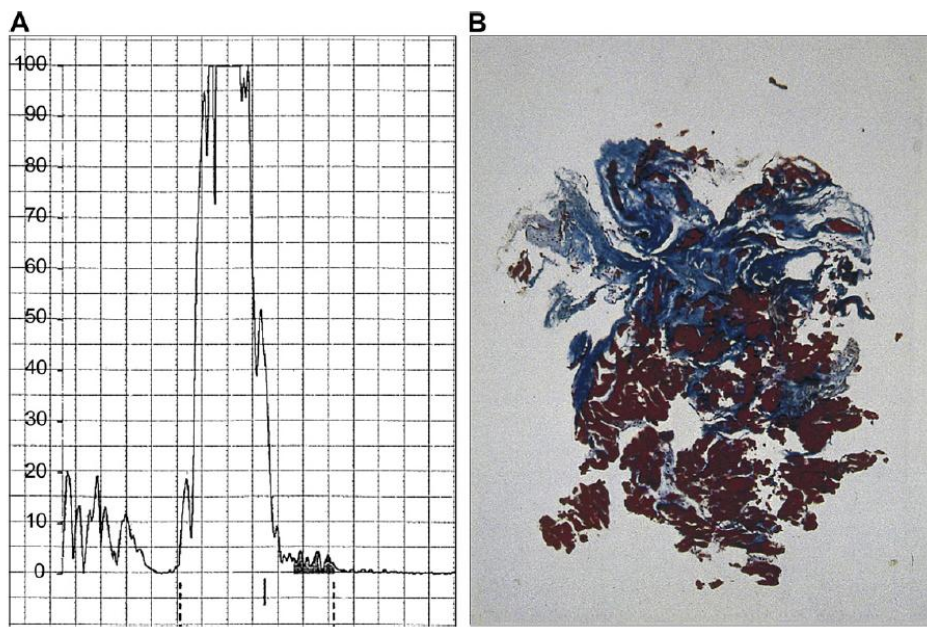
### *ECG and morphofunctional abnormalities*

Right precordial QRS prolongation, QRS dispersion, and late potentials (LPs) on signal-averaged ECG (SAECG) have been significantly associated with an increase of the arrhythmic risk in patients with ARVC. These ECG abnormalities reflect a right intraventricular conduction defect caused by the fibrofatty replacement of the RV free wall, which may predispose to life-threatening ventricular arrhythmias. Localized prolongation of QRS complex in V1 to V3 to more than 110 milliseconds has a sensitivity of 55% and a specificity of 100% for the diagnosis of the disease. (79)

QRS prolongation, in the form of incomplete right bundle branch block (RBBB) or, more often, nonspecific conduction defect, is usually caused by an intraventricular myocardial delay (parietal block). Septal incomplete or complete RBBB may occasionally be the result of marked RV dilatation/dysfunction affecting the specialized right bundle branch (septal block). Right precordial QRS prolongation correlates with the arrhythmic risk, as shown by the study of Turrini and colleagues (91) in which patients who died suddenly showed a significant greater QRS prolongation (125 milliseconds) in V1 to V2/V3 compared with living patients with ARVC with or without VT (QRS duration 5 113 milliseconds and 106 milliseconds, respectively). Turrini and colleagues (91) showed that QRS dispersion of more than 40 milliseconds was the strongest independent predictor of SCD in ARVC, with a sensitivity of 90% and a specificity of 77% (Figure 2). In patients with ischemic heart disease, LPs on SAECG have been shown to be a noninvasive marker for areas of slow ventricular conduction, which is a prerequisite for reentrant arrhythmias. The predictive value of SAECG in this particular subgroup was low: only 44% of subjects with LPs had arrhythmias, whereas 76% of those with arrhythmias had abnormal SAECG. (Figure 3). (94)



**Figure 2.** Distribution of QRS dispersions in 3 ARVC groups: group I is composed of 20 patients who died suddenly, group II of 20 patients with sustained VT, and group III of 20 patients with no sustained ventricular tachycardia. Mean values are indicated by horizontal lines. (Modified from Turrini P, Corrado D, Basso C, et al. Dispersion of ventricular depolarization-repolarization: a non invasive marker for risk stratification in arrhythmogenic right ventricular cardiomyopathy. *Circulation* 2001;103:3078).



**Figure 3.** Signal-averaged ECG and endomyocardial biopsy findings in a patient with ARVC with sustained VT and reduced RVEF (49%). (A) Positive LPs at 40-Hz filter (fQRS 5 136 milliseconds, LAS 5 77 milliseconds, RMS 5 2 mV). (B) Severe replacement-type myocardial fibrosis (blue stain). (Modified from Turrini P, Angelini A, Thiene G, et al. Late potentials and ventricular arrhythmias in arrhythmogenic right ventricular cardiomyopathy. *Am J Cardiol* 1999;83:1218).

### RV Dysfunction and LV Involvement

A ventricular dilatation/dysfunction is a well established clinical marker of a worse prognosis. In the study by Hulot and colleagues (78) on the long-term follow-up of 130 patients

with ARVC, right heart failure and LV dysfunction were identified as independent risk factors predicting cardiovascular death. Several ICD studies indicated extensive RV dysfunction as an independent risk factor for appropriate device discharges. (21,22)

#### Inducibility at Programmed Ventricular Stimulation

The electrophysiologic study with programmed ventricular stimulation (PVS) seems to be of limited value in identifying patients with ARVC at risk of lethal ventricular arrhythmias because of a low predictive accuracy. The results of DARVIN studies show that the incidence of appropriate and lifesaving ICD discharges did not differ among patients who were and were not inducible at PVS, regardless of their indication for ICD implant. (21,22) Moreover, the type of ventricular tachyarrhythmia inducible at the time of electrophysiologic study did not seem to predict the occurrence of VF during the follow-up. These findings are in agreement with the limitation of electrophysiologic studies for arrhythmic risk stratification of other nonischemic heart disease such as hypertrophic and dilated cardiomyopathy. In the study of Wichter and colleagues, (95) inducibility of VT or VF in a preimplant electrophysiologic study of ARVC patients with previous history of cardiac arrest or sustained VT showed just a trend toward statistical significance for subsequent appropriate device interventions. The available data do not support the routine use of PVS for assessing the risk of SCD in patients with ARVC, neither among patients surviving an episode of VF/VT nor among those who are asymptomatic without spontaneous clinical tachyarrhythmias.

#### ICD Therapy-based Risk Stratification

Implantable defibrillator is the most logical therapeutic strategy for patients with ARVC, whose natural history is primarily characterized by the risk of arrhythmic cardiac arrest. Several studies on either secondary or primary prevention have provided significant insights for therapy-based risk stratification of ARVC patients, leading to identification of clinical and

electrophysiologic markers that may predict the appropriate shock against life-threatening ventricular arrhythmias. (21,22,95) The DARVIN 1 study (21) yielded the following predictors of appropriate ICD interventions on potentially lethal arrhythmic events: prior cardiac arrest, VT with hemodynamic compromise, LV involvement, and younger age. There is general agreement that patients who survive an episode of VF or sustained VT benefit most from ICD implantation because of their high incidence of malignant arrhythmia recurrences.(21,22) The life-saving role of prophylactic ICD therapy in patients with ARVC with no previous history of sustained tachyarrhythmias or cardiac arrest is less clear. The DARVIN 2 study (22) showed that patients who received an ICD because of a prior syncope had an incidence of appropriate, life-saving interventions triggered by either VF or ventricular flutter (Vfl) that was similar to that of patients with a history of aborted SCD/poorly tolerated sustained VT. However, asymptomatic patients had a favorable long-term outcome, regardless of familial SCD and electrophysiologic study findings. (21,22) These results are particularly relevant for clinical management of the growing cohort of asymptomatic ARVC relatives and healthy gene carriers who are identified by cascade family screening. Demonstration of nonsustained VT on 24-hour Holter monitoring and/or exercise testing in asymptomatic patients confers an increased risk of developing VT during the follow-up, although it did not significantly predict the occurrence of potentially lethal VF. It remains to be determined whether, in the absence of syncope or significant ventricular arrhythmias, severe dilatation and/or dysfunction of RV, LV, or both, as well as early onset structurally severe disease (age<35 years), are related to adverse arrhythmic outcome and therefore require prophylactic ICD.

### ***Implantable Cardioverter Defibrillator***

There is definitive clinical evidence that the implantable defibrillator (ICD) is the most effective therapy for both primary and secondary prevention of SCD in patients with coronary artery disease. However, there are few available data on efficacy and safety of such a treatment in

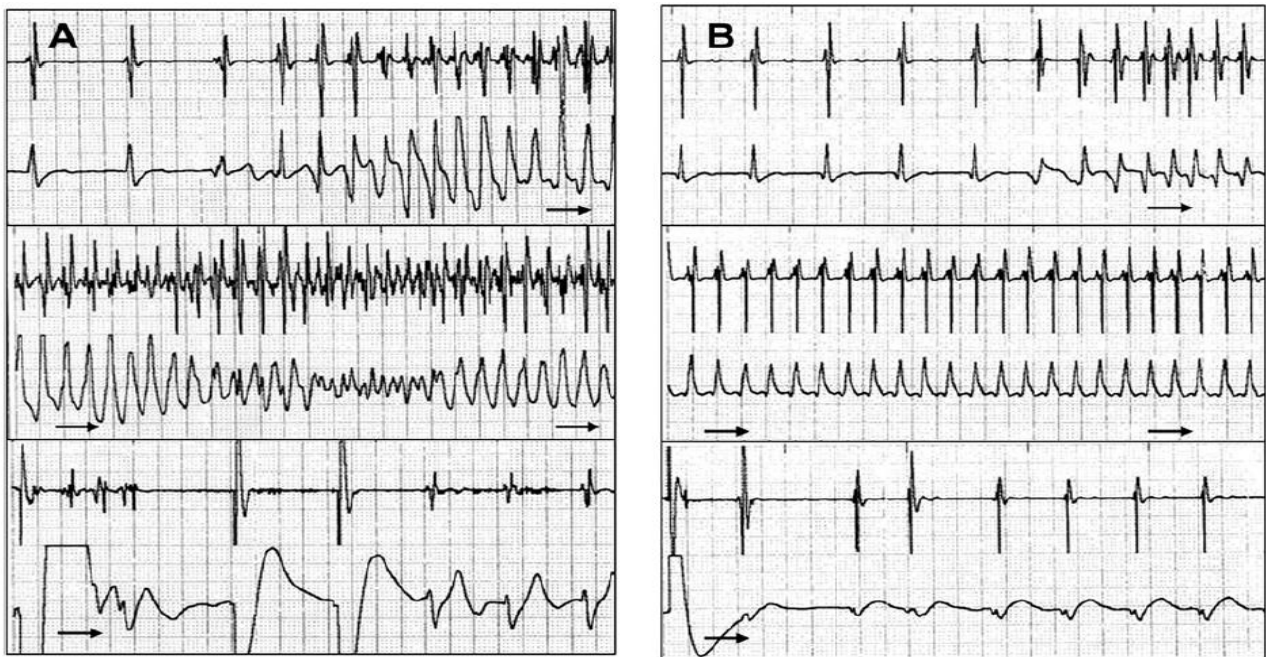
patients with nonischemic cardiomyopathies, mostly because of the relatively low disease prevalence and the relatively low event rate in affected patients. ARVC has become an emerging indication for ICD implantation because its natural history is more strongly related to ventricular electrical instability, which can precipitate SCD mostly in young people, whereas heart failure is uncommon and occurs later during the disease course as a result of RV disease progression and LV involvement. In the past, indications for ICD implantation in ARVC were empiric and based widely on the experience gained by different centers using analogies with coronary artery disease.<sup>8</sup> Because clinical variables predicting clinical outcome were undetermined, there was a tendency to implant an ICD once the disease was diagnosed, regardless of risk stratification. Although ICD confers optimal protection against SCD, economic costs, quality of life concerns including psychological repercussions, risk for inappropriate shocks, and device-related complications argue strongly against indiscriminate device implantation. In this article the authors review the studies that have become available in the last decade on the efficacy and safety of ICD therapy in patients with ARVC. Particular reference is reserved for DARVIN (Defibrillator in Arrhythmogenic Right Ventricular Cardiomyopathy International Study) studies which have addressed the clinical impact of ICD therapy in changing the natural history of ARVC in a large patient population treated for both secondary and primary prevention of SCD.

### *DARVIN Studies*

The DARVIN studies I and II were observational, multicenter investigations aimed to determine the efficacy and safety of ICD therapy in a large patient population with ARVC at high risk for SCD. (21,22) In both studies the survival benefit of the ICD was evaluated by comparing the actual patient survival rate with projected freedom of ventricular fibrillation/flutter (VF/Vfl) (Figure 1). These arrhythmias were used as surrogate for aborted SCD, based on the assumption that in all likelihood they would have been fatal without termination by the device. The end point



was reached by device interrogation and review of intracardiac stored electrocardiograms (ECGs) regarding ICD interventions in response to VF/Vfl during follow-up.

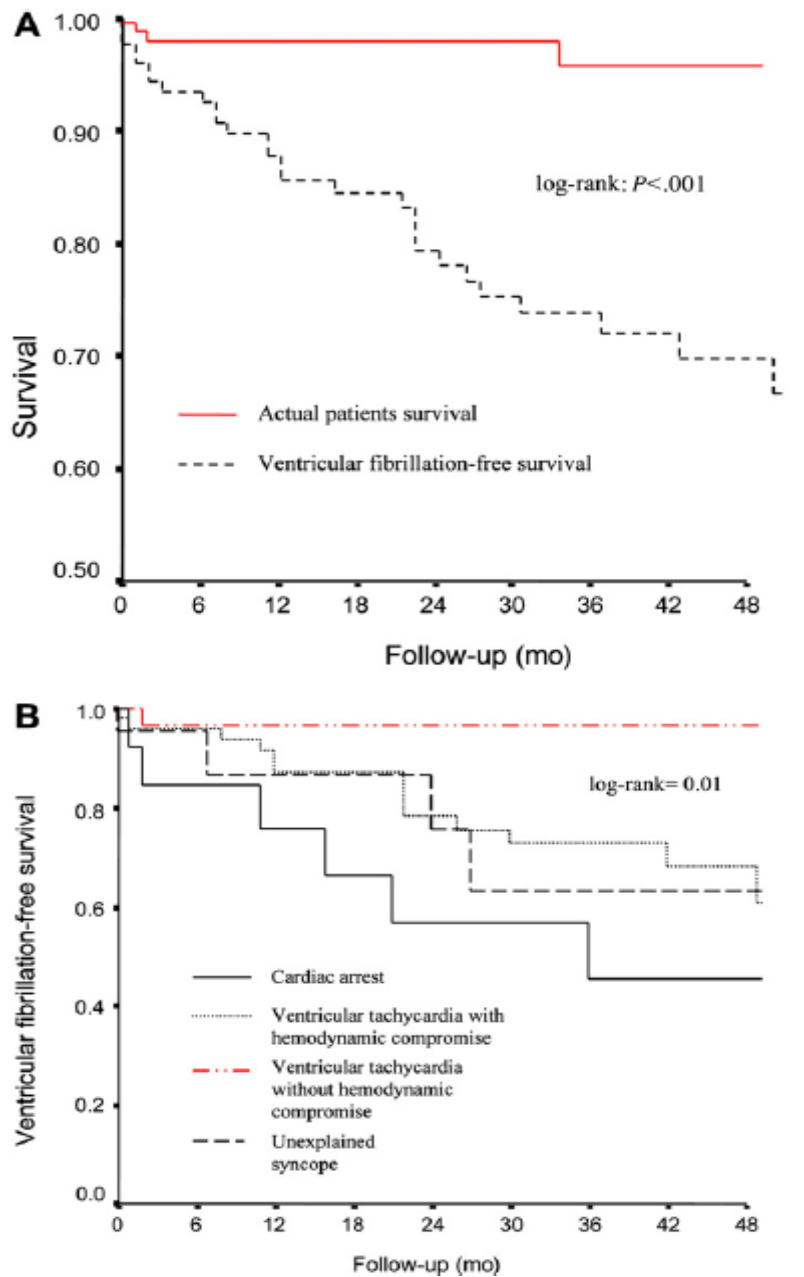


**Figure 1.** Stored intracardiac ventricular electrocardiogram from ARVC patients who received ICD therapy. (A) Spontaneous onset of ventricular fibrillation is automatically terminated by a defibrillation shock, which immediately restores sinus rhythm. (B) Ventricular flutter at a ventricular rate of 280 beats/min, which begins abruptly after 5 beats of sinus rhythm. The ICD discharges appropriately and restores sinus rhythm. Arrows indicate tracings are continuous.

#### DARVIN I

The DARVIN I study population consisted of 132 ARVC patients (93 males, 39 females; mean age  $40 \pm 15$  years) who were recruited at 22 institutions in North Italy and at one in the United States. (21) Most of the patients (~80%) received an ICD implant because of a history of either cardiac arrest or sustained ventricular tachycardia (“secondary prevention”). During a mean follow-up of  $39 \pm 25$  months, there were 3 deaths: one sudden, one due to infective endocarditis, and one due to congestive heart failure. Over the study period, 48% of patients (64 of 132) had at least one appropriate ICD intervention, 12% had inappropriate interventions, and 16% had ICD-related complications. Fifty-three of the 64 patients (83%) were receiving antiarrhythmic drugs at the time of the first appropriate discharges, mostly consisting of sotalol and b-blockers (alone or in association with amiodarone). The analysis of intracardiac ECG data stored by the ICD showed that 32 of 132 patients (24%) experienced VF/Vfl that in all likelihood would have been fatal in the

absence of the device. The VF/Vfl-free survival rate was 72% at 36 months compared with the actual patient survival of 98% (Figure 2A). Younger age, a history of cardiac arrest or hemodynamically unstable ventricular tachycardia, and LV involvement were independent clinical predictors of VF/Vfl. It is noteworthy that the ICD therapy did not improve survival in those patients implanted because of hemodynamically stable ventricular tachycardia, who had a significantly lower incidence of VF/Vfl over the follow-up (Figure 2B). Programmed ventricular stimulation (PVS) was not helpful in risk assessment of patients. More than 50% of inducible patients did not experience ICD therapy, while a similar proportion of noninducible patients had appropriate intervention during the 3.3-year follow-up period. This finding is in agreement with the limitation of electrophysiological study for arrhythmic risk stratification of other nonischemic heart diseases such as hypertrophic and dilated cardiomyopathy. Precise data on the efficacy of ICD in comparison with antiarrhythmic therapy could not be derived from this nonrandomized study. However, the majority of appropriate interventions and 53% of shocks on VF/Vfl occurred despite concomitant antiarrhythmic therapy with b-blockers and/or class III antiarrhythmic drugs. This finding highlights that the protection provided by ICD against SCD may be considerably superior. However, DARVIN I study included high-risk ARVC patients, not comparable with most patients with the disease who can be either not treated or treated effectively with antiarrhythmic drugs because of the low arrhythmic risk.

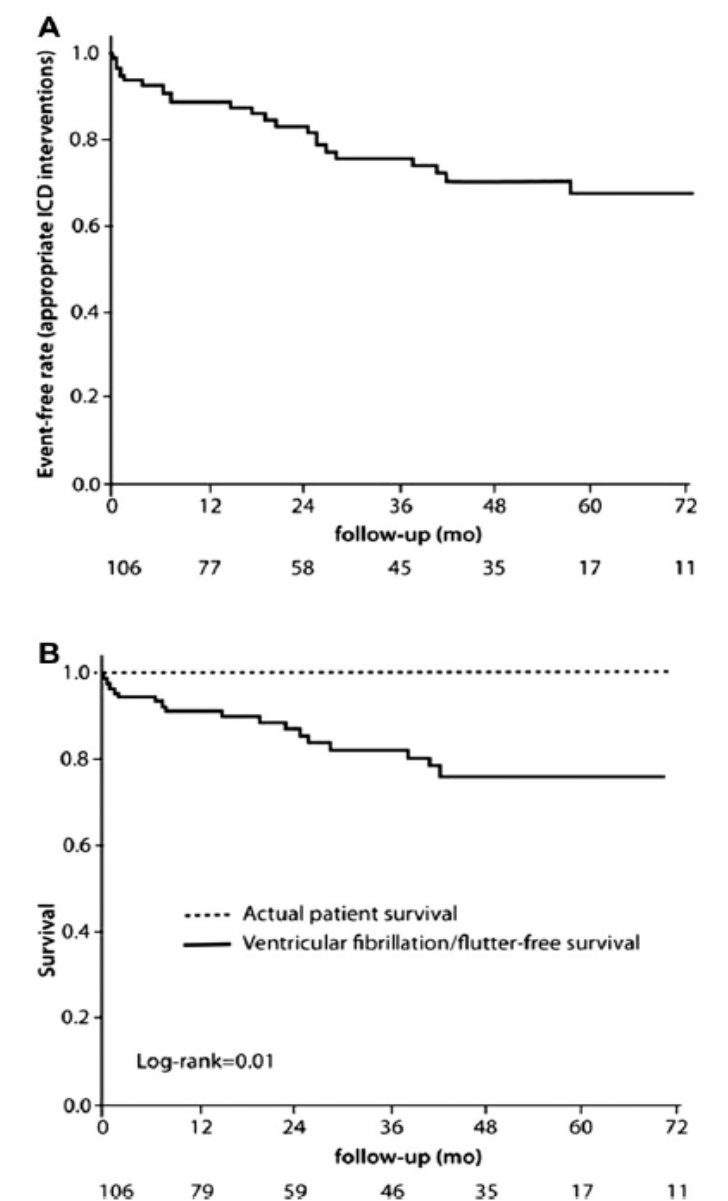


**Figure 2.** DARVIN I study. (A) Kaplan-Meier analysis of actual patient survival (upper line) compared with survival free of VF/Vfl (dashed line) that in all likelihood would have been fatal in the absence of the ICD. The divergence between the lines reflects the estimated mortality reduction by ICD therapy of 24% at 3 years of follow-up. (B) Kaplan-Meier curves of freedom from ICD interventions on VF/Vfl for different patient subgroups stratified for clinical presentation. Patients who received an ICD because of sustained ventricular tachycardia without hemodynamic compromise had a significantly lower incidence of VF/Vfl during the follow-up. (Modified from Corrado D, Leoni L, Link MS, et al. Implantable cardioverter defibrillator therapy for prevention of sudden death in patients with arrhythmogenic right ventricular cardiomyopathy/dysplasia. *Circulation* 2003;108:3087, 3088).

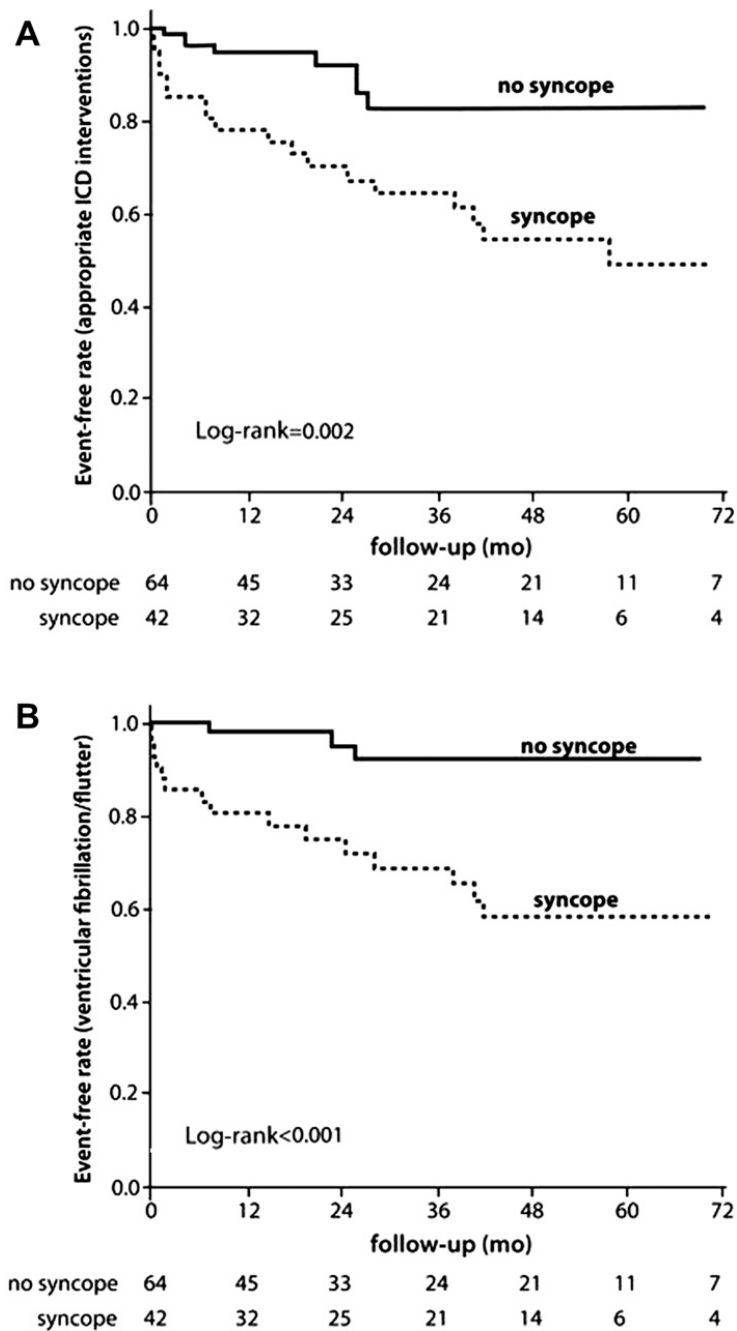
## DARVIN II

This international multicenter study included 106 consecutive patients (62 men and 44 women; mean age  $35.6 \pm 18$  years), with ARVC and no prior VF or sustained ventricular tachycardia (VT), who received a prophylactic ICD because of one or more arrhythmic risk factors such as syncope, asymptomatic nonsustained VT, familial sudden death, and inducibility at PVS.(22) During a mean follow-up of  $58 \pm 35$  months (4.8 years) after ICD implantation, no death occurred. Of the 106 study patients, 25 (24%) had appropriate ICD interventions, 20 (19%) had inappropriate ICD interventions, and 18 (17%) had device-related complications. In 17 of 25 patients, the arrhythmia triggering ICD discharge was VF/Vfl that may have been fatal without termination by the device. The annual rate of potentially “life-saving” shocks against VF/Vfl was 3%. At 48 months, the actual patient survival rate was 100% compared with the VF/Vfl-free survival rate of 77%. The Kaplan-Meier analysis of the incidence of ICD interventions that were triggered by VF/Vfl suggested a significant improvement in survival through the follow-up period, with an actual total patient survival rate of 100% compared with a 77% Vf/Vfl survival rate at 48 months, and an estimated benefit of ICD implantation of 23% (Figure 3). The strongest predictor of an increased arrhythmic risk in the DARVIN II study population was a history of syncope. Syncope was the only independent predictor of any appropriate ICD interventions (hazard ratio [HR] 5 2.94) and shock therapy on VF/Vfl (HR 5 3.16) (Fig. 4). Patients with prior syncope had a fourfold risk for subsequent episodes of potentially fatal VF/Vfl (annual rate 5 9%). Asymptomatic patients with nonsustained VT presented a trend toward an increased arrhythmic risk. These patients had an overall rate of appropriate ICD intervention of 3.7% per year and a rate of appropriate ICD intervention against VF/Vfl of 1.48% per year. Asymptomatic ARVC patients who received an ICD because of a family history of sudden death did not experience any appropriate ICD interventions over the follow-up. This finding is in agreement with those of previous studies showing that the majority of affected ARVC relatives are likely to have a benign course and a that a sizable proportion of healthy gene carriers will not develop clinically significant disease owing to reduced

disease penetrance. As in the DARVIN I study, programmed ventricular stimulation had limited accuracy in predicting appropriate ICD interventions. In the DARVIN II study the positive predictive value of PVS was 30% for any appropriate ICD interventions and 35% for potentially life-saving shock against VF/Vfl. On the other hand, a negative PVS did not indicate better prognosis because approximately one-third of noninducible patients experienced appropriate ICD interventions, and approximately one-fourth experienced shock on potentially lethal arrhythmic events.



**Figure 3.** DARVIN II study. (A) Kaplan-Meier analysis of cumulative survival from any appropriate ICD interventions. (B) Kaplan-Meier analysis of survival free of VF/Vfl compared with actual patient survival. The estimated mortality reduction at 48 months of follow-up is 23% (ie, the difference between the actual patient survival rate of 100% and VF/Vfl-free survival rate of 77%). (Modified from Corrado D et al. *Circulation* 2010;122:1147).



**Figure 4.** DARVIN II study. Kaplan-Meier analysis of freedom from any appropriate ICD interventions (A) and shock therapies on VF/Vfl (B), stratified by syncope.

### Safety of ICD Therapy

Concerns have been raised on the safety of ICD therapy in ARVC patients because of the risk of perforation due to the lead implantation into a thin RV free wall, as well as on the difficulty in obtaining and maintaining adequate sensing and pacing thresholds at implantation and during

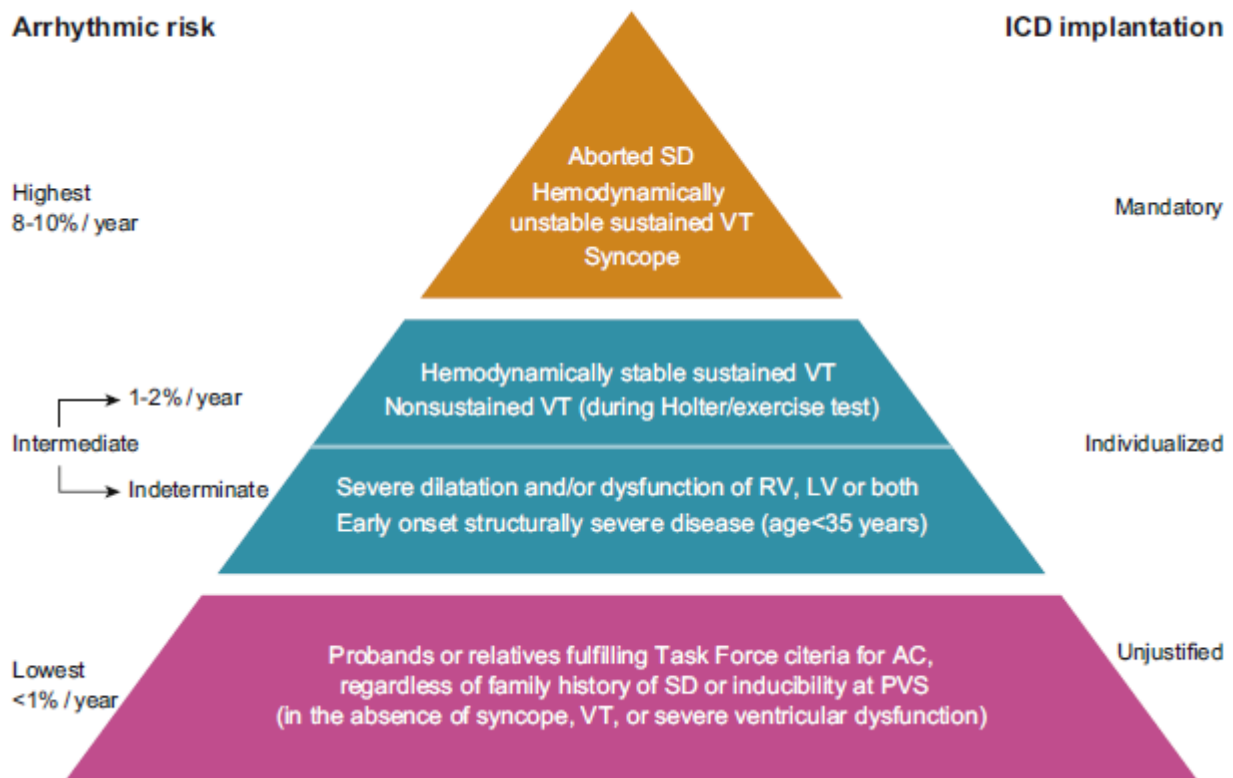
follow-up, due to the progressive loss of the RV myocardium. The referenced series of ARVC patients undergoing ICD implantation did not report any lead perforation. However, a more difficult and timeconsuming ventricular lead positioning to obtain adequate R-wave sensing and pacing thresholds, because of the RV myocardial atrophy with ensuing reduced electrical activity, has been reported. The study of Wichter and colleagues (95) demonstrated a high rate of device-related complications over a long-term follow-up. Thirty-seven of 60 patients (62%) had a total of 53 serious adverse events, 10 occurring during the perioperative phase and 43 during the follow-up. There were 31 leadrelated adverse events in 21 patients (35%); insulation failure/oversensing in 10, undersensing in 8, lead fracture in 5, lead dislodgment in 2, lead thrombosis in 2, and subcutaneous lead fracture in 1. Surgical revision or implantation of an additional pace/sense lead was required in 26 of 31 lead-related complications (84%). This high rate of lead-related adverse events may be explained by the peculiar ARVC pathobiology that leads to progressive loss of myocardium with fibrofatty replacement, also affecting the site of RV lead implantation. In this regard, Corrado and colleagues (21,22) reported that approximately 4% of ARVC patients required an additional septal lead owing to loss of ventricular sensing/pacing functions at the apical RV free wall during a follow-up of 3.3 years. Therefore, particular attention should be paid to progressive loss of R-wave sensing amplitude over time, which may not only compromise adequate device function but may also indicate disease progression. The use of b-blockers and dual-chamber detection algorithms, which improve discrimination of ventricular from supraventricular arrhythmias, have been reported to reduce the number of inappropriate interventions in young ARVC patients. However, limitation of the number of implanted leads may be a favourable approach, mostly in the young patient subgroup, because of the substantial incidence of lead failure over time (cumulatively 37% at 7 years in the Wichter study (95), which includes not only compromise in pacing/sensing or defibrillation function by the mechanisms previously described but also mechanical lead complications (lead insulation failure or fracture) which, in turn, may contribute to inappropriate or inadequate ICD discharges.

### Indication for ICD Implantation

The available data demonstrate that ICD therapy improves long-term prognosis and survival when applied to ARVC patients at high risk for SCD. Although ICD confers optimal protection against sudden death, the significant rate of inappropriate interventions and complications, as well as the psychological repercussions mostly in the younger age group, strongly suggest the need to accurately stratify the patient arrhythmic risk before device implantation. Figure 5 shows the pyramid of arrhythmic risk stratification and the current indications to ICD implantation in ARVC patients, based on the annual rate of appropriate ICD interventions against life-threatening ventricular arrhythmias (ie, episodes of VF/Vfl) derived from observational studies. The best candidates for ICD therapy are patients with prior cardiac arrest and those with VT with hemodynamically unstable VT (ie, associated with syncope or shock); syncope that remains unexplained after exclusion of noncardiac causes and vasovagal mechanisms is also considered a valuable predictor of sudden death and represents an indication for ICD implantation per se. In this high-risk group of patients, the rate of appropriate ICD intervention against life-threatening ventricular tachyarrhythmias (that in all likelihood would have been fatal in the absence of shock therapy) is approximately 8% to 10% per year and the estimated mortality reduction at 36 months of follow-up ranges from 24% to 35%. (21,22,27) By contrast, ICD implantation for primary prevention in the general ARVC/D population seems to be unjustified. As indicated by the DARVIN II study on prophylactic device implantation in ARVC patients with no sustained VT or VF, asymptomatic probands and relatives do not benefit from ICD therapy, regardless of familial sudden death or inducibility at PVS.<sup>12</sup> This patient cohort carries a low arrhythmic risk over a long-term follow-up (ICD intervention rate <1 per year), in addition to a significant rate of device-related complications and inappropriate discharges. Patients with welltolerated sustained VT or nonsustained VT on Holter or exercise testing have an intermediate arrhythmic risk (ICD intervention rate w1%–2% per year). In this patient subgroup, the decision for ICD implantation needs to be individualized; antiarrhythmic drug therapy (including b-blockers) and/or catheter



ablation seem to be a reasonable first-line therapy. In the absence of syncope or significant ventricular arrhythmias, whether severe dilatation and/or dysfunction of right ventricle, LV, or both, as well as early onset structurally severe disease (age <35 years) require prophylactic ICD remains to be determined.



**Figure 5.** Pyramid of arrhythmic risk stratification and current indications to ICD implantation in ARVC patients, based on the annual rate of appropriate ICD interventions against life-threatening ventricular arrhythmias (ie, episodes of VF/Vfl) derived from observational studies. PVS, programmed ventricular stimulation; SD, sudden death. (Modified from Corrado D, Basso C, Pilichou K, et al. Molecular biology and the clinical management of arrhythmogenic right ventricular cardiomyopathy/dysplasia. *Heart* 2011;97:537).

## ***Catheter Ablation of Ventricular Tachycardia***

Catheter ablation for scar-related VT in the postinfarction setting has become an established and effective therapy. The fact that the pathologic and electrophysiologic substrate for VT is uniquely subendocardial in this setting and the development of surgical subendocardial resection as a treatment that could be emulated percutaneously contributed to the modern evolution of VT ablation in ischemic cardiomyopathy. In other contexts, including nonischemic dilated cardiomyopathy and ARVC, the substrate for VT has been more difficult to locate, define, and ablate. In ARVC, the only available surgical therapy, RV disconnection, could not provide definitive information regarding the mechanism of VT in these patients, and the current understanding of this fact has been derived largely from studies in the electrophysiology laboratory.

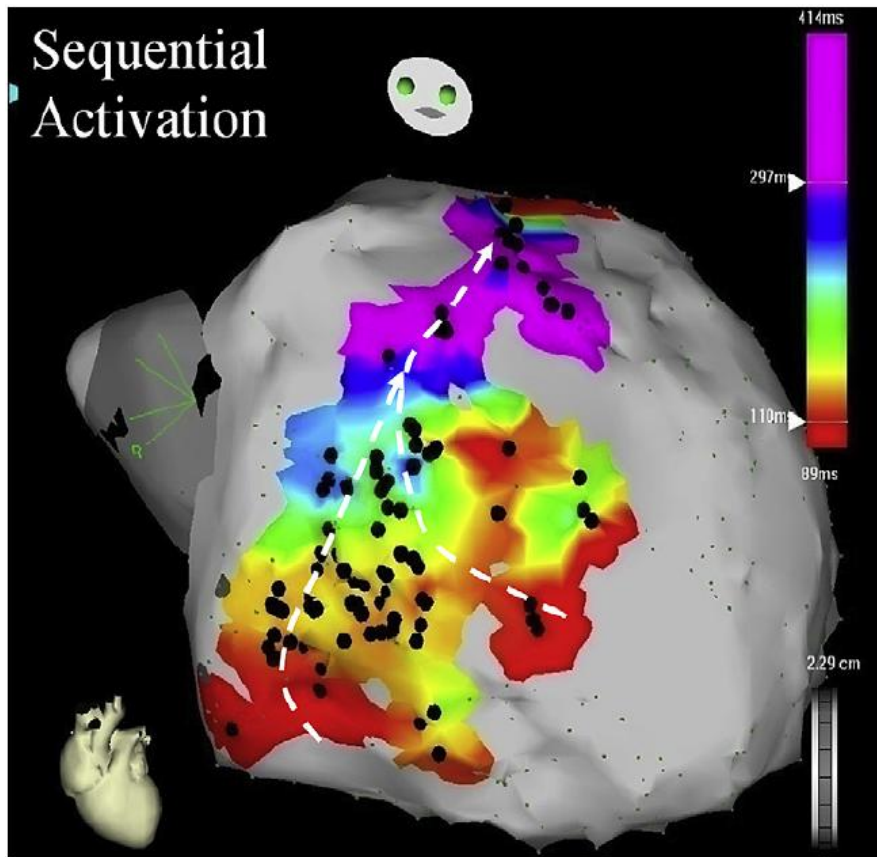
### ***Ventricular Tachycardia in ARVC***

Reentrant mechanisms underlie the overwhelming majority of VT in ARVC, although focal ventricular arrhythmias can occur early in the course of the disease. (96) Given that most ARVC-related VTs arise from the free wall of the RV, most VTs display a LBBB configuration with poor R-wave progression in the precordial leads. An RBBB VT morphology can be created as a result of direct LV involvement with the disease process associated with basal LV substrate abnormalities and RBBB VTs with positive R waves across all or most of the precordial leads. Monomorphic VT with an LBBB configuration generally has a late precordial transition after V4 reflecting the frequent RV free wall origin, with spread of activation away from the anterior RV and precordial leads toward the posterior LV. RV septal VT exits typically display an earlier precordial transition. Given the usual attitude of the RV and its typical axis in the thoracic cavity, leads I and aVR are useful in identifying likely exit sites. Basal sites of origin are characterized by positive forces in lead I, and more apical sites, being closer to the left side, are isoelectric or negative in lead I. Inferior exit sites in the RV display a positive vector in lead aVR, usually with a superior axis.

Close attention should also be paid to the QRS morphology during VT as demonstrated in the precordial lead V2 and inferior leads. QS complexes in these respective leads strongly suggest an epicardial exit from the mid RV free wall or inferior RV wall, respectively. Other characteristics of VT in ARVC are its inducibility with programmed electrical stimulation, multiple morphologies including those with a superiorly directed frontal plane axis, potential termination with overdrive pacing, and ability to be entrained with manifest or concealed fusion. These features strongly suggest a reentrant mechanism and argue against a focal VT mechanism.

The common underlying factor in all cardiomyopathies, ventricular scarring, promotes reentry in at least 2 ways: first, by creating anatomic and functional barriers favoring the development of unidirectional conduction block and second, by altering cell-cell coupling, leading to slowed conduction. The cause, nature, and distribution of the scarring process is unique in ARVC, with genetically determined desmosomopathy leading to widespread myocyte apoptosis, confluent replacement of the lost myocardium with fibrofatty tissue, and a RV free wall preponderance of this process, progressing inwards from the epicardium. However, the electrophysiological consequences are similar to other cardiomyopathic processes, with a generalized milieu of slow and discontinuous electrical propagation that predisposes to the development of often very large macro-reentrant VT circuits. The footprints of this abnormal substrate are well recognized and can be detected with catheter recordings of bipolar electrograms. Electrical activation through normal RV myocardium was defined in patients with no structural heart disease with the use of the CARTO electroanatomic mapping system and the Navistar catheter (Biosense Webster, Diamond Bar, CA, USA), which has a 4-mm distal tip electrode, a 2-mm ring electrode, and a 1-mm interelectrode distance. Normal RV endocardium is characterized by bipolar signals displaying 3 or fewer deflections from baseline, with peak-to-peak amplitude greater than 1.5 mV, (97) whereas areas of bipolar voltage less than 0.5 mV correspond to dense scar. (97)The definition of normal epicardial electrogram parameters is confounded by the presence of epicardial fat, which may have an insulating effect and attenuate signal amplitude. However, it has been established when sampling signals more than 1 cm away

from the defined large epicardial coronary vessels that more than 95% of bipolar electrograms overlying the RV have an amplitude of greater than 1.0 mV. (97) The precision of this determination is increased by incorporating electrogram morphology as well as voltage into consideration of the extent of the epicardial substrate. Normal ventricular electrogram morphology, as well as having fewer than 4 deflections from baseline, is characterized by sharp intrinsic deflections corresponding to rapidly progressing activation wavefronts, with total duration less than 70 ms. Electrical conduction through isolated surviving bundles of myocytes enmeshed within areas of dense fibrosis is slow and serpiginous, which is reflected in long-duration, low-amplitude fractionated potentials. When these bundles form isolated regions deep within confluent scar areas, local activation can occur much later than it occurs in the surrounding areas, resulting in isolated potentials (IPs) being recorded after the far field potential following an intervening isoelectric line. Given the large, confluent scars seen in patients with ARVC, these IPs can occur well into the T-wave or beyond, in which case they are sometimes referred to as very late potentials (VLPs). The prevalence and distribution of these scar-related electrograms, in addition to the bipolar signal amplitude, are important in defining the abnormal electrical substrate in ARVC/D, especially on the epicardium. In some cases, networks of VLPs have been defined by sinus rhythm activation mapping (Figure 1) that mark the location of putative conducting channels anatomically constrained by dense fibrosis. These channels may form critical protected diastolic isthmuses during VT as has been demonstrated in the postinfarct context.<sup>16</sup> Ablation of VLPs at the entrance of these channels can result in disappearance of the entire network of channels when the scar is remapped, strongly suggesting that these potentials are all linked by common conducting fibers. The electroanatomic substrate defined as discussed has been shown to correspond to regions of myocardial loss and replacement with fibrofatty tissue.

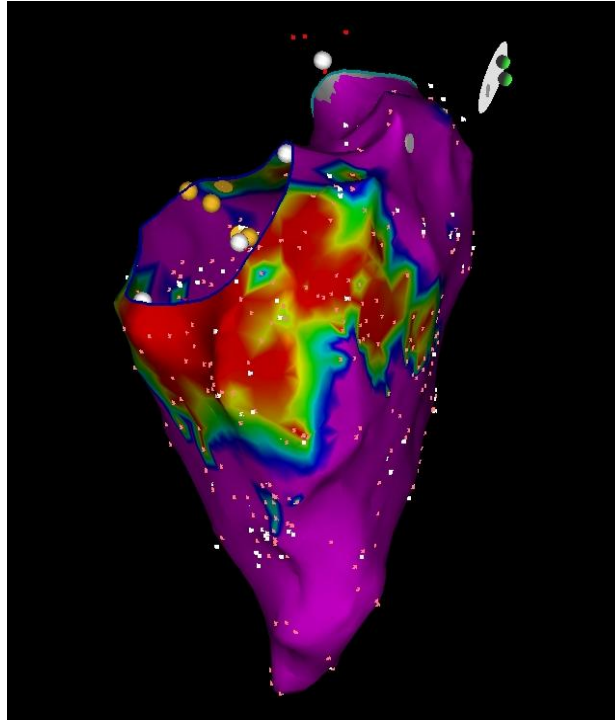


**Figure 1.** Sequential pattern of isolated late potential activation in arrhythmogenic RV dysplasia scar. Activation mapping of sinus rhythm epicardial isolated late potentials is shown. These networks of late potentials show patterns of linking such as those displayed here. The sequential pattern suggests that, when VT isthmuses sites are shown by entrainment to correspond to the sequential IP sites, the barriers of such VT circuits are largely anatomically determined by scar architecture. When IPs are arranged in such networks, significantly less ablation may need to be performed to eliminate them.

In keeping with the general pattern of perivalvular abnormalities seen in nonischemic cardiomyopathies, the endocardial distribution of electroanatomic scar (confluent areas of bipolar low voltage  $<1.5$  mV) in patients with VT in the setting of ARVC has been shown to extend from the tricuspid valve, the pulmonary valve, or from both over the RV free wall (Figure 2). (97-101) This substrate distribution has been shown to correspond to the location of VT circuits. In a significant minority of patients with ARVC presenting with VT, LV involvement is also seen.

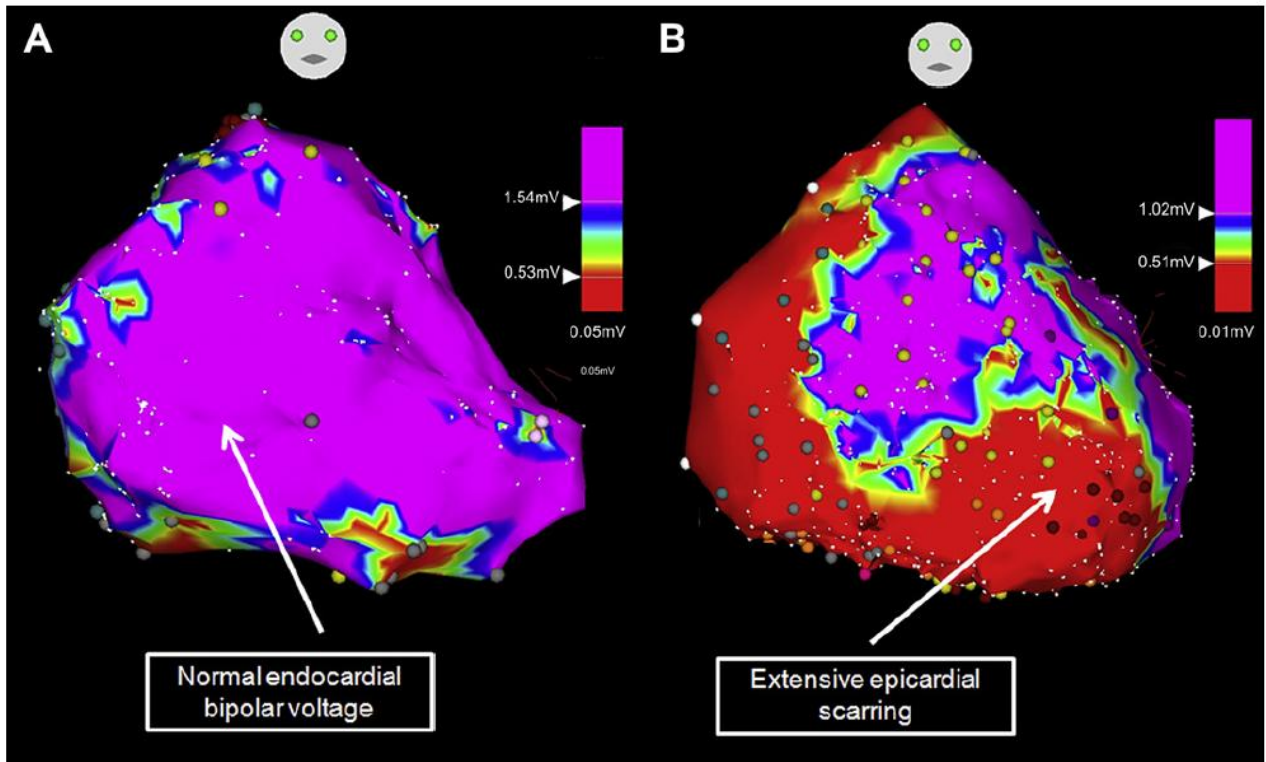
Garcia and colleagues (102) showed that most patients have a far more extensive electroanatomic substrate for VT here than they do on the RV endocardium (Figure 3). Preliminary data suggest that it may be possible to identify patients with this more-marked epicardial VT substrate by examining the unipolar endocardial voltage maps, as unipolar electrogram amplitude,

with its larger field of view, may be influenced by scar lying opposite to the endocardial recording surface (Figure 4). (103)

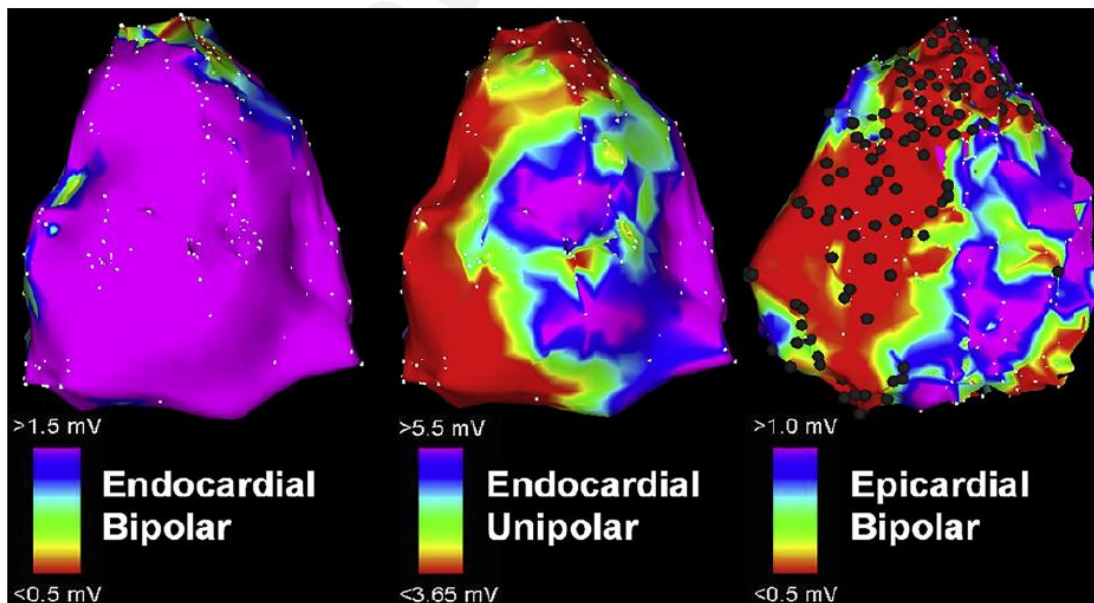


**Figure 2.** Endocardial electroanatomic substrate in ARVC. Typical distribution of endocardial RV low-voltage substrate in ARVC/D with periannular involvement.

Although the temporal progression of the disease process has long been considered inexorable and led to pessimistic views on the efficacy of catheter ablation, it is clear that this is not the case in many patients (Figure 5). Riley and colleagues (104) have performed detailed serial electroanatomic mapping in 9 patients who showed no change in their low-voltage, abnormal electrogram substrate over a mean of 5 years. This important study suggests that aggressive efforts at VT control should not be abandoned based on an assumption that disease progression will inevitably lead to future VT recurrence.

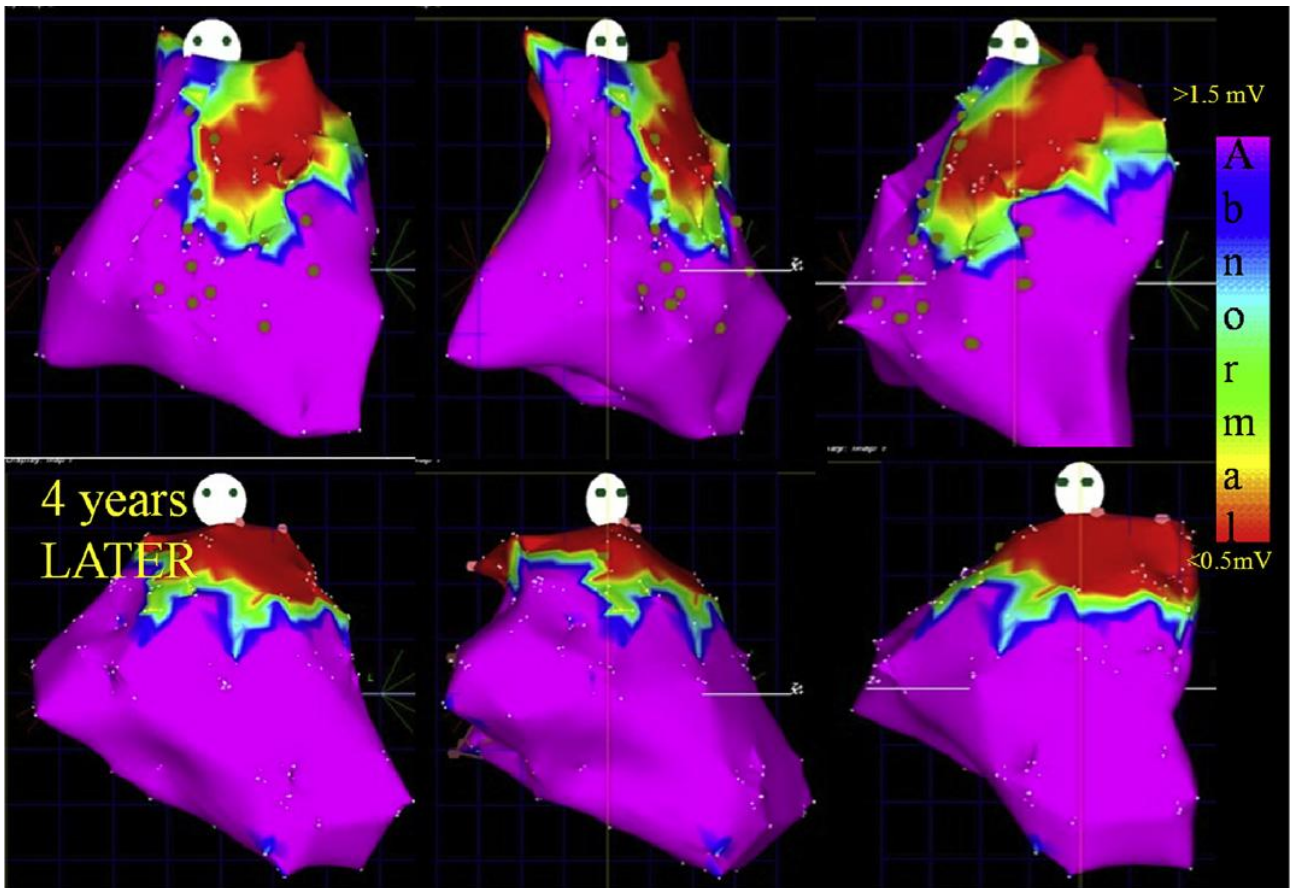


**Figure 3.** Fig. 6. Endocardial and epicardial VT substrate in ARVC. Electroanatomic substrate maps of a patient with ARVC/D and 8 inducible LBBB morphology VTs. Panel A displays the endocardial chamber geometry in the anteroposterior projection showing largely preserved endocardial voltages. The epicardial substrate map in panel B shows an extensive region of fractionated low-voltage potentials (bipolar peak-to-peak signal amplitude  $<1.0$  mV as reflected in the different color scale) involving the inferior and mid RV free wall and extending from the periannular region to the apex. Seven of this patient's VTs were mapped and ablated successfully on the epicardium (from Garcia FC, et al. *Circulation* 2009;120(5):366–75).



**Figure 4.** Unipolar endocardial low voltage as a marker of epicardial scar. Three substrate maps from a patient with ARVC are shown. Normal endocardial bipolar voltage is seen; however, there are widespread endocardial unipolar low-voltage zones, and these correlated with the extent and distribution of the bipolar epicardial substrate (from Polin G et al. *Heart Rhythm* 2009;6:S118).





**Figure 5.** Lack of progression of substrate in an patient with ARVC after 4 years. The endocardial substrate maps acquired 4 years apart in this patient show no significant progression in the size of the low-voltage zone. (Riley MP et al. Heart Rhythm 2008;5:S74).

### ***Pharmacologic Therapy***

Antiarrhythmic drug therapy (AD) is the first line treatment for well tolerated and not life-threatening ventricular arrhythmias in ARVC patients with low risk of sudden death. Prospective and randomized studies on AD in ARVC are not available. Patients are usually treated empirically by beta-blockers, class I (flecainide, propafenone) or class III (sotalol and amiodarone) Ads. Assessment of specific AD efficacy by follow-up studies is difficult because ARVC patients tend to have multiple arrhythmic events over time and drugs are often changed. The available evidence suggests that sotalol and amiodarone (alone or in combination with beta-blockers) are the most effective Ads with a relatively low proarrhythmic risk, although their ability to prevent SCD



remains to be proven. Corrado et al. (21,22) analyzed the outcome of 132 ARVC patients (93 males, 39 females, aged  $40\pm 15$  years) who received an ICD, capable of storing intracardiac electrocardiograms. Of 132 patients, 104 (79%) received concomitant AD therapy which consisted of sotalol (36%), amiodarone alone (8%), or in combination with beta-blockers (13%), beta-blockers (20%), and flecainide (2%). During a follow-up of  $39\pm 25$  months, 64 of 132 patients (48%) had appropriate ICD interventions; 53 of these 64 patients (83%) were taking AD therapy at the time of first ICD intervention, compared with 51 of 68 (75%) with no or inappropriate interventions ( $p=NS$ ). In addition, the incidence of VF/Vfl, which in all likelihood would have been fatal in the absence of the ICD, did not differ between patients who did and did not receive AD therapy (27% vs 18%;  $p=NS$ ) nor between patients treated with different AD, regardless of clinical presentation. These findings strongly suggest that the majority of life-saving ICD interventions in high risk patients occurred despite concomitant ADs and support the concept that AD therapy does not confer an adequate protection against SCD.

The largest series of pharmacologic therapy in ARVC is from Germany, first published in 1992 (105) and updated (106) in 2005. In the initial series, 81 patients with highly suspected or confirmed ARVC and nonsustained or sustained VT underwent a standardized electrophysiologic evaluation. Patients were brought to the electrophysiologic laboratory in an antiarrhythmic drug-free state, and programmed ventricular stimulation was performed. VT was inducible in 42 of these individuals and not inducible in 39. In the inducible group, the clinical arrhythmias was sustained VT in 93%, whereas 8% presented with nonsustained VT. In the noninducible group, only 20% presented with sustained VT, whereas 80% had nonsustained VT. After the initial ventricular stimulation, an antiarrhythmic agent was administered. Each group underwent serial antiarrhythmic drug testing composed of serial electrophysiologic studies in the inducible group and long-term cardiac monitoring in the noninducible group. Immediate efficacy was found in most patients, and they were discharged given the drug effective in preventing VT. Long-term follow-up was also reported with the end point of clinical tachycardia.

In the 42 inducible patients who underwent 174 drug tests, sotalol had the highest efficacy. In 26 of 38 patients given sotalol, the ventricular arrhythmia was not inducible for a success rate of 68%. Combinations of class I AD and sotalol had an efficacy of 20% (2 of 10). Combinations of class I and amiodarone had a success rate of 50% (2 of 4). Class Ia/b (1 of 18) and class Ic (3 of 25) were rarely effective. b-Blockers alone had no efficacy (0 of 7). Amiodarone alone had a success rate of only 15% (2 of 13). Similar results were observed in the noninducible group, with sotalol being effective in 83% of patients (29 of 35) and amiodarone in 25% (1 of 4). Class Ia/b (0 of 16) and class Ic (4 of 23) were rarely effective. However, b-blockers were effective in 30% (2 of 7) of patients. In the inducible group, 31 patients were discharged on pharmacologic therapy, including 25 with sotalol alone or sotalol in combination with type 1 AD. In a long-term follow-up of 34 months, there were no sudden deaths in the inducible group. Of 31 patients discharged on pharmacologic therapy, 3 (10%) had nonfatal recurrences of VT. In the noninducible tachycardia group, 33 of 39 patients were discharged on pharmacologic management, including 24 with sotalol. In a follow-up of 14 months, there were no sudden deaths, and 4 of 33 patients discharged on antiarrhythmic drugs had nonfatal relapses of VT. In studies in patients with coronary disease, tested sotalol was also efficacious, and there have been little published data that untested sotalol in any disease state prevents arrhythmias.<sup>1</sup> This group updated their experience in 2005, with 191 patients and 608 drug tests.<sup>3</sup> Sotalol at Q10 a dosage of 320–40 mg/d was the most effective drug resulting in a 68% overall efficacy. Combinations highly efficacious. Class I AD were efficacious only in a minority of patients (18%). In a small subset of patients thought to have triggered activity or autonomic abnormal automaticity, verapamil and b-blockers had efficacy rates of 44% and 25%; however, they were not likely to be successful in reentrant tachycardias. In long-term follow-up of this group of patients, those who had success with drug testing generally did well, with a much lower recurrence rate on a drug that was effective, versus those in whom no effective drug could be found.

Recently Marcus et al. (107) examined the efficacy of empiric AAs in a rigorously characterized cohort of ARVC patients. Of 108 patients in this registry, 95 had implantable defibrillators. This study was a prospectively enrolled cohort, and pharmacologic therapy, including b-blockers, antiarrhythmic drugs, and Q11 ICDs, was left to the discretion of the treating physician. Fifty-eight patients (61%) received betaadrenergic blocking agents, including atenolol, metoprolol, bisoprolol, and carvedilol. In a mean follow-up of 480 days, there were 235 clinically relevant ventricular arrhythmias observed in 32 patients. There was no clinically significant benefit of preventing VT or ventricular fibrillation with beta-blockade when compared with participants not taking antiarrhythmic drugs or b-blockers. However, there was a trend in the reduction in ICD shocks, although this result did not reach statistical significance. Atenolol potentially showed the greatest benefit in this study, although there were too few patients on the individual b-blockers class II to draw too many conclusions from this subanalysis. Thirty-eight patients were treated with sotalol, with a mean dose of 240 mg/d. In a mean of 644 days, the hazard ratios either showed no effect or favored a detrimental effect of sotalol with regards to any clinically relevant arrhythmia, any ICD shock, first clinically relevant arrhythmia, and first ICD shock. However, the mean tachycardia cycle length of those with VT was significantly greater in those taking sotalol (311 vs 292 ms). Patients who received the upper quartile dose of sotalol ( $\geq 320$  mg/d) had a worse outcome compared with individuals not in the upper quartile of sotalol.<sup>4</sup> Finally, in this study, 10 patients given amiodarone were followed up for a median of 545 days. When taking amiodarone, patients had a 75% lower risk of any clinically relevant ventricular arrhythmia compared with all other patients. However, this study, as well as others on antiarrhythmic drugs and b-blockers in patients with ARVC, should be interpreted with caution because clinical indications for b-blockers, sotalol, and amiodarone were present and it is likely that there was a selection bias that influenced outcomes. This selection bias could explain the worsened results with sotalol but not the reduction in arrhythmias with amiodarone. In addition, amiodarone is widely considered the most efficacious antiarrhythmic drug in other disease states.

The current data indicate that asymptomatic ARVC patients do not require any prophylactic treatment. They should be followed-up on a regular basis by non-invasive cardiac evaluations for early identification of warning symptoms and demonstrations of disease progression or ventricular arrhythmias. Importantly, asymptomatic and healthy gene carriers should be prudently advised to refrain from participating in physical exercise and sport activity, which are associated with an increased risk of ventricular arrhythmias and disease worsening. Whether prophylactic beta-blockers therapy may reduce the rate of ARVC progression and arrhythmic complications in asymptomatic patients and gene carriers remains to be proven.

In patients with RV or biventricular heart failure, treatment consists of diuretics, angiotensin converting enzyme (ACE) inhibitors and digitalis, as well as anticoagulants.

### ***Preparticipation Athletic Screening***

#### ***Sudden Cardiac Death and Sports***

Arrhythmogenic right ventricular cardiomyopathy/dysplasia is an inherited heart muscle disease characterized pathologically by RV fibrofatty myocardial replacement and clinically by ventricular electric instability, which may lead to cardiac arrest from VF, mostly in young people and athletes. (15,18,35) ARVC shows a propensity for life-threatening ventricular arrhythmias during physical exercise, and participation in competitive athletics has been associated with an increased risk for sudden cardiac death (SCD). (108-116) In addition, physical sport activity has been implicated as a factor promoting acceleration of disease progression. Identification of affected athletes by preparticipation screening has proved to result in mortality reduction during sports activity. (108-116) This article examines the role of ARVC in causing SCD in young competitive athletes and addresses prevention strategy based on identification of affected athletes at preparticipation screening.

Although sudden death during sport is a rare event, it has a devastating effect on the community because it occurs in apparently healthy individuals and assumes great visibility through the news media because of the high public profile of competitive athletes. The frequency of sudden death in young athletes during organized competitive sports varies in the different series reported in the literature. A retrospective analysis in the United States has estimated the prevalence of fatal events in high school and college athletes (aged 12–24 years) to be less than 1 in 100,000 per year, whereas a prospective populationbased study in Italy reported a 3 times greater incidence among competitive athletes aged 12 to 35 years. (108-116). The vast majority of athletes who die suddenly have underlying structural heart diseases, which provide a substrate for VF. SCD is usually the result of an interaction between transient acute abnormalities (trigger) and structural cardiovascular abnormalities (substrate). Triggers of SCD in young competitive athletes include exerciserelated sympathetic stimulation, abrupt hemodynamic changes, and acute myocardial ischemia leading to life-threatening ventricular arrhythmias. The causes of SCD reflect the age of the participants. Although atherosclerotic coronary artery disease accounts for the vast majority of fatalities in adults (aged  $\geq 35$  years), (108-116) in younger athletes there is a broad spectrum of cardiovascular substrates (including congenital and inherited heart disorders) (Box 1). Cardiomyopathies have been consistently implicated as the leading cause of sports-related cardiac arrest in the young, with hypertrophic cardiomyopathy accounting for more than one-third of fatal cases in the United States and ARVC for approximately one-fourth in the Veneto region of Italy.

The incidence of sudden death from ARVC in athletes was estimated to be 0.5 per 100,000 persons per year (Figure 1). Sudden death victims with ARVC were all men with a mean age of  $22.6 \pm 4$  years. (111) postmortem, the hallmark lesion of the disease was the transmural replacement of the RV myocardium by fibrofatty tissue. Hearts demonstrated massive regional or diffuse fibrofatty infiltration, parchmentlike translucence of the RV free wall, and mild to moderate RV dilatation, together with aneurysmal dilatations of the posterobasal, apical, and outflow tract regions. These RV pathologic features allowed differential diagnosis with training-induced RV adaptation

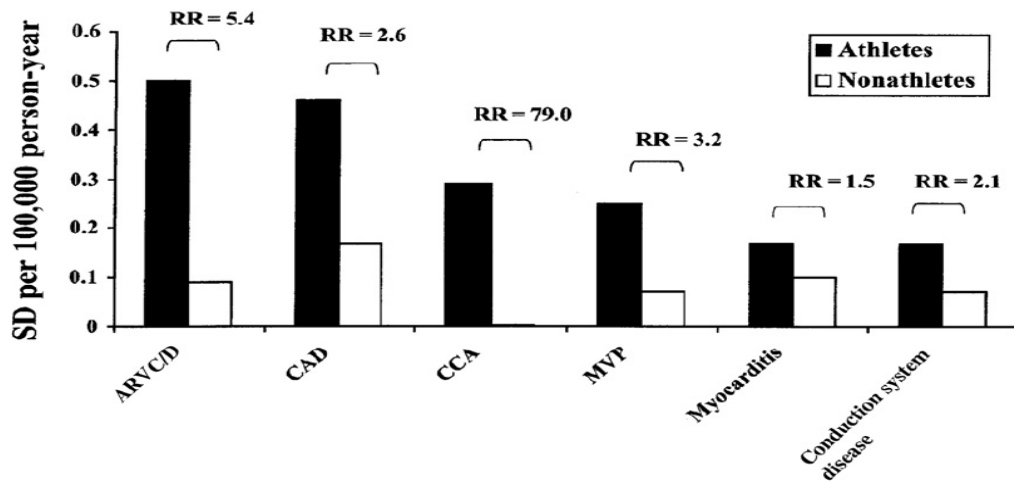
(athlete's heart), usually consisting of global RV enlargement without regional dilatation/dysfunction. Histologically, fibrofatty infiltration is usually associated with focal myocardial necrosis and patchy inflammatory infiltrates. Fibrofatty scar and aneurysms are potential sources of life-threatening ventricular arrhythmias. The histopathologic arrangement of the surviving myocardium embedded in the replacing fibrofatty tissue may lead to inhomogeneous intraventricular conduction predisposing to reentrant mechanisms. Life-threatening ventricular arrhythmias may occur either during the hot phase of myocyte death as abrupt VF or later in the form of scar-related macroreentrant ventricular tachycardia. (21) The risk of sudden death from ARVC has been estimated to be 5.4 times greater during competitive sports than during sedentary activity (Figure 1). Several reasons may explain such a propensity of ARVC to precipitate effort-dependent sudden cardiac arrest. Physical exercise acutely increases the RV afterload and causes cavity enlargement, which in turn may elicit ventricular arrhythmias by stretching the diseased RV myocardium.

Although ARVC has been demonstrated to be the leading cause of SCD in athletes of Veneto, Italy, previous studies in the United States showed a higher prevalence of other pathologic substrates such as hypertrophic cardiomyopathy, anomalous coronary arteries, and myocarditis. (108-116) This discrepancy may be explained by several factors. There have been no previous investigations, such as the Juvenile Sudden Death Research Project in the Veneto region of Italy, that have prospectively investigated a consecutive series of sudden death in young people occurring in a well-defined geographic area with a homogeneous ethnic group. (108-116), the previously reported causes in the United States may have been influenced by the unavoidable limitations in patient selection because of retrospective analysis. Moreover, in other large studies, the autopsies were usually performed by different examiners, including local pathologists and medical examiners. In the Italian study, to obtain a higher level of confidence in the results, morphologic examination of all hearts was performed according to a standard protocol by the same group of experienced cardiovascular pathologists. ARVC is rarely associated with cardiomegaly and usually spares the

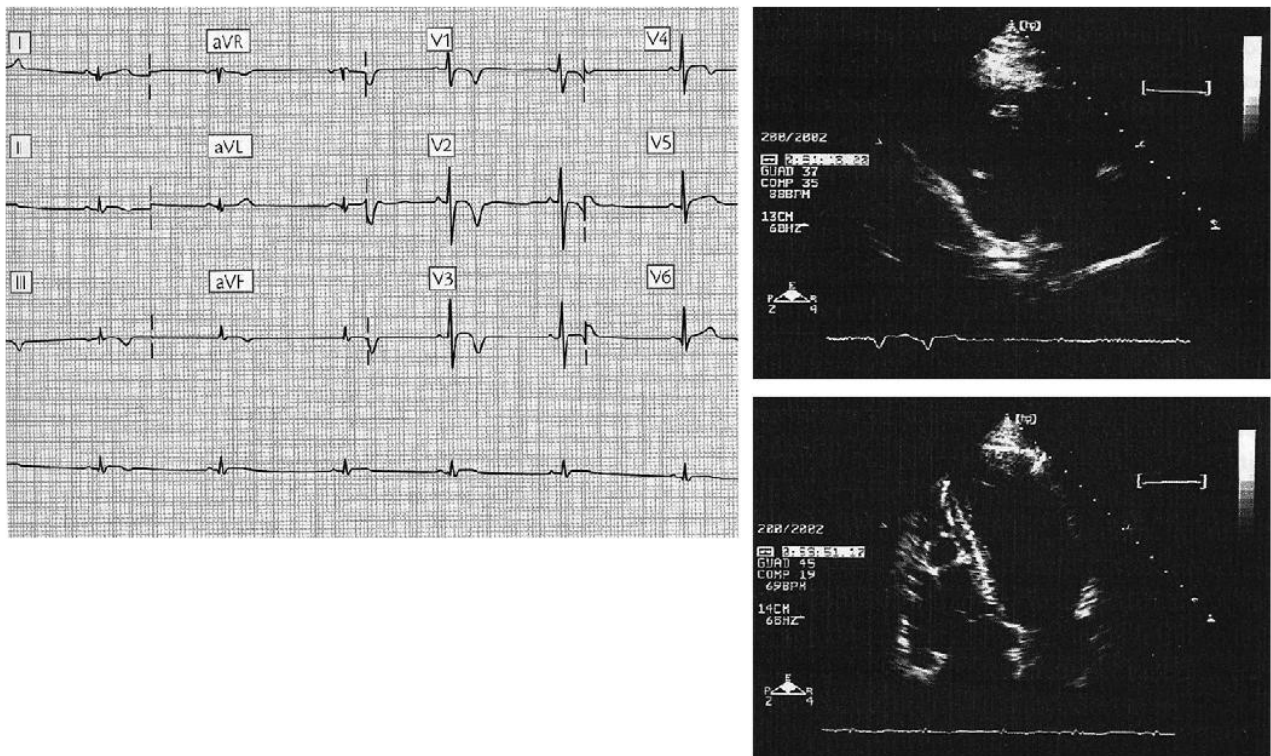
left ventricle so that affected hearts may be erroneously diagnosed as normal hearts. (15,18,35) Therefore, several cases of SCD in young people and athletes, in which the routine pathologic examination discloses a normal heart, may, in fact, be due to an unrecognized ARVC. The high incidence of ARVC in Veneto may be because of a genetic factor in the population of the northeastern Italy, although ARVC can no longer be considered as a peculiar Venetian disease because there is growing evidence that it is ubiquitous, it is still largely underdiagnosed both clinically and at postmortem investigation, and it accounts for significant arrhythmic morbidity and mortality worldwide. (15,18,35)

#### *Clinical Profile of Athletes Dying Suddenly from ARVC*

Early identification of athletes with ARVC plays a crucial role in the prevention of SCD during sport. The most frequent clinical manifestations of the disease consist of electrocardiographic (ECG) depolarization/repolarization changes mostly localized to right precordial leads, global and/or regional morphologic and functional alterations of the RV, and arrhythmias of RV origin (Figure 2). (15,18,35) The disease should be suspected even in asymptomatic individuals on the basis of ECG abnormalities and ventricular arrhythmias. (15,18,35) Ultimately, the diagnosis relies on visualization of morphofunctional RV abnormalities by imaging techniques (such as echocardiography, angiography, and cardiac magnetic resonance) and, in selected cases, by histopathologic demonstration of fibrofatty substitution at endomyocardial biopsy. (26,27)



**Figure 1.** Incidence and relative risk (RR) of sudden death from major cardiovascular causes among young athletes and nonathletes. ARVC, arrhythmogenic RV cardiomyopathy/dysplasia; CAD, coronary artery disease; CCA, congenital coronary artery anomalies; MVP, mitral valve prolapse. (Modified from Corrado D et al. *J Am Coll Cardiol* 2003;42:1961).



**Figure 2.** ECG and echocardiographic findings in an asymptomatic athlete diagnosed with ARVC. The athlete was referred for further evaluation because of ECG abnormalities found at preparticipation evaluation, which consisted of inverted T-waves in the inferior and anteroseptal leads and low QRS voltages in the peripheral leads (A). ARVC was suspected at echocardiographic examination, showing mild RV dilatation, basal and apical wall motion abnormalities with diastolic bulging of the RV inflow tract, and trabecular disarrangement. (B) The RV long-axis view. (C) The 4-chamber view. Final diagnosis was achieved by cardiac magnetic resonance (not shown). (Modified from Corrado D et al. *Sports and heart disease*. In: Camm J, Luscher TF, Serruys PW, editors. *The ESC textbook of cardiovascular medicine*. New York: Oxford University Press; 2009. p. 1215–37).

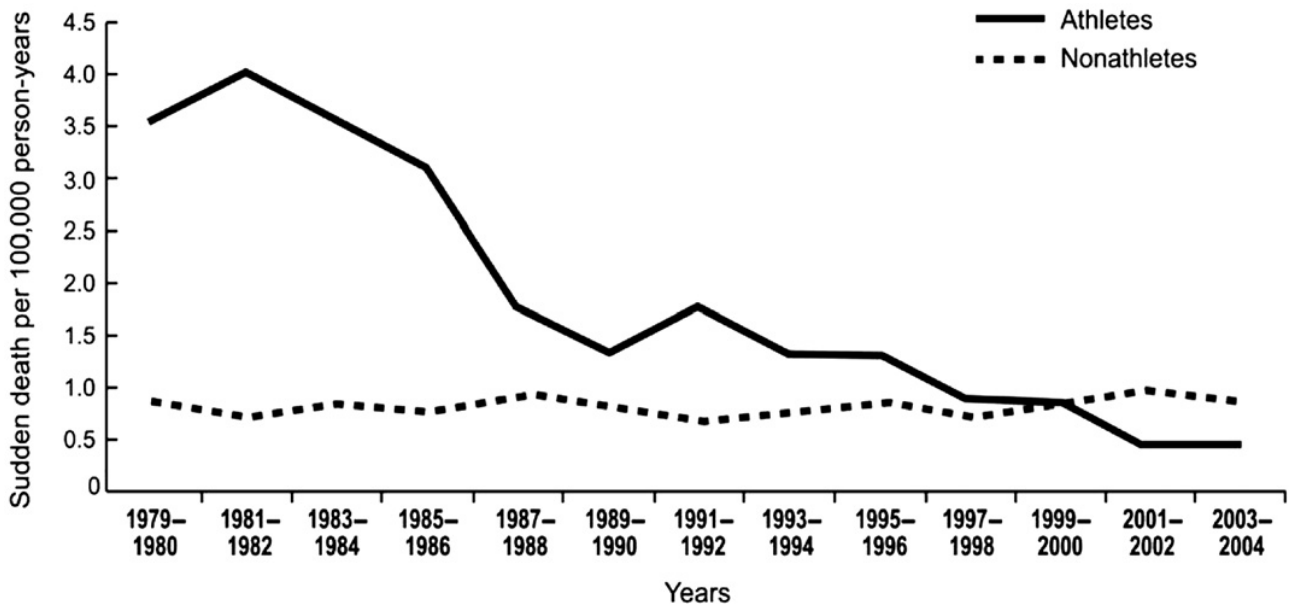


### Preparticipation Screening and Prevention of SCD

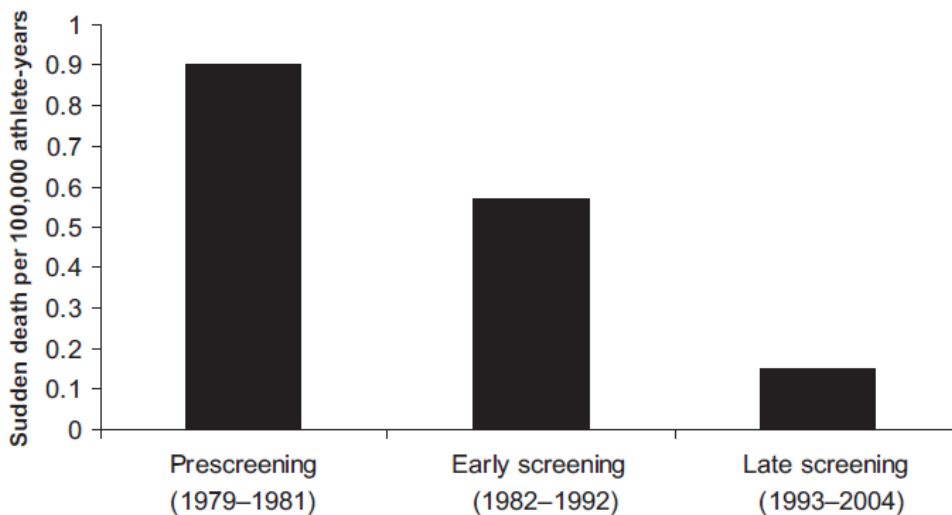
For more than 20 years, a systematic preparticipation screening (PPS), based on 12-lead ECG, in addition to history and physical examination, has been the practice in Italy. (108-118) This screening strategy has been proved to be effective in the identification of athletes with previously undiagnosed hypertrophic cardiomyopathy, thanks to the high sensitivity (up to 95%) of 12-lead ECG for suspicion/detection of this condition in otherwise asymptomatic athletes. Moreover, during long-term follow-up, no deaths were recorded among these disqualified athletes with hypertrophic cardiomyopathy, suggesting that restriction from competition may reduce the risk of sudden death.

A time trend analysis of the incidence of SCD in young competitive athletes aged 12 to 35 years in the Veneto region of Italy between 1979 and 2004 has provided compelling evidence that ECG screening is a lifesaving strategy. (87) The long term effect of the Italian screening program on prevention of SCD in athletes was assessed by comparing temporal trends in SCD among screened athletes and unscreened nonathletes. The assessed intervals were prescreening (1979–1981), early screening (1982–1992), and late screening (1993–2004). The analysis demonstrated a sharp decline of SCD in athletes after the introduction of the nationwide screening program in 1982 (Figure 3). There were 55 cases of SCD in screened athletes (1.9 deaths per 100,000 person-years) and 265 deaths in unscreened nonathletes (0.79 deaths per 100,000 person-years). The annual incidence of SCD in athletes decreased by 89%, from 3.6 per 100,000 person-years during the prescreening period to 0.4 per 100,000 person-years during the late screening period. By comparison, the incidence of SCD in the unscreened nonathletic population of the same age did not change significantly over that time. Most of the mortality reduction was attributable to fewer deaths from hypertrophic cardiomyopathy and ARVC (Figure 4). A parallel analysis of the causes of disqualifications from competitive sports at the Center for Sports Medicine in the Padua country area showed that the proportion of athletes identified and disqualified for cardiomyopathies doubled from the early to the late screening period. This observation indicates that mortality reduction was a

reflection of a lower incidence of SCD from cardiomyopathies, as a result of increasing identification over time of affected athletes at preparticipation screening.



**Figure 3.** Annual incidence rates of SCD per 100,000 person-years among screened competitive athletes and unscreened nonathletes aged 12 to 35 years in Veneto, Italy, from 1979 to 2004. (Modified from Corrado D et al. JAMA 2006;296:1596).



**Figure 4.** Average annual incidence rates of SCD from ARVC among young competitive athletes of the Veneto, Italy, before and after implementation of systematic preparticipation screening. Death rates from AC declined from 0.90 per 100,000 person-years in the prescreening period (1979-1981) to 0.15 per 100,000 in the late screening period (1993-2004) (relative risk, 0.16; 95% confidence interval, 0.03-1.41; P 5 .02).

### Electrocardiographic T-Wave Inversion and Prevalence of Cardiomyopathy

ECG changes are common in athletes and usually reflect the structural and electric remodeling of the heart as an adaptation to regular physical exercise (athlete's heart). However, T-wave inversion may be the expression of an underlying heart disease capable of causing SCD during sports. (119-122).

#### T-Wave Inversion

The presence of T-wave inversion beyond lead V1 is a typical ARVC feature with a sensitivity of 87% among patients fulfilling the International Task Force criteria.(20) Because early clinical manifestation of ARVC usually occurs after puberty, the persistence of right precordial T-wave inversion (beyond V1) in the postpubertal age raises the problem of a differential diagnosis between a benign juvenile pattern of repolarisation and a developing ARVC. This is particularly important in young competitive athletes. The concern arises as to the specificity of the juvenile T-wave pattern for ARVC because it has been reported to occur in a sizeable proportion of healthy children. It is unclear what the prevalence of the juvenile T-wave pattern is in a child who has a normal heart and how often the persistence of the juvenile pattern of repolarization is associated with a cardiomyopathy. The traditional idea that ST-T-wave abnormalities are more common in trained athletes than in a sedentary population may be explained by the high prevalence of early repolarization changes in the athlete's heart, with J-point-ST segment elevation often followed by a terminal negative T-wave, which simulates T-wave inversion. (123)

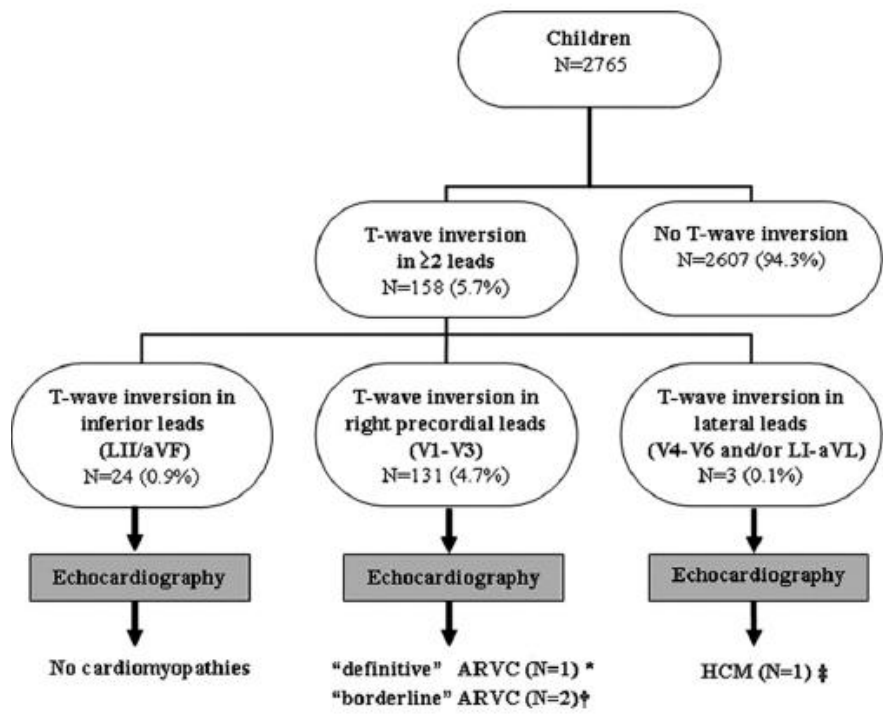
Recently, Migliore et al (124) reported that the prevalence of T-wave is 5.7% in a large cohort of 2765 children and was localized in the right precordial leads in 4.7%. This relatively greater prevalence of T-wave abnormalities is explained by the expected higher rate of physiological right precordial T-wave inversion in our study population, which included a sizeable proportion of prepubertal children. In this study the prevalence of right precordial T-wave inversion decreased significantly with increasing age (8.4% in those <14 years of age compared with 1.7% of

children  $\geq 14$  years of age), complete pubertal development, and greater BMI. Incomplete pubertal development was the only independent predictor of right precordial T-wave inversion. Moreover, in the large series of children reported by Migliore et al, T-wave inversion in the inferior-lateral leads is an uncommon finding, not exceeding 1% (0.9% in inferior leads and 0.1% in lateral leads). This low prevalence of T-wave inversion in inferolateral leads was similar to that (1.5%) previously reported by Papadakis et al. (122) Unlike right precordial T-wave inversion, Migliore et al. did not find any correlation between inferolateral T-wave inversion and sex, age, anthropometric characteristic, and pubertal development (124).

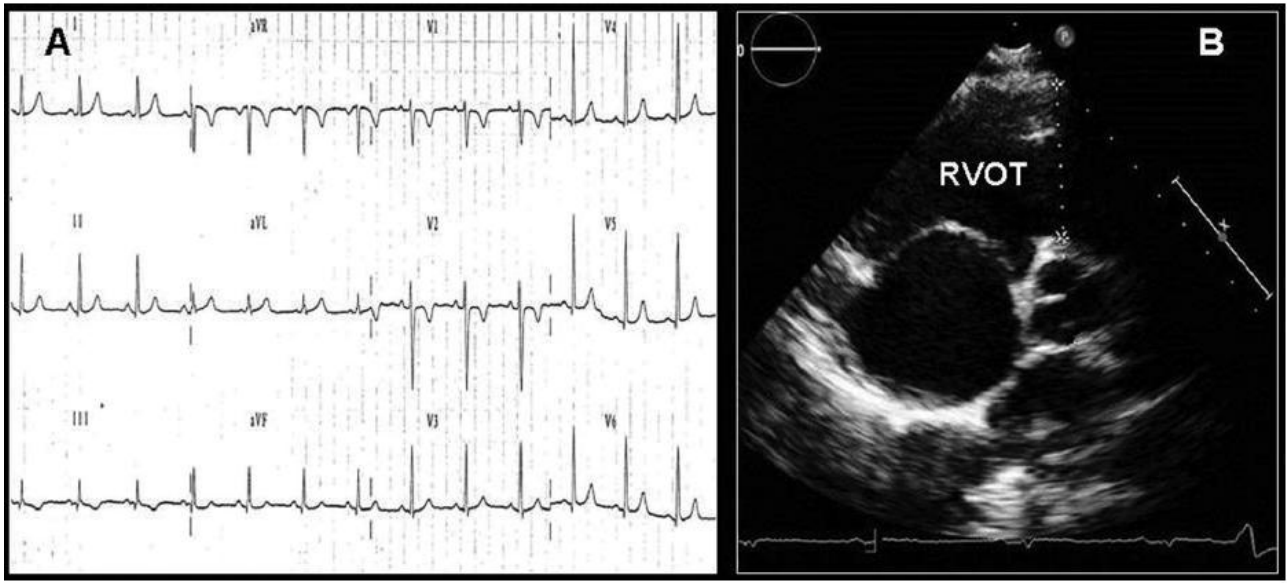#### T-Wave Inversion and Cardiomyopathy

In the Papadakis et al (122) study, the prevalence of right precordial T-wave inversion beyond V2 in athletes  $\geq 16$  years of age was 0.1%, and despite intensive cardiovascular evaluation, no athletes were diagnosed with cardiomyopathy. Migliore et al (124) confirmed and extended these previous observations by showing that T-wave inversion in children with complete pubertal development, although uncommon, may reflect an early cardiomyopathy. Indeed, a cardiomyopathy was diagnosed in 4 children with T-wave inversion: ARVC in 3 with T-wave inversion in the right precordial leads and HCM in 1 with T-wave inversion in the lateral leads (Figure 5,6,7). The discrepancy between the previous and present studies may be explained by the differences in the study population and study design. Migliore et al included a larger cohort of 2765 children who had a greater likelihood to be affected by cardiomyopathies, the estimated prevalences of which in the general population are 1:500 for HCM and 1:2000 for ARVC. Although the role of genetic factors in the population of the Veneto region of Italy cannot be excluded, the relatively high prevalence of ARVC in the Migliore's study is reasonably explained by the use of revised International Task Force criteria for ARVC diagnosis, which have increased the sensitivity for early/minor ARVC variants, as indicated by the identification of 2 borderline ARVC cases that would have been missed by the old International Task Force criteria.<sup>43</sup> Migliore et al (124) reported a relatively low

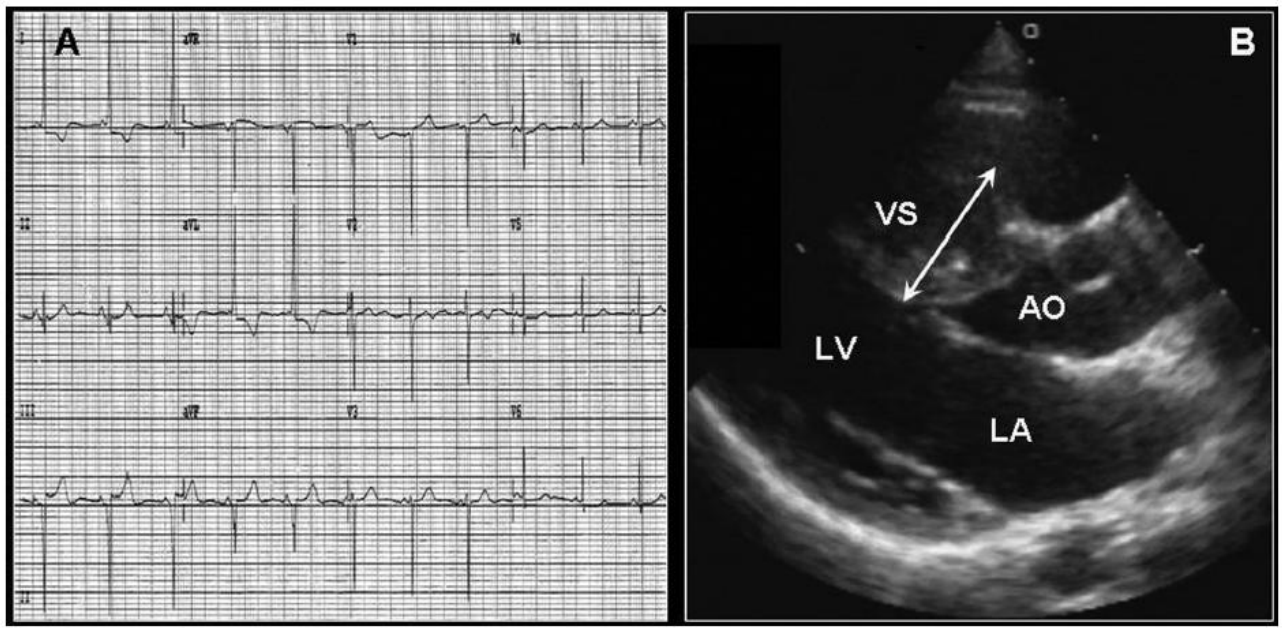
prevalence of HCM in our study population of children with a mean age of ~14 years. This may be explained by the fact that HCM is an inherited heart muscle disease with phenotypic manifestations that are age dependent and occur during adolescence in association with accelerated body growth, with morphological expression usually completed during young adulthood when physical maturity is achieved. Therefore, screening of children is expected to have a low sensitivity for the detection of HCM, which usually develops during a later period of life.



**Figure 5.** Prevalence and distribution of T-wave inversion and underlying cardiomyopathy in the overall study population. \*Male individual 14 years of age with a complete pubertal development. †One female individual 15 years of age and 1 male individual 17 years of age, both with complete pubertal development. ‡Male individual 15 years of age with complete pubertal development. (Modified from Migliore et al. *Circulation* 2012;125:529-538).



**Figure 6.** ECG and echocardiographic findings in a 14-year-old male soccer player with arrhythmogenic right ventricular cardiomyopathy. **A**, ECG shows T-wave inversion in right precordial leads (V1–V2). **B**, Echocardiographic examination reveals RV dilatation (RV outflow tract [RVOT] diameter of 39 mm on end-diastolic parasternal short-axis view) and RV dysfunction (akinesia of RVOT and posterobasal, subtricuspid regions; not shown). (Modified from Migliore et al. *Circulation* 2012;125:529-538).



**Figure 7.** ECG and echocardiographic findings in a 15-year-old male soccer player with hypertrophic cardiomyopathy. **A**, ECG shows T-wave inversion in lateral leads (I and aVL) and pathological Q wave (duration  $>25\%$  of the height of the ensuing R wave) in inferior leads (III and aVF). **B**, Echocardiogram shows an asymmetrical left ventricular hypertrophy with a maximal septal thickness of 31 mm. VS indicates ventricular septum; LV, left ventricle; LA, left atrium; and AO, aorta. (Modified from Migliore et al. *Circulation* 2012;125:529-538).

### Implications for Preparticipation Screening

Migliore et al showed that echocardiographic evaluation of children with persistence of T-wave inversion beyond puberty on PPS allowed identification of ARVC and HCM, which are recognized leading causes of SCD in young competitive athletes. (124) These results have significant implications for PPS, clinical diagnosis, and risk stratification for the prevention of SCD. According to Migliore et al findings, echocardiographic study to exclude an underlying cardiomyopathy is warranted for athletes with postpubertal persistence of T-wave inversion in  $\geq 2$  contiguous leads on resting ECG regardless of age. In the Migliore's study (124), PPS led to identification of additional ECG-detectable cardiovascular diseases capable of causing SCD such as Wolf-Parkinson-White syndrome, long- and short-QT syndrome, and Brugada syndrome. These conditions have been implicated in most SCDs occurring without postmortem evidence of structural heart abnormalities.<sup>46</sup> Unlike cardiomyopathies, most cardiac ion channel disorders have been discovered only recently, so diagnosis at PPS is being increased over time, and its impact on mortality will be assessed in the near future.

The ECG is traditionally considered a nonspecific and non-cost-effective tool for cardiovascular evaluation of athletes because of the presumed high level of false-positive results. This concept was based on a few studies of small and selected series of highly trained athletes from a limited number of sports disciplines. In the Migliore's study, among 2765 children undergoing PPS, 229 (8%) were referred for additional testing because of positive findings such as positive medical history, abnormal physical examination, or ECG abnormalities. Further clinical workup led to the identification of heart diseases in 33 children (1.2%). Hence, the estimated percentage of false positives (ie, athletes with abnormal PPS findings in the absence of heart disease) was 7%. These figures are in keeping with those from a previous prospective Italian study of 42 386 athletes undergoing PPS, which reported a 9% prevalence of athletes with positive findings requiring further examination and a 2% prevalence of total cardiovascular disorders (7% of false-positive results). (87) It is noteworthy that if we had not further investigated athletes with right precordial T-wave

inversion owing to incomplete pubertal development, the proportion of false-positives would have been reduced to 3.3% without altering the screening power for detection of cardiomyopathies and thus resulting in a more favourable screening cost-effectiveness.



## **Introduction: Electroanatomic Voltage Mapping**

### ***Introduction***

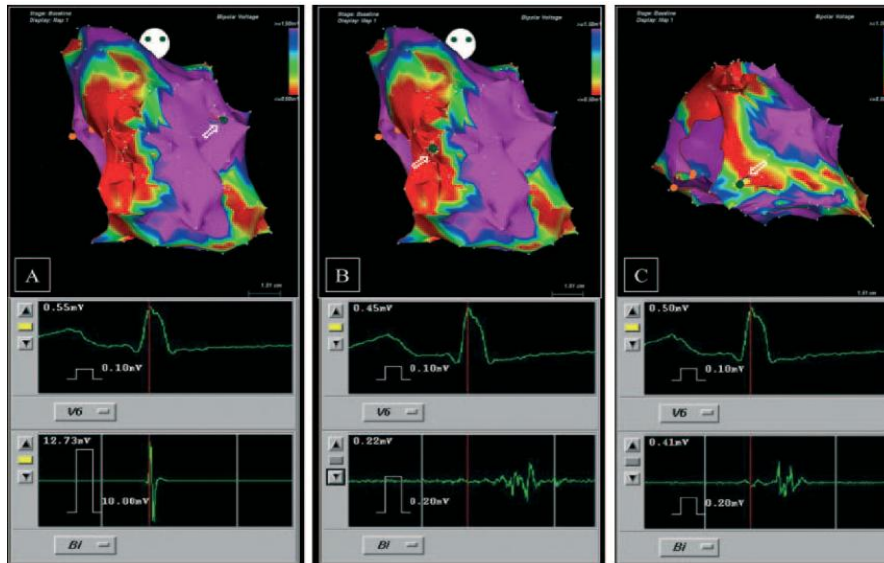
The finding that significant loss of myocardium results in the recording of low-amplitude, fractionated endocardial electrograms has been well established in patients with post-infarction LV scar by intraoperative mapping, conventional endocardial mapping, and 3-D electroanatomic mapping technique. Similar findings have been reported in patients with ARVC, in whom 3-D electroanatomic voltage mapping by CARTO may differentiate RV scar regions from healthy myocardium. (125-133)

The hallmark pathologic lesion of ARVC is a transmural loss of the myocardium with replacement by fibrofatty tissue of the RV free wall reaching the endocardium. The myocardial atrophy accounts for variable degree of RV wall thinning, with areas so thin as to appear completely devoid of muscle at transillumination. 3-D electroanatomic voltage mapping has the ability to identify areas of myocardial atrophy and fibrofatty substitution by recording and spatially associating low-amplitude electrograms to generate three-dimensional electroanatomic map of the RV chamber. The technique has the potential to accurately identify the presence, location and extent of the pathologic substrate of ARVC by demonstration of low-voltage regions, i.e. electroanatomic scars (132,133). In ARVC patients, RV electroanatomic scars have been demonstrated to correspond to areas of myocardial depletion and correlate with the histopathologic finding of myocyte loss and fibrofatty replacement at routine EMB, with samples obtained at the junction between the ventricular septum and the anterior right ventricular free wall. (132)

Furthermore, by assessing the electrical (rather than the mechanical) consequences of loss of RV myocardium voltage mapping may obviate limitations in RV wall motion analysis by traditional imaging techniques such as echocardiography and angiography and may increase sensitivity for detecting otherwise concealed ARVC myocardial lesions. (132-133)

## ***Methods and Equipment***

Three-dimensional electroanatomic voltage mapping technique is performed using the CARTO system (Biosense-Webster) (125-133). In brief, the magnetic mapping system includes a magnetic sensor in the catheter tip that can be localized in 3D space using the ultralow magnetic field generators placed under the fluoroscopic table. A 7F Navi-Star catheter, with a 4-mm distal tip electrode and a 2-mm ring electrode with an interelectrode distance of 1 mm, is introduced into the RV under fluoroscopic guidance and used as the mapping/ablation catheter during sinus rhythm. The catheter is placed at multiple sites on the endocardial surface to record bipolar and/or unipolar electrograms from RV inflow, anterior free wall, apex and outflow. Bipolar electrogram signals are analyzed with regard to amplitude, duration, relation to the surface QRS, and presence of multiple components. Complete endocardial maps are obtained in all patients to ensure reconstruction of a 3-D geometry of the RV chamber and to identify regions of scar or abnormal myocardium. Regions showing low-amplitude electrograms are mapped with greater point density to delineate the extent and borders of “electroanatomic scar” areas. Bipolar voltage reference for normal and abnormal myocardium are based on values previously validated in both intraoperative and catheter mapping studies (125-133). Electroanatomic scar” area is defined as an area  $\geq 1$  cm squared including at least 3 adjacent points with bipolar signal amplitude  $<0.5$  mV (25). The color display for depicting normal and abnormal voltage myocardium ranges from “red” representing “electroanatomic scar tissue” (amplitude  $<0.5$  mV) to “purple” representing “electroanatomic normal tissue” (amplitude  $\geq 1.5$  mV). Intermediate colors represent the “electroanatomic border zone” (signal amplitudes between 0.5 and 1.5 mV) (Figure 1).



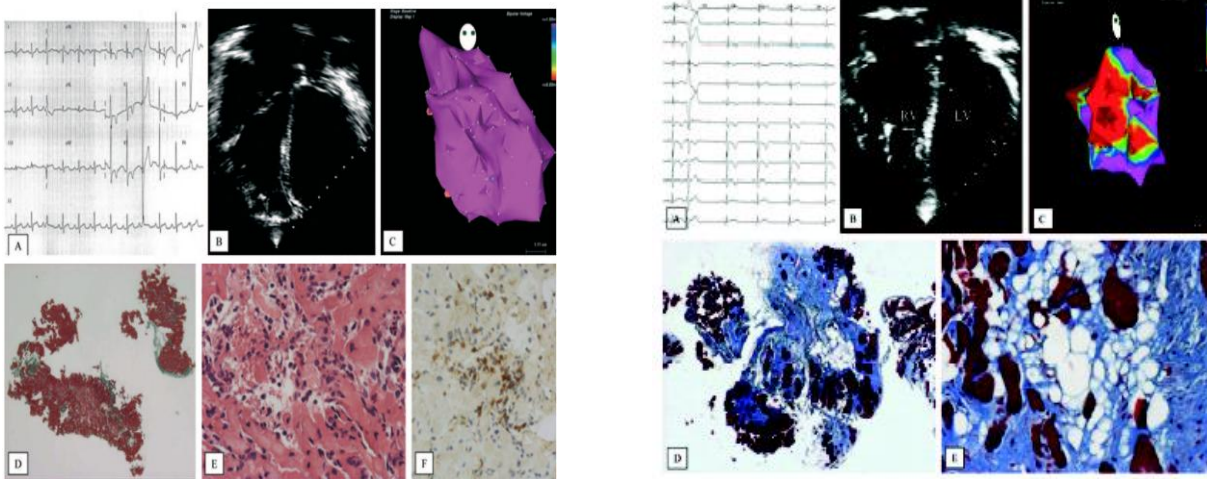
**Figure 1.** Abnormal 3D electroanatomic RV voltage map in both anteroposterior (A and B) and bottom (C) views, with examples of electric signals sampled from within normal and low-amplitude RV areas in the same patient with ARVC. Voltages are color coded according to corresponding color bars: purple represents signal amplitudes  $>1.5$  mV (electroanatomic normal myocardium); red,  $<0.5$  mV (electroanatomic scar tissue); and the range between purple and red, 0.5 to 1.5 mV (electroanatomic border zone). As indicated by the catheter tip (arrows), normal voltage electrogram sampled from the anterolateral region is sharp, biphasic deflection with large amplitude and short duration (A). By comparison, low-voltage electrograms recorded from anterior and inferobasal regions are fragmented with prolonged duration and late activation.

### *Clinical results in ARVC*

A preliminary study by Boulos et al. (131) reported on a series of 7 patients with ARVC, in whom electroanatomic voltage mapping accurately identified RV “dysplastic” regions (24). The authors found a concordance between voltage mapping results and echocardiographic or cardiac magnetic resonance findings in all studied patients.

Corrado et al. (132) tested the hypothesis that characterization of the RV wall by electroanatomic voltage mapping increases the accuracy for diagnosing ARVC in a consecutive series of patients fulfilling non-invasive Task Force criteria (Figure 2). Thirty-one consecutive patients (22 males and 9 females, aged  $30.8 \pm 7$  years) who fulfilled the criteria of the Task Force of the European Society of Cardiology and International Society and Federation of Cardiology (ESC/ISFC) for ARVC diagnosis after “non-invasive” clinical evaluation, underwent further “invasive” study including RV electroanatomic voltage mapping and EMB to validate the

diagnosis. Multiple RV endocardial, bipolar electrograms ( $175\pm 23$ ) were sampled during sinus rhythm. Twenty patients (Group A, 65%) had an abnormal RV electroanatomic voltage mapping showing one or more areas (mean  $2.25\pm 0.7$ ) with low voltage values (bipolar electrogram amplitude  $<0.5$  mV), surrounded by a border zone (0.5-1.5 mV) which merged into normal myocardium ( $>1.5$  mV). Low voltage electrograms appeared fractionated with significantly prolonged duration and delayed activation. In 11 patients (Group B, 35%) electroanatomic voltage mapping was normal, with preserved electrogram voltage ( $4.4\pm 0.7$  mV) and duration ( $37.2\pm 0.9$  ms) throughout the RV. Low-voltage areas in patients from Group A corresponded to echocardiographic/angiographic RV wall motion abnormalities and were significantly associated with myocyte loss and fibrofatty replacement at EMB ( $p<0.0001$ ) and familial ARVC ( $p<0.0001$ ). Patients from Group B had a sporadic disease and histopathologic evidence of inflammatory cardiomyopathy ( $p<0.0001$ ). During the time interval from onset of symptoms to the invasive study (mean 3.4 years), 11 patients (55%) with electroanatomic low-voltage regions received an ICD due to life-threatening ventricular arrhythmias, whereas all but one patient with normal voltage map remained stable on antiarrhythmic drug therapy ( $p=0.02$ ). These results indicate that 3-D electroanatomic voltage mapping may enhance accuracy for diagnosing ARVC by demonstrating low-voltage areas, which are associated with fibrofatty myocardial replacement, and by identifying a subset of patients who fulfil ESC/ISFC Task Force diagnostic criteria, but show a preserved electrogram voltage. This subset appears to have an inflammatory cardiomyopathy mimicking ARVC and a better arrhythmic outcome.



**Figure 2.** Noninvasive and invasive findings in a representative patient with abnormal RV electroanatomic voltage map. A, Twelve-lead ECG showing inverted T waves from V1 to V4 and a premature ventricular beat with a left bundle branch block/superior axis morphology. B, Two-dimensional echocardiographic apical view showing severe RV dilatation. C, Right anterior oblique view of RV bipolar voltage map showing low-voltage values (red indicates  $<0.5$  mV) in anteroinfundibular, inferobasal, and apical regions. D, EMB sample showing massive myocardial atrophy and fibrofatty replacement (trichrome; magnification x6). E, Close-up showing residual myocytes entrapped within fibrous and fatty tissue (trichrome; magnification x40) (From Corrado et al. *Circulation*. 2005;111:3042-3050).

### ***Pathophysiologic and Clinical Implications***

The study by Corrado et al. demonstrated that electroanatomic low-amplitude areas were significantly associated with the histopathologic finding of myocyte loss and fibrofatty replacement at EMB, thus confirming that RV loss of voltage reflects the replacement of action potential-generating myocardial tissue with electrically silent fibrofatty tissue (132). Moreover, there was a concordance between the presence and location of RV low voltage areas identified by electroanatomic map and akinetic/dyskinetic regions detected by echocardiography and/or angiography. The low-amplitude electrogram values were distinctively recorded in the RV free wall, predominantly involving the anterolateral, infundibular and inferobasal regions, and spared the interventricular septum. Such a specific distribution is similar to that observed at autopsy in hearts of patients who died from ARVC, in whom most severe RV myocardial atrophy and wall aneurysms are found predominantly in the anteroinfundibular free wall and underneath the tricuspid valve.

### Abnormal vs normal voltage mapping

The majority of ARVC patients with an abnormal electroanatomic voltage mapping reported by Corrado et al. had a familial form of disease (132). This finding is in keeping with the genetic background of the disease which has been demonstrated in over 50% of ARVC patients, with either autosomal, or less frequently recessive, pattern of inheritance and age-related and variable penetrance. In the study of Corrado et al. (132) 35% of patients who fulfilled the Task Force diagnostic criteria for ARVC by non-invasive evaluation, showed neither evidence of electroanatomic low-voltage regions nor of fibrofatty replacement at EMB. Comparison of mapping results and clinical patient characteristics in this study suggests that the finding of normal RV voltage values characterizes a distinct subgroup of patients with a peculiar etiopathogenetic, clinical and prognostic profile. Patients with normal and abnormal electroanatomic voltage mapping did not differ with regard to mean age and mean time interval between symptoms onset and time of electroanatomic evaluation. Moreover, extent of precordial ECG repolarization changes and severity of morphofunctional abnormalities such as global or segmental right ventricular dilatation/dysfunction, RV wall motion abnormalities and LV involvement, which were detected by echocardiography/ angiography, were similar in both subgroups of patients. These findings argue against the possibility that failure to detect electroanatomic RV low-voltage areas reflects early stages or minor variants of ARVC.

Of note, our results differ from those of other studies in which all patients with suspect ARVC had a positive voltage mapping (125-133). This discrepancy may be explained by different study populations with different prevalence of inflammatory cardiomyopathy as well as by non comparable study design and diagnostic algorithms, with histopathologic data provided only by our investigation.

### ***Differential diagnosis between ARVC and Idiopathic Ventricular Tachycardia***

Idiopathic RVOT tachycardia refers to nonfamilial tachycardias, either paroxysmal or repetitive monomorphic, with a left bundle branch block and inferior axis QRS pattern that are characteristically triggered by physical exercise or by catecholamine infusion in young individuals without clinically detectable structural heart disease. Although RVOT tachycardia is considered benign and non progressive entity, it may cause syncope and, rarely, sudden cardiac death. These malignant events are most likely explained by the clinical overlap between idiopathic RVOT tachycardia and early and/or segmental ARVC. Ventricular tachycardia associated with ARVC/D may be localized to the outflow tract thus mimicking idiopathic RVOT tachycardia. Therefore, discrimination between the two entities is mandatory for prognostic and therapeutic reasons.

Clinical diagnosis of ARVC includes demonstration of morphofunctional abnormalities of the RV by imaging techniques. However, differential diagnosis from idiopathic RVOT tachycardia may be challenging, especially in patients with ARVC at its early stage or in its minor variant which is characterized by clinically subtle structural and functional RV abnormalities. Although conventional imaging modalities including echocardiography and contrast angiography appear to be accurate in detecting RV structural and functional abnormalities in overt forms of ARVC, they are less sensitive in detecting subtle lesions.

Two recent studies tested whether RV voltage mapping can help to differentiate between idiopathic RVOT tachycardia and ARVC due to its ability to identify and characterize electroanatomic scar in patients with ARVC.

Boulos et al. (131) compared electroanatomic findings in patients with an ultimate diagnosis of idiopathic RVOT tachycardia with those in patients who had established ARVC. They found that mapping results were in concordance with previous clinical diagnosis, by showing normal voltages in the idiopathic RVOT tachycardia group and abnormal low-amplitude areas in

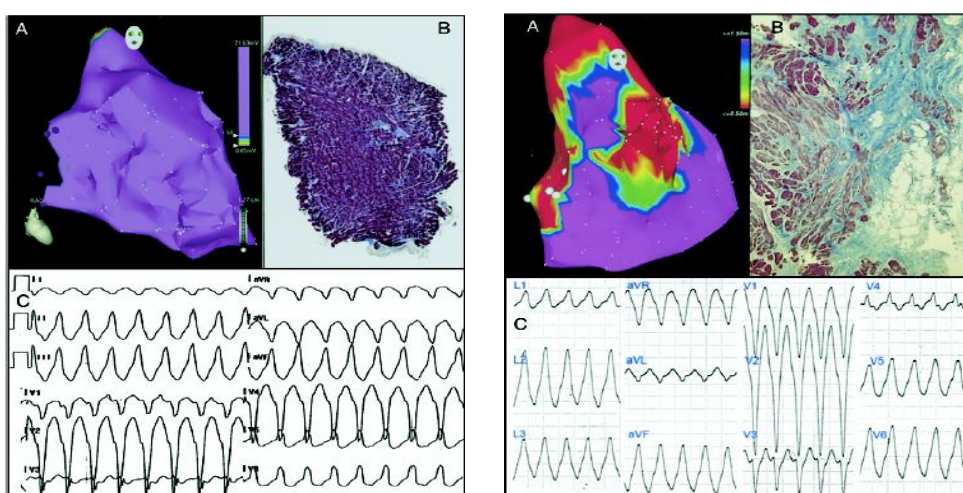
ARVC patients. However, in the investigation a histologic study to validate the clinical diagnosis by EMB was not done.

Corrado et al. (133) examined whether 3-D electroanatomic voltage mapping enhances accuracy to detect early/minor ARVC in patients presenting with RVOT tachycardia and an apparently normal heart. The study population consisted of 27 consecutive patients (15 males and 12 females, age  $33.9 \pm 8$  years) with recurrent RVOT tachycardia and no echocardiographic evidence of RV dilatation/dysfunction, who were referred for characterization of the ventricular tachycardia (VT) substrate and catheter ablation. All patients underwent detailed invasive study including activation and voltage mapping and EMB for histological study. Voltage mapping was normal in 20 of 27 patients (74%, Group A), with electrogram voltage  $> 1.5$  mV throughout the RV. The other 7 patients (26%, Group B), showed one or more ( $2 \pm 1.4$ ) electroanatomic scar areas (bipolar voltage  $< 0.5$  mV) that correlated with histopathologic evidence of fibrofatty myocardial replacement at EMB ( $p < 0.0001$ ). Independent predictors of scar were right precordial QRS prolongation ( $p < 0.001$ ) and VT inducibility at programmed ventricular stimulation ( $p < 0.01$ ). The major finding of this study is that an early/ minor form of ARVC may present clinically as RVOT tachycardia in the absence of RV dilatation/dysfunction, thus mimicking idiopathic RVOT tachycardia. Three-D electroanatomic voltage mapping is able to identify such subclinical ARVC variants by detecting RV electroanatomic scars that correlate with diagnostic histopathologic features of the disease (Figure 3).

A significant clinical implication of this study is that 3-D electroanatomic voltage mapping of the RV enhances accuracy for distinguishing patients with idiopathic RVOT tachycardia from those with an underlying subtle ARVC. The technique detected electroanatomic RV scars in approximately one fourth of patients with RVOT tachycardia, who had a normal RV size and function by customary imaging studies. The majority of patients with abnormal voltage mapping had electroanatomic scars confined to infundibular or anteroinfundibular free wall regions; only 2 patients had multiregional RV scars also involving remote regions of the so called “triangle of



dysplasia” such as the inferobasal or apical free wall areas. It is noteworthy that septal regions showed normal voltage amplitudes in all patients, according to the pathologic experience that the septum is usually not involved in ARVC. These segmental RV lesions with predominant involvement of the RVOT could explain why there were no significant changes in overall RV volume and ejection fraction. This is in keeping with previous studies showing that some patients with segmental ARVC particularly localized to the infundibulum, may have normal angiographic RV volumes and preserved RV function, either global or regional. Electroanatomic voltage mapping by assessing the electrical rather than the mechanical effects of RV myocardium obviated limitations in the analysis of localized RVOT dilatation/dysfunction and increased the sensitivity for detecting otherwise concealed ARVC myocardial substrate. It is noteworthy that electroanatomic scar in patients with RVOT tachycardia correlated with the EMB histopathologic finding of myocyte loss and fibrofatty replacement. This is in agreement with previous study of voltage mapping in patients with ARVC showing that areas of low-amplitude electrograms reflect the abnormal electrical activity of diseased RV myocardium and supports the conclusion that RVOT tachycardia occurred in the context of ARVC cardiomyopathic changes. (132-133)



**Figure 3.** (A) Right anterior oblique view of the right ventricular (RV) bipolar voltage map showing preserved bipolar voltages values (purple indicates >1.5 mV) throughout the RV. (B) Endomyocardial biopsy sample showing normal myocardium (Heidenhain trichrome x40). (C) 12-lead electrocardiogram during clinically sustained ventricular tachycardia 170 beats/min, with a left bundle branch block/inferior axis morphology (from Corrado et al Am Coll Cardiol 2008;51:731–9).

### ***Electroanatomic Voltage Mapping-guided catheter ablation***

Intraoperative studies of patients with ischemic heart disease have shown that circumferential ablation of ventricular scar and/or ablation connecting scar to an anatomic boundary is a successful therapy for ventricular tachycardia (125-133). This substrate-based ablation approach eliminates scar-related exit sites and/or isthmuses of the ventricular tachycardia reentry circuit. In patients with ARVC, fibrofatty replacement of RV myocardium creates scar regions that are regarded as the arrhythmogenic disease substrate. The histopathologic arrangement of the surviving myocardium embedded in the replacing fibrofatty tissue may lead to inhomogeneous intraventricular conduction predisposing to reentrant mechanisms. Hence, ventricular tachycardia in ARVC is the result of a scar-related macro-reentry circuit, similarly to that observed in post-myocardial infarction setting. This explains why RV voltage mapping-guided catheter ablation is successful in patients with ARVC. By using voltage mapping to identify RV low-voltage regions in patients with ARVC, both Marchlinski et al.(98) and Verma et al. (100) were able to create substrate-based RV linear ablation lesions connecting or encircling electroanatomic scars. Both studies showed that the technique is associated with a high rate of short-term success in patients with ARVC, although recurrences of ventricular tachycardia are common, most likely because ARVC is a progressive disease and new regions of fibrofatty scar develop over time and create new ventricular tachycardia circuits.

The main objective of management of patients with ARVC is to prevent arrhythmic sudden death. However, there are no prospective and controlled studies assessing clinical markers which can predict the occurrence of life threatening ventricular arrhythmias. It has been established that sudden death may be the first manifestation of the disease in previously asymptomatic young subjects and athletes. Therefore, all identified or suspected patients are at risk of sudden death even in the absence of symptoms or ventricular arrhythmias. The most challenging clinical dilemma is not whether to treat patients who already experienced malignant ventricular arrhythmias (secondary

prevention), but to consider prophylactic treatment in patients with no or only minor symptoms in whom the disease has been diagnosed during family screening or by chance (primary prevention). Furthermore, ARVC is a progressive disease and the patient's risk of sudden death may increase with time. The risk profile which emerges from retrospective analysis of clinical and pathologic series, including fatal cases, is characterized by young age, participation in competitive sport activity, malignant familial background, extensive right ventricular disease with reduced ejection fraction and LV involvement, syncope, and prior episodes cardiac arrest due to ventricular tachycardia/fibrillation. The baseline clinical study for assessment of the risk of sudden death consists of non-invasive routine clinical study including detailed clinical history (mostly addressing familial background and previous syncope), 12 lead ECG, 24 hour Holter monitoring, exercise stress testing, and signal averaged ECG. Invasive risk stratification traditionally relies on electrophysiologic study, although the predictive value of ventricular tachycardia/fibrillation inducibility by programmed ventricular stimulation has not been demonstrated. Characterization of the RV wall by electroanatomic voltage mapping is an additional invasive technique with the potential to refine risk stratification of ARVC/D patients, given that identification of scar lesions may predict a worse clinical outcome.

In this regard, Corrado et al. (132) reported that the subset of ARVC patients with abnormal electroanatomic voltage mapping had a worse arrhythmic outcome. During a mean 3.4 year clinical interval, 55% of ARVC patients with electroanatomic evidence of low-voltage areas required an ICD implantation due to serious arrhythmic complications, whereas all but one ARVC patient with preserved myocardial voltage values remained stable on antiarrhythmic therapy.

A more recent study from the Padua group (133) showed that the short-term success of catheter ablation of RVOT tachycardia did not differ between patients with normal and those with abnormal RV voltage mapping (85% vs 89%). Despite initial success, however, more than 40% of patients with RVOT tachycardia and underlying RV electroanatomic scar experienced relapse of

life-threatening ventricular tachycardia (leading to syncope in 2 and aborted sudden death in one), compared with none of patients with successful ventricular tachycardia ablation and normal voltage mapping. This is in agreement with previous studies showing a good acute success rate of catheter ablation of right ventricular tachycardia, either idiopathic or associated with ARVC, although in patients with ARVC ventricular tachycardia recurrences are commonly observed (up to 60% of the cases) and may lead to sudden arrhythmic death. The discrepancy between the good acute results and the unfavourable long term outcome has been explained by the progressive nature of the underlying disease which predisposes to the occurrence of new and malignant arrhythmogenic substrates over time. These findings indicate that the subset of patients with RVOT tachycardia and electroanatomic evidence of RV scar may have a worse outcome because of the structural and electrically instable underlying substrate. Whether electroanatomic voltage mapping may refine arrhythmic risk assessment needs to be confirmed by larger prospective studies.

Invasive electrophysiologic study with programmed ventricular stimulation has been performed in patients with ARVC for diagnostic, therapeutic and prognostic purposes. The major aims of electrophysiologic study are: (i) to assess the disease's arrhythmogenic potential by induction of ventricular tachycardia/fibrillation during the basic pacing protocol or during isoproterenol infusion; (ii) to evaluate haemodynamic consequences of sustained ventricular tachycardia and its propensity to degenerate into ventricular fibrillation; (iii) to examine the predictive role of inducible ventricular tachycardia/fibrillation for subsequent arrhythmic cardiac arrest; and (iiii) to establish the susceptibility of ventricular tachycardia to be interrupted by antitachycardia stimulation, and its reinducibility in view of serial electropharmacologic studies, catheter ablation, or implantation of an ICD. The results of recent studies raised concerns on the programmed ventricular stimulation predictive value for risk stratification of patients with ARVC. Corrado et al. (21,22) evaluated the prognostic role of programmed ventricular stimulation in a large series of patients undergoing ICD implantation for prevention of arrhythmic sudden death. Of

98 patients who were inducible at programmed ventricular stimulation, 50 (51%) did not experience ICD therapy during the follow-up, whereas 7 (54%) of 13 noninducible patients had appropriate ICD interventions. Overall, the positive predictive value of programmed ventricular stimulation was 49%, the negative predictive value was 54%, and the test accuracy was 49%. Moreover, the incidence of appropriate ICD discharge did not differ between patients who were or were not inducible at programmed ventricular stimulation, regardless of clinical presentation. Finally, the type of ventricular tachyarrhythmia inducible at the time of electrophysiological study did not predict the occurrence of ventricular fibrillation/flutter during follow-up. The results of this study indicate that the electrophysiological study is of limited value in identifying patients at risk of lethal ventricular arrhythmias because of a low predictive accuracy (approximately 50% of both false-positive and false-negative results). This finding is in agreement with the limitation of electrophysiological study for arrhythmic risk stratification of other non ischemic heart disease such as hypertrophic and dilated cardiomyopathy.

### ***Electroanatomical Voltage Mapping Versus Contrast-Enhanced Cardiac Magnetic Resonance***

Endocardial voltage mapping (EVM) is an invasive technique that has been proved to accurately characterize the presence, location, and extent of RV scars in ARVC by demonstration of low-voltage regions, so-called electroanatomical scars (EAS). (125-133) A significant correlation between RV EAS and fibrofatty myocardial replacement was demonstrated by endomyocardial biopsy (EMB). Moreover, EVM has been clinically validated in the electrophysiological laboratory, where it is used for both mapping of substrate and catheter ablation of RV ventricular tachycardia (VT). (125-133) However, because EVM is an invasive procedure and requires a cardiac catheterization, it cannot be proposed as a routine imaging study of ventricular scar in ARVC patients.

Contrast-enhanced cardiac magnetic resonance (CE-CMR) with delayed contrast enhancement (DCE) sequences using gadolinium is an emerging technique that has the potential to detect ventricular scar in different pathological settings, including ARVC. Compared with EVM, CE-CMR offers the advantage of being noninvasive and identifying LV scars distinct from RV scars.

Recently, Perazzolo Marra et al. (84) compared endocardial voltage mapping (EVM) and contrast-enhanced cardiac magnetic resonance (CE-CMR) for imaging scar lesions in ARVC patients. The study population included 23 ARVC/D patients who underwent both RV-EVM and CE-CMR. In 21 (91%) of 23 ARVC patients, RV EVM was abnormal, with a total of 45 electroanatomical scars (EAS): 17 (38%) in the inferobasal region, 12 (26.6%) in the anterolateral region, 8 (17.7%) in the RV outflow tract (RVOT), and 8 (17.7%) in the apex. RV delayed contrast enhancement (DCE) was found in 9 (39%) of 23 patients, with a total of 23 RV DCE scars: 4 (17.4%) in the inferobasal region, 9 (39.1%) in the anterolateral region, 4 (17.4%) in the RVOT, and 6 (26.1%) in the apex. There was a mismatch in 24 RV scars, with 22 EAS not confirmed by DCE and 2 DCE scars (both in the RVOT) undetected by EVM. In 9 (75%) of 12 patients with abnormal RV EVM/normal RV DCE,  $\geq 1$  DCEs were identified in the LV. Overall, ventricular DCE was detected in 78% of patients. The authors concluded that CE-CMR is less sensitive than EVM in identifying RV scar lesions. Moreover, the high prevalence of LV DCE confirms the frequent biventricular involvement and indicates the diagnostic relevance of LV scar detection by CE-CMR.

### *Electroanatomical Scar in ARVC*

Electroanatomical voltage mapping has identified areas of myocardial loss by recording and spatially associating low-amplitude electrograms to generate a 3D electroanatomical ventricular map. (125-133) In ARVC patients, RV EAS have been demonstrated to correlate with the histopathologic finding of myocardial atrophy and fibrofatty replacement at EMB. (132-133) EVM assesses the electric consequences of loss of RV myocardium, rather than the mechanical dysfunction, either

regional or global, traditionally seen by echocardiography and angiography. EVM was reported to enhance the accuracy of differential diagnosis between ARVC and acquired inflammatory cardiomyopathy or idiopathic RVOT tachycardia.

Perazzolo Marra et al (84) reported that RV EAS are identified by EVM in most ARVC patients. The high prevalence of RV low-voltage areas may be explained by the clinical and electrophysiological characteristics of patients who were probands with an overt disease phenotype, including VT, either sustained or nonsustained. Regional distribution of RV scars, with predominant involvement of the anterolateral and inferobasal RV regions, resembled that observed in autopsy heart specimens of patients who died suddenly from ARVC in whom the most severe atrophy and wall aneurysms were characteristically localized in the anteroinfundibular wall and underneath the tricuspid valve.

#### *Contrast-enhanced Cardiac Magnetic Resonance findings in ARVC*

Typical ARVC/D features on CMR consist of RV dilatation/dysfunction, wall motion abnormalities, diastolic bulging, and thinning of the RV free wall. Moreover, CMR has the unique ability to detect intramyocardial fatty deposition, which may be differentiated by the adjacent myocardium, because of its brighter signal, with the spin-echo technique. (84) Although CMR provides an accurate quantitative analysis of RV volumes, a significant interobserver variability in the interpretation of qualitative findings and segmental contraction analysis of the RV free wall has been reported. CMR has been implicated in overdiagnosis of ARVC based on the low specificity of qualitative findings, such as increased intramyocardial fat and wall thinning. Tandri et al (82) first reported RV DCE in 8 (67%) of 12 of patients with ARVC and demonstrated its relation to inducibility of sustained monomorphic VT at electrophysiological testing and fibrofatty myocardial changes at EMB. Perazzolo Marra et al (84) confirmed a low prevalence (39%) of RV DCE in patients with clinical ARVC. Moreover, by specifically comparing EVM with CE-CMR for RV scar visualization, they found a significant mismatch between the 2 techniques (for imaging RV

lesions), with fewer RV scars detected by RV-DCE compared with RV-EVM. The 19 EAS not confirmed by the DCE mostly affected the anterolateral and inferobasal RV regions. Previous reports comparing EVM with CMR findings in ARVC found a topographical relationship between low-voltage areas and RV dyskinesia/dilation. Because all our patients had clinically overt disease with significant RV dilatation/dysfunction, the low yield of RV DCE cannot be ascribed to early/minor disease forms but, more probably, can be explained by the low resolution of current CMR for the RV free wall and by the protocol design, with inversion time set to null LV myocardium and inversion recovery sequence not fat suppressed. The RV free wall is up to 4-mm thick and the motion artifacts often result in poor quality/spectral resolution to quantify RV wall thickness accurately. In addition, transmural myocardial atrophy and fibrofatty replacement in ARVC patients may lead to further RV free wall thinning (<2 mm) with a suboptimal contrast/noise ratio between normal and scar tissue. The inversion time required for optimal nulling of the myocardium probably differs between RV and LV, making inaccurate simultaneous examination of both ventricles with DCE imaging. In addition, fat and fibrosis give the same signal on CE-CMR and partial volume effects make it difficult to distinguish the 2 different tissues, mostly in a thinned wall. In addition to the limitations due to wall thinning and motion artifacts, the spatial resolution of CE-CMR is good for detecting large confluent areas of scarring, which are observed in diffuse disease variants, whereas it may fail in detecting an epicardial or focal RV scar. On the basis of pathological and CMR studies fibrofatty myocardial replacement in ARVC usually involves large epicardial/midmural areas but reaches focally the RV endocardial layer, according to a “reversed” iceberg-like lesion model with a larger base on the epicardium and a thinner apex on the endocardium. The size of scar lesions reaching the endocardium may decline below the resolution power of CE-CMR, thus explaining the finding of the apparently normal RV wall. The findings of RVOT scars by CE-CMR, undetected by EVM in 2 patients, may be interpreted as false positive. As an alternative explanation, this finding may suggest limited EVM power for detection of scar



lesions in this area. Because in our study EVM was limited to the endocardial side of the RV free wall, this may have underestimated or missed some nontransmural scar lesions.

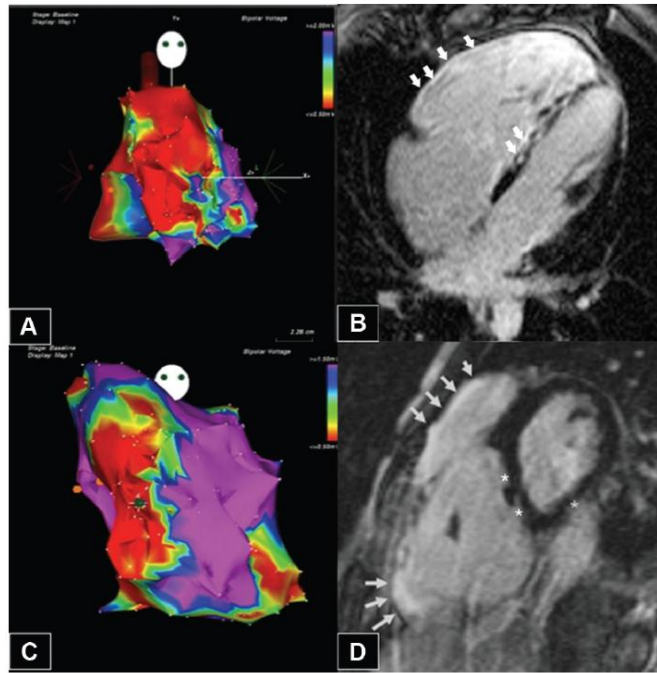
Recent studies suggest a key role of late gadolinium enhancement for detection and morphological characterization of an LV myocardial fibrofatty scar in ARVC. (73)

### *Clinical Implications*

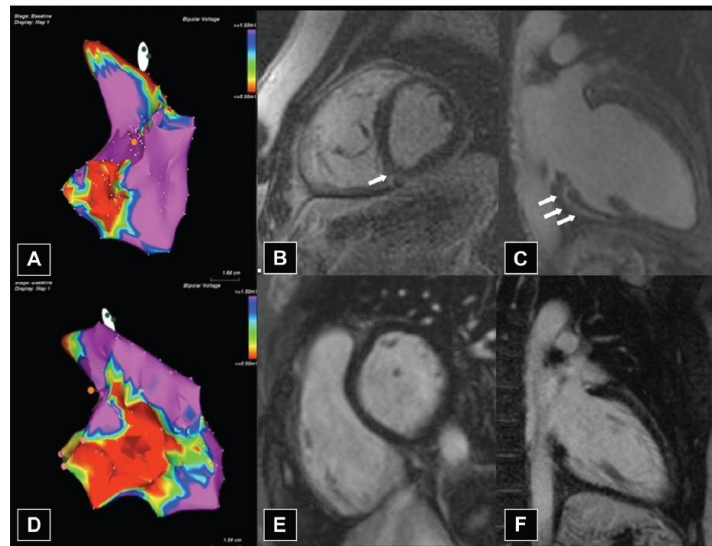
The results of the study by Perazzolo Marra et al (84) confirm that EVM allows an accurate identification of RV EAS in patients with a clinical diagnosis of ARVC and support its clinical use for substratebased mapping and catheter ablation of RV tachycardia and for imaging-guided EMB.

EVM has been successfully used for catheter ablation of LV VT arising from a postinfarct scar, thanks to the ability of CMR to identified nontransmural LV scars and infarct gray zones undetectable by EVM. (132-133) Currently available DCE-CMR visualize RV scars unsatisfactorily, limiting its usefulness for characterizing ARVC myocardial substrate and guiding interventional procedures, such as RV VT catheter ablation and imaging-guided RV EMB. The high prevalence of LV involvement in our cohort of ARVC patients is in keeping with the perspective of biventricular disease and indicates the diagnostic relevance of LV scar detection by CE-CMR.

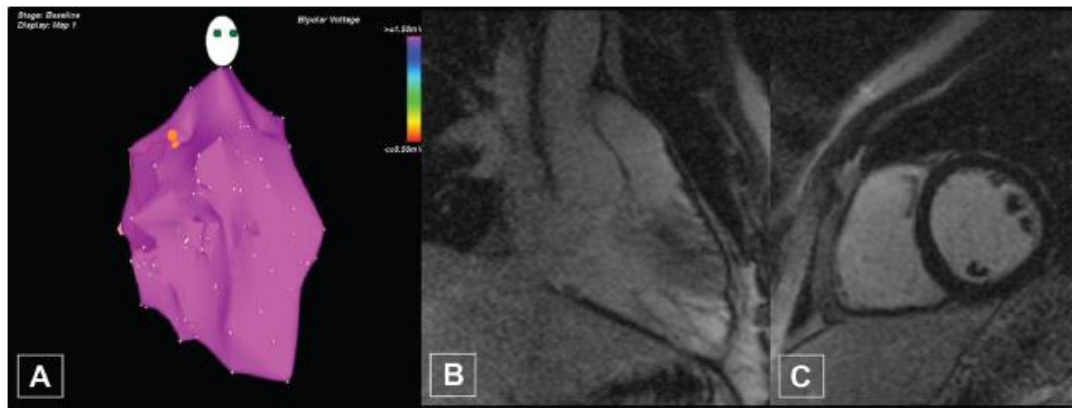
Despite the different accuracy of the 2 techniques for identification of a ventricular scar, CMR and EVM should not be considered alternative imaging tools in ARVC patients; rather, they should be used synergistically to combine their strategic diagnostic and prognostic information, mostly regarding quantitative evaluation of RV function and assessment of arrhythmogenic myocardial substrate.



Representative cases of concordance between endocardial voltage mapping (EVM) and contrast-enhanced cardiac magnetic resonance (CE-CMR). **A**, Anteroposterior view of the right ventricular (RV) EVM showing a large electroanatomical scar (EAS) involving almost completely the RV free wall. **B**, Fourchamber view of CE-CMR showing the widespread RV delayed contrast enhancement (DCE) and the septal involvement (white arrows). **C**, Right anterior oblique view of EVM showing EASs (red indicates  $<0.5$  mV) in the RV inferobasal region and outflow tract. **D**, Basal short-axis view of CE-CMR showing DCE in the RV inferobasal wall and outflow tract (white arrows); DCE also involves the subepicardial layer of the inferior left ventricular (LV) free wall and the septum (white asterisks). (From Perazzolo Marra et al. *Circ Arrhythm Electrophysiol* 2012;5:91-100).



Representative cases of discordance between endocardial voltage mapping (EVM) and contrast-enhanced cardiac magnetic resonance (CE-CMR). **A**, Lateral view of the right ventricular (RV) EVM showing electroanatomical scar (EAS) in the RV inferobasal region and outflow tract. **B** and **C**, Basal short- and long-axis views of CE-CMR sequences showing no signs of delayed contrast enhancement (DCE) in the RV free wall. Subepicardial DCE is visible in the inferior and inferoseptal regions of the left ventricle (LV; white arrows). **D**, Lateral view of EVM showing a large EAS affecting the inferobasal, anterolateral, and, partly, RV outflow tract region. **E** and **F**, Basal short- and long-axis views of CE-CMR showing neither RV nor LV DCE (From Perazzolo Marra et al. *Circ Arrhythm Electrophysiol* 2012;5:91-100).



Representative example of endocardial voltage mapping (EVM) and contrast-enhanced cardiac magnetic resonance (CECMR) in a healthy control subject. **A**, Right anterior oblique view of the EVM showing preserved bipolar voltage values (purple indicates  $>1.5$  mV) throughout the right ventricle (RV). Orange dots indicate the site of His bundle electrogram recording. In the same subject, there is no evidence of RV and left ventricular (LV) delayed contrast enhancement (DCE) on T1 inversion recovery postcontrast sequences, in both right-sided 2-chamber (**B**) and mid short-axis (**C**) views (From Perazzolo Marra et al. *Circ Arrhythm Electrophysiol* 2012;5:91-100).

**Study: Arrhythmogenic Right Ventricular Cardiomyopathy:**

**Prognostic Value of Electroanatomic Voltage Mapping in patients with**

## **AIM OF THE STUDY**

ARVC is an inherited heart muscle disease whose natural history is essentially related to ventricular electrical instability which may lead to SCD, mostly in young people and athletes. Risk stratification of affected patients is mandatory for implementing therapeutic strategies aimed to prevent SCD. Current treatment strategies suggest the implantation of an implantable cardioverter defibrillator (ICD) in symptomatic ARVC patients with prior cardiac arrest due to ventricular fibrillation (VF), history of syncopal episodes, and sustained ventricular tachycardia (VT); in contrast, the role of prophylactic ICD therapy in asymptomatic patients or relatives presenting traditional risk factors such as family history of SCD, severe right ventricular (RV) dysfunction, and inducibility at programmed ventricular stimulation (PVS) remains controversial. (21,22).

The assessment of mechanical consequences of myocardial fibrofatty scar has been traditionally based on imaging techniques such as echocardiography and angiography. Among the techniques now available for direct imaging of ventricular myocardial lesion, endocardial voltage mapping (EVM) is an emerging tool which has the ability to accurately identify and quantify RV regions with low-amplitude electrical signals, i.e. electroanatomic scar areas, which reflect myocardial replaced tissue (125-133). Although the technique has been demonstrated to enhance the accuracy for diagnosing ARVC, its value for arrhythmic risk stratification remains to be established.

Hence this study was designed to prospectively evaluate the prognostic value of RV-EVM in a cohort of ARVC/D patients during a long-term follow-up.

## METHODS

### *Study population*

The study population included 69 consecutive patients [47 males; median age 35 years ( 28-45)] with ARVC who were referred at the Division of Cardiology of the University of Padova, Italy for risk stratification.

All patients underwent detailed cardiac evaluation including family history, physical examination, 12-lead-electrocardiogram (ECG) recording, signal-averaged ECG; 24-hour Holter monitoring, exercise stress testing, echocardiography and cardiac catheterization including RV and left ventricular (LV) cineangiography in the right and left anterior oblique view and coronary angiography.

All patients met the International Task Force (ITF) criteria (two major criteria or one major criterion plus two major criteria or 4 minor criteria) for diagnosis of definite ARVC. Diagnosis was established according to the original ITF criteria (19) and confirmed using the recently revised criteria. (20)

All patients underwent intracardiac electrophysiologic study with programmed ventricular stimulation (PVS) for assessing VT/VF inducibility and high density EVM for imaging and quantification of abnormal RV-EVM.

The study was approved by the institutional review board, and all patients gave their informed consent.

### *Electrophysiological study*

All antiarrhythmic drugs were discontinued 5 half-lives (6 weeks for amiodarone) before the electrophysiological study. Programmed ventricular stimulation protocol included 3 drive cycle lengths (600, 500, and 400 ms) and 3 ventricular extrastimuli while pacing from 2 RV sites (apex

and outflow tract). Programmed ventricular stimulation was considered positive if either a VF or sustained ventricular tachycardia (VT), i.e., one that lasted  $\geq 30$  seconds or required termination because of hemodynamic compromise, was induced. Programmed ventricular stimulation was repeated after intravenous isoproterenol infusion in those patients with effort induced non sustained VT (16 of 53, 26%).

### ***Electroanatomic voltage mapping***

At the time of electrophysiologic study, all patients underwent detailed EVM by the CARTO system (Biosense-Webster) during sinus rhythm, as previously reported (125-133). A 7-F Navi-Star (Biosense-Webster) catheter, with a 4-mm distal tip electrode and a 2-mm ring electrode with an interelectrode distance of 1 mm, was introduced into the RV under fluoroscopic guidance and used as the mapping/ablation catheter. The catheter was placed at multiple sites on the endocardial surface of RV free wall [infero-basal, antero-lateral free wall, apex, and RV outflow tract (RVOT)] and septum to reconstruct the 3D-geometry of the RV chamber. Bipolar electrogram signals (filtered at 10 to 400 Hz and displayed at 100 mm/s speeds on the CARTO system) and unipolar signals (filtered at 1 to 240 Hz and displayed at 100 mm/s speeds on the CARTO system) were recorded and analyzed simultaneously with regard to amplitude, duration, relation to the surface QRS, and presence of multiple components.

Duration of an endocardial bipolar electrogram was measured as the time from the earliest electrical activity to the artefact produced by the decay of the amplified filtered signal (132-133).

Bipolar signals were recorded between the distal electrode pair, unipolar signals between the distal tip of the ablation catheter (cathode) and the Wilson central terminal.

In our study the following tools were used to avoid false low-voltage recordings: 1) adequate catheter contact was confirmed by concordant catheter tip motion with the cardiac silhouettes on fluoroscopy; 2) a recording was accepted and integrated into the map when the variability in cycle length, local activation time stability, and maximum beat-to-beat difference of

the location of the catheter (automatically detected by the CARTO system) were  $<2\%$ ,  $<3$  ms, and  $<4$  mm, respectively (these parameters, combined with the stability of the impedance reading, were used to exclude low amplitude signals due to poor endocardial catheter contact); 3) in the presence of a low voltage area, at least 3 additional points were acquired in the same area to confirm the reproducibility of the voltage measurement (132-133). Particular attention was paid to validate the acquisition of endocardial points from the RV inferobasal region, because of the recognized risk of poor tissue contact in this area. Because of the potential high mapping error and to avoid overestimation of low-voltage RV areas due to inclusion of normal annular fibrous tissue, the immediate perivalvular areas (i.e. within 1.5 cm of the valvular locations on post-processing measurement) were excluded in the analysis of endocardial low voltages.

Values of normal RV endocardial voltages were established by RV-EVM in 6 reference patients without structural heart disease, who underwent electrophysiological study for evaluation of supraventricular tachycardia. RV septal endocardial sites ( $23\pm 5$ ) were excluded and only RV free-wall electrogram recordings ( $207\pm 16$  points sampled), either bipolar or unipolar, were analyzed. Normal bipolar electrograms were sharp with  $\leq 3$  rapid deflections; the mean electrogram duration was  $34.8\pm 1.2$  ms and the mean amplitude  $5.3\pm 0.9$  mV, with 95% of all electrogram signals  $<66$  ms and  $>1.47$  mV.

In addition, we analyzed the amplitude of unipolar electrograms which was  $10.3\pm 0.6$  mV with 95% of all unipolar signals recorded having an amplitude  $>5.96$  mV.

Then in the present study the reference values used to define normal RV electrogram amplitude was set at 1.5 mV for bipolar signals and 6.0 mV for unipolar signals, which were the values above which 95% of all bipolar and unipolar electrogram voltages from the endocardium of normal RVs were included.

We considered normal bipolar electrocardiograms those with sharp and  $\leq 3$  spikes, amplitude  $>1.5$  mV and duration  $\leq 70$  ms. We defined as fragmented electrograms those characterized by multiple deflections ( $>3$ ) amplitude  $\leq 1.5$  mV and duration  $>70$  ms.



Normal amplitude electrograms (bipolar >1.5 mV and unipolar >6.0 mV) were represented in the electroanatomic CARTO map by the color purple, whereas low-amplitude signals were represented by non-purple range of colors. Color red indicated “dense scar” which was arbitrarily defined as bipolar signal amplitude <0.5 mV and unipolar signal amplitude <3.5 mV, according to previously reported criteria (132-133). An EVM was considered abnormal in the presence of a single or multiple RV low voltage areas  $\geq 1$  cm<sup>2</sup> including at least 3 adjacent points with a bipolar signal amplitude <1.5 mV and an unipolar signal amplitude <6.0 mV.

Complete endocardial maps were obtained in all patients to ensure reconstruction of a 3-dimensional geometry of the RV chamber and to identify areas of abnormal electrograms in the RV free wall. The septum was excluded from the analysis (Figure 1). Regions showing low-amplitude signals were mapped with greater point density to delineate the extent and borders of endocardium electroanatomic scar areas.

The extent of low-voltage areas was estimated by using a CARTO-incorporated area calculation software (CARTO, Biosense Webster Inc, Diamond Bar, CA) and was expressed both as total RV area and percentage of RV area, excluding tricuspid and pulmonary valvular annuli.

### ***Follow-up***

The follow-up data were obtained prospectively during regular outpatient visits at 6 to 12-months intervals. Routine ICD interrogation and ECG recordings at the time of symptoms were used to document the occurrence of spontaneous VT during follow-up. The study outcome was the index combined end point of major arrhythmic events such as sudden death (SD), cardiac arrest due to VF, sustained VT or appropriate ICD intervention. Sudden death was defined as any natural death occurring instantaneously or within one hour from symptoms onset.

Sustained VT was defined as tachycardia originating in the ventricle with rate >100 beats/minute and lasting >30 seconds or requiring an intervention for termination. Appropriate ICD

intervention was defined as a device shock or antitachycardia overdrive pacing delivered in response to a ventricular tachyarrhythmia and documented by stored intracardiac ECG data. Ventricular fibrillation and VT were defined as a ventricular tachyarrhythmia with a cycle length  $\leq$  240 ms or  $>$  240 ms respectively. Implantable cardioverter defibrillator were routinely programmed to include a monitoring zone that identified VT with a rate  $>$ 160 bpm.

### ***Statistical analysis***

Results are summarized as mean  $\pm$  standard deviation (SD) or median with 25%-75%-iles for normally distributed and skewed variables, respectively. Normal distribution was assessed using Shapiro-Wilk test. Categorical differences between groups were evaluated by the  $\chi^2$  test of the Fisher exact test as appropriate. Paired and unpaired t-tests were used to compare normally distributed continuous variables respectively obtained from the same patient and different patients; paired and unpaired Rank Sum test were used for skewed continuous variables.

Kaplan-Meier analysis was used to estimate the survival distributions of the index combined end point and to show the difference in survival between patients with normal vs abnormal bipolar-EVM and positive vs negative PVS. Start of follow-up was defined as the date of the initial EVM. Patients were censored at the time of their first event or the time of their last clinical follow-up. The mean event rate per year was evaluated by the number of events occurring during the follow-up divided by the number of patients multiplied by the average duration of follow-up.

The independent correlation of traditional clinical predictors of arrhythmic risk in ARVC with the index combined end-point during follow up was determined by means of univariate and multivariable Cox regression analysis. Variables with a P value  $<$ 0.15) were integrated into multivariable analysis using Cox proportional-hazard models to estimate the Hazard ratio (HR) and to identify independent predictors of major arrhythmic events. The Cox model was used to calculate the relation between amount of RV low-voltage areas and hazard ratios. Hazard ratios (HR) and confidence intervals (CI) are presented both in univariate and multivariable analysis. The c-statistic

method was used to estimate the best cut-off value of bipolar low-voltage area to discriminate between patients with and those without major arrhythmic events during follow-up. A value of  $P < 0.05$  was considered significant. Statistics were analyzed with SPSS version 17 (SPSS Inc, Chicago, Ill).

## RESULTS

### *Clinical characteristics*

Baseline clinical characteristics and instrumental findings are summarized in Tables 1. The study population included 69 consecutive patients [47 men; median age 35 years (28-45)]. Twenty-eight patients (40%) had a family history of ARVC (N=12, 17%) or premature (<35 years) sudden death (N=16, 23%). Twenty-two (32%) patients had a history of cardiac arrest or syncope. Ventricular tachycardias were documented in 53 (76%) patients and included sustained VT (N=9, 13%) or non-sustained VT (N=44, 63%). There were 15 morphologies of sustained VT, all with a left bundle branch pattern, with a superior axis in 8, inferior axis in 4, and undetermined axis in 3. Right ventricular dilatation/dysfunction were observed at echocardiography/angiography in all patients. Multiregional wall motion abnormalities (akinesia, dyskinesia or bulging involving  $\geq 2$  RV regions) were found in 25 (36%) patients. Thirty-four (49%) patients were inducible at programmed ventricular stimulation to either sustained monomorphic VT (N=23) or VF (N=11). Among 8 noninducible patients, 2 experienced exercise induced arrhythmic events during follow-up. At enrolment, 57 (82%) patients with VT or frequent premature ventricular beats were empirically treated with antiarrhythmic drug therapy which consisted of sotalol (N=22), amiodarone either alone (N=9) or in combination with beta blockers (N=14), beta blockers (N=7) and flecainide (N=5).

### ***Electroanatomic voltage mapping***

Endocardial voltage mapping was successfully acquired during sinus rhythm in all patients, with a mean number of sites sampled of  $195\pm 22$ .

### ***Bipolar EVM***

An abnormal bipolar RV-EVM was recorded in 53 (77%) patients. Patients with and without evidence of abnormal bipolar-EVM had similar baseline clinical characteristics, except for multiregional RV wall motion abnormalities which was significantly more prevalent in the abnormal bipolar-EVM group. In patients with an abnormal bipolar-EVM the median RV low-voltage area was  $39.1 \text{ cm}^2$  (13.2-67.8) with a median percent RV area of 24.8 % (7.2-31.5) (Figure 2). The involved RV regions were infero-basal in 49 (71%) patients, antero-lateral in 28 (40%), RVOT in 25 (36%) and apex in 15 (22%) (Figure 1).

Mean bipolar amplitude of local electrograms recorded from within RV electroanatomic scar areas was significantly lower than that sampled from unaffected RV areas ( $0.38\pm 0.11$  versus  $5.2\pm 0.6\text{mV}$ );  $P<0.001$ ). Similarly, bipolar electrograms from low-voltage areas had a longer mean duration ( $78.9\pm 18$  versus  $33.5\pm 7.8\text{ms}$ ;  $P<0.001$ ) and more often extended beyond the offset of the surface QRS (64% vs 7%;  $P<0.001$ ), compared with electrograms sampled from regions with preserved electrogram voltage (Figure 3). Fragmented bipolar electrograms (i.e. signals with  $> 3$  deflections, amplitude  $\leq 1.5\text{mV}$  and duration  $> 70\text{ms}$ ) were recorded in 47 of 53 (88%) patients with an abnormal bipolar-EVM.

In 16 patients (23%), EVM was normal, with preserved bipolar endocardial electrogram amplitude ( $4.8\pm 1.3\text{mV}$ ) and duration ( $35.3\pm 0.8\text{ms}$ ) (Figure 2).

### ***Unipolar EVM***

In the 53 patients (77%) with abnormal bipolar-EVM, unipolar-EVM recorded significantly more extensive RV electroanatomic scar involvement with a median RV low-voltage area of 68.5

cm<sup>2</sup> (22.9-98.7) and median percent RV area of 64.8 % (39.8-95.3) compared with low-voltages obtained by bipolar-EVM (P<0.009) (Figure 2).

In all 16 patients (23%) with normal bipolar-EVM, the use of unipolar-EVM technique unmasked  $\geq 1$  regions of low-voltage unipolar electrogram abnormality 37.3 cm<sup>2</sup> (12.1-48.9); 26.2 % (11.6-38.2) (Figure 2).

### ***Follow-up***

During a median follow-up of 41 (28-56) months, 19 patients (27.5%) reached the composite arrhythmic end point, with a 6.7% annual rate of major arrhythmic events. Eleven patients (16%) had an episode of sustained VT, 7 (10%) experienced  $\geq 1$  appropriate ICD interventions, either against VF (N=4) or VT (N=3), and one (1.4%) died suddenly. Among the 4 patients who experienced VF, one underwent orthotopic heart transplantation because of intractable recurrent VF storms (Figure 4).

Table 2 shows the clinical characteristics of patients with or without major arrhythmic events during follow-up. Patients who experienced arrhythmic events significantly more often had a history of cardiac arrest or syncope (73% vs 16%; P=0.001), and abnormal bipolar-EVM (100% vs 68%;P=0.003).

Figure 5A shows Kaplan-Meier analysis of survival from the index combined end point of sustained VT, appropriate ICD intervention and SCD for the overall population, stratified by bipolar-EVM findings. Overall, the annual event rate was 11.4%/year in patients with an abnormal bipolar-EVM and 0%/year with a normal bipolar-EVM (logrank: P=0.02).

### ***Electrophysiologic study***

Overall, the annual event rate was 6.1%/year in patients who were inducible at PVS and 7.1%/year in those who were noninducible (logrank: P=0.46) (Figure 5B). Of 34 patients who were inducible at PVS, 23 (68%) did not experience major arrhythmic events during the follow-up

(i.e. false positives), whereas 8 of 35 (23%) noninducible patients had malignant events (i.e. false negatives). The type of ventricular tachyarrhythmia which was inducible at the time of PVS (either VT or VF) did not predict either the presence of bipolar electroanatomic scar or the occurrence of arrhythmic events during follow-up. Patients with and without events during follow-up had a similar prevalence of RV fragmented bipolar electrograms (79% vs 64%).

### ***Predictors of events***

Univariate and multivariable analysis for predictors of adverse events during follow-up are listed in Table 3. Univariate predictors of events were a previous history of cardiac arrest or syncope and extent of abnormal bipolar-EVM. The overall arrhythmic risk increased with percentage of abnormal bipolar-EVM (HR 1.7 per 5% abnormal EVM increase, 95% CI:1.5-2.0;  $P<0.001$ ) (Figure 6). At multivariable analysis the amount of abnormal bipolar-EVM was an independent predictor of events (HR 1.6 per 5% increase of abnormal-EVM percentage, 95% CI 1.2-1.9;  $P<0.001$ ). The amount of abnormal bipolar-EVM was a predictor of events (HR 1.4 per 5% increase of abnormal bipolar-EVM percentage, 95% CI 1.1-1.9;  $P=0.004$ ) even in the subgroup of 55 patients without previous sustained VT ( $n=9$ ) and prior cardiac arrest ( $n=5$ ). According to c-statistic, the best cut-off value for abnormal bipolar-EVM % area was 27.8% ( $c=0.74$ ).

## DISCUSSION

The present study was designed to evaluate the value of the presence and extent of RV electroanatomic scar areas for predicting arrhythmic outcome in a consecutive series of ARVC patients. The major study findings were that: 1) abnormal bipolar-EVM was of independent prognostic significance, with the arrhythmic risk being proportional with the increased extent of RV low-voltage areas; 2) abnormal bipolar-EVM appeared to be superior in predicting major arrhythmic events over a long-term follow-up to classic clinical risk factors such as clinical history, arrhythmic background and ventricular dilatation/dysfunction; and 3) a normal bipolar RV-EVM characterized a low-risk subgroup of ARVC patients.

These study results suggest that EVM should supplement the traditional intracardiac electrophysiologic studies for prognostic evaluation of ARVC patients.

### *Diagnostic utility of EVM*

Endocardial voltage mapping has the ability to identify areas of scar tissue by recording and spatially associating low amplitude electrograms to generate a 3-D electroanatomic ventricular map (125-133). The technique has been clinically validated in electrophysiological labs where it is increasingly used for substrate-based mapping and catheter ablation of scar-related VT, in either ischemic or non ischemic cardiomyopathies (125-133). In ARVC patients, RV bipolar low-voltage areas was demonstrated to correlate with the histopathologic finding of fibrofatty myocardial replacement at endomyocardial biopsy (132-133). Previous studies showed that EVM provides additional value for ARVC diagnosis (125-133). EVM has been recently reported to be significantly more sensitive than contrast-enhancement-cardiac magnetic resonance to identify RV scar lesion (132-133).

In the present study, an abnormal bipolar-EVM was demonstrated in the majority of ARVC patients, confirming data from previous studies (125-133). Regional distribution of bipolar low-voltage regions, with predominant involvement of the antero-lateral and infero-basal RV regions, resembled that observed in autopsy hearts of ARVC patients who died suddenly or underwent heart transplant, in whom the most severe atrophy and wall aneurysms were characteristically localized in the antero-infundibular wall and underneath the tricuspid valve.

### ***Prognostic value of abnormal EVM***

The available data based on autopsy series or observational clinical investigations suggest that predictors of SCD in ARVC patients include the young age at the time of diagnosis, previous cardiac arrest or syncope, VT, severe RV/LV dysfunction and inducibility at PVS (21,22). Our previous retrospective analysis of clinical history of ARVC patients undergoing EVM, suggested that demonstration of bipolar low-voltage areas may be associated with a greater arrhythmic risk in ARVC patients (132). We previously found that during the time interval from onset of symptoms to the invasive study, 55% of patients with evidence of abnormal bipolar-EVM required an ICD because they experienced malignant ventricular tachyarrhythmias, whereas all but one patient with preserved myocardial voltage values remained stable on antiarrhythmic therapy (132). The present study confirms and extends such previous observations by showing that an abnormal-EVM identifies patients at increased risk of major arrhythmic events during a prospective long-term follow-up. We found that the amount of abnormal bipolar-EVM was of independent prognostic significance, with the arrhythmic risk being proportional with the increased amount of abnormal bipolar-EVM. At univariate Cox regression analysis, an abnormal bipolar-EVM was a significant predictor for the composite arrhythmic end point, yielding an HR of 1.7 for every 5% increase in abnormal-EVM; the other variable that was found to predict adverse arrhythmic outcome included history of cardiac arrest or syncope (HR=3.4). However, the extent of abnormal-EVM appeared to be superior to classic clinical risk factors, because at multivariable analysis it remained the only



independent predictor of malignant arrhythmic outcome in our patients population (HR=1.6 per 5%). It is noteworthy that according to the c-statistic method based on survival data, 27.8% abnormal bipolar low-voltage area was the best cut-off value to discriminate between patients with and without major arrhythmic adverse events during follow-up.

### *Arrhythmogenic substrate*

Unlike traditional imaging techniques such as echocardiography and ventriculography which disclose RV mechanical dysfunction (either regional or global) caused by fibro-fatty myocardial replacement, EVM has the ability to accurately identify and quantify low-amplitude RV regions which represent the electrical consequences of RV scar lesions (125-133).

Ventricular tachyarrhythmias in ARVC are frequently the result of a scar-related macro-reentry circuit, similar to that observed in the post-myocardial infarction setting (134-135). Voltage mapping-guided catheter ablation of VT by linear radiofrequency lesions connecting or encircling electroanatomic scar areas has proven to successfully interrupt the arrhythmic reentry circuit in ARVC patients (125-133). In the majority of patients with an abnormal bipolar-EVM we recorded fragmented bipolar electrograms (i.e. > 3 deflections, amplitude  $\leq$  1.5 mV and duration > 70 ms) from within the electroanatomic RV low-voltage. As shown by previous studies on scar-related electrical activity in either ischemic or non ischemic heart disease, these electrographic abnormalities are the result of complex anisotropic propagation of the electrical wave-front through scar tissue which predisposes to the genesis of re-entrant ventricular tachyarrhythmias. Accordingly, we found that EVM provided prognostic value additional to traditional imaging techniques such as echocardiography and angiography, because demonstration of an electroanatomic scar area implies that the RV lesion acts as an arrhythmogenetically active myocardial substrate. This explains why the presence and amount of electroanatomic scar areas were stronger predictors of adverse arrhythmic outcome than traditional hemodynamic RV parameters such as RV dilatation/dysfunction.

### ***Prognostic value of normal EVM***

Failure to detect endocardial low-voltage areas in about one fourth of our patients fulfilling ITF criteria for ARVC remains to be explained. It is relevant that in our study unipolar-EVM unmasked the presence of large regions of confluent abnormal unipolar electrograms in patients with a normal bipolar-EVM as well as identified a greater amount of low-amplitude electrogram area in those with an abnormal bipolar-EVM. The most likely explanation for the discordant unipolar and bipolar-EVM is that fibro-fatty scar involvement of outer RV wall layers (i.e. epi- and mid-myocardium) is detected better with unipolar mapping technique (103,136). Indeed, because the wave front of RV fibrofatty myocardial replacement in ARVC progresses from the epicardium to the endocardium, scar tissue in non-advanced ARVC may be confined to epicardial/midmural layers, sparing (or reaching focally) the endocardial region (23,26). In our study, voltage mapping was limited to the endocardial side of the RV free wall and may have underestimated or missed non-transmural low-voltage areas. Previous studies showed that unipolar EVM recording may accurately predict the location and extent of epicardial electroanatomic scar involvement as evidenced by direct epicardial bipolar voltage mapping (103,136). Polin et al. validated the use of unipolar-EVM to identify confluent areas of signals with an amplitude  $<5.5\text{mV}$  as a strategy for approximating the degree and location of epicardial bipolar voltage abnormality in ARVC patients with only limited endocardial bipolar voltage changes (103). It has been suggested that unipolar-EVM provide a larger “antenna” than bipolar-EVM to detect fibro-fatty substrate involvement of epi- and mid-myocardium which is commonly present in ARVC patients.

It is noteworthy that in our ARVC study population major arrhythmic events occurred exclusively in the group of patients with RV electroanatomic scar involvement on bipolar-EVM (Figure 3). Specifically, ARVC patients with a preserved bipolar voltages through the RV had an

uneventful arrhythmic outcome, regardless of the amount of low amplitude electrocardiogram areas evidenced by unipolar-EVM.

### ***Voltage mapping-enhanced electrophysiologic study***

The results of this study confirm previous data showing that traditional electrophysiological study is of limited value for risk stratification of ARVC patients (21,22). We found that the positive predictive value of PVS for major arrhythmic events was only 32%. On the other hand, a negative PVS could not indicate better prognosis because approximately one fourth of noninducible patients experienced malignant events.

By contrast, Bhosale et. al (137) reported that non-sustained VT and inducibility at PVS were significant predictors of appropriate discharges in ARVC patients who received an ICD for primary prevention. The discrepancy between our study findings and those reported by Bhosale may be related to differences in patient populations, which in the latter study also included subjects with a probable (non definite) ARVC diagnosis, and to different arrhythmic study end-points (i.e. composite arrhythmic end-point versus appropriate ICD intervention alone).

The addition of EVM to traditional intracardiac electrophysiologic study provides significant added value for arrhythmic risk assessment. Although recording of low-voltage, polyphasic, and abnormally wide scar-related electrograms do not necessarily require the use of electromagnetic mapping techniques, the ability of RV-EVM to generate a three-dimensional reconstruction of RV electroanatomic scar regions by spatially associating the abnormal local electrograms offers the potential not only to determine the presence but also to quantify the amount of RV myocardial tissue replaced by scar tissue, which was the most powerful predictor of adverse arrhythmic outcome in our study.

At variance with our results, Santangeli et. al (138) found that fragmented electrograms were the only variable independently associated with arrhythmic events during follow-up in a series of 32 patients with ARVC undergoing bipolar-EVM, while the extent of electroanatomic scar was not predictive of outcome. The discrepancy between study results may be explained by a different abnormal bipolar signals definition and the different patient populations, with the Santangeli's study including a highly selected group of ARVC patients, all showing an abnormal bipolar-EVM and receiving a prophylactic ICD because of inducible sustained monomorphic VT.

### ***Study Limitations***

Although the study cohort was relatively large for ARVC, a small number of patients and outcomes were analyzed, linked predominantly to relatively low disease prevalence and low event rate. The small number of events limits both the power to detect associations and the ability to control completely for all potential confounders in the multivariable models. Nonetheless, we believe that our study results and statistical analysis indicate important trends that are of clinical relevance for arrhythmic risk stratification and management of ARVC patients. Further studies with larger number of patients and longer follow-up are needed to confirm the value of bipolar-EVM for predicting long-term clinical outcome of ARVC patients.

The different rate of ICD implantation (54% of patients with an abnormal bipolar-EVM versus 12% of those with normal bipolar-EVM) may represent a study bias with regard to arrhythmia detection. However, ICD were routinely programmed to include a monitoring zone that identified VT with a rate  $>160$  bpm; this lessens the potential limitation of not homogeneous distribution of ICD, because slower, asymptomatic VTs remained equally undetected in both patient subgroups, regardless of ICD monitoring.

## **CONCLUSIONS**

In conclusion, the results of the present study indicate that RV-EVM has an important prognostic value in ARVC patients and that the arrhythmic risk is related to regional extent of RV scar lesions. RV-EVM should supplement the traditional intracardiac electrophysiologic studies for characterization of the arrhythmic substrate and risk stratification of patients with ARVC/D.

## TABLES

**Table 1.** Clinical characteristics of overall sample and according to results of bipolar-EVM.

	<b>Overall sample N = 69</b>	<b>Abnormal bipolar-EVM N = 53 (77%)</b>	<b>Normal bipolar-EVM N = 16 (23%)</b>	<b>P</b>
Age (yrs)	35 (28-45)	36 (28-46)	34 (28-44)	0.42
Sex (male)	47 (68)	36 (68)	11 (69)	1.00
Family history of sudden death (<35 years)	16 (23)	15 (28)	1(6)	0.12
Family history of ARVC	12 (17)	11 (20)	1(6)	0.34
History of cardiac arrest or syncope	22 (32)	20 (37)	2 (12)	0.07
Right precordial T-wave inversion (V1-V3)	49 (71)	41 (77)	8 (50)	0.04
Positive SAECG	34 (49)	29 (54)	5 (31)	0.13
Premature Ventricular Beats > 1000/24 hours	59 (85)	45 (85)	15 (94)	0.72
Non-sustained VT	44 (63)	33 (62)	11 (69)	0.81
Sustained VT	9 (13)	8 (15)	1 (6)	0.72
RVEDV (ml/m2)	80 (63-97)	82 (65-99)	77 (58-90)	0.09
RVFAC (%)	40 (38-41)	40 (28-30)	40 (28-31)	0.82
LVEDV (ml/m2)	46 (55-75)	65 (55-77)	55 (55-65)	0.94
LVEF (%)	50 (45-60)	50 (46-60)	49 (43-58)	0.26
Multiregional RV-WMA*	25 (36)	22 (41)	3 (19)	0.01
Inducibility at PVS	34 (49)	26 (49)	8 (50)	1.00
- VT	28 (41)	22 (42)	6 (38)	0.93
- VF	6 (9)	4 (8)	2 (13)	0.91
ICD implantation	31 (44)	29 (54)	2 (12)	0.004

\* *multiregional WMA=akinesia, dyskinesia or bulging in  $\geq 2$  RV regions*

Categorical variables are presented as number of patients (%). Continuous values are expressed as median with 25% and 75%-iles. ARVC=arrhythmogenic right ventricular cardiomyopathy; EDV=end diastolic volume; EF=ejection fraction; FAC=fractional area change; LV=left ventricle; PVS=programmed ventricular stimulation; RV=right ventricle; SAECG=signal averaged electrocardiogram; SD=standard deviation; VT=ventricular tachycardia; WMA=wall motion abnormalities.

**Table 2.** Characteristics of patients with and without arrhythmic events during follow-up.

	<b>Events</b> N=19 (28%)	<b>No events</b> N=50 (72%)
Age (yrs)	34 (23-42)	37 (28-47)
Sex (male)	14 (74)	36 (72)
Family history of sudden death (<35 years)	6 (32)	10 (20%)
History of cardiac arrest or syncope	14 (73)	8 (16)
Non-sustained VT	10 (53)	34 (68)
Sustained VT	6 (32)	6 (12)
RVEVD (ml/m2)	80 (55-103)	80 (64-96)
RVFAC (%)	39 (40-41)	39 (38-40)
LVEVD (ml/m2)	59 (54-71)	65 (55-80)
LVEF (%)	50 (45-58)	50 (45-60)
Fragmented bipolar electrograms	15 (79)	32 (64)
Inducibility at PVS	11 (58)	23 (46)
- VT	9 (47)	19 (38)
- VF	2 (11)	4 (8)
Antiarrhythmic drug therapy	15 (79)	42 (84)
Abnormal bipolar-EVM	19 (100)	34 (68)
Abnormal unipolar-EVM	19 (100)	50 (100)

Categorical variables are presented as number of patients (%). Continuous values are expressed as median with 25% and 75%-iles.

Abbreviations as in Table 1.

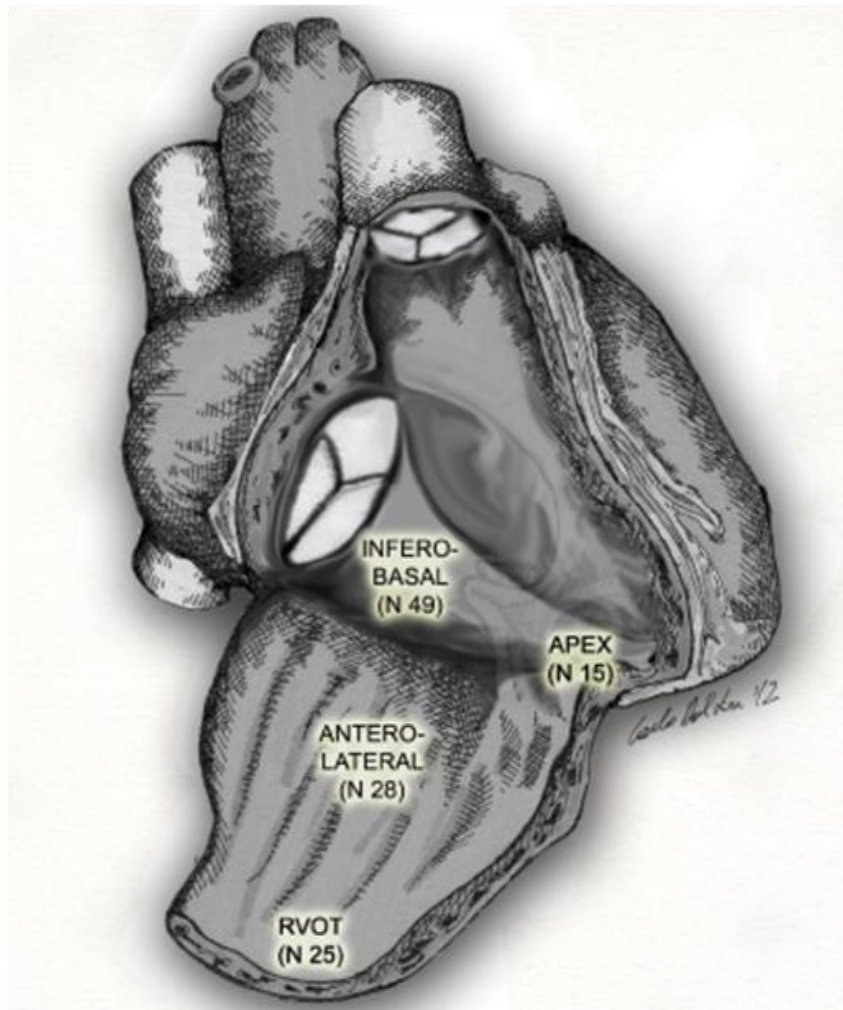
**Table 3.** Predictors of arrhythmic events during follow-up.

	Univariate analysis			Multivariable analysis		
	HR	CI	P	HR	CI	P
Age	1.0	1.0-1.0	0.73			
Sex (male)	1.1	0.4-3.3	0.78			
Family history of sudden death	1.1	0.4-3.0	0.88			
History of cardiac arrest or syncope	3.4	1.4-8.8	0.03	2.4	0.8-6,2	0.11
Non-sustained VT	1.8	0.3-5.7	0.72			
Sustained VT	1.1	0.4-2.5	0.90			
RVEVD (ml/m2)	1.1	0.9-1.3	0.81			
RVFAC (%)	1.0	0.9-1.1	0.52			
LVEVD (ml/m2)	0.9	0.9-1.0	1.0			
LVEF (%)	1.0	0.9-1.1	0.96			
Fragmented bipolar electrograms	1.2	0.7-3.1	0.32			
Inducibility at PVS	1.4	0.5-5.0	0.44			
Antiarrhythmic drug therapy	0.9	0.3-3.4	0.84			
Abnormal bipolar-EVM†	1.7	1.5-2.0	<0.001	1.6	1.2-1.9	<0.001
Abnormal unipolar-EVM†	1.3	0.6-4.3	0.31			

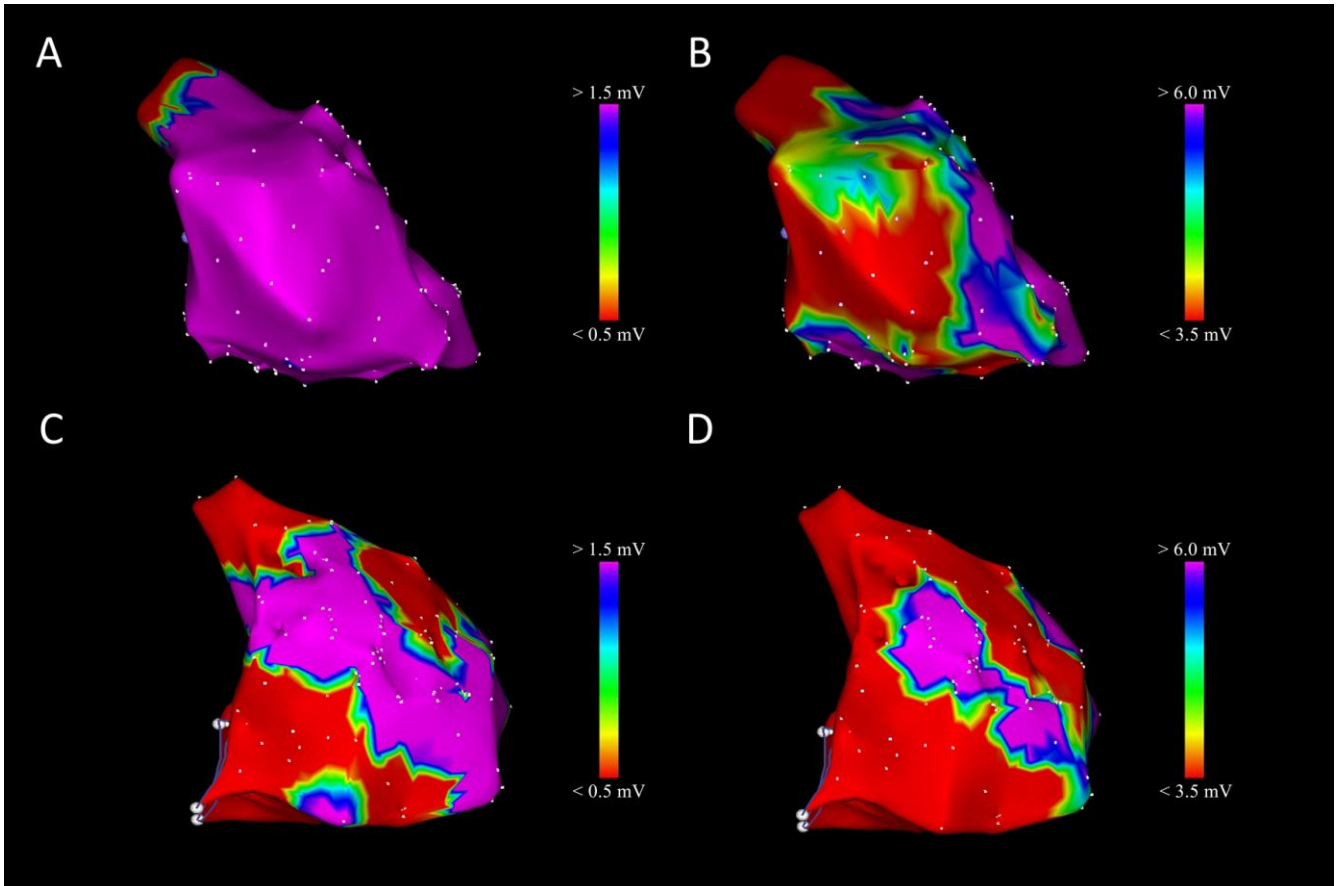
† HR per 5% interval

Abbreviations as in Table 1.





**Figure 1.** The involved right ventricular regions at bipolar-EVM. (From Migliore et al. *Circulation: Arrhythmia and Electrophysiology* 2012. In press)

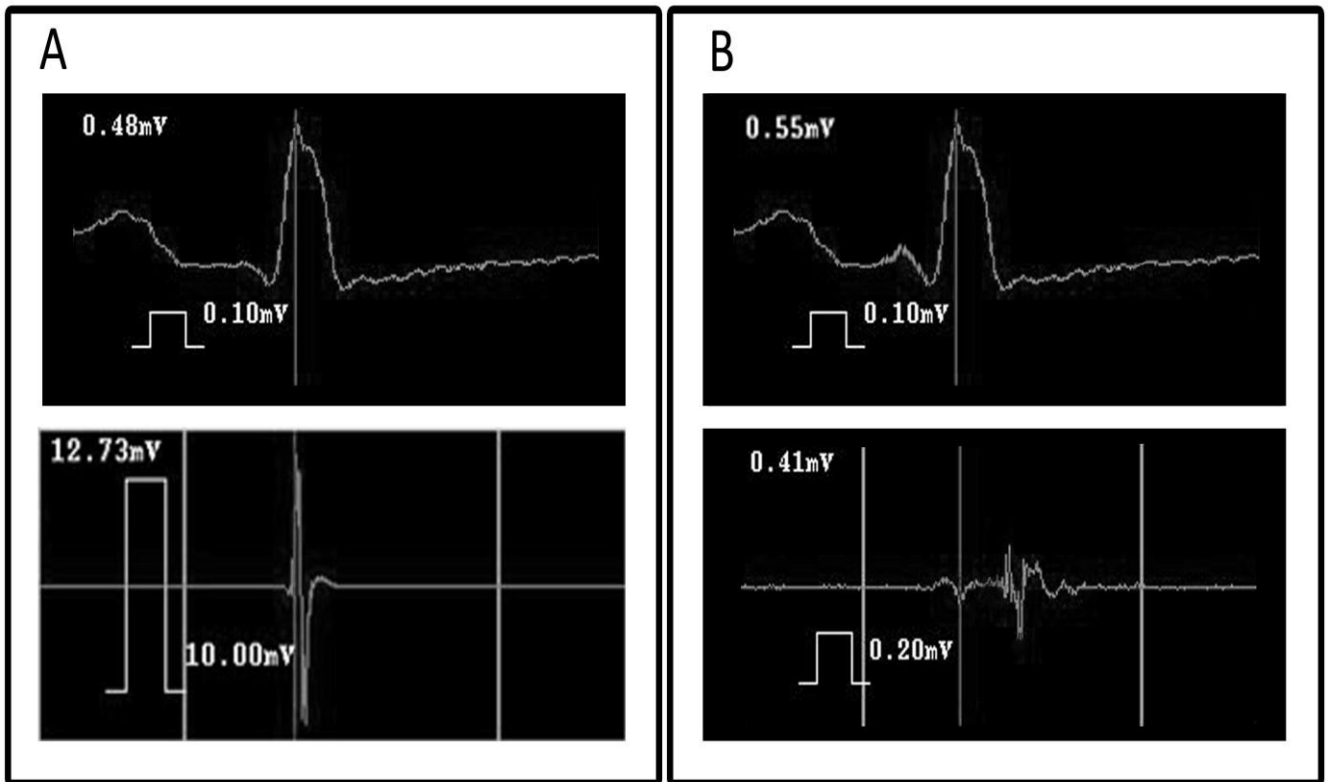


**Figure 2.** Representative bipolar and unipolar RV-EVM from 2 ARVC patients.

- Patient #16: right anterior oblique view of RV bipolar-EVM showing preserved bipolar voltages values (A); right anterior oblique view of RV unipolar-EVM from the same patient unmasking the presence of a significant electroanatomic scar (B).

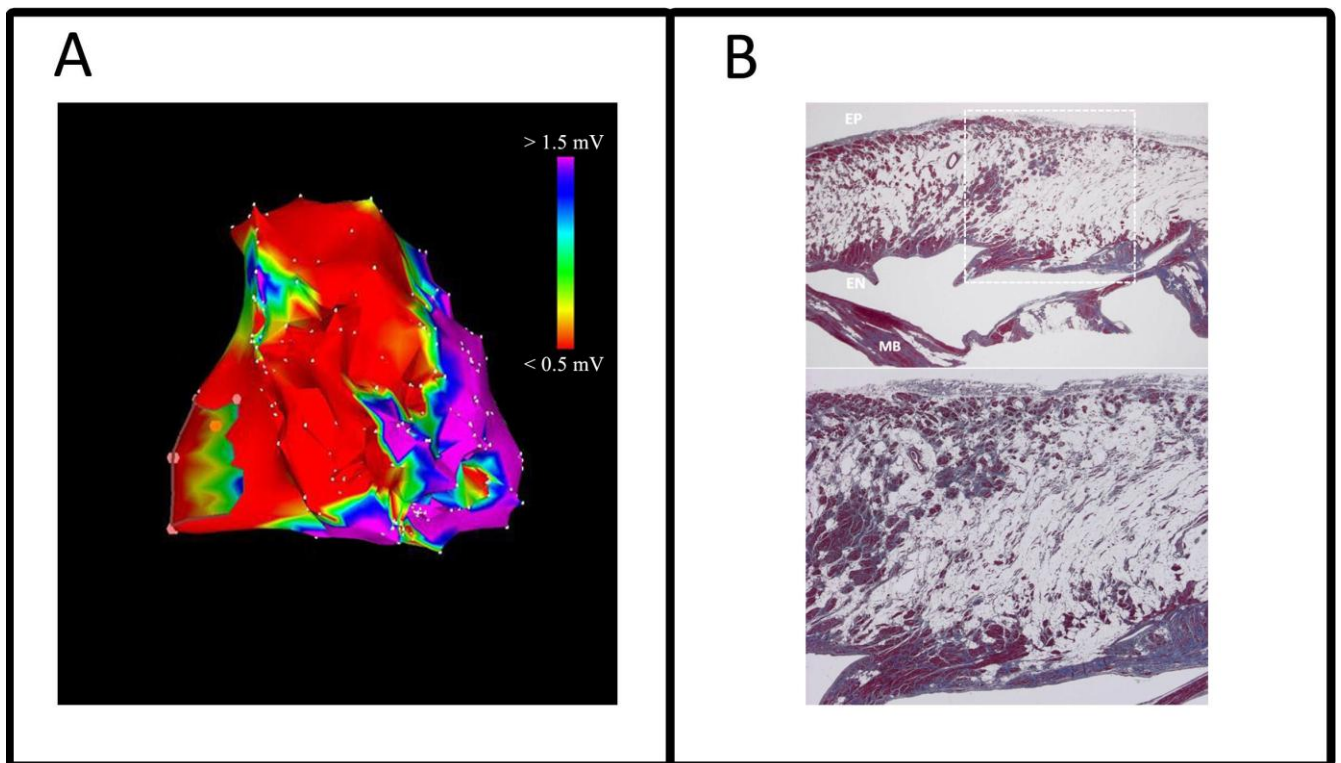
- Patient #47: compared with right anterior oblique view of bipolar RV-EVM (C), unipolar RV-EVM (D) reveals a greater burden of low-voltage electrogram area involving the RVOT, infero-basal and apex regions.

(From Migliore et al. *Circulation: Arrhythmia and Electrophysiology* 2012. In press)



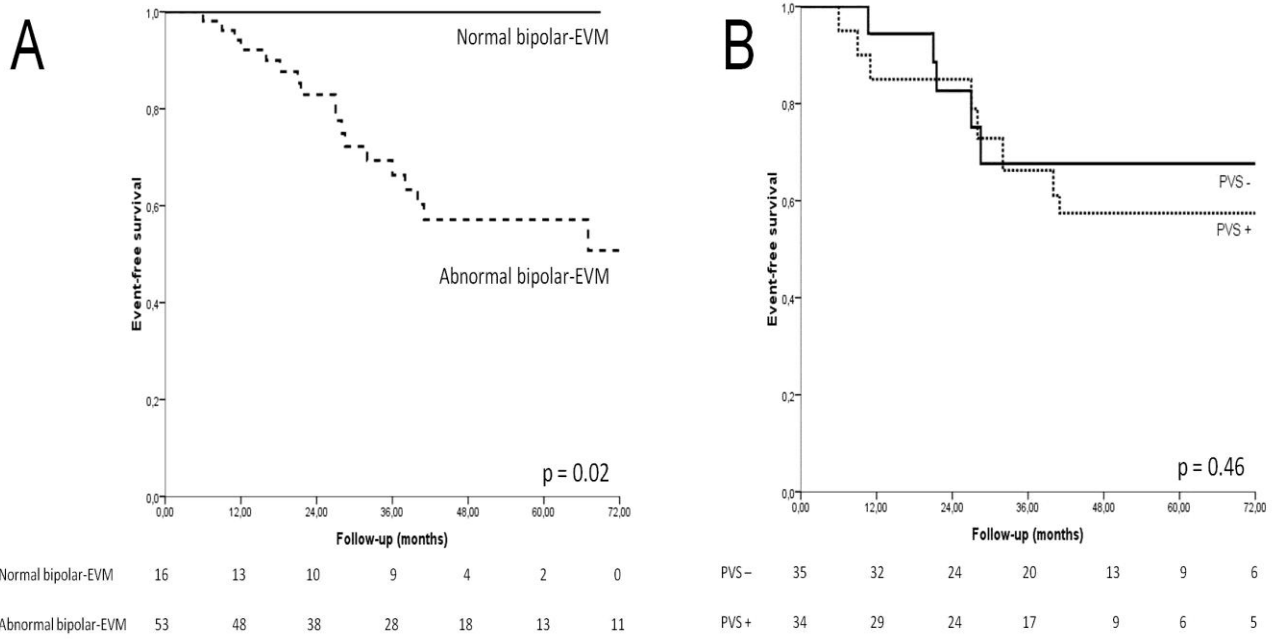
**Figure 3.** Surface ECG (top) and bipolar intracardiac electrocardiograms (bottom) sampled from within normal (A) and low-amplitude (B) RV area in the same ARVC patient. Normal voltage electrogram is characterized by a sharp, biphasic deflection with large amplitude and short duration (A). By comparison, electrogram recorded from low-voltage areas (i.e. electroanatomic scar) are fragmented with late activation and prolonged duration beyond the QRS complex.

(From Migliore et al. *Circulation: Arrhythmia and Electrophysiology* 2012. In press)



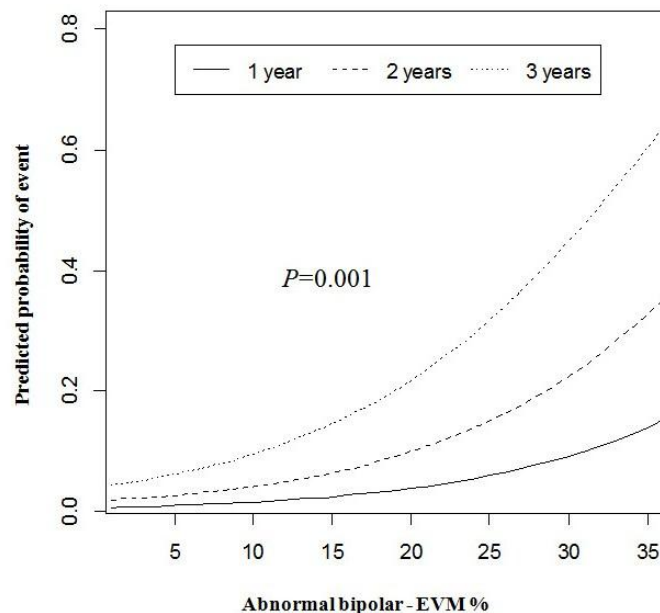
**Figure 4.** Clinico-pathologic correlation between bipolar-EVM and histopathologic findings in a 18-year old ARVC patient who underwent heart transplantation because of refractory VF storms. (A) Antero-posterior view of bipolar-EVM featuring a large RV electroanatomic scar involving the antero-lateral, RVOT and infero-basal regions. (B) Histology of the antero-lateral right ventricular free wall from the native heart coming from transplantation. Panoramic histological section of RV anterior wall (Top) shows the massive and transmural fibro-fatty replacement of the atrophic myocardium (Heidenhain trichrome stain). Close-up of the boxed area details residual myocytes (red) which are embedded within fibrous (blue) and fatty tissue (white) (Heidenhain trichrome stain) (bottom). End=endocardial side; Epi=epicardial side; MB=moderator band.

(From Migliore et al. *Circulation: Arrhythmia and Electrophysiology* 2012. In press)



**Figure 5.** Kaplan-Meier analysis of freedom from adverse events stratified by the presence of abnormal bipolar-EVM (A) and programmed ventricular stimulation (PVS) findings (B).

(From Migliore et al. *Circulation: Arrhythmia and Electrophysiology* 2012. In press)



**Figure 6.** Predicted probability of reaching the combined arrhythmic end point at 1, 2, and 3 years on the basis of the extent of abnormal bipolar-EVM.

(From Migliore et al. *Circulation: Arrhythmia and Electrophysiology* 2012. In press)

## REFERENCES

1. Lancisi GM. De motu cordis et aneurysmatibus. Caput V. Naples (Italy); 1736
2. Laennec RT. Paris, 1904. In: Laennec SH, editor, Savie, son ouvrage, vol. 13. London: Encyclop. Brit; 1956. p. 586
3. Eliot G. Middlemarch. 1st edition. New York, 1871
4. Osler W. The principles and practice of medicine. 6th edition. New York: D. Appleton & Co; 1905. p.20
5. Segall HN. Parchment heart (Osler). Am Heart J 1950;40:948–50
6. UHL HS. A previously undescribed congenital malformation of the heart: almost total absence of the myocardium of the right ventricle. Bull Johns Hopkins Hosp 1952;91:197–209
7. Dalla Volta S, Fameli O, Maschio G. Le syndrome clinique et hemodynamique de l'auricularisation du ventricule droit. Arch Mal Coeur Vaiss 1965;58:1129–43
8. Thiene G, Nava A, Marcus FI. Introduction: arrhythmogenic right ventricular cardiomyopathy/dysplasia clarified. In: Marcus FI, Nava A, Thiene G, editors. Arrhythmogenic right ventricular cardiomyopathy/dysplasia—recent advances. Milano (Italy): Springer; 2007. p. 1–6

9. Thiene G. Storia di una malattia. In: Basso C, Nava A, Thiene G, editors. *La cardiomiopatia aritmogena*. Milano (Italy): Arti Grafiche Color Black; 2001. p. 1–7
10. Fontaine G, Guiraudon G, Frank R, et al. Stimulation studies and epicardial mapping in ventricular tachycardia: study of mechanisms and selection for surgery. In: Kulbertus HE, editor. *Reentrant arrhythmias*. Lancaster (UK): MTP; 1977. p. 334–50
11. Fontaine G, Frank R, Gallais-Hamonno F, et al. Electrocardiographie des potentials tardifs du syndrome de post-excitation. *Arch Mal Coeur Vaiss* 1978;71:854–9
12. Marcus FI, Fontaine G, Guiraudon G, et al. Right ventricular dysplasia. A report of 24 adult cases. *Circulation* 1982;65:384–98.
13. Nava A, Scognamiglio R, Thiene G, et al. A polymorphic form of familial arrhythmogenic right ventricular dyplasia. *Am J Cardiol* 1987;59:1405–9
14. Nava A, Thiene G, Canciani B, et al. Familial occurrence of right ventricular dysplasia: a study involving nine families. *J Am Coll Cardiol* 1988;12:1222–8
15. Thiene G, Nava A, Corrado D, et al. Right ventricular cardiomyopathy and sudden death in young people. *N Engl J Med* 1988;318:129–33
16. Maron BJ. Right ventricular cardiomyopathy. Another cause of sudden death in the young [editorial]. *N Engl J Med* 1988;318:178–9

17. Protonotarios N, Tsatsopoulou A, Scampardonis G. Familial arrhythmogenic right ventricular dysplasia associated with palmoplantar keratosis. *N Engl J Med* 1988;319:174–6
18. Corrado D, Thiene G, Nava A, et al. Sudden death in young competitive athletes: clinicopathologic correlation in 22 cases. *Am J Med* 1990;89:588–96
19. McKenna WJ, Thiene G, Nava A, et al. Diagnosis of arrhythmogenic right ventricular dysplasia/cardiomyopathy. *Br Heart J* 1994;71:215–8
20. Marcus FI, McKenna WJ, Sherrill D, et al. Diagnosis of arrhythmogenic right ventricular cardiomyopathy/dysplasia. Proposed modification of the Task Force criteria. *Circulation* 2010;121:1533–41
21. Corrado D, Leoni L, Link MS, et al. Implantable cardioverter defibrillator therapy for prevention of sudden death in patients with arrhythmogenic right ventricular cardiomyopathy/dysplasia. *Circulation* 2003;108:3084–91
22. Corrado D, Calkins H, Link MS, et al. Prophylactic implantable defibrillator in patients with arrhythmogenic right ventricular cardiomyopathy/dysplasia and no prior ventricular fibrillation or sustained ventricular tachycardia. *Circulation* 2010;122:1144–52
23. Basso C, Thiene G, Valente M, et al. Arrhythmogenic right ventricular cardiomyopathy: dysplasia, dystrophy or myocarditis? *Circulation* 1996;94:983–91



24. Thiene G, Corrado D, Basso C. Cardiomyopathies: is it time for a molecular classification? *Eur Heart J* 2004;25:1772–5
25. Maron BJ, Towbin JA, Thiene G, et al. American Heart Association; Council on Clinical Cardiology, Heart Failure and Transplantation Committee; Quality of Care and Outcomes Research and Functional Genomics and Translational Biology Interdisciplinary Working Groups; Council on Epidemiology and Prevention. Contemporary definitions and classification of the cardiomyopathies: an American Heart Association Scientific Statement from the Council on Clinical Cardiology, Heart Failure and Transplantation Committee; Quality of Care and Outcomes Research and Functional Genomics and Translational Biology Interdisciplinary Working Groups; and Council on Epidemiology and Prevention. *Circulation* 2006;113:1807–16
26. Basso C, Corrado D, Marcus FI, Nava A, Thiene G. Arrhythmogenic right ventricular cardiomyopathy. *Lancet*. 2009;373:1289-1300
27. Corrado D, Basso C, Pilichou K, Thiene G. Molecular biology and clinical management of arrhythmogenic right ventricular cardiomyopathy/dysplasia. *Heart*. 2011;97:530-539
28. Bauce B, Basso C, Rampazzo A, et al. Clinical profile of four families with arrhythmogenic right ventricular cardiomyopathy caused by dominant desmoplakin mutations. *Eur Heart J* 2005;26:1666–75
29. Sen-Chowdhry S, Syrris P, Ward D, et al. Clinical and genetic characterization of families with arrhythmogenic right ventricular dysplasia/cardiomyopathy provides novel insights into patterns of disease expression. *Circulation* 2007;115:1710–20

30. Basso C, Czarnowska E, Della Barbera M, et al. Ultrastructural evidence of intercalated disc remodelling in arrhythmogenic right ventricular cardiomyopathy: an electron microscopy investigation on endomyocardial biopsies. *Eur Heart J* 2006; 27:1847–54
31. Sen-Chowdry S, Syrris P, McKenna WJ. Role of genetic analysis in the management of patients with arrhythmogenic right ventricular dysplasia/cardiomyopathy. *J Am Coll Cardiol* 2007;50:1813–21
32. Corrado D, Fontaine G, Marcus FI, et al. Arrhythmogenic right ventricular dysplasia/cardiomyopathy: need for an International Registry. *Circulation* 2000;101:e101–6
33. Basso C, Wichter T, Danieli GA, et al. Arrhythmogenic right ventricular cardiomyopathy: clinical registry and database, evaluation of therapies, pathology registry, DNA banking. *Eur Heart J* 2004;25:531–4
34. Marcus F, Towbin JA, Zareba W, et al, ARVD/C Investigators. Arrhythmogenic right ventricular dysplasia/cardiomyopathy (ARVD/C): a multidisciplinary study: design and protocol. *Circulation* 2003;107:2975–8
35. Corrado D, Basso C, Thiene G, et al. Spectrum of clinicopathologic manifestations of arrhythmogenic right ventricular cardiomyopathy/dysplasia: a multi center study. *J Am Coll Cardiol* 1997;30:1512–20
36. Thiene G, Corrado D, Basso C. Arrhythmogenic right ventricular cardiomyopathy/dysplasia. *Orphanet J Rare Dis* 2007;2:45

37. Thiene G, Corrado D, Nava A, et al. Right ventricular cardiomyopathy: is there evidence of an inflammatory aetiology? *Eur Heart J* 1991;12:22–5
38. Basso C, Thiene G. Adipositas cordis, fatty infiltration of the right ventricle, and arrhythmogenic right ventricular cardiomyopathy. Just a matter of fat? *Cardiovasc Pathol* 2005;14:37–41
39. Marcus F, Basso C, Gear K, et al. Pitfalls in the diagnosis of arrhythmogenic right ventricular cardiomyopathy/dysplasia. *Am J Cardiol* 2010;105:1036–9
40. Angelini A, Basso C, Nava A, et al. Endomyocardial biopsy in arrhythmogenic right ventricular cardiomyopathy. *Am Heart J* 1996;132:203–6.
41. Basso C, Ronco F, Marcus F, et al. Quantitative assessment of endomyocardial biopsy in arrhythmogenic right ventricular cardiomyopathy/dysplasia: an in vitro validation of diagnostic criteria. *Eur Heart J* 2008;29:2760–71
42. Nava A, Bauce B, Basso C, et al. Clinical profile and long-term follow-up of 37 families with arrhythmogenic right ventricular cardiomyopathy. *J Am Coll Cardiol* 2000;36:2226–33
43. McKoy G, Protonotarios N, Crosby A, et al. Identification of a deletion in plakoglobin in arrhythmogenic keratoderma and woolly hair (Naxos disease). *Lancet* 2000;355:2119–24

44. Norgett EE, Hatsell SJ, Carvajal-Huerta L, et al. Recessive mutation in desmoplakin disrupts desmoplakin-intermediate filament interactions and causes dilated cardiomyopathy, woolly hair and keratoderma. *Hum Mol Genet* 2000;9:2761–6
45. Alcalai R, Metzger S, Rosenheck S, et al. A recessive mutation in desmoplakin causes arrhythmogenic right ventricular dysplasia, skin disorder, and woolly hair. *J Am Coll Cardiol* 2003;42:319–27
46. Rampazzo A, Nava A, Malacrida S, et al. Mutation in human desmoplakin domain binding to plakoglobin causes a dominant form of arrhythmogenic right ventricular cardiomyopathy. *Am J Hum Genet* 2002;71:1200–6
47. Gerull B, Heuser A, Wichter T, et al. Mutations in the desmosomal protein plakophilin-2 are common in arrhythmogenic right ventricular cardiomyopathy. *Nat Genet* 2004;36:1162–4
48. Pilichou K, Nava A, Basso C, et al. Mutations in desmoglein-2 gene are associated with arrhythmogenic right ventricular cardiomyopathy. *Circulation* 2006;113:1171–9
49. Syrris P, Ward D, Evans A, et al. Arrhythmogenic right ventricular dysplasia/cardiomyopathy associated with mutations in the desmosomal gene desmocollin-2. *Am J Hum Genet* 2006;79:978–84
50. Asimaki A, Syrris P, Wichter T, et al. A novel dominant mutation in plakoglobin causes arrhythmogenic right ventricular cardiomyopathy. *Am J Hum Genet* 2007;81:964–73

51. Klauke B, Kossmann S, Gaertner A, et al. De novo desmin-mutation N116S is associated with arrhythmogenic right ventricular cardiomyopathy. *Hum Mol Genet* 2010;19:4595–607
52. Tiso N, Stephan DA, Nava A, et al. Identification of mutations in the cardiac ryanodine receptor gene in families affected with arrhythmogenic right ventricular cardiomyopathy type 2 (ARVD2). *Hum Mol Genet* 2001;10:189–94
53. Beffagna G, Occhi G, Nava A, et al. Regulatory mutations in transforming growth factor-beta3 gene cause arrhythmogenic right ventricular cardiomyopathy type 1. *Cardiovasc Res* 2005;65:366–73
54. Merner ND, Hodgkinson KA, Haywood AF, et al. Arrhythmogenic right ventricular cardiomyopathy type 5 is a fully penetrant, lethal arrhythmic disorder caused by a missense mutation in the TMEM43 gene. *Am J Hum Genet* 2008;82:809–21
55. Corrado D, Thiene G. Arrhythmogenic right ventricular cardiomyopathy/dysplasia: clinical impact of molecular genetic studies. *Circulation* 2006;113:1634–7
56. Baucé B, Nava A, Beffagna G, et al. Multiple mutations in desmosomal proteins encoding genes in arrhythmogenic right ventricular cardiomyopathy/dysplasia. *Heart Rhythm* 2010;7:22–9
57. Xu T, Yang Z, Vatta M, et al. Multidisciplinary Study of Right Ventricular Dysplasia Investigators. Compound and digenic heterozygosity contributes to arrhythmogenic right ventricular cardiomyopathy. *J Am Coll Cardiol* 2010;55:587–97

58. Kaplan SR, Gard JJ, Protonotarios N, et al. Remodeling of myocyte gap junctions in arrhythmogenic right ventricular cardiomyopathy due to a deletion in plakoglobin (Naxos disease). *Heart Rhythm* 2004;1:3–11
59. Kaplan SR, Gard JJ, Carvajal-Huerta L, et al. Structural and molecular pathology of the heart in Carvajal syndrome. *Cardiovasc Pathol* 2004;13:26–32
60. Asimaki A, Tandri H, Huang H, et al. A new diagnostic test for arrhythmogenic right ventricular cardiomyopathy. *N Engl J Med* 2009;360:1075–84
61. Bowles NE, Ni J, Marcus F, et al. The detection of cardiotropic viruses in the myocardium of patients with arrhythmogenic right ventricular dysplasia/cardiomyopathy. *J Am Coll Cardiol* 2002;39:892–5
62. Calabrese F, Basso C, Carturan E, et al. Arrhythmogenic right ventricular cardiomyopathy/dysplasia: is there a role for viruses? *Cardiovasc Pathol* 2006;15:11–7
63. Pilichou K, Remme CA, Basso C, et al. Myocyte necrosis underlies progressive myocardial dystrophy in mouse *dsg2*-related arrhythmogenic right ventricular cardiomyopathy. *J Exp Med* 2009;206:1787–802
64. Mallat Z, Tedgui A, Fontaliran F, et al. Evidence of apoptosis in arrhythmogenic right ventricular dysplasia. *N Engl J Med* 1996;335:1190–6
65. Valente M, Calabrese F, Thiene G, et al. In vivo evidence of apoptosis in arrhythmogenic right ventricular cardiomyopathy. *Am J Pathol* 1998;152:479–84

66. Huber O. Structure and function of desmosomal proteins and their role in development and disease. *Cell Mol Life Sci* 2003;60:1872–90
67. Desai BV, Harmon RM, Green KJ. Desmosomes at a glance. *J Cell Sci* 2009;122:4401–7
68. Green KJ, Getsios S, Troyanovsky S, et al. Intercellular junction assembly, dynamics, and homeostasis. *Cold Spring Harb Perspect Biol* 2010;2:a000125
69. Sato PY, Musa H, Coombs W, et al. Loss of plakophilin-2 expression leads to decreased sodium current and slower conduction velocity in cultured cardiac myocytes. *Circ Res* 2009;105:523–6
70. Delmar M, McKenna WJ. The cardiac desmosome and arrhythmogenic cardiomyopathies: from gene to disease. *Circ Res* 2010;107:700–14
71. Yang Z, Bowles NE, Scherer SE, et al. Desmosomal dysfunction due to mutations in desmoplakin causes arrhythmogenic right ventricular dysplasia/cardiomyopathy. *Circ Res* 2006;99:646–55
72. Garcia-Gras E, Lombardi R, Giocondo MJ, et al. Suppression of canonical Wnt/beta-catenin signalling by nuclear plakoglobin recapitulates phenotype of arrhythmogenic right ventricular cardiomyopathy. *J Clin Invest* 2006;116:2012–21
73. Sen-Chowdhry S, Prasad SK, Syrris P, et al. Cardiovascular magnetic resonance in arrhythmogenic right ventricular cardiomyopathy revisited: comparison with task force criteria and genotype. *J Am Coll Cardiol* 2006;48:2132–40

74. Protonotarios N, Tsatsopoulou A. The Naxos disease. In: Nava A, Rossi L, Thiene G, editors. Arrhythmogenic right ventricular dysplasia/cardiomyopathy. Elsevier Science B.V; 1997. p. 454–62
75. Fontaine G, Fontaliran F, Frank R. Arrhythmogenic right ventricular cardiomyopathies. Clinical forms and main differential diagnoses. *Circulation* 1998;97:1532–5
76. Fontaine G, Fontaliran F, He´bert JL, et al. Arrhythmogenic right ventricular dysplasia. *Annu Rev Med* 1999;50:17–35
77. Protonotarios N, Tsatsopoulou A, Gatzoulis K. Arrhythmogenic right ventricular cardiomyopathy caused by a deletion in plakoglobin (Naxos disease). *Card Electrophysiol Rev* 2002;6:72–80
78. Hulot JS, Jouven X, Empana JP, et al. Natural history and risk stratification of arrhythmogenic right ventricular cardiomyopathy. *Circulation* 2004;110:1879–84
79. Fontaine G, Umemura J, Di Donna P, et al. Duration of QRS complexes in arrhythmogenic right ventricular dysplasia. A new non-invasive diagnostic marker. *Ann Cardiol Angeiol (Paris)* 1993;42(8):399–405
80. Peters S, Trummel M. Diagnosis of arrhythmogenic right ventricular dysplasia-cardiomyopathy: value of standard ECG revisited. *Ann Noninvasive Electrocardiol* 2003;8:238–45



81. Cox MG, Nelen MR, Wilde AA, et al. Activation delay and VT parameters in arrhythmogenic right ventricular dysplasia/cardiomyopathy: towards improvement of diagnostic ECG criteria. *J Cardiovasc Electrophysiol* 2008;19:775–81
82. Tandri H, Saranathan M, Rodriguez R, et al. Noninvasive detection of myocardial fibrosis in arrhythmogenic right ventricular cardiomyopathy using delayed enhancement magnetic resonance imaging. *J Am Coll Cardiol* 2005;45:98–103
83. Bomma C, Rutberg J, Tandri H, et al. Misdiagnosis of arrhythmogenic right ventricular dysplasia/cardiomyopathy. *J Cardiovasc Electrophysiol* 2004;15:300–6
84. Marra MP, Leoni L, Bauce B et al. Imaging study of ventricular scar in arrhythmogenic right ventricular cardiomyopathy: comparison of 3D standard electroanatomical voltage mapping and contrast-enhanced cardiac magnetic resonance. *Circ Arrhythm Electrophysiol*. 2012;5:91-100
85. Vasaiwala SC, Finn C, Delpriore J, et al. Prospective study of cardiac sarcoid mimicking arrhythmogenic right ventricular dysplasia. *J Cardiovasc Electrophysiol* 2009;20:473–6
86. Marcus FI, Zareba W, Calkins H, et al. Arrhythmogenic right ventricular cardiomyopathy/dysplasia clinical presentation and diagnostic evaluation: results from the North American Multidisciplinary Study. *Heart Rhythm* 2009;6:984–92
87. Corrado D, Basso C, Pavei A, et al. Trends in sudden cardiovascular death in young competitive athletes after implementation of a preparticipation screening program. *JAMA* 2006;296:1593–601

88. Buja G, Estes NA, Wichter T, et al. Arrhythmogenic right ventricular cardiomyopathy/dysplasia: risk stratification and therapy. *Prog Cardiovasc Dis* 2008;50:282–93
89. Canu G, Atallah G, Claudel JP, et al. Pronostic et e´volution a` long term de la dysplasie arythmoge`ne du ventricule droit. *Arch Mal Coeur Vaiss* 1993;86:41–8
90. Marcus FI, Fontaine GH, Frank R, et al. Long-term followup in patients with arrhythmogenic right ventricular disease. *Eur Heart J* 1989;10(Suppl D):68–73
91. Turrini P, Corrado D, Basso C, et al. Dispersion of ventricular depolarization-repolarization: a non invasive marker for risk stratification in arrhythmogenic right ventricular cardiomyopathy. *Circulation* 2001;103:3075–80
92. Corrado D, Basso C, Rizzoli G, et al. Does sports activity enhance the risk of sudden death in adolescents and young adults? *J Am Coll Cardiol* 2003;42:1959–63
93. Kirchhof P, Fabritz L, Zwiener M, et al. Age- and training-dependent development of arrhythmogenic right ventricular cardiomyopathy in heterozygous plakoglobin-deficient mice. *Circulation* 2006;114:1799–806
94. Turrini P, Angelini A, Thiene G, et al. Late potentials and ventricular arrhythmias in arrhythmogenic right ventricular cardiomyopathy. *Am J Cardiol* 1999;83:1214–9
95. Wichter T, Paul M, Wollmann C, et al. Implantable cardioverter/defibrillator therapy in arrhythmogenic right ventricular cardiomyopathy: single-center experience of long-term follow-up and complications in 60 patients. *Circulation* 2004;109:1503–8

96. Leclercq JF, Potenza S, Maison-Blanche P, et al. Determinants of spontaneous occurrence of sustained monomorphic ventricular tachycardia in right ventricular dysplasia. *J Am Coll Cardiol* 1996;28:720–4
97. Marchlinski FE, Callans DJ, Gottlieb CD, et al. Linear ablation lesions for control of unmappable ventricular tachycardia in patients with ischemic and nonischemic cardiomyopathy. *Circulation* 2000;101:1288–96
98. Marchlinski FE, Zado E, Dixit S, et al. Electroanatomic substrate and outcome of catheter ablative therapy for ventricular tachycardia in setting of right ventricular cardiomyopathy. *Circulation* 2004;110:2293–8
99. Miljoen H, State S, de Chillou C, et al. Electroanatomic mapping characteristics of ventricular tachycardia in patients with arrhythmogenic right ventricular cardiomyopathy/dysplasia. *Europace* 2005;7(6):516–24
100. Verma A, Kilicaslan F, Schweikert RA, et al. Short and long-term success of substrate-based mapping and ablation of ventricular tachycardia in arrhythmogenic right ventricular dysplasia. *Circulation* 2005;111:3209–16
101. Satomi K, Kurita T, Suyama K, et al. Catheter ablation of stable and unstable ventricular tachycardias in patients with arrhythmogenic right ventricular dysplasia. *J Cardiovasc Electrophysiol* 2006;17:469–76

102. Garcia FC, Bazan V, Zado ES, et al. Epicardial substrate and outcome with epicardial ablation of ventricular tachycardia in arrhythmogenic right ventricular cardiomyopathy/dysplasia. *Circulation* 2009;120:366–75
103. Polin G, Hutchinson MD, Garcia FC, et al. Endocardial unipolar voltage mapping more accurately predicts epicardial scar than endocardial bipolar mapping in an ARVD population. *Heart Rhythm* 2009;6:S118
- .
104. Riley MP, Zado ES, Hutchinson MD, et al. Lack of uniform progression of endocardial scar in patients with arrhythmogenic right ventricular dysplasia/cardiomyopathy and ventricular tachycardia. *Heart Rhythm* 2008;5:S74
105. Wichter T, Borggrefe M, Haverkamp W, et al. Efficacy of antiarrhythmic drugs in patients with arrhythmogenic right ventricular disease. Results in patients with inducible and noninducible ventricular tachycardia. *Circulation* 1992;86:29–37
106. Wichter T, Paul TM, Eckardt L, et al. Arrhythmogenic right ventricular cardiomyopathy. Antiarrhythmic drugs, catheter ablation, or ICD? *Herz* 2005;30:91–101
107. Marcus GM, Glidden DV, Polonsky B, et al. Efficacy of antiarrhythmic drugs in arrhythmogenic right ventricular cardiomyopathy: a report from the North American ARVC Registry. *J Am Coll Cardiol* 2009;54:609–15
108. Corrado D, Basso C, Thiene G. Sudden death in young athletes. *Lancet* 2005;366 (Suppl 1):S47–8

109. Maron BJ. Sudden death in young athletes. *N Engl J Med* 2003;349:1064–75
110. Corrado D, Basso C, Schiavon M, et al. Screening for hypertrophic cardiomyopathy in young athletes. *N Engl J Med* 1998;339:364–9
111. Corrado D, Basso C, Rizzoli G, et al. Does sports activity enhance the risk of sudden death in adolescents and young adults? *J Am Coll Cardiol* 2003;42:1959–63
112. Corrado D, Migliore F, Bevilacqua M et al. Sudden cardiac death in Athletes. Can it be prevented by screening? *Herz* 2009;34:259-66
113. Corrado D, Basso C, Schiavon M, et al. Pre-participation screening of young competitive athletes for prevention of sudden cardiac death. *J Am Coll Cardiol* 2008;52:1981–9
114. Van Camp SP, Bloor CM, Mueller FO, et al. Non-traumatic sports death in high school and college athletes. *Med Sci Sports Exerc* 1995;27:641–7
115. Maron BJ, Gohman TE, Aeppli D. Prevalence of sudden cardiac death during competitive sports activities in Minnesota high school athletes. *J Am Coll Cardiol* 1998;32:1881–4
116. Corrado D, Migliore F, Basso C, et al. Exercise and the risk of sudden cardiac death. *Herz* 2006;31:553–8
117. Corrado D, Basso C, Pelliccia A, et al. Sports and heart disease. In: Camm J, Luscher TF, Serruys PW, editors. *The ESC textbook of cardiovascular medicine*. New York: Oxford University Press; 2009. p.1215–37

118. Corrado D, Pelliccia A, Bjornstad HH, et al. Cardiovascular pre-participation screening of young competitive athletes for prevention of sudden death:proposal for a common European protocol. Consensus Statement of the Study Group of Sport Cardiology of the Working Group of Cardiac Rehabilitation and Exercise Physiology and the Working Group of Myocardial and Pericardial Diseases of the European Society of Cardiology. *Eur Heart J* 2005;26:516–24
119. Pelliccia A, Di Paolo FM, Quattrini FM et al. Outcomes in athletes with marked ECG repolarization abnormalities. *N Engl J Med*. 2008;358:152–161
120. Pelliccia A, Maron BJ, Culasso F et al. Clinical significance of abnormal electrocardiographic patterns in trained athletes. *Circulation*. 2000;102:278 –284
121. Pelliccia A, Culasso F, Di Paolo FM et al. Prevalence of abnormal electrocardiograms in a large, unselected population undergoing pre-participation cardiovascular screening. *Eur Heart J*. 2007;28:2006 –2010
122. Papadakis M, Basavarajaiah S, Rawlins J et al. Prevalence and significance of T-wave inversions in predominantly Caucasian adolescent athletes. *Eur Heart J*. 2009;30:1728–1735.
123. Corrado D, Pelliccia A, Heidbuchel H et al. Recommendations for interpretation of 12-lead electrocardiogram in the athlete. *Eur Heart J*. 2010;31:243–259
124. Migliore F, Zorzi A, Michieli P et al. Prevalence of cardiomyopathy in Italian asymptomatic children with electrocardiographic T-wave inversion at preparticipation screening. *Circulation*. 2012;125(3):529-38

125. Klein H, Karp RB, Kouchousus NT et al. (Intraoperative electrophysiologic mapping of the ventricles during sinus rhythm in patients with a previous myocardial infarction. Identification of the electrophysiologic substrate of ventricular arrhythmia. *Circulation*; 1982;66:847-854
126. Cassidy DM, Vassallo JA, Miller JM, et al. Endocardial catheter mapping in patients in sinus rhythm: relationship to underlying heart disease and ventricular arrhythmias. *Circulation* 1986;73:645–52
127. Gepstein L, Goldin A, Lessick J, et al. Electromechanical characterization of chronic myocardial infarction in the canine coronary occlusion model. *Circulation*;1998:2055–64
128. Kornowski R, Hong MK, Gepstein L, et al.. Preliminary animal and clinical experiences using an electromechanical endocardial mapping procedure to distinguish infarcted from healthy myocardium. *Circulation*; 1998;98:1116–24
129. Smeets JLRM, Ben-Haim SA, Rodriguez LM, et al. New method for nonfluoroscopic endocardial mapping in humans : accuracy assessment and first clinical results. *Circulation* 1998;97:2426-2432
130. Callans DJ, Ren JF, Michele J, et al. Electroanatomic left ventricular mapping in the porcine model of healed anterior myocardial infarction: correlation with intracardiac echocardiography and pathological analysis. *Circulation* 199;100:1744–50
131. Boulos M, Lashevsky I, Reisner S, et al. Electroanatomical mapping of arrhythmogenic right ventricular dysplasia. *J Am Coll Cardiol* 2001;38:2020-7.
132. Corrado D, Basso C, Leoni L, et al. Three-dimensional electroanatomic voltage mapping increases accuracy of diagnosing arrhythmogenic right ventricular cardiomyopathy/dysplasia. *Circulation* 2005;111:3042-50

133. Corrado D, Basso C, Leoni L, et al. Three-dimensional electroanatomical voltage mapping and histologic evaluation of myocardial substrate in right ventricular outflow tract tachycardia. *J Am Coll Cardiol*. 2008;51:731-739
134. Fontaine G, Frank R, Tonet JL et al. Arrhythmogenic right ventricular dysplasia: a clinical model for the study of chronic ventricular tachycardia. *Jpn Circ J*. 1984;4:515-538
135. Ellison KE, Friedman PL, Ganz LI, Stevenson WG. Entrainment mapping and radiofrequency catheter ablation of ventricular tachycardia in right ventricular dysplasia. *J Am Coll Cardiol* 1998;32:724–728
136. Hutchinson MD, Gerstenfeld EP, Desjardins B et al. Endocardial unipolar voltage mapping to detect epicardial ventricular tachycardia substrate in patients with nonischemic left ventricular cardiomyopathy. *Circ Arrhythm Electrophysiol* 2011;4:49-55
137. Bhonsale A, James CA, Tichnell C, Murray B et al. Incidence and predictors of implantable cardioverter-defibrillator therapy in patients with arrhythmogenic right ventricular dysplasia/cardiomyopathy undergoing implantable cardioverter-defibrillator implantation for primary prevention. *J Am Coll Cardiol* 2011;58:1485-1496
138. Santangeli P, Dello Russo A, Pieroni M, Casella M, Di Biase L, Burkhardt JD, Sanchez J, Lakkireddy D, Carbucicchio C, Zucchetti M, Pelargonio G, Themistoclakis S, Camporeale A, Rossillo A, Beheiry S, Hongo R, Bellocci F, Tondo C, Natale A. Fragmented and delayed electrograms within fibrofatty scar predict arrhythmic events in arrhythmogenic right ventricular cardiomyopathy: Results from a prospective risk stratification study. *Heart Rhythm*. 2012;9:1200-6



## **Publications by Dr. Federico Migliore**

1. Migliore F, Zorzi, Silvano M, Bevilacqua M, Leoni L, Perazzolo Marra, Elmaghawry M, Brugnaro L, Dal Lin C, Bauce B, Rigato I, Tarantini G, Basso C, Buja G, Thiene G, Iliceto S, Corrado D. PROGNOSTIC VALUE OF ENDOCARDIAL VOLTAGE MAPPING IN patients with Arrhythmogenic Right Ventricular Cardiomyopathy/DYSPLASIA. *circulation: Arrhythmia and Electrophysiology* 2012

2. Migliore F, Maffei E, Perazzolo Marra M, Bilato C, Napodano M, Corbetti F, Zorzi A, Andres AL, Sarais C, Cacciavillani L, Favaretto E, Martini C, Seitun S, Cademartiri F, Corrado D, Iliceto S, Tarantini G. LAD Coronary Artery Myocardial Bridging and Apical Ballooning Syndrome. *JACC Cardiovasc Imaging*. 2013;6:32-41

3. Zorzi A, Migliore F, Corrado D. Authors' Response to Letter to the Editor "Electrocardiogram in Myocardial Edema due to Takotsubo Syndrome" by John Madias. *J Electrocardiol*. 2013;46:75

4. Migliore F, Zorzi A, Peruzza F, Perazzolo Marra M, Tarantini G, Iliceto S, Corrado D. Incidence and management of life-threatening arrhythmias in Takotsubo syndrome. *Int J Cardiol*. 2012 [Epub ahead of print]

5. Perazzolo Marra M, Zorzi A, Corbetti F, De Lazzari M, Migliore F, Tona F, Tarantini G, Iliceto S, Corrado D. Apicobasal gradient of left ventricular myocardial edema underlies transient T-wave inversion and QT interval prolongation (Wellens' ECG pattern) in Tako-Tsubo cardiomyopathy. *Heart Rhythm*. 2013;10:70-7

6. Migliore F, Zorzi A, Perazzolo Marra M, Corbetti F, Corrado D, Iliceto S, Tarantini G. Typical and atypical Takotsubo syndrome in the same patient. *Int J Cardiol*. 2013 Jan 10;162:28-30

7. Zorzi A, Migliore F, Perazzolo Marra M, Tarantini G, Iliceto S, Corrado D. Electrocardiographic J waves as a hyperacute sign of Takotsubo syndrome. *J Electrocardiol*. 2012;45:353-6

8. Zorzi A, Migliore F, Marras E, Marinelli A, Baritussio A, Allocca G, Leoni L, Perazzolo Marra M, Basso C, Buja G, Thiene G, Iliceto S, Delise P, Corrado D. Should all individuals with a nondiagnostic Brugada-electrocardiogram undergo sodium-channel blocker test? *Heart Rhythm*. 2012 Jun;9:909-16

9. Migliore F, Zorzi A, Michieli P, Perazzolo Marra M, Siciliano M, Rigato I,

- Bauce B, Basso C, Toazza D, Schiavon M, Iliceto S, Thiene G, Corrado D. Prevalence of cardiomyopathy in Italian asymptomatic children with electrocardiographic T-wave inversion at preparticipation screening. *Circulation*. 2012;125:529-38
10. Marra MP, Leoni L, Bauce B, Corbetti F, Zorzi A, Migliore F, Silvano M, Rigato I, Tona F, Tarantini G, Cacciavillani L, Basso C, Buja G, Thiene G, Iliceto S, Corrado D. Imaging study of ventricular scar in arrhythmogenic right ventricular cardiomyopathy: comparison of 3D standard electroanatomical voltage mapping and contrast-enhanced cardiac magnetic resonance. *Circ Arrhythm Electrophysiol*. 2012;5:91-100
11. Folino AF, Migliore F, Porta A, Cerutti S, Iliceto S, Buja G. Syncope while driving: pathophysiological features and long-term follow-up. *Auton Neurosci*. 2012;166:60-5
12. Folino AF, Breda R, Calzavara P, Migliore F, Iliceto S, Buja G. In-home controls of pacemakers in debilitated elderly patients. *Geriatr Gerontol Int*. 2012;12:30-5
13. Migliore F, Zorzi A, Marra MP, Basso C, Corbetti F, De Lazzari M, Tarantini G, Buja P, Lacognata C, Thiene G, Corrado D, Iliceto S. Myocardial edema underlies dynamic T-wave inversion (Wellens' ECG pattern) in patients with reversible left ventricular dysfunction. *Heart Rhythm*. 2011;8:1629-34
14. Migliore F, Folino AF, Bilato C, Corrado D, Leoni L, Iliceto S, Buja G. Origin of recurrent syncope in patient with right ventricular outflow tract arrhythmias: evidence of autonomic modulation of the ectopic foci. *J Cardiovasc Med* 2011;12:598-600
15. Migliore F, Bilato C, Isabella G, Iliceto S, Tarantini G. Haemodynamic effects of acute intravenous metoprolol in apical ballooning syndrome with dynamic left ventricular outflow tract obstruction. *Eur J Heart Fail*. 2010;12:305-8
16. Folino AF, Migliore F, Marinelli A, Iliceto S, Buja G. Age-related hemodynamic changes during vasovagal syncope. *Auton Neurosci*. 2010;156:131-7
17. Migliore F, Zorzi A, Silvano M, Rigato I, Basso C, Thiene G, Corrado D. Clinical management of arrhythmogenic right ventricular cardiomyopathy: an update. *Curr Pharm Des*. 2010;16:2918-28
18. Migliore F, Leoni L, Torregrossa G, Guglielmi C, Tarantini G, Buja G, Iliceto S, Corrado D. Asymptomatic right ventricular perforation by an implantable cardioverter defibrillator lead detected by home monitoring system. *J Electrocardiol*. 2010;43:673-5