

Abstract

Introduction

Many evidence confirm that tuberculosis (TB) has been a constant disease of man throughout all his history. Moreover, till now it is one of the most important and dangerous diseases that are presently undergoing re-emergence: each year the number of new cases and the appearance of multiresistant tubercle bacilli are constantly increasing. Although human TB, principally caused by two members (*M. bovis* and *M. tuberculosis*) of the pathogenic *Mycobacterium tuberculosis* complex, is primarily the involvement a soft tissue infection, clinical data show skeletal involvement: for extrapulmonary TB, the rates for all osseous changes range from 1% to 9% (data from various authors reported by Santos, 2001), in the pre-antibiotic era the incidence of skeletal involvement is calculated in average 5-7% (Steinbock, 1976).

The characteristic bone alterations in tuberculosis are the consequence of the development of granulation tissue, with a specific tropism for the richly vascularized sites. The diagnosis of TB in archeological human remains relies on the analysis of disease expression: lesion morphology, location and skeletal pattern.

The skeletal alterations that actually are connected with tuberculosis can be gathered in “classical TB alterations” and in “MOLAT”, (“Minor Osseous Lesions Attributable to Tuberculosis”). The first group consists of characteristic alterations for which there are several clinical and paleopathological literature and osteological collections as referred: they represent TB skeletal changes already in developed stage. The second group of lesions (MOLAT) analyzes the early stages of disease to identify some diagnostic criteria to recognize it, and they don't have the general consensus of all authors. In particular, the MOLAT characteristics are periosteal appositions on the visceral surface of ribs, endocranial changes, hypervascularization of vertebrae and hypertrophic osteoarthropaty.

Objective

The present work studies a small osteological collection (Tedeschi Osteological Collection, T.O.C, of University of Padova, Italy), which was collected with didactical purposes in the years from the end of 19th century to the early 20th century in which cause of death, age at death and job are registered. This collection could be a potential source of information, but it was unknown till now. The aim of the present study is to recover this collection analyzing the TB remains looking for the classical alterations and the MOLAT. Using classical morphological anthropology, histology, radiology, molecular biology and densitometry of bone tissue, we try to confirm the various diagnostic criteria. Furthermore, this work, based on data arising before antibiotics became available for treatment, might contribute to the future diagnosis of TB or other pathologies in non-documented skeletal material.

Material and methods

We have organized a work schedule with different exams to carry out in each individual recovered. This work form includes several aspects: individualization of remains, morphological study of diseases, histological and molecular analyses, bone density determination, and radiological exams.

The individualization of remains, concerning sex, age, state of preservation and type of bone, was processed in all remains with the method of classical anthropology. Morphological study of diseases was the following stage of search. The pathological conditions were observed in the bones, looking at osseous diseases and particular infectious conditions. Histological analyses are processed in several cases. The osteological remains had been boiled and collocated in an unsuitable place and used for uncontrolled proposes: the thaphonomic processes occurred were unclear and extremely difficult to define. Six samples, randomly selected, were processed searching for DNA traits of *Mycobacteria*, although as remembered, the osteological collection was used by different researchers during these years and the perfect idea of a “virgin bone”, as many authors crave, is very distant to our sample situation. The densitometer is provided with a data base that allows comparison of the measured bone mineral content of an individual with that of a referral population. The data base of instrument was generated *in vivo* from healthy

patients of both sexes. The machine used is called *MatriScan*, with a test totally not invasive, extremely quick and no special arrangements or training are required. Unfortunately, this is the first time that this new technique is used on osteological remains, thus similar data are not available to compare the results. Finally, the X-ray imaging is used in few ambiguous singular cases.

Results and discussion

During this research, for the first time T.O.C. was ordered and analyzed with traditional and modern techniques, about 60 individual forms have been completed and presented.

Some characteristic TB evidences, that are part of MOLAT, have been studied for their diagnostic value. Our results could support the idea that vertebral hypervascularization is caused by TB disease: in T.O.C. sample it is associated with other typical TB evidences and it has been found in 53% of total spines and in 63% of spines with pathological evidences. In T.O.C. samples, only 31% of individuals recovered with ribs show periostitis. This result can not support the sure evidence that periostitis is caused by TB, according to Pfeiffer (1991) who claimed that it could rather be interpreted as a non-specific indicator of chronic respiratory disease stress.

The histological analyses emphasized several unknown aspects concerning histology of ancient remains, i.e. the remodelling shown with haematoxylin-eosin and tricromic stain technique.

The molecular tests demonstrate the presence of mycobacterium on the osteological samples analyzed, although they were partial and limited as state before.

Densitometry with the new technique of *MetriScan* appears a potential instrument for further investigations.

Many considerations were formulated to create the basis for further and deepened investigations not only to study TB individuals, but also to amplify the study with other skeletal pathologies described as causes of death (i.e. syphilis). In particular, molecular and morphological analyses should be furtherly considered.

1. Palaeopathology

In the first chapter of this PhD thesis, a brief overview on palaeopathology will be given to introduce the real aim of the present work that is the study of tuberculosis disease in a collection dated at the end of 19th century. In this chapter the methods used by this science will be described and the problems and hitches that palaeopathologists can face will be briefly presented.

1.1 Introduction

Pathology is the study (*logos*) of suffering (*pathos*). In practice, pathology is defined as the scientific study of disease processes. Palaeopathology was described in 1910 by Sir Marc Armand Ruffer as the science of diseases whose existence can be demonstrated on the basis of human and animal remains from ancient times. Palaeopathology can be considered a sub-discipline of biological anthropology (Roberts & Manchester, 2001). It can be defined as the science that studies the diseases of past population with analyses of remains, which can be mummies, skeletons or burnt remains. The used methods concern from anatomy, pathology, anthropology and archaeology, in a multidisciplinary approach. A realistic diagnosis is extremely important to reconstruct the etiology and epidemiology of diseases in ancient populations (Schultz, 2001). Furthermore, it is helpful to extend the knowledge in bio-archaeology and socio-biology to explain both the diseases and their causes and the general life conditions in past populations.

Traditionally, in palaeopathology the emphasis was on description of individual cases, principally in order to demonstrate the specific conditions and to establish the antiquity of various diseases (Pinhasi & Mays, 2008).

In addition to general details such as age, sex, and height concerning the individuals recovered, archaeologists would like to know what diseases the individuals suffered from, what they died of, what their occupation was, what their state of nutrition, and as much as possible about their lifestyle, and the health status of the population of which they came from. The paleopathological study can help to answer to these questions.

Capasso (1999) divides the paleopathological sources into 3 types:

- 1) the direct sources: the remains themselves on which a direct study can be done;
- 2) the indirect sources: historic and literal sources from ancient texts, object of study of History of Medicine and can give further information on history of human health;
- 3) the comparative sources: information on diseases on other animal contemporary living species.

Fornaciari (2008) underlines that palaeopathology has a double interest: anthropology and medicine. For the anthropological interest, we have to consider that from the study of diseases and their impact, we can realize the uses and habits of ancient populations: each disease is expression of an interaction between natural sphere and cultural milieu of that specific society. A palaeopathological study can offer important elements to understand the society itself. The medical interest derives from the fact that a certain determination of the origin and evolution of some important diseases, such as tuberculosis, arteriosclerosis or cancer, arise great relevance in medicine.

The medical interest also includes the opportunity to examine every joint all the joints of the body, as well as just a segment, like bone, teeth or mummified tissue, and it is possible to identify pathologies in sites where the clinician and radiologist seldom, if ever, have brought their notice. For example, osteoarthritis (OA) affecting the odontoid peg is relatively common in skeletal populations but scarcely recognised as a clinical entity, other unusual

sites at which OA may be found include the inter-metacarpal and inter-metatarsal joints (Rogers & Waldron, 1995).

First of all, the palaeopathologist shall *describe* the skeletal remains. This description altogether with data from other sources, i.e. archaeological or historical or like technical sources (e.g. results from histological or molecular tests), can help the interpretation and comprehension of uses and habits of ancient population. For Example, Capasso, (2001), describes a particular wear of the internal face in the upper incisive teeth of an individual discovered at Ercolano (Individual E6 – The Flute-playing). The discovery of a particular flute, called *tibia* and in this particular case the *tibia multifora*, can clearly explain this singular wear.

The most recent techniques which sometimes can be used, like radiology, histology and molecular biology, can give a further help to the interpretation of the situation described by palaeopathologist.

1.2 Methods of palaeopathology

Since palaeopathology requires a multidisciplinary approach, also the methods of study are many, some of them are classical and some more recent using advanced technologies.

Primarily, the study relies on macroscopic observation and description of abnormal changes seen in the human remains. A description of these changes and their distribution in the skeleton or soft tissues is a prerequisite to attempting a diagnosis of the disease process being observed although diagnosis in modern contexts is difficult even with the array of diagnostic tests available. The absence of evidence does not mean evidence of absence in all cases (Roberts & Manchester, 2001).

In addition to macroscopic examination of the skeleton, radiography plays a crucial role in the diagnosis of disease and trauma, especially in the case of

unwrapped mummies, as remembered by Notman (1986, cited in Roberts & Manchester, 2001). Imaging of skeletal lesions using plain-film radiography has been used on ancient human remains for over 100 years, and it increases the information obtained by visual examination of specimens in the description and diagnosis of disease in paleopathology. Since the discovery of radiographic imaging in the late 19th century, many allied techniques using X-rays have been developed and used in clinical medicine (Mays, 2008). In the radiographic study of lytic lesions, it is important to note not only lesion morphology, but also the nature of lesion margins. Radiographically, a slowly developing lytic lesion tends to have a margin that is well defined and often shows some sclerosis, as pointed out by Ortner, (2003, cited by Mays, 2008, p.83).

The oldest technique for measuring bone density from radiographs is photodensitometry. A standard of known density, usually an aluminium step-wedge, is exposed in the radiograph alongside the bone, and the standard used to estimate bone density using an optical densitometer. This method has been little used in palaeopathology (Mays, 2008). The value of BMD (Bone Mineral Density), measured using DXA (Dual-energy X-ray Absorptiometry) as a stress indicator in juvenile skeleton has also recently begun to be investigated (McEwan *et al.*, 2005, cited by Mays, 2008, pp. 92). A general problem with making comparisons between different studies is that, due to hardware and software differences between different DXA scanners, absolute BMD values from different machines cannot be directly compared. In order to do such comparisons, a cross-calibration between machines needs to be carried out, or, alternatively, cross calibration data may be derived by scanning the same set of subjects in different machines. In DXA scanners, attenuation of X-rays by soft tissue is taken into account by the computer software when BMD is calculated. This means that, for scanning, archaeological specimens generally need to be placed in a material whose density approximates to that of soft tissue, such as water or dry rice.

Nevertheless, because archaeological specimens lack marrow and soft tissue, absolute BMD values cannot be compared with those on living subjects. This means that peak BMD cannot be compared between ancient and modern subjects. However, provided that significant diagenetic changes in bone density in archaeological specimens can be excluded, valid comparisons of age-related patterns in BMD between ancient and modern data can be made and peak BMD can be compared between different skeletal populations (Mays, 2008).

In addition, light, transmission and scanning electron microscopy add an extra dimension and increase accuracy for diagnosing disease and also in the identification of pseudo-pathological conditions. Many bone changes which cannot be observed by macroscopic analysis are revealed by microscopic techniques. Thus, many alterations caused *intra-vitam* by disease can clearly be differentiated from changes due to *post-mortem* reactions. In paleopathology, all diseases which produce changes in the skeleton can be studied by microscopic techniques. In particular, diseases affecting the microstructure of compact bone of the long bones (e.g., hematogenous osteomyelitis, treponemal disease, leprosy) and the cortical and cancellous bone of the skull (e.g., anemia, scurvy, rickets, meningitis, non-specific and specific osteomyelitis) (Schultz, 2001).

Physical and chemical techniques of analysis have been used increasingly over time to diagnose disease and also to examine dietary status that has a role on the likelihood of acquiring a disease.

Recently, research has focused on identifying disease at the molecular level. DNA can be extracted from osteocytes and from nuclear elements of the blood of vascular canals. This level of study opens a new source of information that can help palaeopathologist, but its limitations should be also considerate as the possible contaminations in every phase of study or the possible absence of pathogen DNA in early stages of disease. However, the

molecular paleopathology can expand the traditional morphological research (Capasso, 1999).

1.3 Limitations of palaeopathological study

There are several limitations to the study of palaeopathology, as in any discipline. Woods *et al.* (1992) stated that light on a fruitful and unstopped debate on this issue.

The populations being studied in palaeopathology are dead and therefore may not be representative of the living group. Partial excavation of a cemetery is the most common occurrence in archaeology and therefore only a portion of the original buried population will be examined, the differential disposal of males, females and sub-adults and their subsequent excavation means that biases in the data produced are unavoidable (Roberts & Manchester, 2001). As well as concerning the sample of human osteological collections, the data are threshold *a priori*. Many physicians, who collected them, gathered the bodies looking for the largest types, not the real frequencies in the population (see Chap. 5 of this PhD Thesis).

Therefore, no evidence of abnormal bone change would be visible because the person died before the bone change developed and many diseases also only affect the soft tissues and therefore would not be visible on the skeleton. In many infectious diseases only a small percentage of people will have skeletal involvement (e.g. 3-5% in tuberculosis), and some people may have died before bone changes occurred, i.e. in the acute phase of the disease (Roberts, 2000). Further, pathological bones are fragile structures and may, in some circumstances, become damaged while buried and not survive to the excavation, which precludes examination and recording, thus their prevalence may be under-represented (Roberts & Manchester, 2001).

A further factor to consider as a general limitation in palaeopathology is the impossibility, in most circumstances, to describe a cause of death of an individual. What can be indicated are the disease processes an individual may have been suffering from in life and whether the disease was active or not at the time of death (Roberts & Manchester, 2001). Only in some osteological collections there are recorded causes of death: the importance of these types of information is clear to have source for diagnostic criteria.

It should also be taken in mind that different diseases may induce similar lesions in bone and occur on the skeleton at the same time, because bone can only react to pathological stimulus in a limited number of ways (Schultz, 2001). Unfortunately, in archaeological contexts complete skeletons are not always available, but the unique way to overcome this problem is considering of the degree of the bone changes altogether with its distribution in the different osseous districts (Rogers & Waldron, 1995).

Thaphonomic processes include human and non-human effects, and usually archaeological remains were exposed to a mixture of both during their history (Roberts *et al.*, 2002). From the point of view of the investigator, there are at least three events in taphonomic time: (1) the time of death; (2) the time of deposition in the recovery location and (3) the time of recovery. In some cases, there is also an archival period following analysis. But usually these events are not chronologically precise or even discoverable as actual time points (Sorg and Haglund, 2002).

Schultz (2001) explains very well the influence of autolysis, decomposition and diagenesis in bone, and, consequently, the limitations that occur. A corpse disintegrates in various ways. *Autolysis* is the breakdown of tissues by the action of enzymes contained in the tissues damaged immediately after death. As a rule, the autolytic process does not change the microstructure of mineralized or calcified components of bone. However, autolysis may destroy cells and soft tissues. This is important to keep in mind for someone working on special problems at the molecular biological level. Further disintegration of

soft tissues occurs through *decomposition*. During this process, the soft tissues are separated or resolved into constituent parts or elements, particularly by bacteria, fungi, and arthropods. This process usually takes months or even years. Mineralized or calcified tissues are, as a rule, not affected. The term “diagenesis” characterizes the disintegration of mineralized or calcified tissues. Archaeological bone is known to be affected under ground by various factors (e.g., roots of plants, fungi, algae, bacteria, arthropods and their larvae, worms, protozoa, and mechanical agents such as water and crystals).

This process, diagenesis, is characterized by the destruction of bones by physical and chemical agents produced by the factors described above. For the physical agents, the compression under several levels of burials and soil should be considered: deformities or break of bones are problematic in the diagnostic study. Others physical agents that should be considerate are heat and fire occurring *peri-* or *post-mortem*. When the action of these agents is slow, the alterations of bone tissue are superficial and can be distinguished by histological study, when the action is fast, the dehydration that occurs can break the cortex or induce a burst. Finally, also the human action can be added to the physical agents, such as agricultural utensils that can ruin or mutilate the remains (Capasso, 1999).

Generally, diagenesis occurs in the soil after the process of decomposition. Unfortunately, even today, relatively little is known about the physiology of the fauna and flora of bodies, represented by the various organisms living over many centuries on and in a corpse causing decomposition and diagenesis. All these *post-mortem* factors produce damages that can falsely be diagnosed by paleopathologists as lesions caused *intra-vitam* by diseases (pseudo-pathology). As a rule, many of the changes cannot be differentiated by macroscopic or radiological analysis, but are diagnosed by microscopic techniques. For instance, compact bone can be destroyed by characteristic tunnel-like canals caused by the *post-mortem*

growth of fungi or algae (Hackett, 1981, cited in Schultz, 2001). Furthermore, it should be kept in mind that these *post-mortem* factors can affect the results of immunohistochemical and molecular biological investigations (e.g., DNA, bone proteins) as well as the examination of trace elements and stable isotopes. Therefore, microscopic investigation is indispensable before examination of archaeological remains by chemical and physical techniques can be carried out (Hanson and Buikstra, 1987, cited in Schultz, 2001). Sometimes bones are preserved in the ground by protective surroundings. Thus, the process of diagenesis works very slowly and incompletely or is even suspended. This, for instance, happens when a bone becomes a fossil. In such a case, the bone could have been preserved over many thousands of years in a cave or in a rock shelter. However, subfossils such as prehistoric bones have a good chance of not being affected by diagenesis if elements such as copper (Cu), manganese (Mn), and even iron (Fe) are present in the soil (Schultz, 2001).

In the non-rare case that the analyses are carried out on human osteological collection, as in the present PhD thesis, a particular situation on palaeopathological study is that the human bones have been boiled. In the majority of cases, they have suffered this process to strip off soft tissue without damages. Many authors (as Lyman, 1994, cited in Roberts *et al.*, 2002) studied various aspects on this issue, however none of them established unequivocally whether and how cooked bone are different from un-cooked ones. Roberts *et al.* (2002) conclude their analyses suggesting that the boiling process is to some extent an analogue of diagenesis, with similar processes occurring – loss of collagen, increasing crystallinity and increasing porosity, but histology does not change. They have shown that it requires boiling for extensive periods to mimick these changes, with what could be considered conventional boiling times (1–9 h) having little or no physico-chemical effects. They occur after a boiling time of 27 hours. Increased

porosity might have a severe effect, with a greater surface area available for dissolution processes. The authors concluded that cooking can be considered an analogue for burial diagenesis, with patterns similar to those observed in archaeological samples. For the histology analyses, Roberts and colleagues have used the histological index of Hedges *et al.* (1995, cited by the same authors), which is a graded system from 0 to 5, with 0 representing no surviving histological structure and 5 indicating near-perfect preservation of histology. Roberts *et al.* concluded that the histology of all their experiments preserve the same structures.

In light of these considerations, it should be noted that the information on taphonomy of human osteological collections is relatively poor, as well as in the collection used in this PhD thesis (see Chapter 5), but still much more compared to the usual information on archaeological remains. Thus, the importance to study this type of remains is totally incomparable.

2. Skeletal Pathology

In the first part of this chapter, a general introduction to bone tissue and teeth will be given to understand the skeletal modifications that can occur in a pathological condition. There is a description of bone composition that will be useful to the chemical analyses carried out in this work (chapter 6). In the second part, there is a general list of principal skeletal pathologies with their description: this part is not exhaustive at all, as the issue is too ample to be explaining in only a few words. The aim of this section is giving an introduction to the particular issue of this thesis, the tuberculosis (chapter 3) that is just one of the possible pathologies giving skeletal manifestations.

2.1 Bone tissues and the skeleton

2.1.1 Introduction

The evolution of exoskeletons (shells, scales, etc.) some 500–600 million years ago during the “Cambrian explosion” allowed the preservation of this event in the form of fossils in the rock record. The subsequent development of endoskeletons (bones and teeth) gave vertebrates improved mobility and mechanical competence. Bones protect the internal organs, allow enhanced mobility, perform other mechanical functions, and are a ready source of the key regulatory inorganic ions calcium, magnesium, and phosphate and teeth enable mastication of food. They also harbor a myriad of cells and growth factors that, in turn, control tissue properties. The sizes and shapes of bones reflect their function. For example, the flat skull bones protect the brain, the

short tubular bones in the fingers of the hands and feet provide specific grasping functions, the long bones enable locomotion (Boskey, 2007).

In the embryo, the precursor of bone results from a condensation of mesodermal cells called mesenchymal cells. At this stage, these cells are pluripotent and can differentiate into several different types of specialized connective tissue cells. Classically, two types of bone formation occur during the development of skeletal tissue: endochondral ossification and intramembranous ossification (Ortner and Putschar, 1985).

1. Endochondral ossification, where the cartilage cells (*chondrocytes*) play an important role, is associated with the growth phase, but it may occur in the adult in pathological situations, such as fracture healing. In the embryo the earliest centers of endochondral ossification are those areas that will become the major, long, tubular bones (the femur, tibia, fibula, humerus, radius and ulna). All endochondrally derived bones begin as a condensation of mesenchymal cells which develop into a cartilage model (anlage) of the future bone rather than directly into bone itself.
2. Intramembranous ossification involves only bone cells, as during bone matrix formation, the new matrix is laid down on an existing tissue surface with an appositional development.

2.1.2 Structure of bones and teeth

Structural hierarchies are common in biologic systems and are particularly evident in bio-mineralized structures. Variation in structure at different hierarchical levels in the skeleton creates a highly organized, robust mineralized tissue that performs a variety of functions based on the

biomechanical demands at specific anatomical sites (McKee, 2005). Boskey (2007) reports a very useful hierarchical structural, for both bones and teeth. (Fig. 2.1 and Fig. 2.2)

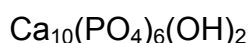
Centimeters At the organ scale, it is possible to distinguish different types of bones (e.g. long, flat) with distinct functions. Long bones consist of an outer cylinder of **cortical bone** surrounding a marrow cavity that includes struts of **trabecular (cancellous) bone**. Flat bones have variable structures; for example, the skull has lesser amounts of cancellous tissue whereas the spine consists mainly of cancellous bone. As for bone, different components of the tooth (dentin, enamel, cementum) are distinguished at the organ scale. The periodontal ligament connects the tooth (via the cementum) to the underlying jawbone. The outer coating of the tooth as far as the gum line is enamel, a very hard material with little or no protein. Below the enamel is dentin, the major component of teeth. Separating the dentin from the surrounding jawbone is a bone–dentin composite material, cementum, and a ligament. The dentin surrounds a pulp cavity that holds the nerves and blood vessels necessary for tooth function.

Millimeters to micrometers At the tissue scale, in general, bones and teeth consist of cells, **organic matrix**, and **inorganic matrix**. The cells control the initial production of the mineralized tissue. In bone, osteoblast cells produce the extra cellular matrix and control mineralization. When osteoblasts become endowed in mineral, they become a different type of cell, called osteocytes, which communicate with each other via interconnecting long channels (canaliculae) that can send messages throughout the tissue. Finally, osteoclast cells remove bone mineral and bone matrix. Thus, bone cells regulate the formation or resorption of bone and turnover, a key step in regulating body calcium, magnesium, and phosphate levels and repairing fractures. This maintenance of inorganic ion levels, or homeostasis, is one of the major non-mechanical functions of bone. This process is unbalanced in a variety of common human diseases such as osteoporosis and osteomalacia.

Micrometers At the microstructure scale, bone consists of structural units such as the trabeculae found in the marrow connecting the bone structure, the thin plates (lamellae) in cortical bone, and the bone formed around blood vessels (osteons). In the tooth, structural units include the tubules that permeate the dentin and the intertubular dentin that surrounds the extensions of the dentin-forming odontoblasts.

Nanometers At the ultrastructural scale, individual tissue components, namely the mineral crystals and the organic matrix, can be discerned. The organic matrix of bone consists primarily of a fibrous protein, collagen, and lesser amounts of other noncollagenous proteins. In tooth, collagen is also the major organic constituent of dentin and cementum, but there is no collagen in enamel. Collagen is the same protein that gives flexibility to ligaments and tendons, but the addition of mineral to the collagen matrix makes it rigid and gives bones and teeth their greater load bearing capacity. The mineral reinforces bone and dentin matrices and is also the major constituent of enamel that is an analogue of the mineral hydroxyapatite.

At the element scale, bone apatite nanocrystals exhibit a variety of substitutions and vacancies that make the Ca/P molar ratio distinct from the stoichiometric hydroxyapatite ratio of 1.67 (Zipkin, 1970, in Boskey, 2007). The hydroxyapatite is the generally accepted basic crystal structure and chemical composition of mature mineral bone with an mixture of variable amounts of carbonate and of citrate and ions (Lean and Urist, 1968). The general formula of hydroxyapatite is the following



Enamel apatite has fewer substitutions than bone or dentin mineral and more closely approximates stoichiometric hydroxyapatite.

Due to bone remodeling or turnover, osseous composition differs with individual age and tissue age, environmental factors, and health status. This dynamics of bone mineral has been investigated for a long time (Lean and

Urist, 1968), and whereas some structures and composition are unknown, they remain also the subject of recent studies. There is an age-dependent variation in bone chemical composition, crystal size, and amount of minerals present in different sites within the osteons and trabeculae. Different parts of the tooth also have variable structure and composition. The outer coating, enamel, is not formed on a collagen matrix, and the organic matrix of enamel is degraded when the tooth is mature (Margolis et al. 2006). Enamel composition may be modified by bacteria that cause dental caries and by chemical agents used to remineralize the damaged enamel. Dentin and cementum are not remodeled, so studies of their age-dependent maturation provide a picture of the dynamics of mineral deposition (Verdelis et al. 2007).

There are a variety of human diseases in which altered mineral properties occur in bone and teeth. Examples of these mineral changes are summarized in Table 2.1 which includes frequently encountered diseases such as osteoporosis and osteomalacia and less-common diseases such as osteopetrosis, osteonecrosis, osteogenesis imperfecta, and odontogenesis imperfecta. Some of these diseases are due to genetic abnormalities, but they may also be attributed, to varying degrees, to environmental factors such as diet, exposure to sunlight, and exercise (Ralston and de Crombrughe 2006).

Variations in mineral properties in bones and teeth are studied using mutant animals lacking one or more extra cellular matrix component and they provide insight not only into the mechanical strength and geometry of these tissues, but also into the functions of the proteins that are knocked out (Boskey, 2005). The transformations that occur in the mineral components of osseous tissue in a disease are various and they are difficult to individualize. This complex situation has to be considerate during skeletal evidence study in palaeopathology.

Table 2.1 Typical mineral changes in human bone and dental disease.

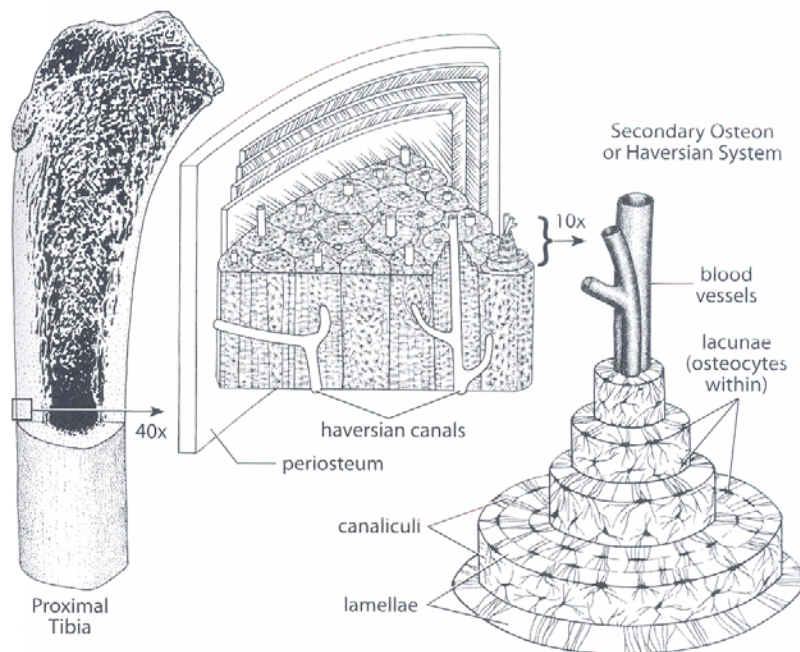
<i>Disease</i>	<i>Description</i>	<i>Prevalence</i>	<i>Mineral Content</i>	<i>Crystal Size</i>	<i>Other Features and Relevant Review</i>
Osteoporosis	Increased porosity with tendency to fracture	High	Variable	Increased	Collagen maturity increased (Boskey et al. 2006)
Amelogenesis imperfecta	Impaired enamel mineralization	High	Decreased	Variable	Hypomineralization; often X-linked (higher prevalence in males) (Robinson et al. 2003)
Osteomalacia	Poorly mineralized bone with tendency to fracture	High	Decreased	Increased	Associated with vitamin D deficiency (Faibish et al. 2005)
Osteogenesis imperfecta	Brittle bone disease due to abnormal collagen synthesis	Low	Decreased	Decreased	Abnormal collagen gene expression (Zhu et al. 2007)
Osteopetrosis	Rock-like bone with increased tendency to fracture	Low	Increased	Decreased	Impaired bone remodeling (Boskey et al. 2006)
Osteonecrosis	Dead bone	Low	Increased	Variable	Lack of viable cells (Weinstein et al. 2000)
Renal osteodystrophy	Kidney malfunction leading to osteoporotic bone	Low	Decreased	Increased	(Sanchez 2006)

From Boskey, 2007

2.1.3 The skeleton

Due to the extreme complexity of the human skeleton and to the consequent impossibility to describe it briefly and thoroughly (and this is not the purpose of this PhD thesis), some figures are presented regarding the internal structure, long bone and whole skeleton. For more detailed explanations, please refer to the literature.

Fig. 2.1 Structure of bone



From White and Folkens, 2005

Fig. 2.2 Long Bone

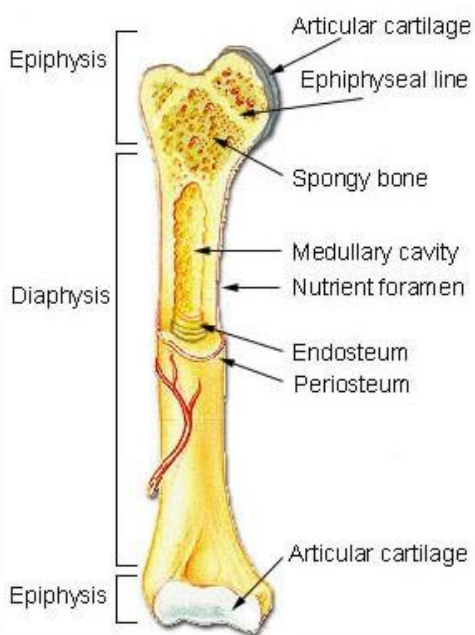
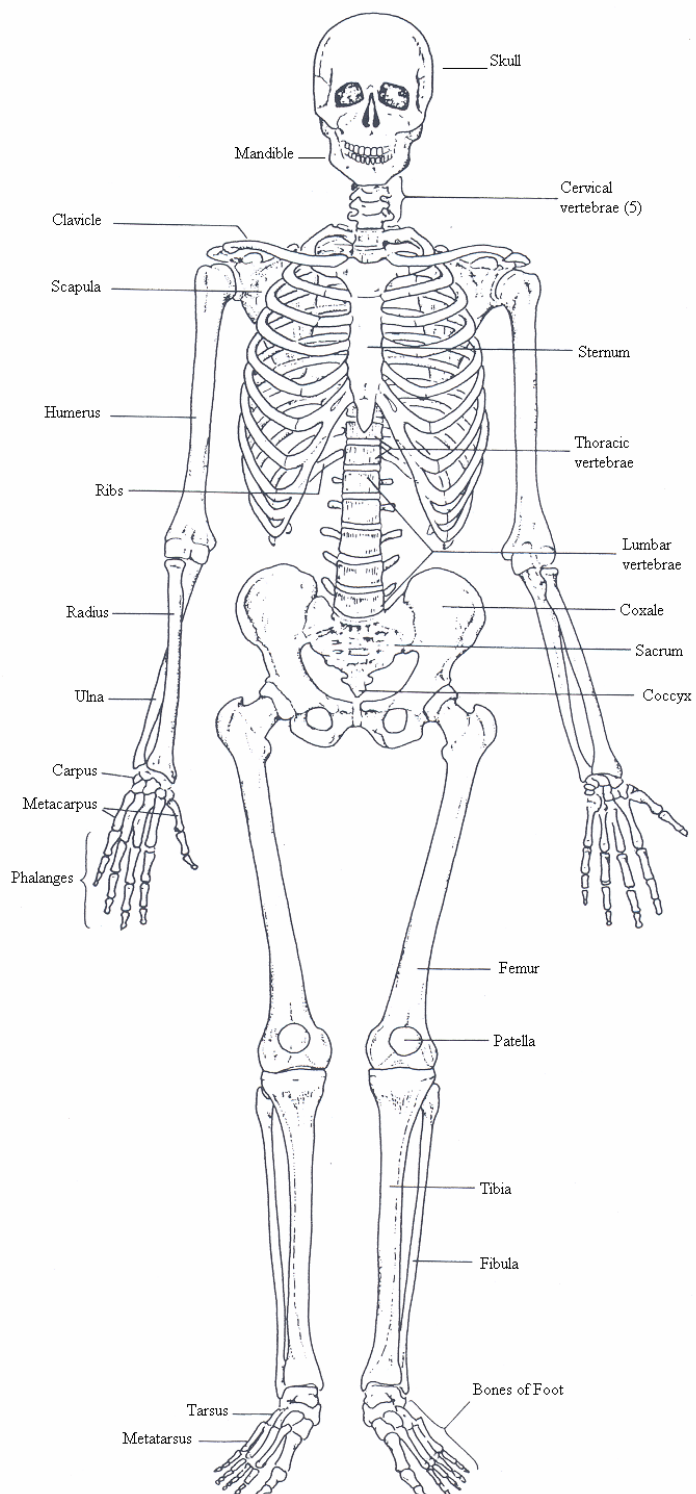


Fig. 2.3 The human skeleton



Modified from Roberts & Manchester, 2001

Besides the common characteristics, we have to consider the possible presence of epigenetic variant that are non-pathological skeletal variants of the skeleton. This term is now used for the characters studied that shown a non-Mendelian transmission, most of them may appear in more than one manifestation, in different sizes and shapes, in different position and in a variable number (Hauser *et al.*, 1989).

2.2 Palaeopathologies

In normal living bone there is a dynamic equilibrium between the cells that make bone (the osteoblasts), and those which resorb it (the osteoclasts), and this allows maintaining the integrity of the skeleton. This equilibrium is disturbed by disease, but since bone has only a limited capacity to react to disease processes (as remembered in chap. 1), one may greatly oversimplify the outcome by saying that bone disease is characterized by there being too much or too little. The diseases which affect bone, however, rarely do so in isolation. For example, the joint disease may not have their origin in the bone, but the other tissues of the joints, the articular cartilage or the synovial membrane (Rogers & Waldron, 1995).

According to the same authors, the reaction of bone tissue to a disease process can be limited. They are listed below.

- Proliferation: presence of new bone around a joint margin or the surface of a joint
- Erosions: can present some diagnostic problems, since it is difficult distinguishing them from *post-mortem* damage and from other holes which may result by a pathology.
- Eburneation: is an important feature in joint disease (particularly of osteoarthritis - OA) that appears itself in dry bones by highly

polished areas on the joint surface and is caused by an area of bare bone moving over other structures.

- Osteoporosis: is the loss of bone substance resulting in a decrease in the number of trabeculae and in cortical thinning or.

2.2.1 Dental diseases

Teeth are often the only part of the body that survives, due to their hard and robust structure, provide a wealth of information about, for example, diet, stress, occupation, cultural behaviour and subsistence economy, and of course oral hygiene and dentistry.

Dental caries

It is perhaps the most common of the dental diseases and is reported for archaeological populations more frequently than other dental diseases; it may occur as opaque spots on the enamel surface or as large cavities. It is a transmissible disease and it is the result of fermentation of food sugars, especially sucrose, in the diet by bacteria that occur in the teeth, e.g. *Lactobacillus acidophilus* and *Streptococcus mutans*. Powell (1985, cited in Roberts & Manchester, 2001) usefully divides the epidemiology of caries into several areas; environmental factors (e.g. trace elements in food and water), pathogenic agents (the bacteria causing the disease), exogenous factors (e.g. diet, oral hygiene), and endogenous factors (e.g. the shape and structure of the teeth).

Dental abscess

Dental caries can predispose to the development of a dental abscess through exposure of the pulp cavity from attrition or trauma and infiltration of the cavity by bacteria; abscess formation can also occur if an individual develops periodontal disease and a periodontal pocket.

Dental wear

Dental wear is the natural result of masticatory stress upon the dentition in the course of both alimentary and working activities, and it usually occurs on the occlusal surfaces of the teeth during grinding of the crowns of the teeth against each other. The cause of severe attrition may be reflected in other areas of the oral cavity, the degeneration of the temporomandibular joints and the transformation of maxillary and palatine tori, which reflects high levels of masticatory stress producing a bone reaction. As a relevant example of technological activity, the study of the Eskimo Inuit population (Merbs, 1983, cited in Roberts and Manchester, 2001) describes the use of jaws and teeth for cultural activities such as stretching and softening animal skins to make into clothing.

The dental wear is a used system of estimation of the age at death and there are various methods by different authors. The most widely used is the by Brothwell (1989, cited by Hillson, 1996) reported in figure 2.4. A diagram on occlusal attrition stages widely used is the one based on diagrams of Murphy, who developed it in 1959 and was reprinted by Smith in 1984 (Hillson, 1996).

Fig. 2.4 Brothwell's system for age estimation from attrition.

Age Period (years)	About 17-25			25-35			35-45			About 45		
Molar number	M1	M2	M5	M1	M2	M5	M1	M2	M5	M1	M2	M5
Wear pattern	 OR OR 	 OR 	<p>Dentine <i>not</i> exposed. There may be slight enamel polishing</p>	 OR 	 OR 	 OR 	 OR 	 OR 	 OR 	<p>Any greater degree of wear than in the previous columns</p> <p>NB. Very unequal wear sometimes occurs in the later stages</p>		

From Hillson, 1996

Fig. 2.5 Murphy's occlusal attrition stages.

STAGES OF WEAR	MOLARS			PREMOLARS			INCISORS & CANINES	
	L	U	L	U	L	U	U	U
1								
2								
3								
4								
5								
6								
7								
8								

From Hillson, 1996

Calculus

Other commonly observed dental diseases are calculus accumulation and periodontal disease. Dental plaque consists of micro-organisms which accumulate in the mouth, embedded in a matrix partly composed by the organisms themselves and partly derived from proteins in the saliva. Calculus develops most commonly on the teeth nearest the salivary glands (tongue side of the lower incisors and cheek side of the upper molars) but it may occur to any surface of the tooth. It appears to be a common finding on archaeological teeth, which perhaps reflects a lack of attention to removing plaque and then calculus from teeth. Dental reports from archaeological human population indicate that calculus was common in all periods (Freeth, 2000; Roberts & Manchester, 2001).

Periodontal disease

Calculus accumulates in crevices between the tooth and soft tissue and bone, forming periodontal pockets; it is a major predisposing factor in the development of periodontal disease. Identification of this dental disease in archaeological material is problematic. Signs of inflammatory pitting or new bone formation on the jaw bones are more likely to allow a positive diagnosis for this dental disorder. Bone may be lost horizontally or irregularly, and age, oral hygiene and diets rich in sucrose are major predisposing factors, although this condition recognizes multifactorial causes.

Enamel hypoplasia

Teeth can also indicate other events in a person's life, particularly during the growing years when bone and teeth are developing. In biological anthropology dental enamel defects have attracted the attention of many

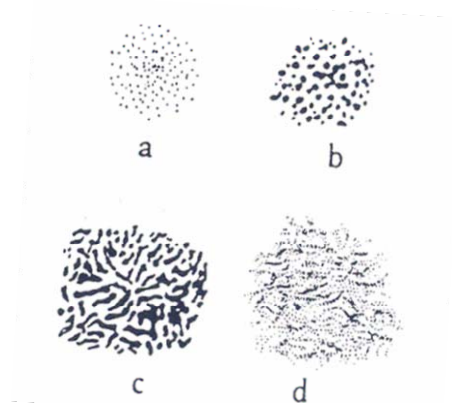
researchers, in studies of both modern and ancient populations (Goodman & Capasso, 1992, cited in Roberts and Manchester, 2001). They are often termed as stress indicators and are defined as deficiencies in enamel matrix composition. Defects in teeth are observed as lines, pits or grooves on the enamel surface, usually more easily seen on the cheek surfaces of the incisors and canines.

2.2.2 Iron deficiency anemia

The *cribra orbitalia* was classified by Knip (1971, cited by Campillo, 1994a), according to morphology and extension in four groups (fig. 2.3):

- type “a”: very small and thin holes;
- type “b”: conglomeration of many separate holes still separated;
- type “c”: irregular furrows in which hyperostitic trabeculae can creep;
- type “d”: surface with creases and external depressions.

Fig. 2.3 The four types of *cribra orbitalia* by Knip



From Campillo, 1994a

2.2.3 Degenerative diseases

Osteoarthritis and Osteophytes

Arthritis is the inflammation of a joint, a general inflammatory process that includes soft tissue effects and that can be a result of trauma as well as of bone and joint infections. Osteoarthritis (OA) is the most common form of arthritis and it is characterized by destruction of the articular cartilage in a joint and by formation of adjacent bone, in the form of bone lipping and spur or nail formation (osteophytes), around the edge of the joints (degenerative joint disease). The disease occurs mostly in load-bearing joints, particularly in the spine, the hip and the knees. Osteoarthritis is usually classified as either primary, resulting from a combination of factors that include age, sex, hormones, mechanical stress, and genetic predisposition, or secondary, initiated by trauma or another cause such as the invasion of the joint by bacteria (septic or pyogenic arthritis) (White and Folkiens, 2005). In the absence of any other

abnormalities in the skeleton, then marginal osteophytes are not considered pathological, but they may be seen in many conditions, some of which are reported in Table 2.2. The conditions are listed in the order in which they might be expected to be found in the skeleton (Rogers and Waldron, 1995).

Table 2.2 Some conditions associated with osteophytosis or new bone formation

Ageing
Osteoarthritis
Intervertebral disc disease
Diffuse idiopathic skeletal hyperostosis
Ankylosing spondylitis
Psoriatic arthropathy
Reiter's syndrome
Acromegaly
Fluorosis
Ochronosis
Neuroarthropathy

From Rogers & Waldron, 1995

DISH - Diffuse idiopathic skeletal hyperostosis

DISH is characterized by ossification of the anterior longitudinal spinal ligament and by ossification into extra-spinal entheses. The development of new bone in the skeleton may reach prolific proportions and has been likened to candle wax flowing down the spine and may reach up to 20 mm in thickness (Rogers and Waldron, 1995). In the thoracic spine the restriction of changes to the right side is considered a consequence of the presence of the pulsating descending aorta on the left. Other spinal ligaments may also become ossified, as for examples the ligamentum flavum or, outside the spine, around the elbow (triceps insertion) or in the patella the insertion of quadriceps femoris into the patella, the insertion patellar ligament into the tibia and the insertion of the Achilles tendon into the calcaneus. Where DISH is coexistent with OA the degree of osteophytes around the affected joints may be considerable (Rogers and Waldron, 1995).

Rheumatoid Arthritis

Rheumatoid Arthritis (RA) is one of the diseases which is generally considered to be recent origin and it is a common condition in modern population, affecting about 1% of the total population (Rogers and Waldron, 1995). Middle-aged women have a predisposition for this type of arthritis, in which the immune system of the body attacks its own cartilage. Bone changes are atrophic and are especially focused in the hands and feet (the small joints, metacarpophalangeal and metatarsophalangeal). The lesions are usually bilaterally symmetrical (White and Folkiens, 2005).

Ankylosing Spondylitis

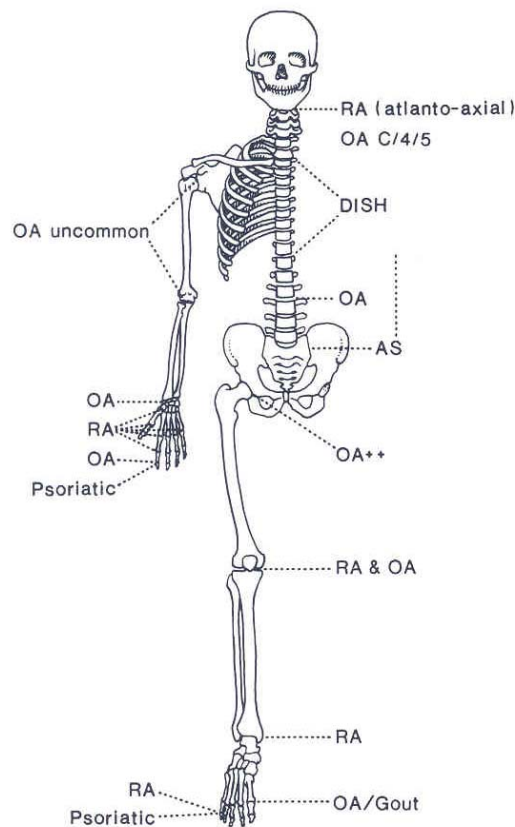
An ankylosis is an abnormal immobility or fixation of a joint resulting from pathological changes in the joints. Ankylosing Spondylitis (AS) is a chronic and usually progressive disease that affects the spine. The associated ligaments ossify and the inter-vertebral joints become immobilized (White and Folkiens, 2005). The disease usually begins in the sacro-iliac joints and the lumbar spine. The sacro-iliac joint is a composite joint (the lower two-thirds is a synovial joint and the upper third is a ligamentous joint), and all compartments can be affected in AS. The pathological changes are symmetrical within the joints but are obvious on the iliac side of the joint, perhaps because the articular cartilage is thinner on the ilium than on the sacrum (Rogers and Waldron, 1995).

Osteoporosis

Osteoporosis or osteopenia in the non-clinical situation is defined (Consensus Conference, 2001) as a skeletal disorder characterized by compromised bone strength predisposing a person to an increased risk of fracture. Bone strength primarily reflects the integration of bone density and bone quality. Bone density is expressed as grams of mineral per area or volume, and in any given individual is determined by peak bone mass and amount of bone loss. Bone quality refers to architecture, turnover, damage accumulation (e.g., microfractures), and mineralization. This idiopathic osteoporosis has been divided into 2 groups: type 1 (primary osteoporosis) can afflict both sexes at all ages, but often follows postmenopausal women 51-75 years old (trabecular bone loss with fractures of the distal radius and vertebrae) and type 2 (secondary osteoporosis) is a result of medications (eg, glucocorticoids), other conditions (eg, hypogonadism), or diseases (eg, celiac disease) (Consensus Conference, 2001). For the spine, the most obvious gross change is a

reduction of bone mass per unit volume and transected vertebrae or metaphyses reveal an overtly porous pattern of cancellous bone. The same process of trabecular thinning and loss is also present in the trabecular bone in metaphyseal areas of long tubular bones (Aufderheide and Rodríguez-Martin, 1998). The frequency for the female gender grows up from climacteric time: 49 years old (7%), to 60~64 years old (46%) and older (78%).

Fig. 2.4 Pattern of characteristic skeletal involvement in various arthropathies



AS: ankylosing spondylitis	DISH: diffuse idiopathic skeletal hyperostosis	DIP: distal interphalangeal	MTP: metatarsophalangea I	OA: osteoarthritis
OD: osteochondritis dissecans	PIP: proximal interphalangeal	PA: psoriatic arthropathy	RA: rheumatoid arthritis	

From Rogerts and Waldron, 1995

2.2.4 Infectious diseases

The infectious diseases cover a wide range of conditions affecting both soft tissue (e.g. plague, cholera, malaria) and the skeleton. While the infectious involving soft tissue cannot be observed in the skeletal record (even though they may be studied in other ways, e.g. a palaeodemographic study of a plague cemetery, and identification of the plague bacillus using ancient DNA), in many infectious diseases only a small percentage of people has skeletal involvement (e.g. 3-5% in tuberculosis), as remembered in chapter 1, and some people may have died before bone changes occurred, i.e. in the acute phase of the disease (Roberts, 2000).

The infectious most commonly reported and analysed in the palaeopathology literature are the **non-specific infectious** diseases affecting the periostium (periostitis), cortex (osteitis) and medullary cavity (osteomyelitis) of bone. These changes, however, can also be seen as manifestation of a specific infectious diseases (but in a specific distribution pattern), or be focused on a particular part of body.

The most common **specific infectious** diseases reported in the palaeopathological literature are leprosy¹, tuberculosis and treponemal disease² which have all bone changes which overlap in nature with each other (e.g. facial changes). It is therefore particularly important to consider the characteristics and distribution pattern of lesions in the skeleton to hypothesize at an accurate diagnosis (Roberts, 2000). Also brucellosis, which is an infection caused by one of the species of *Brucella* transmitted from some animals, caused lesions difficult to differentiate from tuberculosis, although there tends to be more new bone formation and less osteoporosis in brucellosis than in tuberculosis.

¹ **Leprosy** is an infection cause by *Mycobacterium leprae*, which is contracted via the pulmonary route through droplet infection, and possibly via skin contact.

² **Endemic syphilis** (or treponarid/bejel), yaws and venereal syphilis all affect bone and are caused by spirochetes of the genus *Treponema*.

Fungal diseases affecting bone and joints are rare in Europe but they are much more common in North and South America. The two fungi which account for most skeletal disease are *Blastomyces dermatitidis* and *Coccidioides immitis*, causing blastomycosis and coccidioidomycosis. There may be great difficulty in distinguishing fungal diseases from other infectious diseases, and in the case of coccidioidomycosis sclerotic changes in the vertebral bodies may simulate prostatic carcinoma. Surly, DNA analyses may help in the diagnosis of these conditions (Rogerts & Waldron, 1995).

2.2.5 Lesions and injuries

Ortner and Putschar (1985) remember that the most common pathological condition affecting the skeleton is trauma. Generally, trauma affects the skeleton in four ways:

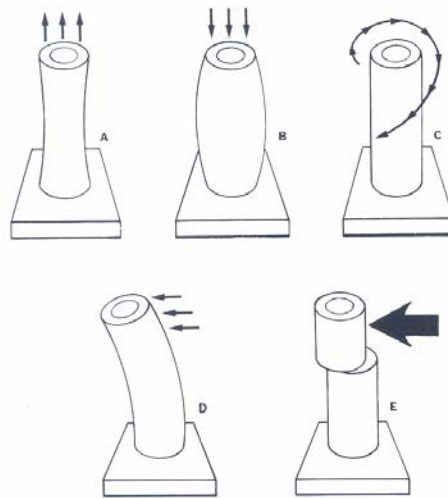
1. partial to complete break in a bone;
2. an abnormal displacement or dislocation of bone;
3. a disruption in nerve and/or blood supply;
4. an artificial inducted abnormal shape or contour of bone.

Dynamic stress fracture is the most common traumatic condition in skeletal material, and each type of stress produces a different type of fracture and, however, many fractures are the result of more than one type of stress. Figure 2.6 shows some different types of stress (Ortner and Putschar, 1985).

Fracture and the complications arising from fracture most often provide the palaeopathologist with easily interpretable lesions in archeological skeletons. However, in the interpretation of this type of trauma there are some problems of which the palaeopathologist should be aware. First, evidence of healed fractures occurring in children can be completely obliterated by the

skeletal remodeling that occurs with growth. Second, it is difficult and often impossible to make a distinction between fractures occurring at the time of death and those that occur subsequent to death and burial (Ortner and Putschar, 1985).

Fig. 2.6 Types of stress in bone that can result in fracture



A: tension B: compression C: twisting
D: bending E: shearing

From Ortner and Putschar, 1985.

3. Tuberculosis

In this chapter, a general overview of etiology and expression of tuberculosis will be given. Tuberculosis – TB – is the leading infectious cause of morbidity and mortality in adults as well as in children worldwide, killing still today about 2 million people every year.

3.1 Introduction on *Tuberculosis Mycobacterium*

3.1.1 Mycobacteria

The bacteria causing tuberculosis belong to a diverse group of microorganisms known as mycobacteria. Many of them operate as opportunistic microbes, able to adapt quickly to changing microenvironments. Some microbes can harmlessly colonize skin or the mucous membranes lining the airways of the lungs and intestinal walls of fish, reptiles, birds and mammals. Usually, colonization is short-term since the host's resident microbes crowd out the mycobacteria, while the host remains unaware of their presence (Collins, 1996, cited in Barnes, 2005, p.138).

These microbes did not develop into true parasites, and they rarely cause serious infection and disease. Occasionally, when they encounter a debilitated host with a compromised immune system, mycobacteria begin to colonize the mucous lining of the mouth, lungs or intestine producing the disease. Currently, taxonomically at the scientific name of *Mycobacterium tuberculosis complex* are listed 39 different types of bacteria that have been characterized molecular level (see tab. 3.1). However, more than 50 bacteria,

that cause several different forms of tuberculosis – TB, are included in this complex.

Tab. 3.1 <i>Mycobacterium tuberculosis</i> complex		
Taxon	Mnemonic	Scientific Name
33894		<i>Mycobacterium africanum</i>
1765	MYCBO	<i>Mycobacterium bovis</i>
233413		<i>Mycobacterium bovis</i> AF2122/97
33892		<i>Mycobacterium bovis</i> BCG
413996		<i>Mycobacterium bovis</i> BCG str. Moreau RDJ
410289	MYCBP	<i>Mycobacterium bovis</i> (strain BCG / Pasteur 1173P2)
78331		<i>Mycobacterium canettii</i>
1806		<i>Mycobacterium microti</i>
194542		<i>Mycobacterium pinnipedii</i>
105643		<i>Mycobacterium</i> sp. 9502227
280783		<i>Mycobacterium</i> sp. CHTN-E
392401		<i>Mycobacterium</i> sp. CIPT 140060001
283017		<i>Mycobacterium</i> sp. CIPT 140070001
283018		<i>Mycobacterium</i> sp. CIPT 140070002
283019		<i>Mycobacterium</i> sp. CIPT 140070003
283020		<i>Mycobacterium</i> sp. CIPT 140070005
283022		<i>Mycobacterium</i> sp. CIPT 140070007
283021		<i>Mycobacterium</i> sp. CIPT 19980863
219965		<i>Mycobacterium</i> sp. N256
219966		<i>Mycobacterium</i> sp. N405
219967		<i>Mycobacterium</i> sp. N406
392322		<i>Mycobacterium</i> sp. 'sarcoidosis patient #1a'
394232		<i>Mycobacterium</i> sp. 'sarcoidosis patient #1b'
392323		<i>Mycobacterium</i> sp. 'sarcoidosis patient #2'
394233		<i>Mycobacterium</i> sp. 'sarcoidosis patient #3'
394234		<i>Mycobacterium</i> sp. 'sarcoidosis patient #4'
394235		<i>Mycobacterium</i> sp. 'sarcoidosis patient #5'
1773	MYCTU	<i>Mycobacterium tuberculosis</i>
164513		<i>Mycobacterium tuberculosis</i> 210
348776		<i>Mycobacterium tuberculosis</i> C
83331		<i>Mycobacterium tuberculosis</i> CDC1551
83332		<i>Mycobacterium tuberculosis</i> H37Rv
478434		<i>Mycobacterium tuberculosis</i> KZN 1435
478433		<i>Mycobacterium tuberculosis</i> KZN 4207
478435		<i>Mycobacterium tuberculosis</i> KZN 605
395095		<i>Mycobacterium tuberculosis</i> str. Haarlem
419947	MYCTA	<i>Mycobacterium tuberculosis</i> (strain ATCC 25177 / H37Ra)
336982	MYCTF	<i>Mycobacterium tuberculosis</i> (strain F11)
182785		<i>Mycobacterium tuberculosis</i> subsp. <i>tuberculosis</i>

from NEWT UniProt Taxonomy Browser

The human form of tuberculosis is an acute or chronic infectious disease caused especially by *Mycobacterium tuberculosis* of the human or bovine type. The human infection by *Mycobacterium leprae* is called leprosy.

Numerous variants of these related strains exist, including *M. africanum*, discovered recently in human inhabitants of South Africa and similar to the bovine and human forms, and *M. microti*, infecting voles (various authors, cited in Barnes, 2005, p. 139).

It is important to keep in mind that some parasitic mycobacteria can migrate from one species of host to another, and back again to the original host species. Changing host microenvironments induces a shift in the dominant microbe form, allowing colonization to be successful, while retaining some of the forms capable of colonizing the former host species or another species. Thus, strains within the *Mycobacterium tuberculosis complex* can move back and forth between voles and cattle, and between cattle and humans, with the dominant variant shifting each time (Barnes, 2005). Other bacteria can produce diseases like TB in patients with a particular history of immunodeficiency: for example *M. avium*, known to infect birds, causes a TB-like disease especially in patients with HIV infection.

All these mycobacteria have a common characteristic: a staining affinity for fuchsin (red) of an intensity sufficient to resist destaining by acid solutions (acid-fast). The species are classified on the basis of cultural colony differences (e.g. colony form, rate of growth, pigment formulation) and biochemical features.

A general list with the principal features is shown in the table 3.2. This list is neither recent nor complete, but it is useful to give an idea about features of these mycobacteria. *M. tuberculosis*, *M. bovis* and *M. leprae* (the first three species listed) produce primary disease in apparently otherwise healthy humans. Each of the diseases caused by these three species usually presents clinical features distinctly different from those produced by either of the other two, especially for the mentioned leprosy. The remaining listed organisms usually produce disease in humans with at least partial immunosuppression or in organs compromised by other disease states. In a minority, primary infections of apparently normal humans may occur. These species

are termed ‘atypical mycobacteria’ or ‘MOTT’ (‘Mycobacteria Other Than Tuberculosis’), and newly identified species of this group continue to be reported.

Table 3.2. Features of *Mycobacterium* Species

Species	Human disease ²	Reservoir ³	Pigment ⁴	Geographic distribution ⁵
<i>M. tuberculosis</i>	L, N, D, B	Humans	N	W
<i>M. bovis</i>	G, N, (L)	A	N	W
<i>M. leprae</i>	S, D	U	-	W
<i>M. kansasii</i>	L, N	W, M	P	NA
<i>M. intracellulare</i>	L, (N, D)	W, S, H, A	N	W
<i>M. avium</i>	L, (N, D)	W, S, H, A	N	W
<i>M. simiae</i>	L	U	P	NA, E
<i>M. szulgai</i>	L	U	S	
<i>M. mageritense</i>	L	W, S, H, A	N	E, AU, NA
<i>M. xenopi</i>	L	U	S	E, NA
<i>M. asiaticum</i>	L	U	P	E, AU, NA, AS
<i>M. chelonae</i>	(L, S)	U	N	
<i>M. scrofulaceum</i>	N, (L)	W, S	S	
<i>M. marinum</i>	S	W	P	W
<i>M. haemophilum</i>	S	W, S, H, A	N	AU, NA
<i>M. ulcerans</i>	S	S	N	W
<i>M. fortuitum</i>	(E)	W, S, H, A	N	W
<i>M. goodii</i>	0	W, S, H	S	
<i>M. flavescens</i>	0	W, S, H	S	
<i>M. gastri</i>	0	W, S	N	
<i>M. terrae complex</i> ¹	0	W, S	N	
<i>M. phlei</i>	0	W, S	S	
<i>M. smegmatis</i>	0	W, S	N	
<i>M. vaccae</i>	0	W, S	S	

¹ Includes *M. terrae*, *M. triviale*, *M. novum* and *M. nonchromogenicum*.

² B, bone; D, disseminated; E, eye; G, gastroenterial; L, lung; M, meninges; N, lymph node; S, skin.

³ A, animal; H, sputum of healthy persons; M, milk; S, soil; U, unknown; W, water.

⁴ P, photochromogen; S, skotochromoge; N, nonchromogen.

⁵ AS, Asia; AU, Australia; E, Europe; NA, North America; SA, South America; W, worldwide.

modified from Aufderheide and Rodríguez-Martin, 1998

3.1.2 Human disease

Human infection by *M. tuberculosis* is usually acquired by inhaling bacilli-laden moisture droplets coughed into the air by a lung-infected human and thus the disease commonly begins as a respiratory infection. *Mycobacterium tuberculosis* can survive for period of outside the host, protected by its complex lipid capsule. Depending on the temperature, mycobacteria in sputum can survive for several months in shaded areas. Direct sunlight destroys the microbes quickly, but they can survive within dark, manmade structures with poor sanitation and poor ventilation for human beings and cattle (Barnes, 2005). The reservoir of *M. bovis*, however, lays in animals – especially cattle – though the specific animal type varies geographically and with cultural practices. Kovalyov (1989, cited in Aufderheide and Rodríguez-Martin, 1998, p. 118) reports, for example, that 30% of the camels shed this organism in their secretions. Consumption of food, especially milk, from these infected animals produces bacterial oropharyngeal penetration with infection of the cervical lymph node draining that area and, less frequently, gastrointestinal infection.

However, pulmonary infection by the aerosol route is the most common form of human infection. The mycobacteria end up in the tiny air sacs (alveoli) where the oxygen breathed in gets absorbed into the bloodstream and carbon dioxide from the blood is expelled. Local macrophage-type cells engulf the invaders and carry them to adjacent lymph nodes in the lungs, where the battle between microbes and host immune cells begins. The next response depends on the host's immune system.

The lipid cell walls of the mycobacteria can resist enzyme actions designed to destroy foreign pathogens within the enclosed vesicles of the macrophages: the bacteria can survive and proliferate within the protective barrier of macrophage. Once the mycobacteria break out of the cells, they tend to deviate from their classic rod shape into a variety of stealth forms: colonies of

fungi-like creeping spindles, virus-like forms and large spherical shapes containing numerous microbes. Changing form helps them to adapt to different microenvironments within the host, and to avoid detection by the immune system as they navigate between and within macrophages. These changes are continuous, from one form to another, depending on the circumstances; they can also remain latent for long periods within macrophages, capable of reactivating when the microenvironment of the host becomes more receptive to growth (Mattman, 1993, cited in Barnes, 2005).

Immune Response

Most individuals infected with *Mycobacterium tuberculosis* never develop the disease, because they are stopped within the macrophages. Since the internal enzymes (lysozymes) within the vesicles of the macrophage are not strong enough to kill the microbes, two other potent enzymes, (phospholipase C and acid phosphatase) must be produced to destroy them. Production of these enzymes depends on instruction from CD₄ T cells: they receive dual signals (one sent to the surface of the macrophage by MHC molecules (MHC, Major Histocompatibility Complex), and another originating from the infected cell's surface), and thus they stimulate infected macrophages to release the more potent enzymes to destroy the microbes within their vesicles. The initial infection ends with this immediate immune response between CD₄⁺ T cells and macrophages (Barnes, 2005).

If one or more steps of this complex immune response don't work, the mycobacteria can then proliferate and spread unless inflammatory immune cells manage to surround them with a chemical barrier and seal them within a fibrous capsule (tubercle), before they break away from the site of invasion. Sometimes the capsule can be reinforced with calcification or can turn to bone (Ghon foci) to prevent the invaders from escaping.

Studies with mice indicate that a gene within the MHC system of macrophage regulates the responses to infection by the mycobacteria (Schurr and

Skamene, 1996, cited in Barnes, 2005). Without this gene, the macrophages fail to signal the CD4⁺ T cells. Immune systems with impaired CD4⁺ T cells function, such as those with HIV infection, cannot respond to signals from infected macrophages, and the disease takes over. Hypothetically, out of twenty healthy, unrelated individuals exposed to one individual with infectious pulmonary tuberculosis, five to ten would become infected but only one would develop the disease (Adler and Rose, 1996, cited in Barnes, 2005). But, Barnes adds, if these twenty individuals shared a common genetic MHC flaw hampering their ability to fight the disease, or if they were HIV-positive, most of them would develop some form of tuberculosis (Barnes, 2005).

Genes

As just reported, in the majority of infectious diseases like TB only a proportion of individuals exposed to a pathogen become infected and develop clinically evident disease. At least in part, this inter-individual variability is determined by the combined effect of host proteins encoded by a series of genes that control the quantity and quality of host-parasite interaction and host immune responses (Marquet and Schurr, 2001).

Evidence of genetic variability in human susceptibility to tuberculosis is difficult to achieve. Bloom and Small (1998) remember that Rich in 1944 reported that the severity of disease was greater in blacks infected with tuberculosis than in whites. Stead *et al.* (1990) found that the rate of conversion of tuberculin tests from negative to positive among blacks in nursing homes in Arkansas was twice the rate among whites. Studies of twins indicated a greater concordance for tuberculosis in monozygotic than in dizygotic twins. A report of an emerging epidemic of tuberculosis among the Yanomami Indians of Brazil, a population isolated from contact with Europeans until the 1960s, indicated that 6.4 percent of the population has active disease and that, in contrast to Europeans who have experienced tuberculosis for centuries, fewer than half of the Yanomami has a positive tuberculin test (Sousa A.O. *et al.*, 1997).

In 1970s genetic studies in mice revealed a gene on chromosome 1, originally termed *Bcg*, that controlled resistance to the early growth of “bacille Calmette–Guérin”, strains derived from *M. bovis* that were used in attenuated vaccines (Bloom and Small, 1998). Although it remained to be established whether this gene controls resistance to virulent *M. tuberculosis* infection in mice, it does confer resistance to other intracellular organisms, such as leishmania and salmonella. This mouse gene, renamed as the gene for natural-resistance–associated macrophage protein 1 (*Nramp1*), encodes a transmembrane protein whose function is unknown but whose DNA sequence has similarities to those of nitrate or iron transporters. Humans have a homologue of this gene on chromosome 2. Several polymorphisms in the NRAMP1 gene were associated with increased susceptibility to tuberculosis. In contrast to the dominance of the resistant allele in the mouse model, susceptibility to tuberculosis appeared to be dominant in humans (Bellamy et al., 1998).

Numerous studies have analyzed a possible contribution of genetic factors to tuberculosis susceptibility; the most probable candidates are: 1) *NRAMP1*, as cited above; 2) *HLA* reported for different populations (Goldfeld et al., 1998); 3) *VDR* that is a variation in the vitamin D receptor gene (Wilkinson et al., 2000); 4) *MBL*, called also *MBP*, that is involved to activate the classical complement pathway and phagocytosis leading to neutralization of the pathogen (Hoal-van Helde et al., 1999); and 5) *IL-1Ra* and *IL-1b* (Juffermans et al., 1998).

In the table 3.2 there are some examples of significant associations or linkages between selected genes and risk of *Mycobacterium tuberculosis* (Marquet and Schurr, 2001).

Table 3.3 Examples of significant associations or linkages between selected genes and risk of *Mycobacterium tuberculosis*

Genes Associated or Linked with Specific Phenotype	Populations and References
MHC class II	
HLA-DR2 (pulmonary tuberculosis)	Indian (Brahmajothi <i>et al.</i> , 1991) Indonesian (Bothamley <i>et al.</i> , 1989)
HLA-DRB1 (pulmonary tuberculosis)	Indian (Ravikumar <i>et al.</i> , 1999)
HLA-DQB1 (tuberculosis progression)	Cambodian (Goldfeld <i>et al.</i> , 1998)
HLA-DQB1 (pulmonary tuberculosis)	Indian (Ravikumar <i>et al.</i> , 1999)
NRAMP1 (pulmonary tuberculosis)	Gambian (Bellamy <i>et al.</i> , 1998) Canadian Indian (Greenwood <i>et al.</i> , 2000)
VDR (pulmonary tuberculosis)	Gambian (Bellamy <i>et al.</i> , 1998) Gujarati (Wilkinson <i>et al.</i> , 2000)
MBL	
(pulmonary tuberculosis)	Indian (Servaraj <i>et al.</i> , 1999)
(tuberculosis meningitis)	Coloured (Hoal-van Helden <i>et al.</i> , 1999)
IL-1RA/IL-1b	Gujarati (Wilkinson <i>et al.</i> , 2000)

Modified from Marquet and Schurr, 2001

Traditionally, protective immunity to tuberculosis has been ascribed to T-cell-mediated immunity, with CD4⁺ T cells playing a crucial role, as reported above in this chapter. Recent immunological and genetic studies support the long-standing notion that innate immunity is also relevant in tuberculosis. Van Crevel *et al.* (2002) put emphasis on these natural, innate host defence mechanisms, referring to experimental data (e.g., studies in gene knockout mice) and epidemiological, immunological, and genetic studies in human tuberculosis. The first step in the innate host defence is the cellular uptake of *M. tuberculosis*, which involves different cellular receptors and humoral factors. Toll-like receptors seem to play a crucial role in immune recognition of *M. tuberculosis*, which is the next step. The subsequent inflammatory response is regulated by production of pro- and anti-inflammatory cytokines and chemokines. Different natural effector mechanisms for killing of *M.*

tuberculosis have now been identified. Finally, the innate host response is necessary for induction of adaptive immunity to *M. tuberculosis*.

3.1.3 Expression of disease

Uncontrolled initial infections develop into acute, generalized infections as the mycobacteria enter the bloodstream and spread rapidly throughout the body. Young children and infants with inadequate immune responses can be especially vulnerable to developing this type of acute infection, and about half of those exposed to the disease under the age of three will die from it.

Reactivated infection can eventually be contained again, if the immune system regains control, but often the growth of the imprisoned, revitalized mycobacteria cannot be stopped. The disease introduces alternative phases, with long periods of good health followed by bouts of suffering. The mycobacteria proliferate and expand, straining the barriers surrounding them, and creating adjacent bloody vessels and other tissues (Lack and Connor, 1997, cited in Barnes, 2005).

The tissue destruction caused by reactivated tuberculosis in the lungs results in fever, fatigue, night sweats, and emaciation. This stage is followed by cough, chest pain, spitting up of blood-tinged phlegm and hoarseness. Death come eventually as the lung deteriorate.

Reactivated tuberculosis can spread to other parts of the body, lymph nodes, heart, kidneys, larynx, bones and joints. Children and young adults become susceptible to chronic middle ear and mastoid infection with mycobacteria, introduced directly through of the Eustachian tubes from the throat, or carried there by the blood circulation. This can lead to severe hearing loss (Various Authors, cited by Barnes, 2005).

Localized infection of lymph nodes away from the lungs frequently develops with reactivated infection, particularly within the cervical lymph nodes of the neck. This form of tuberculosis, referred to as scrofula, can usually be found in young adults where tuberculosis has become endemic. Infection of the intestinal tract can happen from directly ingesting contaminated milk from diseased cows, or from initial infection in the lungs by swallowing infected sputum, or, sometimes, it can spread from the blood circulation into the intestines. Intestinal tuberculosis can be expressed as a fibrous mass or as scattered small nodules that tend to ulcerate and bleed, similar to the lesion of Chron's disease and colitis. Symptoms include abdominal discomfort, pain, weight loss, fever, weakness, vomiting, diarrhea and constipation.

The most common expression of skeletal tuberculosis occurs in the spine. The disease localizes mostly in the vertebrae of the lower back. The granulomas formed by the disease slowly destroy the infected vertebrae, lead to collapse of the lower spine, producing a distinct angular, hunched back known as Pott's disease. Infection can also localize within the red hemopoietic marrow of other bones and adjacent joints, leading to localized swelling, pain and deformity. Occasionally mycobacteria can enter through a break in the skin, producing a chronic, localized skin infection. Occasionally mycobacteria can reach the skin by way of the bloodstream to form skin lesions. Skin infections, referred to as *Lupis vulgaris*, usually derive from butchering and skinning infected animals.

3.2 Introduction on tuberculosis in history

Aufderheide (Aufderheide and Rodríguez-Martin, 1998) reports that three potential sources of information about tuberculosis in antiquity are

available to the historian: iconography, texts and bodies. They are, however, not of equal value.

The images are fallible, whether as rupestrian art, as monumental and textual illustrations or as sculptured figurines. In these contexts, the feature suggestive of tuberculosis is usually a pronounced kyphosis. Southwestern Native American rock art commonly includes a flute-playing hunchback once suspected of affected with Pott's disease, but now generally accepted as related to religious representation of a Hopi Katsina Character Kokopolo (Morse, 1967, cited in Aufderheide and Rodríguez-Martin, 1998, p. 125). The many Egyptian tomb inscriptions demonstrating what appear to be rounded spinal deformities are primarily the product of presenting the upper trunk in frontal view while the remainder of the body is seen in profile. Wood, clay or ivory figurines only rarely conform well to the anatomical characteristics of a tuberculous gibbus.

Almost all of ancient literary sources are treacherous. We have to consider that the relationship of symptom clusters to a single, specific infective agent is a relatively recent medical concept, thus the older descriptions must be approached with utmost caution and with full knowledge that ancient views of medical cosmos provided no stimulus to separate out various diseases producing similar symptoms or to recognize the common cause of a condition such as tuberculosis when it produces lung disease in one patient and ulcerating neck sores in another (Aufderheide and Rodríguez-Martin, 1998). Also the Egyptian medical papyri, which are famous for their medical analysis, do not contain any clear descriptions of tuberculosis (Steinbock, 1976). The earliest literary references to the disease come from the Vedic Hymns of India around 2000 B.C., indicating that the disease was present on Indian subcontinent, and possible descriptions in Bible around 700 B.C. Aufderheide and Rodríguez-Martin (1998) remember the early written records in China dating around 1300 B.C.. A Mesopotamian text, from around 675 B.C., describes tuberculosis-like symptoms of fever, cough, purulent and bloody

sputum and a report by Hippocrates in Greece around 400 B.C. describes symptoms of tuberculosis (Barnes, 2005). The speculations of Greek physicians constituting the Hippocratic corpus are an exception to the usually vague literary references to tuberculosis. Aufderheide remembers that physicians of Hippocrates' era can not be expected to have understood clearly that the pulmonary, lymphatic and skeletal forms of tuberculous infection were but different manifestations of a single infectious agent. Singularly, they describe the Pott's deformity with surprising specificity, not only the kyphosis-producing changes but even the increased vertebral body length of the lordotic spinal segment, the paravertebral (psoas) abscess, and comment further that 'they have, also, as a rule, hard and unripened tubercles in the lungs'. Also the Roman literature from 900 B.C. on contains many descriptions on tuberculosis (Steinbock, 1976).

The human remains are, without doubts, the most reliable of the three potential sources of information noted by Aufderheide and mentioned above.

3.2.1 Antiquity

Old World. The oldest evidence of human tuberculosis comes from human bones associated with cattle bones and recovered in two sites from western Italy, ("Arene Candide" cave and "Arma dell'Aquila" cave, Liguria), both dated 4000-3520 B.C by radiocarbon (Formicola *et al.*, 1987; Canci *et al.* 1996). These tuberculosis evidences consisted in a 90° sharply angulated, thoracolumbar kyphosis secondary to complete destruction of the vertebral bodies of T11 and T12 with minimal new bone formation. Human tuberculosis spread into northwestern Europe, as evidenced in the skeletal remains of a young woman (22-30 years old) from the Karlstrup hill in Zealand, Denmark, relating to the Danish Neolithic Age between 2500 and 1500 B.C. (Sager *et al.*, 1975, cited in Aufderheide and Rodríguez-Martin, 1998, p. 126 and in Barnes, 2005). Bartels (1907, cited in Ortner and Putshar, 1985 and in

Aufderheide and Rodríguez-Martin, 1998, p. 126) also reported an adult male excavated from a Neolithic site near Heidelberg, Germany, with a 45° angular, thoracic kyphotic spine lesion due to complete destruction of the bodies of vertebrae T4 and T5 with a partial destruction of T3 and T6. These three cases confirm that tuberculosis was a well-established condition in Europe during the Neolithic Age: at the modern rate (1-3%) of skeletal involvement in tuberculous patient, these three cases imply the presence of 100-300 humans infected with the disease.

By the beginning of Middle Age human tuberculosis had become well known throughout Europe. The disease reached epidemic proportions in crowded villages and cities with poor sanitation, and peaked during the industrial revolution. The disease appears to have been unknown in sub-Saharan Africa until Europeans introduced it (Cockburn, 1963, cited in Barnes, 2005).

New World. Native Americans suffered severely from tuberculosis once Europeans conquered their lands and crowded them onto reservations (Cockburn, 1963, Dubos and Dubos, 1952, both cited in Barnes, 2005). The disease took its toll, aided by poor nutrition, unsanitary conditions and the stress of confinement. Doctors assumed that the native people suffered more than Europeans because they had never been exposed to the disease before the European conquest of Americas. The most serious problems in differential diagnosis arises in distinguishing between pyogenic osteomyelitis, perhaps the mycotic infection, tuberculosis and, in some cases, brucellosis. Assuming that all of these infectious conditions are endemic, tuberculosis, being the most frequent morbid condition, becomes the most likely diagnosis on the basis of probability (Ortner and Putshar, 1985). The pre-Columbian presence of tuberculosis in the New World had remained controversial for many years. However, large evidence has been found in ancient Native American human remains to show that human tuberculosis existed in the New World long before European conquest. The earliest example of skeletal tuberculosis comes from Peru, dating around 160 B.C. (Allison *et al.*, 1981, cited in

Barnes, 2005). The same authors (Allison *et al.*, 1973, cited in Aufderheide and Rodríguez-Martin, 1998, p. 127) described one of the most convincing cases in Nazca culture (radiocarbon dated A.D. 700) mummified child with characteristic Pott's deformity, psoas abscess and miliary lesions in the kidney, lung, liver and heart, acid-fast bacilli being demonstrable in abundance in the miliary lesions. More recently, *Mycobacterium tuberculosis* DNA has been identified in a vertebral lesion dating A.D. 1000 from northern Chile (Arriaza *et al.*, 1995). Further, other modern studies confirmed that the disease was known before European conquest. Barnes reports that the earliest evidence for human tuberculosis in North America comes from the southwestern United States. The disease existed in prehistoric Puebloan peoples at Mesa Verde in southwestern Colorado, dating from A.D. 750-900, and in a small Kayenta village in northeastern Arizona, dating A.D. 875-975 (Barnes, 2005). Other cases of the disease have been reported in prehistoric southwestern village sites dated later, from A.D. 900 to 1500. The Spanish did not arrive in this area until 1540. Barnes studied nine prehistoric skeletal collections from this area, finding one or more cases of skeletal tuberculosis in each collection. The prehistoric village of Puye on the west side of the Rio Grande Valley in north-central New Mexico showed 4% of skeletal sample with skeletal tuberculosis between 1300 and 1540. Another village from the same time period, Hawikuh near the Arizona border in New Mexico, showed a 7% frequency of the disease. Considering that about 5-7% of individuals suffering from tuberculosis develop skeletal lesions, Barnes supposes that the disease was endemic in the prehistoric villages of the American Southwest (Barnes, 2005). Evidence for the presence of tuberculosis dating from A.D. 1000 has been found in village populations in the southeastern United States, the central Mississippian Valley of the Midwest, and the upper Midwest in North Dakota and southeastern Saskatchewan. The frequency of individuals with bone lesions ranging from 5% to 7%, indicates that TB had also reached

endemic proportions in these areas (Buikstra and Williams, 1991, cited in Barnes, 2005).

The dramatic episodes that native North Americans suffered after contact with European infectious agents, suggested they had 'lost their immunity' during the millennia of separation following their New World colonization (the 'virgin soil' syndrome). Later, when chronic illnesses such as tuberculosis reached epidemic proportions on reservations it was not unexpected that the contribution made by the degradation, malnutrition, crowding and effects of social upheaval on the reservations would be obscured by a cultural concept that was content to explain the phenomenon on an immunological basis (Aufderheide and Rodríguez-Martin, 1998).

As Mackowiak and colleagues summarized (Mackowiak et al., 2005) after more than a century of debate, it is now firmly established that tuberculosis existed in the New World before the arrival of Columbus. Although proof of the existence of tuberculosis in pre-Columbian Mesoamerica is presently lacking, the recent demonstration of mycobacterial DNA by PCR amplification of specimens from ancient human tissues recovered from sites elsewhere in the Americas removes any doubt that the infection was already endemic in the New World before the European arrival. What is not yet known is how or when, exactly, the infection reached the Americas, how it spread from one continent to the other, and whether the pre-Columbian infection was caused by *Mycobacterium tuberculosis* or *Mycobacterium bovis* (Mackowiak et al., 2005).

Asia. The spread of human tuberculosis into Asia has been documented in the mummified remains of Marquise of Tai, a middle-aged woman belonging to the ruling elite of the early Western Han dynasty in Changsha, Hunan, China, around 100 B.C.; the disease reached Japan by the protohistoric (Kofun period) before A.D. 200 (Cockburn, 1980, and Suzuki, 1985, cited in Barnes, 2005). There are several reports of lesions attributed to

tuberculosis in Egyptian skeletal material. Eliot-Smith and Ruffer (1910, cited in Ortner and Putshar, 1985 and in Aufderheide and Rodríguez-Martin, 1998, p. 127) reported a case of probable tuberculosis in an Egyptian mummy dating from the Twenty-first Dynasty (ca. 1000 B.C.). Although no tubercle bacilli were found in any of the soft tissue lesions of this particular sample, the morphological evidence for tuberculosis is strong and Aufderheide reported this case as the most convincing example from Egypt. In fact, in addition to a characteristic skeletal lesion of Pott's deformity, the adjacent soft tissues of a large paravertebral (psoas) abscess were preserved. Zimmerman (1977, cited in Aufderheide and Rodríguez-Martin, 1998, p. 127) reported a 5 year old child with recent pulmonary hemorrhage and tuberculosis of the lung and vertebra in the New Kingdom Upper Egypt tomb of the first high priest of Amun of Ramses II: in this case bacilli were demonstrated in vertebral sections. Recently, the characterization of *Mycobacterium tuberculosis* complex DNAs from Egyptian Mummies by spoligotyping was made in bone and soft tissue samples from 85 ancient mummies (Zink *et al.*, 2003). The specimens were obtained from individuals from different tomb complexes in Thebes West, Upper Egypt, which were used for upper social class burials between the Middle Kingdom (since ca. 2050 B.C.) and the Late Period (until ca. 500 B.C.). A total of 25 samples provided a specific positive signal for the presence of *M. tuberculosis* DNA. Finally, we can consider that molecular analyses confirm the morphological evidences of this disease in ancient Egyptian state.

The widespread distribution of disease raises questions of how, when, from, and where human tuberculosis gained entry into New World, but also developed into the entire World. Barnes reports that the evidence strongly supports *Mycobacteria tuberculosis* as the pathogen, with human-to-human transmission in all disease evidences. El Najjar (1979, cited in Barnes, 2005), supposed that humans infected with inactive tuberculosis most likely carried

the disease across the ancient land bridge that once connected Siberia with Alaska during some of the last migrations from the Old World to the New World. Likewise, ancient Polynesian settlers brought the disease to Hawaii. The disease can remain latent for up to thirty years before reactivating into contagious infection. This would have allowed human carriers plenty of time to deliver the disease to a new location. The infection does not rely on large numbers of people for survival in a community. Family groups crowded into poor shelters can maintain the disease within ranks for generations.

Perhaps, the earliest domestication or semi-domestication of cattle occurred much earlier than we realize in Central Asia, followed by the development of human tuberculosis. From there, domestication of cattle and tuberculosis could have spread both west and east. Once the disease had become well established within human populations, it could have spread through human carriers into northeast Asia and into New World. In fact, archaeological evidence shows mixing of Central Asian populations with eastern Asian populations in the far eastern portion of Central Asia, long before the Mongols began to move forward into Central Asia during the second century B.C. The disease could also have spread into Southeast Asia and eventually into Oceania (Oshanin, 1964, cited in Barnes, 2005).

Although recent evidence indicates that *M. tuberculosis* predated *M. bovis* in the Old World, some authors believe that *M. bovis*, which privileges human bones and lymph nodes, was responsible for the pre-Columbian cases of New World tuberculosis, rather than *M. tuberculosis* (Daniel, 2000). If this was the case, human tuberculosis in the Americas likely would have consisted initially only of sporadic infections, because *M. bovis* is rarely transmitted via an airborne route and is not readily spread from human to human. Moreover, until the advent of *M. tuberculosis*, the infection would have been largely confined to its principal animal reservoir, cattle, which, although domesticated in the eastern Mediterranean basin 7000–9000 years earlier, did not reach the New World until imported by the Spanish during the 16th century c.e. (Manchester,

1984 cited in Mackowiak *et al.*, 2005). Given that bovine tuberculosis has been detected in modern llamas and wild buffalos, their ancestors might have transported tuberculosis to the New World across the Bering land bridge before it sank below the Arctic Sea. However, because animals are not a natural host for *M. bovis*, it is more likely that the original cases of American tuberculosis were *M. tuberculosis* infections transported to the new land not by animals, but by infected humans (Mackowiak *et al.*, 2005).

3.2.2 Classical and Medieval Ages

The extra-European data sources are just some Chinese medical text dating to the Sui (A.D. 581-617) and Tang (A.D. 618-907) dynasties that describe chronic, lingering illnesses with pulmonary symptoms that might be those of tuberculosis (Aufderheide and Rodríguez-Martin, 1998). Some writings by Chinese Taoist priests from the twelfth century suggest that consumption may be due to the breathing of 'evil airs', and that living agents may play a significant role (Johnston, 1993, cited in Aufderheide and Rodríguez-Martin, 1998, p.129).

The information from Greece's classical period is largely literary. Aufderheide and Rodríguez-Martin (1998) remember that Homer (about 800 B.C.) is cited as referring tuberculosis; Euryphon (fifth century B.C.) at least listed cough and hemoptysis as symptoms; Hippocratic authors (ca. 400 B.C.) recognized very dissimilar clinical presentations and they did not conduct them as the product of a single etiological agent; Isocrates and Aristotele (late fourth century B.C.) clearly understood the contagious nature of consumption. Galen was so impressed by the etiological role of climate that he include a change of residence to the arid regions of North Africa as a therapeutic measure. While no quantitative estimate is possible on the basis of such observations, it is evident that these conditions occurred at a frequency high enough to allow an

active medical practitioner experience sufficient to recognize them as a syndrome.

Roman writers described consumption during the first century A.D. (Seneca, Ovidio e Celsus). Other authors, like Columella (A.D. 50) and Vegetius (A.D. 420), noted that this type of consumption also affected animals (Meinecke, 1927 cited in Aufderheide and Rodríguez-Martin, 1998).

During medieval period, the majority of population had a rural lifestyle: they lived in small, relatively self-sufficient family clusters and villages, usually walked to their work areas and had only limited opportunities for extensive social contact with large groups. Most of the European continent differed little from this pattern. These conditions were not able to spread a disease like pulmonary tuberculosis, but skeletal collection to search for the evidence are limited. One of the first case of tuberculosis of this period, is recovered by Stirlanda and Waldron (1990) in Britain: they provide examples of several cases, including Pott's disease.

Aufderheide (Aufderheide and Rodríguez-Martin, 1998) remembers that the later part of the Middle Ages and early Renaissance were characterized in part by two closely-linked events that acted to alter the frequency of tuberculosis in the European population and simultaneously to provide us with data from which some concept of tuberculosis prevalence can be derived. These events were the philosophical concept of governance and the dramatic demographic shifts. During this period, both religious and secular movements stimulated the view that an elite population subset with natural leadership qualities had an obligation and right to rule over the remaining bulk of the population. As early as about A.D. 1100 in France and in Britain, the royalty embraced this concept by claiming a divine origin and therefore they enjoyed a 'divine right' to rule. They publicized this viewpoint claiming a royal supernatural healing power of disease, especially for ulcerating lesions of tuberculous cervical adenitis (lymph node infection: scrofula). It was performed in a ritual during which the king touched the sufferer, made a sign

of the cross and then provided the afflicted commoner with a gold coin. In England, this practice was still used in the early 19th century (Roberts, 1987, cited in Aufderheide and Rodríguez-Martin, 1998, p. 129).

3.2.3 Renaissance and industrial revolution

The increase in tuberculosis prevalence and incidence, noted so prominently in the seventeenth century, continued throughout the following hundred years. Gradually, physicians increased their experience and understanding of tuberculosis: in 1700 Manget described the extrapulmonary forms (miliary tuberculosis); in 1768 Whytt described the meningitis form (meningitis tuberculosis) and in 1779 Sir Percivall Pott the spine tuberculosis. But these different manifestations of disease continued to elude physicians, leading to etiological and therapeutic controversy.

By the early nineteenth century, tuberculosis had become the most common cause of death by single disease. In Britain the annual tuberculosis mortality rate peaked at about 400-500/100000 individuals, while in Philadelphia it reached 618/100000 (Aufderheide and Rodríguez-Martin, 1998). However, autopsy studies continued to broaden the understanding of the disease. After 1800, there were some important observations that brought to identify the mycobacterium. In 1821, Laennec suggested that the same agent caused scrofula and extra-pumonary forms. In 1865, Villemin in France injected rabbits with the contents of tubercles and reproduced the disease. In 1882, Robert Kock identified *Mycobaterium tuberculosis* as the etiology of tuberculosis initiating the era of its rational treatment and prevention.

3.2.4 The modern era

Santos (2001) reports that documentary evidence identifies tuberculosis as a major cause of death and one of the most common

pathological conditions plaguing past populations, especially for the post-medieval period in Europe. Following the 17th century, tuberculosis rose to epidemic proportions (Daniel, 1997). For example, in 1667, 20% of all deaths in London were due to tuberculosis (Myers, 1977). Another peak in frequency of TB occurred at the end of the 18th century with the Industrial Revolution, and at the beginning of the 19th century. At that time in the Hôpital de Charité in Paris, 36% of deaths were due to TB (Scannell, 1992). Only after the identification of the infectious agent by Koch in 1882, the tuberculosis diagnosis became more accurate, with the development of methods that permitted positive identification. However, assessing the reliability of past diagnoses documented in historical records is difficult because the clinical manifestations are not pathognomonic of TB and may be the result of other pulmonary diseases. With Koch's discovery, the development of preventive medicine for TB began. In 1921 the TB vaccine (Bacille Calmette-Guérin) was first tested on humans, and its general use began in 1924 (Daniel, 1997). Besides this vaccine, and the development of drug therapy in the 1940s and later, improvement in living conditions and diet in the last few decades have contributed to diminishing the rate and severity of TB, certainly in developed countries. In many European countries and North America, an earlier decrease of cases from the second half of the 19th century is recorded (Wood et al., 1992; Johnston, 1993). A factor that should be considered as a possible explanation for this decline, apart from improvements in the quality of life and developments in medicine, is "herd immunity," or the acquisition of immunity to TB by a human population recently devastated by the infection (Ávila, 1992; Daniel, 1997, p. 28). Despite this decline, since the late 1980s TB has again increased unexpectedly in many industrialised countries (Brown, 1992; Raviglione et al., 1995). Factors likely responsible for this increase include one or more of the following: depressed immune systems, reactivation/reinfection in older people (Seymour, 1992; Daniel, 1997; van Rie et al., 1999), malnutrition, homelessness, poor hygiene, unhealthy living

conditions, infection with HIV, presence of AIDS, infection with multidrug-resistant strains of the mycobacteria, and specific categories of occupations, e.g., healthcare workers (Brown, 1992; Clever and LeGuyader, 1995; Anderson, 1999). These factors, or a combination of them, are now contributing to 8,000 deaths from TB per day worldwide. It is also estimated that one third of the world population is affected by this disease at any time (World Health Organization, 2008).

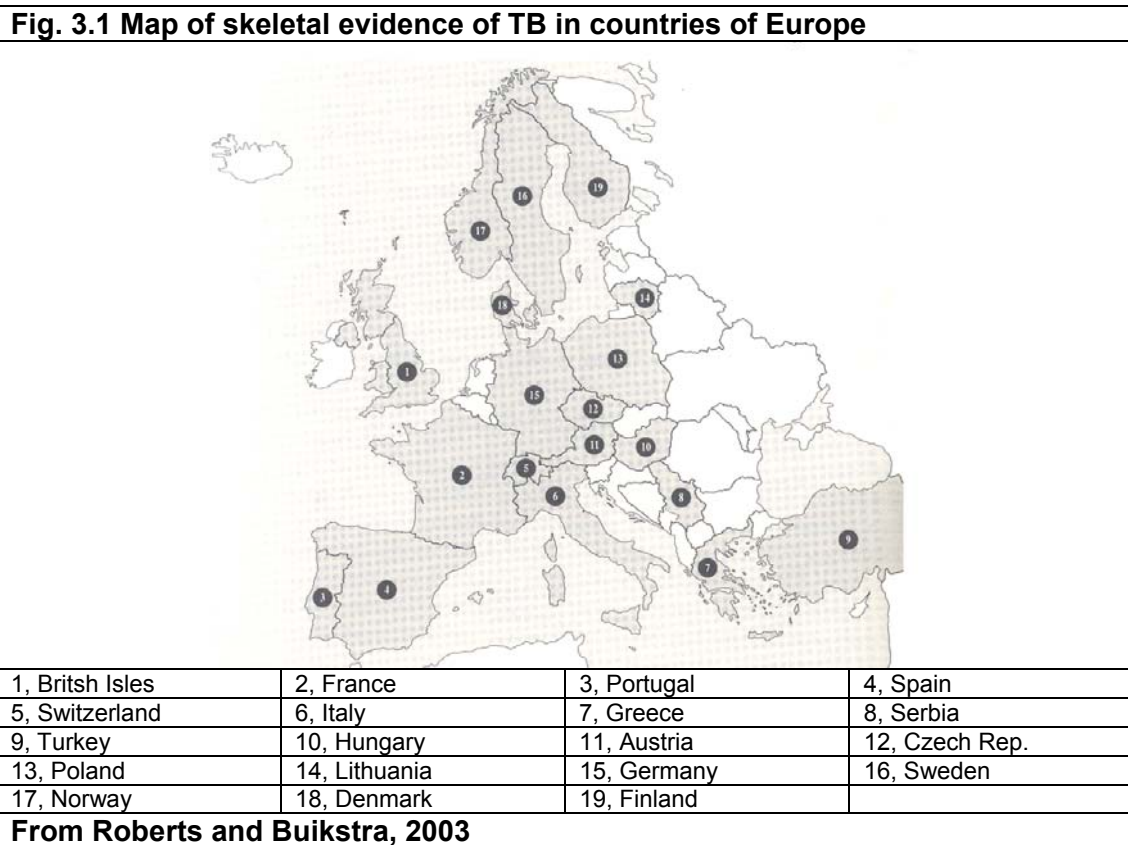
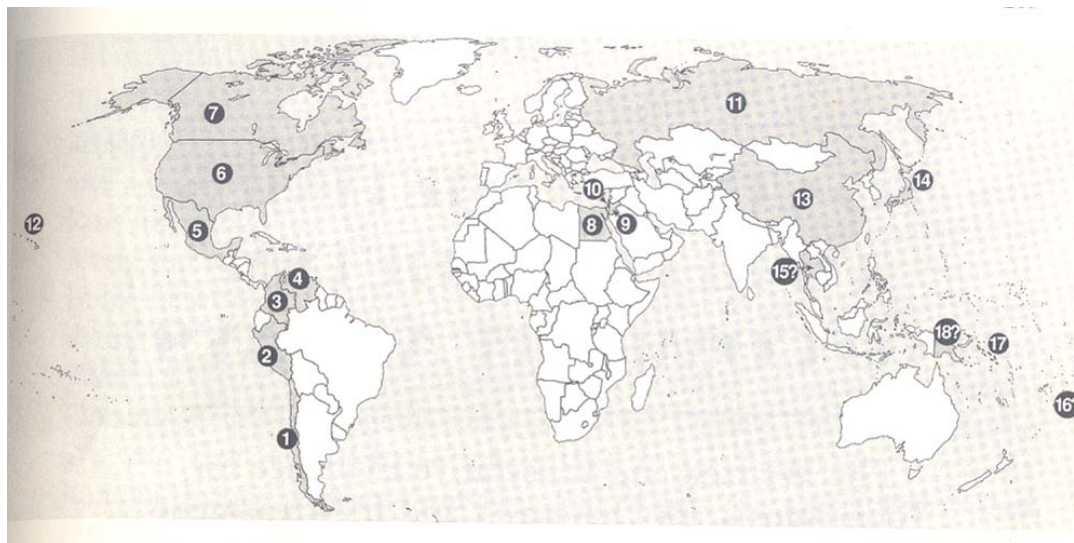


Fig. 3.2 Map of skeletal evidence of TB worldwide, excluding Europe



1, Chile	2, Peru	3, Colombia	4, Venezuela	5, Mexico	6, USA
7, Canada	8, Egypt	9, Jordan	10, Israel	11, Russia	12, Hawaii
13, China	14, Japan	15, Thailand	16, Tonga	17, Solomon Islands	18, Papua New Guinea

From Roberts and Buikstra, 2003

4. Skeletal evidences of Tuberculosis

In the present chapter the skeletal evidences of tuberculosis disease will be presented explaining the classical and better known osseous changes and the minor and less known ones. These last changes are more difficult to individuate, whereas they represented first stages of TB disease.

4.1 Introduction

There are various historical records and pathological findings in ancient human remains, (see the chapter 3), but certain recognition of this infectious condition is seriously constrained by the nature of the disease itself. The problems studying this particular field can be divided in two groups. As described in chapter 2, the first problem is that most infections are acute and the efficient strong immune system prevents the progression of the disease to the bones, or they prove fatal before bone changes are manifest. The second problem is that only rarely infectious diseases produce etiologically specific morphological changes in bones, as reported by various authors (Bosh, 2000 and Dixon and Roberts, 2001, both cited by Maczel, 2003).

Concerning the difficulty on interpretation of health status of past population using osteological remains, there are several issues to consider. Some authors emphasize the interpretation of pathologies and the inference of health, since the development of bone alterations can also be linked to good immunization, according to theory of “better health makes for worse skeletons” (Wood *et al*, 1992). Furthermore, Cohen underlines that most human deaths are probably only weakly related to the chronic illness that human skeletons display (or those pathologies make only a little contribution to the probability of dying), and skeletons may therefore be a relatively

random sample with regard to visible skeletal pathology in the population (Cohen *et al.*, 1994). Generally, Aufderheide and Rodríguez-Martin (1998), report that the lesions of skeletal tuberculosis in non-spinal locations may be indistinguishable from other etiologies: for these reasons, it becomes particularly important to study not only the lesions themselves, but also their distribution within the skeleton and within the populations that are being examined.

The *nature of the material* can also restrict the identification of pathological conditions and infectious disease. As reported in chapter 1, the diagenesis of skeletal remains plays an important role in these studies. Although palaeopathology also uses mummified tissue and calcifications that allow different types of search, these remains represent only a small contribution. The main sources of information are the bone records and teeth, which are often incomplete or biased by archeological conditions, taphonomical processes, time effects and burial assemblages (Nowell and d’Errico, 2007).

Further limitations are represented by *nature of the scientific field* itself. The diagnosis of diseases relies basically on analogous reasoning taking into account the clinical diagnostic criteria, which may not always be appropriate for ancient human remains with a different living conditions, diet and available therapy. It is interesting to note, however, that the obvious discrepancy in prevalence rates between historical and skeletal data may be the result not only of the problems of identifying disease in ancient human remains, but also be explained by incorrect diagnoses in the past (Dixon & Robert, 2001 cited in Maczel, 2003).

Obviously, by pass the problem on the scientific field itself, modern techniques such as densitometry, histology and molecular biology, are now available, if the nature of the remains allows their use, of course.

4.2 Skeletal manifestation

As it was previously outlined, the manifestation of TB depends on several factors, such as the infecting organism, the age of onset, the site of involvement, the host's immune response and the acute or chronic nature of illness (Aufderheide and Rodríguez-Martin, 1998). Although the mycobacteria might enter the human body in two ways, either via the gastrointestinal system (mainly *M. bovis*) or via respiratory system (mainly *M. tuberculosis*) by droplet infection, the skeletal tuberculosis is generally the result of hematogenous spread of infection from soft-tissue foci. As it was described in chapter 2, any aggression of osseous tissue from any infectious agent generates an inflammatory reaction (periostitis, osteitis and osteomyelitis). On dry bones, we can differentiate: periostitis (inflammatory reaction of periostium with often bone proliferation), and osteomyelitis (inflammatory reaction of the cortex and the medullary cavity). Osteomyelitis occurs at the ends of long bones and frequently affects the joints themselves inducing a septic arthritis (Steele and Bramblett, 2000).

Based on clinical data, skeletal involvement in TB is very low: for extrapulmonary TB, the rates for all osseous changes range from 1% to 9 % (data from various authors reported by Santos, 2001), in the pre-antibiotic era the incidence of skeletal involvement is calculated in average 5-7% (Steinbock, 1976). In general, such lesions develop in less than 7% of cases of human tuberculosis (Kelly and Micozzi, 1984).

The characteristic bone alterations in tuberculosis are the consequence of the development of granulation tissue, with a specific tropism for the richly vascularized sites. The diagnosis of TB in archeological human remains relies on the analysis of disease expression: lesion morphology, location and skeletal pattern. Buikstra (1976) pays attention in her complete analysis to epidemiological characteristics, like age of onset, sex and geographical area. Zimmermann and Kelley (1982) report that females seem to be slightly more

predisposed to TB, but generally it is accepted that skeletal tuberculosis can affect individuals of all ages and both sexes.

The skeletal alterations that actually are connected with tuberculosis can be gathered in “classical TB alterations” and in “MOLAT”, (“Minor Osseous Lesions Attributable to Tuberculosis), formulated by Prof. O. Dutour (Maczel, 2003). The first group consists of characteristic alterations for which there are several clinical and paleopathological literature and osteological collections as referred: they represent TB skeletal changes already in developed stage. The second group of lesions (MOLAT) analyzes the early stages of disease, to identify some diagnostic criteria to recognize it.

The present work studies a small osteological collection (Tedeschi Osteological Collection, T.O.C, of University of Padova, Italy), which was collected in the years from the end of 19th century to the early 20th century with registered cause of death, age at death and job (this collection is introduced in chapter 5). The aim of the present study is to analyze these remains looking for the classical TB alterations and the MOLAT. Using classical morphological anthropology, histology, molecular biology and densitometry of bone tissue, we will try to confirm the various diagnostic criteria. Furthermore, this work, based on data arising before antibiotics became available for treatment, might contribute to the future diagnosis of TB in non-documented skeletal material.

4.2.1 Classical tuberculosis alterations

Tuberculosis is mainly characterized by destruction of skeletal tissue, appearing as a pattern of resorptive lesions with little evidence of proliferative, reactive changes. The bones predominantly affected by tuberculosis are fragile and highly susceptible to post-mortem resorptive processes (Brothwell,

1981). Ortner and Putschar (1985) suggest that general pattern of bone and joint tuberculosis is characterized by several features, listed below.

Very little, if any, perifocal reactive bone formation is shown; the lesion is primarily or exclusively a lytic process.

In long bones, the process is localized in the metaphyses or in the epiphyses.

Sequestra are very uncommon.

Except for *spina ventosa*, periosteal reactive bone formation is very limited. Involvement of soft tissue adjacent to bone, often with skin fistulae, is commonly found.

Hematogenous dissemination to the synovium can preserve joint structure, but joints becoming infected by perforation from a metaphyseal abscess will commonly suffer severe anatomic disruption and even ankylosis.

Like osteomyelitis, peripheral involvement of the growth plate in a growing bone may stimulate growth, but destructive involvement can arrest growth.

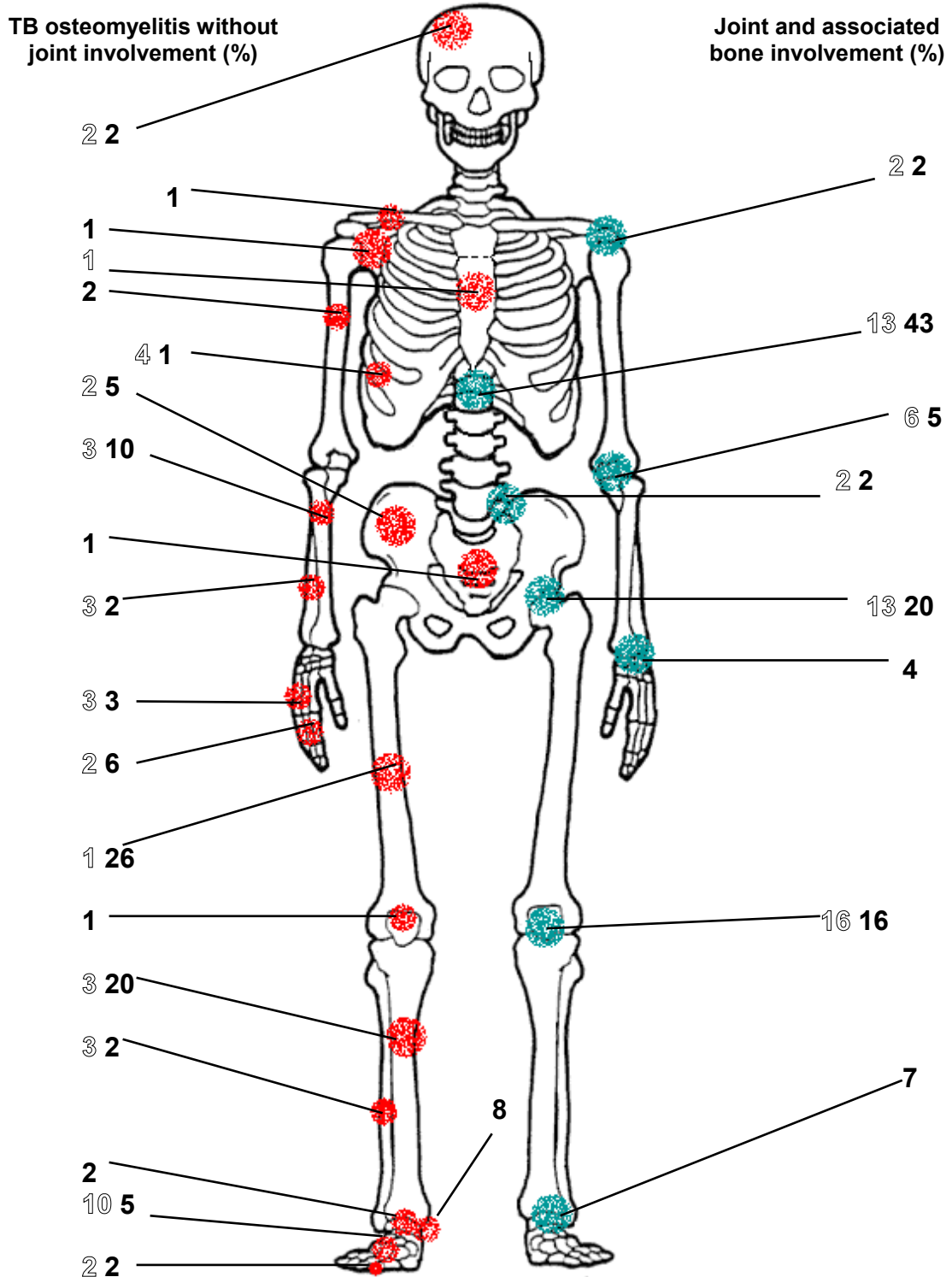
cited in Aufderheide and Rodríguez-Martin, 1998

Multiple skeletal lesions are more common in children than in adults, but constitute the minority (5-15%) of all patients with skeletal tuberculosis (Messner, 1987, cited by Aufderheide and Rodríguez-Martin, 1998).

In fig. 4.1 the frequencies and the distribution of skeletal tuberculosis are reported, they are calculated by Aufderheide and Rodríguez-Martin (1998) and from data by Ortner & Putschar (1985). These values differ from each other in some particular district, but they agree on general involvements of some joints (e.i. spine and hip) with respect to others.

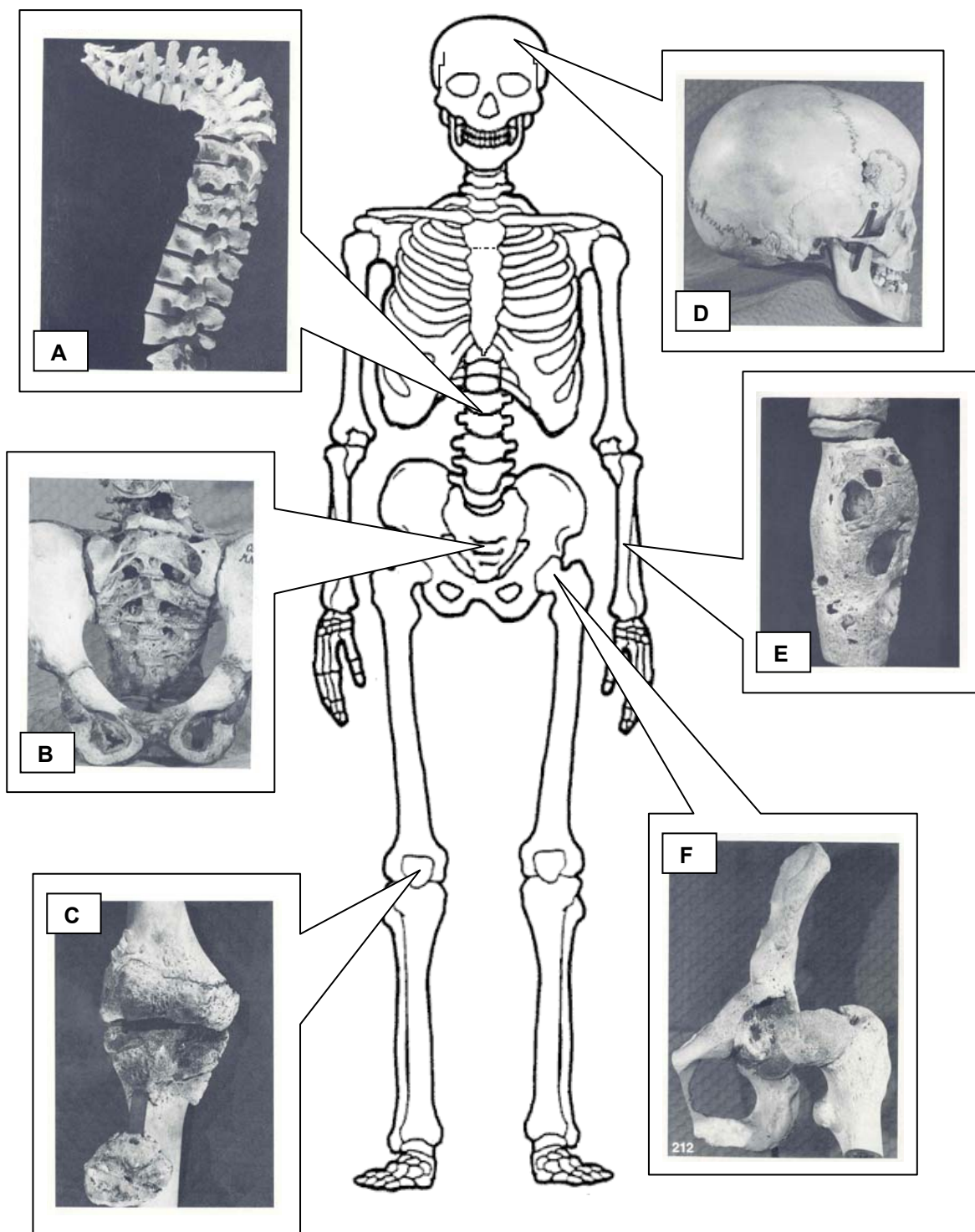
In figure 4.2, are reported some photographic examples of the anatomical districts more frequently involved. The photos are taken from Ortner and Putschar (1985) and represent cases of officially recognized death for TB, which can be considered as examples of diagnosis.

Fig. 4.1 Distribution and frequency of skeletal TB evidence



Data from Auferderheide & Rodriguez-Martin, (1998) - values in colour and data from Ordner & Putchar, (1985) - values in outline.

Fig. 4.2 Classical tuberculosis alteration



A: Spine

B: Lumbosacral

C: Knee

D: Skull

E: TB of proximal radius

F: Hip

Photographic examples of TB at different sites from Ortner and Putschar, 1985

A. Vertebral Tuberculosis

(spondylitis tuberculosa or tuberculous spondylitis or Pott's disease)

The tuberculosis of the spine is the most typical representation of skeletal TB, known since antiquity. This affection - also named Pott's disease - is particularly consists of the tuberculous destruction of vertebral bodies accompanied by kyphosis. The disease is named after Sir Percival Pott, an English surgeon at St. Bartholomew's Hospital in London in the 18th century, who provided the first description.

According to Steinbock (1976), who examined approximately 5618 reported cases, 25 to 50% of all cases of skeletal TB involve the spine, which makes this site of crucial importance to the palaeopathologist for diagnostic criteria.

The spine is usually infected via hematogenous dissemination, but it can be involved by direct extension from adjacent visceral lesions.

The organisms spread from an involved area in the trabecular bone of the vertebral body to a site beneath the anterior longitudinal ligament. Aufderheide and Rodríguez-Martin, (1998) report an interesting distribution within the vertebral body.

- *Anterior* (20%) leading to cortical destruction under the longitudinal ligament and extension of the infection to adjacent vertebrae. The disc height is preserved. Anterior tuberculous disease is associated with spine deformity only rarely.
- *Paradiskal* location (more than 50%) eroding the cartilage and the plate with narrowing of the disk space and causing kyphosis by bone destruction in the metaphyseal region of the vertebrae.
- *Central* (20-30%) that starts in the middle of the vertebral body and spreads to involve the entire vertebral body, producing collapse and kyphosis.

The spine lesions involve the vertebrae with different frequency (see Table 4.1), maybe because it houses the skeleton's largest mass of trabecular bone. Tuberculous

<i>Vertebral level</i>	%
Cervical	6
Thoracic	45
Lumbar	48
Sacral	1

From Aufderheide and Rodríguez-Martin, 1998

mycobacteria are known to grow best under conditions of high oxygen tension, and trabecular bone is extremely vascularized.

The trabecular bone of the infected vertebral body may become destroyed by several mechanisms, creating the characteristic gibbus. These mechanisms include expansion of the initial abscess within the vertebral body, initiation of multiple abscesses *in situ* or deprivation of blood to the trabecular bone (infarction) with bone necrosis. Progressive destruction of the vertebral body by one or more of these causes eventually often reaches a point at which insufficient vertebral trabecular bone remains to support the weight of the upper trunk. Collapse of the vertebral body commonly causes not only shortening of the trunk, but also anterior bending of the spine above the collapsed vertebrae (kyphosis), since the posterior vertebral structures are either usually intact or at least extremely less destroyed (Aufderheide and Rodríguez-Martin, 1998).

The destruction of vertebral body is generally monofocal and only minimal new bone formation is detectable. The inflammatory stimulus might spread further beneath the anterior longitudinal ligament and along the psoas muscle (*cold abscess*). The direct contact with this paravertebral abscess usually causes the tubercular involvement of the inner surface of the ilium as well as of the proximal part of the femur in the form of periosteal reactions (Lichtenstein, 1976).

B. Extra-vertebral Tuberculosis

B.1. Tuberculosis of ribs and sternum

As reported in Fig. 4.1, the involvement of other districts than spine is much less frequency, but the involvement of ribs in TB is not rare, with lytic lesions on the middle or lower parts of them, usually as a direct extension from adjacent tuberculous foci (Baker, 1999, cited by Maczel, 2003).

The theory that the tubercle bacillus responsible for the infection can pass from the initial peripheral focus in the lungs via the pleura to the ribs has been proven in clinical circumstances (Roberts, 1994).

Roberts and colleagues (Roberts *et al.*, 1994) studied the ribs of more than 1718 individuals from Terry – Trotter Collection and in their study, total individuals with rib lesions were 380, of which 165 with non-pulmonary cause of death, 157 with TB, 51 with pulmonary disease but not TB and 7 with TB and another pulmonary disease. This comparison of the occurrence and distribution of rib lesions suggests that overall there is not a marked difference between the two major groups of data studied (Tb and non pulmonary disease causes of death). A general final consideration is reported by several Authors: these lesions could be a non specific indicator of pulmonary stress, which could be considered with pathological features such as dental enamel hypoplasia or porotic hyperostosis (Pfeiffer, 1991; Goodman *et al.*, 1980; Stuart-Macadam, 1991).

Concerning the involvement of sternum in tuberculosis, it is uncommon, and when it does occur, the manubrium is most frequently involved by a lytic lesion, with complete destruction of the sternal body. Sclerosis and loss of the normal texture represent the late deformity (Aufderheide and Rodríguez-Martin, 1998).

Recently, since 1985, in living patients, tuberculous sternal osteomyelitis has been reported in association with spontaneous sternal fracture, disseminated tuberculosis, thalassemia, and coronary artery-bypass surgery. Some authors outline that the incidence of TB has recently increased 1.8%/year worldwide

due to inadequate local resources and the global epidemic of HIV infection, and consequently, in this period, there are also various new cases of tuberculosis in sternal bones (Mohammadi, 2007).

B.2. Tuberculosis of the diaphysis of the long bones

These types of lesions (*tuberculous osteomyelitis*) are rare in adults and even in children they aren't really common. The bones affected most frequently are tibia, ulna, radius, humerus, femur and fibula. The disease usually begins under the periostium and may spread into the epiphysis. The disease usually begins under the periostium and may spread into the epiphysis. In children, lesions near the bone ends may involve the growth plate, distorting bone development sufficiently to cause deformity.

The tuberculous infection might also involve the shaft of short tubular bones of hands and feet, also known as *tuberculous dactylitis*. The first anatomical description of *spina ventosa*, an extension of the bone with cystic appearance, especially seen in children, in short tubular bones is attributed to Boyer, at the beginning of the 19th century. This affection is more common in children than in adults, possibly because in children they contain trabecular bone with activity productive marrow (Aufderheide and Rodríguez-Martin, 1998).

B.3. Tuberculosis of the joints (tuberculous arthritis)

About 90% of tuberculosis skeletal lesions involve a joint. Infection of the joint is generally unilateral and develops as a result of the disease process breaking through the epiphyseal cartilage or affecting the synovial membrane. In joint affection, the erosion of the articular surfaces might be followed by subluxation and bone ankylosis.

Aufderheide (Aufderheide and Rodríguez-Martin, 1998) reports that frequently articular tuberculosis results from a combination of osteomyelitis and arthritis. Among patients with tuberculous arthritis, **hip** involvement (*coxitis tuberculosa*) is second only to the spine, but the bacteria often spread and

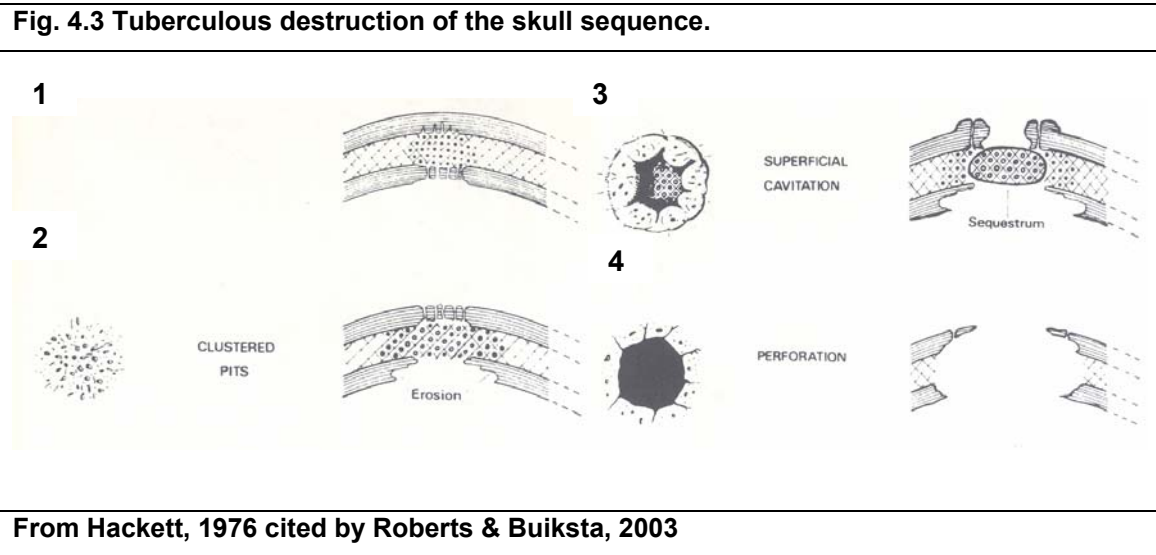
settle in the **knee**, too (*gonitis tuberculosa*). According to Steinbock (1976), the hip joint is affected in 15 to 30% of all cases, and the knee is the site of involvement in 10 to 20%. Other major sites of tubercular destruction are the **ankle** joints, the bones of fingers and toes, and the **sacroiliac** joint.

Because of its hematogenous spread, however, tuberculosis may involve any bone of the skeleton. In general, tubercular involvement of two or more different skeletal areas is rather uncommon. When it does occur, the spine, hip, and knee often affected simultaneously.

B.4. Tuberculosis of the skull

Sporadically the skull is a site of skeletal tuberculosis. All authors agree on the rarity of cranial injuries but differ on the prevalence: for example Ganguli (1963, cited by Roberts & Buiksta, 2003) reports 0.1 % of people with skeletal tuberculosis, while Aufderheide and Rodríguez-Martin (1998) state 2%. It affects children and young adults almost exclusively secondary to hematogenous dissemination. The cranial vault is the most common site of cranial tuberculosis and it appears as numerous small areas of destructions of less than 2 cm in diameter, with poor defined margins and some surrounding reactive sclerosis (Aufderheide and Rodríguez-Martin, 1998). The frontal and parietal bones are the most commonly involved (Roberts & Buiksta, 2003) and the inner table first, although the occipital bone and the base-sphenoid can also be affected (Maczel, 2003). Lesions can cross the cranial sutures, too. Hackett (1976, cited by Roberts & Buiksta, 2003) illustrates and describes the bone changes of the skull in TB (see fig. 4.3). The facial bones can be involved, particularly the maxillary area and, secondary infection may spread from *lupus vulgaris*, that is tuberculosis of the soft tissues especially seen in the nose, cheeks, brow and neck regions, and in the hands and inside of the nose and mouth. This condition occurs in people before the age of 20 and persists throughout life, healing in one place and appearing in another

(Roberts & Buiksta, 2003). The long standing tuberculosis of the facial skin and soft tissues often leads to the destruction of the nasal bones, as in leprosy (Ortner, 2003, cited in Maczel, 2003)



4.2.2 Minor Osseous Lesions Attributable to Tuberculosis (MOLAT)

The classic skeletal TB changes represent already a more or less developed stage of tuberculosis. However, the importance of establishing diagnostic criteria for early stage lesions has been recognized, since they would have an immense value in the evaluation of the disease's impact in ancient populations. Actually, there are available some new methods to determine the infectious disease, such as molecular extraction, that can help the classical morphological studies. However, in the majority of the cases, a real response isn't possible to obtain: i.e. the osseous remains could be touched by many operators, or they could be too precious to use part of them for invasive tests. Further, the tests are expensive. Therefore, obtaining diagnostic criteria in morphological classical way in all disease stages is important also today.

The other minor characteristic signs probably related to tuberculosis (they don't have the consensus of all authors) are part of the MOLAT and consisted in 4 different markers.

1. Rib lesions

The periosteal appositions on the visceral surface of ribs seem to reflect pleuropulmonary tuberculosis in a large number of cases (Kelley and Micozzi, 1984; Roberts *et al.* 1994). Roberts and colleagues conducted a review (Roberts *et al.*, 1998), on which they suggest that rib periostitis must be considered an additional diagnostic criterion for tuberculosis that should be included in the modern clinical literature, although it will never become one of the major diagnostic criteria for tuberculosis in modern populations, purely because detection uses more sophisticated methods. Pfeiffer (1991) claimed that they could rather be interpreted as a non-specific indicator of chronic respiratory disease stress within a population.

2. Endocranial changes

These changes are often attributable to tuberculous meningitis (TBM) (Schultz, 2001), although other author (Hershkovitz *et al.* 2002) emphasized that certain endocranial alteration might refer to intrathoracic infection, not specifically TB. Particularly *in the Terry – Todd collection*, two kinds of endocranial lesions are defined: SES – *serpens endocrania symmetrica*, discolored areas with maze-like surface excavations, and SDED – *sharply demarcated erosive defects*, denuded superficial areas.

3. Hypervascularization of vertebrae

The term hypervascularization of vertebrae corresponds to a severe circumferential pitting. These characteristic lesions were noted by Menard in 1888 and just a century later they were discovered as peculiar signs by Baker (1999) and consequently by others authors. Biomelecular analyses proved the

relationship between these superficial vertebral alteration and tuberculosis (Haas *et al.*, 2000). In spite of these results, some reluctances are present to accept these superficial lesions as pathognomonic alteration for TB (Mays and Taylor, 2002).

4. Hypertrophic osteoarthropathy (HOA)

HOA is a diffuse periosteal new bone formation, which appears to be a general skeletal response to intrathoracic disease, most often tuberculosis (Mays and Taylor, 2002). Aufderheide and Rodríguez-Martin (1998) remember that although its etiology is unknown, it is classically related to intrathoracic pathology (as cancer or chronic infection) and it appears to be a response to increased peripheral blood flow.

Since the original authors were very careful in considering them as peculiar signs of tuberculosis and the prevalence of pulmonary infections in a population is an important indicator of lifestyle and health, the rib periostitis, endocranial lesions and skeletal changes of HOA can at least be considered as important indicators of health in archaeological populations.

5. Human osteological collections

In the present chapter, a brief overview of most of human skeletal collections worldwide is presented. Within this list, our small collection, Tedeschi Osteological Collection – T.O.C., is presented as a possible new source of information on palaeopathology, occupational markers or epidemiological study.

5.1 Introduction

A useful source of information on how diseases affect the bones is in skeleton collections where the causes of death are recorded.

It takes a long time to organize a skeleton collection. It is necessary: to obtain the corpses, especially from anatomy departments or hospitals; to develop a well-established uniform protocol for collecting the cadavers; to document them; to prepare them through a maceration process and to catalogue them with appropriate identification numbers. In most cases, bodies were made available to the medical school for use in anatomy lessons, a widespread practice in most jurisdictions in the US and Canada, as well as in Italy, before World War II.

At present, osteological collections are mostly used to study effects of some particular diseases and for developing diagnostic criteria, for paleopathological identification and interpretation, as a comparative modern human reference in human evolutionary studies and as the basis for medical and denting training.

The first collection used to determine diagnostic features of TB was that of Hamann-Todd, housed in Cleveland Museum of Natural History (Cleveland,

OH, USA), studied by various authors, particularly by Kelley, El-Najjar and Micozzi (Kelley and El-Najjar, 1980; El-Najjar, 1981; Kelley and Micozzi, 1984). Subsequently, work on the Terry Collection was undertaken (Roberts *et al.*, 1994) by the National Museum of Natural History – Smithsonian Institution, (Washington, DC). There are other collections on which some TB studies were conducted, as the Coimbra Identified Skeletal Collection in Portugal – CISC (Santos *et al.*, 2001) and the Grant Collection at the University of Toronto.

5.1.1 Hamann-Todd Osteological Collection

The Hamann-Todd Osteological Collection was assembled at Western Reserve Medical School (later Case Western Reserve University) between 1893 and 1938. Dr. Carl August Hamann (1868 – 1930) started to collect skeletons when he was professor of anatomy at Western Reserve Medical School. In 1912 T. Wingate Todd (1871 – 1937) moved to the US from University of Manchester to replace C. A. Hamann as professor and then became dean of the medical school. When Todd took up the appointment, he immediately began expanding Hamann's teaching collection, which already numbered over 100 skeletons.

In 1911, Drs. Roger G. Perkins and Carl Hamann supported changes in the Ohio anatomical laws which allowed corpses originally destined for a potters field burial to be turned over to a permanent morgue in the nearest medical school. In addition, Todd received strong administrative support from Carl Hamann who was the dean of the medical school. Colleagues and friends (e.g., Dr. Oliver Weber, Mr. Newton T. Baker, and Mr. G.G. Marshall) also assisted Todd both financially and with donations of specimens.

By the time of Todd's premature death in 1938, there were over 3,300 skeletons in what is one of the largest identified research collections in the

world. Todd collected demographic data, and, where available, medical data for each corpse, as well as a series of anthropometric measurements (Cobb, 1952 and 1981, both cited by Hunt and Albanese, 2005). Todd also included over 900 ape and monkey skeletons. Today, the Hamann-Todd Anatomical Collection is located at Cleveland Museum of Natural History (Cleveland, OH, USA). It consists in complete human skeletons well documented with respect to age, sex, race, height and weight, cause of death, and somatological observations and measurements. In addition, most corpses were carefully inspected at the time of autopsy, and shortly after, by Todd and associates to detect pathologic conditions. Osteologic entities as fractures, anomalies, age changes, dietary deficiencies, and lesions produced by infectious and non-infectious diseases were recorded (Kelley and El-Najjar, 1980).

Particularly tuberculosis, in its various clinical manifestations, is recorded as the cause of death in more than 500 individuals, in which only 26 cases (~6%) have skeletal tuberculosis. This frequency suggests that the collection is not atypical for pre-antibiotic populations (Aufderheide and Rodríguez-Martin, 1998).

The cited twenty-six well documented cases of skeletal tuberculosis were located and examined by Kelley and El-Nejjar (1980). The term “well documented” is used by the authors to refer to medical files that fulfil one or more of the following criteria:

- 1) skeletal involvement specifically stated on death certificate (e.g., Pott's disease);
- 2) a hospital record containing clinical diagnosis of skeletal tuberculosis;
- 3) post-mortem bone and soft tissue inspection by Todd and colleagues for tuberculous lesions.

Their work has been very important to fix the general ideas on TB skeletal evidence: earlier works placed strong emphasis on vertebral collapse as the primary diagnostic feature for tuberculosis, while Kelley and El-Nejja underline that it is essential for the palaeopathologist to be familiar with the widest range

of different types of lesions that resemble tuberculosis throughout the skeleton. They noted that just one case in 26 displayed angular kyphosis, and this means that not all lesions lead to collapse of the vertebra and 40-50% of skeletal tuberculosis cases are reported to be located in regions other than the spine (Kelley and El-Nejjar, 1980).

An additional method of diagnosis is represented by the patterns of multiple lesions. In the present sample, 38% of individuals show multiple sites of skeletal involvement. This share is considerably higher than those previously reported which range between 5% and 20%. In particular, they suggested that combinations such as spine-rib, rib-sternum, spine-rib-sternum and spine-hip involvement might be useful in diagnostic criteria for TB.

5.1.2. Terry Anatomical Collection

Robert J Terry (1871 – 1966) was keenly interested in human anatomy, and particularly in normal and pathological variations in the skeleton. He was aware that there was a lack of documented human osteological/anatomical specimens from which skeletal biology, anatomy and pathology could be investigated. He was strongly influenced by George Huntington, who had been one of his professors at the College of Physicians and Surgeons in New York in 1893, and by Sir William Turner, who had been his professor at Edinburgh where he spent a period during 1898.

In 1910, Terry was appointed chair of the Anatomy Department and he developed the protocol for collecting and documenting skeletons, after two unsuccessful attempts, with failures due to fire and to a general non-documented “dispersion” (Hunt and Albanese, 2005).

The bodies of Terry collection were obtained from St. Louis hospitals and institutional morgues and from other institutions throughout the state of Missouri. The cadavers predominantly consist of individuals who were not claimed by relatives at local morgues, became property of the state, and

would have been buried at Missouri taxpayers' expense, thus it is clear that the collection derives from the lower socioeconomic classes.

Terry's goal was to represent the complete range of human skeletal variation, thus he did not focus on pathological specimens or conditions found in the cadaver series.

Decades of handling by hundreds of students took their toll and damaged and incomplete skeletons were gradually replaced by new skeletons, marked with an "R" (Replacement) suffix to catalogue number. Some skeletons collected by Terry were sent to other institutions and may now be part of their collection (to W.W. Howells – Peabody Museum, Harvard University; to A. Hrdlička – NMNH collection; to R. Dart – University of the Witwatersrand in exchange for six Basuto, still part of the Terry Collection).

After Terry's retirement, Mildred Trotter (1899 – 1991) continued collecting skeletons until 1967. Over 80% of the collection had already been amassed by the time Trotter moved into Terry's position. The most significant contribution to the collection by Mildred Trotter was her effort to balance the collection's demographic composition, adding females and younger individuals. She also focused on burnt bone with some important experiments on bone ash weight. She transferred the entire Terry Collection, Trotter's collection of burnt bones, as well as her collection of hair samples from her studies on hair morphology and identification to the Smithsonian Institution – National Museum Natural History, Anthropology Department for permanent curation (by Hunt and Albanese, 2005).

The final demographic distribution is:

- 461 White Males
- 546 Black Males
- 323 White Females
- 392 Black Females
- 5 Asian Males
- 1 Unknown Origin

Age at death ranges from 16 years to 102 years, and date of birth is from 1822 to 1943; the highest percentage of individuals is at 45 years or older. There are representative numbers of younger age ranges for all groups except for a deficiency in young White Females under 27 years. In the skeletal inventory, damaged or absent bones, pathological and normal osteological variants are defined. Approximately 60% of the collection has associated anthropometric measurements and cadaver photographs. There are 836 plaster death masks and 1078 hair samples curated with the collection (Hunt, 2008).

Terry's collection process (by Hunt and Albanese, 2005)

Maceration consisted of stripping the bone of as much soft tissue as possible without damaging the bone, soaking the skeleton in hot water for 72 hr, brushing, and then drying the bone. Each hand and foot was placed in a cotton glove, with each finger in the appropriate sleeve of the glove and tied at the open end (Trotter, 1981, cited by Hunt and Albanese, 2005). Degreasing of the bone was accomplished by exposure to benzene vapors for a lapse to remove some of the fats, using a pressurized heating unit. He explicitly didn't want the bone void of fats, because he felt the bone would preserve better with some fats still present: the long-term survival of this collection despite its extensive use demonstrates Terry's foresight in the preservation of skeletal elements by his maceration protocols. After completion of the skeletal processing, the catalogue number was written on each bone, with the exception of the tiniest elements such as ear bones. Furthermore, in many cases, every single phalanx and sesamoid of the hand and foot was numbered according to his position. In most cases, hand and foot bones are color-coded as to side: red ink for bones of the right side and black ink for bones of the left side. At various points in processing, such as before and

after soaking in water and before and after exposure to degreasing agents, inventory check-lists were made for each bone in the skeleton.

5.1.3. Grant Collection (University of Toronto)

John Charles Boileau Grant (1886-1973) was the author of *Grant's Atlas of Anatomy*, edited in 1943 and used to train thousands of medical students around the world. He moved from Edinburgh to University of Manitoba (Canada) to University of Toronto's Faculty of Medicine, where he was Chair of the Department of Anatomy from 1930 to 1965. Although he is best known for this famous atlas, his research and teaching also included biological anthropology, as evidenced by the work *Anthropometry of the Cree and Saulteaux Indians in Northeastern Manitoba* (Archaeological Survey of Canada, 1929). The human skeletal collection he formed, named Grant Collection, is still a core collection for human osteology in the Department of Anthropology at University of Toronto. He is also mentioned in the Grant's Museum at the Medical Sciences Building at the University of Toronto. This museum, with its displays of anatomical specimens, many of which were dissected by Grant himself, continues to be used in an active learning environment by more than 1000 students each year (University of Toronto, 2001).

5.1.4. Coimbra Identified Skeletal Collection

The Coimbra Identified Skeletal Collection (CISC) is curated at the Museum of Anthropology, University of Coimbra, Portugal. The collection was accumulated in the first half of the 20th century and comprises 505 males and females. For each individual a record exists with information such as birth and death place, occupation, own and parents' names, and cause of death (Rocha, 1995). The individuals died between 1904 and 1936, i.e., between

Koch's identification of pathogen of TB in 1882 and the introduction of antibiotic therapy in the late 1940s (various authors, cited in Santos, 2006). Almost all the skeletons are complete and in a good state of preservation, although some periosteal destruction has occurred. Sex estimation, adult age-at-death estimation, and paleopathological analysis have been undertaken. Research on documents from several institutions and in medical literature from the beginning of the 20th century indicates that the cause-of-death records associated with the CISC are accurate and reliable (Santos, 2006). The research on the old documents of Coimbra University Hospital (CUH) records that the place of burial for 240 individuals of CISC was the Cemetery da Conchada. The autopsy is documented by the Instituto de Medicina Legal and provides important data that confirmed and complemented the Collection files, particularly concerning the causes of death (Santos, 1999, cited in Santos, 2006; Santos and Roberts, 2001).

5.1.5. Huntington Collection

George Sumner Huntington (1861 – 1927) was one of mentors of R. J. Terry. He was a strong proposer of saving skeletons of the documented human cadavers from the medical school for skeletal biological research. Aleš Hrdlička (1869 – 1943, one of his students and himself important physician, who developed the Physical Anthropology Section of the Smithsonian Institution), remembers "*Dr. Huntington was not a public nor a popular lecturer; but he developed into a great teacher of anatomy. He changed anatomical teaching from didactic to essentially demonstrative; and he widened its scope by comparative anatomy.*"(Hrdlička, 1937).

The bone collection was begun in 1893. It started with a heterogeneous lot of unidentified older bones and skulls, to which was added a rather large series of Indian crania. From 1893 the bones of all the bodies dissected in the College, except those used for surgical demonstrations, were collected,

provided with leaden tags holding the number of the specimen with the year of dissection, boiled out in steam-piped vats, and during vacation time spread over the dissecting tables, under sky-lights, where they were left to partly dry and lose excess oil until fall, when they were placed in boxes and cases and taken down to the cellar. Professor Huntington was personally more interested in research on the soft parts, but he was fully aware of the prospective scientific value of the osteological material and so continued its collection (Hrdlička, 1937). At the end, he amassed over 3,800 skeletons from his dissection classes during his tenure at the College of Physicians and Surgeons in New York, but it has not been extensively used for research in the past because of its difficult accessibility. After Huntington's retirement, Aleš Hrdlička worked to have Huntington's skeletal collection transferred to the Smithsonian Institution, that was in 1937 (Hunt and Albanese, 2005).

The Huntington Collection is currently located in the Department of Anthropology at the National Museum of Natural History (NMNH) and is available for research (Hunt, 2008).

5.1.6. Other “minor” osteological collection

Raymond A. Dart (1893 – 1988) was a senior demonstrator at University College under G. E. Smith. He traveled to the US and Canada visiting Todd and Terry laboratory. Dart began collecting skeletons in 1923, after he was appointed chair of the Department of Anatomy at the University of the Witwatersrand, Johannesburg (Tobias, 1985 and 1991, both cited by Hunt and Albanese, 2005). By Dart's retirement in 1958, there were over 2,000 skeletons in the collection. After him, Philip V. Tobias named the collection as **Dart Collection**, and continued the collection process.

William Montague Cobb (1904 – 1990) was a Todd's student and when he was appointed professor of anatomy at Howard University in 1932, he

started a new collection, named **Cobb Collection**. This collection numbers over 700 documented individuals, and is located at the Cobb Laboratory at Howard University (Rankin-Hill and Blakey, 1994 cited by Hunt and Albanese, 2005).

Dart's efforts influenced A. Galloway, a senior lecturer for Dart, to establish a similar skeletal collection at **Makerere College in Kampala, Uganda**.

D. Allbrook, a Galloway's senior lecturer, and L. Freedman, a Tobias' senior lecturer, became heads of the Anatomy Department at the **University of Western Australia in Perth**, and they formed a collection of skeletons from anatomical cadavers at that institution.

As Tobias comments "*in almost Biblical fashion, it is possible to trace the odyssey of an idea and an ideal down the generations*" (Tobias, 1985, cited by Hunt and Albanese, 2005),

5.2 Tedeschi Osteological Collection – T.O.C.

5.2.1 The author

Enrico Emilio Tedeschi (1860-1913), was the founder of Institute of Anthropology of Padova University and can be considered its first director.

He was born in Trieste in 1860 and took a degree in "Letters and Philosophy". His early works, focused on sociology, granted him a university chair in sociology that he declined. From his meeting with Giuseppe Sergi he developed a strong interest in science which grew up through his acquaintance with Canestrini, the man who introduced the Darwinian Theory and works in Padova University. His friendship with Canestrini was such that

he wrote a commemoration for “*Accademia scientifica Veneto-Trentino-Istria*” in 1907 with a list of his works. Thanks to lessons in anatomy by Mingazzini and the contact with the “*Scuola Romana in Antropologia*”, he continued his fruitful studies in anthropology. From 1899, he taught anthropology at Faculty of Science at Padova University, as free lecturer for 4 years and as Professor from 1903.

Tedeschi leaves very few publications, perhaps because of his strive for perfection, as Corrain supposes (Corrain, 1988); for example, he wrote 22 printed pages to establish the concept of anthropology at the opening lecture of anthropology course in academic year 1893-1894. One of the most original works by Tedeschi was “*Sistema di craniologia*” (1906). This work is unfinished, but bears brilliant insights. Tedeschi was a forerunner of the following works by Klaatsch and Falkenburger. Within the field of craniology, in 1906 he published a new “*cranial-face space machine*” that made it possible to determine cranial plates and draw the different profiles of skull.

Tedeschi was also psychologist and worked especially in the field of developmental psychology with some publications *ad hoc*.

Most of Tedeschi’s publications are available at University of Padova and they are presented below:

- Tedeschi Enrico, 1890, *Ricerche intorno alla genesi del bacio: studi di etnografia comparata*. Library S. Biagio ARDIG.D. 69/20
- Tedeschi Enrico, 1893, *Studi. La proprieta’. La Controversia Aria. Antichita’ Arie sociologiche*. Fratelli Drucker, Verona, Librai Editori, Padova. Library Vallisneri M.GN.449.(1)
- Tedeschi Enrico, 1897, *Studi sulla simmetria del cranio*. Estratto dagli Atti della Societa’ Romana di Antropologia. Vol. IV – Fascicolo II e III
- Tedeschi Enrico, 1898, *Ricerche intorno alla funzione del senso muscolare nella percezione delle forme*. Library S. Biagio ARDIG.D.01/21
- Tedeschi Enrico, 1902, *I miti dell’anima: bacio e sternuto*. Library Beato Pellegrino TRAD.POP.X.220
- Tedeschi Enrico, 1906, *Sistema di craniologia*. Padova, A. Draghi ed.

- Tedeschi Enrico, 1912, *Storia naturale dell'uomo (1)*. Library Vallisneri M.GN.738.(2).1
- Tedeschi Enrico, 1912, *Storia naturale dell'uomo (2):la civiltà primitiva*. Library Vallisneri M.GN.738.(2).1
- Tedeschi Enrico, 1912, *L'uomo: storia naturale e preistoria*.

Some of his opening lessons in academic years of University of Padova in 1898 and 1909 are also available:

- Tedeschi Enrico, 1898, *Prolusione al corso di Antropologia dell' a.a. 1897-1898*. Archeografo Triestino. Nuova Serie, Vol. XXII – Fascicolo I
- Tedeschi Enrico, 1909, *Le razze indo-europee: discorso inaugurale dell'anno accademico 1909-1910*. Library S. Biagio ARDIG.D. 24/39 ARDIG.D. 35/28

In 1988 Cleto Corrain (1921-2007), anthropologist of University of Padova and director himself of Institute of Anthropology for several years, wrote a brief summary of life and work of Tedeschi, as cited above:

- Corrain Cleto, 1988, *Enrico Tedeschi: 1860-1931*. Estratto di *Antropologia Contemporanea*. Vol 11, n. 1-2 (1988): 74-77. Library Galileiana, OPUS.Cor.41.

In this work, Corrain cites other publications by Tedeschi that are not available in libraries:

- 1900, *Opera di un cranioforo a doppia sfera, lo stereografo-planimetro , la cubature ad acqua dei crani*.
- 1902, *Saggio di una craniologia senza numeri*.
- 1906 (?), *Bimbi e selvaggi*.
- 1909 (?), *L'animismo letterario*.

5.2.2 Collection and Register

In 1912 Tedeschi compiled a precise register on osteological remains he had collected in several years from different sources:

- some remains were owned by Tedeschi himself;
- some remains came from donations from other medical doctors or specialists who collaborated with him¹;
- some remains came from anatomical dissections of Medicine Department of Padova University;
- some remains were bought by Institute of Anthropology;
- some remains were recovered from archeological excavations in or in the nearby of Padova (Roman archaeological site and cemetery dated 1610 for plague) .

Totally, 1639 remains are listed that include entire skeletons (213), just skulls (1298, on which 31 only skullcaps), *infans*² (128 and 2 *feti*), incomplete skeletons (39) and just single elements, for example single mandibles or clavicles (150). For the most part, skeletons originated from Italy, (from Padova, Ferrara, Bologna, Trentino region, Manfredonia, Roma, Cagliari, Canicattì and from Todi) and few from abroad (from Albania and Brazil). He compiled this precise register writing beside each remain the date, the origin and other informations he had collected. Especially for the majority of entire skeletons, which probably he prepared for didactic purposes, he quoted:

- date of death

¹ The collaborations were with Prof. Castellini, Prof. Manca, Prof. Galeno, Prof. Baldacci, Prof. Gangitano and Prof. Zanolli which worked in other Universities or Institutions last century.

² The age categories of Martin are the following: *Fetus*; *Infans I* (0-7 years); *Infans II* (7-14 years); *Juvenis* (14-20); *Adultus* (20-40); *Maturus* (40-60) and *Senium* (over 60). In the collection, there are quoted only infants with age inferior to 3 years; thus when there are nominated *Infans*, they can be considered as *Infans I* by Martin.

- name and surname³
- sex
- age at death
- cause of death
- job or occupation
- origin of skeleton
- other notes

Several skeletons were originated from prison of Padova and Tedeschi annotated for each individual who was sentenced the number of years of imprisonment and the crime. Maybe these particular remarks are due Lombroso's influence or to a general attention for all aspect of individual's life. Maybe for the same reason, he reported that individual number 413 killed himself by weapon and number 464 by nitric acid. However, the quoted causes of death are several and sometimes unclear (see table 5.1).

Table 5.1 Diseases reported as causes of death in Tedeschi register

<u>Diseases</u>	<u>Number of cases</u>	
	<u>Adultus</u>	<u>Infans</u>
Abscess gangrenous	4	-
Apoplexy	4	-
Bronchus pneumonia	3	9
Cancer	10	-
Catarrh bronchial	1	4
Childbirth (parturition)	1	-
Decline (general physical decline) *	18	-
Drowning	1	-
Enteritis	1	10
Haemorrhage celebrate	3	-
Hepatitis	1	-
Measles	-	8
Meningitis	1	1
Nephrite	2	-

³ For a general respect of the dead person, in the present work the name and the surname are always indicated just with initial letters.

Nervous breakdown *	7	-
Occlusion intestinal	1	-
Paralysis cardiac	5	-
Pellagra *	8	-
Peritonitis	7	-
Plague	34	-
Pneumonia	3	-
Senile insanity	6	-
Suicide	2	-
Syphilis **	4	13
Tuberculosis	81	-
Uterine fibroids	1	-
Weakness *	4	12
	<u>Total</u>	213
Unknown †	2	57

* Probably, concerning on adult death, all these terms are joined to pellagra, since they are the description of symptoms linked to this widespread disease in the last century. In this case, the number of pellagra remains will come up to 37.

** The infants' cases of syphilis are quoted as congenital cases.

† The causes of death are unknown, but all other information are known.

Unfortunately, we do not have any note on how Tedeschi prepared the remains, how he cleaned the bones from soft tissue and conserved them. Nevertheless, we have remarks on how similar remains were processed by other authors (for example, see on Terry collection in this chapter) and direct knowledge of other professional workers, as Rizzi⁴, archaeozoologist with many years of practical experiences (Rizzi, 2008).

Generally, there are several methods to clean bones from soft tissues; each of them has positive and negative aspects. These methods are actually used almost exclusively by taxidermists, to prepare animals for didactic and expositive purpose.

⁴ Dr. Jasmine Rizzi is an archaeozoologist who works in archeological excavation from many years. She directs a company with more than 30 years of experiences. She takes care of all aspects of excavation, among which treatment and recovery of archaeological materials. For work and for personal interest, she has a great practical experience on treatments of bones. As more information, please look at www.rizziarcheologia.it and www.paleopatologia.com.

One method is to use specific animals, as *Dermestes Lardarius* Linnaeus, a Coleoptera, (common name Larder Beetle - Phylum *Arthropoda*, Class *Hexapoda*, Order *Coleoptera*, Family *Dermestidae*). Experts say that this beetle can clean the bones very well and quickly, but it can eventually damage the osseous tissue itself if it is left too long on the bone. This method is quite recent and was probably not used in the past century.

A recent method is represented by the use of enzymes for proteolysis: they are useful and quick but rather expensive and they were surely not used in the past century.

Another method consists in putting the body directly in sandy soil: this type of substratum allows correct ventilation to the natural decomposition process. In this way, bones can result to be not white and the process itself takes a long time (months).

A cheap method is to macerate the body in big tanks full of water, but it takes a long time to get through the process. As a side effect, an unpleasant smell emanate from the corpse.

The most common method is the boiling of bones, since it is clean, cheap and quick. It is important to note the time of permanence in water (Terry suggested 72 hours, Hunt and Albanese, 2005) to clean them from soft tissue without damaging osseous tissue. In fact, if bones are soaked for a too long time, fractures could occur near the diaphysis. Further, the addition of oxygen water (130 volumes) can speed up the process and dissolve cartilages but, as a negative aspect, could make the bones too white and damage them. Exposure to benzene vapors is used to remove some fats, but it is necessary to use a pressurized heating unit since the vapors are toxic. A more practical method is to use common dishes cleanser to polish great part of fats. Practical experience shows that if boiling parameters (e.g. time or temperature) are not correct, some marrow may crop out in the form of reddish stains on the surface of osseous tissue, especially near diaphysis. Exposure to the sun makes the bones white and dry.

Finally, thanks to personal experience of Rizzi and the general notes of other collection processes, with regard to the T.O.C., we can suppose that:

- ✓ most remains have been boiled for many hours;
- ✓ maybe the boiled remains have been exposed to sun to make them white and dry;
- ✓ some remains weren't boiled for a suitable time, since some reddish stains appear near the diaphysis (Photo 5.3)
- ✓ some remains are quoted as buried in common cemetery at Bologna;
- ✓ the buried remains appear as brown colored and more ruined than the unburied remains (which have been boiled);
- ✓ the catalogue number was written on each bone for each prepared skeleton (Photo 5.4).

Part of the remains has been used with didactical purpose by various professors: some anatomical points are marked by pencil directly on the bones.

In 1983 the Institute of Animal Biology and the Anthropological Institute, the Botanical Garden and Marine Biology merged to form the Department of Biology. From those years on, for a great lack of suitable spaces, the osteological collection is collocated in cardboard boxes in damp basements, extremely disordered and dusty (Photo 5.5). Until now, they are in excellent state of conservation, but dampness is beginning to ruin the bones: it would be necessary a new and more suitable collocation.




Photo 5.1
Some original notes on skeletons of the Tedeschi collection recovered in the boxes.

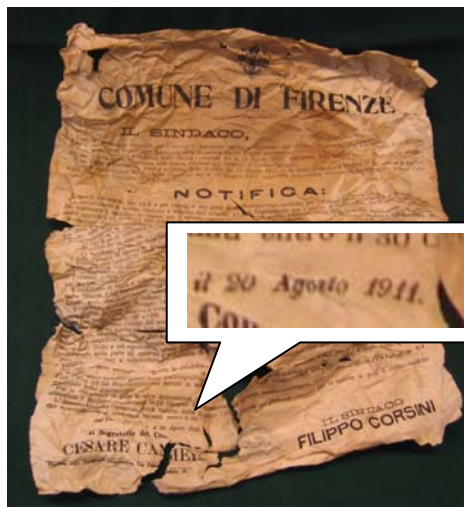


Photo 5.2
Original paper used to wrap some remain and dated 20th of August, 1911.

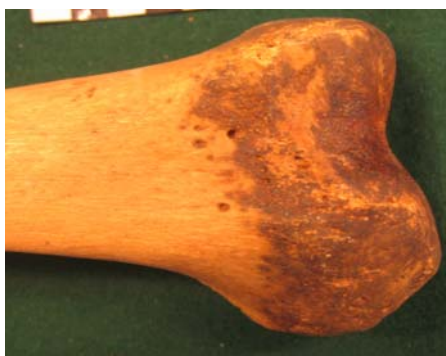

Photo 5.3
Individual 657: the marrow appears near distal diaphysis.



Photo 5.4
Individual 1482: the catalogue number is reported on each bone.



Photo 5.5
The dusty boxes for the remains.

6. Tuberculosis in T.O.C. – Tedeschi Osteological Collection

In the present chapter the investigation regarding tuberculous (TB) samples for the Tedeschi Osteological Collection will be reported. Each case will be considered with her/his own work schedule on work is carried out on radiological or chemical, histological and molecular (when available) analyses.

6.1 Introduction

The Tedeschi Osteological Collection – T.O.C. is presented in Chapter 5, but some peculiar characteristics, concerning the cases studied in this PhD Thesis, need to be considered.

Concerning consumptives skeletal remains:

- TB remains quoted in Tedeschi's register are 81 (29 females and 52 males);
- TB remains found are 59 (22 females and 37 males);
- mostly bones have been boiled to strip the flesh from the skeleton;
- 20 skeletons have been buried (from number 402 to number 470);
- all remains have been preserved in cardboard boxes;
- major part of remains have been used for didactical purposes during these years.

Tedeschi numbered each individual with a number code; therefore all bones of an individual are codified with the same number. Different number

specifies different individual, but it doesn't show the type of bone. Each individual form will be reported in the following paragraph (6.3) in the same numerical order used by Tedeschi, that doesn't coincide neither with date of death nor with importance or completeness of remain but just with the date of collection.

6.2 Materials and Methods

The first stage of this research was to find the remains of individuals dead of TB which were quoted in the register. The register was filled in 1912 and since then the collections¹ of the Department of Biology have been moved in different places. Furthermore, during this period of time of about one century, the remains were used for didactical purposes, as mentioned above. The situation required a total checking of all remains. All osteological remains were located in hundreds cardboard boxes in damp basements and they were disordered and dusty (Photo 6.1 and Photo 6.2). Prof. A. G. Drusini, Dr. N. Carrara, who is the curator of the Anthropological Museum, and myself checked all boxes looking at the consumptives remains quoted in Tedeschi's register. Some bones were located in singular boxes with original notes wrote by Tedeschi himself and they were still now wrapped with original newspapers (see Photo 5.1 and Photo 5.2, in the previous chapter). The recovered individual and bone have been positioned in suitable boxes and taken in the laboratory of Anthropological Museum.

The second phase of the research consisted in the systematic study of the finds, as in the following numbering:

¹ In the Anthropological Museum of the Biology Department at University of Padova, there are various collections, with different histories and origins: paletnological collection, etnografical collection, collection with orient arts and the T.O.C. – Tedeschi Osteological Collection, that is the only one quoted in this PhD thesis.

1. individualization of remains;
2. morphological study of diseases;
3. histological analyses;
4. molecular analyses;
5. bone density determination;
6. radiological exams.

Specifically, the first 2 aspects (individualization of remains and morphological study of diseases) were been processed in all remains, while the other aspects were conducted in specific cases, which seemed to be more peculiar than others. Each analysis is reported in the individual form in the following paragraph (6.3).

1. The individualization of remains, concerning sex, age, state of preservation and type of bone, was processed in all remains with the method of classical anthropology. Firstly, the age at death and sex were investigated and, secondly, they were checked by Tedeschi's quotes. Sometimes the remains are too much litter and it is impossible to determine sex or age: in these cases the register quotations have been approved directly. In other rare cases, the biological age of some findings did not match the anagraphical age (as sometimes it could be right to attend it) and the notes in the register were accepted. Furthermore, the state of preservation, the type and the number of bones have been recorded in order to obtain a picture of the individual remain.

The estimate age at death can be processed with a relatively good precision for subadult individuals, since the criteria are based on the phenomena of growth, while the determination of adult individuals is more problematic due to phenomena of individual aging that can be different from one individual to another (Simon, 1990, cited by Maczel, 2003). Currently employed methods of ageing adults using skeletal material are based on four principal criteria, as remembered by Cox, 2000. 1) For young adults, the final

stages of skeletal maturation which take place into the late 20s; 2) morphological changes in joints where movement is either limited or non-existent (cranial suture closure, rib-end, auricular surface and pubic symphysis morphology); 3) examination of continued ossification of hyaline cartilage; 4) changing to bone structure including involutional bone loss and osteon frequency. Furthermore, the dentition, the state of teeth and their wear can help the estimation of age at death (Whittaker, 2000). The most widely used system is by Brothwell (1989, cited by Hillson, 1996) and presented in chapter 2, altogether with the attrition stages diagram of Murphy (1959, reprinted by Smith 1984 and cited by Hillson, 1996).

As Mays and Cox cite (2000), it is important to remember that a reliable determination of sex from human skeletal remains is clearly of fundamental importance and the two areas of the skeleton that exhibit sexual dimorphism most strongly in the adult are the pelvis and the skull.

2. Morphological study of diseases was the following stage of search. The pathological conditions were observed in the bones, looking at osseous diseases and particular infectious conditions. In our sample, the information that all individuals were died for tuberculosis was known, thus the stage of disease has been studied. As reported in chapter 2 and in chapter 4, many other pathological signs could be noted and they were been reported in each individual form.

3. Histological analyses are processed in several cases. As already specified, the osteological remains have been boiled and collocated in an unsuitable place and used for uncontrolled proposes: thaphonomic processes occurred were unclear and extremely difficult to define. Even if authors report that the histology does not change also after more than 80 hours of boiling, we would expect boiled bone to be less resistant to all forms of diagenetic alteration, including microbial attack as described by Roberts *et al.* (2002).

Since the bone mass of any particular skeletal element is intricately tethered to its specific mechanical loading environment (Peck and Stout, 2007) and since the tuberculous disease shows itself in different ways, histological sample from different bones are analyzed:

- a. Tissue from long bone
- b. Tissue from a rib

These samples have been withdrawn from several individuals (10 and particularly: 1485, 1477, 1580, 1486, 1481, 1487, 1436, 1579, 1438, 1439) and worked at CLOPD Laboratory – Department of Medical Diagnostic Sciences and Special Therapies, University of Padova. They were processed with different technique and colorations. Each result is presented in own individual form.

4. Molecular tests. Six samples, randomly selected, were processed searching for DNA traits of *Mycobacteria*. As remembered, the osteological collection was used for didactical purposes by different researchers during these years. The perfect idea of a “virgin bone”, as many authors crave, is very distant to our sample situation. However, we tried to have some results on molecular analyses and some elements were processed in Cardiovascular Pathology laboratory, Department of Medical Diagnostic Science and Special Therapies, University of Padova.

The following precautions have been used to clean bone surface (Caramelli & Lari, 2004):

- a. abrasive paper;
- b. sodium hypochlorite;
- c. absolute alcohol;
- d. bi-distillate water.

After these precautions, the sample was processed with UV ray and mechanically crushed with mortar under aspiration hood, thermal shock (alternative shocks with boiling water and liquid nitrogen for 5 times).

DNA was extracted by a *QIAamp DNA Mini kit* with an amended protocol for our demands. The result was amplified with nested PCR using two different primer pairs. The primers were designed to amplify a region of the gene encoding the *65 kDa mycobacterial heat shock protein (ML 30)* (Cook *et al.*, 1994). Each set of experiments was accompanied by appropriate blank controls. The PCR results were shown on a UV screen after gel electrophoresis in 2% agarose.

The PCR product's specificity was confirmed by automated sequencing. The gel-band was cut with sterile blade to purify the amplicone. Subsequently, the sequencing reaction was performed using Big Dye® dideoxy-terminator chemistry (ABI PRISM 310, Applied Biosystems). The sequence chromatogram was analyzed using Chromas® (Technelysium). The resulting spoligotyping patterns were compared to an international database (BLAST). In each form the result and its analysis are reported.

5. Bone density. At present, the gold standard for the assessment of bone mineral density (BMD) is DXA (Dual-energy X-ray Absorptiometry). The densitometer is provided with a data base that allows comparison of the measured bone mineral content of an individual with that of a referral population. The two indicexes used, besides BMD are T and Z scores, i.e. the numbers of standard deviations compared to young healthy adults of the same ethnicity and sex (T- score) and age matched individuals (Z-score). Currently, the instrumental diagnosis is done on the basis of a T score less than -2.5 SD. To reduce the operational costs, a pre-screening process to select people for the DXA evaluation could be useful. To this aim at University of Padova a middle phalangeal radiographic absorptiometry (RA) has been employed scanning at the 2nd, 3rd and 4th fingers of the non-dominant hand by

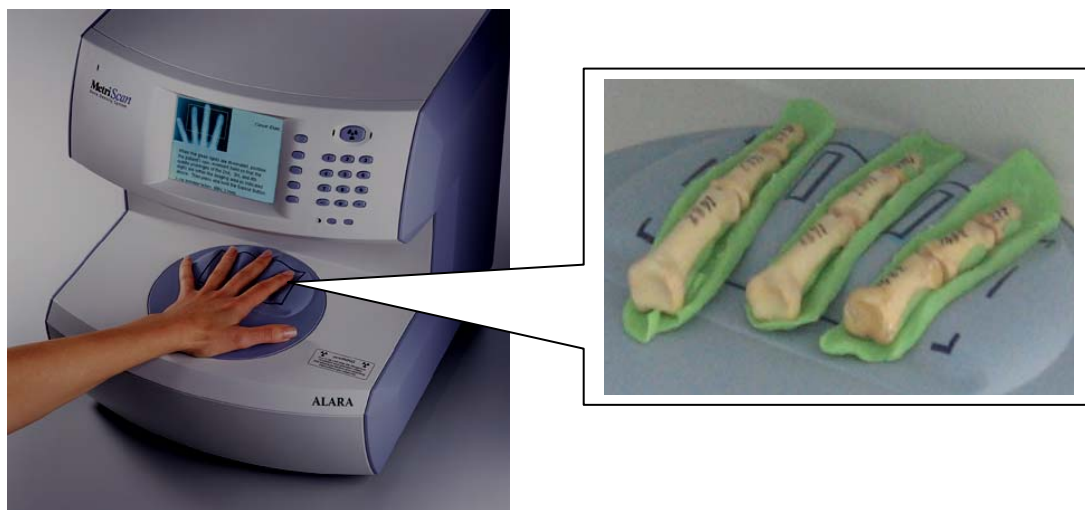
means of a monoenergetic X-ray (60 kV) equipment. This technique has an extremely short performing time (less than 1 second, only 300 msec). Furthermore, it does not require the undressing and the lying down of the patient that, especially with old subjects, sensibly slow down the measuring process. RA is also characterized by reduced X-ray exposure ($<0.012 \mu\text{Sv}$, that is less than 5% of dental Rx) and by an *in vivo* precision of 1.5-2.0% (Sartori, 2006). The machine used is called MatriScan (fig. 6.1) that is compact and self-contained, requiring only a printer as an accessory. In particular, the system has its own X-ray source and image sensor which don't require any handling or maintenance by the operator. The system runs on an embedded microprocessor system which controls system function, manages interactions with the operator through a menu-driven interface, and automatically processes and analyzes the digital images of the patients' hand.

This new technique has been employed on tuberculous remains, since the positive aspects of these analyses are evident and useful to the case of our samples: the test is totally not invasive, it is extremely quick and no special arrangements or training are required.

Despite that, some peculiar aspects need to be remembered during data processing. First of all, this is the first time that this new technique is used on osteological remains, thus similar data aren't available to compare the results; the data base of instrument was generated *in vivo* from healthy patients of both sexes. As reported in chap. 1, because archaeological specimens lack marrow and soft tissue, absolute BMD values cannot be compared with those of living subjects not understanding that the contribute of the two latter to BMD value is negligible. The analysis was performed on middle phalanges of 2nd, 3rd and 4th fingers and it was reliable only for nine individuals. In some cases, the hands were mounted in a metal structure and we decided to not dismantle the bones maintaining the collection more integrated, since this is a pilot study.

The machine has three housings where the fingers can be placed while whole hand holds in the correct position. In our study, the phalanges were too thin to stay in the right position: they needed some no radio-opaque material² to support them and simulate the soft tissue (fig. 6.1).

Fig. 6.1 MetriScan (with fingers *in vivo* and with bones)

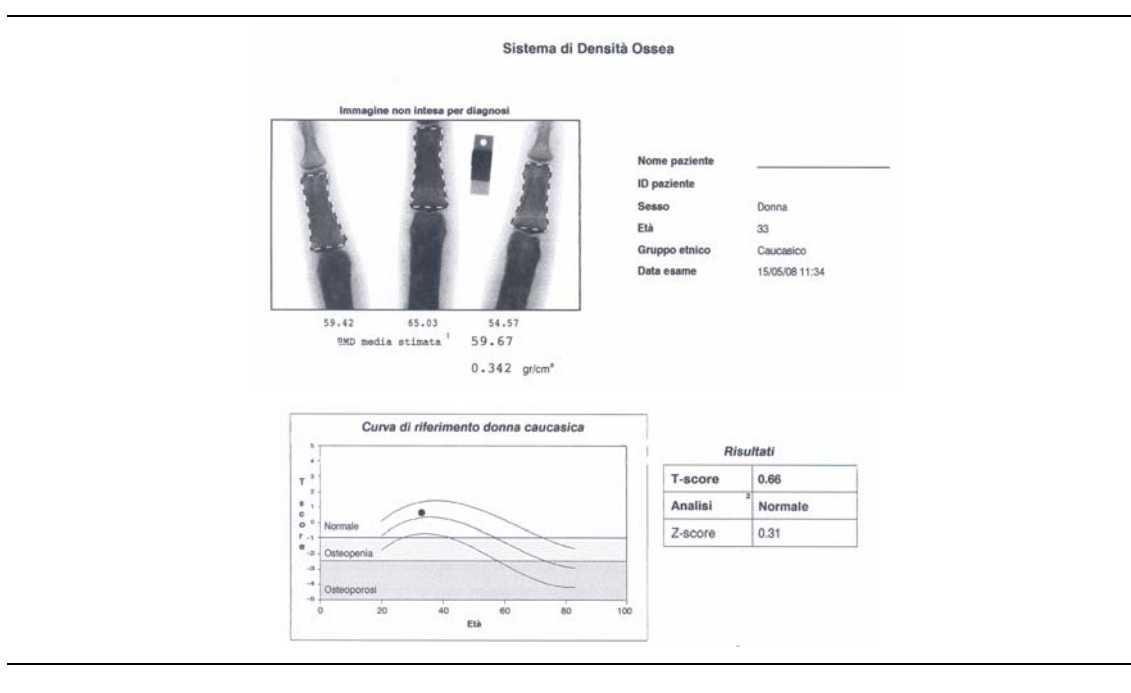


At right, detail of material to support the phalanges.

MetriScan prints directly the results besides the estimated BMD, T and Z scores. An example of this sheet is reported in the following figure (6.2), while each schedule is in each individual form.

² The material used to our purpose was “Didò”, that is the trading name of a material easily fabricable produced by FILA (Torino, Italy), similar to wonder and plasticize. The product doesn't contain heavy metals.

Fig. 6.2 Schedule by MetriScan



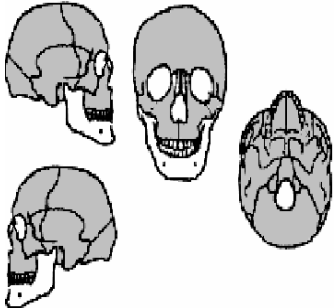
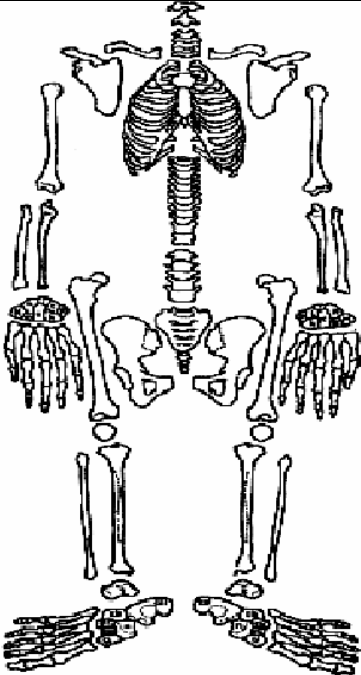

6. Radiological exams. The X-ray imaging is used only in singular cases (Individual number 450, 1456, 1457 and 1485), since the ambiguous cases seemed to be few. The exams are carried out at Radiological Clinic – University of Padova. The images are reported in each individual form.

6.3 Results – Individual forms

In this section, all osteological forms of consumption remains are presented. The organization is similar to that used by Legal Medicine and proposed also by Capasso (2001). The description is organized for “individual form” that is divided into 3 separate sections: description, comment and photos. In the description section, the observed data and results of laboratory tests are exposed, as objective work. First of all this section quote information from Tedeschi’s register and then it reports a schematic presentation of remains, which are listed and indicated in a schematic figure. The following are comments of the case, with bibliographic references cited. All photos are

in the final part only for practical layout, since all photos are directly part of the study: their descriptions help the presentation of case itself. The original bone photos contain also the unit of measure, but unfortunately it has been cut limiting the image in the major part of cases.

Skeleton 397

Tedeschi Register (1912)	
Sex::	<i>M – P. G.</i>
Age:	<i>65 years</i>
Job:	<i>Servant</i>
Date of death:	<i>August 1906</i>
Cause of death:	<i>Lung tuberculosis</i>
Origin:	<i>Common burial (Bologna)</i>
Bone Remains	
Skull: <i>Cranium</i>	
Skeleton: ---	
Teeth: <i>Upper: left arch, in situ the lateral incisor, first and second premolars and first and second molars.</i>	

The state of preservation of the cranium is good, but it is the only element of the individual found. The *Maturus* – *Senilis* age of death is confirmed by total closure of the cranial sutures and the male gender by the evident temporal lines.

The cranial sutures are totally closed (Photo 397/1), with a sagittal suture depressed. On the right side, a traumatic incision mark is evident, maybe due to an *ante-mortem* injury (Photo 397/2).

In the internal side of the cranial bones close to the sagittal sulcus, there are many *arachnoid foveae* (Pacchioni granulations) (Photo 347/3). These non-pathological foveae are holes with loss of internal plank (Capasso, 2006).

In situ, there are 5 teeth, all with an elevate degree of wear (4/5 degree in the Murphy scale at 8 degrees); the first molar has a great caries and calculus is present (Photo 347/4).

Concerning pathological analyses, there are not enough elements to suggest a particular suffering disease.



Photo 397/1
Superior cranium view: all sutures are closed.

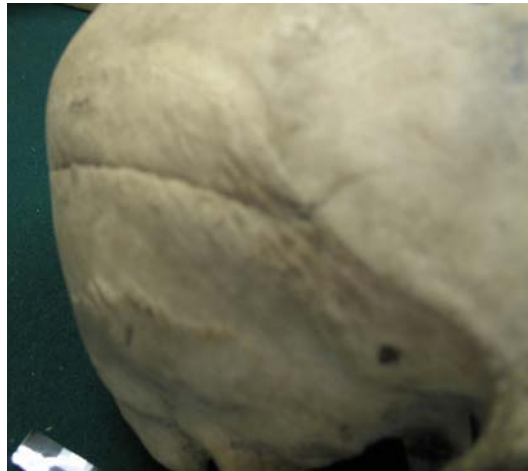

Photo 397/2
Right temporal bone: traumatic incision mark *ante-mortem*.

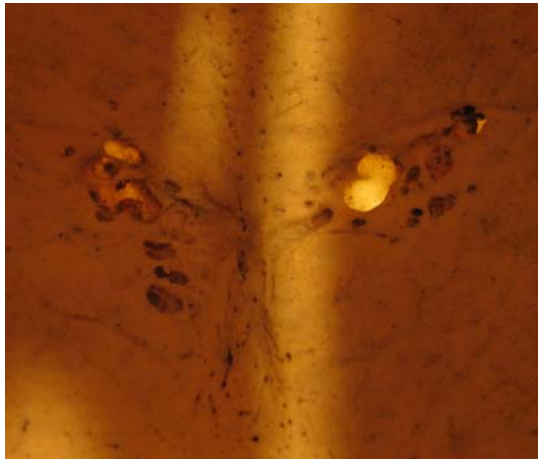
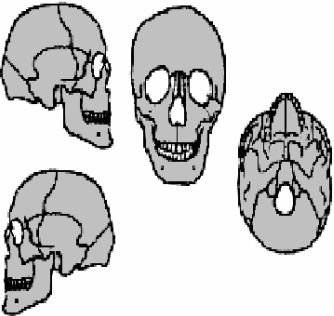
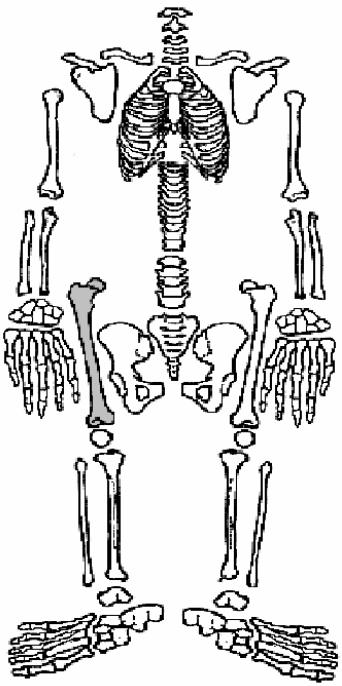



Photo 397/3
Endocranial vault: many arachnoid foveae are present near the sagittal sulcus.

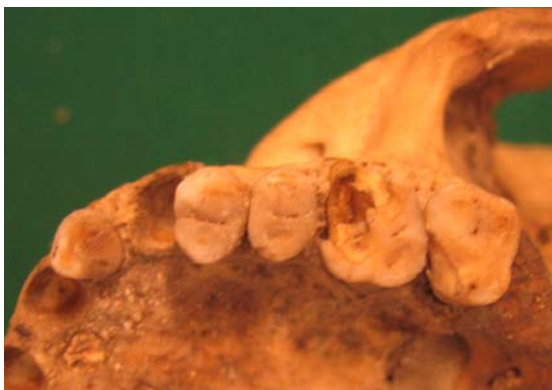

Photo 397/4
Dentition: the wear and the caries are evident.

Skeleton 400

Tedeschi Register (1912)	
Sex::	<i>M – B. G.</i>
Age:	<i>54 years</i>
Job:	<i>Barber</i>
Date of death:	<i>August 1906</i>
Cause of death:	<i>Lung tuberculosis</i>
Origin:	<i>Common burial (Bologna)</i>
Bone Remains	
<u>Skull:</u> <i>Cranium with mandible</i>	
<u>Skeleton:</u> <i>Femur: right</i>	
<u>Teeth:</u> <i>Upper: right and left second molars.</i> <i>Lower: 2nd left molar.</i>	

The skull is clean and white; the femur is clean but brown colour.

The cranial sutures are completed, with strong occipital in the lambdoid suture with sagittal one (a slightly *chignon-shape* occipital).

In the jaw there are only 2 molars *in situ*, one in the right arch and one in the left arch. In the right arch 2nd incisive, 2nd molar and canine were lost *ante-mortem*, 1st pre-molar probably was lost in *peri-mortem* time. In the left arch, the two premolars and the 1st molar were lost *ante-mortem*. In left arch, an evident abscess can be seen with probable periodontitis in the mandible: the destruction of cortical region occurs above the 1st molar root. Maybe, there is the same pathology at the first stage in right arch (Photo 400/1).

In mandible, there is only 2nd left molar *in situ*. All right molars and the left others are lost *ante-mortem* (Photo 400/2).

The right femur has evident periostitis at the lesser trochanter with bone formation (Photo 400/3).

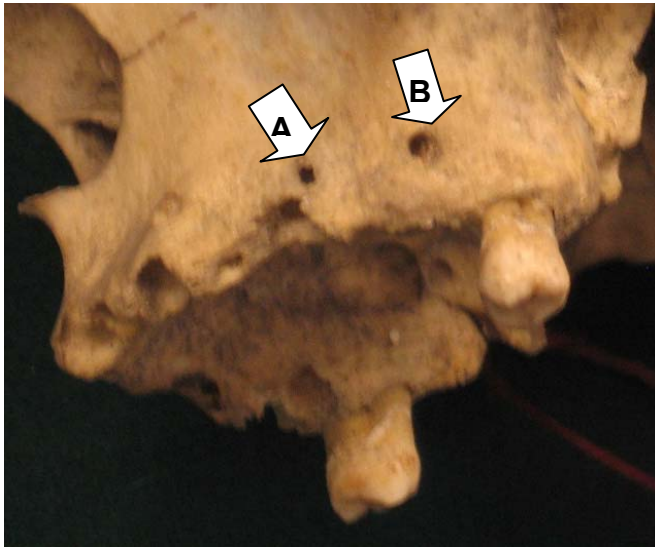


Photo 400/1

Exposure of the roots of the first molar (arrow A) but without pathology, as there are no voids around the root apices. A granuloma/cyst related to the upper second has become a chronic abscess (arrow B). The thickened and rounded margins can be noted.

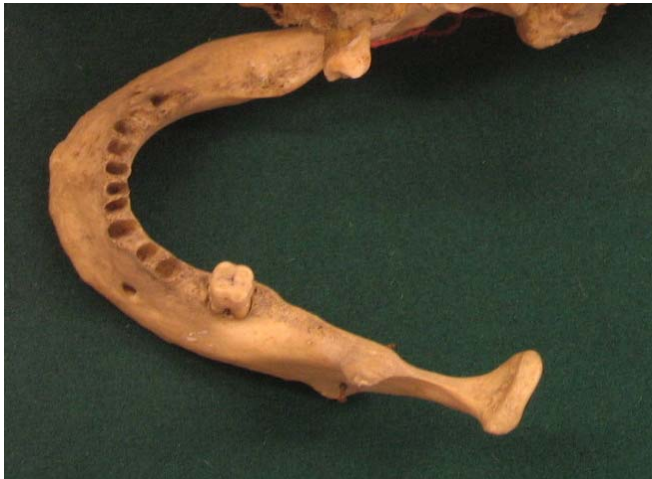

Photo 400/2

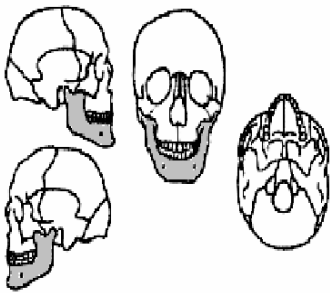
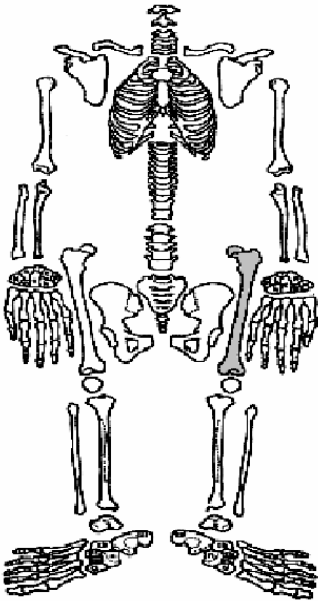
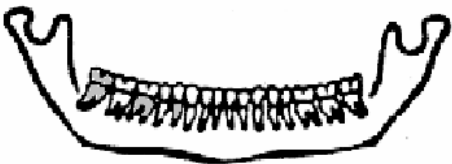
In the mandible there is only one molar *in situ*, while the other molars are lost *ante-mortem*.

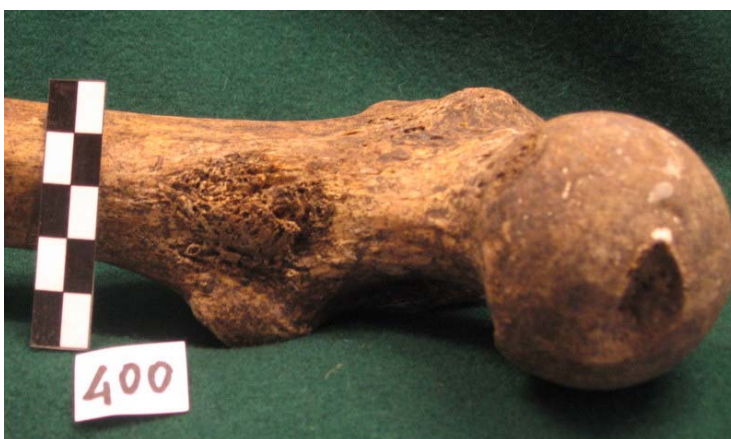

Photo 400/3

Evident periosteal reaction near the lesser trochanter with bone formation

Skeleton 402

Tedeschi Register (1911)	
Sex::	<i>M – B. G.</i>
Age:	<i>37 years</i>
Job:	<i>Butcher</i>
Date of death:	<i>29th of January, 1889</i>
Cause of death:	<i>Lung tuberculosis</i>
Burial:	<i>Common burial (Bologna)</i>
Bone Remains	
<u>Skull:</u> <i>Mandible</i>	
<u>Skeleton:</u> <i>Femur: left</i>	
<u>Teeth:</u> <i>Lower: 3rd molar right and roots of 1st right molar and 1st premolar right.</i>	

The remains of individual 402 are composed by the mandible and the left femur and they are white and clean and in a general good state of conservation.

The mandible has only 1 tooth *in situ*, the last right molar, and the roots of the 1st molar and the 1st premolar are partially in their positions. These teeth seem broken recently since the broken surfaces are white and clean. Any tooth seems lost *ante mortem*, and that one present does not evident signs of wear due to attrition. No evident signs of periodontal diseases are notable (Photo 402/1).

The femur presents some slight signs of wear and attachment of tendons near the lesser trochanter (Photo 402/2) and the cervical Allen's fossa with the underlying trabecular bony tissue.

The recovered remains aren't enough to suppose a pathological condition or a particular disease. The Allen's fossa is a small depression to a large eroded area (1 cm²) where cortical bone has been lost exposing underlying trabeculae and the border of this fossa may has a ridge or thickening tissue around it as reminiscent of an inflammatory response (Finnegan, 1978). This particular imprint may be due to extension when walking and running (Capasso, 1999)

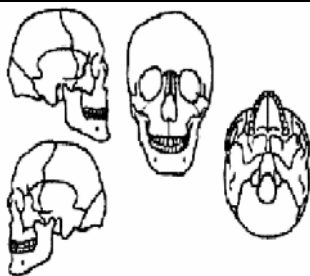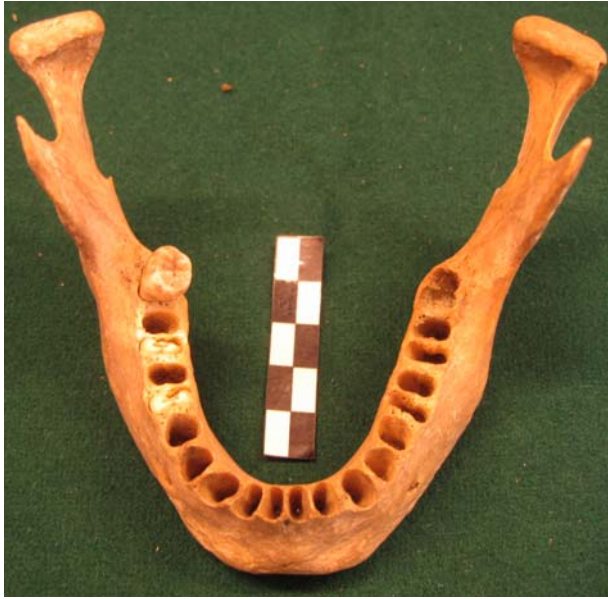
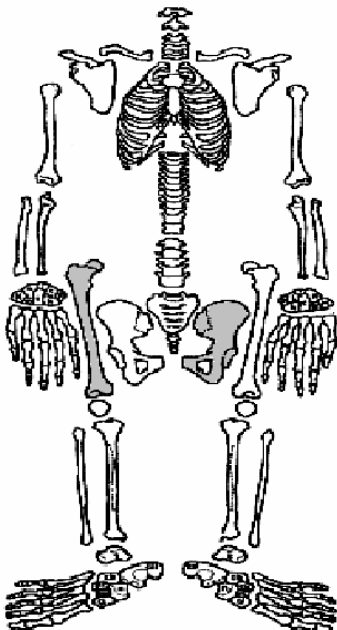
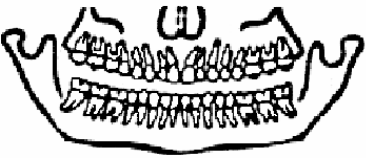


Photo 402/1
Mandible



Photo 402/2
Femur, right:
head and
neck with the
clear Allen's
fossa (black
arrow) and its
rim (white
arrow).

Skeleton 403

Tedeschi Register (1911)	
Sex::	<i>M – B.I.</i>
Age:	<i>55 years</i>
Job:	<i>Barber</i>
Date of death:	<i>31st of January, 1889</i>
Cause of death:	<i>Lung tuberculosis</i>
Burial:	<i>Common burial (Bologna)</i>
Bone Remains	
<u>Skull:</u> ---	
<u>Skeleton:</u> <i>Coxale: left</i> <i>Femur: right</i>	
<u>Teeth:</u> ---	

The remains of individual 403 are brown colour and clean. The remains are recovered from common burial of Bologna.

The coxal element presents several defects and granular surface. The internal surface of acetabular fossa is damaged and pitting, while the external rim appears remodelled by new bone tissue (Photo 403/1 and Photo 403/2). The obturator foramen seems deformed with osteophytes in the internal rim; the ischiopubic ramus presents many apposition of bone tissue.

The femur presents evident signs of periostitis in the lesser trochanter, along the diaphysis and in the distal end (Photo 403/3, Photo 403/4). The distal articular surface appears smooth and pitting, as the cortical external surface was wear and the internal trabecular bone is appearing (Photo 403/5).

Although the elements of individual 403 are few, they are explicative of health state. The femur shows many signs of periostitis and a great amount of remodelling bone tissue is available in the coxal element. These signs of disease agree with the possible cause of death marked, that is TB.

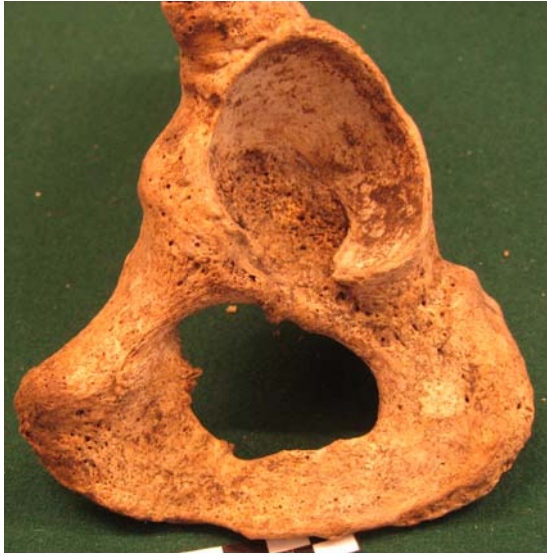

Photo 403/1
Coxal: note sign of remodelling bone with the deformed rim of obturator foramen and ischiopubic ramus.




Photo 403/2
Acetabular fossa: internal surface appears extremely damaged and pitting up.



Photo 403/3
Femur: lesser trochanter has periostitis signs.

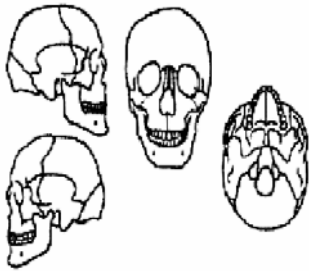
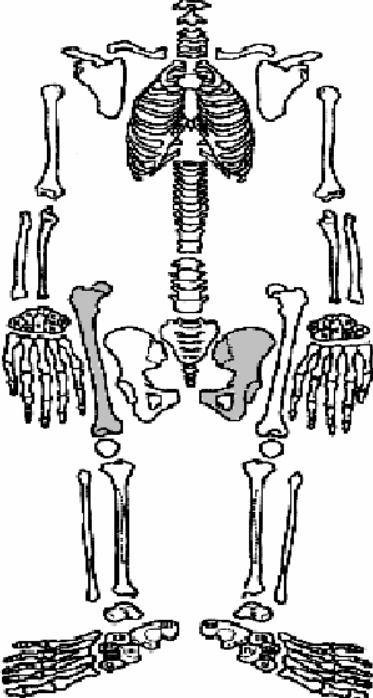
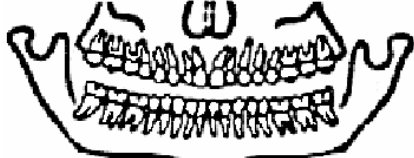


Photo 403/4
Femur, particular: note the evident signs of remodelling bone.



Photo 403/5
Femur: distal surface of the femur (knee), with an evident pitting surface.

Skeleton 410

Tedeschi Register (1911)	
Sex::	<i>M – Z. G.</i>
Age:	<i>20 years</i>
Job:	<i>Tailor</i>
Date of death:	<i>13th of March, 1889</i>
Cause of death:	<i>Lung tuberculosis</i>
Burial:	<i>Common burial (Bologna)</i>
Bone Remains	
<p><u>Skull:</u> ---</p>	
<p><u>Skeleton:</u> <i>Coxal: left</i> <i>Femur: right</i></p>	
<p><u>Teeth:</u> ---</p>	

The remains of individual 410 are the left coxal and the right femur, both of them clean and light brown colour, in general good state of preservation.

The coxal element is complete and presents the rim of cartilage in evidence, confirming the young age of the individual, as reported in the register (Photo 410/1).

The femur is lacking of a portion of greater trochanter that seems consumed: the cortex is totally damaged and the internal trabecular bone is visible (Photo 410/2). Along the intertrochanteric crest, the bone tissue appears visibly damaged and remodelling in the surface. In the diaphysis, no particular inflammation sign is present. In the distal end (knee) the two condyles are damaged, especially in the lateral condyle a notch is evident (Photo 410/3) without any particular remodelling tissue.

The remains present evident signs of inflammatory reaction only along the intertrochanteric crest, in the other marked places, the tissue appear damaged post-mortem. The only particular situation is the lateral condyle, but there aren't signs of inflammation or pathological condition.



Photo 410/1

Coxal: external rim of iliac bone with cartilage visible stating the young age of the individual.

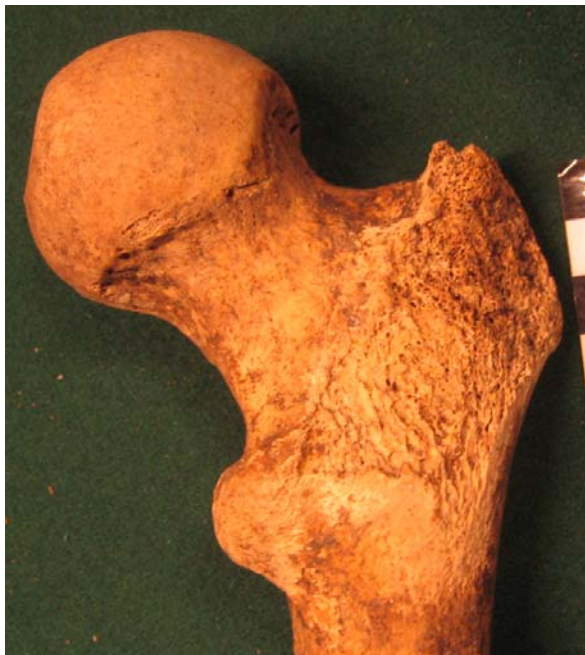

Photo 410/2

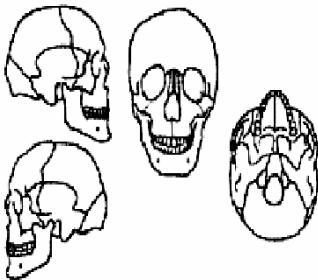
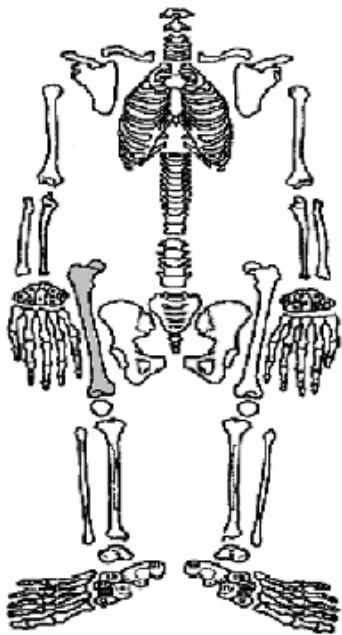
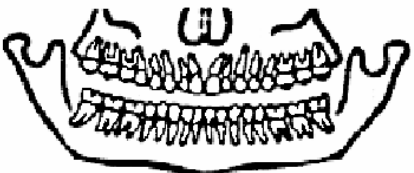
Femur, head: note the modified bone tissue in the intertrochanteric crest (periostitis).



Photo 410/3

Femur, distal end: both condyles appear damaged; the lateral one presents a notch that changes the form of the whole condyle.

Skeleton 411

Tedeschi Register (1911)	
Sex::	<i>M – G. L.</i>
Age:	<i>33 years</i>
Job:	<i>Porter</i>
Date of death:	<i>13th of March, 1889</i>
Cause of death:	<i>Lung tuberculosis</i>
Burial:	<i>Common burial (Bologna)</i>
Bone Remains	
<u>Skull:</u> ---	
<u>Skeleton:</u> <i>Femur: left</i>	
<u>Teeth:</u> ---	

The remains of individual 411 are constituted by only the left femur in a good state of preservation.

In the head of the femur, there are many signs of tendons insertion and an evident remodelling of bone tissue (Photo 411/1) with a big *Plaque* formation that can be defined as overgrowth or bone scar extending from the area of Poirier's facet on the femoral head down on to the femoral neck (Finnegan, 1978). In the distal end the surface has hypervascularization with a great porosity (Photo 411/3).

The remain is too few to define a specific pathology suffered by the individual 411, although the situation agrees with an inflammation reaction.



Photo 411/1

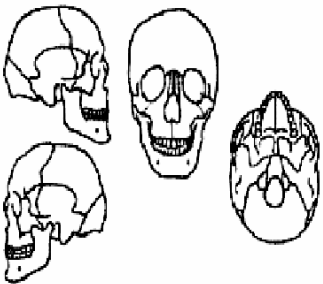
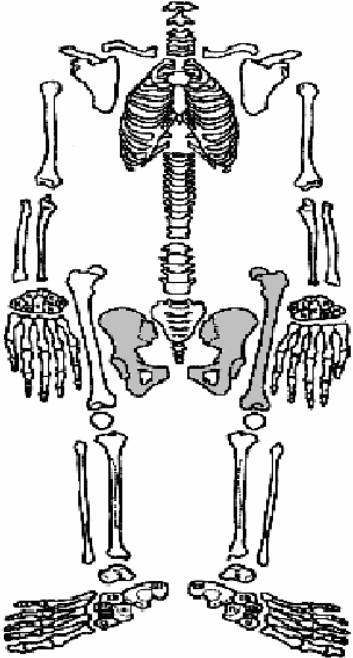
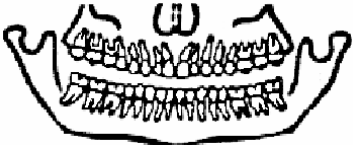
Femur, head: note the modified bone tissue and the plaque.



Photo 411/2

Femur, distal end: the patellar surface appears normal, without pathological signs, maybe slightly eburneated, but in particular the lateral surface is strongly remodelled.

Skeleton 422

Tedeschi Register (1911)	
Sex::	<i>F – N. F.</i>
Age:	<i>53 years</i>
Job:	<i>Housewife</i>
Date of death:	<i>19th of February, 1888</i>
Cause of death:	<i>Lung tuberculosis</i>
Burial:	<i>Common burial (Bologna)</i>
Bone Remains	
<u>Skull:</u> ---	
<u>Skeleton:</u> <i>Coxal: right and left elements</i> <i>Femur: left</i>	
<u>Teeth:</u> ---	

The remains of individual 422 are the 2 elements of coxale and the left femur, all of them are in good state of preservation and show a light brown colour.

The two coxal elements present sign of inflammatory reacts in all surfaces of contact with other bones i.e. with sacrum bone and pubic joint (Photo 422/1 and 422/2). Particularly, the acetabular fossae of both coxal have signs of inflammation and remodelling with apportion of new bone tissue (Photo 422/3 and Photo 422/4). In the internal rim, there are some important ostephytic nails (Photo 422/5 and Photo 422/6).

The femur does not present particular signs of inflammation reaction.

The remains number is scarsely representative to define a specific pathology, though the signs in the coxal elements correspond with the pathological marks of a first stage of tuberculosis , as report in the register. It is true that the age of individual can be related with the marks referred.



Photo 422/1
Coxal, right: contact surface with sacrum, note the inflammatory reaction.



Photo 422/2
Coxal, left: pubic surface, note the signs of inflammatory.



Photo 422/3
Coxal, left: acetabular fossa with apposition of new bone tissue.


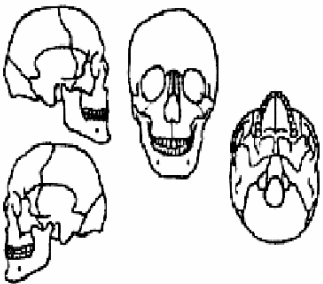
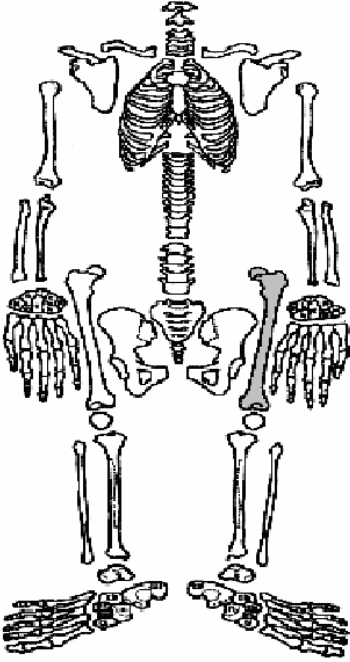
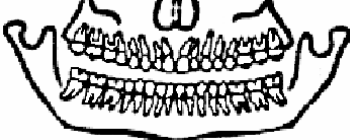


Photo 422/4
Coxal, left: internal rim.

Skeleton 432

Tedeschi Register (1911)	
Sex::	<i>F – N. L.</i>
Age:	<i>33 years</i>
Job:	<i>Housewife</i>
Date of death:	<i>3rd of August, 1888</i>
Cause of death:	<i>Lung tuberculosis</i>
Burial:	<i>Common burial (Bologna)</i>
Bone Remains	
<u>Skull:</u> ---	
<u>Skeleton:</u> <i>Femur: left</i>	
<u>Teeth:</u> ---	

The individual 432 is constituted just in the left femur, in good state of preservation, colour light brown.

The only one particular mark in the remain of individual 432 is the apposition on new bone tissue along intertrochanteric crest, probably due to the insertion of tendons (Photo 432/1). Also around the lesser trochanter, there are signs of bone tissue remodelling (Photo 432/2). The head of femur does not present marks of deformation or inflammatory reaction.

The remains are too few to define a particular pathology, nevertheless the state of the only element presented is compatible with first stage of TB or with other inflammatory diseases.

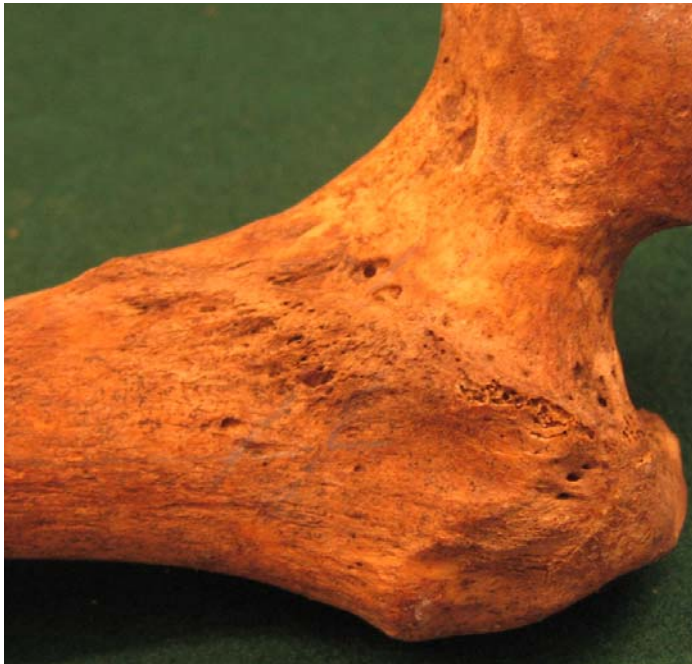

Photo 432/1

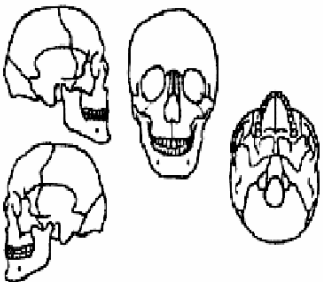
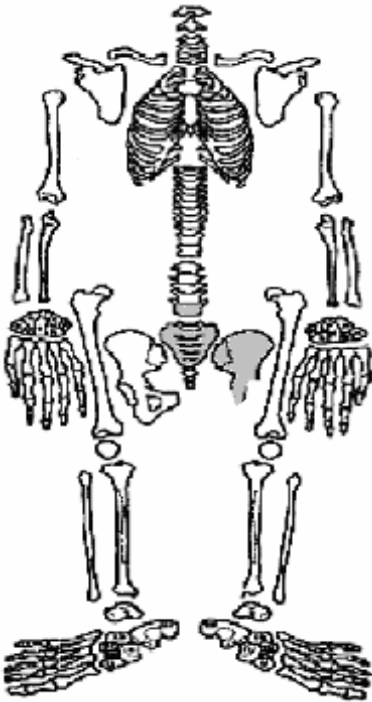
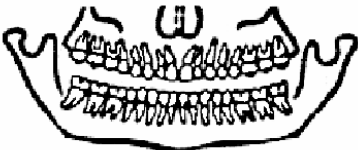
Femur, left: intertrochanter crest with signs of cartilage insertions and a plaque formation in early stage.

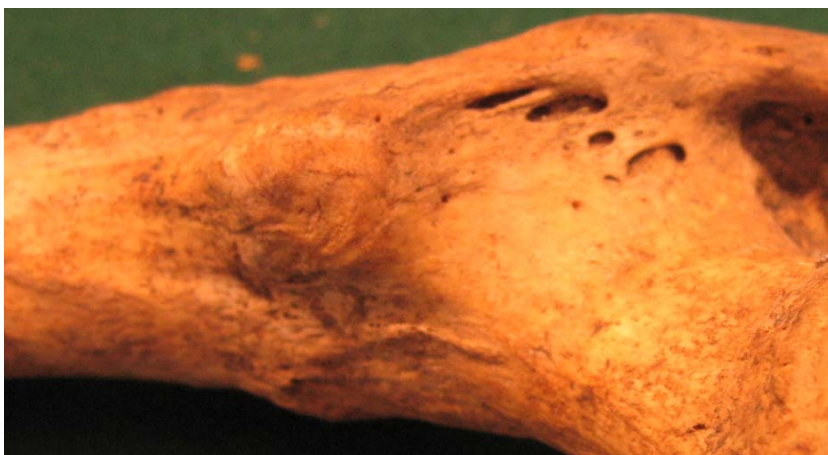

Photo 432/2

Femur, left: lesser trochanter, note signs of remodelling bone tissue.

Skeleton 438

Tedeschi Register (1911)	
Sex::	<i>F – Z. G.</i>
Age:	<i>22 years</i>
Job:	<i>Tailor</i>
Date of death:	<i>4th of March, 1888</i>
Cause of death:	<i>Lung tuberculosis</i>
Burial:	<i>Common Burial (Bologna)</i>
Bone Remains	
<u>Skull:</u> ---	
<u>Skeleton:</u> Sacrum Coxal: <i>portion of left elements</i>	
<u>Teeth:</u> ---	

The individual 438 remains are composed by the sacrum and a portion of left coxal bone. Both the elements are in good state of preservation and light brown colour.

In the sacrum bone it is notable a sacralization of L5: the morphological aspect is normal, but there is a symmetrical incomplete fusion of the last lumbar vertebra (L5) with the first sacral vertebra (S1) (Photo 438/1). This anomaly shows 5 sacral foramina per side, although there is the non total fusion for the last foramina: at both sides the foramina are opened and in the right side the opened element is broken (Photo 438/2). In the posterior view, it is detectable that the sacral tuberosity and the articular process of the vertebrae deformed and they don't have a normal appearance (Photo 438/3).

The coxal element presents some inflammation reacts in the ischio-pubic ramus (Photo 438/4) with a light apposition of new bone tissue (Photo 438/5).

Aufderheide & Rodríguez-Martín (1998), report that the sacralizations occur in 3-5% of the population and two-thirds are sacralizations of L5. In sacralization the anomalies in development of one or both of the transverse processes of the fifth lumbar vertebra may produce fusion with the base of sacrum, producing a “butterfly wing” appearance (Duthie & Bentley, 1987, cited by Aufderheide & Rodríguez-Martín, 1998).

No marks are notable to define a particular pathological disease, except the cited congenital malformation of the sacrum. The inflammation of the ischio-pubic ramus is a-specific reaction and there aren't elements enough to define a possible cause of death.



Photo 438/1

Sacrum: general view of the morphological aspect of the sacrum, with the sacralization of L5, symmetrical and non incomplete (the body is unfused).



Photo 438/2

Sacrum, terminal vertebrae: the two last foramina are open and the right element is lacking.



Photo 438/3

Sacrum, posterior view: sacral tuberosity with a "butterfly wing" appearance.



Photo 438/4

Coxal, left: inflammation reacts notable in the ischio-pubic ramus.


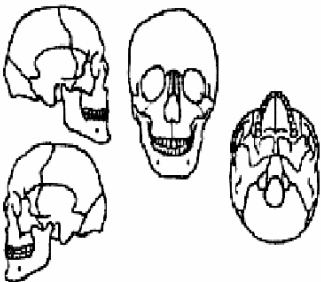
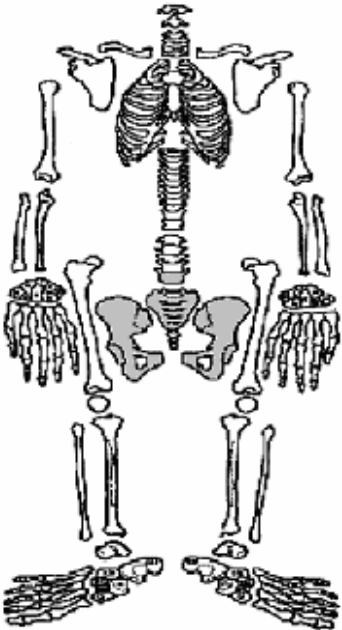
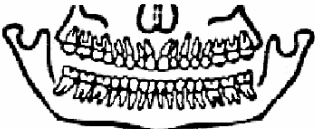


Photo 438/5

Coxal, left: close-up of Photo 438/4, detail of new bone tissue (arrows) formed in the ischio-pubic ramus.

Skeleton 439

Tedeschi Register (1911)	
Sex::	<i>F – M. C.</i>
Age:	<i>18 years</i>
Job:	<i>Housewife</i>
Date of death:	<i>4th of May, 1888</i>
Cause of death:	<i>Lung tuberculosis</i>
Burial:	<i>Common burial (Bologna)</i>
Bone Remains	
<u>Skull:</u> ---	
<u>Skeleton:</u> Sacrum Coxal: right and left	
<u>Teeth:</u> ---	

The individual 439 is constituted of the sacrum and the coxal, all are in good state of preservation, colour light brown.

In the sacrum bone it is notable a sacralization of L5: the morphological aspect is normal, but there is a symmetrical incomplete fusion of the last lumbar vertebra (L5) with the first sacral vertebra (S1) (Photo 439/1 and Photo 439/2)). This anomaly shows 5 sacral foramina per side, although there is the non total fusion for the last foramina at left side. As quoted for the previous individual, Aufderheide & Rodríguez-Martín (1998) report that these types of anomalies occur in 3-5% of the population and two-thirds are sacralizations of L5. In sacralization the anomalies in development of one or both of the transverse processes of the fifth lumbar vertebra may produce fusion with the base of sacrum, producing a “*butterfly wing*” appearance (Duthie & Bentley, 1987, cited by Aufderheide & Rodríguez-Martín, 1998). In this case, the posterior view is normal appearance.

The two coxal elements are present. In numerous parts of the bone rims (as in the wing of left ilium or in the ischium), there are notable the cartilages don't fused with the bone (Photo 439/3). This characteristic is a peculiarity of young people, as the individual 439 is like quoted by Tedeschi's register.

In the right os coxae the acetabulum presents an inflammatory reaction, in the internal surface of the acetabular fossa is granular (Photo 439/4). In the left acetabular notch the surface is less granular and damaged.

The characteristics present in the remains of individual 439 aren't specific of a particular disease. The signs of inflammatory reaction in the acetabular notch are compatible with the TB disease, but they are absolutely too much few to be elements of diagnosis.



Photo 439/1

Sacrum: sacralization of the L5 that appears fused with the S1. Note the 5 sacral foramina and the last opened at left side. In the external rim, there are notable the marks of trasversal processes.



Photo 439/2

Sacrum: particular aspect of the connection between bodies L5 and S1. Note the presence of inflammatory tissue, with numerous little osteophytes.

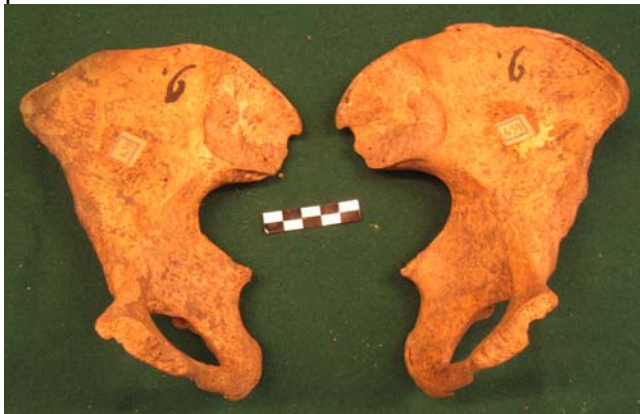

Photo 439/3

Coxal elements: note the presence of cartilage's lines.

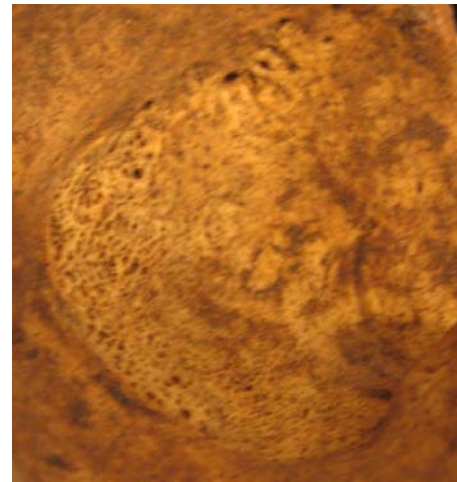
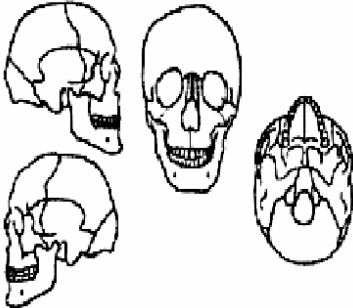
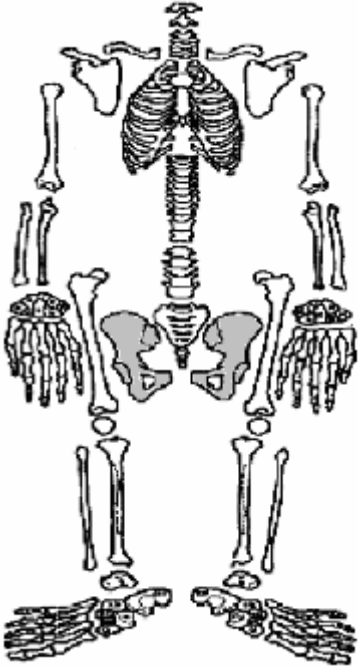
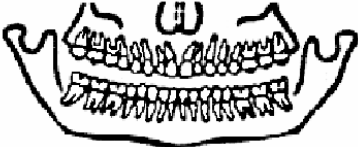


Photo 439/4

Acetabular fossa, right: note the inflammatory reaction.

Skeleton 445

Tedeschi Register (1911)	
Sex::	<i>F – M. L.</i>
Age:	<i>28 years</i>
Job:	<i>Servant</i>
Date of death:	<i>23rd of October, 1888</i>
Cause of death:	<i>Lung tuberculosis</i>
Burial:	<i>Common burial (Bologna)</i>
Bone Remains	
<u>Skull:</u> ---	
<u>Skeleton:</u> <i>Coxal: right and left</i>	
<u>Teeth:</u> ---	

The only remains of individual 445 are the coxal elements, right and left, both light brown colour and clean. The elements are complete and in a good state of conservation.

The only particular aspect of the coxal elements is the acetabular fossa: in both cases, the notches present an inflammatory reaction and the surfaces are very granular and damaged. The external surface is normal without pathological signs of diseases (Photo 445/1, Photo 445/2 and Photo 445/3).

The granular internal surface of the acetabular notch is one of the characteristic features reported by Aufderheide and Rodríguez-Martín (1998) as TB evidence. For Individual 445, this is the only sign of the two elements recovered and it can't be sure evidence of this specific disease.



Photo 445/1
Coxal elements: general view.



Photo 445/2
Acetabular fossa, right: granular surface in internal notch.

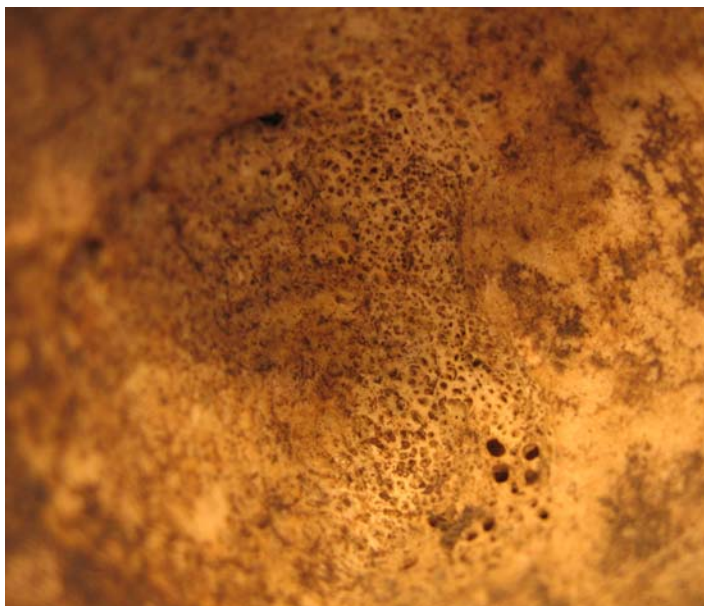
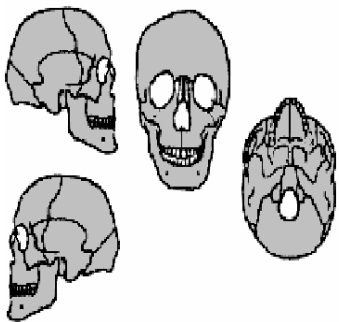
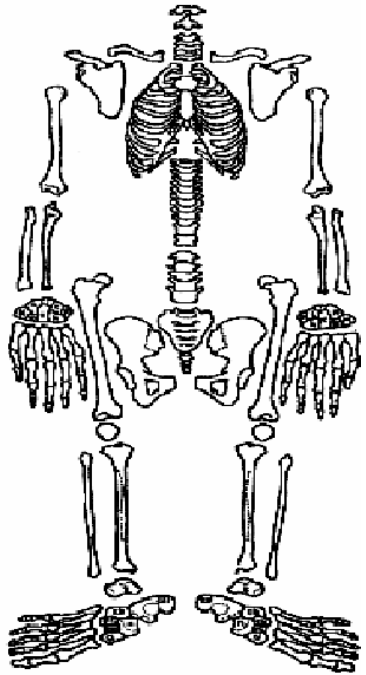
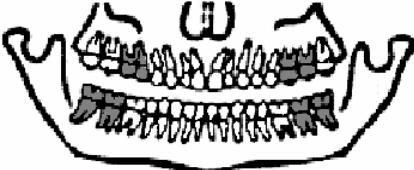


Photo 445/3
Acetabular fossa, left: granular surface is notable also in this side.

Skeleton 450

Tedeschi Register (1912)	
Sex:	<i>F – C. R.</i>
Age:	<i>20 years</i>
Job:	<i>Corset maker</i>
Date of death:	<i>7th of September 1888</i>
Cause of death:	<i>Lung tuberculosis</i>
Origin:	<i>Common burial (Bologna)</i>
Bone Remains	
<p><u>Skull:</u> <i>Cranium with mandible</i></p>	
<p><u>Skeleton:</u> ---</p>	
<p><u>Teeth:</u> <i>Upper: 2nd pre-molar and 1st molar right, 1st and 2nd molars left.</i> <i>Lower: 2nd and 3rd molars right and left.</i></p>	

The Individual 450 is composed only by the cranium and mandible and both of them are ochre color and clean.

The cranium's sutures are notable clearly, due to the young age at death. The squamosal suture is open and raised (Photo 450/1).

In the jaw, right arch there are the 2nd premolar and the 1st molar, while in left arch there are 1st and 2nd molars *in situ*. The 3rd left molar is ready to erupt. In the mandible, there are 2nd and 3rd molars in both arches. There are lost 3 teeth *ante mortem* (2nd right molar upper, 1st right and left molars down) and in these areas the bone tissue is almost completely adsorbed (Photo 450/2).

The external diploe is damaged and absent in several areas, especially in the left parietal bone: the trabecular bone is detectable below the diploe (Photo 450/3 and Photo 450/4). The lacking diploe is removed in different layers that are parallel or sub-parallel in some points, alternating areas with the outer layer and areas with inner layers (Photo 450/5 and Photo 450/6). These erosions affect the entire left side until the mastoid process, where there are some small perforations. The two bigger holes measured mm 3x4 and mm 4x3 (Photo 450/6). In the temporal bone there is an irregular perforation, whose major dimensions measure mm 29x14. The edges are clean and regular and hole's form is asymmetrical (Photo 450/8). The x-ray images are reported (Photo 450/9).

It is very difficult to identify the real cause of these irregular lesions. Thanks to the register, we know that this skull was buried in a common cemetery at Bologna. The individual died in 1888 and it is catalogued with a number lower than number 470 that is the identification code of an individual dead in 1890. Since we can suppose that Tedeschi registered the remains in progressive order, we can deduce that individual 450 staid directly in the soil only for 2 years, that seems be few for a thaphonomic process due to botanical effects. Furthermore, as many authors report (Aufderheide. and Rodríguez-Martin, 1998; White and Folkens, 2005) the groundwater and/or plant secretions can generate surface grooves that can simulate vascular impressions, though their reticulate pattern can often be recognizably from ante mortem blood vessel structures. In the description of bone modification by nonhuman animal, White and Folkens, (2005) report that “the chisel edge of the rodent incisor is used

to shave away the surface bone, producing a distinctive, fan-shaped pattern of regular, shallow, parallel or sub-parallel, flat-bottomed grooves that are usually concentrated on the projecting surfaces of bones”.

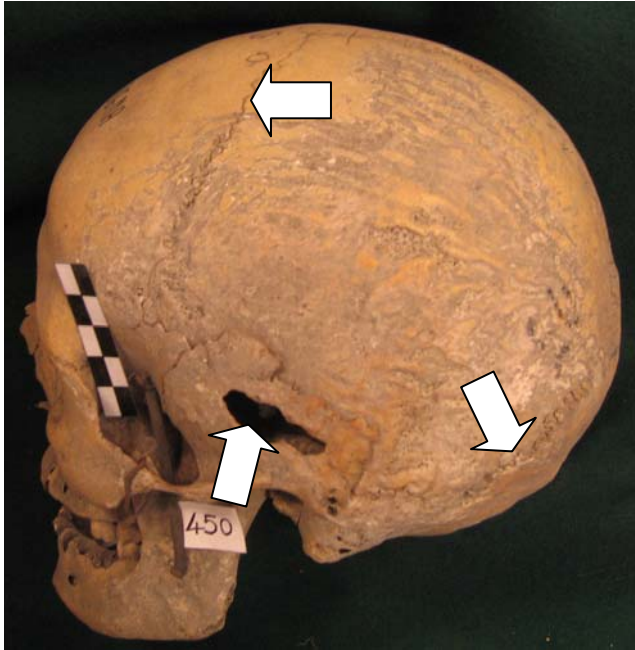


Photo 450/1
Cranium sutures are evident and the squamosal one is open and raised.

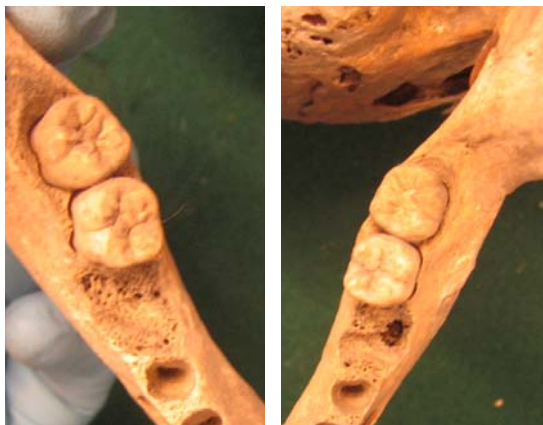

Photo 450/2
Mandible: bone tissue absorbed after lacking teeth (right and left arch, respectively).



Photo 450/3
Cranium: diploe is removed and trabecular tissue is visible.



Photo 450/4
Cranium: another particular of damaged tissue of cranium, near lambdoid suture.



Photo 450/5
Cranium: particular of the bone tissue damaged, lacking the superficial layer of external diploe.

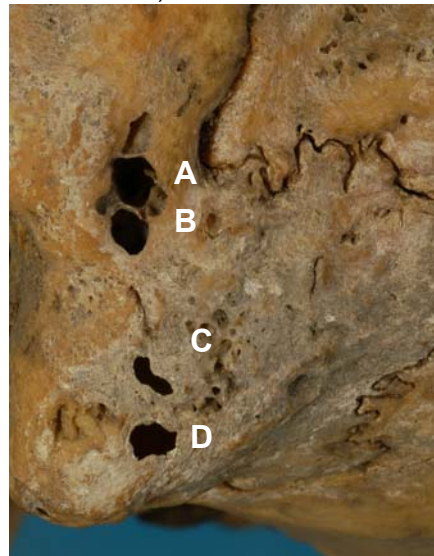


Photo 450/6
Mastoid process: small holes are present (Major dimensions measure: A. 4x4 mm; B. 3x3 mm; C. 3x1 mm and D. 4x3 mm).

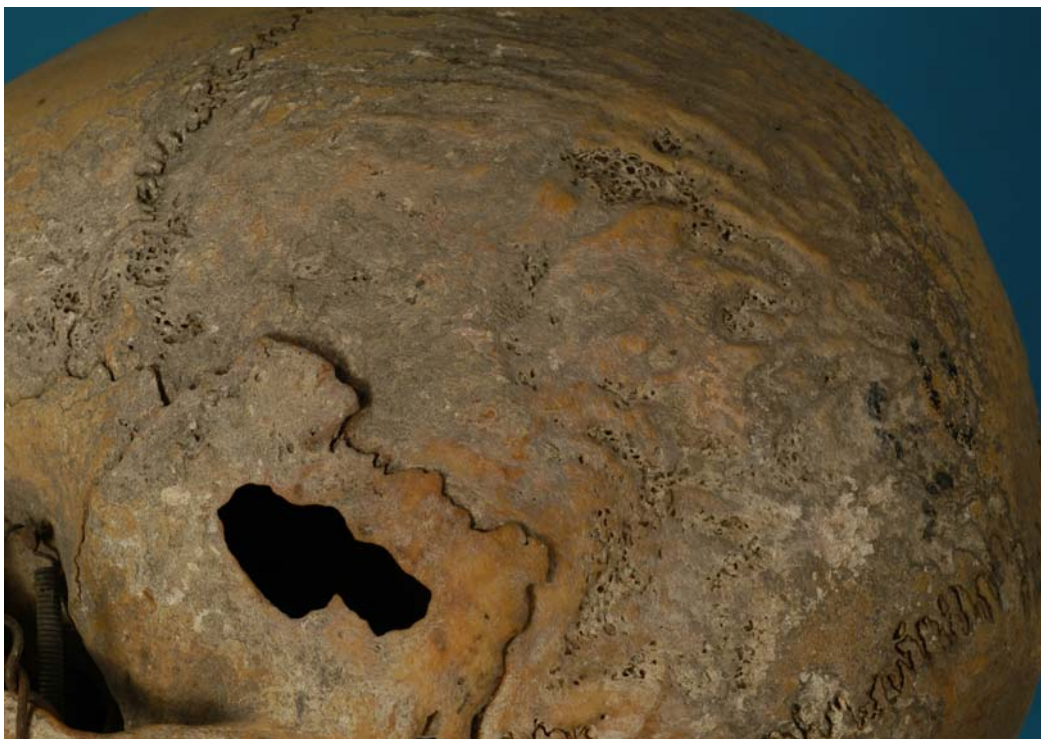

Photo 450/7

Cranium: removed areas with different strength of signs (almost parallel signs in cranium vault).




Photo 450/8

Temporal bone: irregular perforation but with regular and clean edges (29x14 mm).

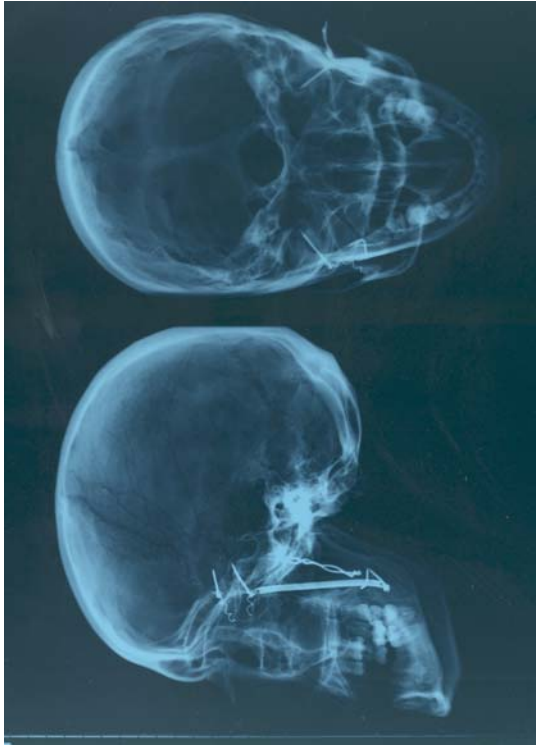
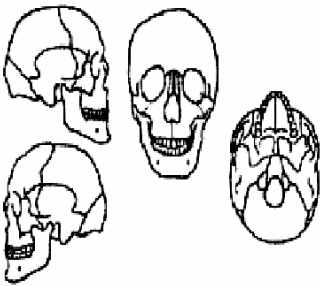
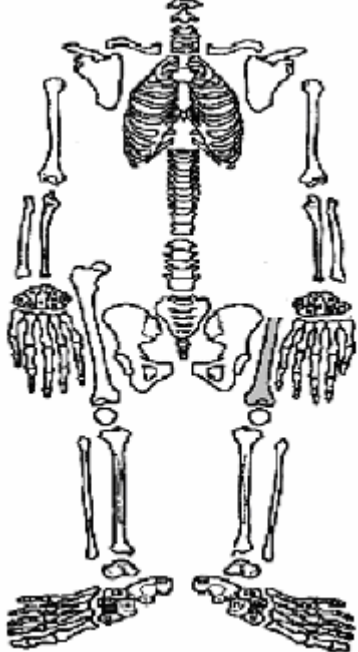
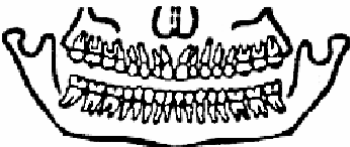


Photo 450/9

X-Ray of the skull. The metal spring used to hold the cranium and the mandible is visible.

Skeleton 454

Tedeschi Register (1911)	
Sex::	<i>F – N. L.</i>
Age:	<i>33 years</i>
Job:	<i>Housewife</i>
Date of death:	<i>3rd of August, 1888</i>
Cause of death:	<i>Lung tuberculosis</i>
Burial:	<i>Common burial (Bologna)</i>
Bone Remains	
<u>Skull:</u> ---	
<u>Skeleton:</u> <i>Femur: left, portion.</i>	
<u>Teeth:</u> ---	

The individual 454 is constituted only in a portion of left femur, in good state of preservation and white colour. The femur appears lacking of the head and diaphysis.

The only one particular mark in 454 remain is the depression of eroded area and the apposition on new bone tissue in the popliteal surface (Photo 454/1), especially in the medial condyle side (Photo 454/2). This marker is called Charles' facet and it is attributed to squatting by some authors (cited by Capasso, 1999). The condyles are wearing in the lateral surfaces, such that the external rim appears more prominent than the internal surface (Photo 454/3). This rounding of lateral trochlear margin is called Martin's facet and it is associated with pressure from the quadriceps tendons, particularly during knee flexion (Capasso, 1999).

The remains are too few to define a particular pathology, although the state of the distal epiphysis suggests a disease that could involve the knee. An early stage of TB (as quoted by Tedeschi) or of other inflammatory disease might be compatible with remain.

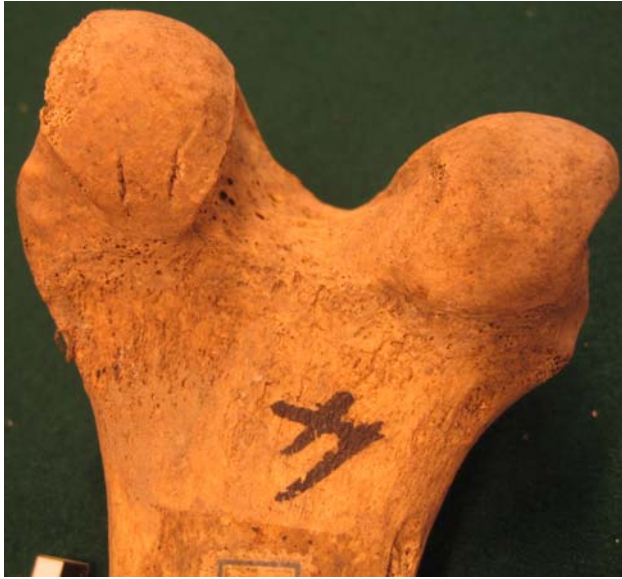

Photo 454/1

Femur, left: popliteal surface present remodelling new tissue. Note the signs in the medial condyle surface, called Charles' facet.



Photo 454/2

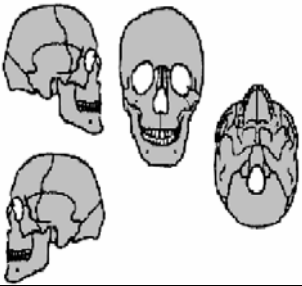
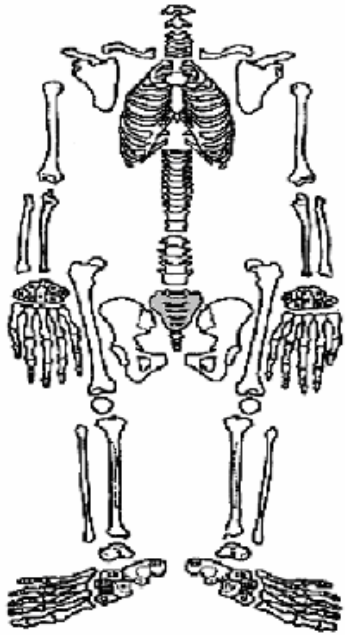
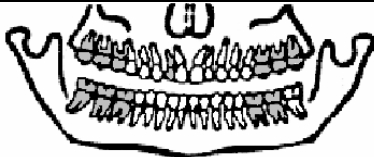
Femur, left: medial condyle, close up of Photo 454/1, note the apposition of new bone tissue and the underlying trabeculae.



Photo 454/3

Femur, left: lateral view, note the consumed surfaces.

Skeleton 455

Tedeschi Register (1911)	
Sex::	M – S. F.
Age:	24 years
Job:	Porter
Date of death:	4 th of February, 1888
Cause of death:	Lung tuberculosis
Burial:	Common burial (Bologna)
Bone Remains	
<u>Skull:</u> <i>Cranium and mandible</i>	
<u>Skeleton:</u> <i>Sacrum</i>	
<u>Teeth:</u> <i>Upper: right and left all molars and 2nd right incisive tooth.</i> <i>Lower: right arch, all molars, left arch 1st and 2nd molars.</i>	

The remains of individual 455 include the entire skull and the sacrum. They are clean and light brown colour, in a general good state of preservation.

The skull is complete and the mandible is holed with metal spring. In the jaw there are all molars and the 2nd right incisive *in situ*. All teeth don't show wear attrition, only calculus in the external side. In two points the roots are visible, but without any inflammatory process (Photo 455/1). No tooth seems lost *ante mortem*. In the mandible, there are all molars *in situ*, except the 3rd in left arch, that seems lost *ante mortem* without any pathological involvement.

The maxilla bones show a slight inflammation reaction (Photo 455/2).

The cranial sutures are closed but evident, with numerous wormian bones (Photo 455/3).

In the vault of cranium there are some marks, some of those appear semi-parallel, that scrape the superficial diploe and leaving grey colour signs (Photo 455/4). So, the cranium appears damaged and granular, no hole is visible. In the right parietal bone, posterior side, there are various small brown marks with irregular defects (Photo 455/5).

Sacrum is complete and without particular marks of pathological conditions.

The general situation is similar to cranium of Individual 450, although in an early inferior stage. Similarly, thanks to the register, we know that this skull was buried in a common cemetery at Bologna. The individual died in 1888 and it was catalogued with a number lower than 470 that is the identification code of an individual dead in 1890 and who is the first non-buried. Since we can suppose that Tedeschi registered the remains in progressive order, we deduce that individual 455 staid directly in the soil only for 2 years (similarly to individual 450). This period seems to be too few for a thaphonomic process due to botanical effects. The characteristic lesions of individual 455 can be assimilating to lesion of individual 450, except for the cited brown lesions. We can suppose that the general lesions are caused in a similar way of individual 450, while the brown lesions are caused by syphilis. There aren't elements to confirm the cause of death.

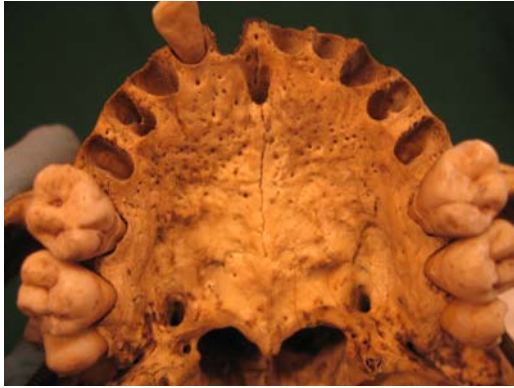

Photo 455/1
Maxilla: good state of teeth and maxilla bones with slight inflammation reaction.



Photo 455/2
Cranial sutures: wormian bone.

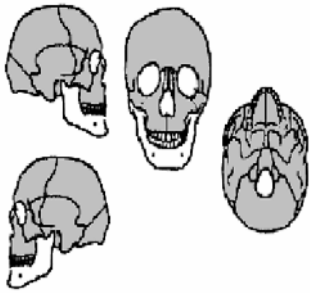
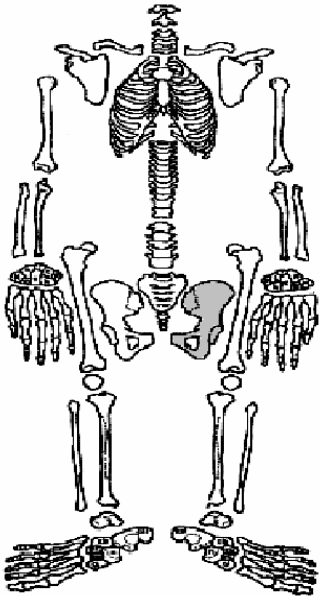



Photo 455/3
Cranial vault: superficial lesions with tissue defects.



Photo 455/4
Lesions visible in the posterior side of parietal bone.

Skeleton 456

Tedeschi Register (1911)	
Sex::	<i>M – L. L.</i>
Age:	<i>20 years</i>
Job:	<i>Shoemaker</i>
Date of death:	<i>17th of May, 1889</i>
Cause of death:	<i>Lung tuberculosis</i>
Burial:	<i>Common burial (Bologna)</i>
Bone Remains	
<u>Skull:</u> <i>Cranium</i>	
<u>Skeleton:</u> <i>Coxal: left.</i>	
<u>Teeth:</u> <i>Upper: right arch, 2nd premolar and 1st molar; left arch 2nd premolar and 1st and 2nd molars.</i>	

The 456 remains are the cranium and the left coxal, both are light brown colour and in a good state of preservation.

In situ the teeth present are 1st premolar, 1st and 2nd molars on left arch and 2nd premolar and 1st molar on right arch. All teeth haven't wear attrition that could confirm the young age of individual (Photo 456/1).

The cranial sutures are closed but very evident, they are indented and various wormian bones are present (Photo 456/2).

In cranial vault there are numerous damaged areas, where the superficial diploe is amended. These regions can be divided in two different groups:

1. a first group, near mastoid processes and occipital bone, the tissues appear remodelling (Photo 456/2 and Photo 456/3);
2. a second group, in frontal, parietal and occipital bone, the tissue appear lacking in the superficial layer (Photo 456/4 and Photo 456/5).

The left coxal has the cartilage lines open that confirm the young age of individual 456 (Photo 456/6).

The two different modifications of cranial vault could be due to a single cause in different stages of disease. Also in the precedent individual cases, 455 and 450 individuals, the 456 individual was buried directly in the soil in a common cemetery, and we can't be sure on taphonomic process. The lesions may suggest about syphilis, in tertiary stage, in an enough early stage.

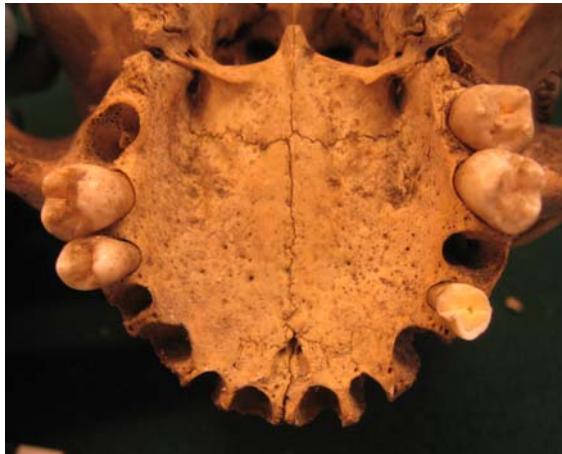

Photo 456/1

Jaw: the teeth *in situ* appear don't wear, no teeth seem lost *ante mortem*.

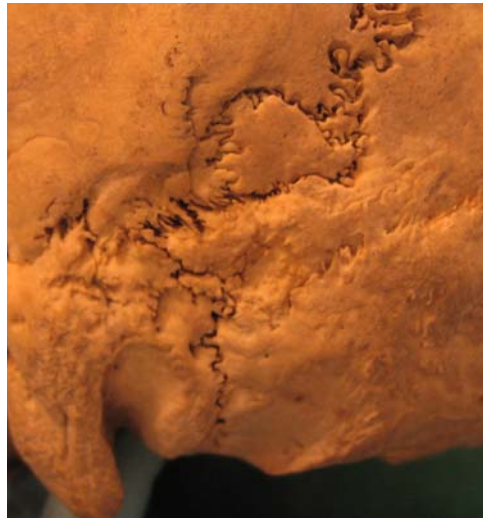

Photo 456/2

Sagittal suture: note the indented rim with wormian bones.

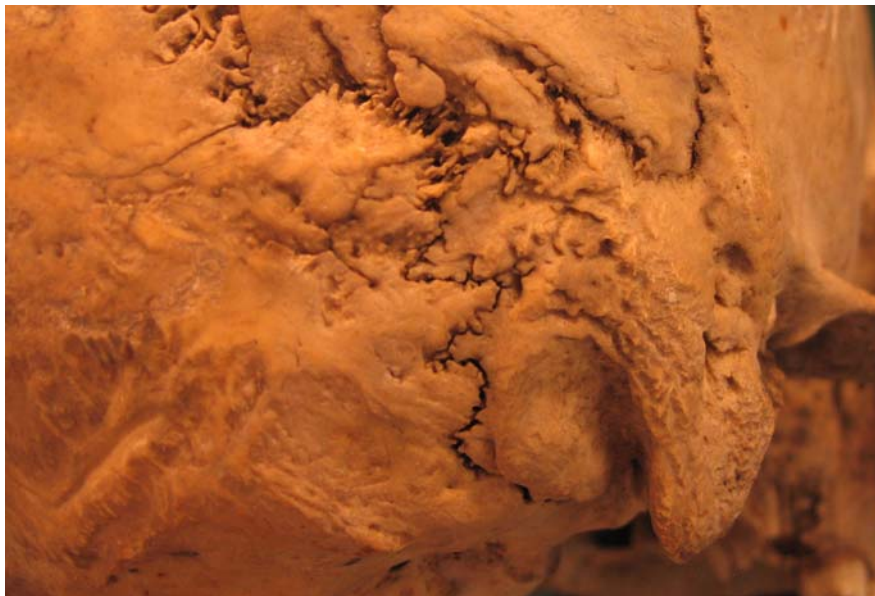


Photo 456/4

Mastoid process (right) and occipital bone: damaged and remodelling bone with areas lacking of the superficial layer.

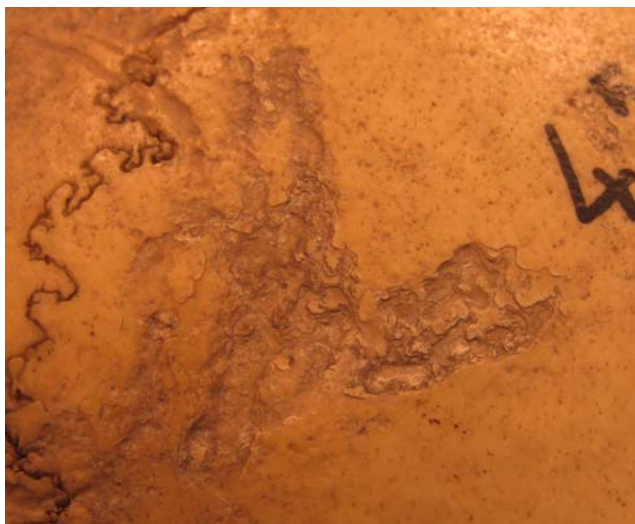


Photo 456/5

Frontal bone: irregular areas lacking of superficial layer of external diploe, without involvement of trabecular internal bone tissue.



Photo 456/5

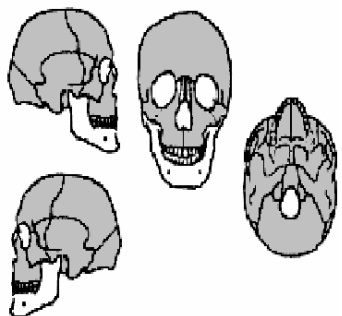
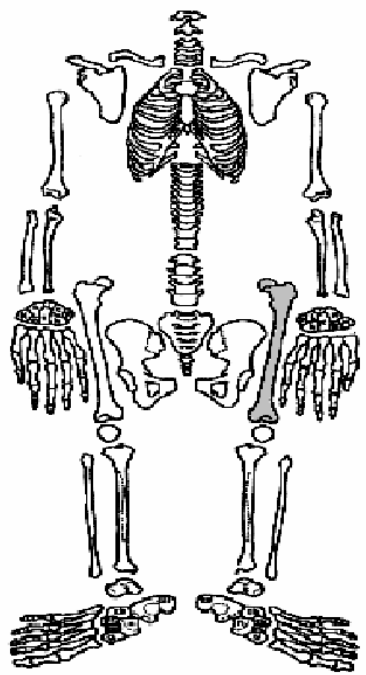

Parietal bone: irregular areas lacking of superficial layer of external diploe.



Photo 456/7

Pubic ram: note the cartilage line open due to the young age of individual 456.

Skeleton 457

Tedeschi Register (1911)	
Sex::	<i>M – M.O.</i>
Age:	<i>58 years</i>
Job:	<i>Tailor</i>
Date of death:	<i>21st of August, 1889</i>
Cause of death:	<i>Lung tuberculosis</i>
Burial:	<i>Common burial (Bologna)</i>
Bone Remains	
<u>Skull:</u> <i>Cranium</i>	
<u>Skeleton:</u> <i>Femur: left</i>	
<u>Teeth:</u> <i>Upper: 1st molar right, 1st and 2nd molars left.</i>	

The individual 457 remains are the cranium and the left femur, both are beige color and clean.

The cranial sutures are totally closed, that confirm the *senior* age of individual, and they appear very indented with several wormian bones.

In situ there are only 3 teeth (1st right molar and 1st and 2nd left molars) and all of them have calculus in the external surfaces. The 2nd right molar appears lost *ante-mortem* with slight bone adsorption.

The teeth present a 5th stage of attrition wear by Murphy's scale at 8 stages (Hillson, 1996) (Photo 457/1).

The left femur has strong marks of exostoses near the greater trochanter and along the linea aspera with apposition of new bone tissues (Photo 457/2 and Photo 457/3).

The few remarkable marks and the small number of recovered bones aren't enough to define a possible pathology. The bilateral exostoses located on the superior medial surface of the trochanteric fossa can be determined by prolonged sitting posture with the legs extended (Capasso, 1999), unfortunately the right femur has been lost to define with more precision better this situation.

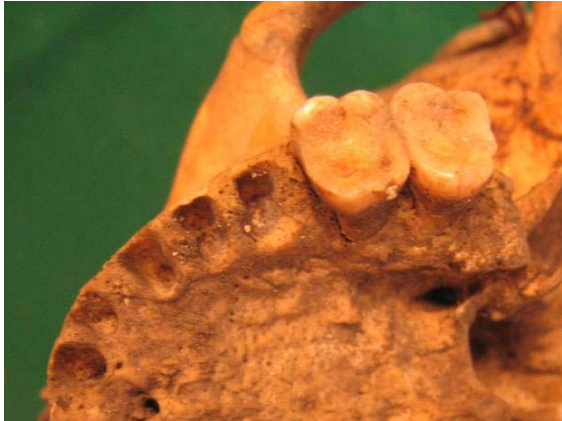

Photo 457/1
Maxilla, left: wear of 1st and 2nd molars.

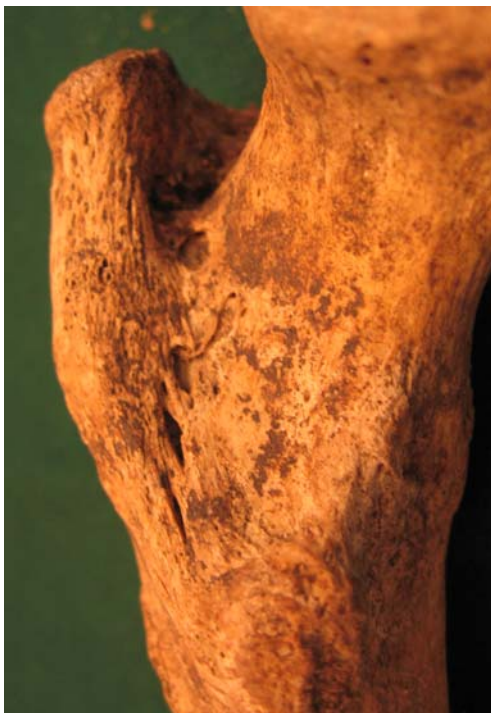
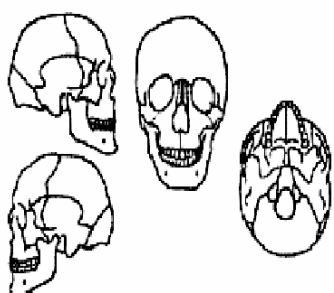
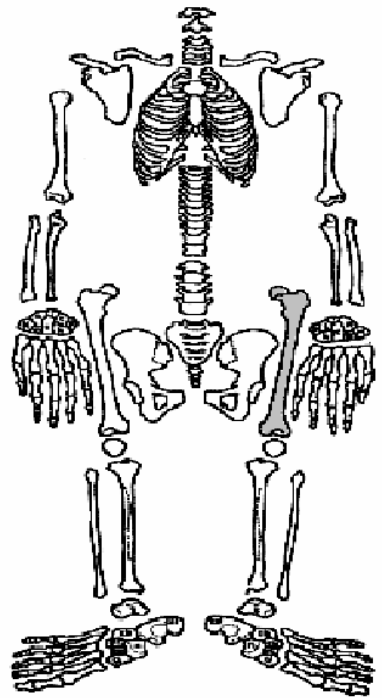
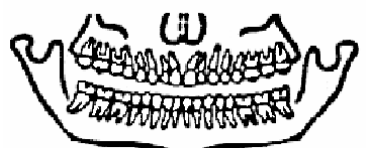


Photo 457/2
Femur, left: greater trochanter.



Photo 457/3
Femur, left: signs of new bone apposition.

Skeleton 458

Tedeschi Register (1911)	
Sex::	<i>M – V. L.</i>
Age:	<i>60 years</i>
Job:	<i>Farmer</i>
Date of death:	<i>6th of August, 1889</i>
Cause of death:	<i>Lung tuberculosis</i>
Burial:	<i>Common burial (Bologna)</i>
Bone Remains	
<p><u>Skull:</u> ---</p>	
<p><u>Skeleton:</u> <i>Femur: left</i></p>	
<p><u>Teeth:</u> ---</p>	

Individual 458 is constituted by left femur, that is light brown colour and in a good state of preservation.

The femur presents apposition of new bone tissue in the intertrochanteric line, while in the anterior superior margin the tissue presents some lacking areas (Allen's fossa) where the underlying trabeculae are visible (Photo 458/1 and Photo 458/2). The femur appears with a high level of remodelling along intertrochanteric crest in a posterior view (Photo 458/3 and Photo 458/4). In the diaphysis, the linea aspera is evident and strong for the insertion of tendons. In a distal view epiphysis, the condyles appear slight deformed and the lateral surface is damaged and medial epicondyle is prominent (Photo 458/5 and Photo 458/6).

Unfortunately, there aren't elements to define with precision the pathological signs noted in the femur. Probably, the individual 458 suffered from a pathology involvement the joints and TB infectious, like reported in the register, can be considerate probable.

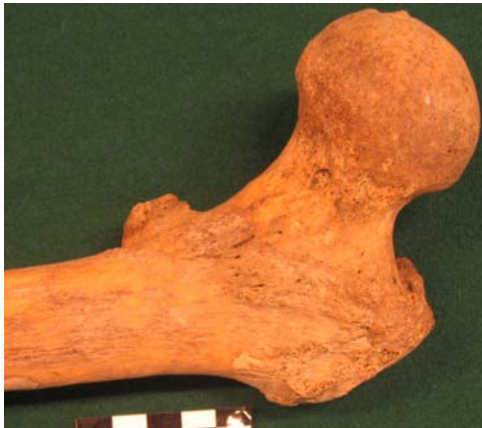

Photo 458/1

Femur, left: anterior view, note the intertrochanteric line with apposition of new tissue and remodelling of the profile.

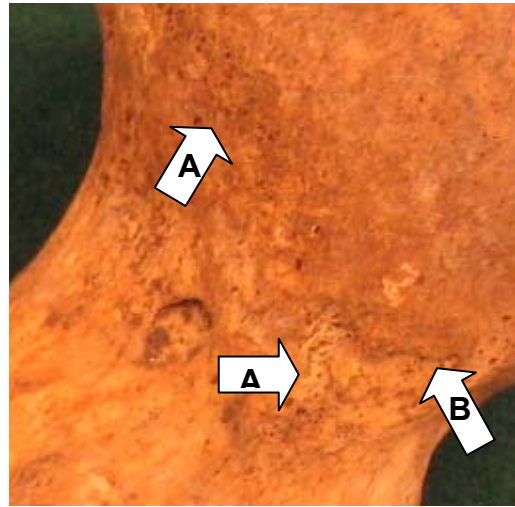


Photo 458/2

Femur, left: particular of neck, with lacking areas (Arrow A) and slight apposition of new bone tissue in other areas, plaque formation (Arrow B).

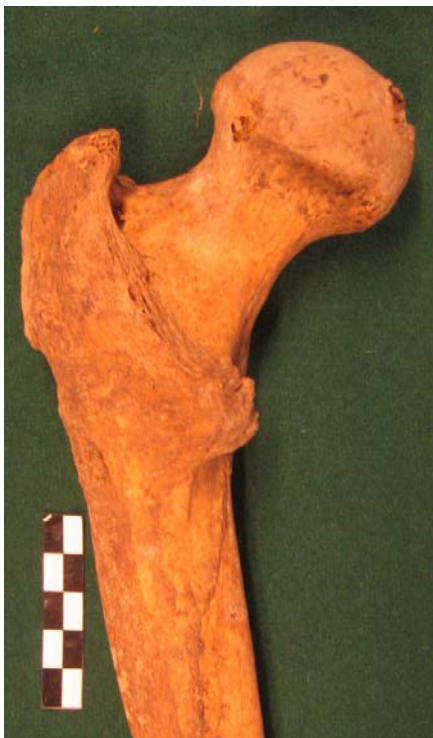

Photo 458/3

Femur, left: posterior view, note the exostoses located along intertrochanteric crest, while neck and head are normal.



Photo 458/4

Femur, left: posterior view, oblique, note the apposition of bone tissue in numerous layers in the greater and lesser trochanters

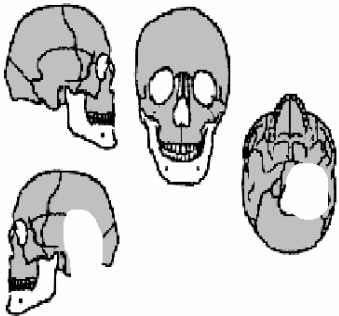
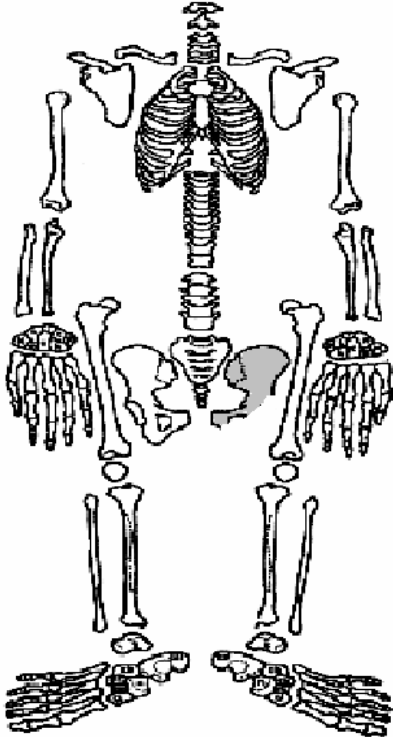



Photo 458/5
Femur, left: posterior view, distal epiphysis, note the intercondylar fossa that present hypervascularization in the surface

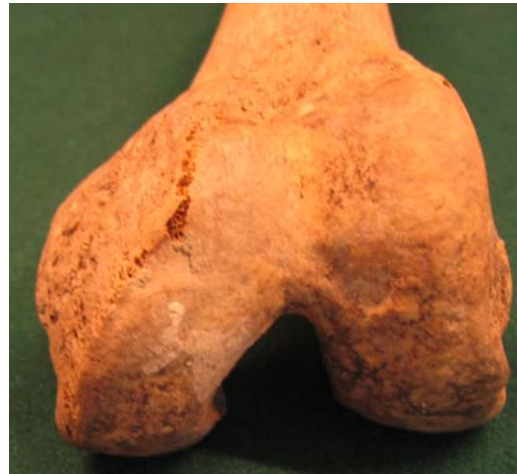

Photo 458/6
Femur, left: distal view of condyles with abnormal medial epicondyle.

Skeleton 459

Tedeschi Register (1911)	
Sex::	<i>M – T.A.</i>
Age:	<i>26 years</i>
Job:	<i>Painter</i>
Date of death:	<i>7th of August, 1889</i>
Cause of death:	<i>Lung tuberculosis</i>
Burial:	<i>Common burial (Bologna)</i>
Bone Remains	
<p><u>Skull:</u> <i>Cranium, lacking of a portion in left parietal bone.</i></p>	
<p><u>Skeleton:</u> <i>Coxale: left, partial</i></p>	
<p><u>Teeth:</u> ---</p>	

The remains recovered are a portion of cranium and of left coxale. They are clean and cranium is white, while the coxale appears darker.

The cranium sutures result almost closed and regular. The cranium's form is strongly brachycephalic, *in situ* there aren't teeth and all molars and premolars were lost *ante mortem* since the bone tissue adsorption is almost completed (Photo 457/1). Only in the left orbit there are some slight sings of *cribra orbitalia*, type "a" by Knip definition (Campillo, 1994a) (Photo 457/2).

The acetabulum demonstrates some defects (lacking inferior part) and its articular surface is slight granular (Photo 457/3).

Even if the bones are few, we can note that the remains present some marks of stress, as the losing of many teeth for the young age of the individual and the inflammation reaction on the acetabular surface that could agree with TB infection, as quoted by Tedeschi.

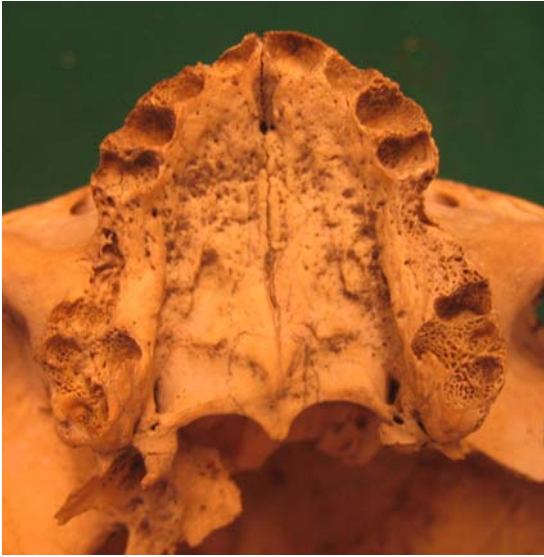

Photo 459/1
Maxilla: total bone tissue adsorption
for numerous lost teeth.

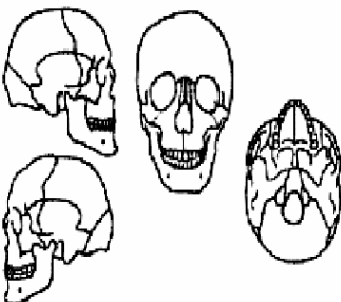
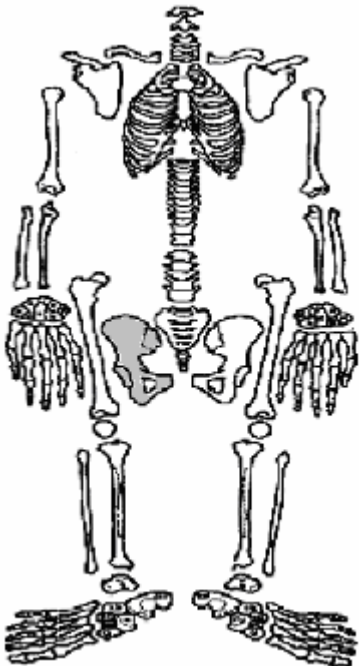
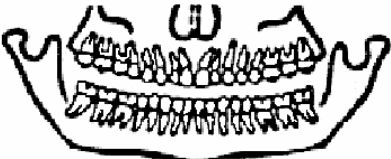


Photo 459/2
Orbit, left: slight *cribria*
orbitalia



Photo 459/3
Acetabulum: articular
surface appears
granular and damaged.

Skeleton 461

Tedeschi Register (1911)	
Sex::	<i>M – P. C.</i>
Age:	<i>36 years</i>
Job:	<i>Employee</i>
Date of death:	<i>5th of June, 1889</i>
Cause of death:	<i>Lung tuberculosis</i>
Burial:	<i>Common burial (Bologna)</i>
Bone Remains	
<u>Skull:</u> ---	
<u>Skeleton:</u> <i>Coxal: right</i>	
<u>Teeth:</u> ---	

The individual 461 is presented by only right os coxale, generally in a good state of preservation and brown colour.

The bone presents an inflammatory reaction in the acetabular fossa, where the tissue is strongly granular (Photo 461/1). Apposition of new bone tissue is notable also in the iliopubic ramus (around acetabular fossa) and in the ischiopubic ramus (Photo 461/2 and Photo 461/3).

There aren't other pathological signs.

In the acetabular fossa, the rims of the inflammatory are clear, but, unfortunately, the femur has been lost. Although the inflammatory reaction is visible, the remains aren't enough to define a cause of death (TB is possible).



Photo 461/1

Coxal, right: acetabular fossa appears granular and remodelling new bone tissue (arrow).



Photo 461/2

Coxal, right: iliopubic ramus, note the inflammation react and new bone tissue.


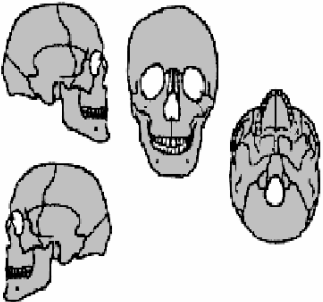
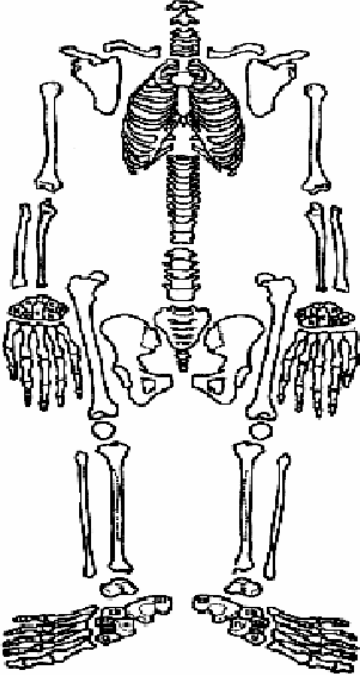
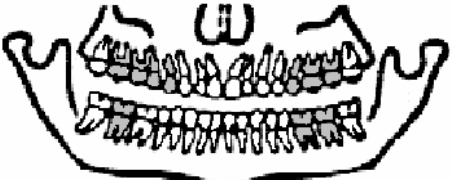


Photo 461/3

Coxal, right: ischiopubic ramus, note the modifications of the tissue.

Skeleton 462

Tedeschi Register (1912)	
Sex::	<i>M – N. G.</i>
Age:	<i>20 years</i>
Job:	<i>Student</i>
Date of death:	<i>20th of August, 1989</i>
Cause of death:	<i>Lung tuberculosis</i>
Origin:	<i>Common burial (Bologna)</i>
Bone Remains	
<p><u>Skull:</u> <i>Cranium with mandible</i></p>	
<p><u>Skeleton:</u> ---</p>	
<p><u>Teeth:</u> <i>Upper: right arch, 1st and 2nd premolars, 1st and 2nd molars; left arch, 2nd premolars, 1st and 2nd molars. Lower: 2nd right molar and 1st and 2nd left molars.</i></p>	

The skull is the only remain of individual 462 and it is clean and in a good state of preservation.

In jaw the teeth *in situ* are 4 molars and 3 premolars, all of them appear without attrition wear that confirms young age at death, but with calculus and dental caries. In the mandible, at right arch there is the 2nd molar (the 1st and the 3rd are lost *ante mortem*), while in the left arch 1st and 2nd molars are *in situ*, the 2nd premolar was lost *ante mortem* and the 3rd molar was ready to erupt (Photo 462/1 and Photo 462/2).

The young age at death is confirmed by the cranial sutures that are open. There are some small wormian bones and in the posterior parietal bone an osteoma is visible (Photo 462/3 and Photo 462/4).

In the vault of cranium, in the frontal and parietal bones, there are some signs: the external surface of diploe appears lacking, as being scratched. The lacking tissue is superficial and the entire structure is perfect (Photo 462/4 and Photo 462/5).

There aren't particular signs that suggest pathology. The cranial signs could be compared with the similar signs in skulls of individual 455 and individual 456, although in the present case they appear slighter and less. In the others cases, the markers were stronger and together with possible signs of syphilis, that are lacking in the present individual. The cause of these types of markers could be by taphonomic processes due to the burial in soil, even if the deposition seems to be lasting only about 1 year.

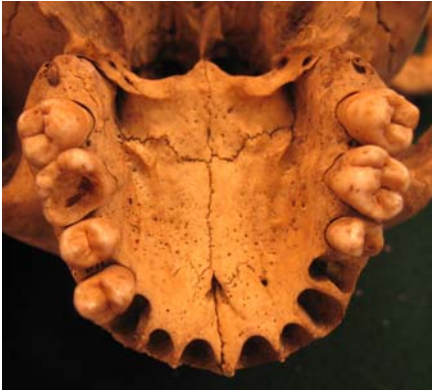

Photo 462/1
Jaw: note the teeth *in situ* all with no signs of wear.

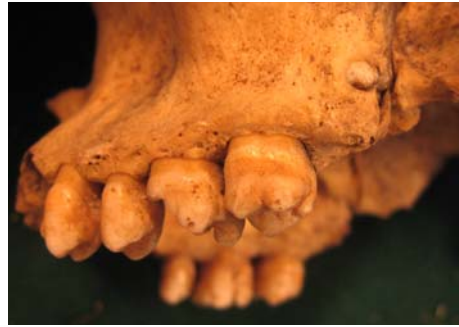

Photo 462/2
Jaw: left 3rd molar is visible underlying the bone tissue.

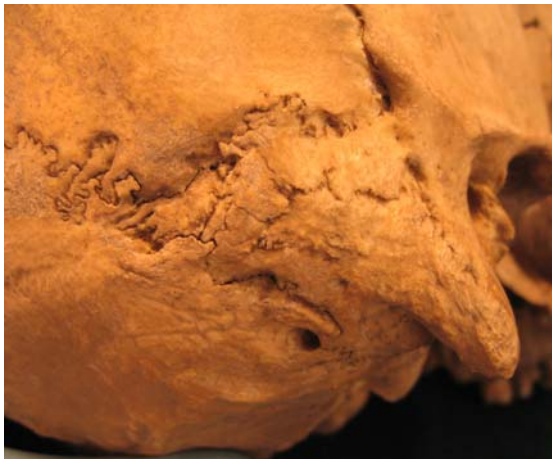

Photo 462/3
Mastoid process: note the wormian bones.

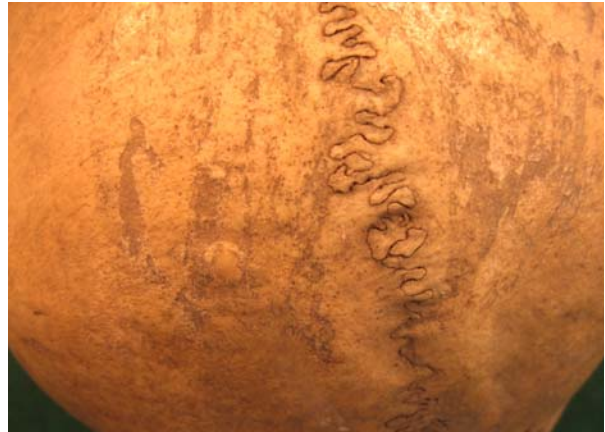

Photo 462/4
Parietal bones: osteoma is visible on the left bone and the vault appears scratched.


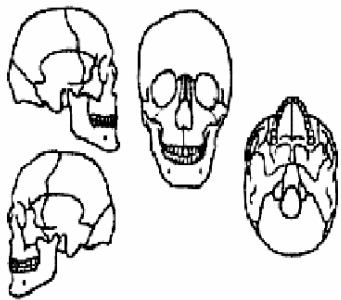
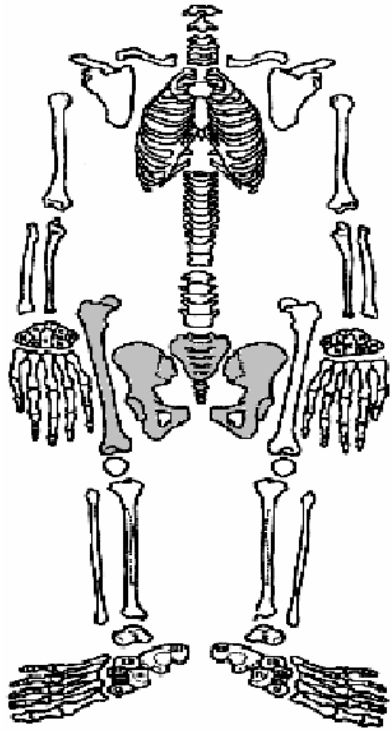
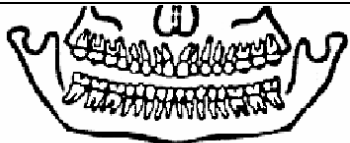


Photo 462/5
Cranial vault: the external diploe is damaged and some lacking areas are notable (arrows).

Skeleton 468

Tedeschi Register (1911)	
Sex::	<i>M – G. G.</i>
Age:	<i>33 years</i>
Job:	<i>Employer</i>
Date of death:	<i>24th of August, 1889</i>
Cause of death:	<i>Lung tuberculosis</i>
Burial:	<i>Common burial (Bologna)</i>
Bone Remains	
<u>Skull:</u> ---	
<u>Skeleton:</u> Sacrum Innominate: right and left Femur: right	
<u>Teeth:</u> ---	

The remains of individual 468 are in a general good state of preservation and light brown colored.

The pelvis is complete; there are the sacrum and both innominates. The sacrum presents the incomplete sacralization of the coccyx (Photo 468/1 and Photo 468/2), although the sacral foramina are in the normal number of 4 per side. The further vertebra is one, since the transverse lines are 5, 4 for the normal sacrum and 1 for the added element. In the posterior view of the sacrum bone, the median spine is notable: it is fused only partially (Photo 468/3).

The femur neck presents two well defined areas with external compact bone tissue damaged and absorbed (Photo 468/4). A big eroded area with underlying trabeculae is detectible (Allen's fossa) and a plaque formation is above and surround the fossa.

Aufderheide & Rodríguez-Martín (1998) report that the sacralization of the coccyx is a common malformation and this non pathological characteristic seem to be more frequent in males than females.

The modified areas in the neck of femur correspond to Allen's fossa, that is the first marker formed by atrophy of the bone while under stress, but as stress decreases or stops, the resultant hypertrophy forms a plaque. Allen's Fossa is defined as vary from a small depression to a large eroded area 1 cm² where cortical bone has been lost exposing underlying trabeculae. The border of this fossa may have a ridge or thickening around it, reminiscent of an inflammatory response (Finnegan, 1978).

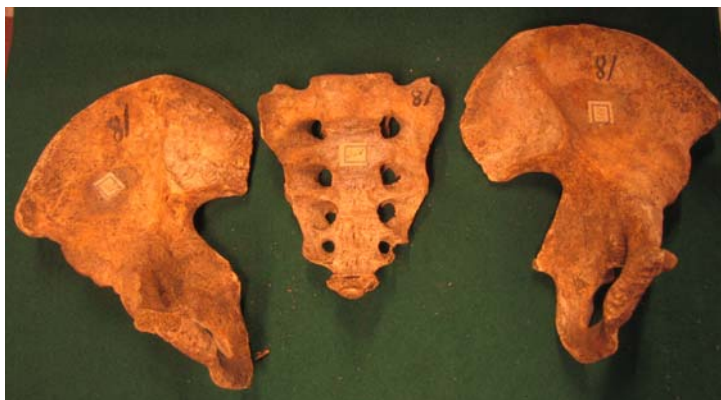

Photo 468/1

Pelvis: the innominates and the sacrum with the sacralization of the coccyx.



Photo 468/2 and Photo 468/3

Sacrum: frontal and posterior view: the sacralization of the coccyx is detectible, with the partial non fusion of the dorsal walls in the medial crest.

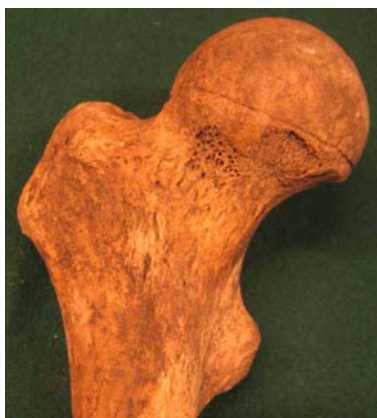

Photo 468/4

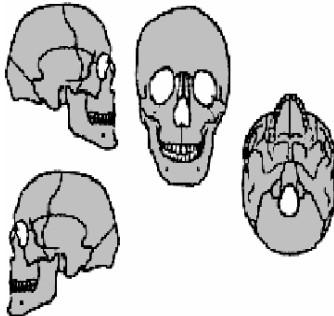
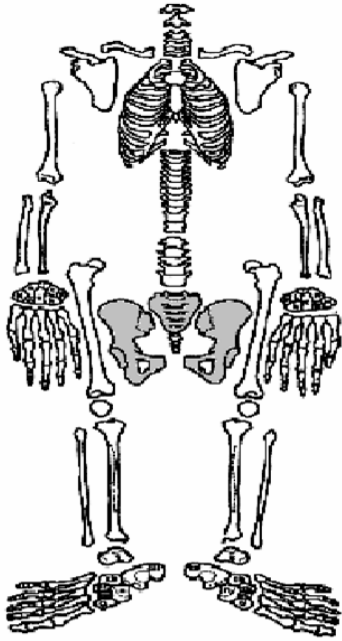
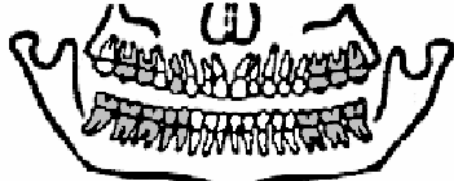
Femur, right: not e the presence of the Allen's fossa with a plague.



Photo 468/5

Femur, right: particular of the Allen's fossa and the plague with the trabecular tissue exposed.

Skeleton 470

Tedeschi Register (1912)	
Sex::	<i>F – A. B.</i>
Age:	<i>18 years</i>
Job:	<i>Home worker</i>
Date of death:	<i>13th of June 1889</i>
Cause of death:	<i>Tuberculosis</i>
Origin:	<i>Common burial (Bologna)</i>
Bone Remains	
<p><u>Skull:</u> <i>Cranium complete with mandible</i></p>	
<p><u>Skeleton:</u> <i>Sacrum elements</i> <i>Coxal: right and left</i></p>	
<p><u>Teeth:</u> <i>Upper: right arch, 3 molars, left arch 2nd pre-molars and 1st and 2nd molars. Lower: all molars and 1st and 2nd pre-molars at right arch.</i></p>	

The skull is composed by the cranium and the mandible. The skeleton consists just in coxale and some sacrum elements.

The skull is almost white and clean, the other bones are of brown colour.

In situ there are all molars, except the 3rd molar upper right: they are in good state of conservation, no tooth seems lost *ante mortem* and no attrition wear is present. These conditions agree with the young age of individual at time of death, like quoted by Tedeschi. There are evident some exposures of the molars roots without pathological complication, since there are no voids around the root apices (Photo 470/2), except in the left upper 3rd molar, where a discrete apical abscess cavity is present on the root of the tooth (Photo 470/3).

The skull belongs to a young man; in fact the cranial sutures are not closed totally. In both orbits, there are evident signs of *cribra orbitalia* type “c”, according to Knip classification (1971, cited by Campillo, 1994a) (Photo 470/1).

The sacrum elements appear damaged: there are numerous cavities and porosities, with re-modeling osseous tissue. Especially in the joint connection with ileum, the surface is really damaged. However, the surface show clear signs of periostitis (Photo 470/4).

Both coxal elements show clear signs of dislocation of hips: there are 2 new acetabular fossae (called *false acetabulum*) above the anatomical ones. In all notches, the surfaces of bone tissue are damaged and consumed by the common rubbing of the surfaces of femoral head and acetabulum (Photo 470/5 and Photo 470/6). In the inferior two new fossae, the bone tissue is extremely worn. The lunate surface of acetabulum is flattening and elongating in both sides, such as the heads of femuri shouldn't have the real supports that occurs (Photo 470/7).

Unfortunately, there are not femuri to compare the heads and to understand the cause of dislocations, that, as Aufderheide and Rodríguez-Martin (1998) remember, can be caused by 3 malformations: 1) acetabulum (aplasia of the lunate surface), 2) femoral head and neck (ossification development of the

femoral head is delayed) or 3) pelvis (its development is impaired or assumed a vertical position in bilateral position).

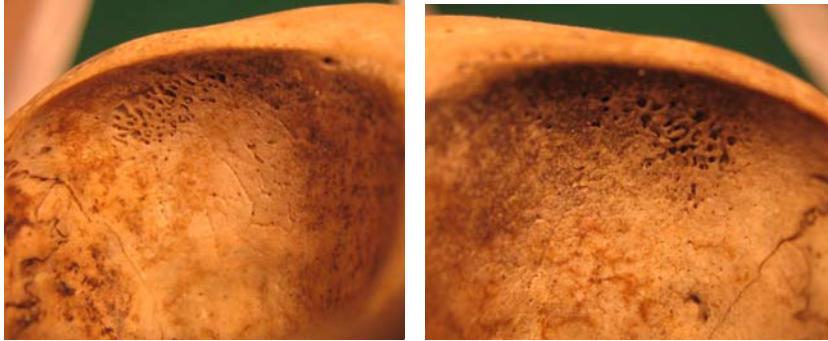


Photo 470/1

Orbits: evident signs of *cribra orbitalia* in the right and in the left vault.

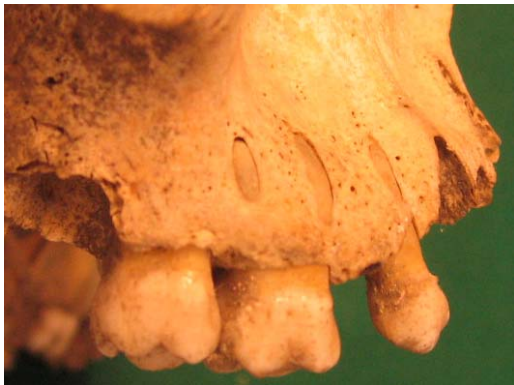

Photo 470/2

Buccal view of right molars with evident exposures, without pathology. Numerous porosities are present in the bone.

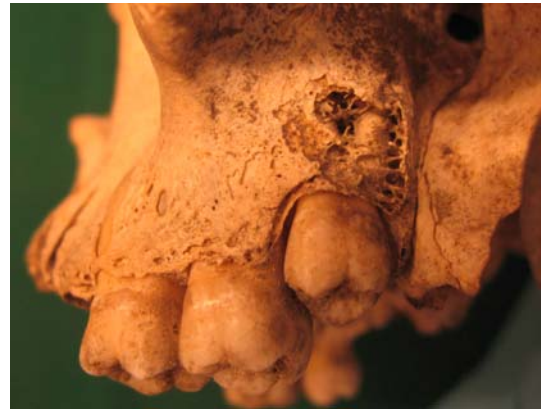

Photo 470/3

Upper 3rd molar (left arch): abscess cavity with exposure of root and the bone tissue presents many signs of suffering.



Photo 470/5

Surface with signs of periostitis and remodeling bone tissue.

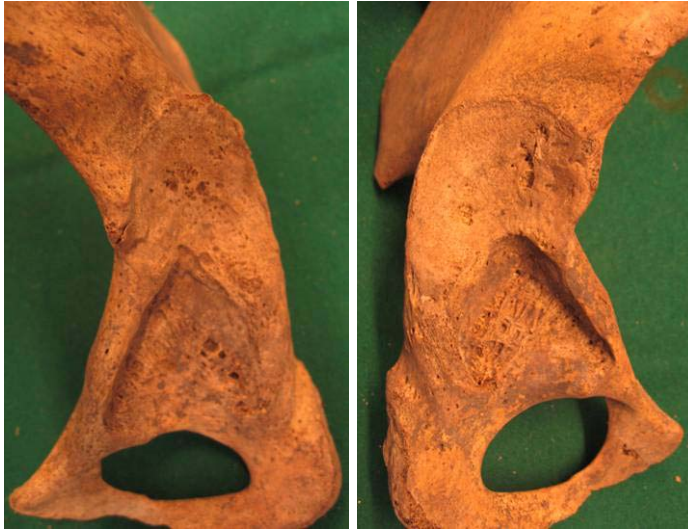

Photo 470/5

General view of left and right coxal: in both cases, the 2 acetabular fossae, the old and the new one, are evident.



Photo 470/6

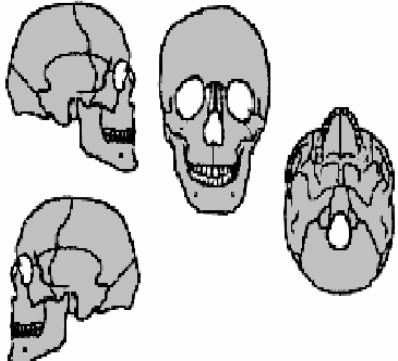
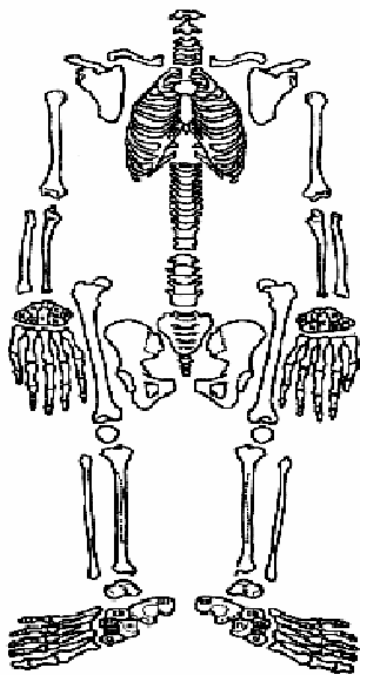
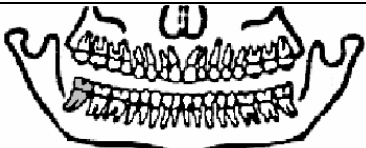
Left coxal: particular of the worn tissue of the new acetabular fossae build after the dislocation of hip. the structure is such as if the head of the femur had slipped progressively.

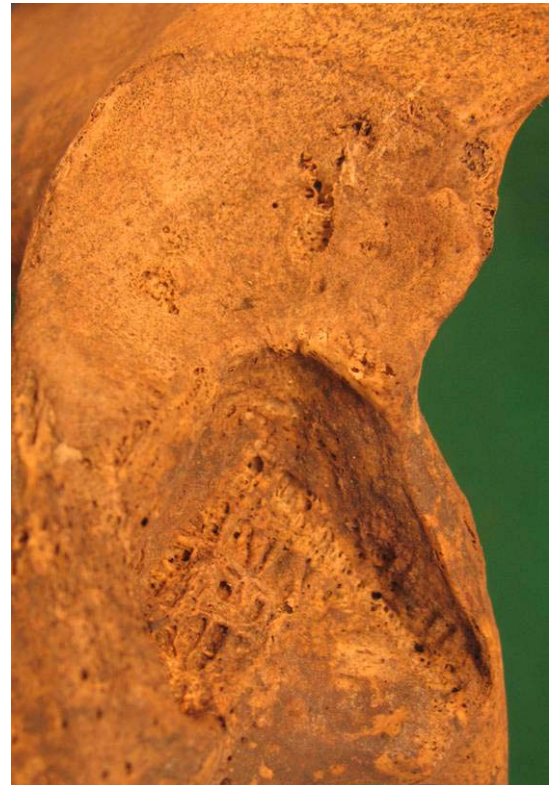

Photo 470/7

Right coxal: particular of the bone tissue of the two acetabular fossae. Also in this case, the tissue of the second acetabulum appears more worn.

Skeleton 594

Tedeschi Register (1911)	
Sex::	<i>M – D. L. D.</i>
Age:	<i>42 years</i>
Job:	<i>Porter</i>
Date of death:	<i>1906</i>
Cause of death:	<i>Lung tuberculosis</i>
Origin:	<i>General hospital (Padova)</i>
Bone Remains:	
<p><u>Skull:</u> <i>Cranium with mandible.</i></p>	
<p><u>Skeleton:</u> ---</p>	
<p><u>Teeth:</u> <i>Lower: right arch, 3rd molar.</i></p>	

The individual 594 remain is the skull, white, clean and in a general good state of preservation.

In situ there are no teeth and many of them have been lost *ante mortem* since in various cases the alveolar adsorptions are complete, as for example in premolars alveolars in yaw or in molars alveolars in mandible (Photo 594/1 and Photo 594/2). In the left palatine bone, there is visible the root of an extra tooth (Photo 594/3).

A slight adsorption of nasal hole could suggest that the individual 594 suffered by *lupus vulgaris* (Photo 594/4).

The lupus vulgaris is a pathology characteristic of young age, before 20 years old, and it persists throughout life as Roberts and Buikstra (2003) remember. Lupus vulgaris is a TB of soft tissue, especially in the nose, cheeks, brow and neck regions.



Photo 594/1
Yaw: note the teeth lost *ante mortem* with a total alveolar adsorption in many cases.

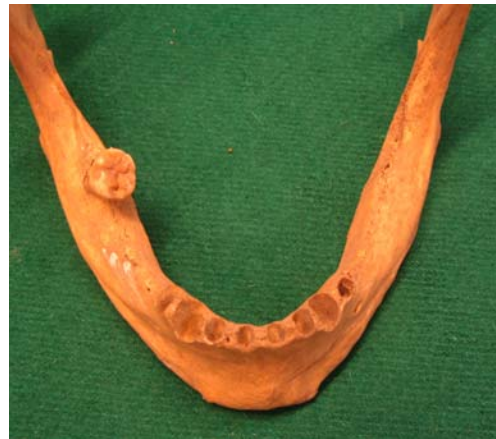

Photo 594/2
Mandible: note the adsorption in all premolars and molars teeth.

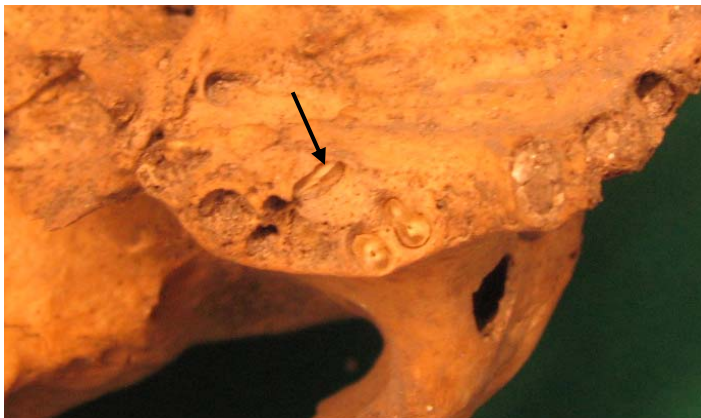

Photo 594/3
Yaw: left arch, note root of extra teeth in maxilla bone (arrow).

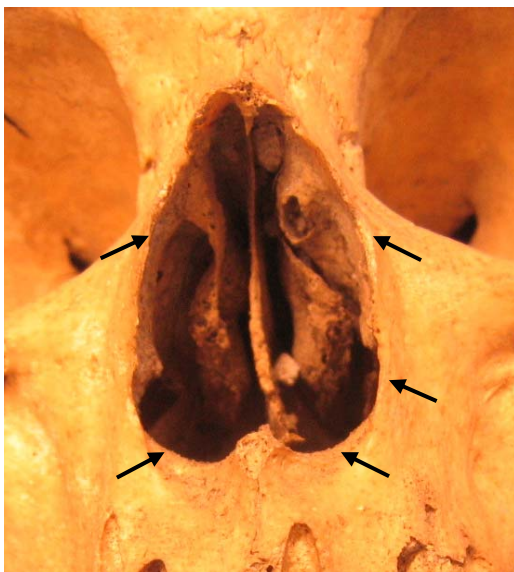


Photo 594/4
Nasal region: note a very slight adsorption of the rim of the nasal hole (arrows).

