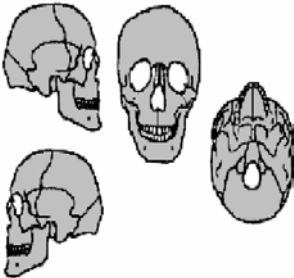
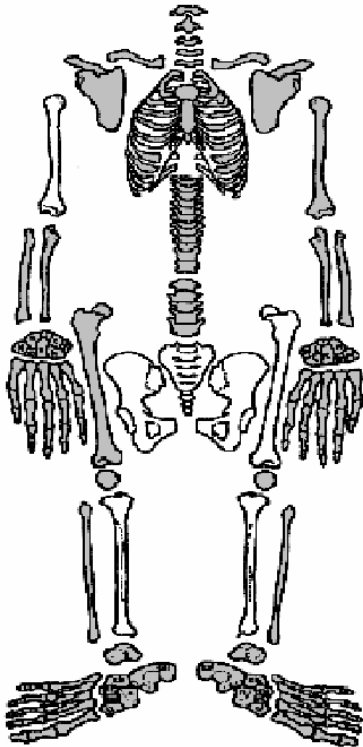
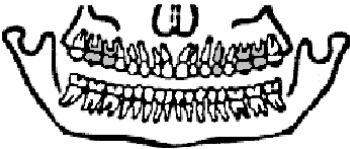


## Skeleton 1438

Tedeschi Register (1911)	
Sex::	M- S. A.
Age:	31 years
Job:	Blacksmith
Date of death:	9 <sup>th</sup> of February, 1911
Cause of death:	Lung tuberculosis
Origin:	General Hospital (Padova)
Bone Remains	
<p><u>Skull:</u> Cranium with mandible</p>	
<p><u>Skeleton:</u> Spine: complete Sternum: manubrium and body Ribs Scapulae: right and left Clavicles: right and left Humeri: left Radii: right and left Ulnae: right and left Hands: complete, right and left Femuri: right Patellae: right and left Fibule: right and left Feet: complete, right and left</p>	
<p><u>Teeth:</u> Upper: right arch, 1<sup>st</sup> and 2<sup>nd</sup> molars; left arch, 1<sup>st</sup> premolar, 1<sup>st</sup> and 2<sup>nd</sup> molars.</p>	

The individual 1438 is almost complete, all bones are white and in a general good state of preservation.

*In situ* the teeth are 5 (4 molars and 1 premolar) in the upper jaw. In the mandible, there are no teeth. In the maxilla the complete right arch is filled by 6 teeth instead of the normal 7 teeth (Photo 1438/1) and the space for the 3<sup>rd</sup> molar does not seem enough in both arches to complete the 8 correct number of teeth for arch. The right 2<sup>nd</sup> incisive seems totally absent.

The cranial sutures are closed but still now evident, confirming the age of individual. In the right orbital vault there is evident *cribra orbitalia* (Photo 1438/2), that seems agrees on type “c” by Knip description (Campillo, 1994a).

The spine is complete: the vertebral bodies show hypervascularization and osteophytes with deposits of bone tissue (Photo 1438/3). Cervical vertebra number 5 has transverse foramen bipartite. Thoracic vertebrae have also osteophytes in the external rims (especially T11 and T12).

The ribs have deposits of bone tissue in the rims.

The left humerus shows olecranial foramen, that is a non pathological epigenetic characteristic.

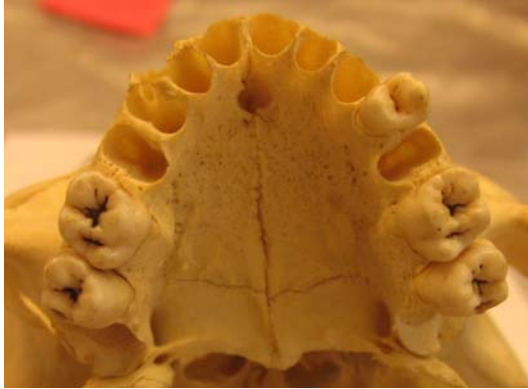The femur presents signs of stress with porosity in the epiphysis with attrition wear in the *Allen's fossa* and the tendon insertions are evident along diaphysis. Generally, the long bones discloses remodelling bone tissue in both epiphysis.

The tarsal and carpal bones have evident signs of microporosity in the epiphysis with wear affecting numerous areas.


PCR: negative

*Allen's fossa is the first marker formed by atrophy of the bone while under stress, but as stress decreases or stops, the resultant hypertrophy is called plaque. Allen's Fossa is defined from a small depression to a large eroded area 1 cm<sup>2</sup> where cortical bone has been lost exposing underlying trabeculae. The border of this fossa may have a ridge or thickening around it, reminiscent of an inflammatory response (Finnegan, 1978).*

*The general markers present in the remains concord with a pathology as TB, even though none of these prints are peculiar.*



**Photo 1438/1**



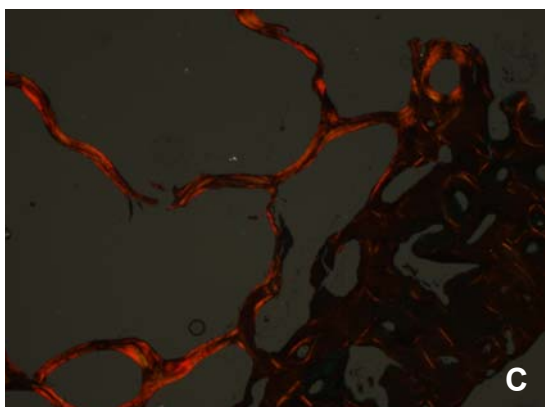
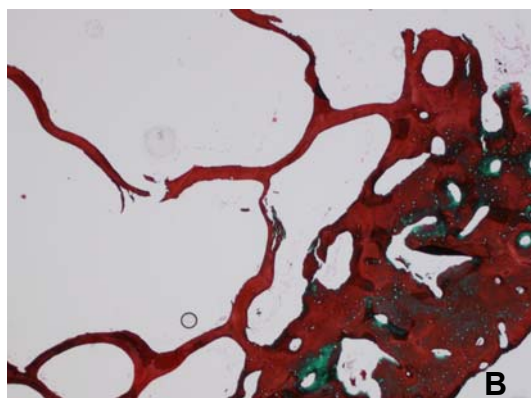
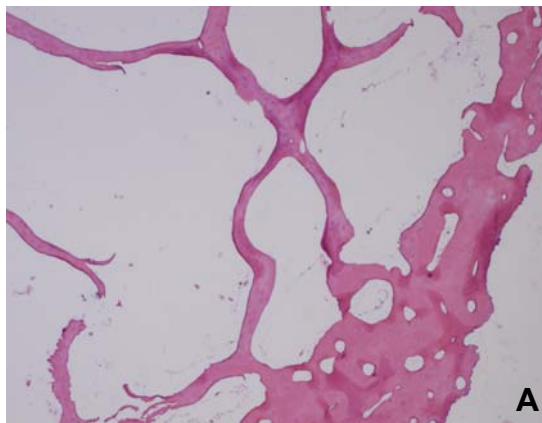
**Photo 1438/2**

Orbital vault: note the cribra orbitalia in the right orbital vault, type “b” by Knip.



**Photo 1438/3**

Spine: note the osteophytic nails in the rims.



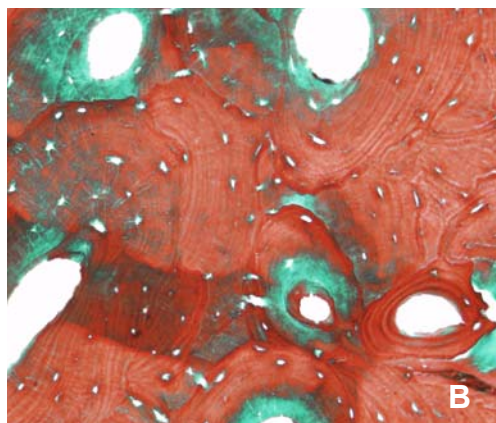
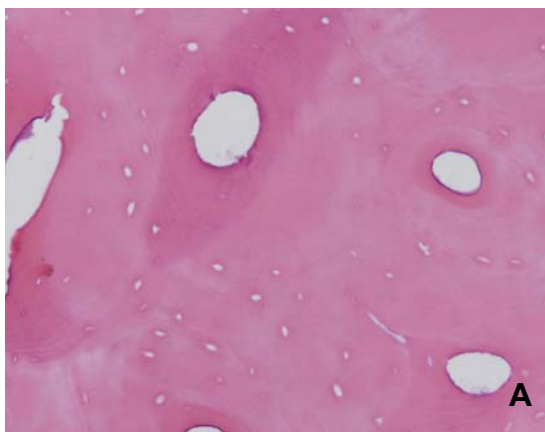
**Photo 1438 H1**

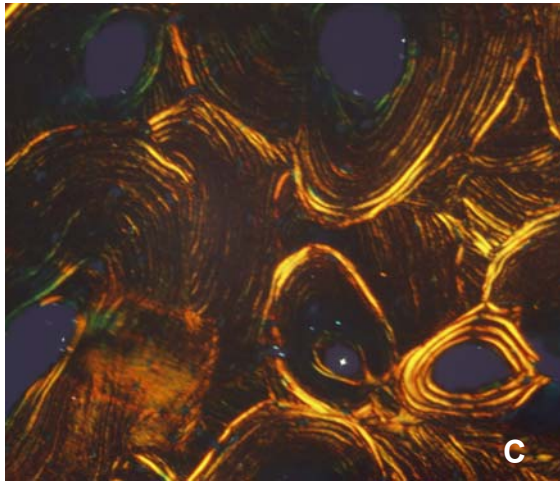
Histological section of rib, in which the rare trabeculae and the empty osteons are detectable.

A: Heamatoxylin-Eosin, original magnification 25X;

B: Masson Tricromic stain, original magnification 25X;

C: Masson Tricromic stain at polarized light, original magnification 25X.





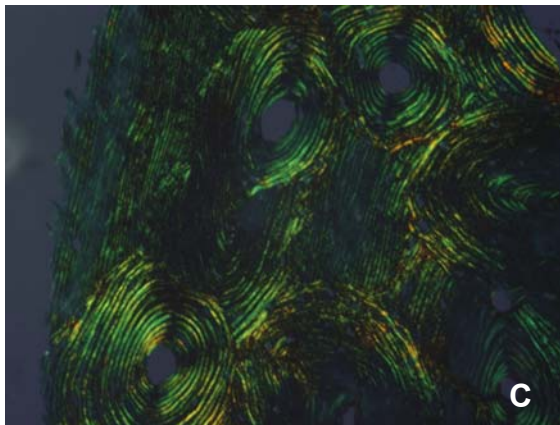
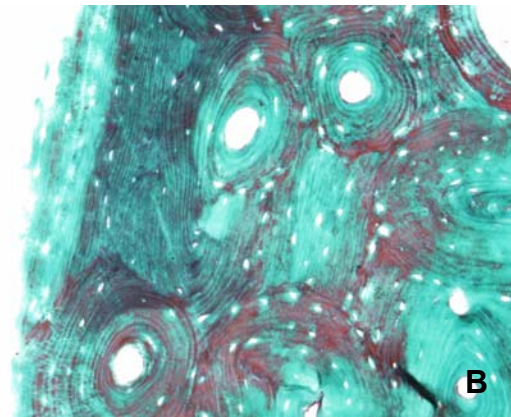
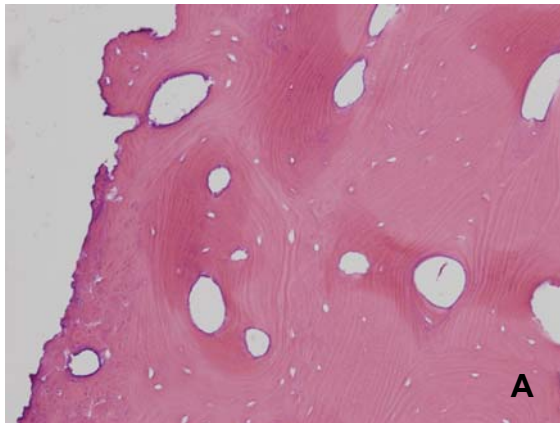
**Photo 1438 H2**

Close-up of 1438 H1. The remodelling lamellae are detectible, the different layers of lamellae are clearly visible.

A: Heamatoxylin-Eosin, original magnification 125X;

B: Masson Tricromic stain, original magnification 125X;

C: Masson Tricromic stain at polarized light, original magnification 125X.



**Photo 1438 H3**

Histological section of femur. The remodelling lamellae are detectible, with the new in tissue in the external rim.

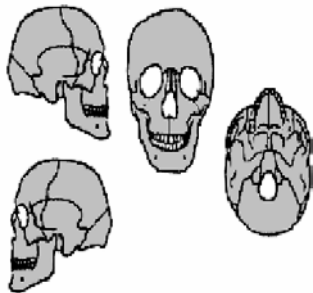
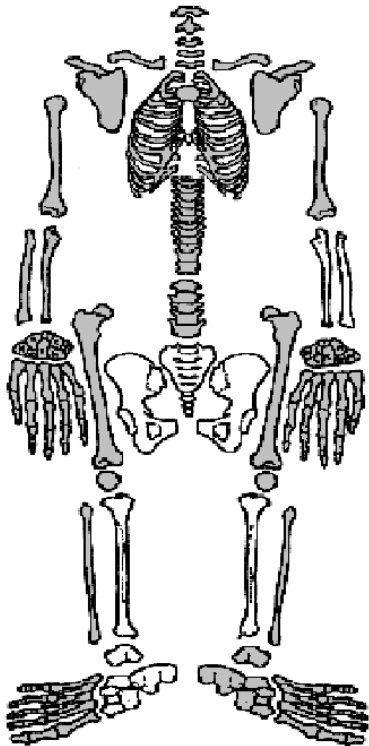
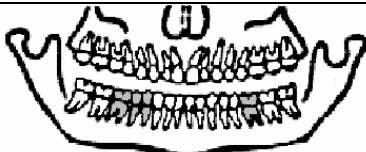
A: Heamatoxylin-Eosin, original magnification 125X;

B: Masson Tricromic stain, original magnification 125X;

C: Masson Tricromic stain at polarized light, original magnification 125X.



## Skeleton 1439

Tedeschi Register (1911)	
Sex::	<i>M- P. E.</i>
Age:	<i>35 years</i>
Job:	<i>Umbrella maker</i>
Date of death:	<i>23<sup>rd</sup> of May, 1911</i>
Cause of death:	<i>General tuberculosis</i>
Origin:	<i>Prison (Padova)</i>
Bone Remains	
<p><u>Skull:</u> <i>Cranium with mandible</i></p>	
<p><u>Skeleton:</u> <i>Spine: complete</i> <i>Sternum: manubrium</i> <i>Ribs</i> <i>Scapulae: right and left</i> <i>Clavicles: right and left</i> <i>Humeri: right and left</i> <i>Radius: right</i> <i>Ulna: right</i> <i>Hands: complete, right and left</i> <i>Femuri: right and left</i> <i>Fibulae: right and left</i> <i>Feet: complete, right and left</i></p>	
<p><u>Teeth:</u> <i>Lower: right arch, 1<sup>st</sup> and 2<sup>nd</sup> premolars and 1<sup>st</sup> molar; left arch 1<sup>st</sup> molar.</i></p>	

The individual 1439 is almost complete and the bones are clean and in a good state of preservation.

*In situ* the teeth are only in the mandible: 2 premolars and 2 molars. In the jaw there aren't teeth *in situ* and the adsorption in the dental alveolars appears in an advanced stage (Photo 1439/1). Also in the mandible there is the adsorption due to teeth lost *ante mortem*. The left molar has a stage of attrition wear more advanced than the right teeth (Photo 1439/2): according to Murphy's occlusal attrition at 8 stage (Hillson, 1996), the left molar can be classified at 7<sup>th</sup> stage, while the right molar at 4<sup>th</sup> stage (Photo 1439/3).

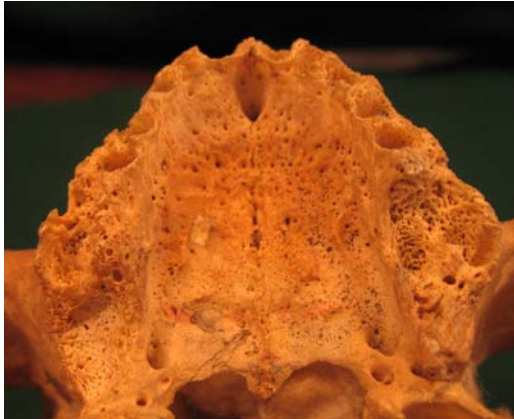
The cranium is complete with a sign of a trauma in the right parietal bone (Photo 1439/4).

The spine is complete with numerous signs of inflammatory reaction. C4 and C5 show bipartite foramen transverse. The bodies of thoracic vertebrae are damaged and the external rims are crushed, especially T5, T6, T7 and T8. An analogue situation is present in lumbar vertebrae, L2 and L5.

The long bones have signs of remodelling bone tissue: the femurs' neck and head are damaged and changed (Photo 1439/5 and Photo 1439/6). Along diaphysis the signs of periostitis are visible (Photo 1439/7).

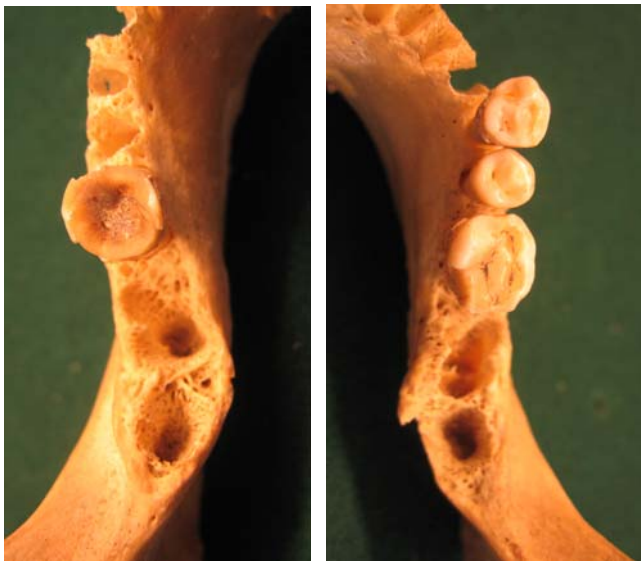
*In the bone remains, the sings agree with an infectious disease like tuberculosis, although there aren't peculiar and unique marks.*





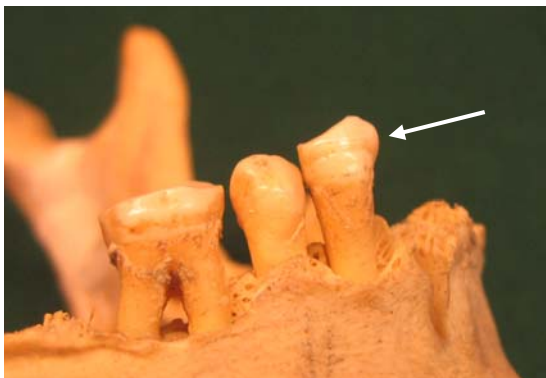**Photo 1439/1**

Jaw: no teeth in situ and all molars and premolars are lost *ante mortem*, the adsorption is almost complete in numerous alveolars. The extremely pitting up of palatine bones suggests that the individual could suffer of a dental pathology.



**Photo 1439/2**

Mandible: left and right arches. Note the major wear of left molar than the right one.



**Photo 1439/3**

Mandible, lateral view: note the calculus and the dental hipoplasia (arrow).




**Photo 1439/4**

Cranium, parietal bone: note the trauma.



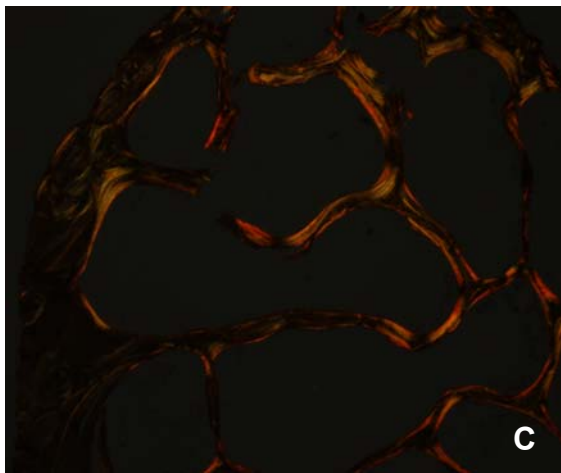
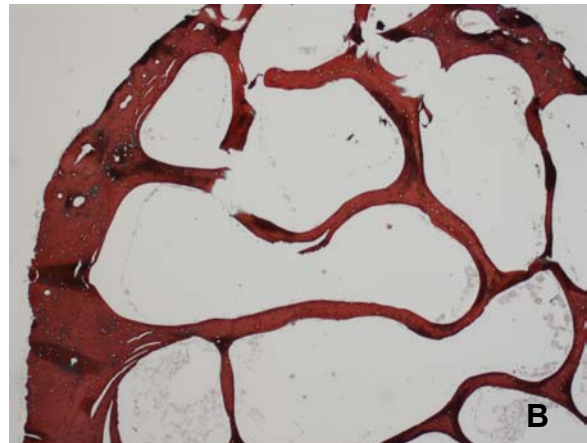
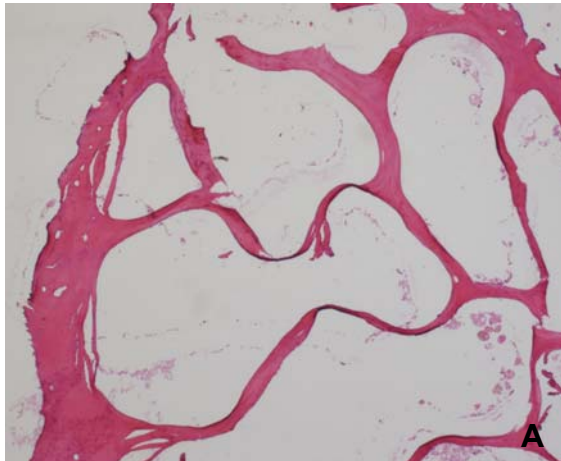
**Photo 1439/5**  
Femur: the neck and the head are damaged.



**Photo 1439/8**  
Femur, detail: the bone tissue is remodelled and pitting up.



**Photo 1439/9**  
Femur, detail: the diaphysis present signs of periostitis.



**Photo 1439 H1**

Histological section of rib. The empty lacunae and rare trabeculae are visible.

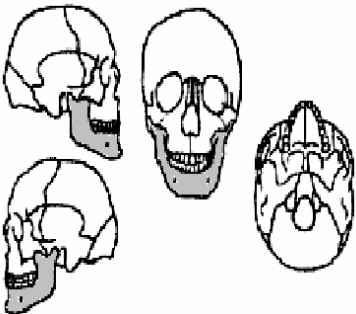
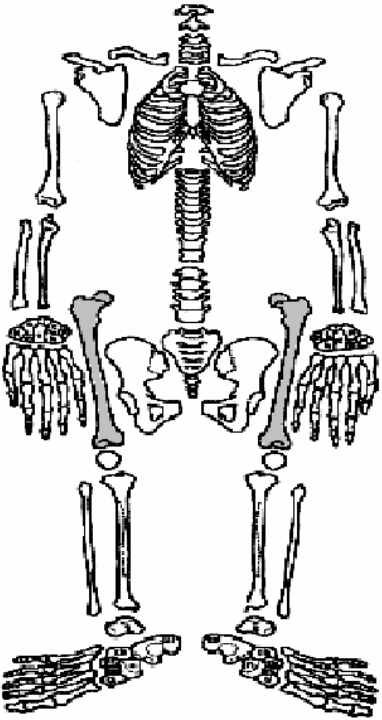
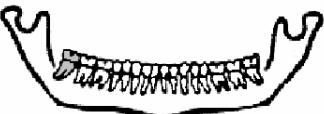
A: Haematoxylin-Eosin, original magnification 25X;

B: Masson Tricromic stain, original magnification 25X;

C: Masson Tricromic stain at polarized light, original magnification 25X.



### Skeleton 1440

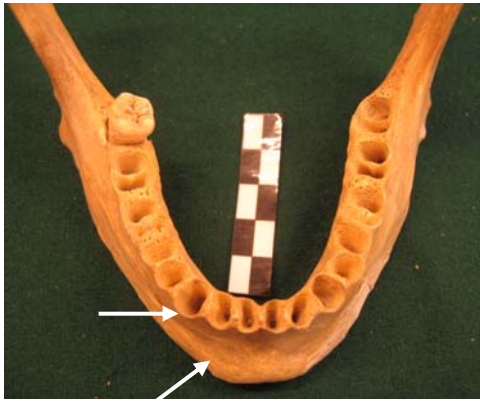
Tedeschi Register (1911)	
Sex::	<i>M – S. U.</i>
Age:	<i>31 years</i>
Job:	<i>Postman</i>
Date of death:	<i>1911</i>
Cause of death:	<i>Lung tuberculosis</i>
Origin:	<i>Prison (Padova)</i>
Bone Remains	
<u>Skull:</u> <i>Mandible</i>	
<u>Skeleton:</u> <i>Femurs: right and left</i>	
<u>Teeth:</u> <i>Mandible: right 3<sup>rd</sup> molar.</i>	

The individual 1440 remains are composed by the mandible and both femuri. All these 3 elements are in good state of preservation, white and clean.

*In situ* there is only the 3<sup>rd</sup> molar in right arch, in which no signs of wear attrition are evident. No teeth seem lost *ante mortem*, although some dental alveolars have signs of inflammation (Photo 1440/1).

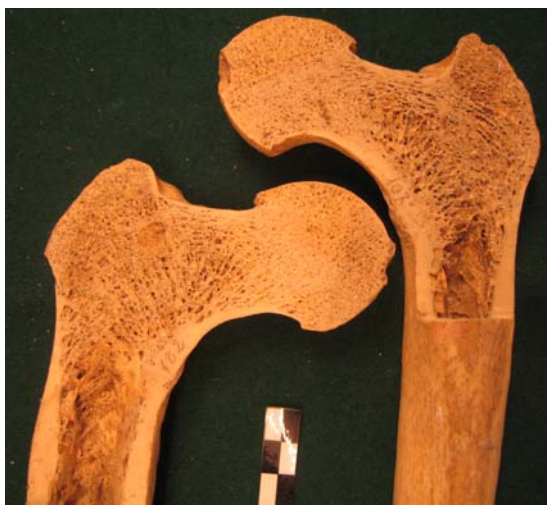Both femurs have heads cut in longitudinal length: the internal structure is visible and the trabecular tissue appears normal (Photo 1440/2). The same situation occurs to distal epiphysis of the right femur (Photo 1440/3). The removed portions haven't been recovered. In the anterior view of the proximal epiphysis, some thick tissues are notable near intertrochanteric lines in a almost symmetrical position (Photo 1440/4 and Photo 1440/5). These elements are defined plaque by Finnegan (1978).

*There aren't peculiar pathological signs that could suggest a disease and the elements recovered aren't enough to define a particular cause of death. Finnegan (1978) defines that "the plaque formation is scored as present when as overgrowth or bone scar can be defined extending from the area of Poirier's facet on the femoral head down on to the femoral neck where it often surrounds or covers Allen's fossa" and it is caused by walking and running (Capasso, 1999).*



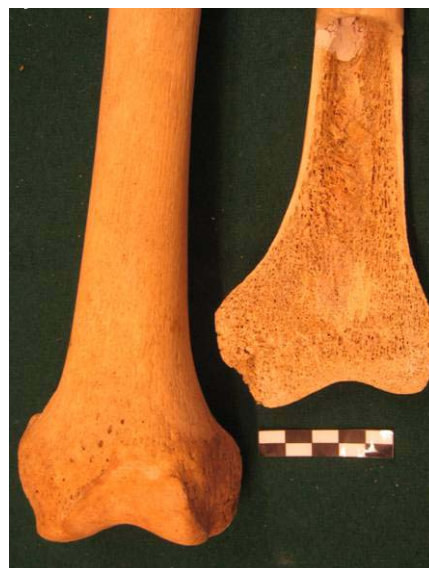**Photo 1440/1**

Mandible: a slight inflammation react is notable in premolars and molar roots (arrows).



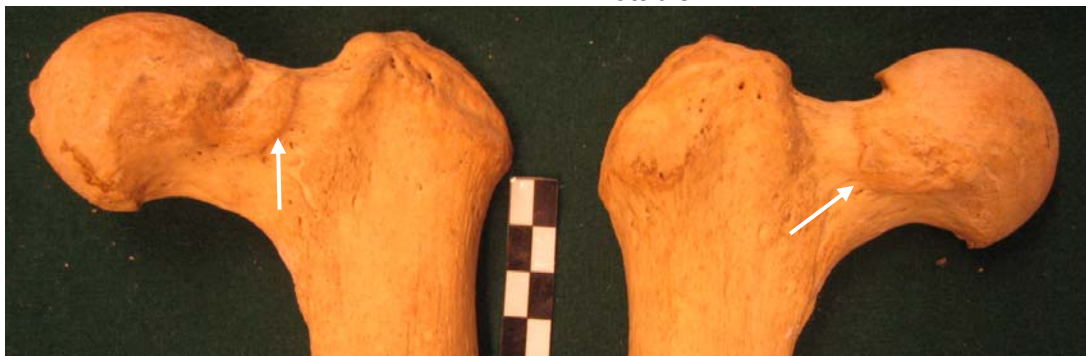**Photo 1440/2**

Femurs, heads: internal structure of bones is visible (epiphyseal line, spongy bone and medullary cavity).



**Photo 1440/3**

Femurs, distal epiphysis: the right epiphysis is cut in longitudinal length and the internal spongy tissue is notable.



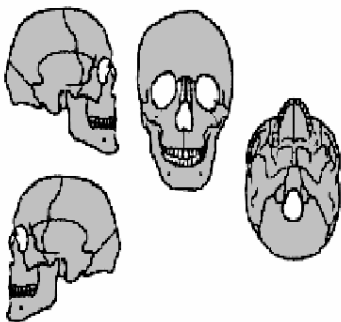
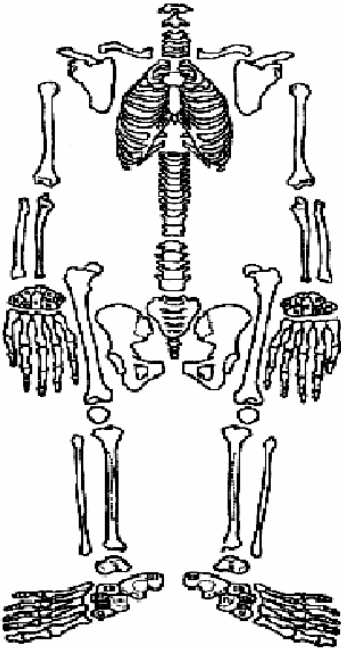
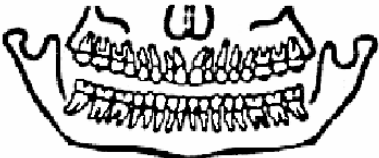
**Photo 1440/4**

Femuri: note the plaque formation (arrows) that are extremely defined although they have a different shape.





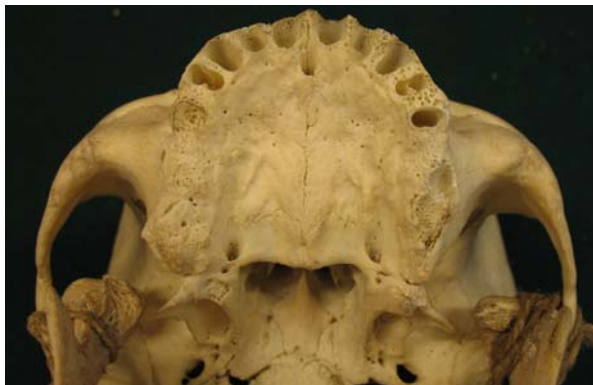### Skeleton 1448

Tedeschi Register (1912)	
Sex::	M – R. G.
Age:	42 years
Job:	Horse carriage driver
Date of death:	1911
Cause of death:	Lung tuberculosis
Origin:	General Hospital (Padova)
Bone Remains	
<u>Skull:</u> Cranium with mandible	
<u>Skeleton:</u> ---	
<u>Teeth:</u> ---	

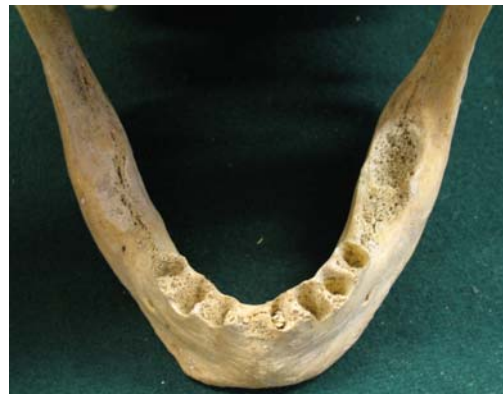The individual 1448 is composed only by the skull (cranium and mandible) and it is white and in good state of preservation.

There are no teeth *in situ*, the dental alveolars of molars and premolars present an advanced state of adsorption both in mandible and in jaw. (Photo 1448/1 and Photo 1448/2). All dental alveolars present a pitting up surface, as a reaction of a general inflammation.

*The individual don't present any pathological sign that could suggest the cause of death.*

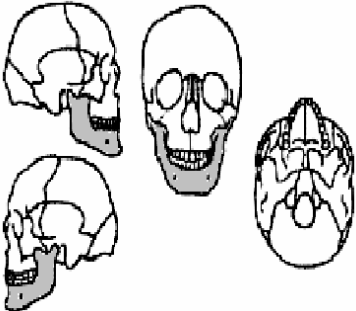
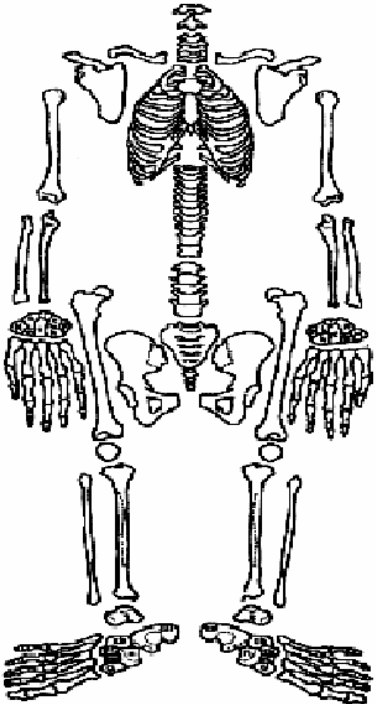
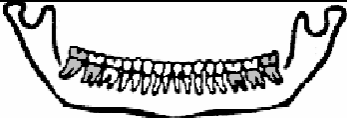


**Photo 1448/1**  
Jaw: note the adsorption of bone tissue in the dental alveolars.



**Photo 1448/2**  
Mandible: note the adsorption of molar and premolar alveolars

### Skeleton 1454

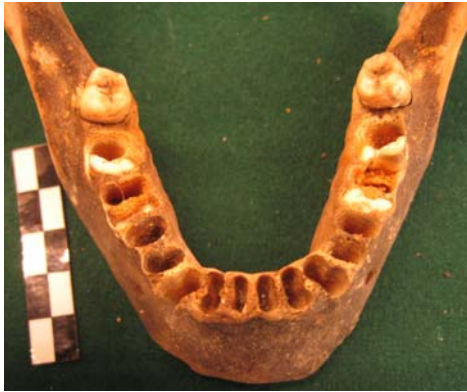Tedeschi Register (1911)	
Sex::	<i>M – B. P..</i>
Age:	<i>22 years</i>
Job:	<i>Itinerant</i>
Date of death:	<i>1911</i>
Cause of death:	<i>Lung tuberculosis</i>
Origin:	<i>General Hospital (Padova)</i>
Bone Remains	
<u>Skull:</u> <i>Mandible</i>	
<u>Skeleton:</u> ---	
<u>Teeth:</u> <i>Lower: the two 3<sup>rd</sup> molars.</i>	

The mandible is the only remain of individual 1454, and it is dark with a lot of marks due to the marrow appearing in surface.

*In situ* there are only the two 3<sup>rd</sup> molars and some portions of the roots of several molars. These teeth appear broken recently since the breaking lines are white and clean (Photo 1454/1).

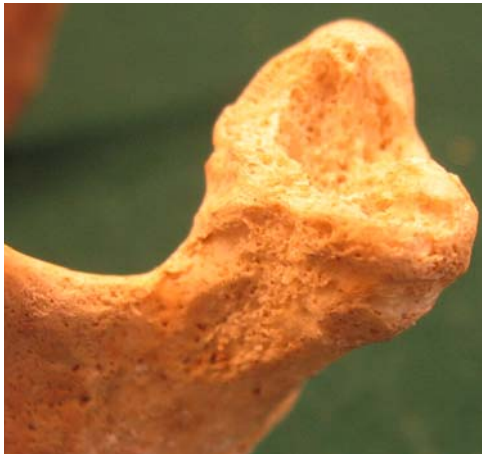The left mandibular condyle is strongly damaged: the surface appears lipping and remodelled with apposition of new bone tissue that is pitting up and rich of very small osteophytes (Photo 1454/2 and Photo 1454/3). The right condyle presents a normal look.

*The temporomandibular joint osteoarthritis may be unilateral (like in individual 1454) or bilateral and can be caused by stress factor as chewing or the use of teeth as power tools (Capasso, 1999). The mandible is too few to define a possible cause of death or a general pathology, although the strong periostitis in the mandibular condyle confirms a state of suffering of the articular element.*



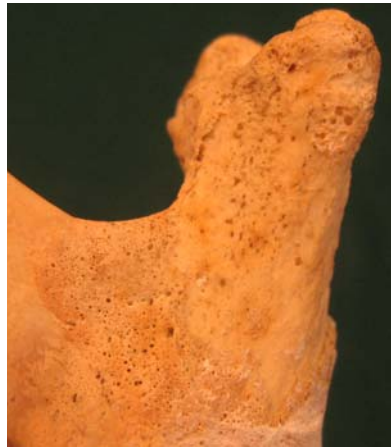**Photo 1454/1**

Mandible: note the humidity marks and the partial roots present in the dental alveolars.



**Photo 1454/2**

Mandibular condyle, left: note the modification of surface, with lacking areas that appear consumed and apposition of new bone tissue.



**Photo 1454/3**

Mandible: the periostitis continues in the ascending ramus from mandibular notch.



**Photo 1454/4**

Mandibular condyle (left) and ramus (right): details of the surfaces note the bone modifications with apposition of tissue and pitting.

