

Imaging the Enthesopathy and Manipulating the Fascia: Ultrasound is the “Sous Chef”

Carmelo Pirri¹ , Carla Stecco¹ , Nina Pirri² , Raffaele De Caro¹ , Levent Özçakar³ 

A 62-year-old man was seen due to pain and limited motions in the right knee for the last 2 weeks. His pain was worse in the morning and during walking. He declared that he had been diagnosed with osteoarthritis 5 years ago and that previous physiotherapy had been only partially effective. The medical history was otherwise noncontributory.

During the physical examination, the superior-lateral edge of the right patella was painful to palpation and the knee motions were also painful and limited (especially during flexion). Using a high-frequency linear probe (6-15 MHz), an ultrasound (US) examination of the knee was performed in accordance with the EURO-MUSCULUS/USPRM basic scanning protocol.¹ Enthesopathy was detected on the patellar insertion of the quadriceps tendon (Figure 1) whereby sono-palpation was painful as well. Power Doppler imaging was unremarkable. While the patient lied in the supine position (with the knee in semi-flexion with a rolled-up towel under the popliteal fossa), dynamic/longitudinal US imaging was further carried out. Based on the clinical and US findings, three sessions of manual therapy (Fascial Manipulation®) and physical therapy were prescribed—for maintaining knee flexibility, restoring fascial tension, and reducing fluid collection and pain. One week after the last session, his complaints improved significantly and the patient could walk without any pain.

In this case, first, we aimed to underscore the role of US imaging (including sono-palpation) in the substantial assessment of entheses, that is, to uncover the exact pain generator as well as to better evaluate the tendon's integrity. This way not only can prompt diagnosis of the patient be established (with an in-depth

ORCID iDs of the authors:

C.P. 0000-0002-0119-6549,
C.S. 0000-0002-8767-4555,
N.P. 0000-0001-7165-3648,
R.D.C. 0000-0002-2307-0277,
L.Ö. 0000-0002-2713-4071.

Cite this article as: Pirri C, Stecco C, Pirri N, De Caro R, Özçakar L. Imaging the enthesopathy and manipulating the fascia: Ultrasound is the “Sous Chef”. *Eur J Rheumatol.* 2022; 10.5152/eurjrheum.2022.22208 [Epub Ahead of Print].

¹ Department of Neurosciences, Institute of Human Anatomy, University of Padova, Padova, Italy

² School of Medicine and Surgery, University of Messina, Messina, Italy

³ Department of Physical and Rehabilitation Medicine, Hacettepe University Medical School Ankara, Turkey

Corresponding author:
Carmelo Pirri
E-mail: carmelop87@hotmail.it

Received: March 28, 2022
Accepted: June 8, 2022
Publication Date: October 19, 2022

Copyright©Author(s) - Available online at
www.eurjrheumatol.org.

Content of this journal is licensed under a Creative Commons Attribution-NonCommercial 4.0 International License.

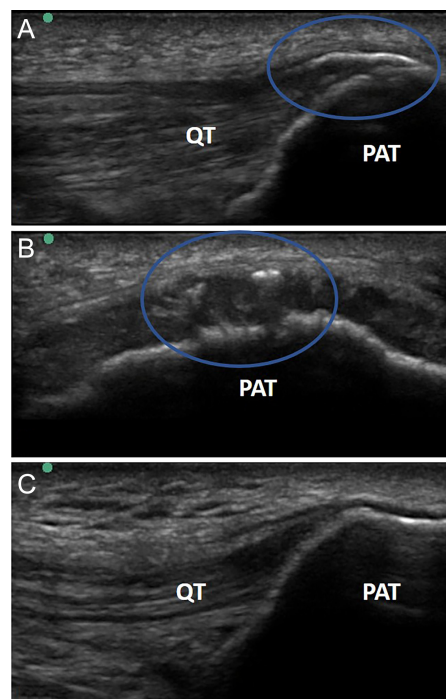


Figure 1. A-C. Sono-inspection of the right quadriceps femoris tendon in long- (A) and short- (B) axis views. Left/normal side (long-axis view) (C). QT, quadriceps tendon; PAT, patellar bone.

understanding of the symptomatology and tissue biomechanics) but also targeted interventions might be planned accordingly.

Second, we also aimed to highlight the contribution of fascia in the overall/pertinent symptomatology in enthesopathies.² As a side note, other than enthesopathies commonly seen in rheumatic diseases, mechanical stress is usually the inciting event that triggers the cascade and repetitive cycle of inflammation and pain. Recent research highlighted that fasciae own a greater/homogeneous distribution of the neural network compared to the adjacent muscles. Moreover, undergoing tractions, they also have a role in force transmission.³ Concerning our case, the quadriceps tendon is in continuity with the fascia lata that influences/overstres-

ses the tendon.⁴ Therefore, the fascia should be manipulated to reduce the mechanical stress of the quadriceps tendon and the anterior knee compartment.

Peer-review: Externally peer-reviewed.

Author Contributions: Concept - C.P., C.S.; Supervision - R.D.C.; Data Collection and/or Processing - N.P.; Analysis and/or Writing - C.P.; Critical Review - C.S., L.Ö.

Declaration of Interests: The authors have no conflicts of interest to declare.

Funding: The authors declared that this study has received no financial support.

References

1. Özçakar L, Kara M, Chang KV, et al. EURO-MUSCULUS/USPRM. Basic scanning protocols for knee. *Eur J Phys Rehabil Med.* 2015;51(5):641-646.
2. Pirri C, Stecco C, Fede C, De Caro R, Özçakar L. Dynamic ultrasound examination of the paratenon and fascia in chronic achilles tendinopathy. *Am J Phys Med Rehabil.* 2021;100(5):e75. [\[CrossRef\]](#)
3. Stecco C, Pirri C, Fede C, Yucesoy CA, De Caro R, Stecco A. Fascial or muscle stretching? A narrative review. *Appl Sci.* 2021;11(1):307. [\[CrossRef\]](#)
4. Pirri C, Fede C, Petrelli L, et al. An anatomical comparison of the fasciae of the thigh: a macroscopic, microscopic and ultrasound imaging study. *J Anat.* 2021;238(4):999-1009. [\[CrossRef\]](#)